Exam One Study Guide

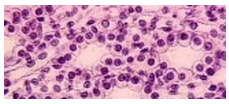

Simple Cuboidal Epithelium

Simple Cuboidal Epithelial Tissue**Simple cuboidal epithelium** is found in organs that are specialized for secretion, such as salivary glands and thyroid follicles, and those that are specialized for diffusion, such as the kidney tubules. As its name implies, this tissue consists of a single layer of **cuboidal** cells on the basement membrane.

Simple Cuboidal Epithelium - appears as a set of somewhat organized "cubes". Cuboidal cells are seen packed more tightly together in tissues than squamous cells. The nuclei of cuboidal epithelial cells usually appear round and are located at the center of the cell.

Simple cuboidal epithelium is found in organs that are specialized for **secretion**, such as salivary glands and thyroid follicles, and those that are specialized for**diffusion**, such as the kidney tubules. The main function of simple cuboidal cells in glands is secretion and absorption. The main function in the kidney tubules is diffusion. The slide we have for the practical are from the kidney tubules.
Slides of simple cuboidal epitheliual tissue taken from kidney tubules. This accounts for the circular arrangement of the cells. The simple cuboidal epithelial tissue appears as a single layer of cube-like cells. The nuclei are relatively large, round and centrally located within the cuboidal cells.

Why is Anatomy so Latin??

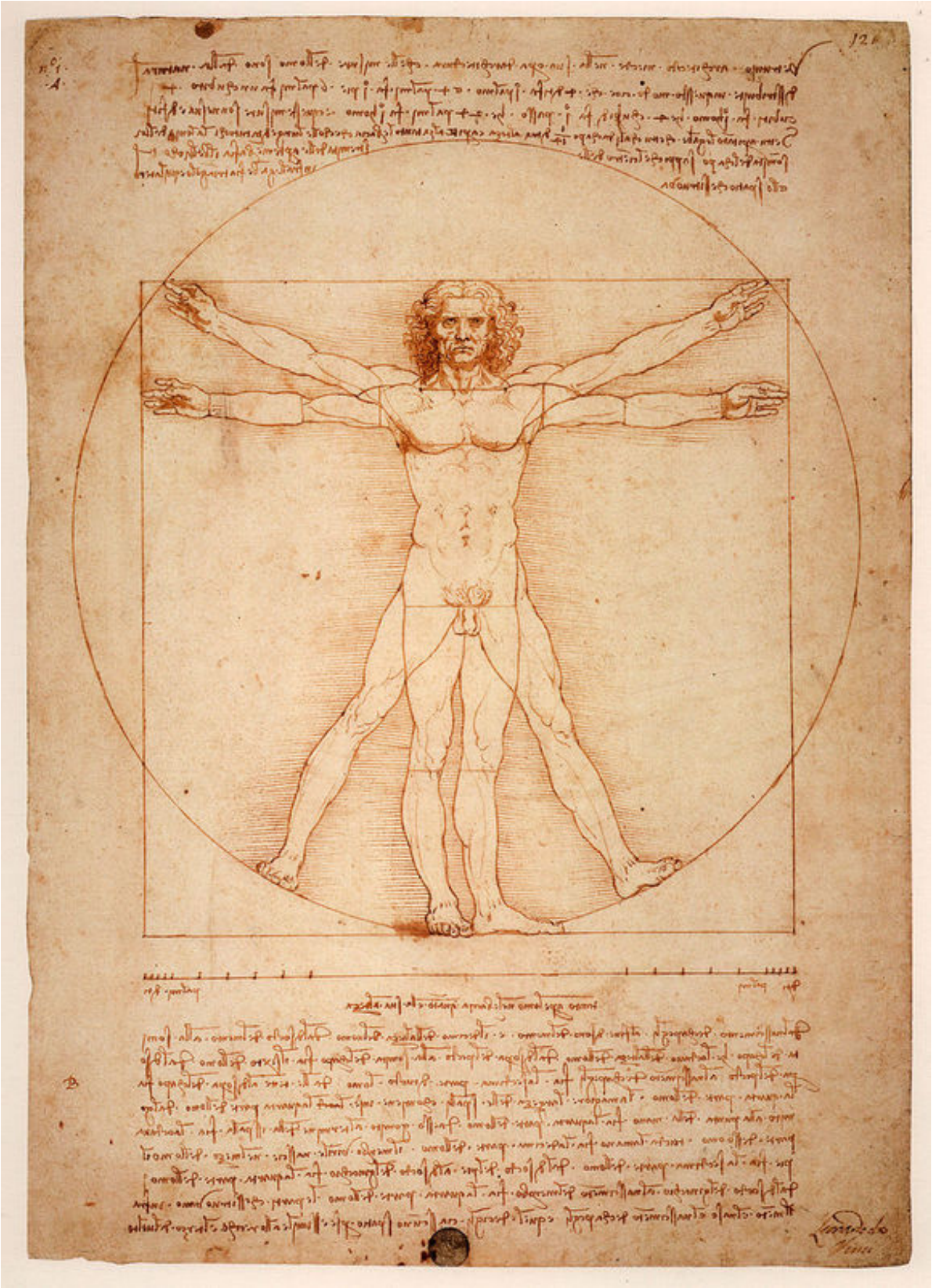

Latin was intended to be a universal language that would be spoken by all scholars throughout the world. So the ideas is that the greatest minds would be able to communicate with each other and to share ideas! But... that's not all! Latin was also set to NOT change with time in order to preserve knowledge for future generations!

Many languages change over time.

If you read a text written in Old English, you may find it challenging to interpret, even as an English

speaker. Several documents exist today that experts cannot interpret because the language or dialect in which it was written has essentially "died out".

The idea of using a universal language for scholars (LATIN) was to preserve important knowledge for future generation.

Latin as a universal language persisted through the Renaissance Era. The idea of Latin as the universal language began to fall out of favor in the 1700's. However, the Latin roots in medical terminology and anatomy have remained intact.

What is Anatomy?

We often hear the terms "anatomy" and "physiology" used together, but do you know what they mean? The terms are definitely related. **Anatomy** refers to structure and **physiology** refers to function.

ANATOMY comes from the Latin word "anatomia" which means "to cut up". ANATOMY is defined as the study of *STRUCTURE* of the body, whereas PHYSIOLOGY is defined as science of the *FUNCTION* of living things.

The Complementarity of Structure and Function

The over-arching concept of anatomy and physiology is **"the complementarity of structure and function".** We can see how anatomy and physiology are so intertwined by comparing the structure of a body part with the function of that body part. You will find that the structure of a given anatomical feature will be directly related to its function, and the function of an anatomical feature will depend upon the structure.

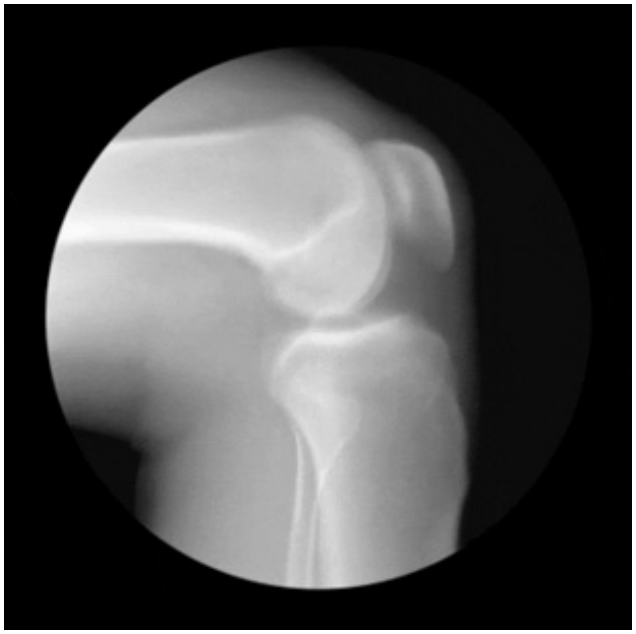

Hierarchical Levels of Anatomy

There are six hierarchical levels of anatomy and physiology.

(1) Chemical level
(2) Cellular level
(3) Tissue level
(4) Organ level
(5) Organ system level
(6) Organism level

The Chemical Level

The chemical level is the level of the ATOMS - A ll matter in the universe as we know it, is made up of atoms. It is for this reason that **we define the atom as <u>the fundamental unit of matter</u>.**

Picture

ANIMATED GIF Courtesy of Source imgur.com via GIPHY

The Cellular Level

<u>The cell is the fundamental unit of life.</u> All living things are made up of one or more cells.

Cells and their surroundings are made up of molecules. It takes about 100 trillion atoms to make a typical cell. Proteins, lipids, carbohydrates and nucleic acids are arguably the 4 most important molecules for the cell, *and for life in general*.

Animated GIF courtesy of http://giphy.com/gifs/black-and-white-life-99XYfEEF2QV7a via GIPHY

The Tissue Level

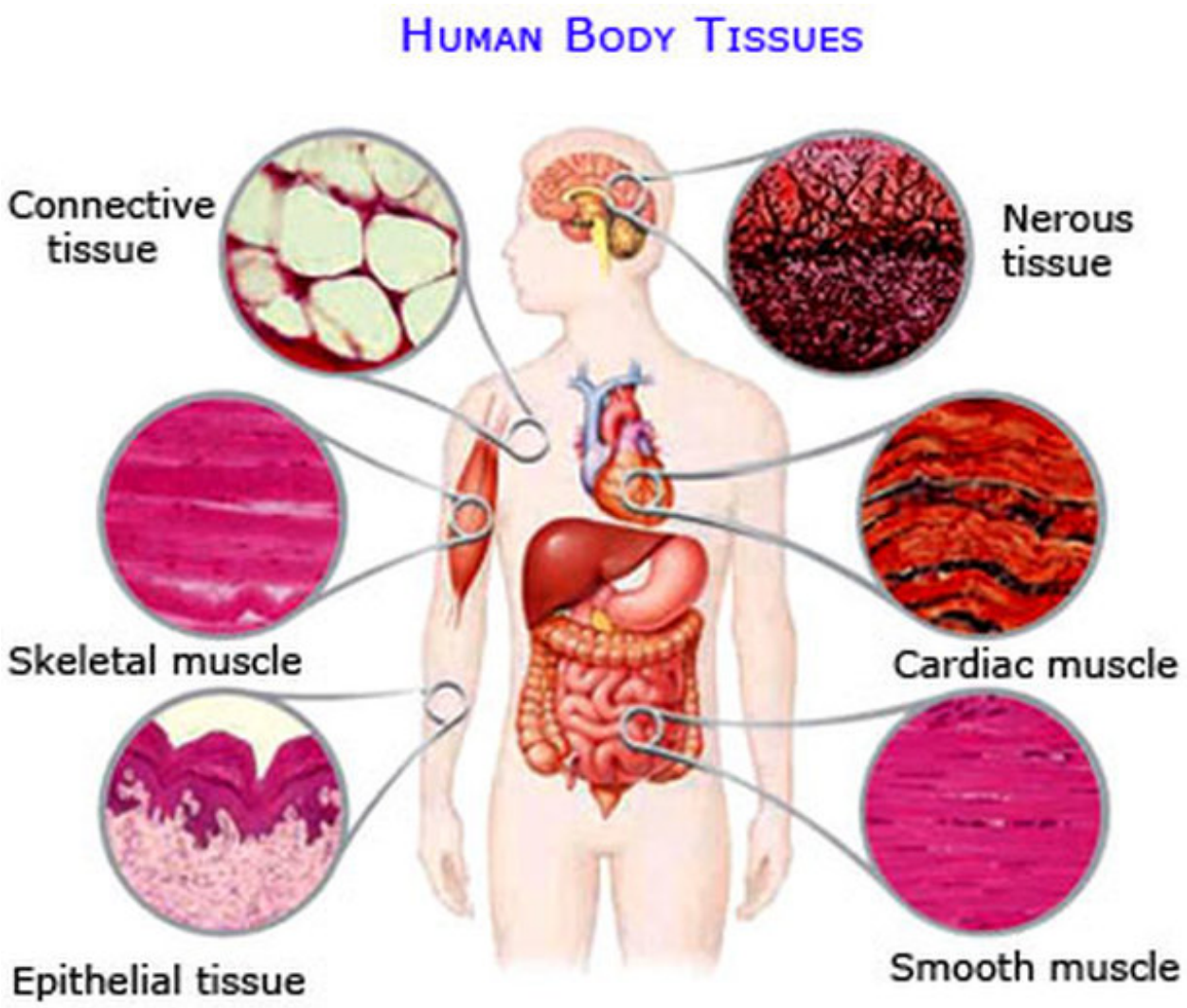

Cells of similar types come together to form tissues. A TISSUE is a group of two or more cells (of similar function or origin) that come together to perform a common function.

Tissue level:

<u>There are 4 types of tissues</u>

1. Epithelial (skin) Tissue
2. Connective Tissue
3. Nervous Tissue
4. Muscle Tissue

Muscle Tissue
The body contains three types of muscle tissue:

1. skeletal muscle
2. smooth muscle
3. cardiac muscle.

The Organ Level

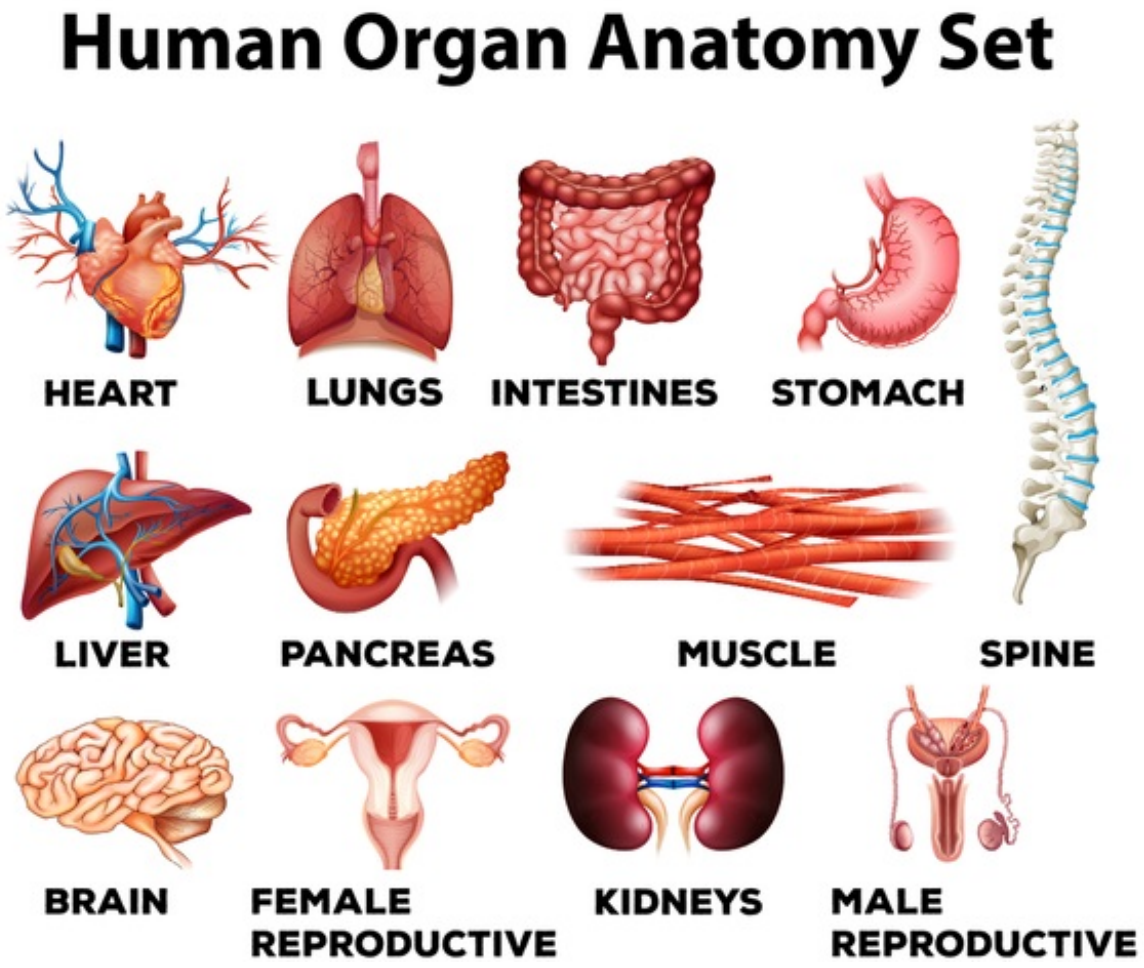

An organ is a discrete structure made up of multiple tissue types (2 or more) that work together as a functional unit for the body.

Organs that are found anywhere in the ventral cavity, can be referred to as **visceral organs**. The word "visceral" or "viscera" refers specifically to the internal organs that lie in the thoracic or abdominal regions of the body. In a figurative sense, something "**visceral**" is felt "deep down."

The Organ System Level

There 11 Organ Systems of the Human Body. An organ system is a group of organs and associated structures that perform a specific function in the body. Examples of organ systems include the cardiovascular system, nervous system, endocrine system, urinary system, reproductive system, digestive system, lymphatic system, endocrine system, urinary system, muscular system and the skeletal system.

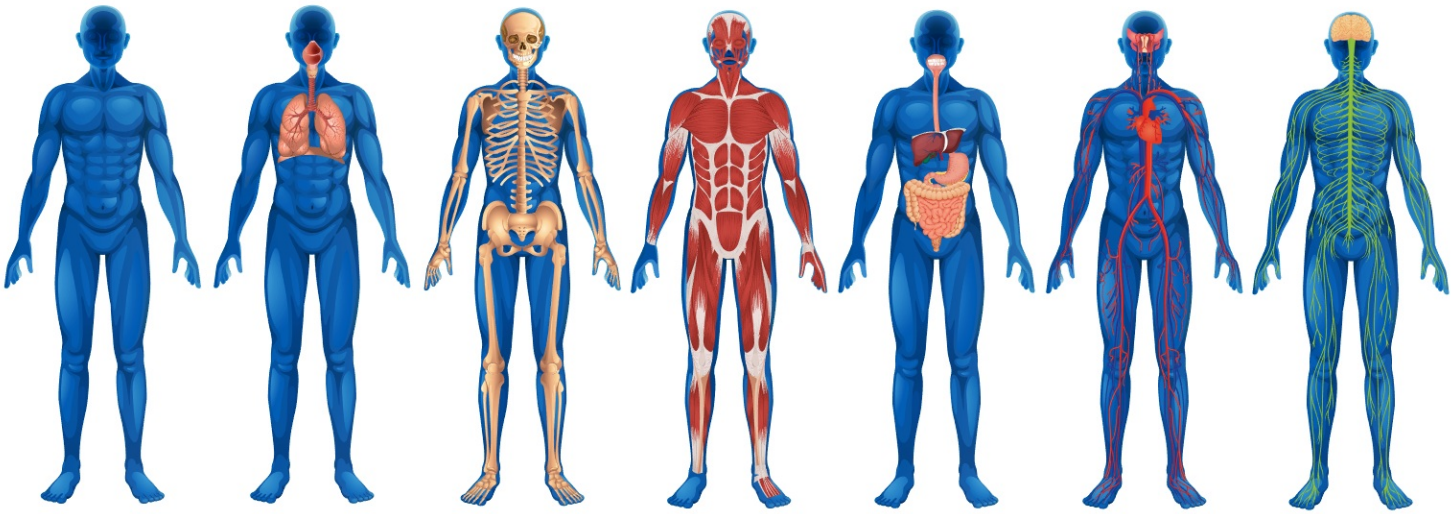

The Organism Level

The level of the organism looks at how all of the anatomical structure of body work together to provide all of the necessary functions for life.

ANATOMICAL POSITIONS

TERMINOLOGY

When anatomical positioning is discussed, we must have a standard position (see image) that we refer to as a "frame of reference". In anatomy, whenever we use positional terminology, we ALWAYS refer to the position AS IF the patient was in the "anatomical position"

In the *anatomical position*, the body is upright, directly facing the observer, feet flat and directed forward. The upper limbs are at the body's sides with the palms facing forward.

Also, the "right side" of the body, refers to the patient's right side. The "left side" of the body, refers to the patient's left side.

Ipsilateral* = *same side
Contralateral* = *opposite side

Anterior = Front
Posterior = Back
Midline = Right Down the Middle
Lateral = away from the midline
Medial = Toward the Midline
Superior = Above
Inferior = Below
Superficial = Surface / Shallow / near the surface
Deep = far below the surface of the skin
Proximal = Point on a limb that is close to the body
Distal = Point on a limb that is far from the body

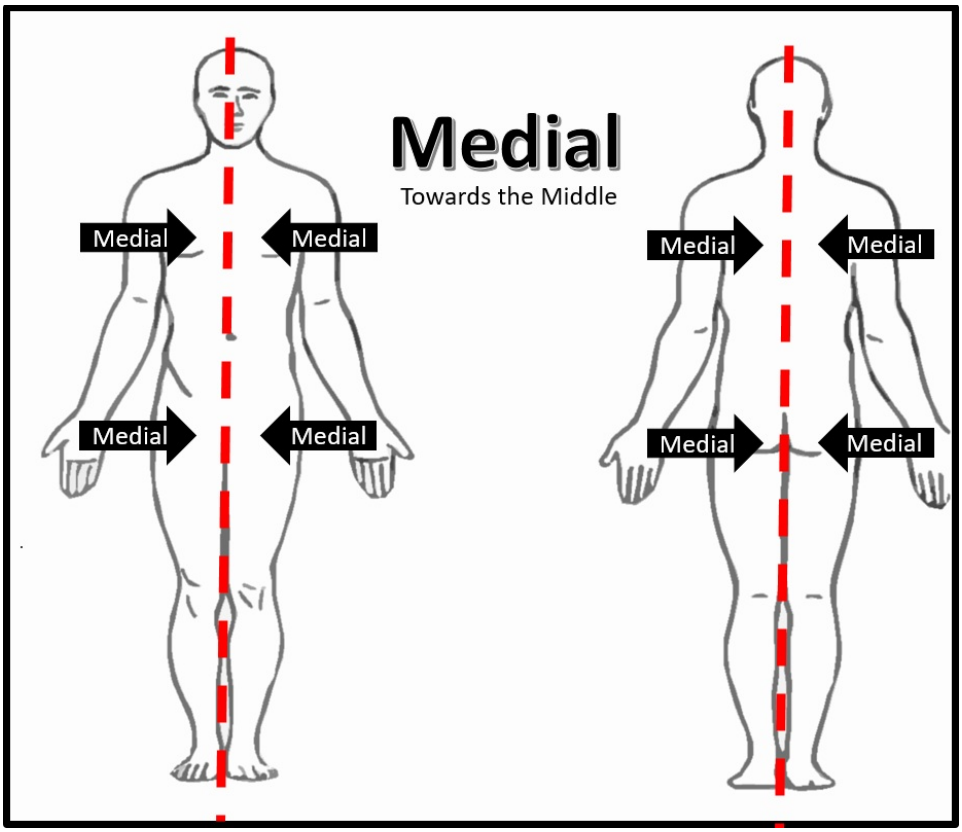

Midline = The midline is the imaginary line down the middle of a person that would perfectly bisect them into equal right and left halves.

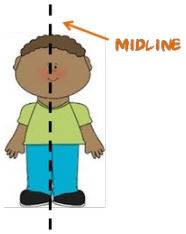

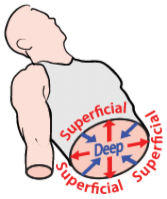

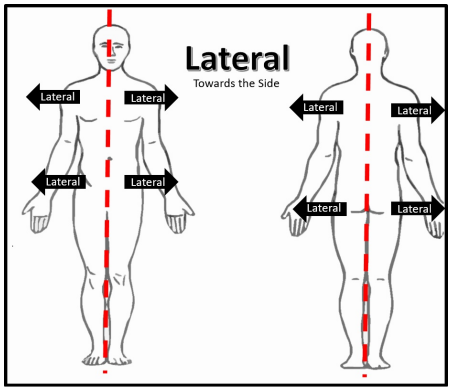

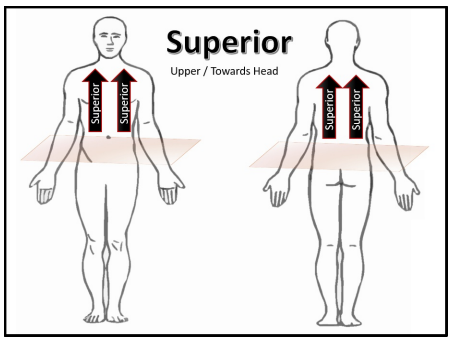

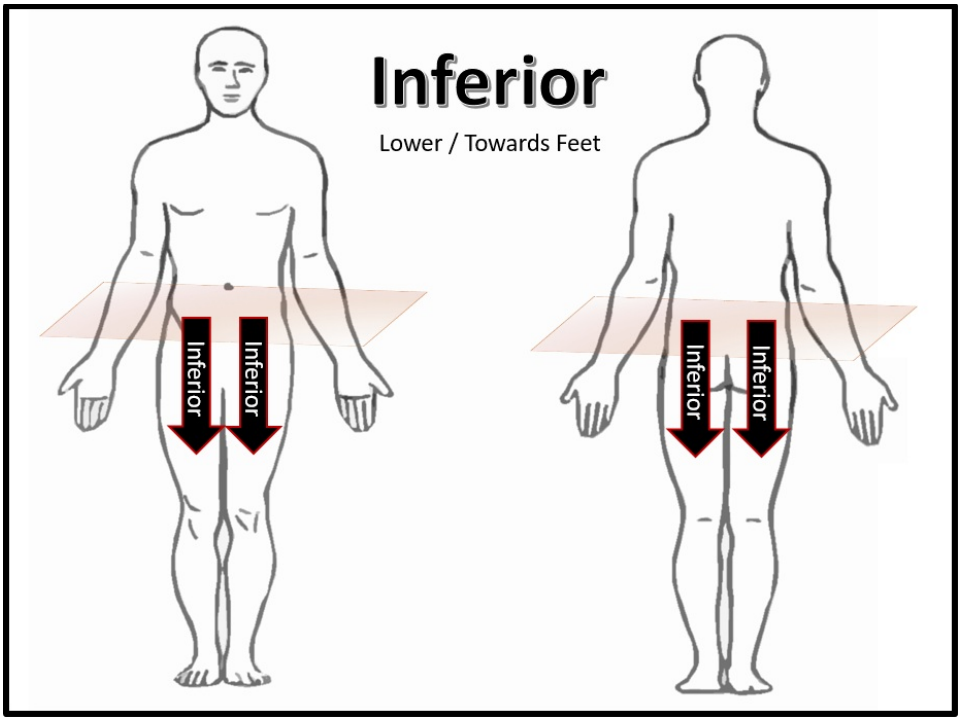

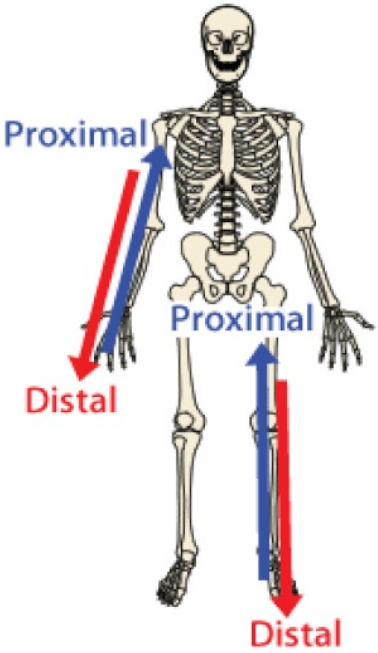

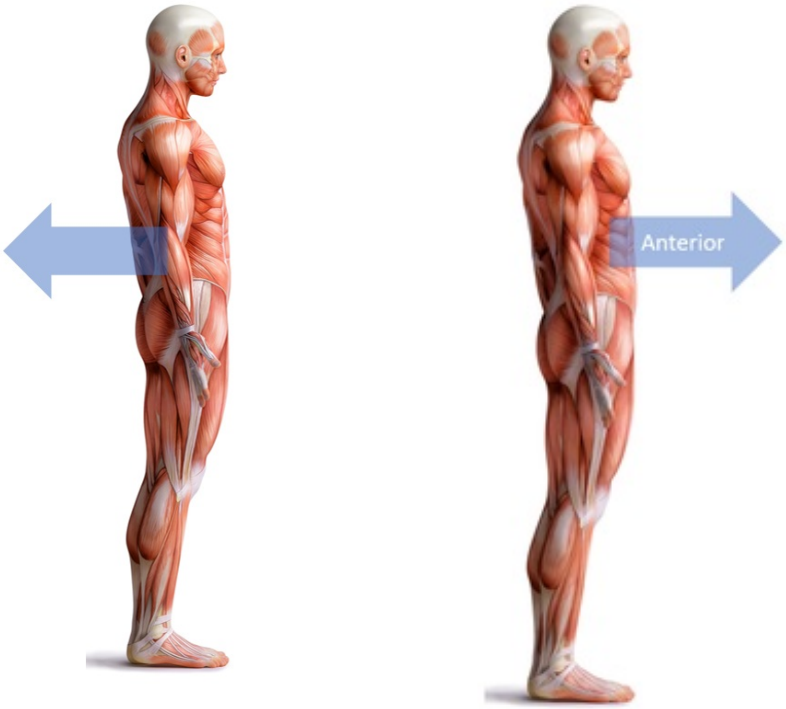

posterior

anterior

PLANES OF THE BODY

Special Types of Sagittal Planes

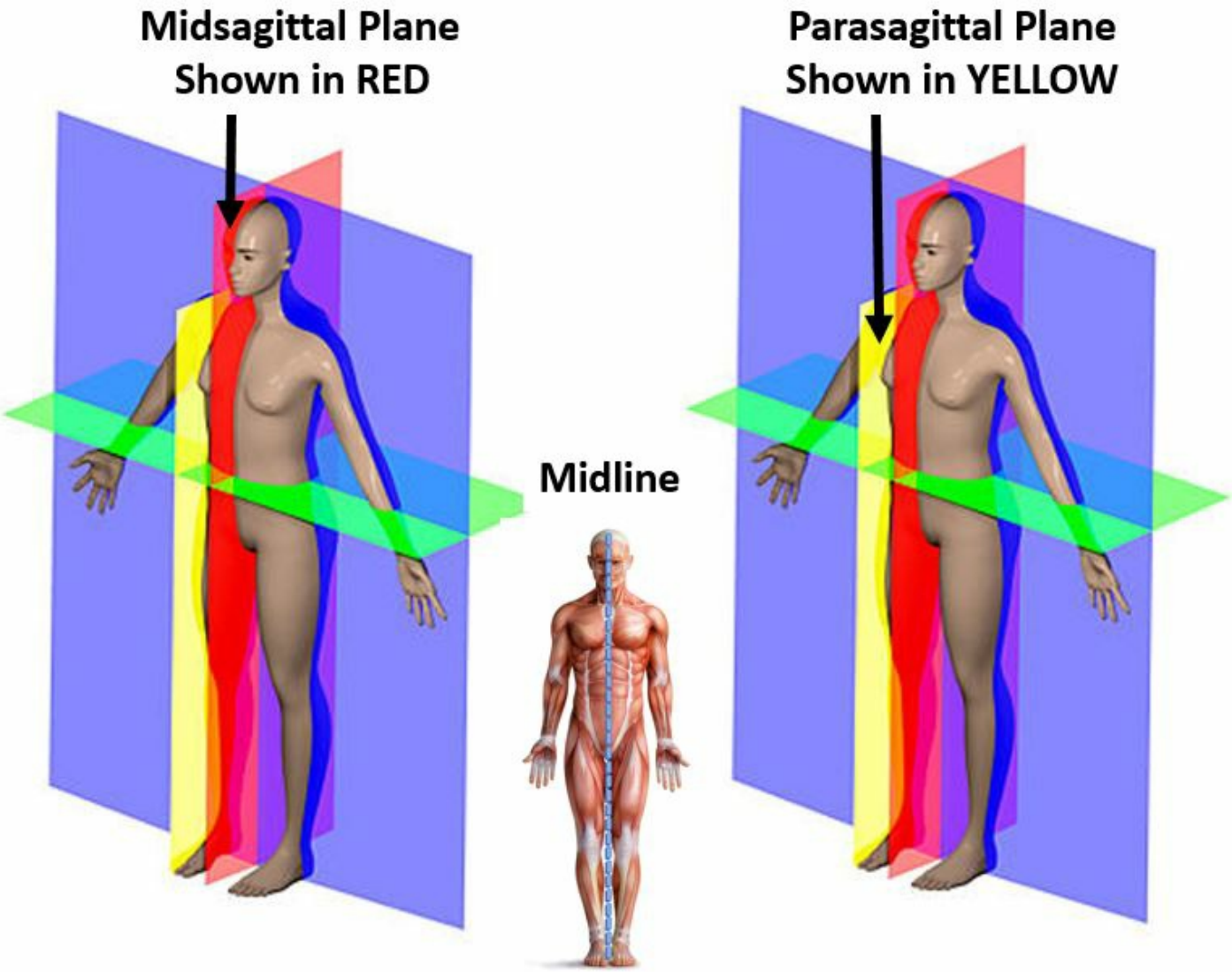

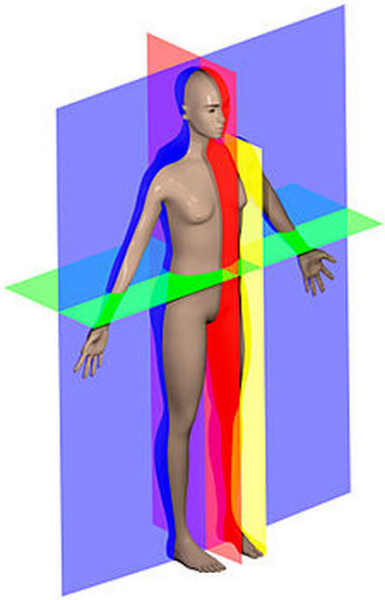

Anatomical Planes of the Human Body

The plane shown in BLUE is the coronal plane.

The plane shown in GREEN is the transverse plane (also called a cross section).

The plane shown in RED and the plane shown in YELLOW are both sagittal planes, but they can also be referred to as...

The plane shown in RED is the sagittal plane that is exactly at the midline and it can be more specifically referred to as the midsagittal plane.

The plane shown in YELLOW is called a parasagittal plane. When a sagittal plane is moved either right or left from the midline, it is considered a parasagittal plane.

.

The Sagittal Plane - The sagittal plane runs vertically through the body dividing the body into the left (sinister) and right (dexter) sides .

Oblique - Oblique sections are not very useful in most situations in medicine. It is rare to see this type of section done in histology or when using imaging techniques. However, this term can be used to characterize the angle of a wound.

Transverse Plane -The transverse plane separates the body horizontally. A "transverse section" can also be called a "cross-section" of the body. This plane separates the superior (*or upper*) part of the body from the inferior *(or lower)* part of the body.

Coronal Plane - The **coronal plane** (also known as the **frontal plane**) divides the body into front (ventral or anterior portion of the body) and *back (posterior or dorsal)* portion of the body.

BODY REGIONS

Head and Neck Anatomical Regions

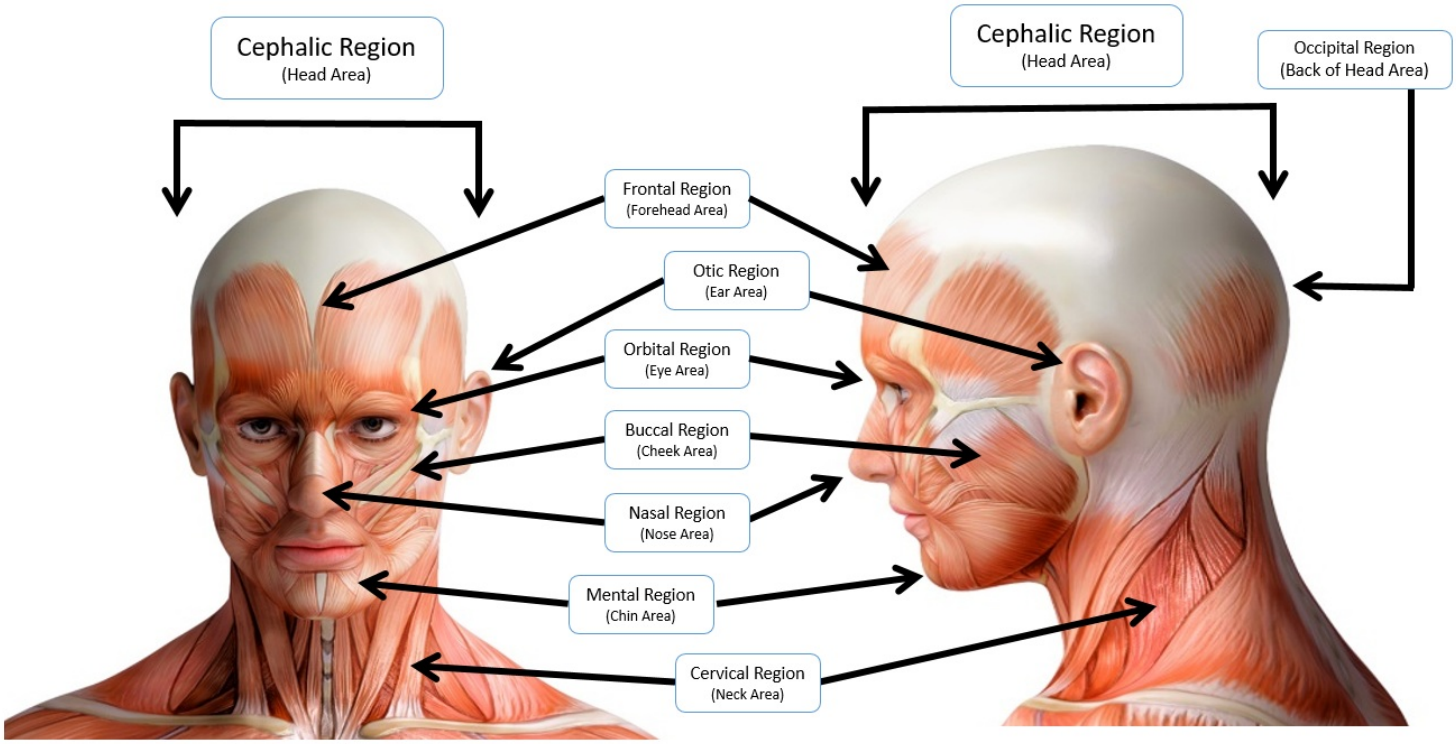

Thorax Anatomical Regions

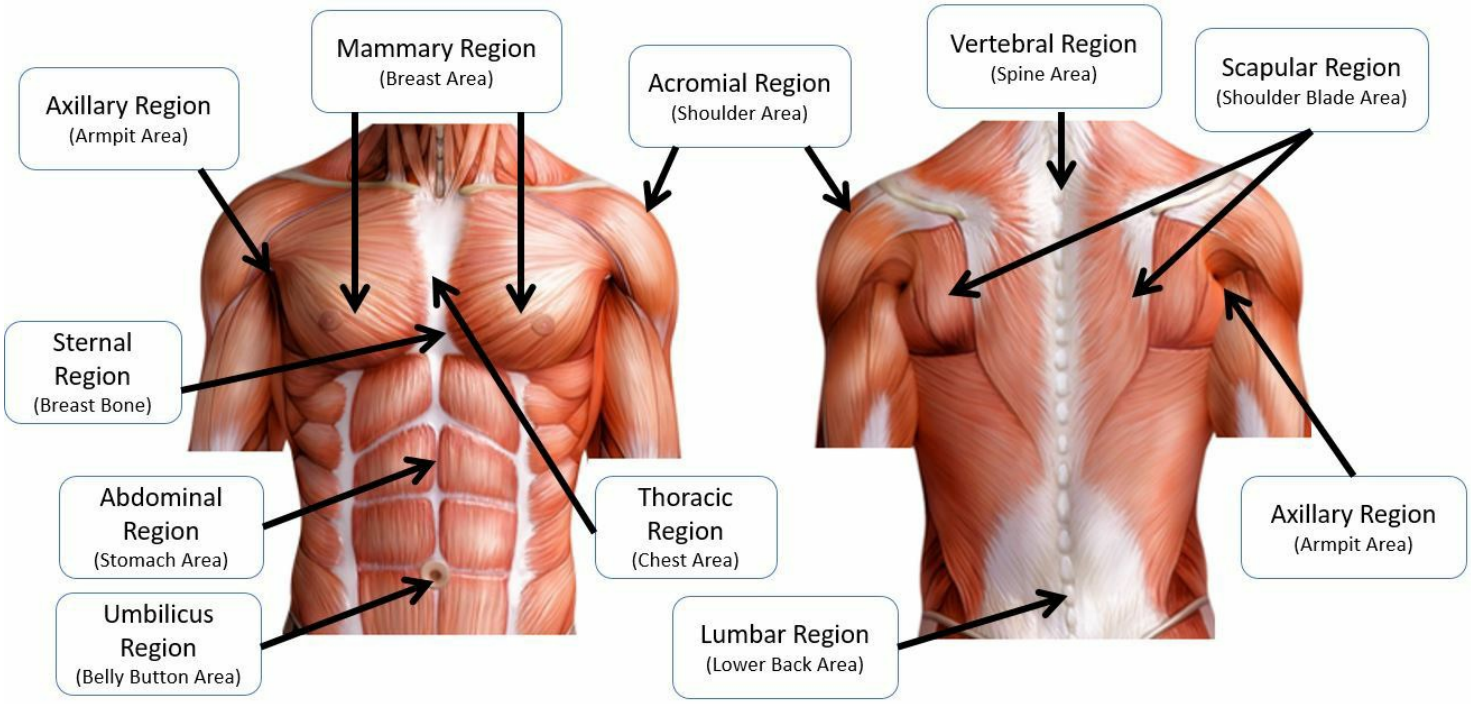

Arm Anatomical Regions

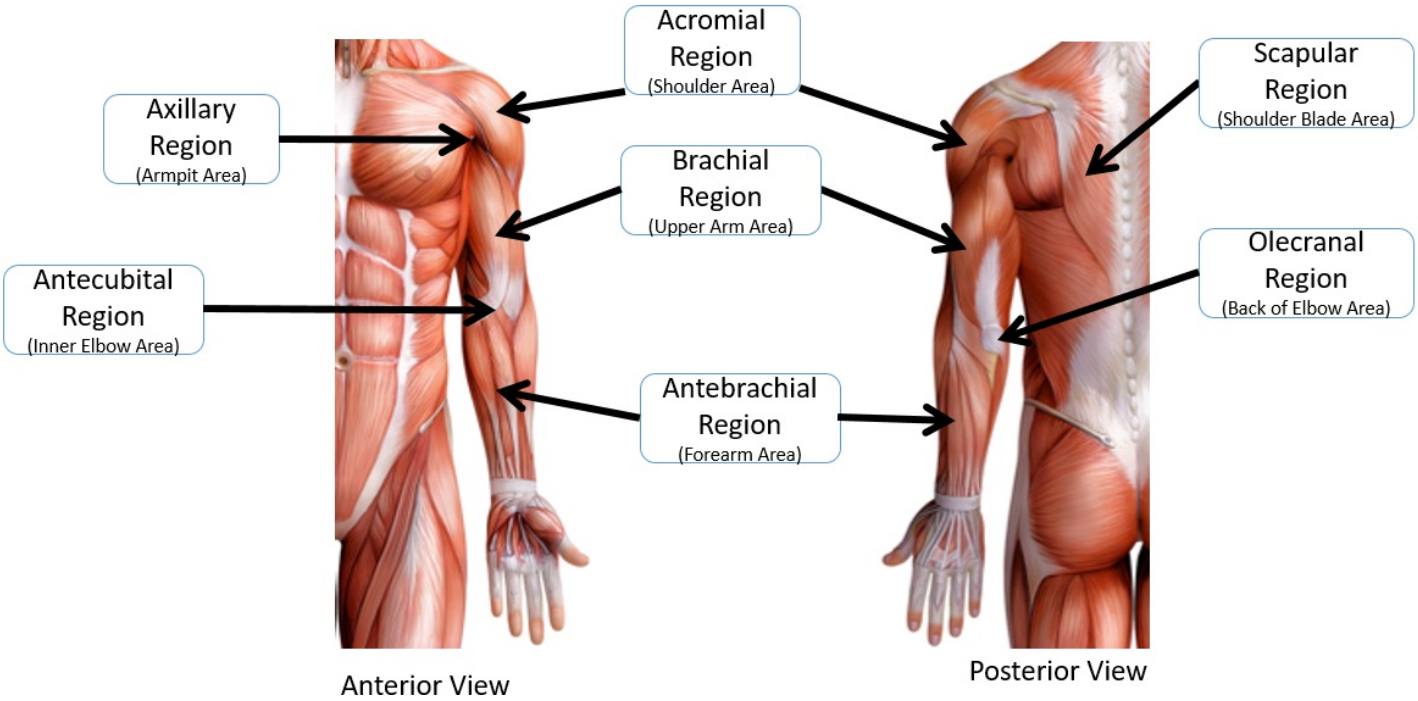

Hand Anatomical Regions

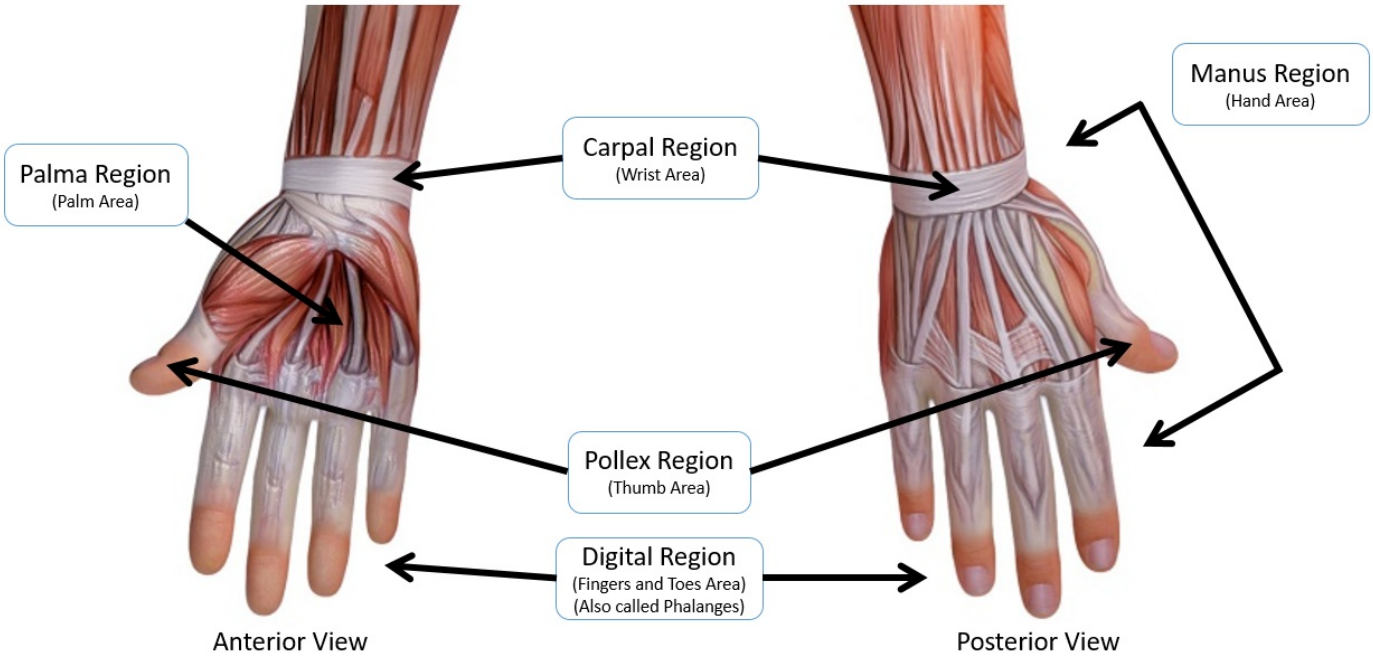

Pelvic Anatomical Regions

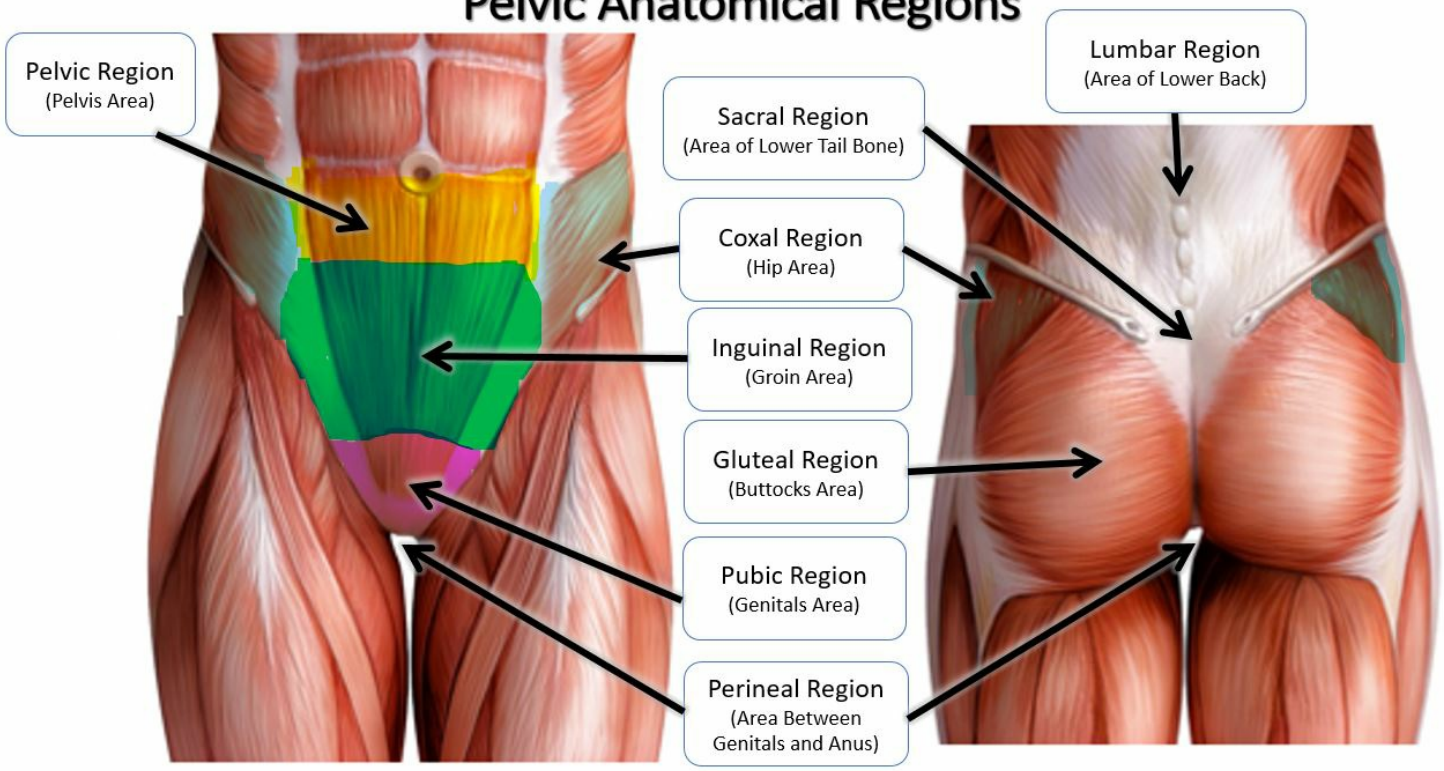

Leg Anatomical Regions

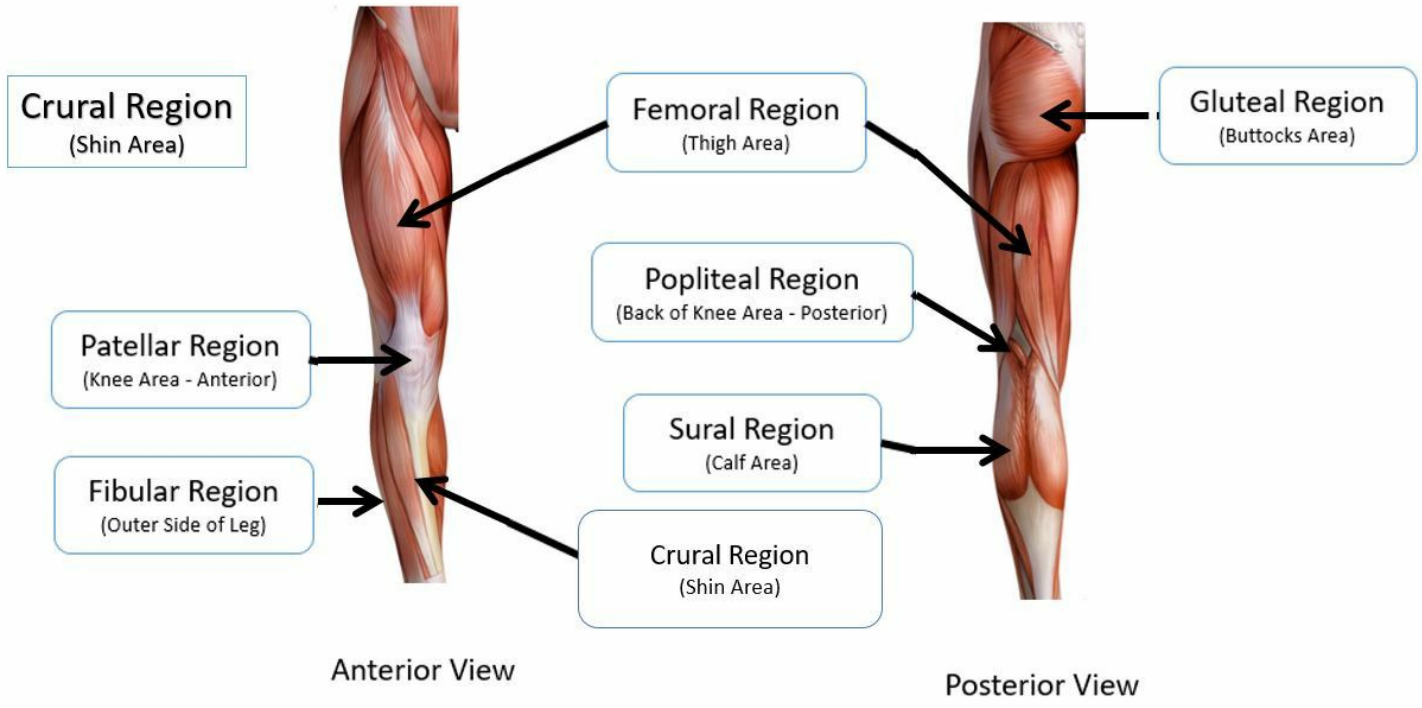

Foot Anatomical Regions

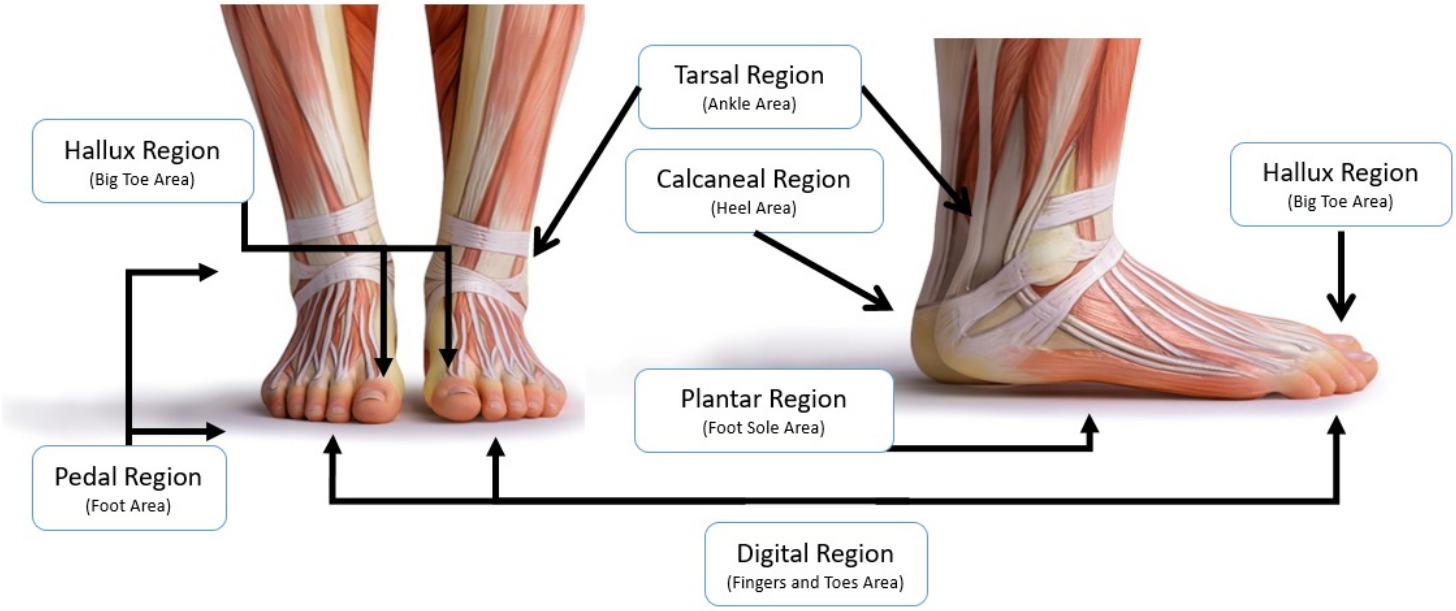

BODY CAVITIES AND MEMBRANES

In anatomy you learn that the human body is, in a sense, a glorified tube. (*I can almost hear you GASP!*) OK, a tube is an over simplification, but the premise holds true. The inside and the outside of your *tube* is covered with epithelial tissue. This *tube* has some specialized regions that are made up of concave regions (also lined with epithelium) that are connected to the outside. You also have fluid-filled chambers inside of your body that is NOT connected to the outside. All of these regions are considered **CAVITIES**.

The definition of a body cavity - a body cavity is considered to be any fluid-filled space in the body, other than vessels (blood and lymph).

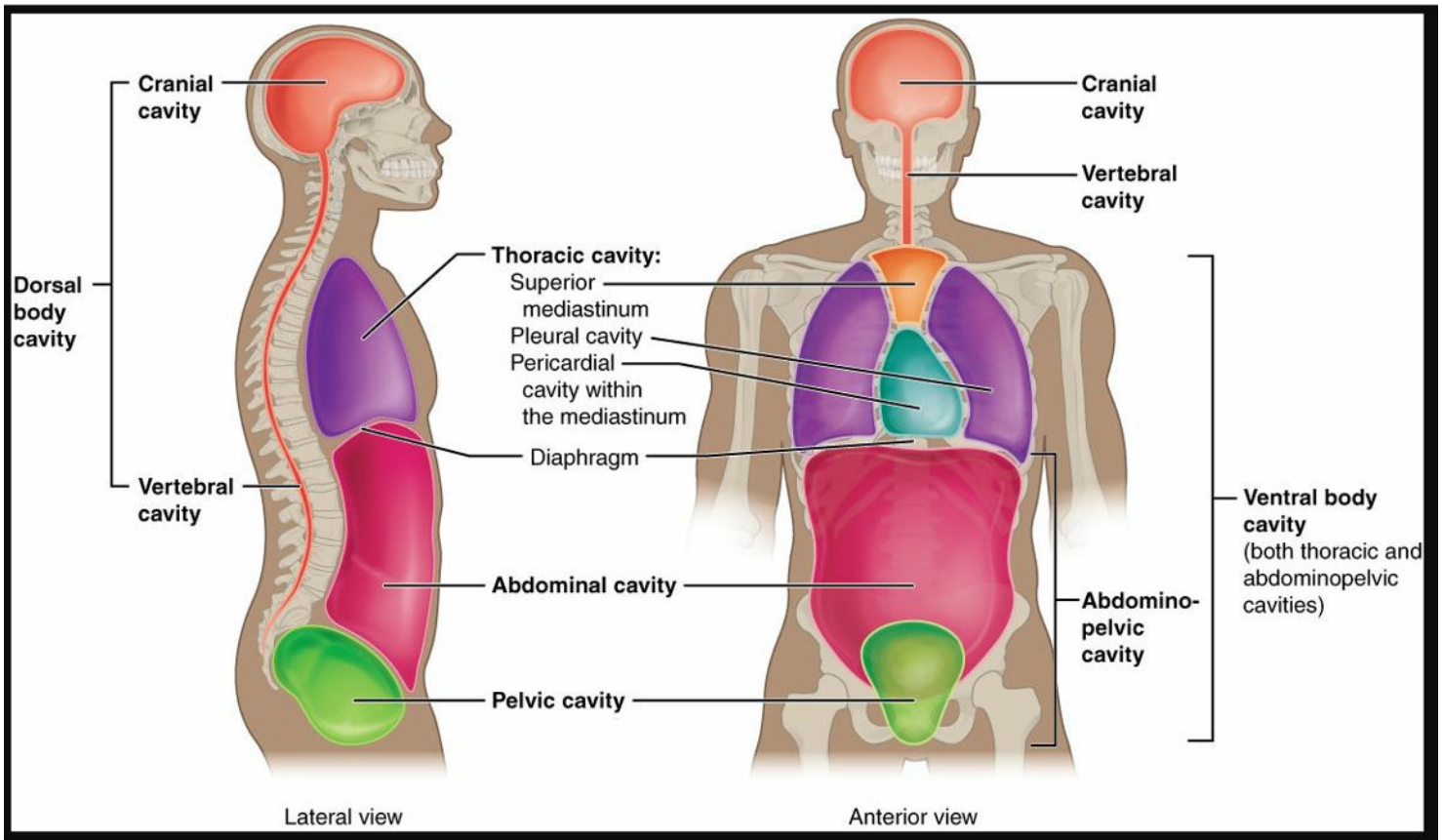

Body Cavities

http://anatomybody-charts.us/wp-content/uploads/2016/03/thoracic-cavity-diagram-thoracic-cavity-diagrams.jpg

The human body has 2 main body cavities.

1. **the dorsal (or posterior) cavity**
2. **the ventral (or anterior) cavity**

The Dorsal (or Posterior) Cavity has 2 regions

1. The Cranial Cavity
2. The Vertebral (or Spinal)

The dorsal cavity consists of the cranial cavity that houses the brain and the vertebral (or spinal) cavity which contains the spinal cord. There is no separation between the vertebral and cranial cavities. This cavity is a continuous chamber filled with cerebrospinal fluid that surrounds the brain and the spinal cord. "*Cerebro-"* means "brain" and "spinal" means "of the spine", so the liquid cerebrospinal fluid is named after what it essentially bathes, which is the brain **and** spine.
The Ventral (or Anterior) Cavity has 2 regions

- The Thoracic Cavity
- The Abdominopelvic Cavity

The ventral (or anterior) cavity contains the body's ***visceral* organs**. The visceral organs are your body's internal organs, including the heart, the lungs, the liver, the pancreas and the intestines.

The **ventral cavity** of the human body is divided into two main regions;

1. the **thoracic cavity**
2. the **abdominopelvic cavity**

The thoracic cavity and the abdominal cavity are separated by the **diaphragm**.

Subdivisions of the Thoracic Cavity are as Follows:

*The thoracic cavity is separated into three chambers; the left and right **pleural cavities** and the **mediastinum** that sits between the pleural cavities.* The **thoracic cavity** is the cavity of the chest area. This cavity lies underneath the rib cage and houses many important organs and structures of cardiovascular, respiratory and lymphatic systems. The two arguably most notable organs of the thoracic cavity are the **heart** and the **lungs**.

The Pleural Cavities
The left lung is in the left pleural cavity and the right lung is in the right pleural cavity.

The Mediastinum Cavity
The space between the 2 pleural cavities is the mediastinum, which holds the pericardial cavity which contains the heart (see illustration).

Subdivisions of the Abdominopelvic Cavity

The Abdominopelvic Cavity
The abdominopelvic cavity is divided into 2 areas; the **abdominal cavity** and the **pelvic cavity.**

The Abdominal Cavity
The abdominal cavity contains digestive organs., including the stomach, the liver, the kidneys, the small intestines, etc.

The Pelvic Cavity
The pelvic cavity contains the internal reproductive organs, the urinary bladder and the rectum.

There are other body cavities in addition to the dorsal and ventral cavities. These other cavities, however, are accessible from the outside of the body.
This includes the oral cavity, the nasal cavity and the orbital cavity.

Membranes It is important to also know about the membranes that line the body's cavities, as well. The body's cavities are lined with a specialized membrane, called the **serous membrane (serosa).** The serous membrane supplies the cavity with a constant supply of **serous fluid** that is secretes**.**

- The serous membrane (serosa) is a thin membrane that covers the walls and organs of the ventral cavity.
- **PARIETAL SEROSA** - The portion of the serous membrane that covers the walls of the cavity is called the **parietal serosa.**
- **VISCERAL SEROSA -** The portion of the serous membrane that covers the internal organs (*or viscera*) is referred to as the **visceral serosa.**

Some areas of the serous membrane (serosa) have special names. For example, the serosa of the pericardial cavity that houses the heart is called the **pericardial membrane,** and the serosa that lines the peritoneal cavity that surrounds most of the organs of the abdomen, is called the **peritoneum**.

ANATOMY OF THE CELL

The **cell membrane** is also called the **plasma membrane**. You can think of the membrane as the "skin" of the cell. Anything outside of the cell is considered "**extracellular**" and the contents inside the cell are considered "**intracellular**". The cell membrane **protects** the cell by creating a barrier between what is inside the cell and what is outside the cell. The cell membrane is made up of a double layer of phospholipids. Proteins, sugars and lipids are also incorporated into the cell membrane.

Regions of the Cell
The 3 Main Regions of the Cell are
1) Cell Membrane (Plasma Membrane)
2) Cytoplasm (Cytosol and Cytoplasmic Organelles)
3) Nucleus

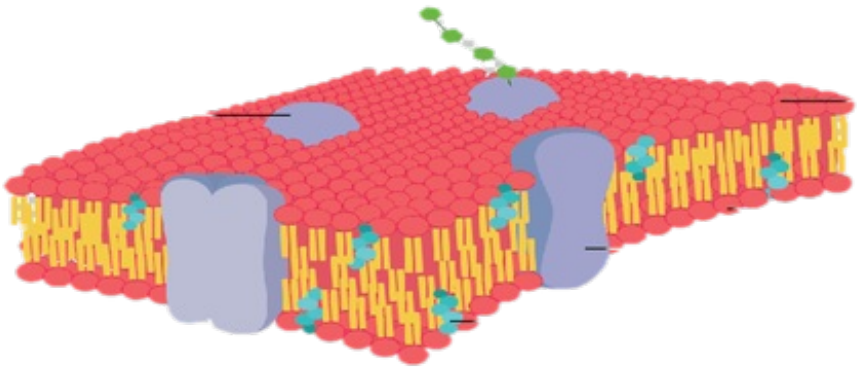

The Cell Membrane (Plasma Membrane)
- The Main Function of the Cell Membrane is PROTECTION - The **cell membrane** is also called the **plasma membrane**. You can think of the membrane as the "skin" of the cell. Anything outside of the cell is considered "**extracellular**" and the contents inside the cell are considered "**intracellular**". The cell membrane **protects** the cell by creating a barrier between what is inside the cell and what is outside the cell. The cell membrane is made up of a double layer of phospholipids. Proteins, sugars and lipids are also incorporated into the cell membrane.

T**he cell membrane surrounds the entire cell and act as protection. You can think of the cell membrane as acting like our skin!**

In addition to this, the cell membrane does something our skin can't do... It **regulates** what comes into the cell and what goes out of the cell. For this reason, we consider the cell membrane to be**"SELECTIVELY PERMEABLE"** which means that it allows *some* substances to enter or exit the cell, but not others. This is a very important function.

The Cell Membrane is selectively permeable due to its structure. The cell membrane is made up of a phospholipid bilayer.

Nucleolus

The Main Function of the Nucleolus is to Make Ribosomes

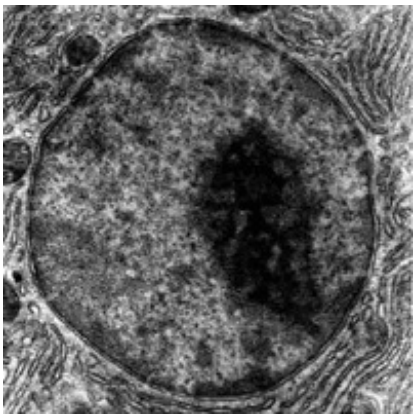

- The nucleolus is located inside of the nucleus. It is the largest structure residing inside of the nucleus. Its primary function is to make ribosomes. The ribosomes then leave the nucleus through one of the nuclear pores. Ribosomes function as the site of protein synthesis for the cell.

The nucleolus is usually visible as a darkened area lying within the cell's nucleus.

The Rough Endoplasmic Reticulum (The Rough ER)

The rough ER gets its name from its 'bumpy' or 'rough' appearance due to ribosomes that are attached to it. In the rough ER, ribosomes are assembled in the nucleolus and then exit the nucleus. Some of these ribosomes then attach themselves to the rough endoplasmic reticulum, where they will act as a "site of protein synthesis" for the cell. The rough ER is composed of a network of membranous sacs or envelopes and tubules. The outside of the rough ER appears 'rough' due to attached ribosomes.

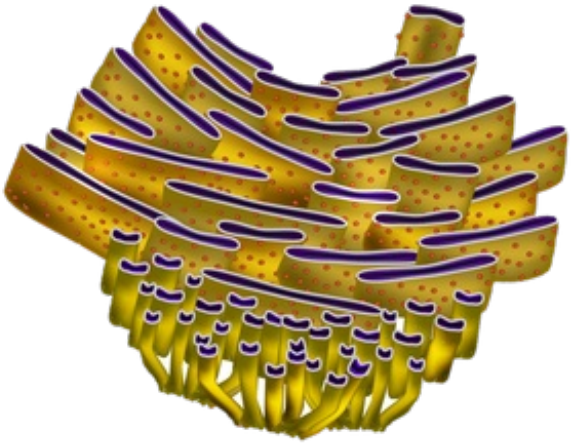

The Smooth Endoplasmic Reticulum (The Smooth ER)

The Main Function of the Smooth ER is to Make Lipids The smooth endoplasmic reticulum (Smooth ER) appears smooth in comparison to the rough ER. This is because the smooth ER does not have ribosomes bound to it. The structure of the smooth ER is similar to that of the rough ER in the fact that it is composed of a membranous system of sacs or envelopes and tubules. Its structure differs in the fact that it appear smooth since it does not have ribosomes attached to it. The smooth ER's main function is to make lipids. The smooth ER also functions to synthesize steroid hormones, metabolize lipids and even acts assists in detoxification of the cell.



RIBISOMES

The Main Function of a Ribosome is to Be the Site of Protein Synthesis,

RIBOSOMES - Particles composed of RNA and protein that are involved with messenger RNA in the synthesis of proteins.

After the ribosome is assembled (made) in the nucleolus, it leaves the nucleus. Some ribosomes will end up as "**free ribosomes"** that remain unattached in the cytosol. Other ribosomes will attach to the nearby Rough Endoplasmic Reticulum.

All ribosomes function as **"the site of protein synthesis".** Free ribosomes are used as the site for making water-soluble proteins, whereas the ribosomes that are attached to the rough endoplasmic reticulum act as the site for making proteins that will either be incorporated into the cell membrane or will be transported out of the cell (via exocytosis).

The ribosome is the location of the assembly of the amino acid sequence that makes up the protein. mRNA is used as a template for the amino acids that are to be used.

The ribosome is composed of two subunits that are made of ribosomal RNA (rRNA) and protein.

Phospholipid

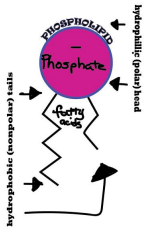

The phospholipid bilayer of the cell membrane has a unique structure. It is made up of an inner layer and an outer layer of phospholipids that are oriented with their 'tails' facing each other.

Phospholipids are considered **amphiphilic,** because they contain a polar, hydrophillic head that consists of a phosphate group and two nonpolar, hydrophobic fatty acid chains as 'tails'.

When the phospholipids form the cell membrane, the polar, **hydrophillic (water-loving)** heads are oriented towards the liquid outside the cells (**extracellular fluid)** and the liquid inside the cell (**extracellular fluid**). The tails of the phospholipids are oriented towards each other, away from the liquid, since they are made up of **hydrophobic (water-fearing)** fatty acid chains. This formation creates a barrier between the extracellular matrix and the **intracellular fluid (cytosol).**

ENDOPLASMIC RETICULUM The endoplasmic reticulum (ER) consists of flattened sheets, sacs and tubes that extend through the cytoplasm. The sheets may be continuous with the outer membrtme of the nuclear envelope. If the ER is studded with ribosomes that are synthesizing proteins, it is called rough ER. In contrast, smooth ER lacks ribosomes and is involved in lipid synthesis.

GOLGI BODY A system of stacked, membrane-bounded sacs. The Golgi is involved in processing macromolecules for secretion and delivery to other components of the cell.

LYSOSOMES Membrane-bounded vesicles that contain enzymes involved in the digestion of foreign elements. Conditions that result in the release of these enzymes into the cytoplasm may result in cell death.

MITOCHONDRIA Organelles present in eukaryotic cells and bounded by two membranes. They are often referred to as the power plants of cells as they are the site of aerobic respiration that combines oxygen with food molecules to generate ATP, an important energy containing molecule. Mitochondria contain circular DNA (similar to the organization of DNA in bacterial cells) that codes for some of the mitochondria! proteins. Ribosomes in mitochondria are smaller than those in the cytosol and of the same size as bacterial ribosomes.

NUCLEAR ENVELOPE The double membrane structure that surrounds the nucleus and separates it from the rest of the cytoplasm. It has nuclear pores that allow for communication between the nucleus and the cytoplasm. NUCLEAR PORES Openings in the nuclear envelope that allow for communication between the nucleus and the cytoplasm.

NUCLEOLUS Site in the nucleus where ribosomes are synthesized. NUCLEOPLASM Matrix of the nucleus, not including nucleolus and chromosomes.

NUCLEUS This is the largest organelle in most cells. It is separated from the cytoplasm by the nuclear envelope that consists of an inner and outer membrane layer. Nuclear pores in the envelope allow the nucleus to communicate with the cytoplasm. The nucleus contains most of the cell's genetic material in the DNA that makes up the chromatin fibers of the chromosomes. The nucleolus is in the nucleus and it is the site at which ribosomes are assembled.

PEROXISOMES Membrane-bounded vesicles that contain oxidative enzymes concerned with the generation and destruction of hydrogen peroxide, a molecule that would cause serious damage if it were released into the

cytoplasm

PLASMA MEMBRANE The outer boundary of the cell; also called the cell membrane. A sheet of lipid molecules (bilayer) with proteins embedded in it. The plasma membrane controls movement of materials into and out of the cytoplasm.

CHROMATIN Complex of the DNA and proteins, such as histones, in the nucleus of a eukaryotic cell.

CYTOPLASM All the material and organelles inside the plasma membrane and outside of the nucleus.

CYTOSOL Everything in the cytoplasm other than the membranebounded organelles.

CENTROSOME Region close to the nucleus in eukaryotic cells. It is an area involved in the development of microtubules (often referred to as a microtubule organizing center) that are necessary for cell movements, e.g. the mitotic spindle. Each pole of the spindle of a dividing nucleus would have a centrosome. In animal cells and most plants and fungi with motile cells, the centrosome contains a pair of centrioles.

CENTRIOLES A short cylindrical array of nine triplet microtubules. Found in animal cells and cells of most eukaryotic organisms that produce flagellate cells.



The Mitochondria
- The Main Function of the Mitochondria is to Make Energy in the Form of ATP for the Cell
The Peroxisome - The Main Function of the Peroxisome is to Detoxify the Cell
The peroxisome is a small round cytoplasmic organelle that functions to detoxify the cell. The peroxisome houses

oxidase enzymes inside of membranous sacs. These enzymes act to catalyze the breakdown of harmful substances to the cell.

The Golgi Body
(Golgo Apparatus)
The Main Function of the Golgi Body is to Package and Ship Proteins
The Golgi body functions to Modify, Package and Ship proteins! The Golgi body is able to sort the incoming proteins and can tell where their final destination should be. These proteins could be destined for a number of destination including secretion from the cell, inclusion in lysosomes, or incorporation into the plasma membrane. The Golgi Apparatus is made up of 3 – 10 “envelopes” called cisternae.

You can think of the Golgi body as the Post Office of the cell. After proteins are made at the ribosome, the proteins travel to the Golgi body. The Golgi body will modify the proteins with strings of amino acid sequences (called signaling sequences) that will tell the cell where the protein is going to go! You can think of this process as "gift wrapping" and "placing a shipping label" on the protein!

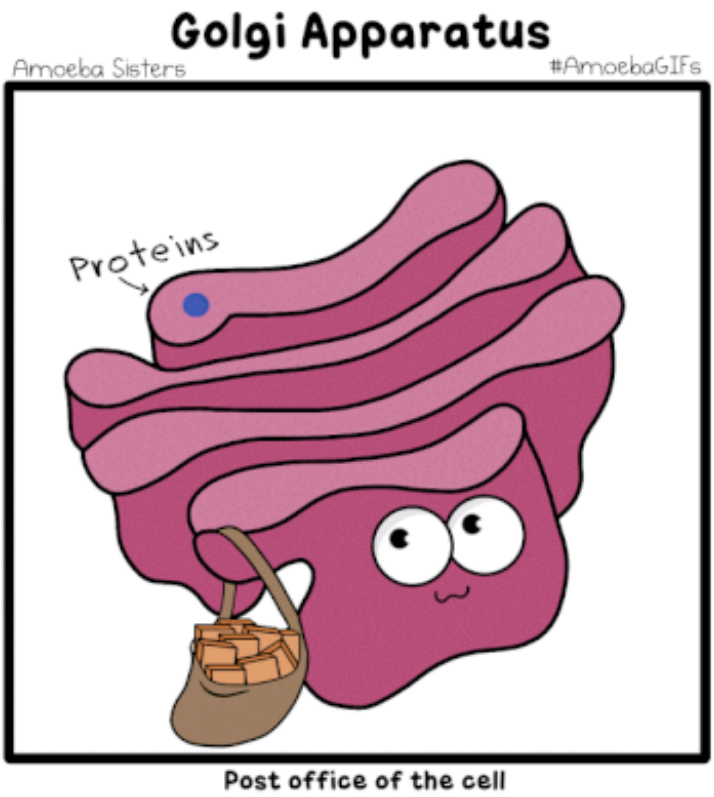

Lysosome

The Main Function of the Lysosome is to Digest Biological Matter.
A **lysosome** is a membrane-bound cytoplasmic organelle that contain enzymes that can break down different biomolecules. The lysosome works to digest substances in a similar way that our own stomach does.

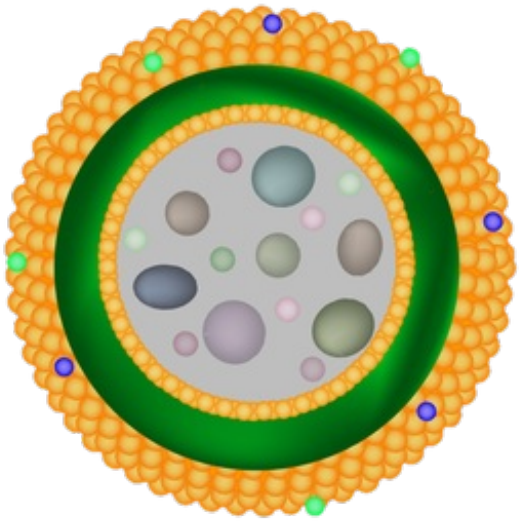

The Nucleus

The Main Function of the Nucleus is to hold the DNA / Chromatin

The structure of the nucleus -

- The nucleus is surrounded by the **nuclear envelope**, which is essentially a membrane (*a phospholipid bilayer*) that compartmentalizes (*or separates*) the nucleus from the rest of the cell. The nuclear envelope is similar to the cell membrane, except that it contains more *pores.* The pores allow substances like ribosomes to pass through. The nuclear envelop is selectively permeable.

- The liquid inside of the nucleus is called the **nucleoplasm.** The nucleoplasm is separated from the cytosol of the cell.

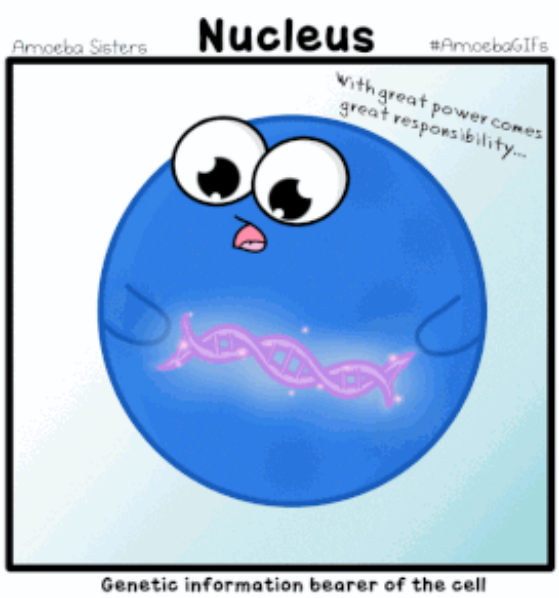

- The main function of the nucleus is to house the DNA. DNA is associated with histone proteins that act to package the DNA into bundles. The name for the collection of DNA and histone proteins is **chromatin**. The DNA holds the instructions for protein synthesis (as well as other instructions for the cell).

- DNA stands for deoxyribonucleic acid. It is the "instruction manual" for the cell. The primary function of the DNA is to provide the instructions for protein synthesis to the cell through the processes of **transcription** and **translation.**

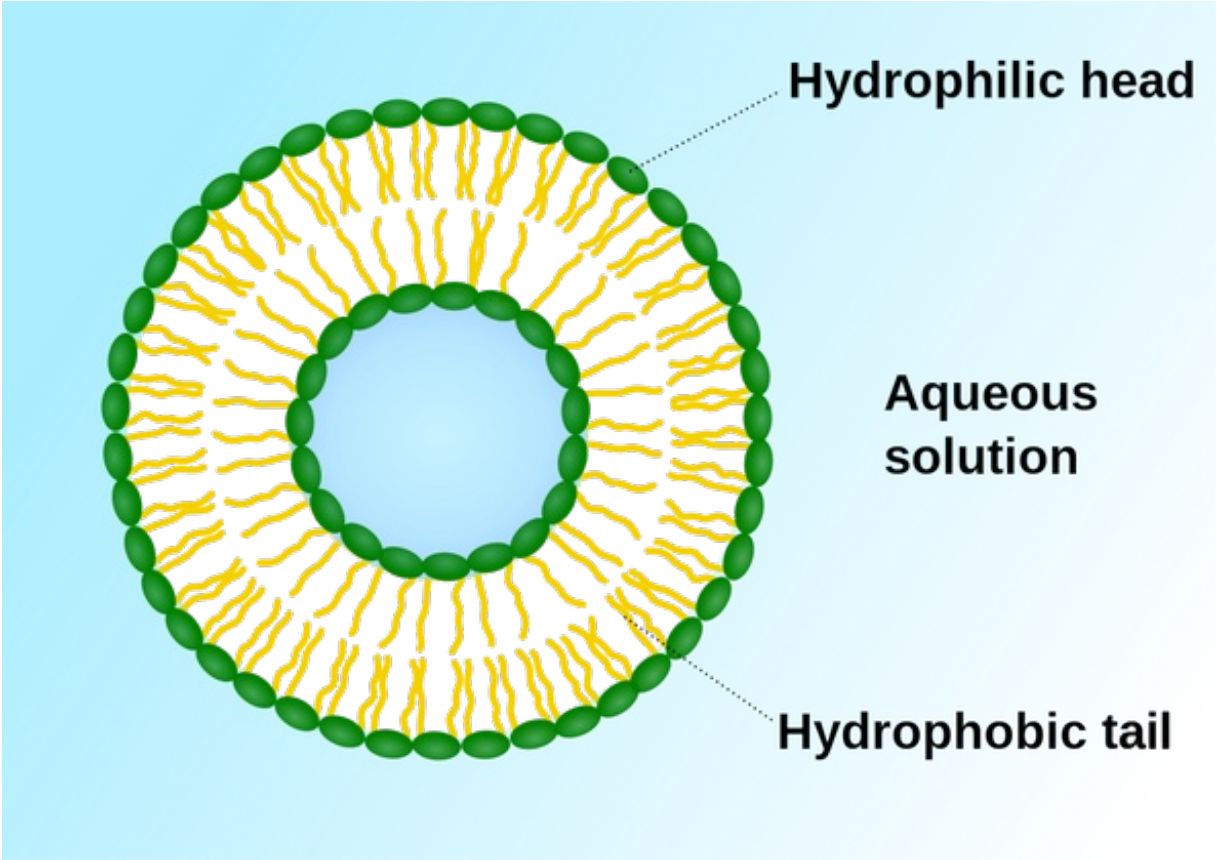

Vesicle

The Main Function of the Vesicle is Transport

- The vesicle consists of a small amount of fluid (and sometimes particles) surrounded by a phospholipid bilayer. This bilayer is made up of the same phospholipids that are found in the cell membrane of the plasma membrane. This is due to the fact that vesicles are actually made from the cell membrane itself!
- Vesicles move larger particles (like proteins) or large amounts of molecules (like neurotransmitters) across the membrane via endocytosis and exocytosis. Vesicles are also used within the cell to transport substances from one area to another.

EPITHELIAL TISSUE

The word "tissue" is derived from the word meaning "woven". Tissues are made up of a group of cells of the same type or that have similar embryonic origins and serve a specific function in the body. Cells in a tissue are physically arranged in such a way to serve their unique purpose. This is another illustration of the complementarity between structure and function.

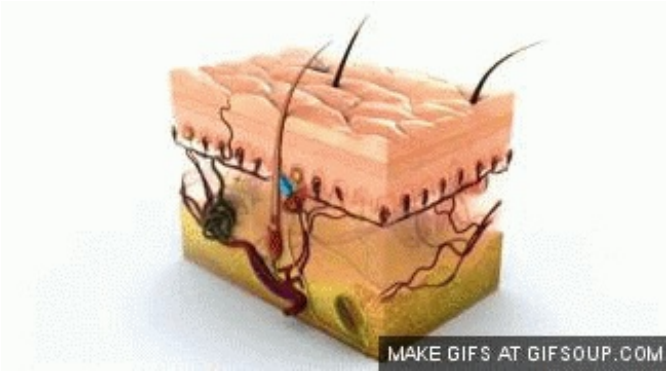

Although there are many types of cells in the human body, they are all organized into four broad categories of tissues:

The Four Tissue Types

1. Epithelial Tissue
2. Connective Tissue
3. Muscle Tissue
4. Nervous Tissue

Epithelial tissue line your internal and external surfaces, your cavity linings and most of your organs.

Most of your epithelium is considered **"epithelium proper"**, which refers to epithelium that lines your organs, your body cavities and all of your body's inner and outer surfaces. The main function of epithelium proper is protection.

You also have **glandular epithelium** that forms most of your body's glands. Glandular epithelium acts to secrete hormones for your endocrine system.

Characteristics of Epithelial Tissue

1. Cellularity - Epithelial tissue is made up of tightly packed epithelial cells that are connected to one another to form sheets.
2. Special Connections Between Cells -

- **Tight junctions** are integral proteins that fuse adjacent cells together to create a continuous sheet of cells

that prevents molecules from passing through the intercellular space

- **Desmosomes** are essentially internal tension-reducing networks of fibers that anchor adjacent cell to each other and are specially suited to resist mechanical stress.
- **Gap junctions -** Communicating junctions that allow ions and small molecules to pass for cell-to-cell communication

2. Polarity - A cell is considered 'polar' when one end is different from the other end. Epithelial cells are 'polar', because they have an 'upper' and an 'lower' portion.

- The top of the epithelial cell is called the **apical** side. The apical side usually has cilia or microvilli which act to move extracellular substances along.
- The bottom portion of epithelial tissue is called the **basal** side. The basal side of the tissue is connected to a **basal membrane or the basement membrane.** The basement membrane is composed of collagen fibers and it function to connect your epithelial tissue to the underlying connective tissue.

3. Avascular, but Innervated-

- Your epithelium does not have its own blood supply, so it must get its nutrients from the nearby connective tissue.
- Your nervous system, however, does connect to the epithelial cells.

4. Supported by connective tissue -

- As previously stated, the bottom portion of epithelial tissue is called the **basal** side. The basal side of the tissue is connected to a **basal membrane**.The basement membrane is composed of collagen fibers and it function to connect your epithelial tissue to the underlying connective tissue.

5. High regenerative capacity–

- Epithelial cells can be replaced fairly rapidly to replaces old or damaged cells. This is important property for wound repair.

Cells	Location	Function
Simple squamous epithelium 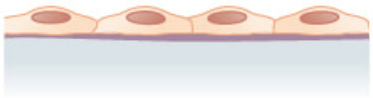	Air sacs of lungs and the lining of the heart, blood vessels, and lymphatic vessels	Allows materials to pass through by diffusion and filtration, and secretes lubricating substance
Simple cuboidal epithelium 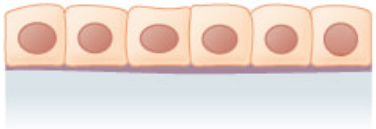	In ducts and secretory portions of small glands and in kidney tubules	Secretes and absorbs
Simple columnar epithelium 	Ciliated tissues are in bronchi, uterine tubes, and uterus; smooth (nonciliated tissues) are in the digestive tract, bladder	Absorbs; it also secretes mucous and enzymes

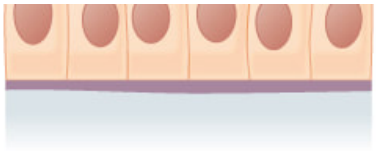		
Pseudostratified columnar epithelium 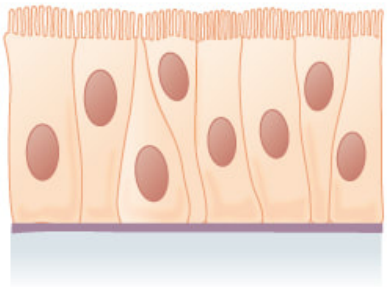	Ciliated tissue lines the trachea and much of the upper respiratory tract	Secretes mucus; ciliated tissue moves mucus
Stratified squamous epithelium 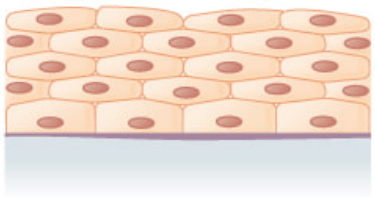	Lines the esophagus, mouth, and vagina	Protects against abrasion
Stratified cuboidal epithelium 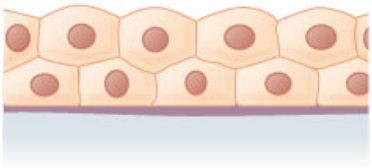	Sweat glands, salivary glands, and the mammary glands	Protective tissue
Stratified columnar epithelium 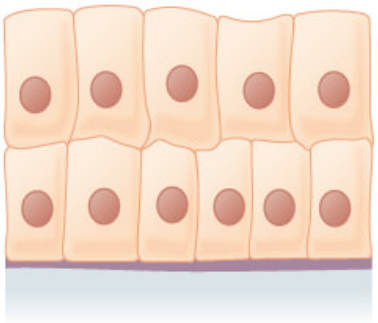	The male urethra and the ducts of some glands	Secretes and protects
Transitional epithelium 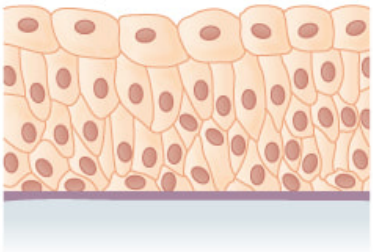	Lines the bladder, uretha, and the ureters	Allows the urinary organs to expand and stretch

How Are Different Epithelial Types Named?

What's in a name?

Epithelial tissue has a first name and a last name, so to speak. Epithelial tissue is named according ts layering first, followed by the shape of the epithelial cells that make up that layer.

The *first* name = LAYERING

Epithelial tissue is composed of one or more cell layers. When the tissue is composed of only one layer we refer to the tissue as being **"simple"**. When the epithelial tissue is composed of two or more layers, it is referred to as **"stratified"**. The word "stratified" literally means "layered", which also makes sense.

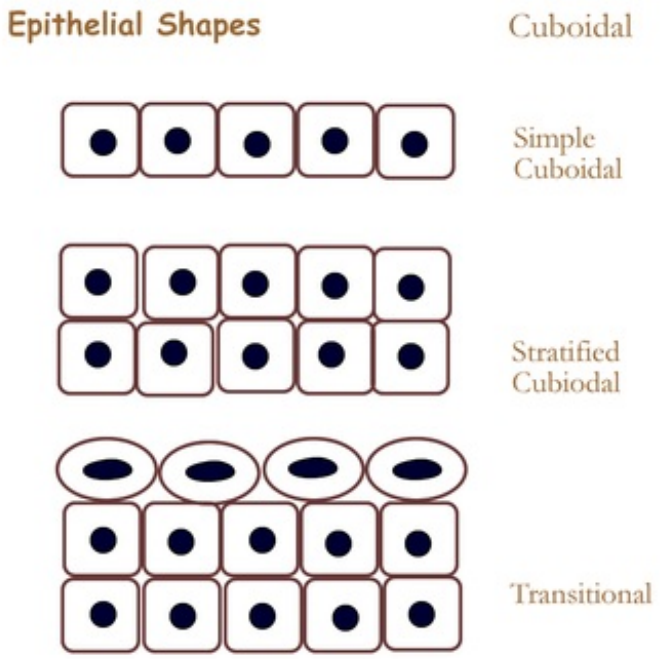

The *last* name = SHAPE

Epithelial tissue can be form from epithelial cells that have varies shapes. The last name of the tissue describe the appearance of the cells that make up the tissue.

There are three principal shapes of epithelial cell:

1. squamous
2. columnar
3. cuboidal.

Simple Squamous Epithelial Tissue

Simple Squamous Epithelial Tissue



When we name tissues, we begin with the layering reference, followed by the shape reference. For example, a **single** layer of squamous epithelium is called, "**simple squamous epithelium**". A **single** layer of columnar epithelium is called, "**simple columnar epithelium**". And, as you would expect, a **single** layer of cuboidal epithelium would be called "**simple cuboidal epithelium".**

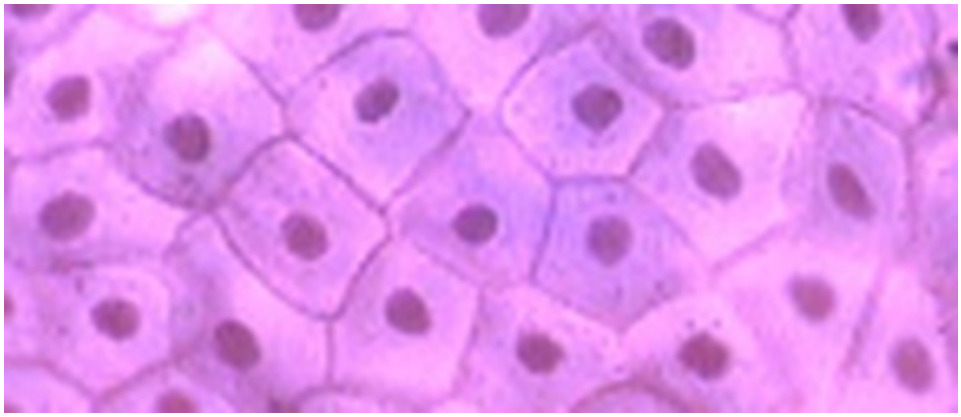

Simple Squamous Epithelium

Simple Squamous Epithelium
Epithelial cells that appear flat, are called **squamous epithelial cells**. A tissue that is made up of squamous epithelial cells is called **squamous epithelial tissue**. If the squamous epithelial tissue has only **one** layer, we call it **simple squamous epithelial tissue.** If the squamous epithelial tissue has **more than one** layer of squamous epithelial cells, it is called **stratified squamous epithelial tissue.**

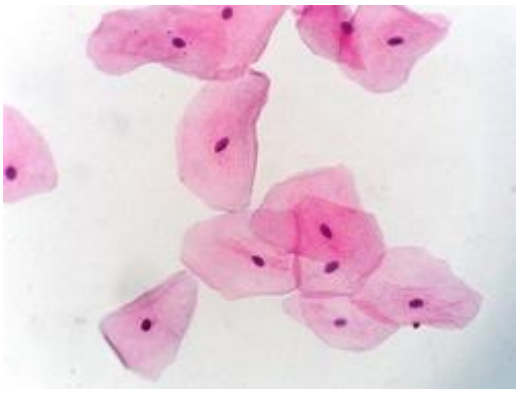

Squamous epithelium gets its name from its "scale-like" appearance. You could also think of squamous epithelium as appearing "squished", "squashed" or flattened. In addition, the nuclei of squamous epithelial cells are flattened as well. The nuclei of squamous cells tend to take up a lot of nuclear stain, so they will appear relatively dark. Squamous cells are flat.

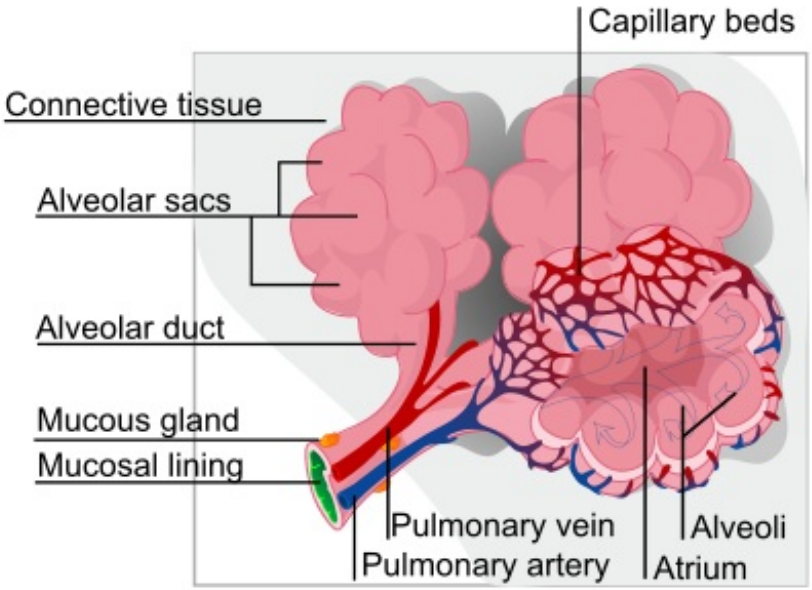

The main function of simple squamous epithelial tissue is to allow diffusion or filtration. For example, the alveolar sacs of the lungs are lined with simple squamous epithelial tissue that allows for the diffusion of gases between nearby blood vessels (specifically capillaries) and the lungs. Simple squamous epithelial tissue also lines your heart, your blood vessels and your lymphatic vessels. All of these areas depend upon diffusion of gases for proper functioning.

Simple Cuboidal Epithelial Tissue

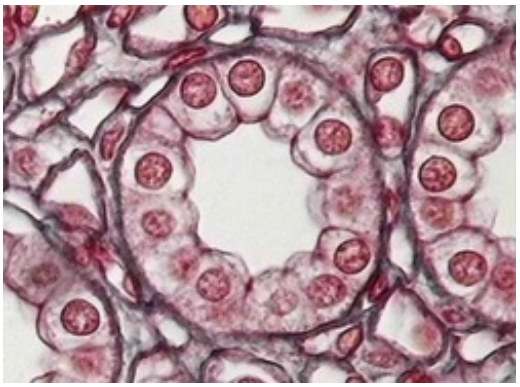

Simple cuboidal epithelium is found in organs that are specialized for secretion, such as salivary glands and thyroid follicles, and those that are specialized for diffusion, such as the kidney tubules. As its name implies, this tissue consists of a single layer of **cuboidal** cells on the basement membrane.

Simple Cuboidal Epithelium - appears as a set of somewhat organized "cubes". Cuboidal cells are seen packed more tightly together in tissues than squamous cells. The nuclei of cuboidal epithelial cells usually appear round and are located at the center of the cell.

Simple cuboidal epithelium is found in organs that are specialized for **secretion**, such as salivary glands and thyroid follicles, and those that are specialized for**diffusion**, such as the kidney tubules. The main function of simple cuboidal cells in glands is secretion and absorption. The main function in the kidney tubules is diffusion. The slide we have for the practical are from the kidney tubules.
Slides of simple cuboidal epitheliual tissue taken from kidney tubules. This accounts for the circular arrangement of the cells. The simple cuboidal epithelial tissue appears as a single layer of cube-like cells. The nuclei are relatively large, round and centrally located within the cuboidal cells.

Simple Columnar Epithelial Tissue

Simple Columnar Epithelial Tissue



Columnar epithelium looks long and cylindrical, kind of like "columns". Even the nuclei of columnar cells appear elongated into an ellipse. The nuclei of columnar epithelial cells are oriented toward the bottom (or basal side) of the cell (closer to the basement membrane).

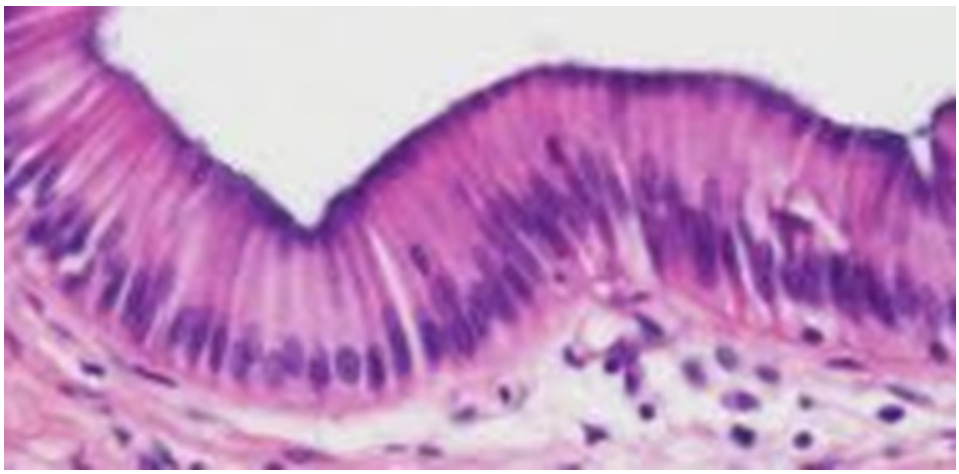

simple columnar epithelium

Columnar cells are specialized for absorption and secretion. They are able to secrete mucus, enzymes, and other substances the body needs. Columnar epithelial tissue is found in our **stomach lining** where they **create and secrete mucus**.

This function requires the cell to have a lot of machinery, so the columnar cells have to be large.
Depending on the location of the tissue, some simple columnar epithelia may contain columnar cells that have **cilia** at their apical surfaces and may contain goblet cells.

Stratified Squamous Epithelial TissueIf the squamous epithelial tissue has **more than one** layer of squamous epithelial cells, it is called **stratified squamous epithelial tissue.**

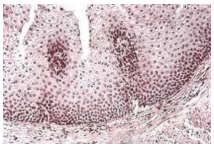

Stratified Squamous Epithelium

Stratified squamous epithelium is found in areas of your body that experience a lot of " *wear and tear*" . These vulnerable areas of your body are covered with several layers of squamous tissue in order to protect the deeper tissues that are harder (more biologically expensive) to replace.

Squamous cells are somewhat *disposable*, meaning they take less time and less *biological energy* to be replaced. Squamous cells are small, so they can undergo mitotic cell division on short notice. For this reason, squamous epithelium is found in areas that need to be replaced rather frequently like the vagina, the esophagus and the mouth. Stratified squamous epithelium acts to protect against *abrasion*.

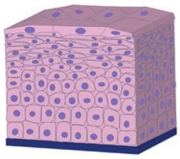

Stratified Cuboidal Epithelial Tissue

- WILL NOT BE ON PRACTICAL -

Stratified cuboidal epithelium is composed of two or more layers of cube-shaped cells.

Distribution and Function - This type of tissue can be observed in sweat glands, mammary glands, and salivary glands and serve to protect the area.
We DO NOT have this type of slide for the practical.

Stratified Columnar Epithelial Tissue

It is rarest tissue type of tissue. Stratified columnar epithelial tissue consists of several layers. Cuboidal cells may also be present in this type of tissue. When cuboidal cells are present, they are located near the basal membrane. Cells that are further toward the apical side of the tissue will appear more columnar or elongated.

Stratified columnar epithelial tissue can be found in the male **urethra** and in large ducts of some glands. This tissue functions as protection and secretion.

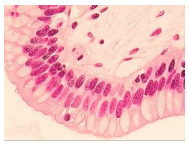

Stratified Columnar Epithelium

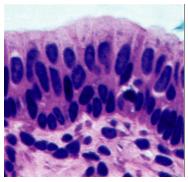

Stratified Columnar Epithelium

PSEUDOSTRATIFIED COLUMNAR EPITHELIUM

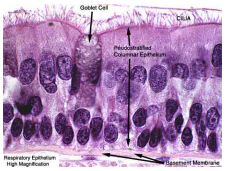

Pseudostratified Columnar Epithelium

CILIA - The cilia **move mucus** and other substances along a path. These cells can be found in the bronchial mucosa, which is part of the respiratory system where they function to prevent mucus from building up and blocking the airways. The bronchial mucosa also contains **goblet cells** which function to secrete mucus.
Columnar epithelium can also form a layer in which the nuclei are at different levels within the cells. This type of layering is called "*pseudostratified", because,* despite the cells forming a single layer, the variable position of the nuclei can make the tissue layer appears as though it was composed of two or more layers. It is for this reason that the layer is called "pseudo" (meaning "fake") - stratified.

Pseudostratified columnar epithelium is found in the esophagus, the trachea and the lining of the lungs. The main function of of this tissue is to **move mucus**.
IF YOU SEE CILIA, IN OUR PRACTICAL, IT IS GOING TO BE THE Pseudostratified (Ciliated) Columnar Epithelium

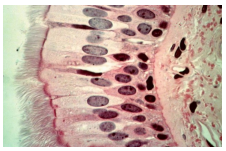

Ciliated Pseudostratified Columnar Epithelium

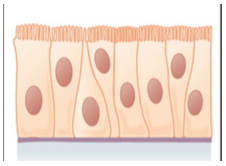

Illustration of Ciliated Pseudostratified Epithelium

Transitional Epithelium

Transitional epithelium lives up to its name. Its name is due to the 'transition' or changes in shape of the cells that make up the tissue. In this type of tissue, the most superficial (apical) cells get stretched out and deformed. Transitional tissues exist in areas of the body that undergo extreme stretching, like the bladder. The more 'stretchy' the tissue, the more 'bent out of shape' the apical cells become.

When transitional epithelium is not in its stretched shape (for example when your bladder is empty), in an empty bladder) the cells of the surface layers are large and rounded. When a transitional epithelium is stretched (as it would be in a full bladder) the cells of the surface layers are pulled into a flatter shape.

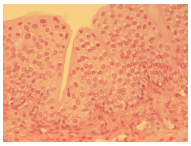

Transitional Epithelium

On a slide, the apical cells appear large and rounded, kind of like flower petals

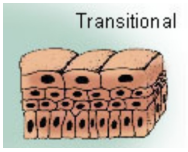

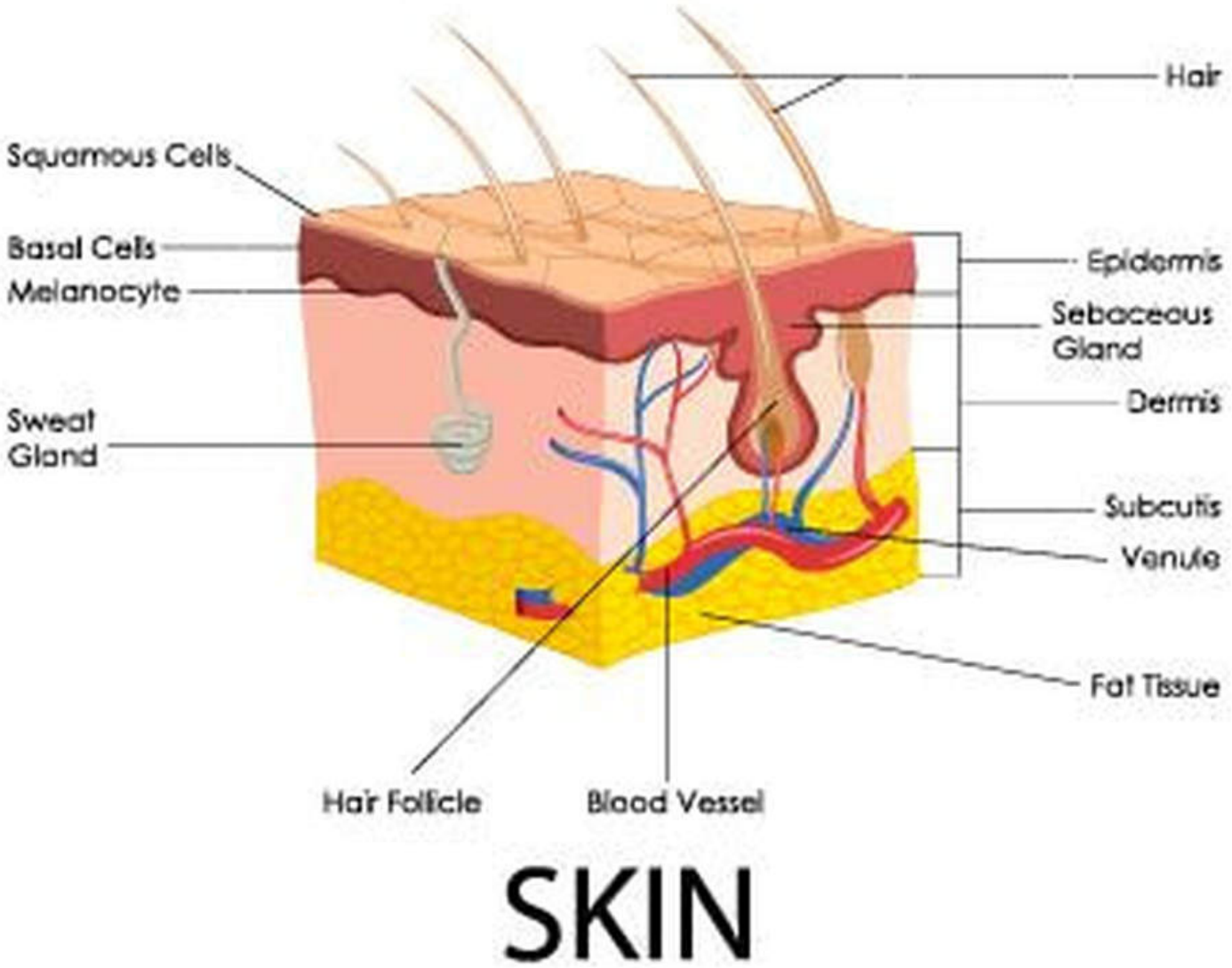

Your skin's thickness varies in different areas of your body. Skin can be categorized as either **thick skin** or **thin skin**.

- Your thick skin is located in regions of your body that has a lot of physical contact with the outside world. These areas include your fingertips, your palms and the soles of your feet. These extra layers help to protect the soft tissues from abrasions. Thick skin differs from thin skin in its structure. While the epidermis is thicker in thick skin than in thin skin, but the layer of the dermis turns out to be thinner. Also, thick skin does not contain hairs, sebaceous glands, or sweat glands. The epithelium of thick skin contains 5 epidermal layers, whereas thin skin contains only 4 layers.

The skin performs a variety of functions. *We may spend a lot of time preparing our dead skin cells to look their best for the world, but your skin does a lot more than just give you an attractive face! Let's take a look at the ways your skin is hard at work to keep you movin' and groovin' throughout your day*!

1. Protection

The primary function of your skin is to protect your internal organs and soft tissue from the outside world. It provides a barrier that is able to withstand some wear and tear. It can get bumped, bruised or scraped and it is able to heal relatively quickly. This is because the epidermis is composed of stratified squamous tissue which provides layers of small, easily replaced squamous cells. The barrier of your skin also protects you from harmful elements like

bacteria, viruses, chemicals and even contains melanin (within specialized cells called melanocytes) which provides protection from harmful UV radiation from the sun. Skin also prevents excess water loss from the body.

2. Body Temperature Regulation.

Your skin helps control your body temperature. When you are getting too hot, the skin reacts by activating sweat glands to secrete sweat that helps your body cool down. Your layers of adipose tissue (fats) helps the internal core body to keep warm. In extremely low temperatures, the blood flow to your extremities is restricted to conserve warmth toward the core of the body where vital organs are located.

3. Excretion

You sweat, but what is it? Your sweat is made of urea, salts, and water.

4. Production of vitamin D

Not all UV radiation is bad for you. Your skin actually does need a small amount of UV rays from the sun to produce valuable vitamin D. Vitamin D is necessary for the body to absorb calcium from your digestive tract.

5. Sensory Reception.

The skin gathers sensory information about the outside world that gets relayed to the brain. Your skin has sensory receptors for temperature, touch and pain.

The Layers of the Skin

The outermost surface of your skin (the superficial region) is made of a thick epithelial tissue called epidermis. The word "*derm*" means "skin". The prefix "*epi*-" means "above". Beneath the epidermis, (deep to the epidermis) is the layer of the dermis. The dermis is composed of connective tissue. The skin is composed of the epidermis and the dermis. Below the skin (deep to the skin) there is another layer called the hypodermis. "Hypo-" means "below". This layer is composed of areolar connective tissue and adipose tissue.*The hypodermis is NOT considered to be part of the skin itself.*

The skin is composed of 2 primary layers:
1) the epidermis
2) the dermis

The apical (outer most) layer is called the epidermis. The prefix "epi-" means "above". Lying underneath the epidermis is the dermis. Each of these primary layers is broken down into subsequent layers.

Epdermal tissue is categorized as a ***keratinized stratified squamous epithelial tissue***. The most abundant type of cell found in the epidermis are **keratinocytes**. Keratinocytes produce **keratin** which is a fibrous protein that gives strength to epidermis. The keratin protects the deeper tissue layers not only by providing a physical barrier to the outside world, but they provide antibiotics. and enzymes that act to detoxify the harmful chemicals to which our skin is exposed. Keratinocytes form in the deepest portion of the epithelium (the stratum basale) and then are continously pushed outward until they die and eventually get sloughed off of the body. We loose millions of these dead skin cells every day! your epidermis is completely replaced every 35-45 days.

The keratinocytes undergo physical changes as they mature and move closer to the surace of your skin. The keratinocytes are created from stem cells that extist in the stratum basale. As these cells are pushed up by the production of new cells beneath them, they make theor way to higher (more apical) epithelial layers. When the keratinocytes reach the stratum spinosum (the layer superficial to the stratum basale) they begin to produce keratin. Once they reach the stratum granulosum, these cells are busy making lots of keratin which fills their cytoplasm. The keratinocytes begin to die as they become part of the stratum lucidum, becoming smaller and clear. They begin to loose their organelles as they die. By the time these dead keratinized squamous epithelial cells reach the skin's surface, they are completely dead and are characterized as "corneocytes". The corneocytes are basically dead, flat sacs completely filled with fibrous keratin.

There are no blood vessels in the epidermis, so the epidermis does not have its own blood supply.The epidermis get nutrients and gasses , oxygen, and vitamins travel to the epidermis through the rete pegs, which are made up of a network of very small blood vessels that project down to the dermis layer.

The Epidermis

The Layers of the Epidermis

The epidermis consists of 5 layers in thick skin / 4 layers in thin skin.

1. **Stratum Corneum** - Translates as "horny layer".
2. **Stratum Lucidem** - Translates as "clear layer". ONLY EXISTS IN THICK SKIN
3. **Stratum Granulosum** - Translates as "granular layer".
4. **Stratum Spinosum** - Translates as "spinous layer/prickle cell layer".
5. **Stratus Basale** - Translate as "basal layer".

Need a Mnemonic?? Try, Come, Let's Get SunBurned!
C = Stratum Corneum
L = Stratum Lucidem
G = Stratum Granulosum
S = Stratum Spinosum
B = Stratum Basale

The Layers of the Epidermis
(HINT: they go in alphabetical order).
Starting at the apical (top) end...

1. The Stratum Corneum (Horny Layer)

The stratum corneum is a ***keratinized stratified squamous epithelium***that contains four types of cells. The four cells types cells that make up the stratum conrneum are 1) keratinocytes, 2) melanocytes, 3) tactile epithelial cells, and 4) dendritic cells

The **stratum corneum** is Latin for 'horny layer'. Its odd name comes from the dead squamous cells called **corneocytes** that make up the apical surface of the tissue. The corneocytes form several layers of flattened (squamous) cells with no nuclei and no organelles. This is the layer that includes the final keratin product, which is a combination of cytokeratin and keratohyaline.

2. *The Stratum Lucidum

The **stratum lucidum** is Latin for "clear layer". This epidermal layer gets its name from translucent appearance of the dead skin cells that make it up. **<u>*This layer only exists in the thick skin of the soles of your feet, your palms and your fingertips.</u>**

3. Stratum Granulosum (Granular Layer)

The **stratum granulosum** is Latin for granular layer. n this layer, the keratinocytes have become **squamous cells** that contain granules of keratohyaline, a precursor to the extracellular keratin that protects the skin tissue from abrasion.

4. Stratum Spinosum (Prickle Cell Layer)

The **stratum spinosum** is Latin for "spiny". After forming in the basal cell layer, keratinocytes migrate upwards to form the stratum spinosum. In this layer, they develop short projections that attach via desmosomes to adjacent cells. The stratum spinosum is also known as the "prickly layer" because of these characteristic spines. The cells in this layer produce cytokeratin, an intermediate filament precursor to keratin.The cells in this layer experiences shrinking of its microfilaments during the slide staining process.

5. Stratum Basale (Basal Layer)

The **stratum basale** is the deepest of the 5 epidermal layers. The primary cell of the epidermis is the keratinocyte stem cells which give a continuous supply of new cells to replace old dead ones. The stratum basale also contain sensory nerves called **Meissner's (Tactile) Corpuscles** that are sensitive to light tactile sensations (light touch). This layer also contains **melaocytes** which produce the pigment**melanin** which acts to filter out harmful UV radiation.

The epidermis consists of 4 cell types.

1. **Keratinocytes -** The most abundant cell type in the epidermis. They are created in the stratum basale and pushed upward toward the skin's surface. These cells make keratin and act to protect deeper layers of soft tissue. These cells die as they approach the surface of the skin. Once they are dead and shriveled up, they are called corneocytes.
2. **Melanocytes -** Pigmented cells of the stratum basale region that produce melanin which protects from UV radiation.
3. **Merkel Cells -** function as *touch receptors* in association with sensory nerve endings (Merkel disc); located at epidermal-dermal junction
4. **Langerhans' Cells -** epidermal macrophage-like cells that help activate the immune system via receptor-mediated endocytosis; arise from bone marrow;

Touch receptors of the skin.

Your skin has specialized sensory receptors called touch (tactile) receptors or mechanoreceptors which responds to mechanical pressure or distortion by generating a signal that will ultimately reach the brain.

There are four main types of mechanoreceptors in your skin

1. **Pacinian corpuscles**
2. **Meissner's corpuscles**
3. **Merkel's discs**
4. **Ruffini endings**

Mela<u>nocytes</u> - make **melanin** - makes skin dark. Protects from UV Light. UV light is carcinogenic. This is why getting too much sun can cause skin cancer. **Melanocytes** are specialized cells that lie within the skin. They produce a brown pigment (**melanin**) that functions to provide protection from damaging UV radiation from the sun. The pigment filters out the UV light. When your skin is exposed to more sunlight, your melanocyte darken the skin by increasing the production of melanin.

3D Skin Model

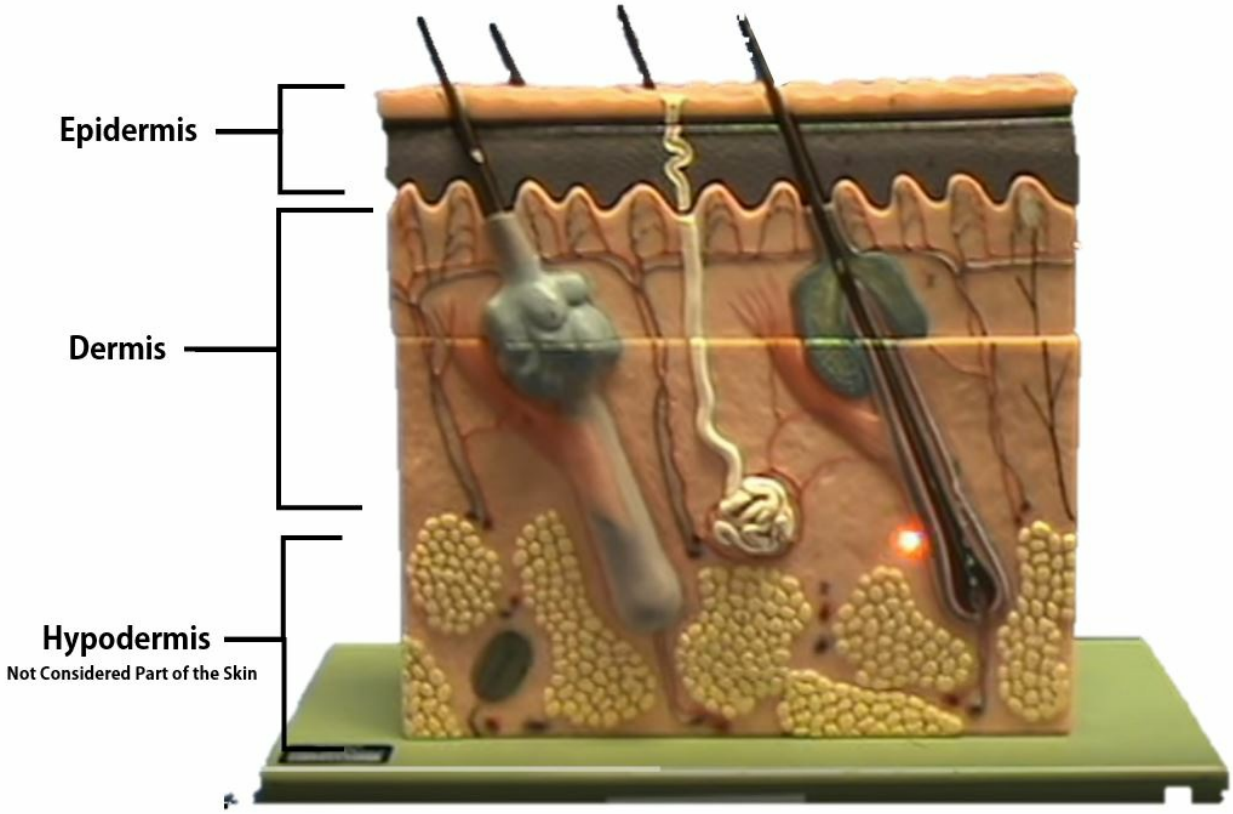

3D Skin Model Dermis and Hypodermis

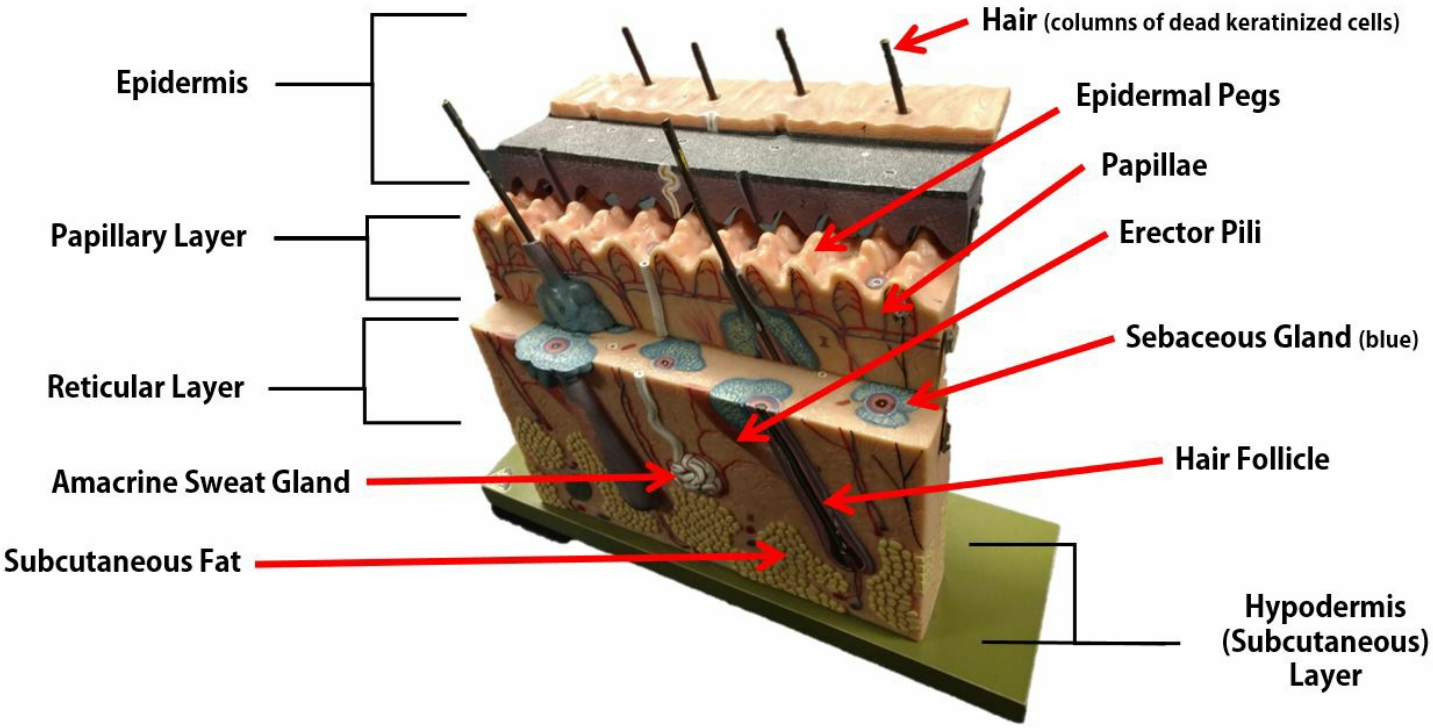

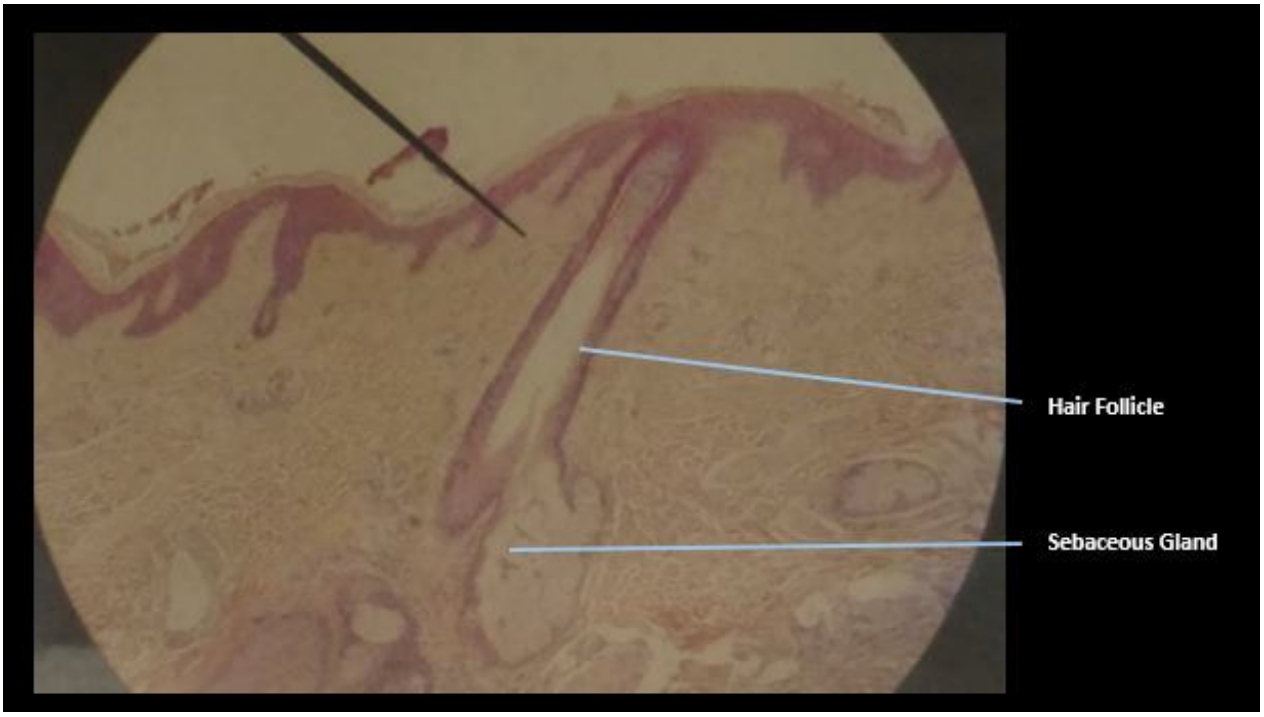

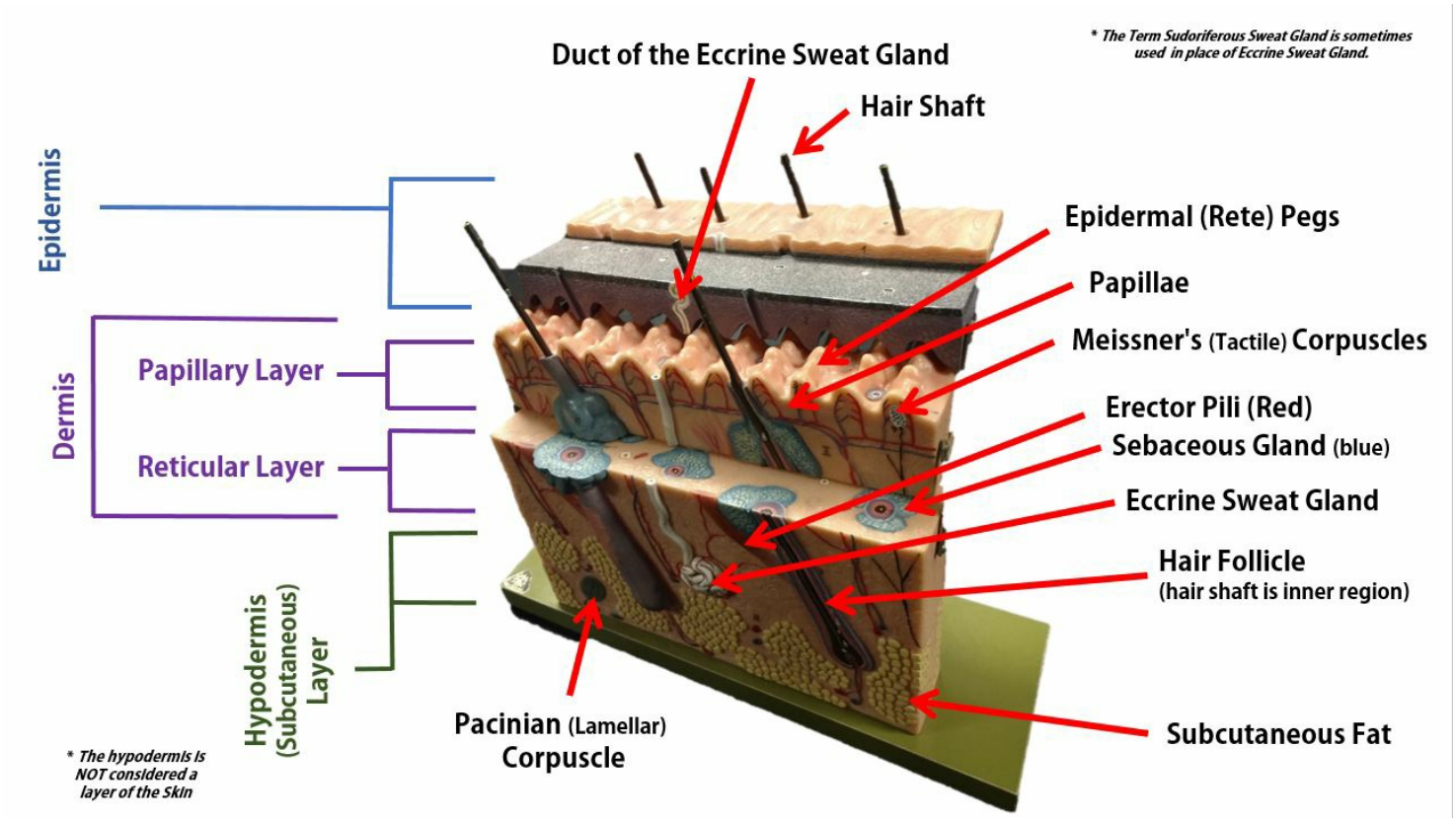

CONNECTIVE TISSUE

The 4 Types of Connective Tissues *Connective tissues include a wide variety of tissue types with a wide variety of functions, only one of those functions is to connect tissues and organs together. For example, your bones and your cartilage are connective tissues that function as the structural support of the body. Fat tissue and blood are connective tissues that function to store and carry nutrients. Connective tissue proper acts to surround delicate vessels and nerves and contains specialized cells that fight infection.*

The four broad categories of connective tissue are classified according to the characteristics of their ground substance and the types of fibers found within the matrix.

The 4 Types of Connective Tissues Include:

1) Connective Tissue Proper
2) Cartilage
3) Bone
4) BloodConnective Tissue ProperCartilageBoneBlood

There are 3 characteristics that are shared by all of the different types of connective tissue.

1. All connective tissue contains relatively few cells with large space between them.
2. All connective tissue contains a large amount of extracellular matrix(ground substances and protein fibers).
3. All connective tissues have the same embryonic origin; the mesenchyme (comes from mesoderm germ layer of embryo).
4. Special cell that secrete extracellular matrix proteins
   •fibroblasts for areolar tissue and reticular C.T.,
   •adipocytes for adipose
   •chondroblasts for cartilage
   •osteoblasts for bone
   •hematopoietic stem cell for blood

Connective tissues are composed of not only of specific cell types, but also the protein fibers and ground substance that make up the surrounding extracellular matrix. Connective tissue cells are interspersed within the unique extracellular matrix of the tissue. The composition and density of proteins and molecules that make up the matrix varies with the different types of connective tissues. It is the specific composition of the cells, ground substance and the protein fibers that make up the connective tissue that gives it the ability to provide its specific function within the body. This is the complementarity between structure and function in connective tissues.

What is the "Ground Substance"? *The ground substance refers to the substance that surrounds the cells and fibers of the extracellular matrix. The ground substance is a thick or jelly-like substance in connective tissues, except for in bone and cartilage in which the ground substance is calcified.*

What are the "Protein Fibers"? *The matrix has a scaffolding made up of fibrous proteins. that provide support for the connective tissue. There are 3 types of protein fibers that can be found in connective tissues: 1) collagen fibers, 2) reticular fibers, and 3) elastic fibers. The types, density, and distribution of the protein fibers is unique in different connective tissue types.*

The matrix of connective tissues is made up of three types of fibers.

1. **collagen fibers**
2. **reticular fibers.**
3. **elastic fibers.**

The cells that make up the different connective tissue types all have the same embryonic origin.

During the early stages of development, the embryo form 3 distinct layers; the ectoderm (outer layer), the mesoderm (middle layer, and endoderm (inner layer) and).

The cells of the mesoderm have mesenchymal stem cells that can differentiate into many different cell types.

The Origin of Connective Tissue Cell Types: The mesenchymal stem cells give rise to the different cell types needed to form all of the different connective tissue types.

Mesenchymal stem cells give rise to

- the osteoblasts which form your bones,
- the chondrocytes that form your cartilage,
- the fibrocytes that form your connective tissue proper,
- and the adipocytes that form your adipose (fat) cells.

Connective Tissue Proper The first category of connective tissue we will explore is called the **connective tissue proper.** The main function of connective tissue proper is to bind tissues, and to resist stress and taring due to stretching and tension placed on the tissue. Connective tissue proper, found in most organs, is characterized by a predominance of fibers (mainly type I collagen) in the extracellular matrix. Its varied functions are chiefly related to binding cells and tissues into organs and organ systems. Its sub-classes are based on the type, density, and orientation of its fibers.

The primary cell type in **connective tissue proper** is the **fibroblast**.

The **fibroblast** produces components for the extracellular matrix of the connective tissue proper, which includes collagen and elastin. The fibroblast means “fiber formers”, and they live up to their name. Fibroblasts manufacture proteins and secrete them (via exocytosis) into the extracellular matrix where they act as building blocks for the matrix.

Connective tissue proper includes a few other cell types in addition to its primary cell type, the fibroblast. These additional cells include fibrocytes, defense cells, and adipose (fat) cells. The ground substance in connective tissue proper is the consistency of jelly and is composed of collagen and elastin.

What Tissue Types Are Considered "Connective Tissue Proper"?

Connective tissue proper contains tissues that fall into 2 different categories.
1) Loose Connective Tissues
2) Dense Connective Tissues

There are 3 types of Loose Connective Tissue.
1) Areolar Connective Tissue
2) Adipose (Fat) Tissue
3) Reticular Tissue

There are 3 types of Dense Connective Tissue.
1) Dense Regular Connective Tissue
2) Dense Irregular Connective Tissue
3) Elastic Connective Tissue

Areolar Connective Tissue

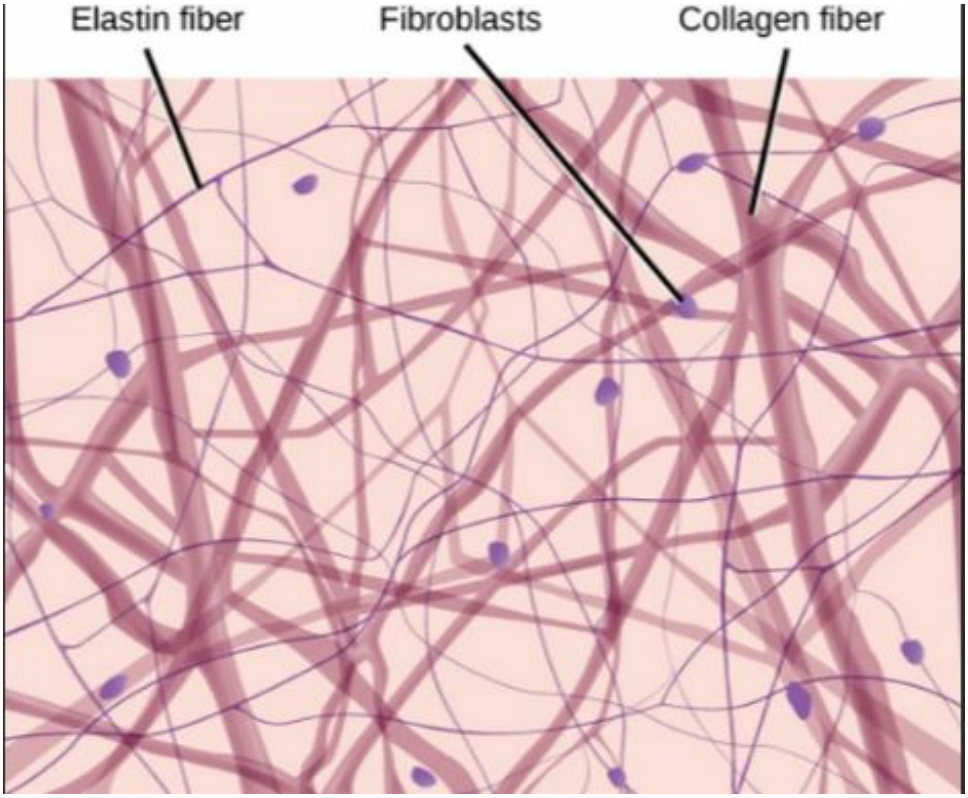

A Type of Loose Connective Tissue

Here is an illustration of areolar connective tissue. Areloar connective tissue is very ' *loose'.* Areolar tissue is composed of a lot of matrix and relatively few cells. The primary cell of areolar connective tissue is the flibroblast. The fibroblast function in the areloar tissue to form the fibers of the matrix and the surrounding *ground substance.*

Areolar connective tissue is a loose connective tissue.The appearance of areolar connective tissue makes me think of "paint brush strokes".

Areolar tissue appears as a disorganized network of fibers with lots of space between them and a small number of spread out cells. The ground substance of the areolar tissue is a viscous liquid that surrounds the cells and fibers. Areolar tissue is strong, yet flexible and elastic and resists taring. This tissue surrounds blood vessels and nerves, is found in and around most of your organs, and is an important component for your skin where it acts to support the epithelia, and to anchor your skin to underlying muscle tissues.

The areolar tissue surrounds the organs provides flexible structure and support. The areolar tissue allows a high degree of movement between adjacent body parts.

The key functions of areolar tissue can be summarized as providing:

- *Support*
- *Strength*
- *Elasticity*

Adipose Connective Tissue
A Type of Loose Connective Tissue
Adipose (fat) tissue function to store energy and produce heat.

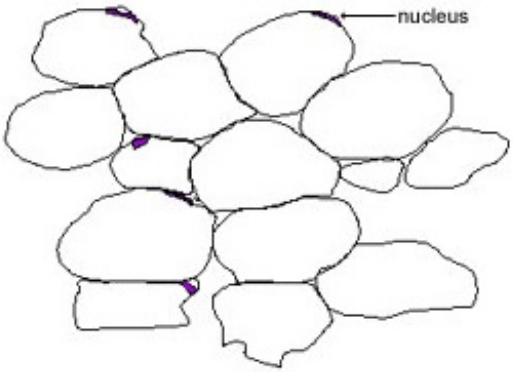

Adipose (fat) cells, is considered a loose connective tissue of the connective tissue proper. There are actually two different types of fat tissue; white fat and brown fat. Your white fat stores energy (in the form of a lipid droplet, while brown fat functions to generate body heat. Infants have a lot more brown fat than adults do. This is one of the reasons that infants have a higher normal temperature than adults.

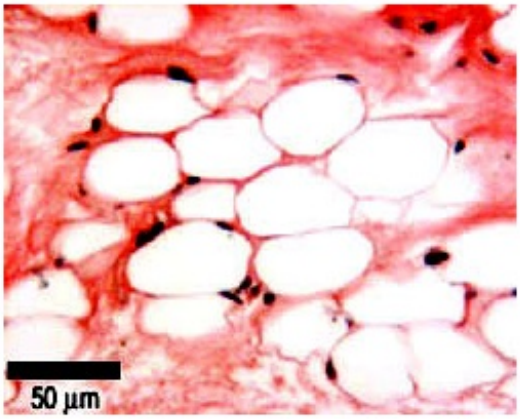

Under the microscope, adipose cells (adipocytes) appear as large ovals with the nucleus off to one side. This odd appearance is due to the presence of a large lipid (fat) droplet that flattens the nucleus and pushes the cytoplasm to one end of the cell. The lipid droplet that takes of most of the area within these cells is hydrophobic, so it does not take up any of the applied stain. So, a slide containing adipose cells is going to appear as mostly "white space". However, it is important to locate the cell membrane and the nuclei to ensure that the slide is of adipose cells and not just out of focus.

Visceral Fat vs. Subcutaneous Fat

Visceral fat is different from subcutaneous fat underneath the skin, and intramuscular fat interspersed in skeletal muscles. You may have heard that people who have a large accumulation of adipose tissue in the abdomen region are at a higher risk diabetes, heart disease, cancer and stroke. This is true, but why?

"Belly fat" is an indicator of "visceral fat". Visceral fat surrounds these visceral organs and can effect their function. Remember that your visceral organs include all of the organs contained within your ventral cavity. Men are more likely to have their excess adipose tissue stored in the abdomen due to male sex hormones. Women, on the other hand, tend to carry their excess adipose tissue on the buttocks, thighs, and hips in women due to female sex hormones. When women reach menopause, the decrease in estrogen production by the ovaries induces a change in the location of fat store from the thighs, hips and buttocks to the abdomen where it is more detrimental to health.

Subcutaneous fat is found just below the skin in a region called the hypodermis and is not related to the obesity-related diseases, cancer and stroke.

Reticular Connective Tissue

A Type of Loose Connective Tissue Reticular Connective Tissue.

Reticular connective tissue is a type of loose connective tissue that contains a network of reticular fibers. The word "recticulum" means (net or network). Reticular fibers are very noticeable in these tissues. These reticular fibers are synthesized by fibroblasts (also called reticular cells).

Reticular connective tissue is found in bone marrow and surrounding the kidneys, the spleen, and the lymph nodes. Reticular connective tissue forms a flexible 'skeleton' or internal framework, that can support many free blood cells (largely lymphocytes) in lymph nodes, the spleen, and red bone marrow

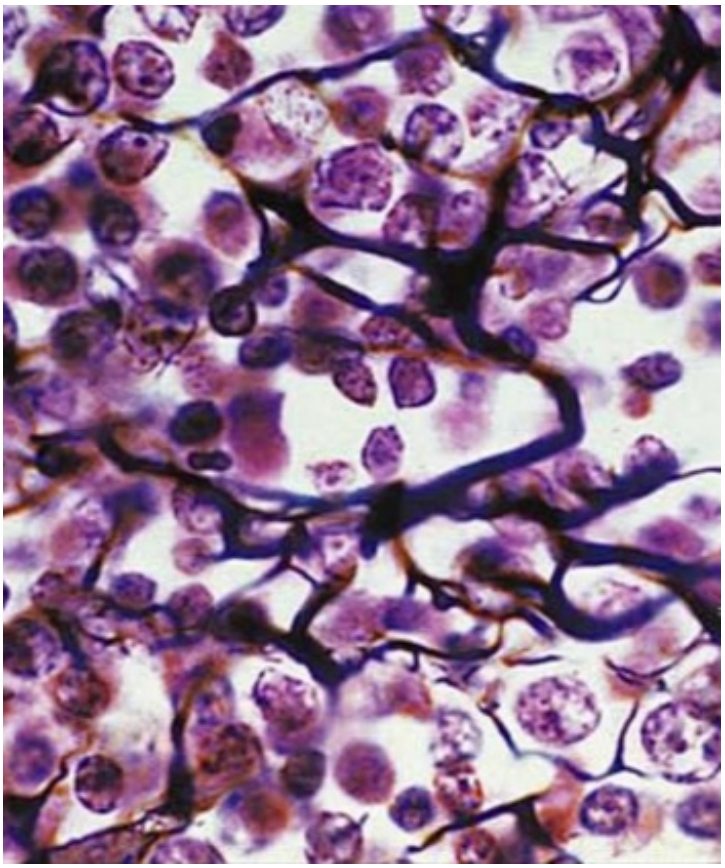

There are 3 types of Dense Connective Tissue:

<u>Dense Regular Connective Tissue</u> - has a rope-like arrangement of fiber bundles
<u>Dense Irregular connective tissue</u> - has a wavy, woven fabric-like arrangement
<u>Elastic Connective Tissue</u> - has stacked swiggly wavy lines

---

Dense Regular Connective Tissue



A Type of Dense Connective Tissue*Dense regular connective tissue*

The fibers of this tissue are tightly packed into parallel bundles, between which are a few highly attenuated, spindle-shaped fibroblasts. The small, cigar-shaped nuclei of the fibroblasts are oriented parallel to the fibers; the cytoplasm is difficult to distinguish with the light microscope. There is little room for the ground substance, which nevertheless permeates the tissue.

Dense regular connective tissue is packed with collagen fibers. This makes them very strong and resistant to stretch. This unique property allows them to transit mechanical force over long distances using a minimum of material and space, while resisting mechanical forces from other directions. This tissue therefore serves to transmit the force of muscle contraction, to attach bones to one another, and to protect other tissues and organs.

Dense regular connective tissue is found in tendons, ligaments, periosteum, perichondrium, deep fascia, and some organ capsules. You are already familiar with these tissues, even if you don't already know it. In some cuts of meat, you can see these tissues as the white stringy substance that has a harder consistency. In anatomy, a **ligament** is the dense regular connective tissue that connects bones to other bones. and a **tendon** is the dense regular connective tissue that connects bones to muscle (for example, the hamstring.)

Dense Irregular Connective Tissue**- WE DO NOT HAVE DENSE IRREGULAR TISSUE SLIDE FOR PRACTICAL -**

Dense irregular connective tissue consists of tightly packer collagen fibers that appear less organized and less uniform that dense regular connective tissue tissue. The nuclei in this tissue are stretch long and the tissue may appear wavy under a microscope. The major cell on dense irregular connective tissue is the fibroblasts.

Dense irregular connective tissue is able to withstand tension from multiple directions. It provides support and strength. This tissue is found in areas that experience stretching from multiple angles, such as the dermis of the skin, the submucosa of the digestive tract and the fibrous capsules of organs and joints.

Elastic Connective Tissue

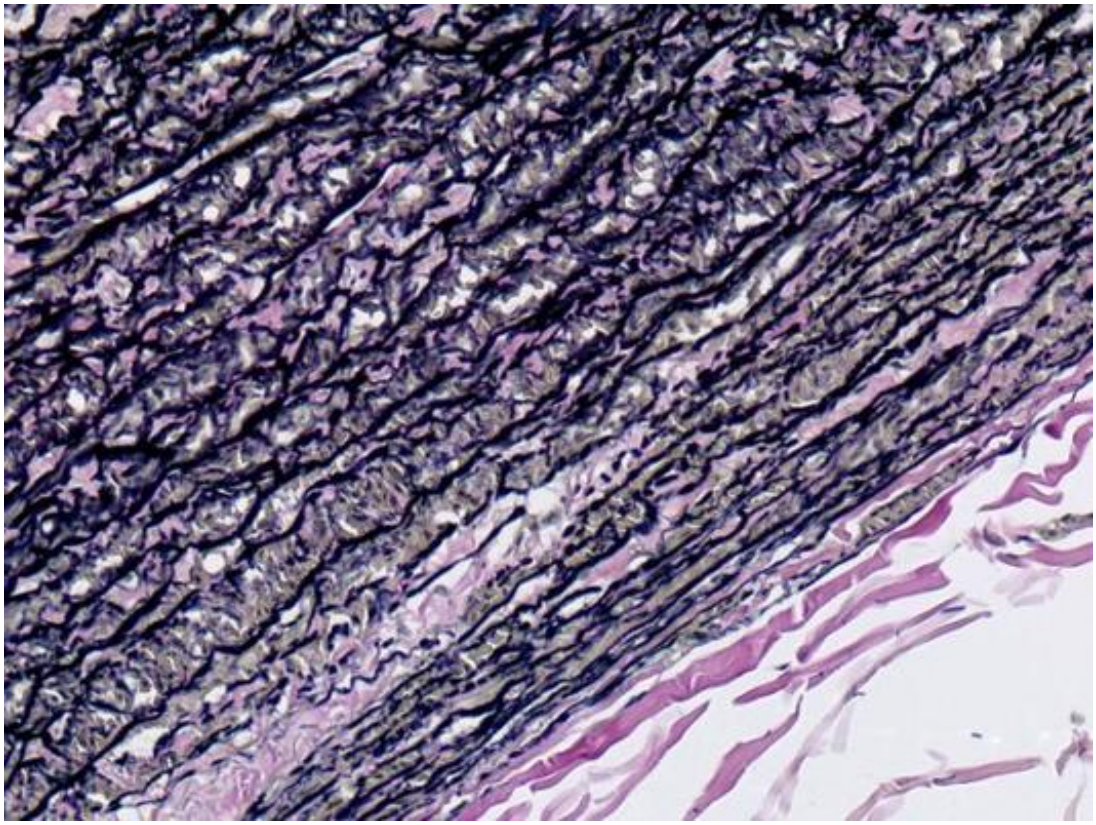

A Type of Dense Connective Tissue

Elastic fibers are present in different concentrations in all of the connective tissues proper. Elastic fibers are made with elastin that has the ability to stretch and then return to its original shape after being stretched. Connective tissues that have a very large amount of elastin are referred to as elastic connective tissue.

Elastic connective tissues are present in relatively high concentration in several organs, including the largest arteries in the body.

Cartilage

WHAT IS CARTILAGE?

Cartilage is a supportive connective tissue that functions in the body to provide structural support, protection of soft tissues and increases strength. You are born with a lot more cartilage than you have as an adult. As you grow, much of this cartilage is used to guide the growth of bones. For example, the human skull is composed of separated bones at birth and then fuses during development to form the skull. Once the bones have fused, the cartilage is broken down by the body and not replaced. This is why infants are born with a "*soft spot"* at the top of their head that disappears.

There are 3 types of cartilage.

1) **Hyaline Cartilage**
2) **Fibrocartilage**
3) **Elastic Cartilage.**

Hyaline Cartilage

Hyaline cartilage is the most abundant type of cartilage found in our body. Your entire skeleton actually started out as hyaline cartilage when you were developing in the womb. As an adult, you have hyaline cartilage covering the surfaces of your bones at each of your joints. Your ribs also contain hyaline cartilage at the anterior ends. You have hyaline cartilage in your bronchi, your bronchial tubes, nose and trachea. You even have hyaline cartilage that forms your vocal cords!

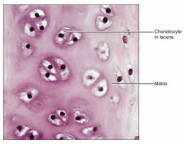

Photomicrograph: Hyaline cartilage from a costal cartilage of a rib (X704).

Fibrocartilage

(Fibrous Cartilage)

Fibrocartilage is a tough form of cartilage that consists of chondrocytes scattered among clearly visible dense bundles of collagen fibers within the matrix. Fibrocartilage is found in portions of your joints, your intevertebral discs, your knee (as the meniscus) and your pubic symphysis which joins the anterior portions of your hip bones together Fibrocartilage provides structure and support. It is also the strongest type of cartilage.

Fibrocartilage has the ability to resist strong compression and strong tension (pushing and pulling) forces. The areas of the body that have this type of cartilage are subjected to a lot of push and pull (compression and tension) forces. its consistency lies somewhere between hyaline cartilage and dense regular connective tissue. Fibrocartilage has thick collagen fibers which makes it somewhat similar to dense regular connective tissue, however the cartilage includes chondrocytes within lacunae. In histology, a lacuna is a small space containing an osteocyte in bone or chondrocyte in cartilage.

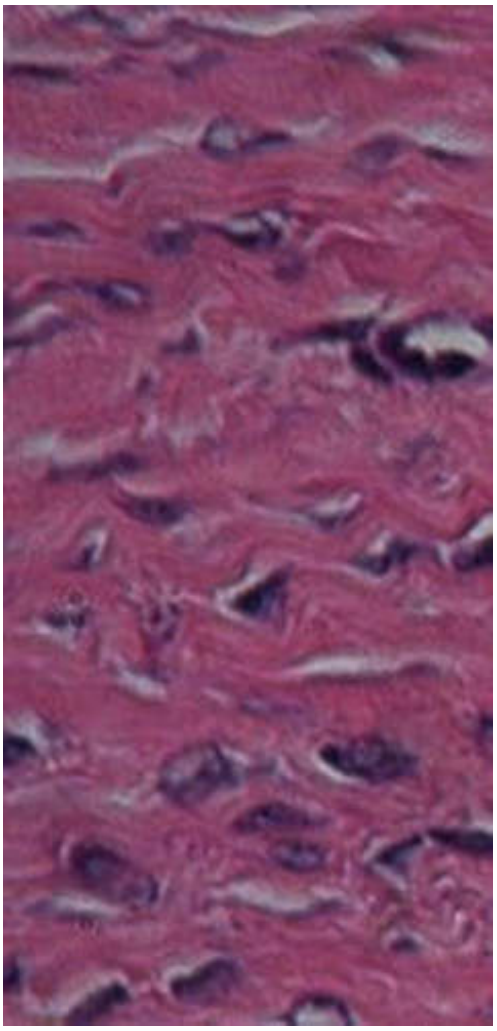

Elastic Cartilage

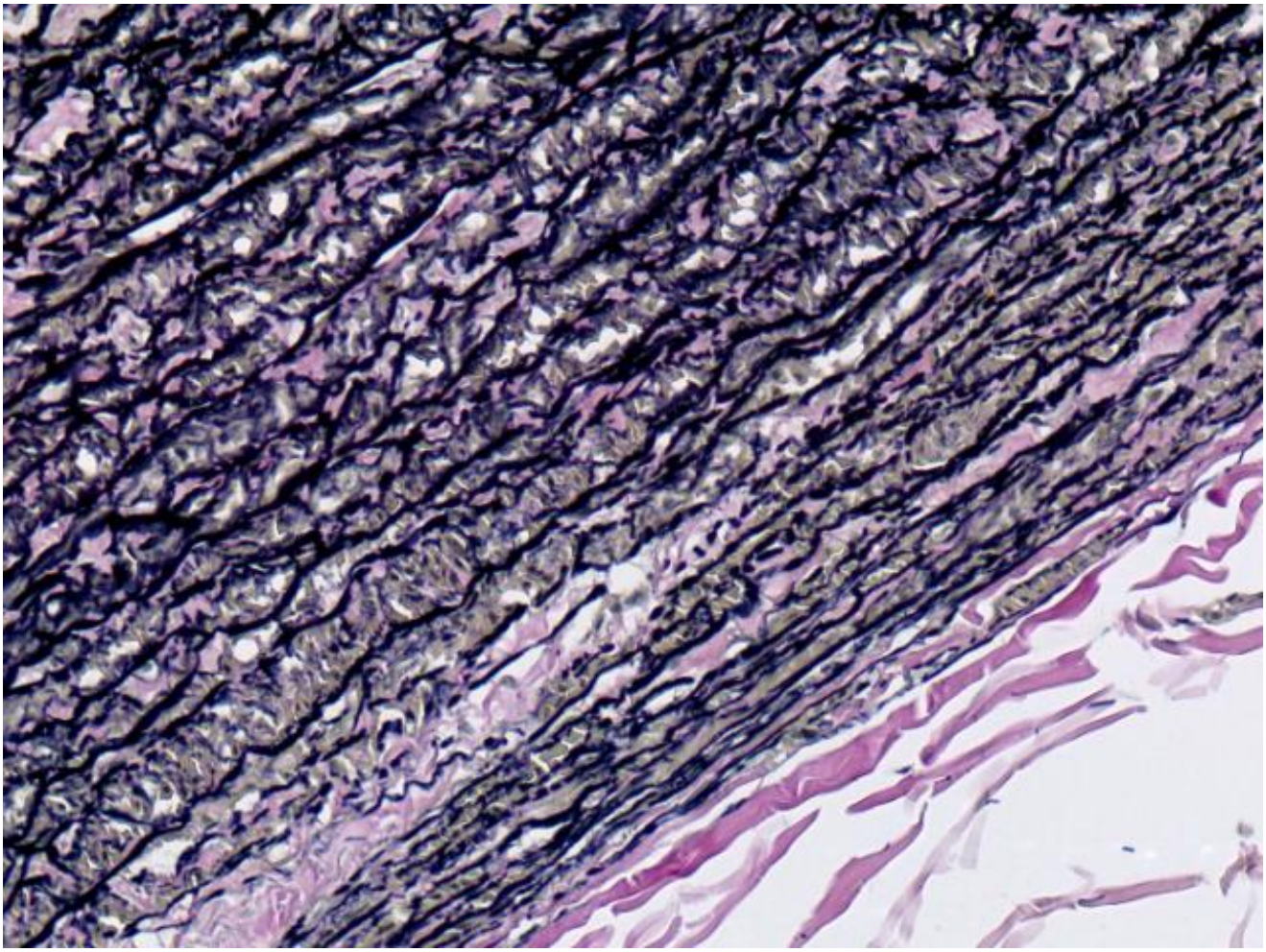

Elastic cartilage contains a lot of elastic fibers with thin collagen fiberils in its matrix. As you would expect, this cartilage is more elastic
than hyaline cartilage. This exatra elasticity allows for better tolerance of repeated bending. The body has elastic cartilage tissue in the eustacian tubes which regulate the inner ear pressure, it form the structure of the outer ear (the auricle) and it forms the epiglottis. The epiglottis, which bends down to cover the glottis (opening) of the larynx each time we swallow, is made of elastic cartilage, as is the highly bendable cartilage in the outer ear. Elastic cartilage contains chondrocytes that are dispersed within a a threadlike network of elastic fibrers. Elastic cartilage functions to provides support. It also provides structure to the area. .

Bone (Osseous Tissue)



Bone is a tissue, also known as osseous tissue. Bone is alive and filled with blood vessels. It has incredible stregthe due to inorganic calcium salts that form a rigid ground substance of the matrix. Bone functions in the body to provide structural support and protection to internal body structures. Bone is able to withstand a great deal of compression and tension (pushing force and pulling force). The primary cell of bone tissue is the osteoblast. Osteoblastss secrete the collagen fibers and the materials needed for the ground substance. These materials are then calcified by the addition of calcium salts which form the rigid ground substance of the bone. When bone is mature, the matrix consists of collagen fibers surrounded by a calcified rigid ground substance. The osteoblasts mature into the osteocytes. The osteocytes reside in the lacunae filling up the space.
