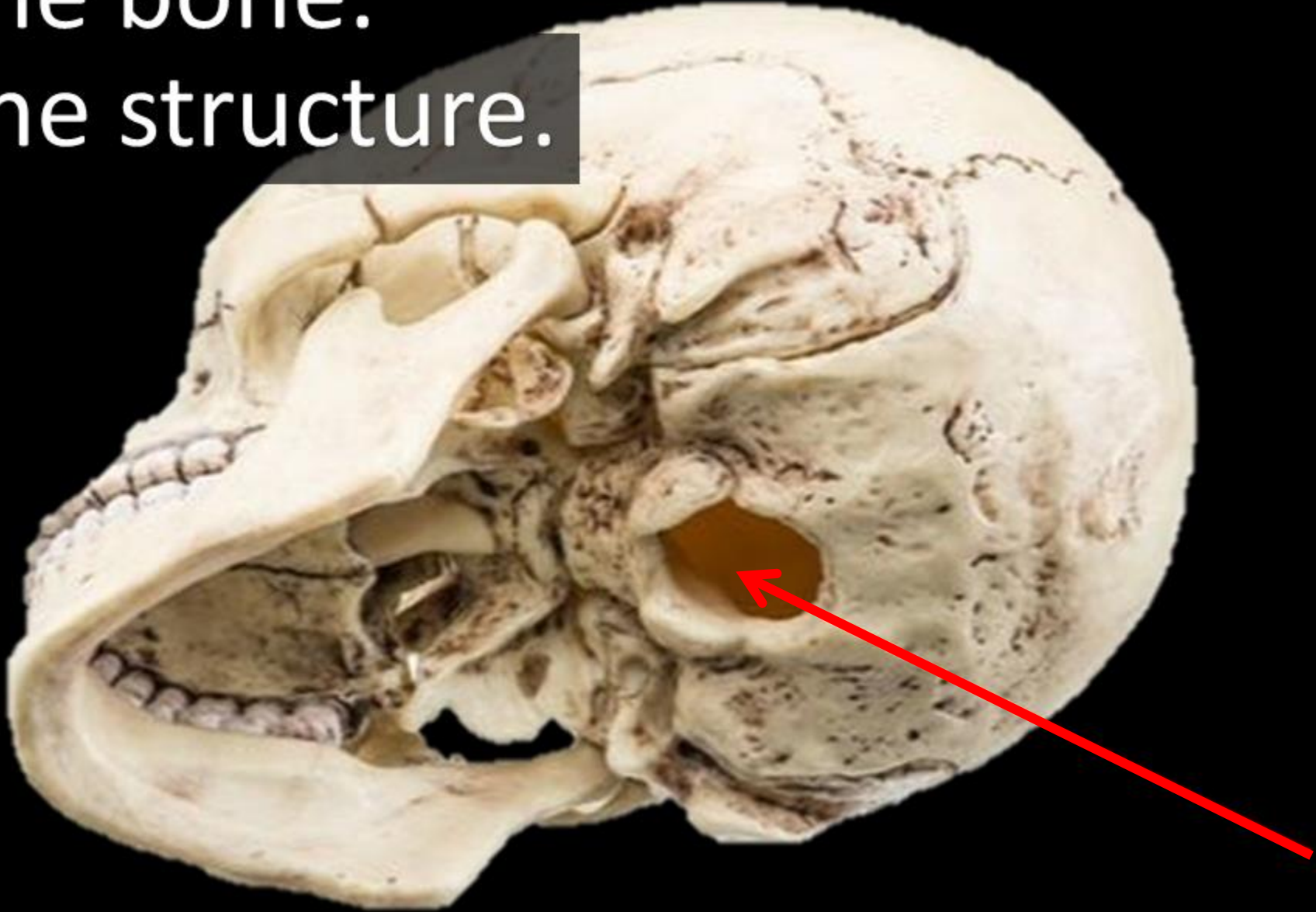


by SCIENTIST CINDY

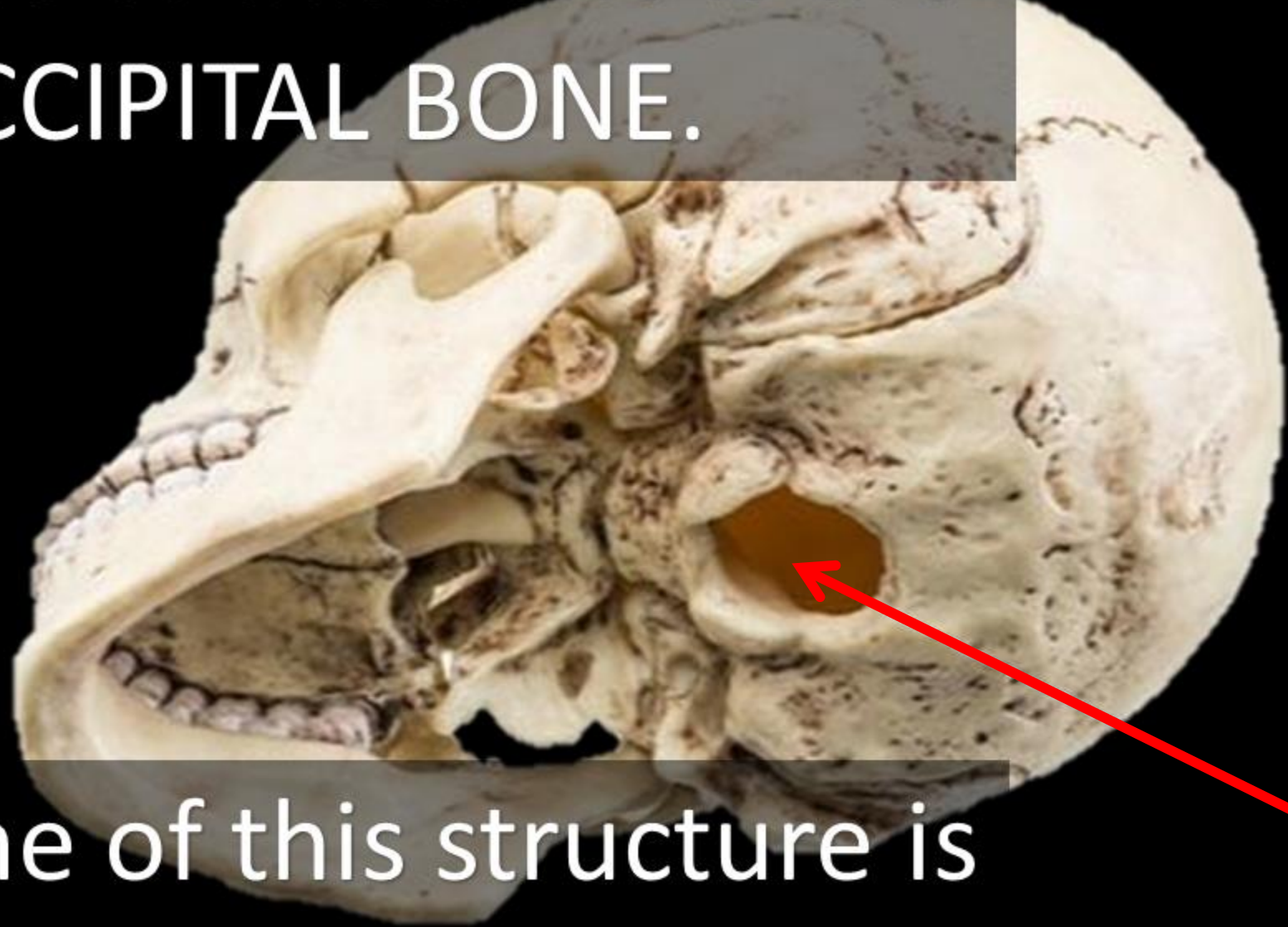
SKULL ANATOMY FLASH CARDS



Name the bone.
Name the structure.

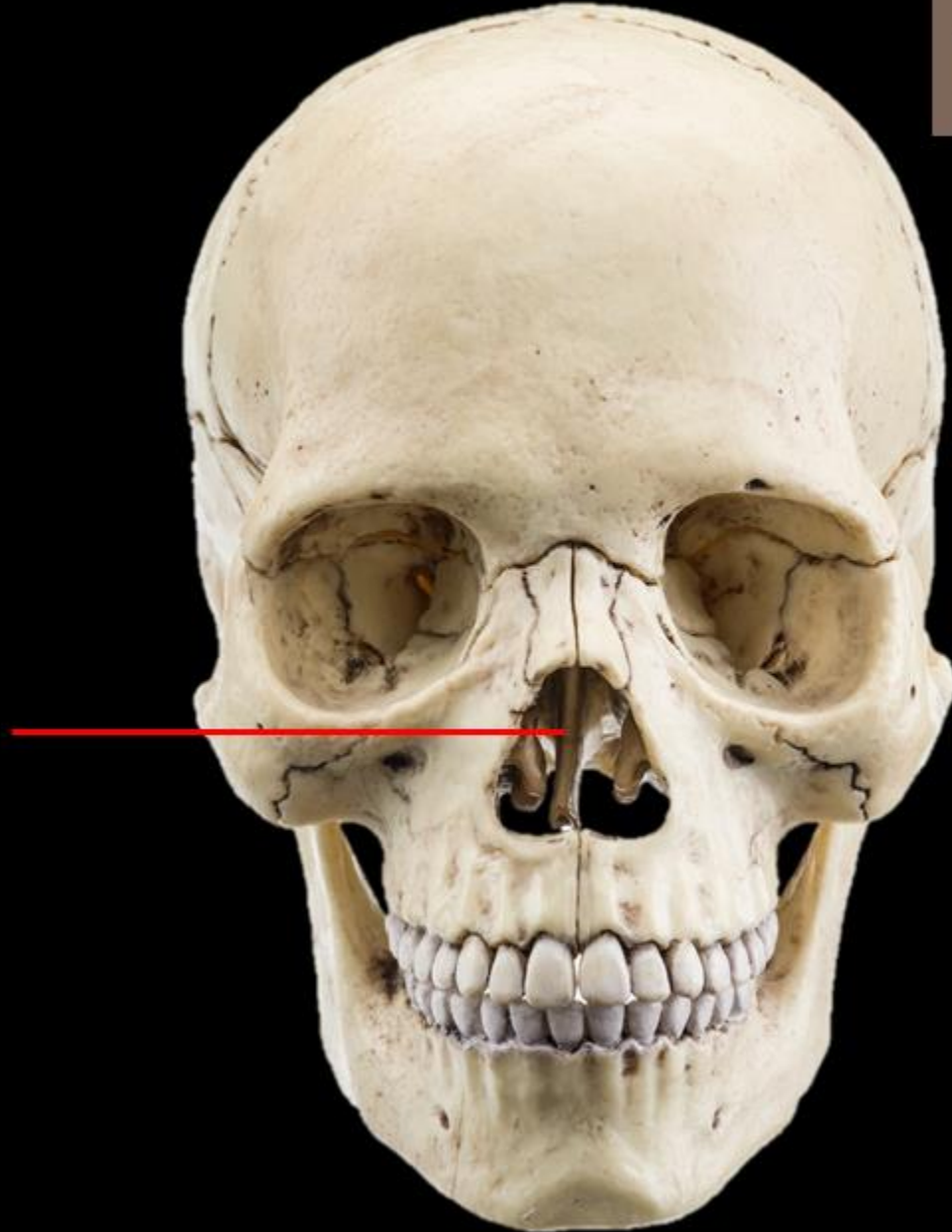


The name of this bone is the
OCCIPITAL BONE.



The name of this structure is
the **FORAMEN MAGNUM.**

Name the Bone
Name the Structure

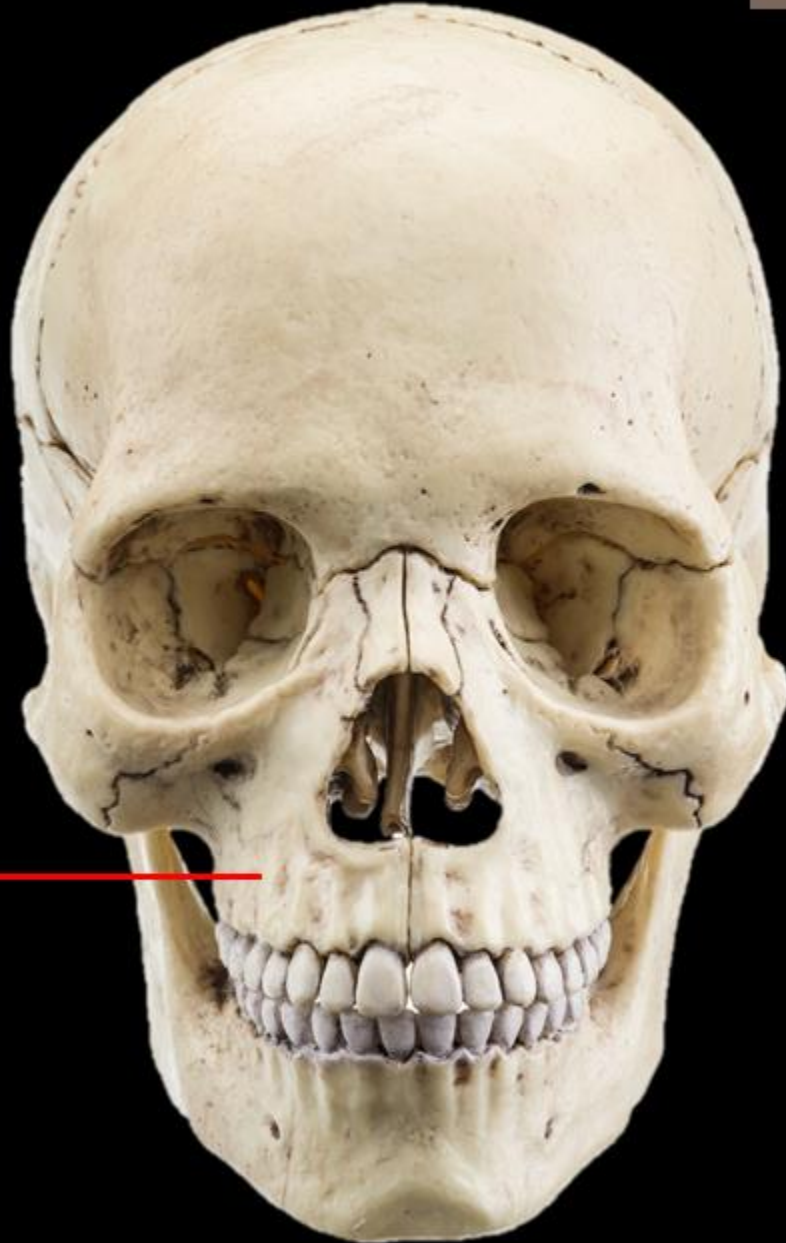

Name the Bone = Ethmoid Bone

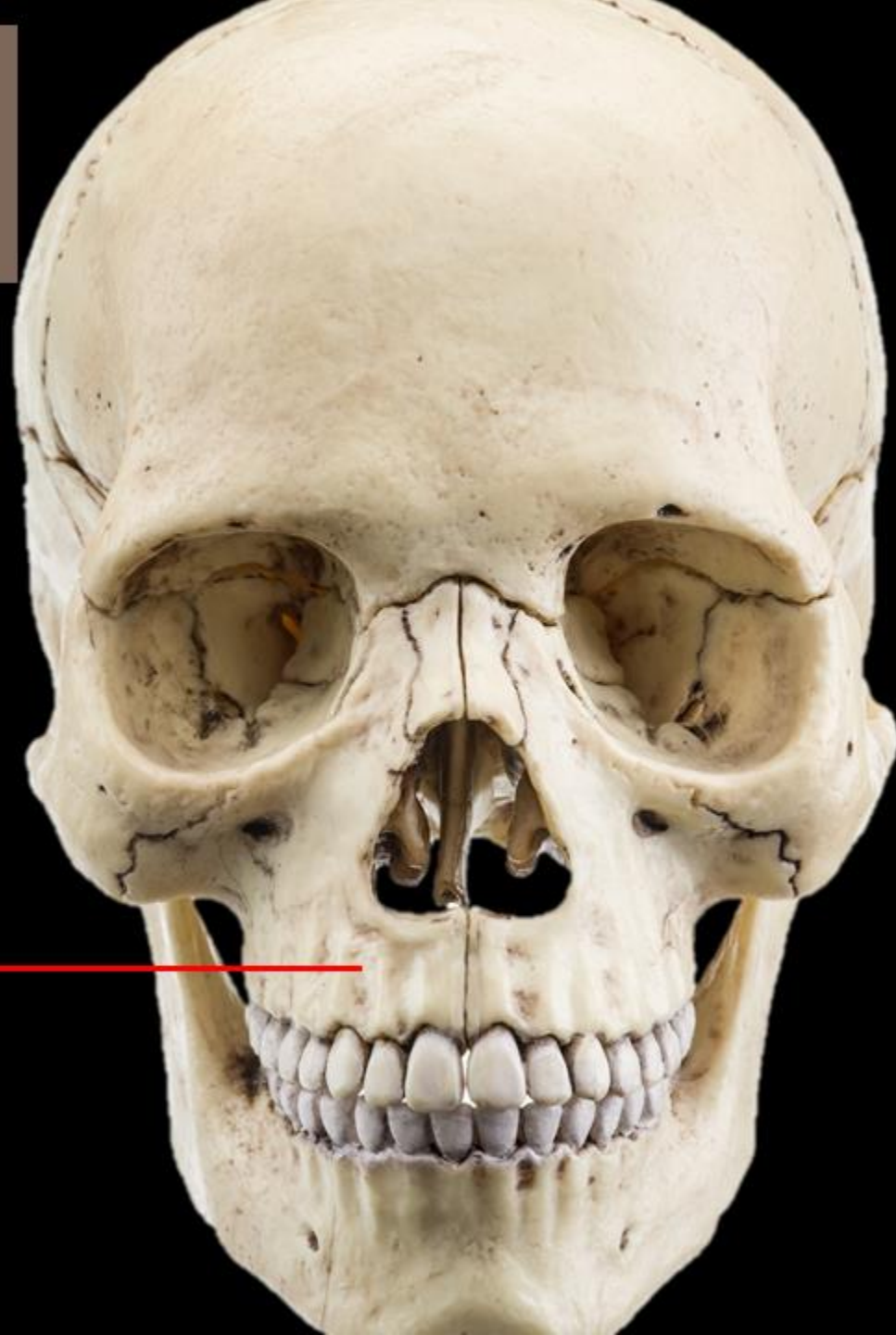Name the Structure = The Perpendicular Plate



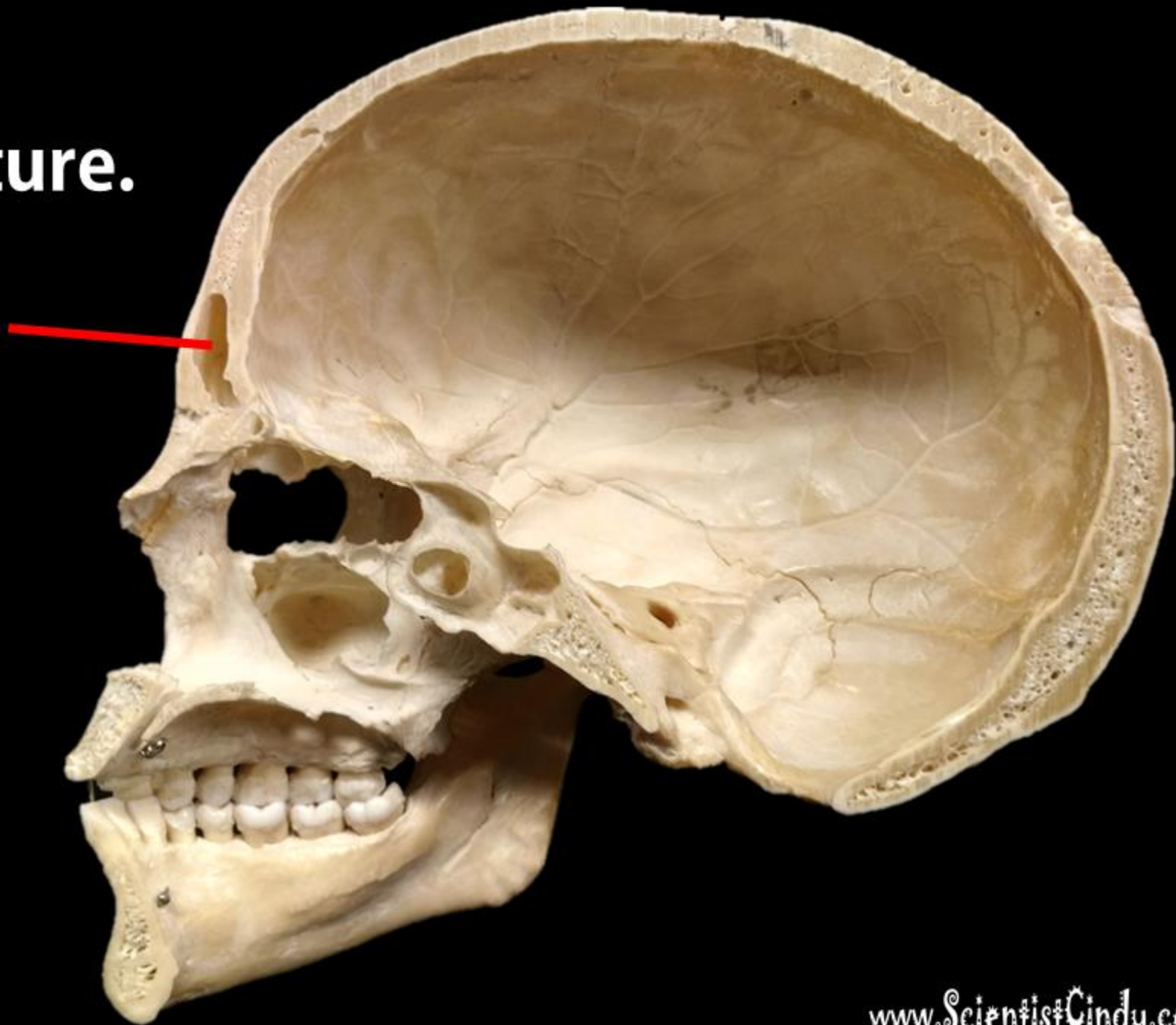
Name the Bone



Name the Bone
= MAXILLA

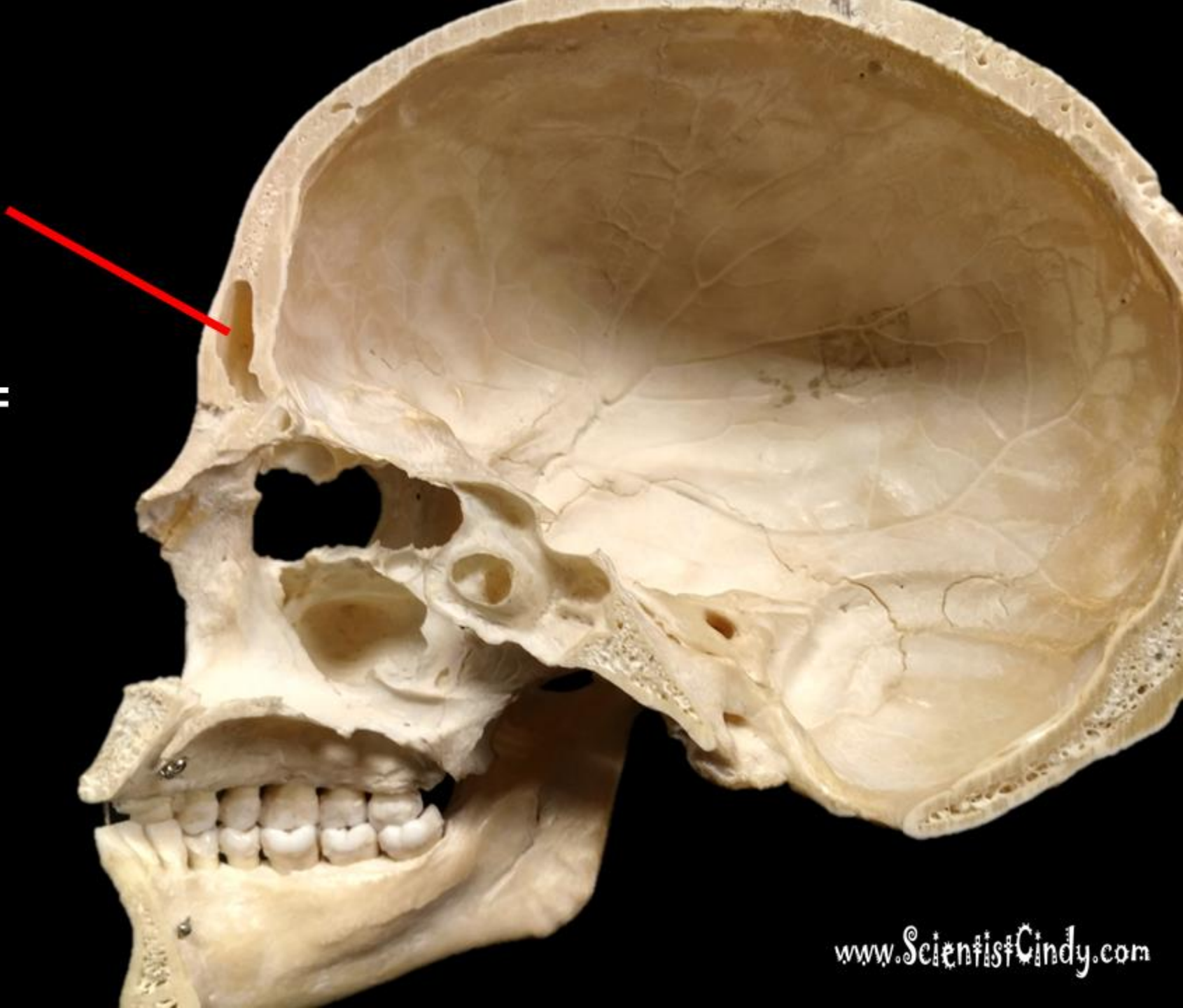


**Name the Bone.
Name the Structure.**



**Name the Bone =
FRONTAL BONE**

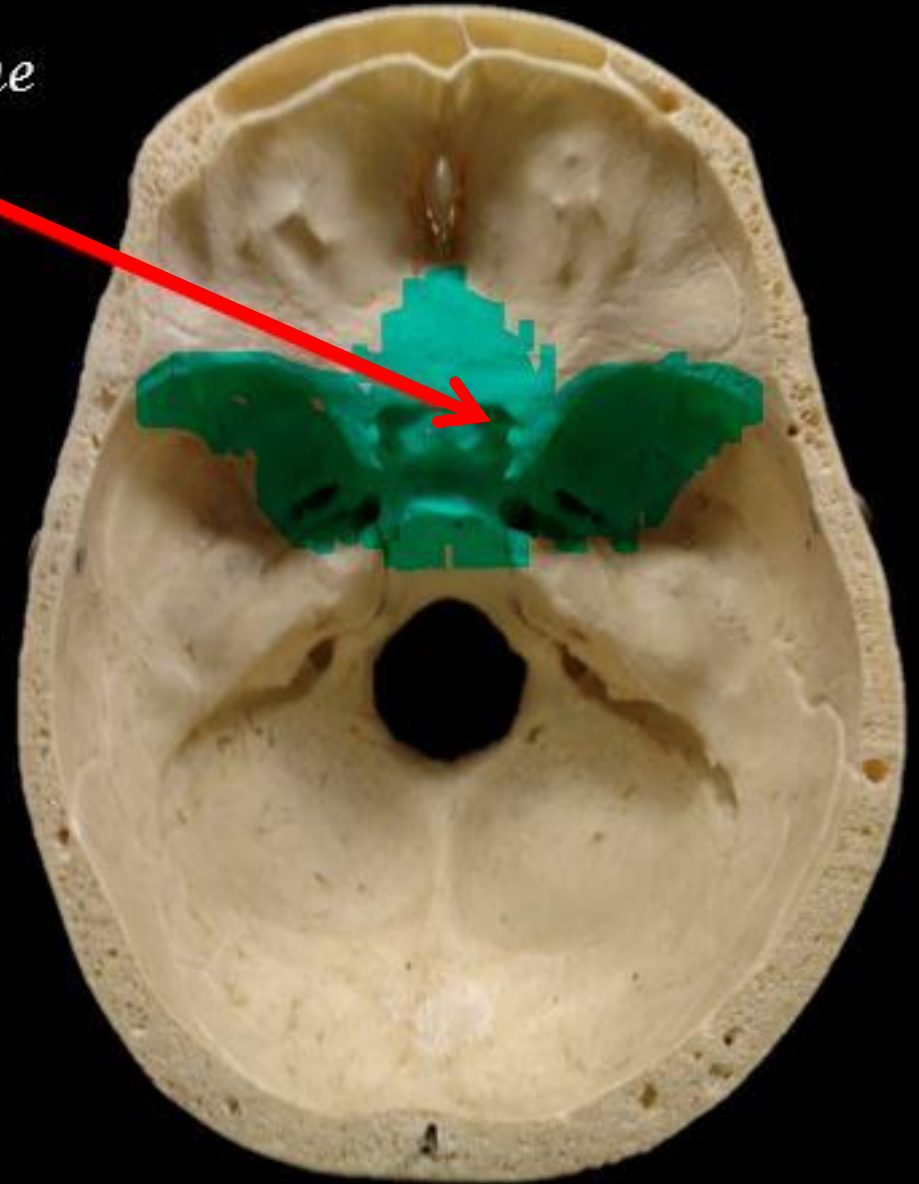
**Name the Structure =
FRONTAL SINUS**



Name the Bone.

Sphenoid Bone

Name the Structure.

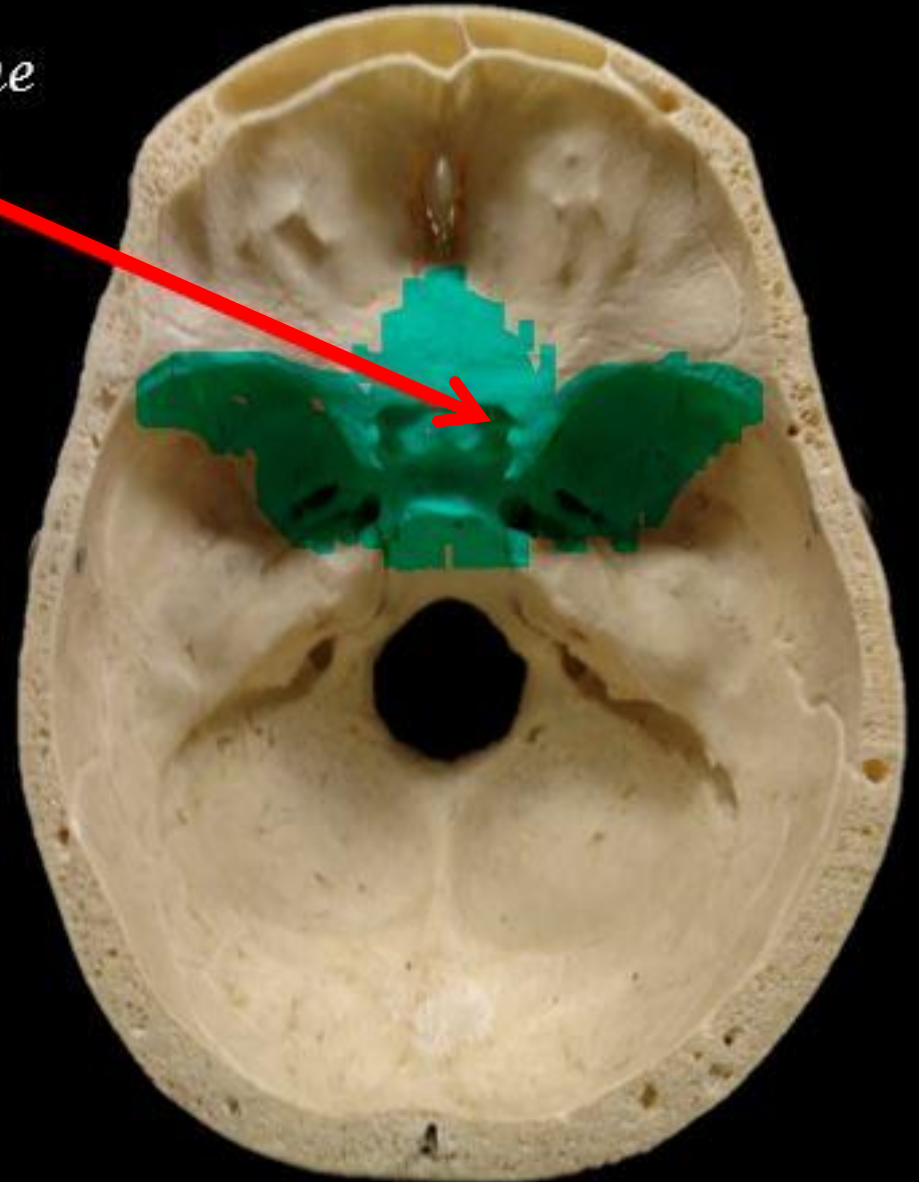


Name the Bone.

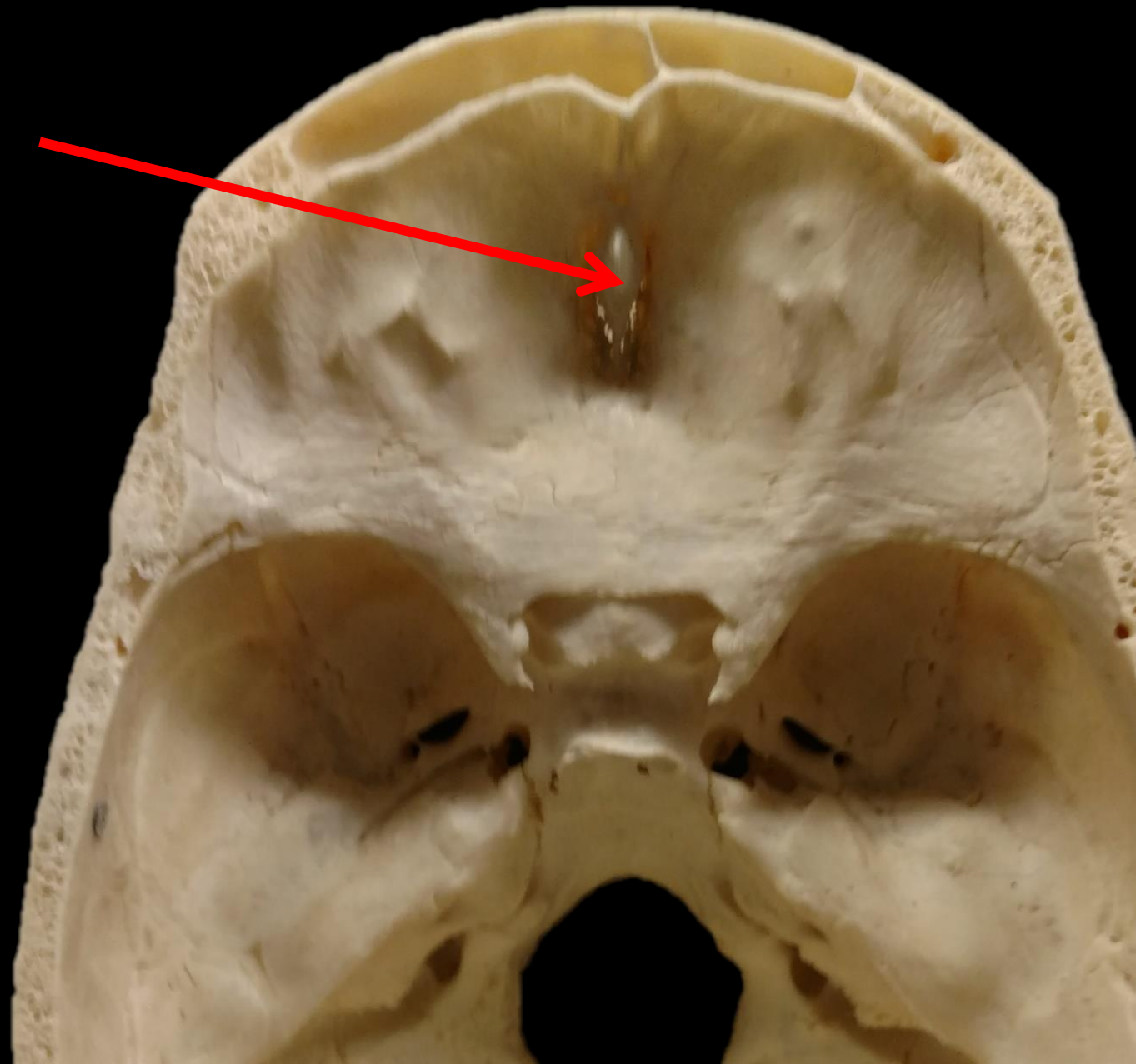
Sphenoid Bone

Name the Structure.

The Optic Foramen of
the Sphenoid Bone

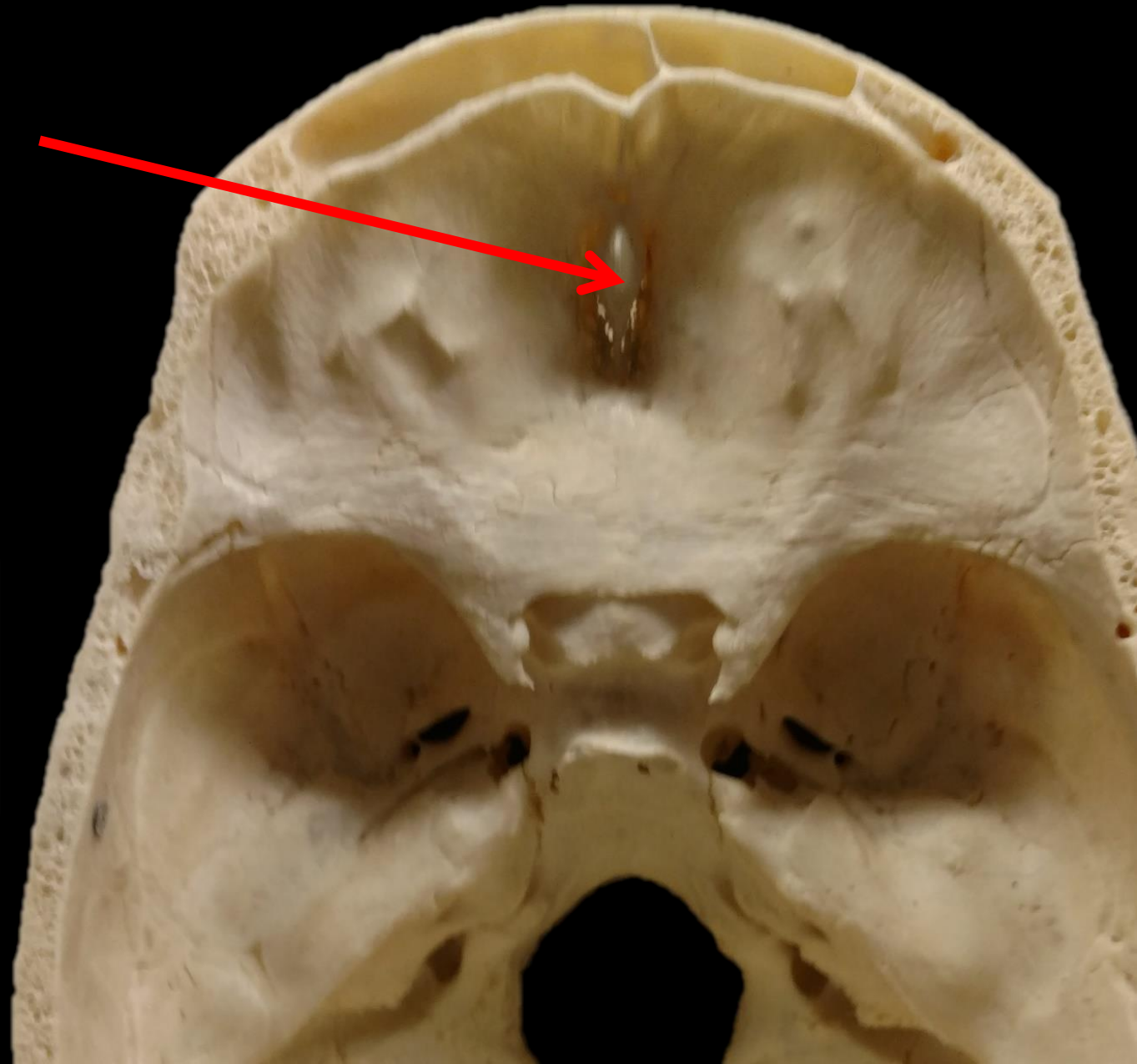


*Name the
Structure and the
Bone.*

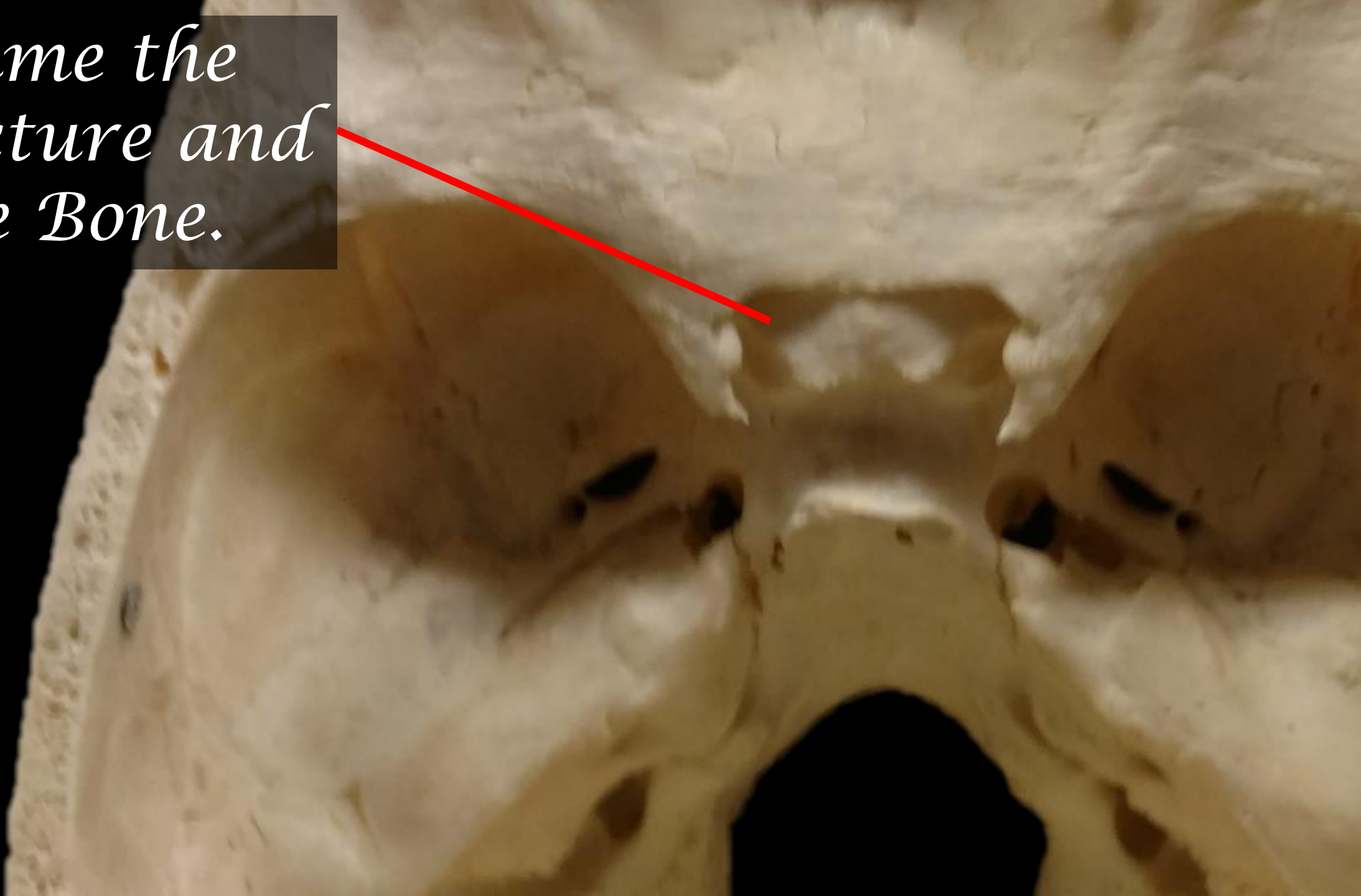


*Name the
Structure and the
Bone.*

The Crista Galli
of the
Ethmoid Bone

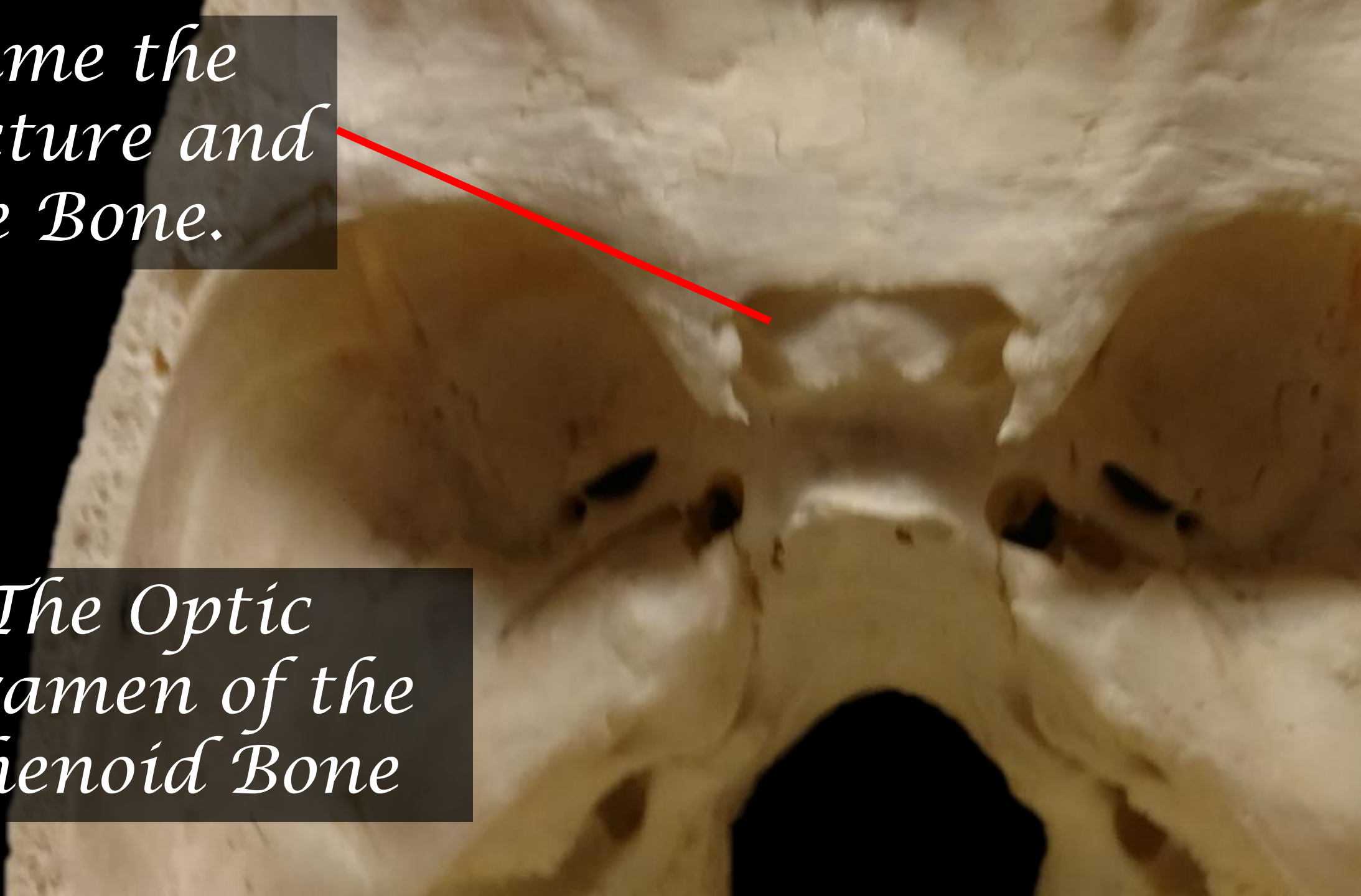


*Name the
Structure and
the Bone.*

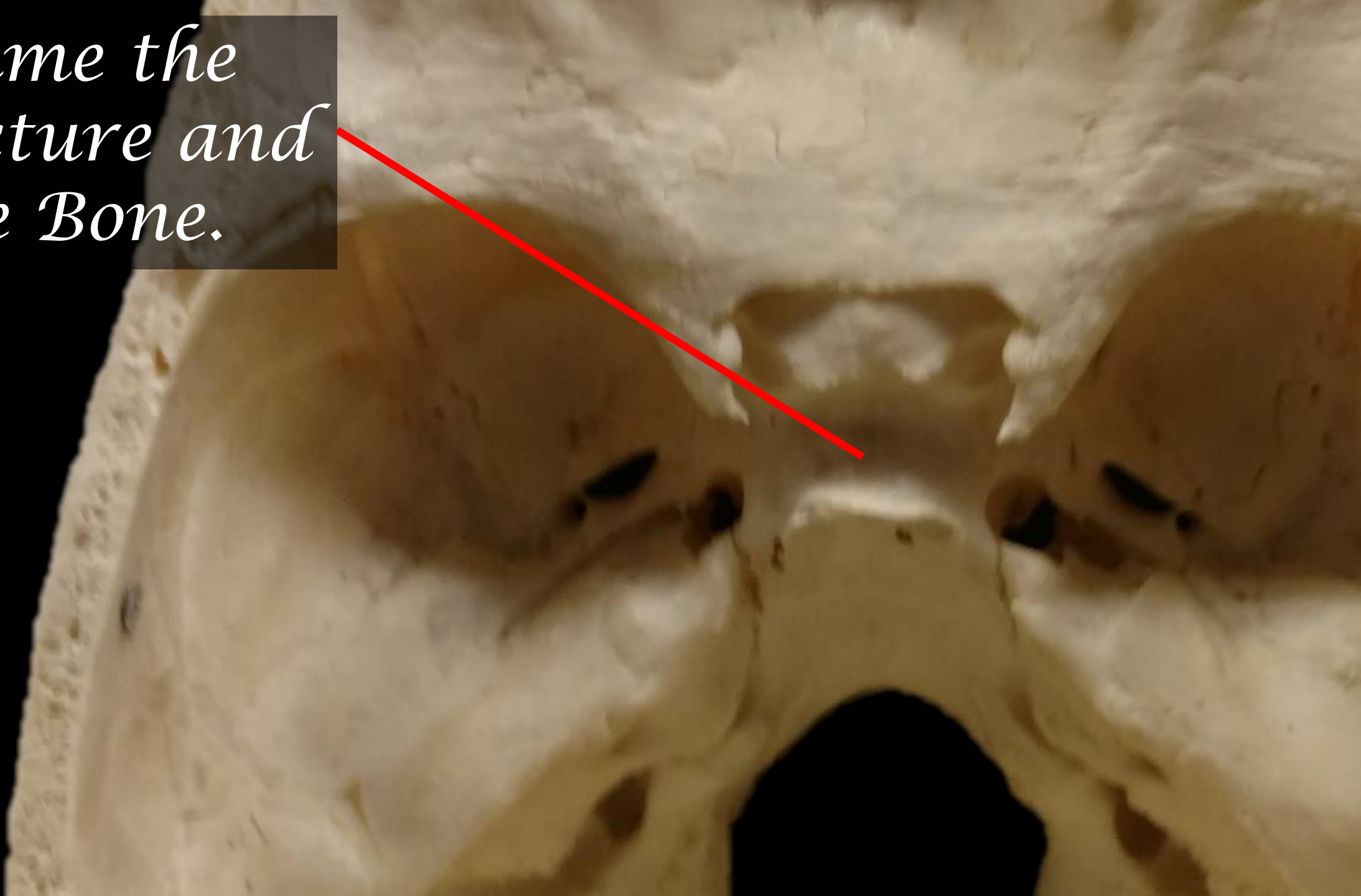


*Name the
Structure and
the Bone.*

*The Optic
Foramen of the
Sphenoid Bone*

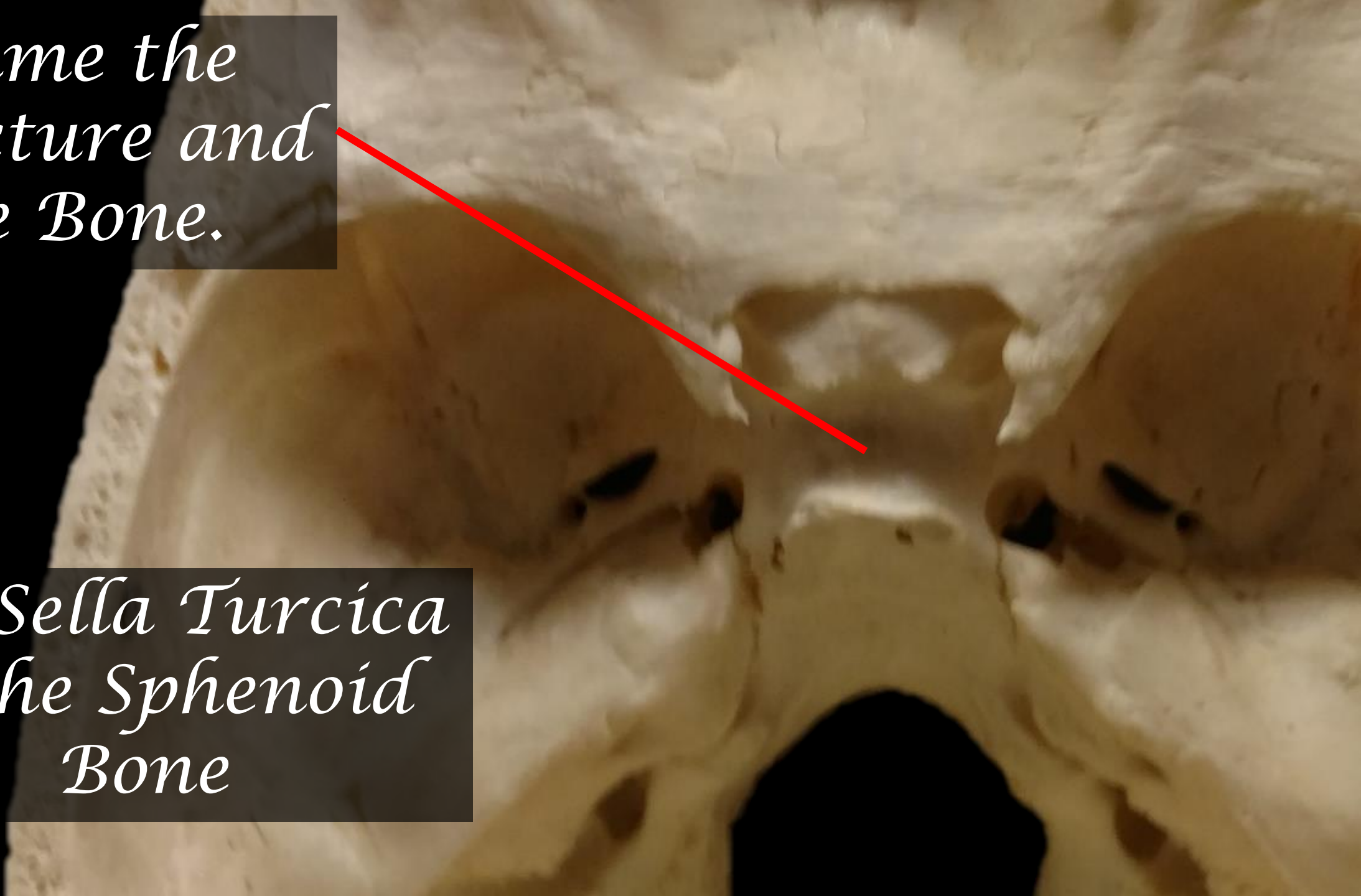


*Name the
Structure and
the Bone.*

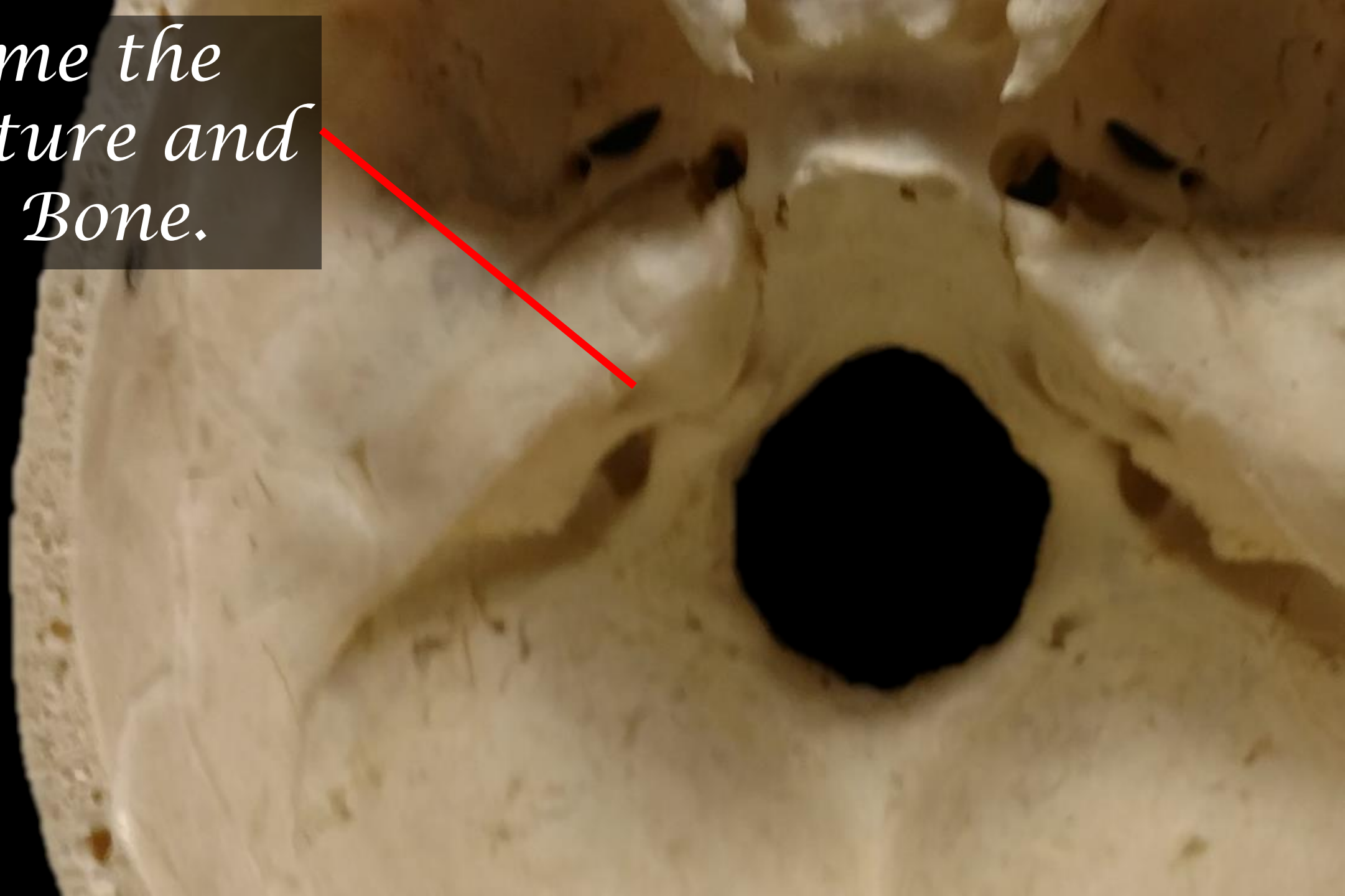


*Name the
Structure and
the Bone.*

*The Sella Turcica
of the Sphenoid
Bone*



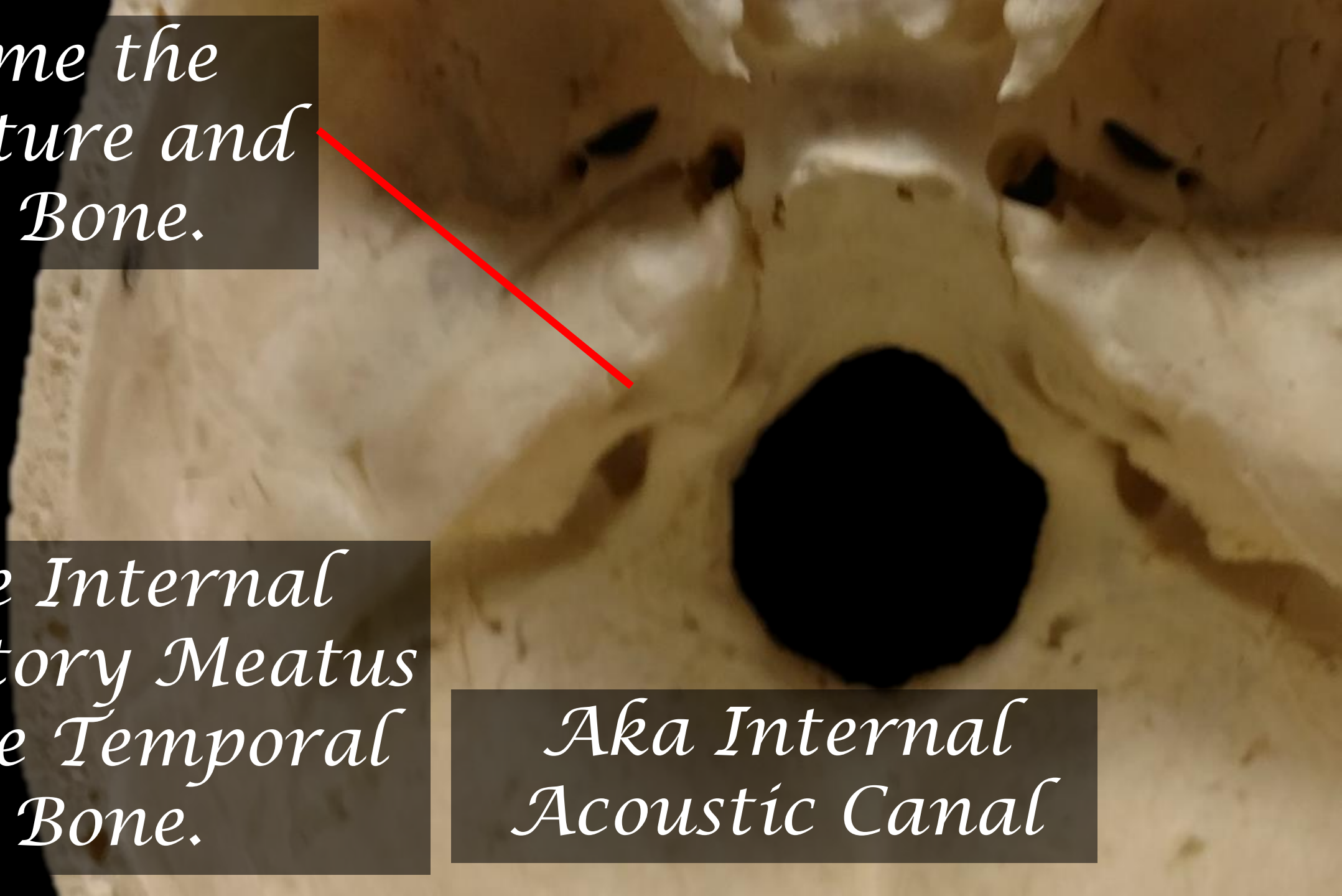
*Name the
Structure and
the Bone.*



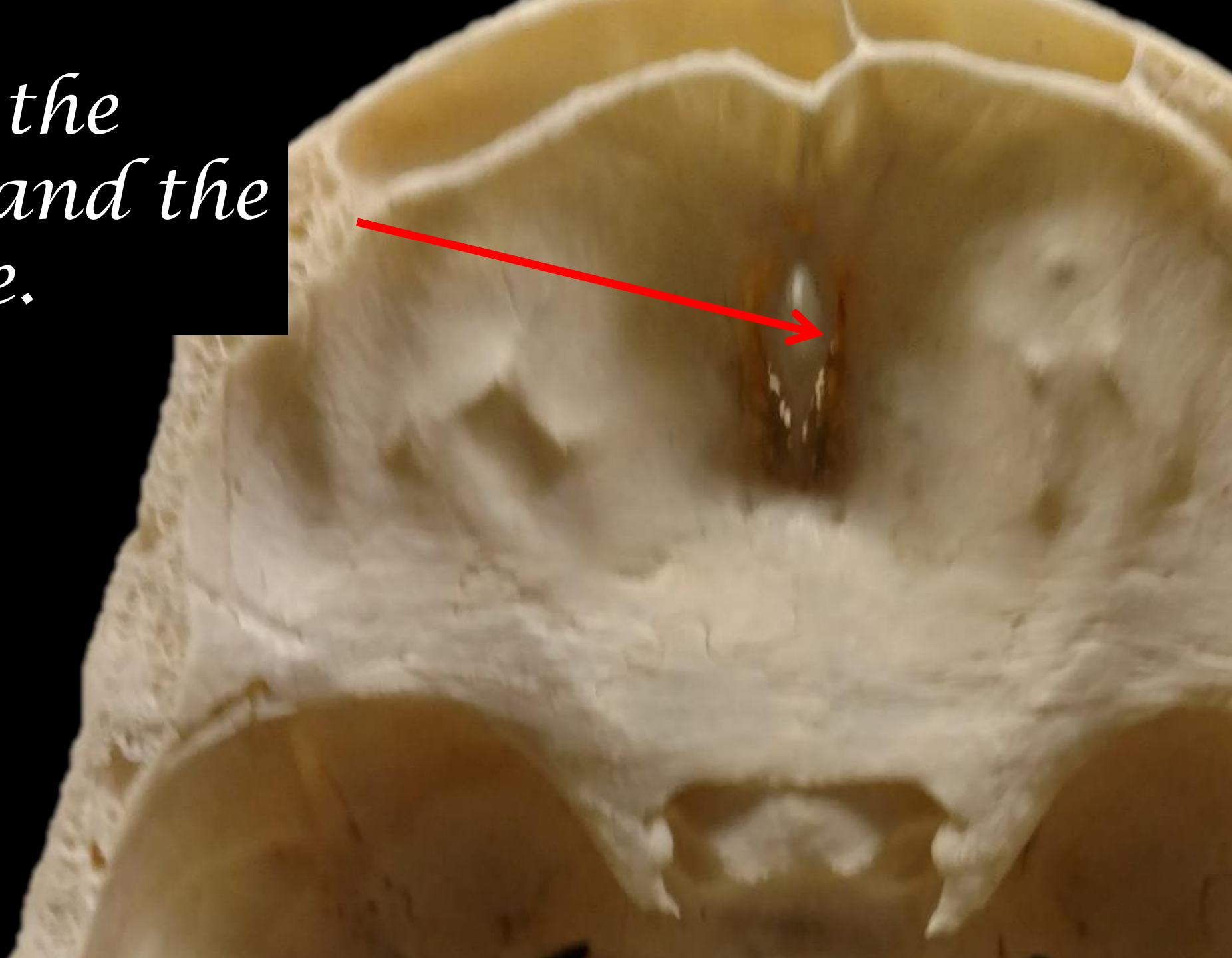
*Name the
Structure and
the Bone.*

*The Internal
Auditory Meatus
of the Temporal
Bone.*

*Aka Internal
Acoustic Canal*

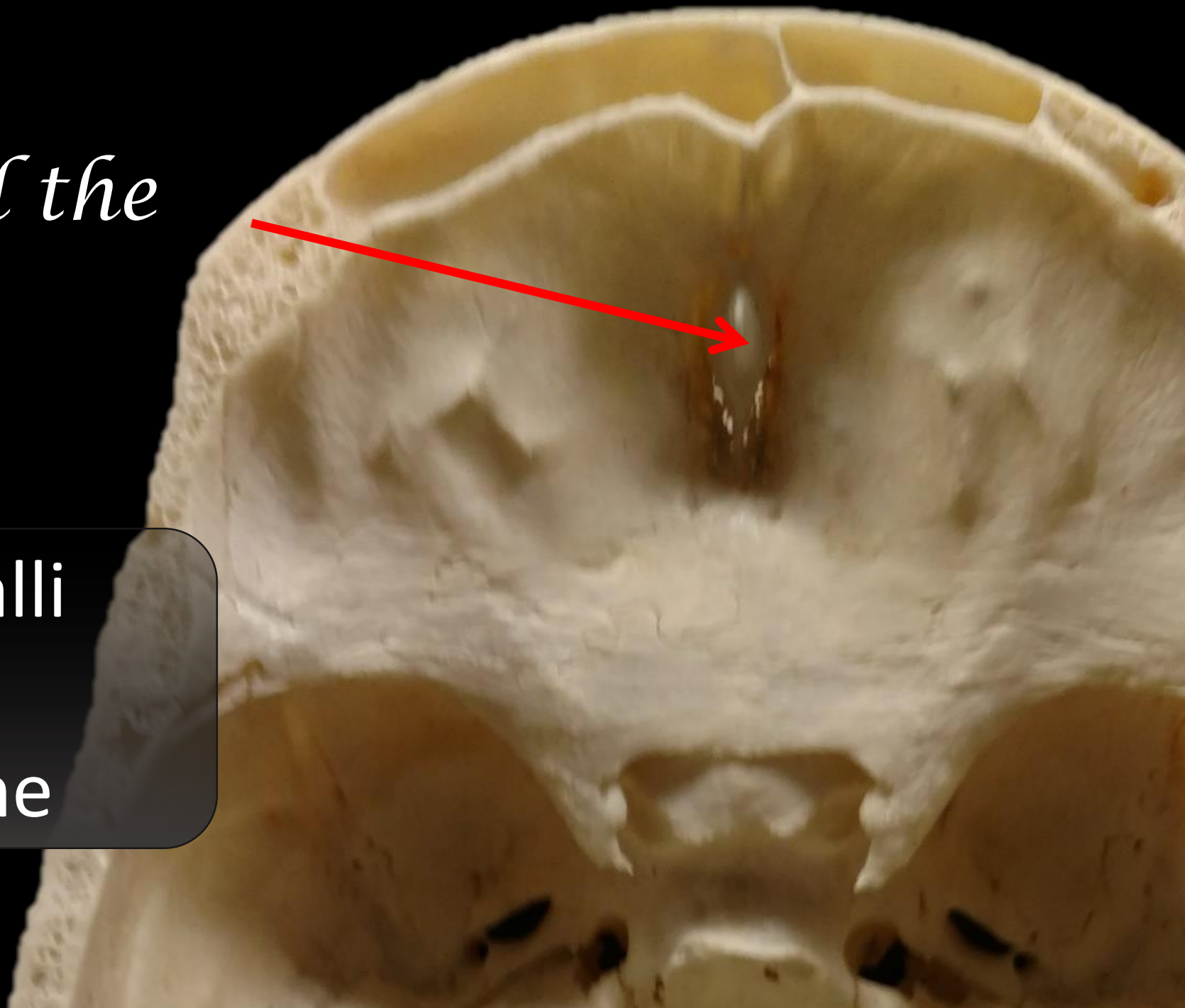


*Name the
Structure and the
Bone.*

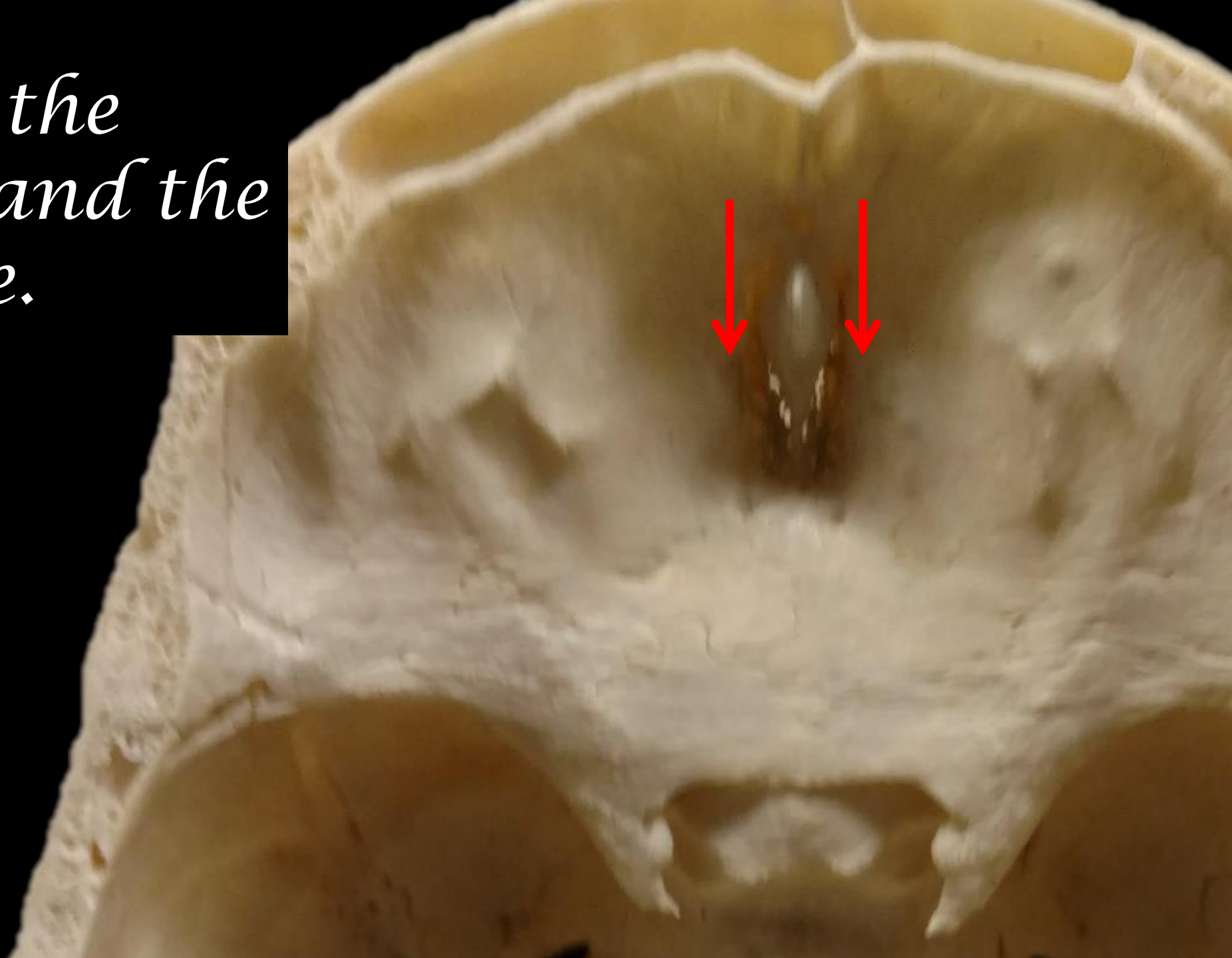


*Name the
Structure and the
Bone.*

The Crista Galli
of the
Ethmoid Bone

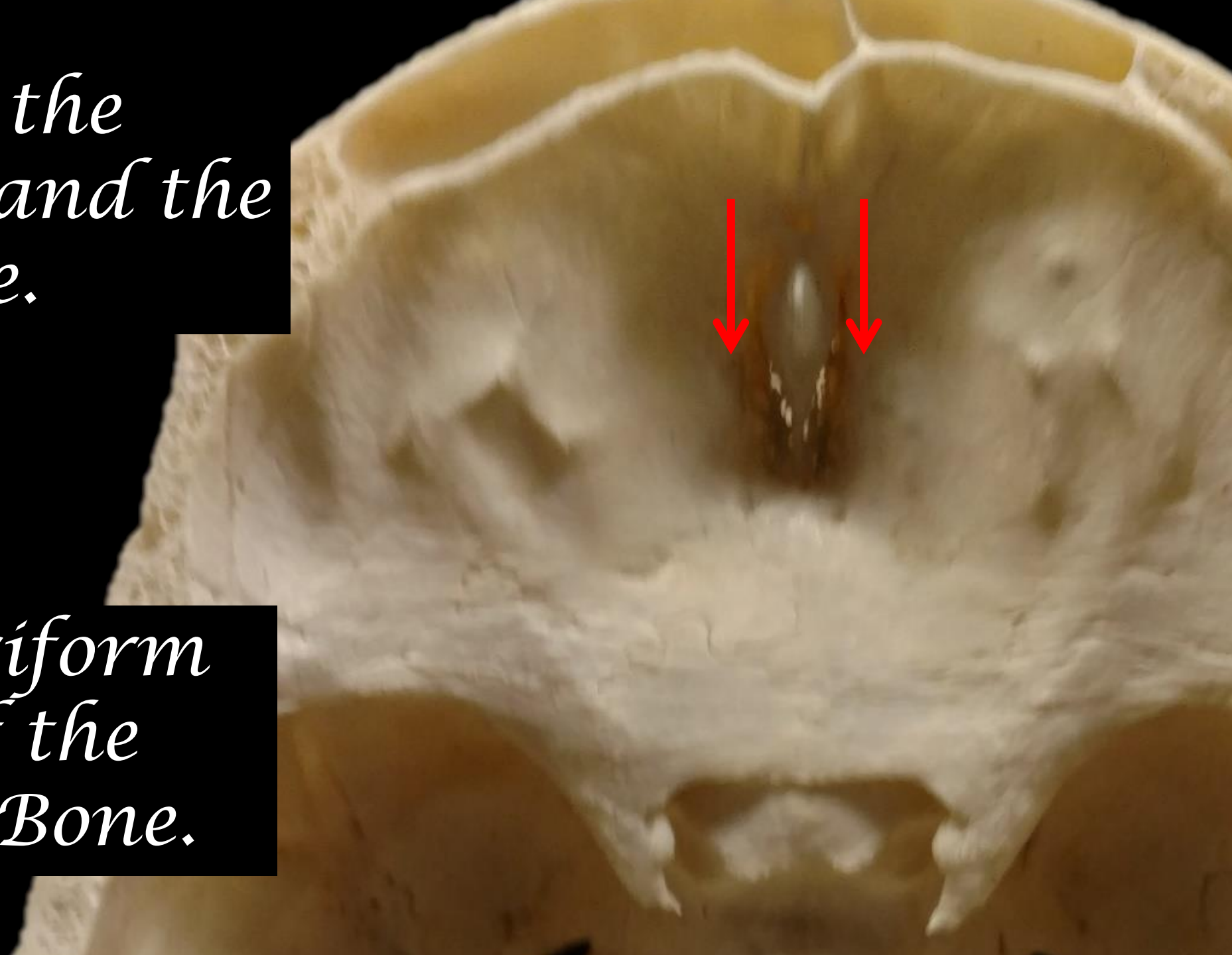


*Name the
Structure and the
Bone.*



*Name the
Structure and the
Bone.*

*The Cribriform
Plate of the
Ethmoid Bone.*

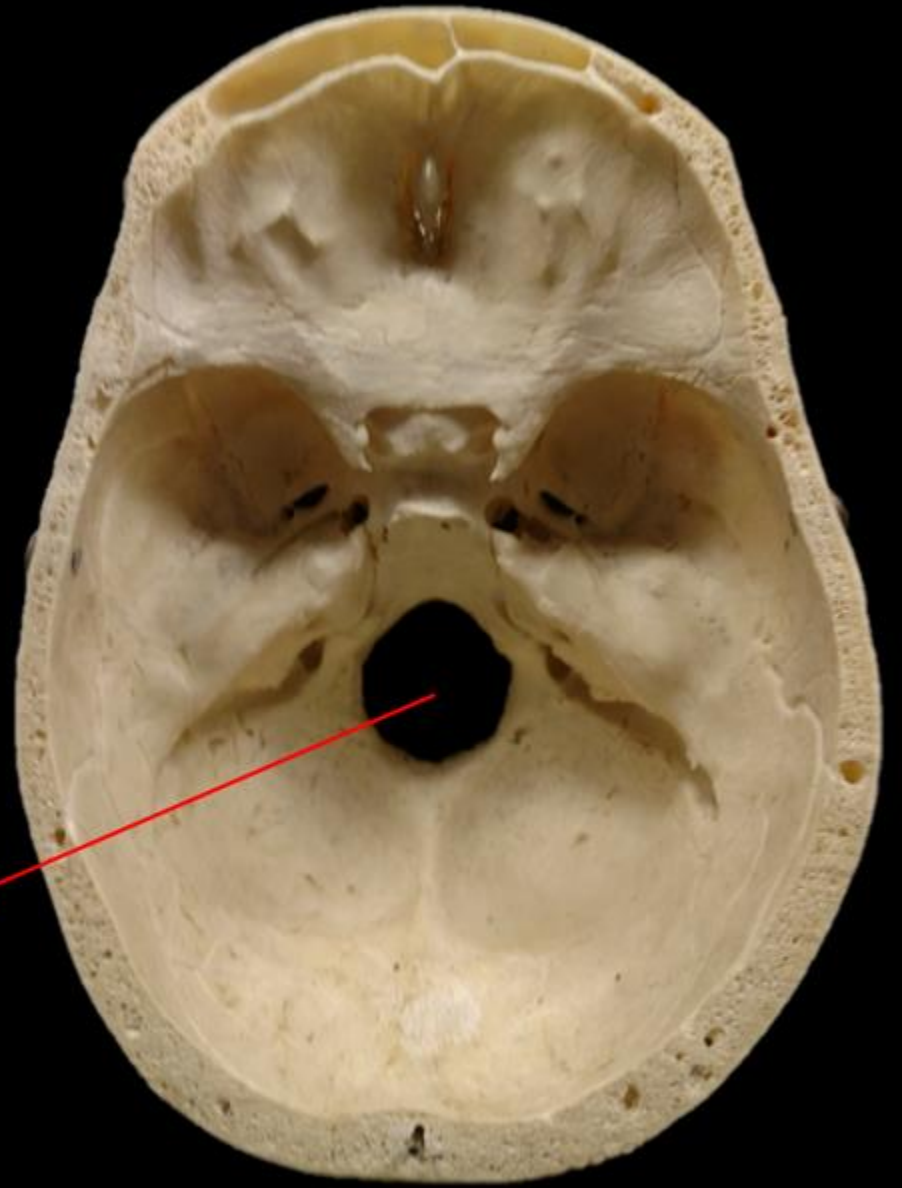


Name the Bone.

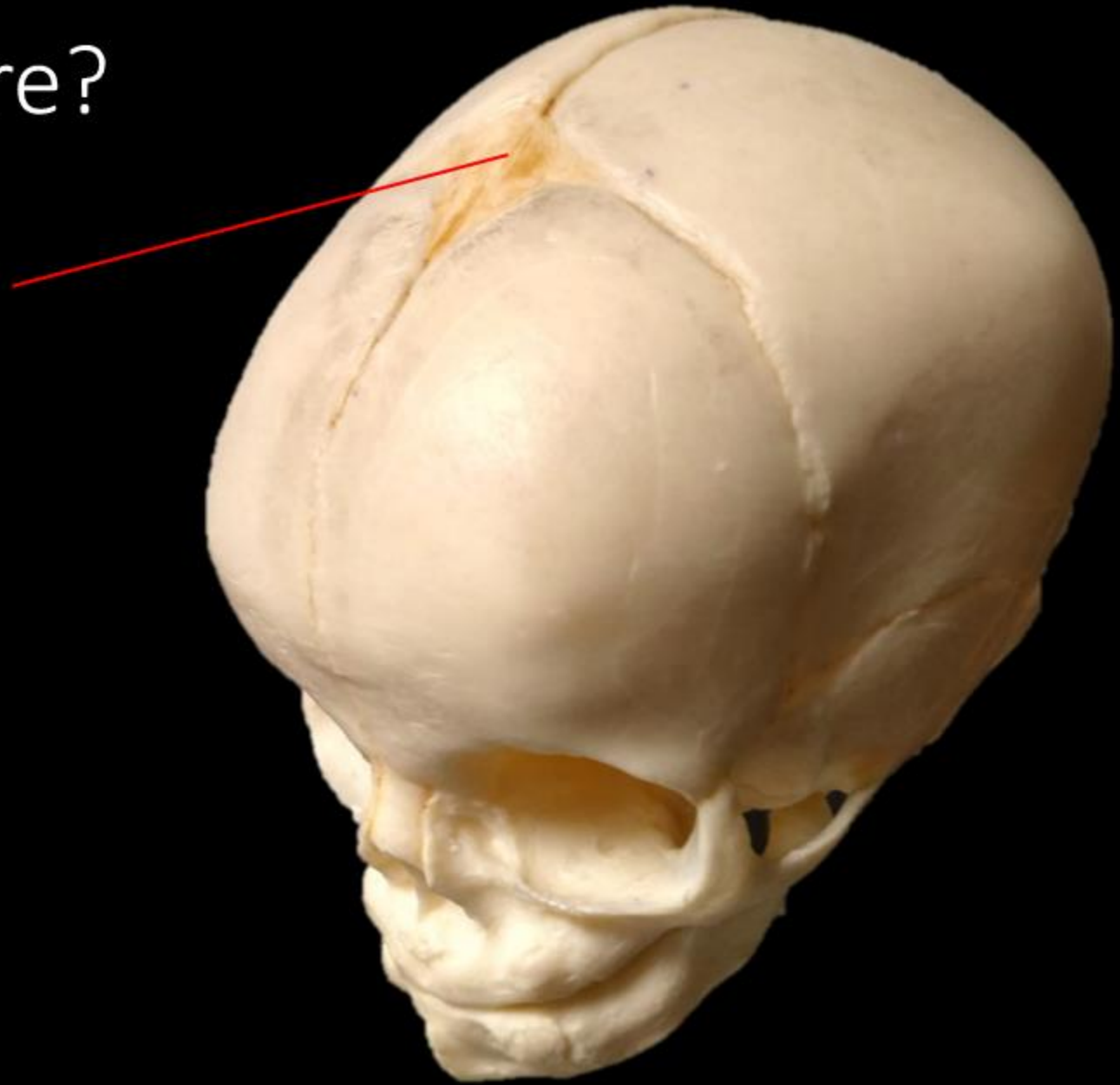
OCCIPITAL BONE

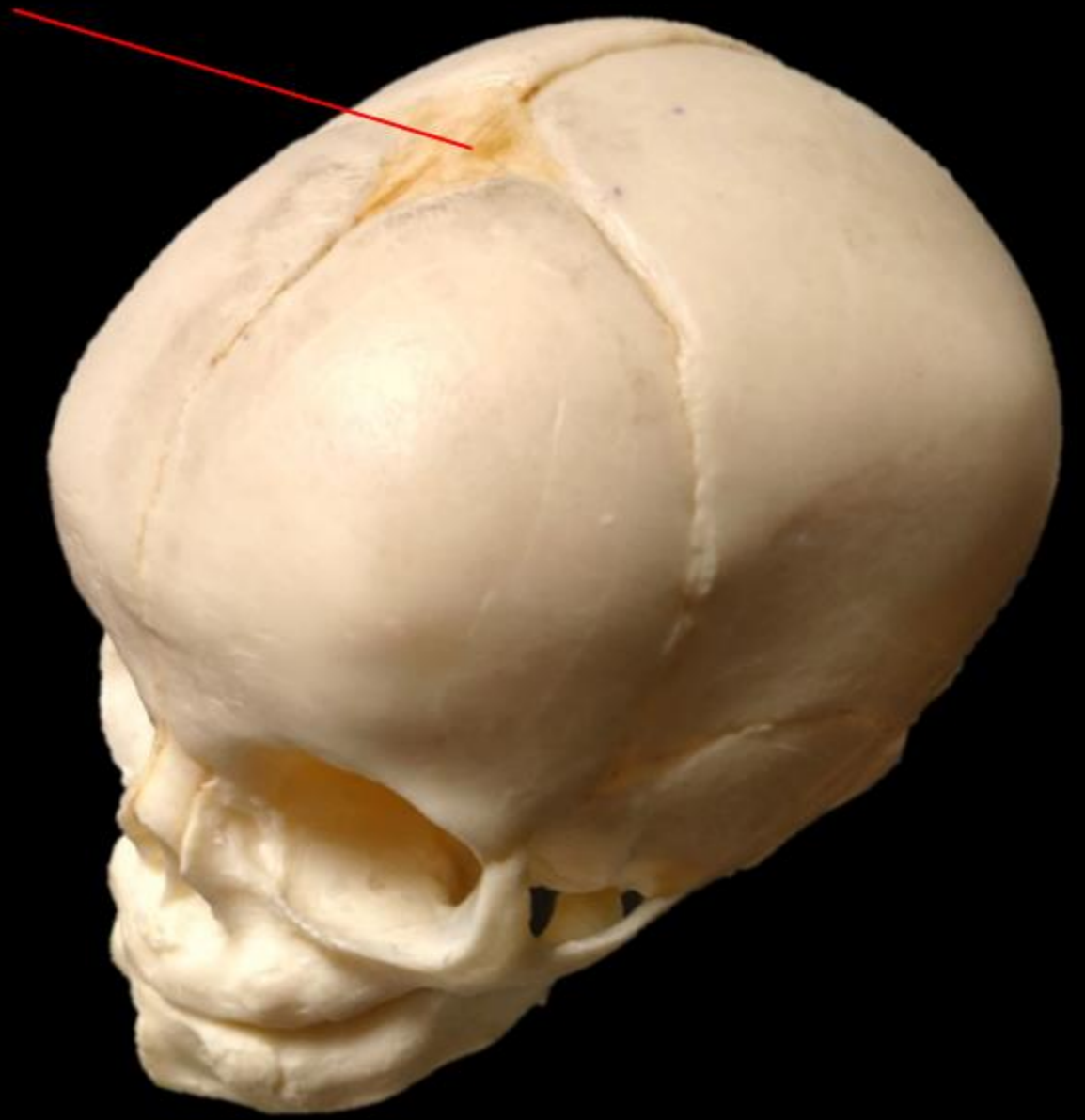
Name the Structure.

FORAMEN MAGNUM



What is the structure?

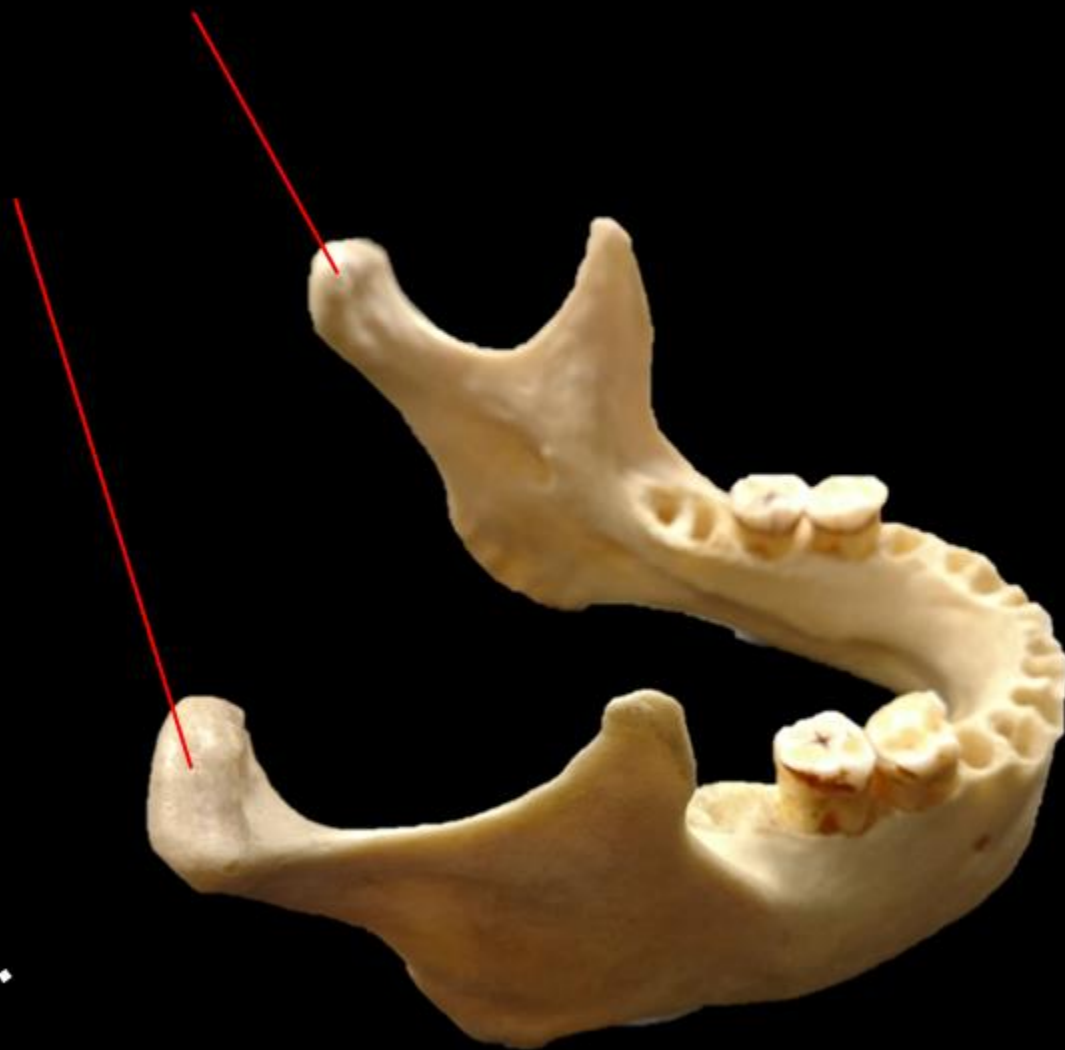




What is the structure =
ANTERIOR FONTANEL

Name the Bone.

Name the Structure.

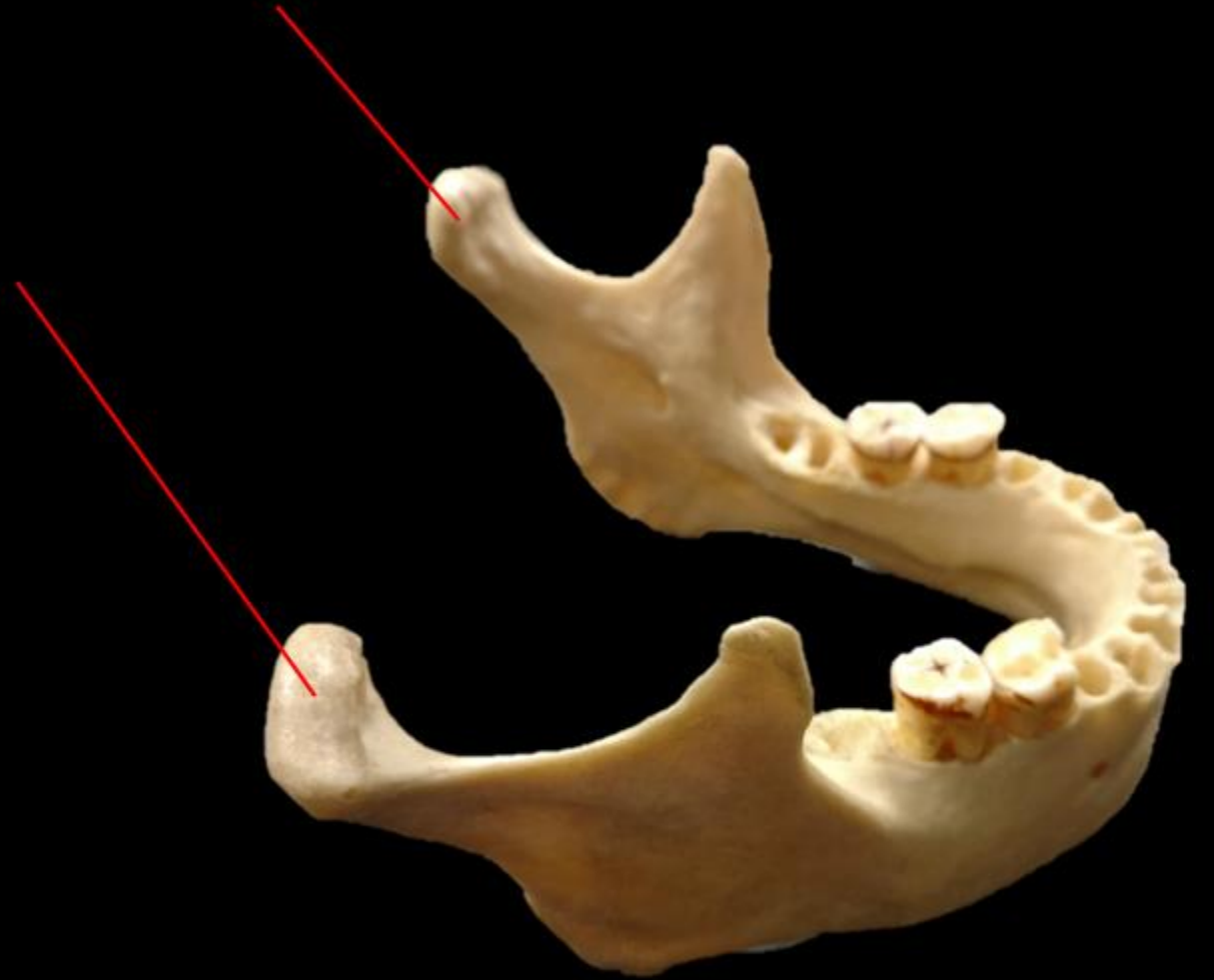


Name the Bone.

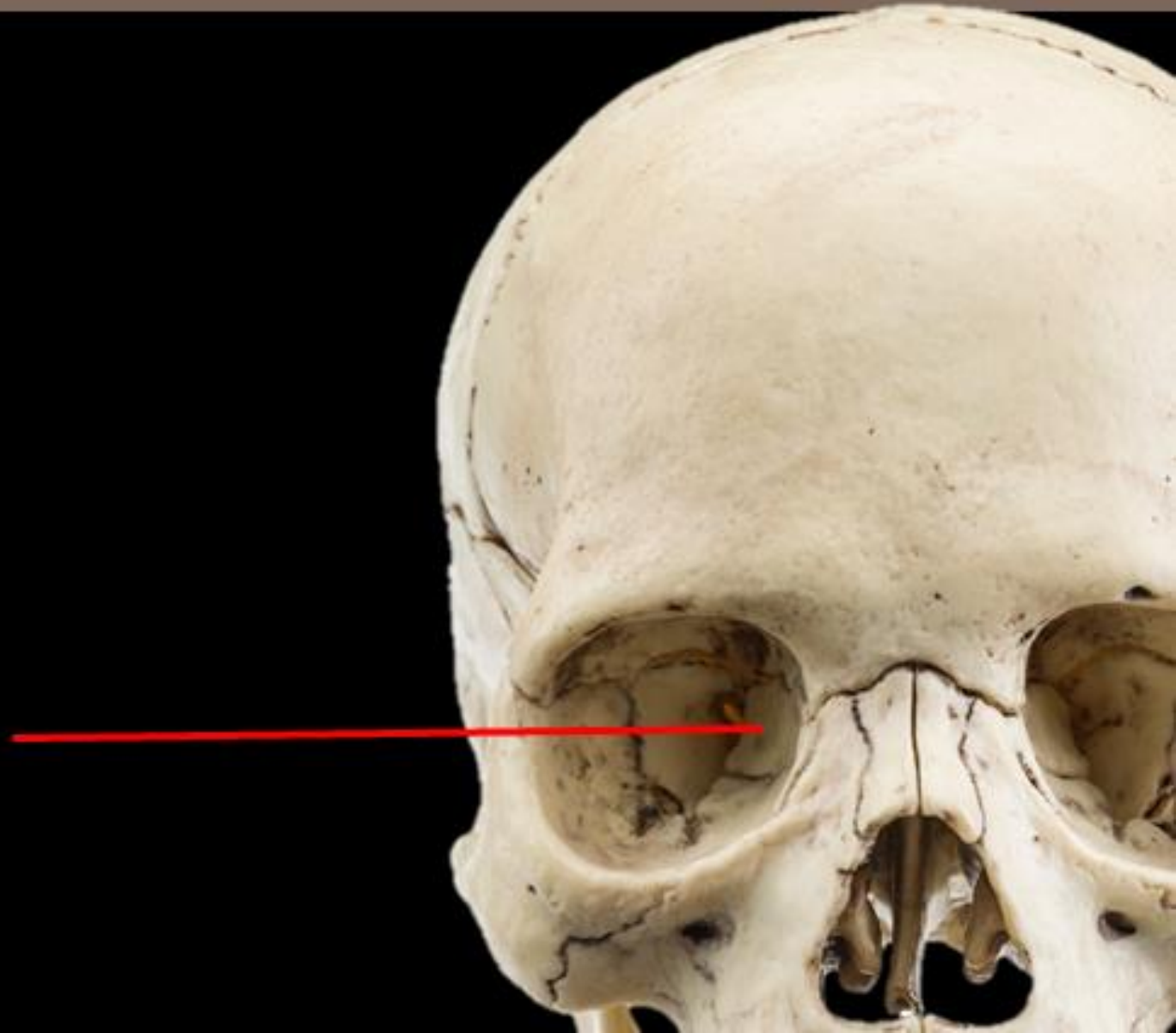
MANDIBLE

Name the Structure.

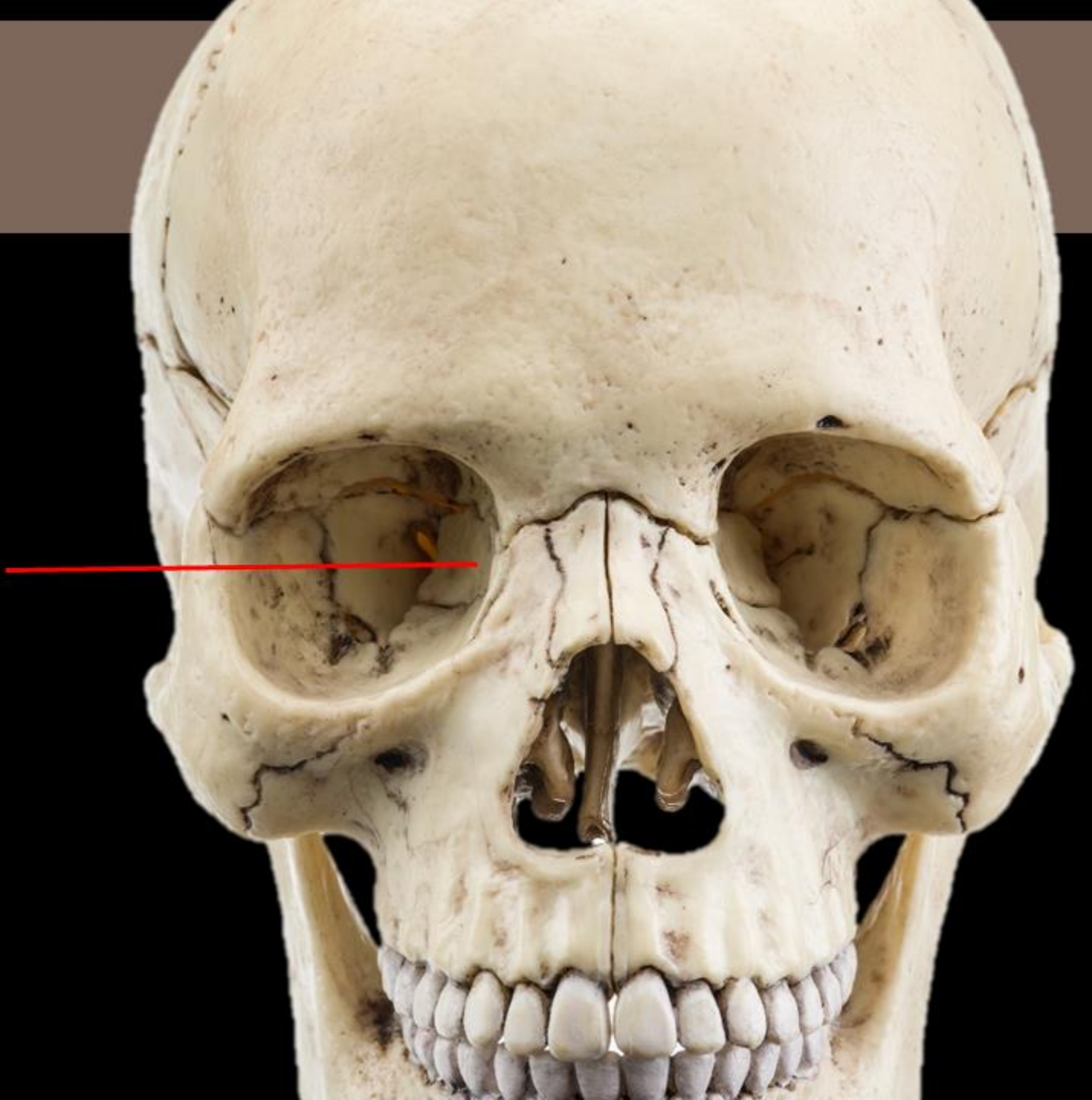
**MANDIBULAR
CONDYLE**



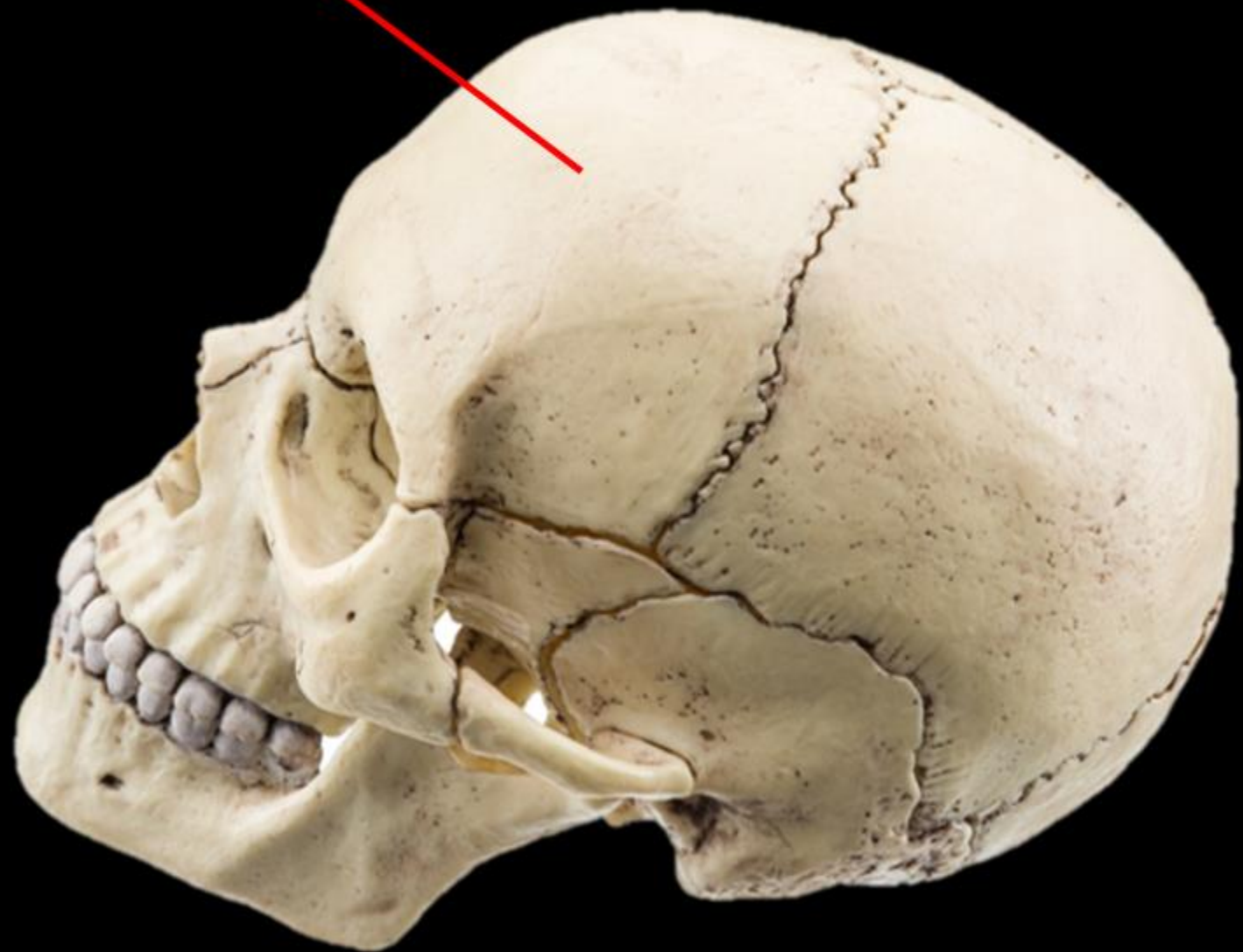
Name the Bone



Name the Bone
= LACRIMAL BONE

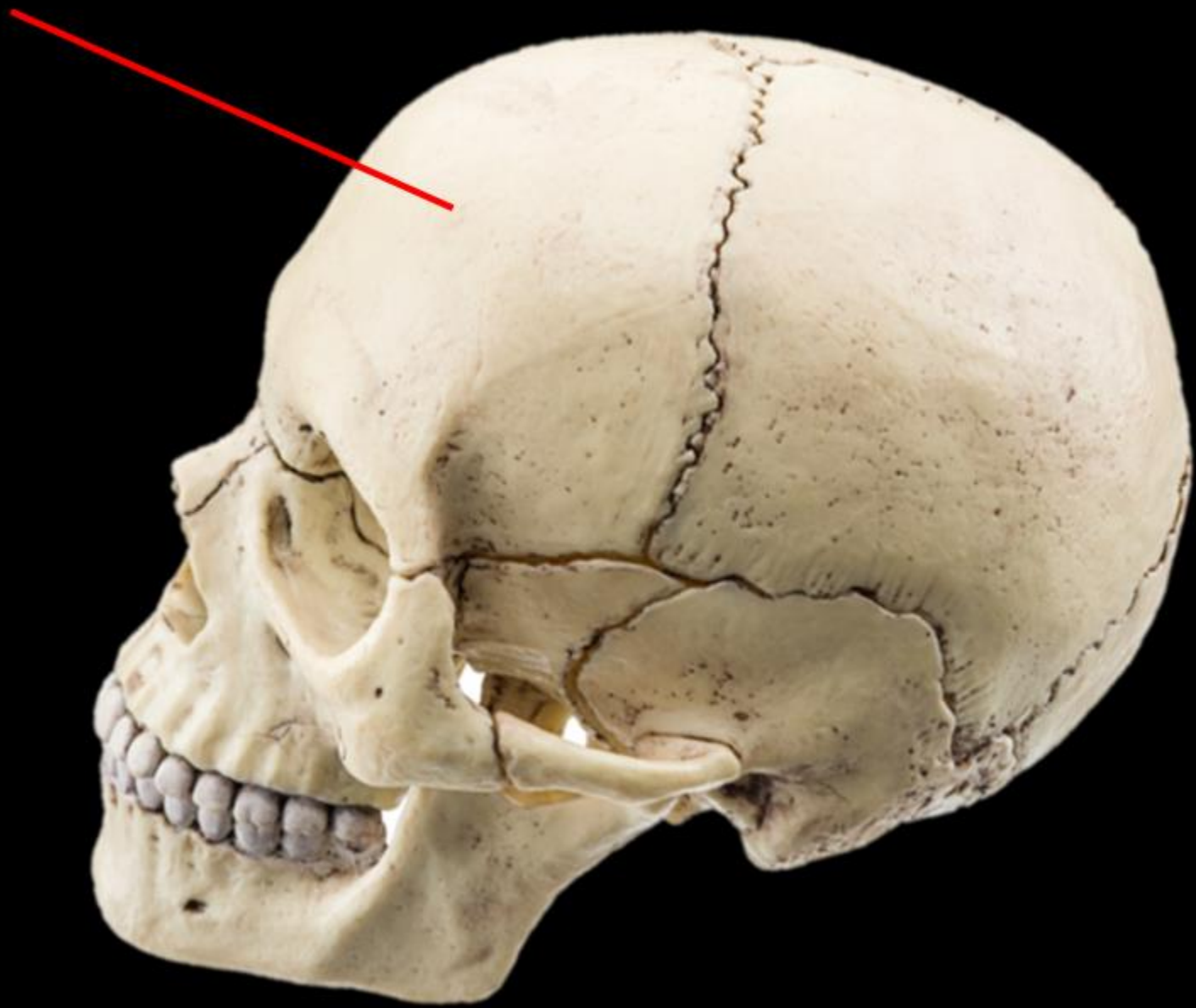


Name the Bone

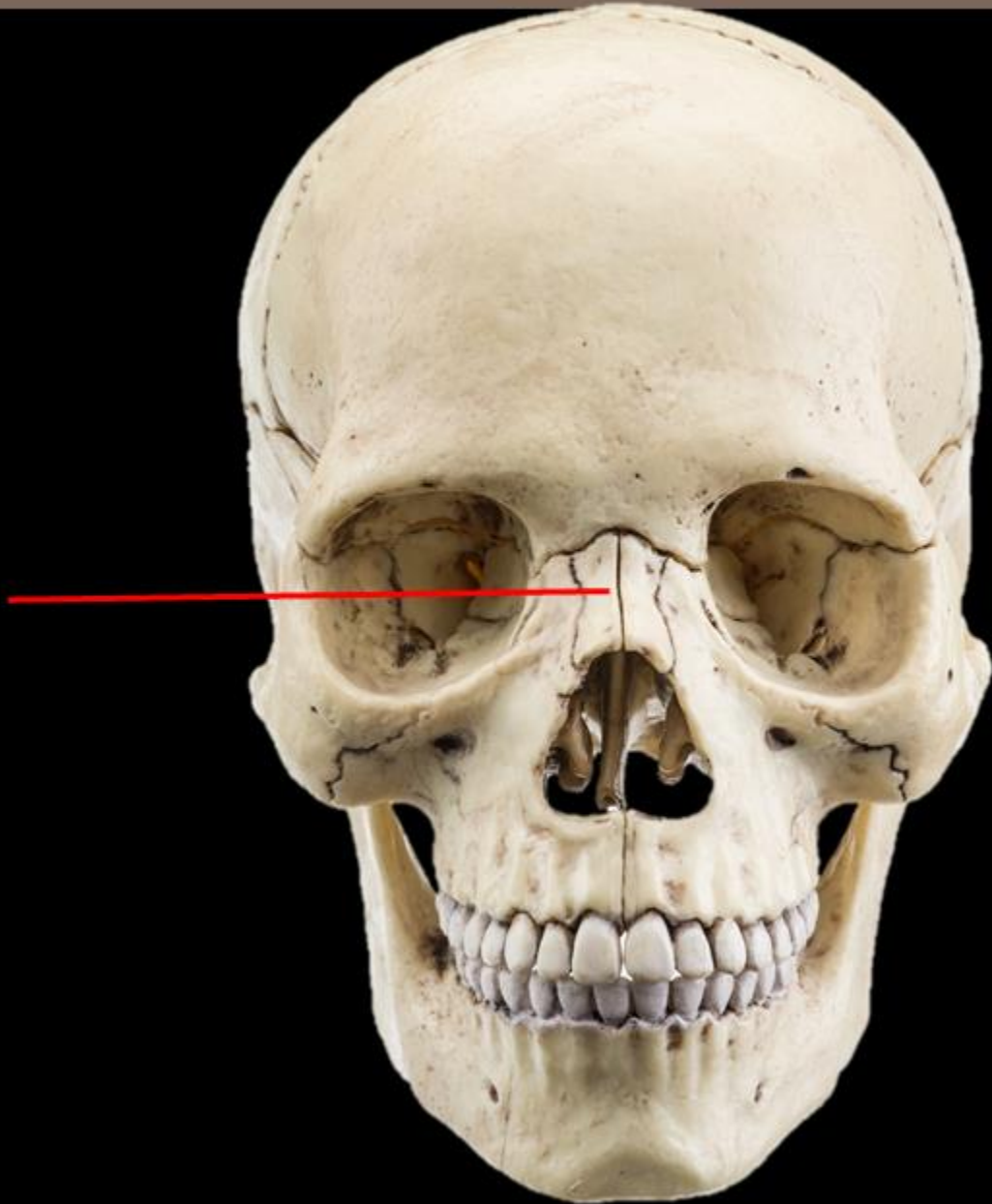


Name the Bone =

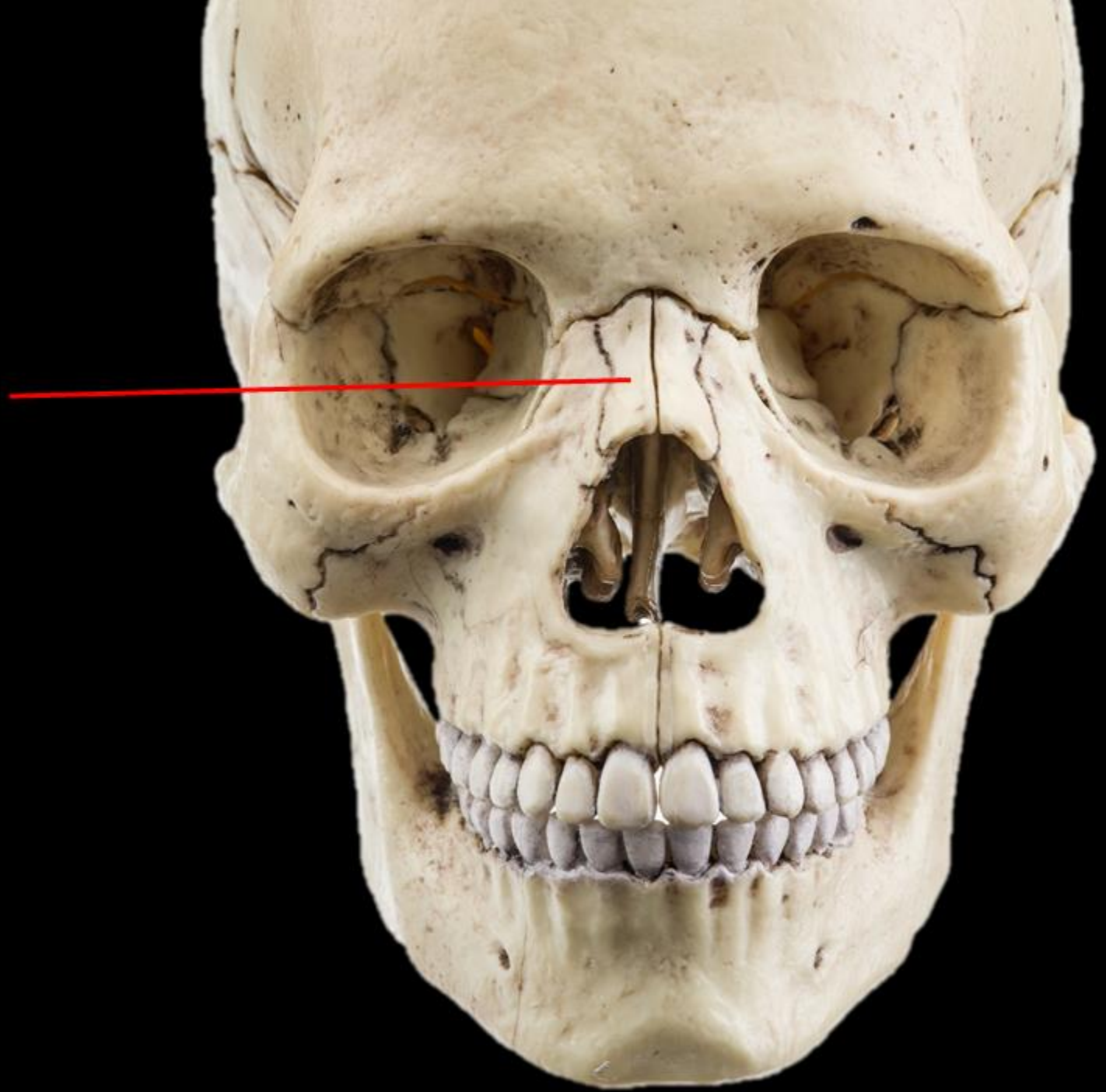
FRONTAL BONE



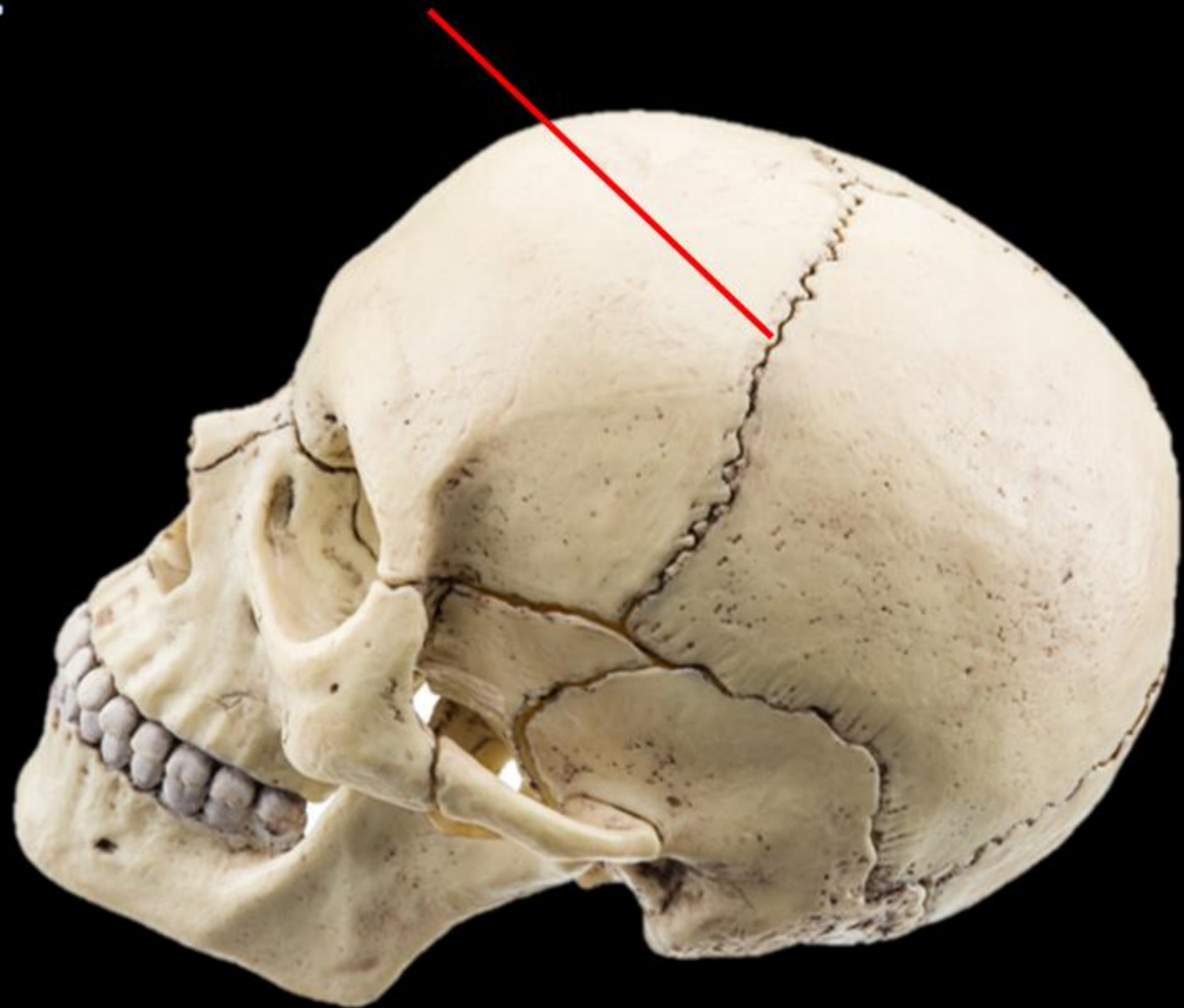
Name the Bone



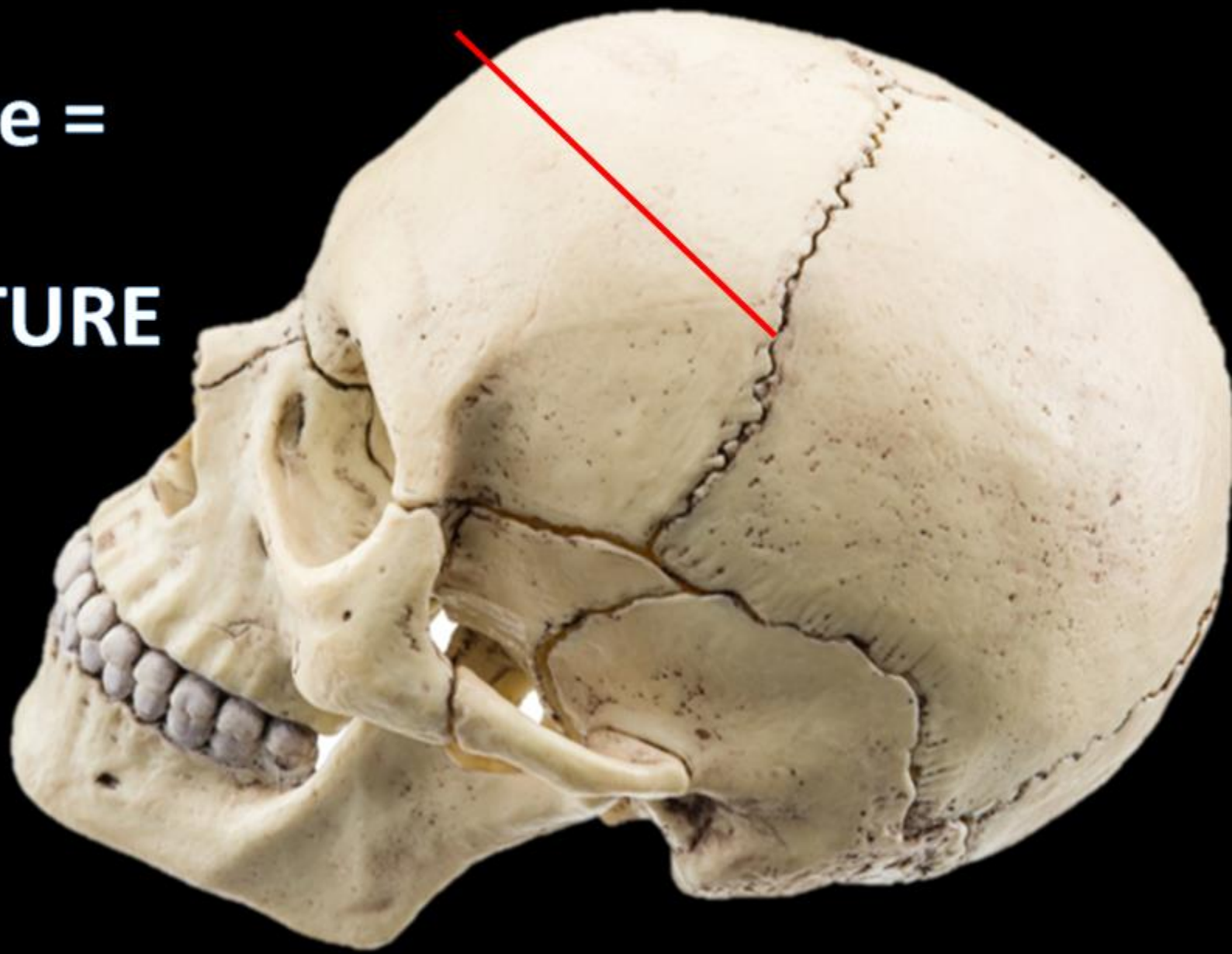
Name the Bone
= NASAL BONES



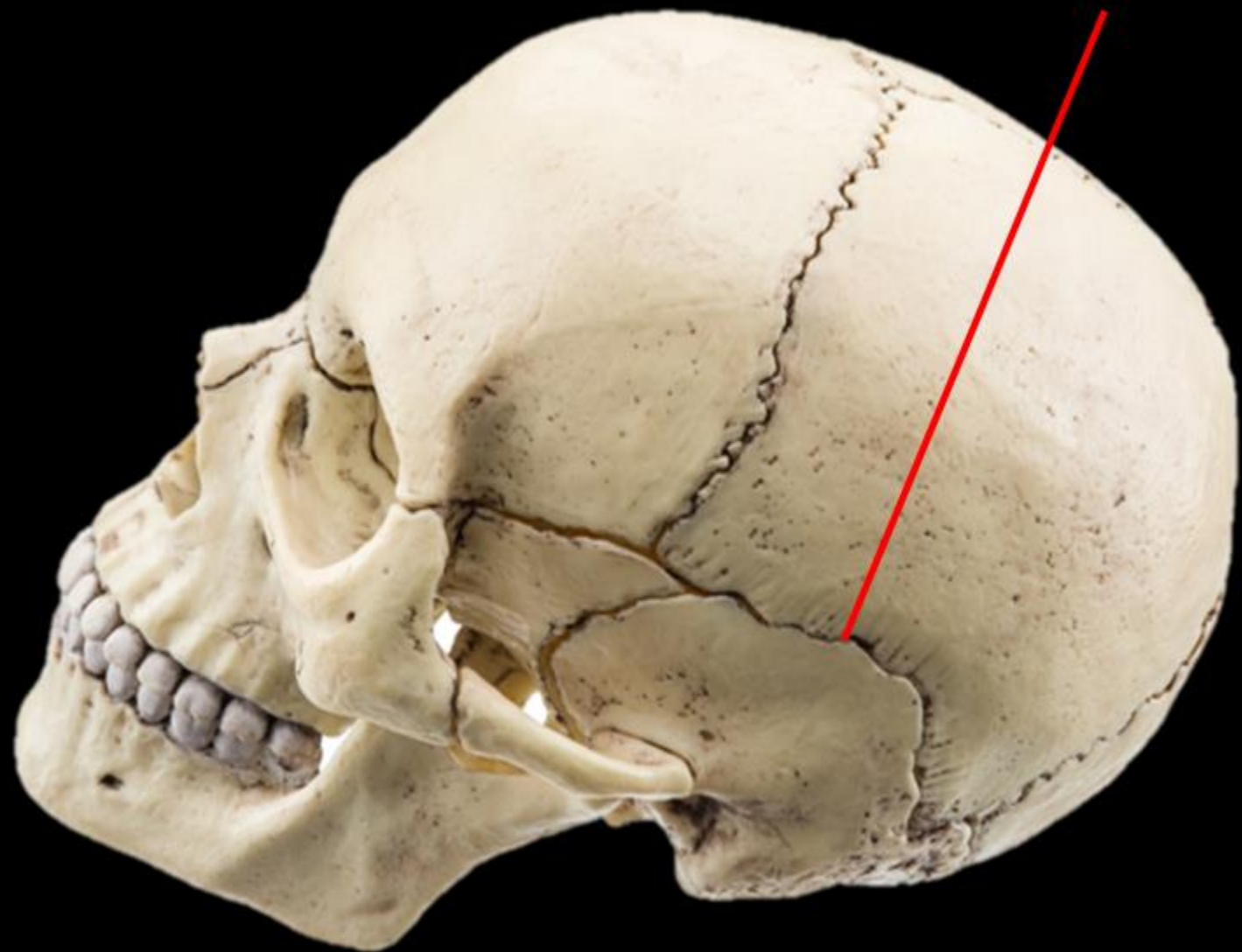
Name the Structure



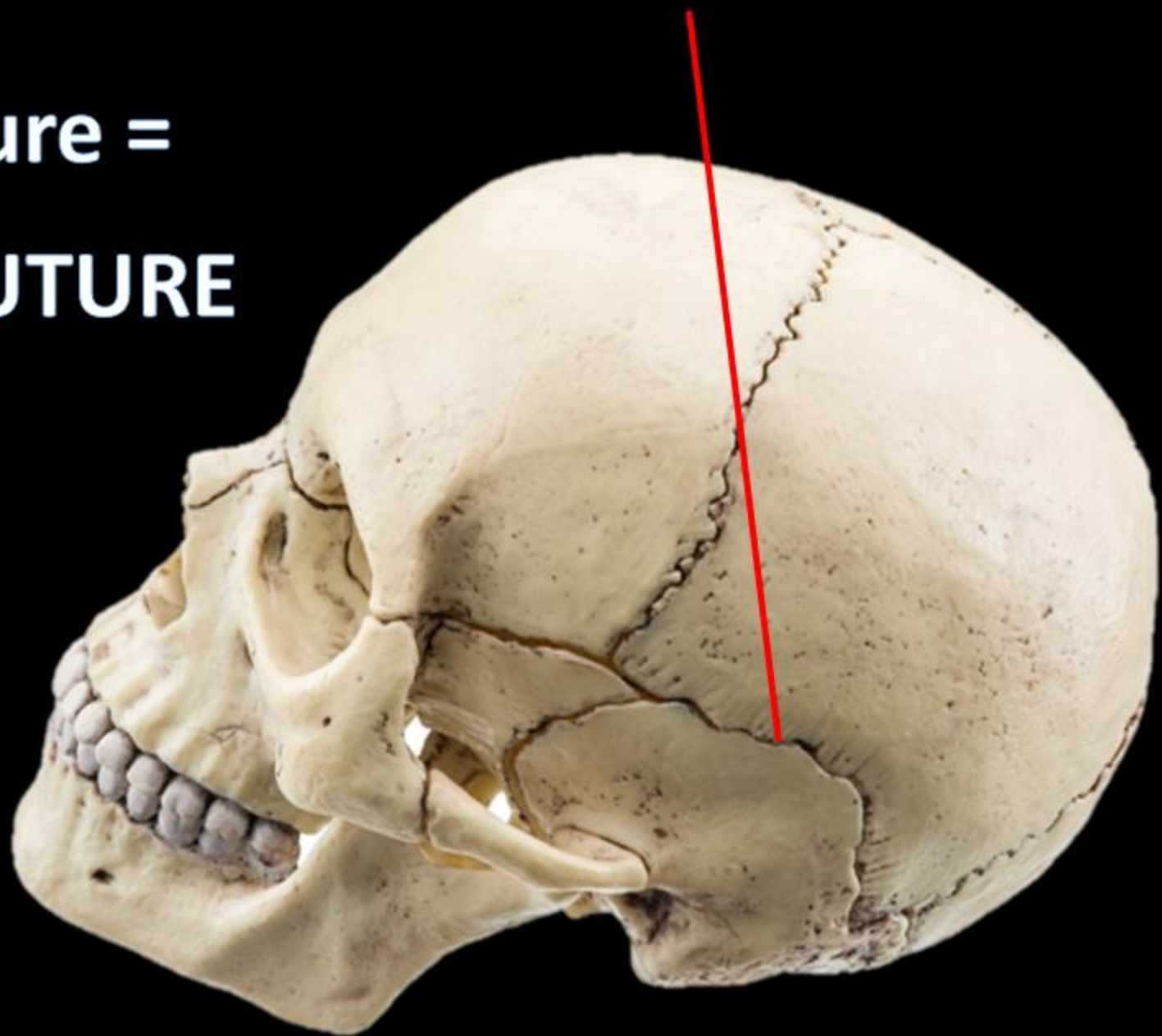
**Name the Structure =
THE CORONAL SUTURE**



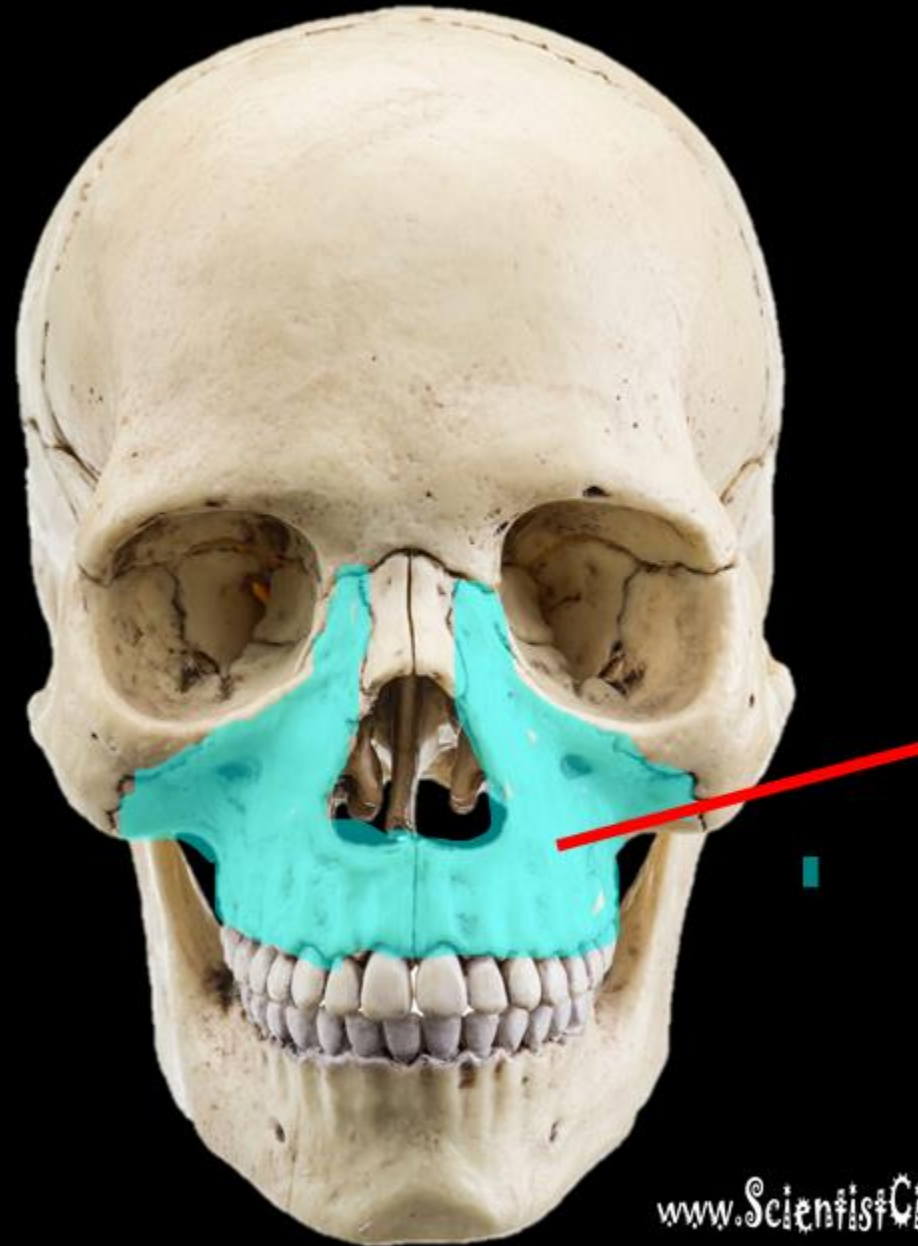
Name the Structure



**Name the Structure =
THE SQUAMOSAL SUTURE**

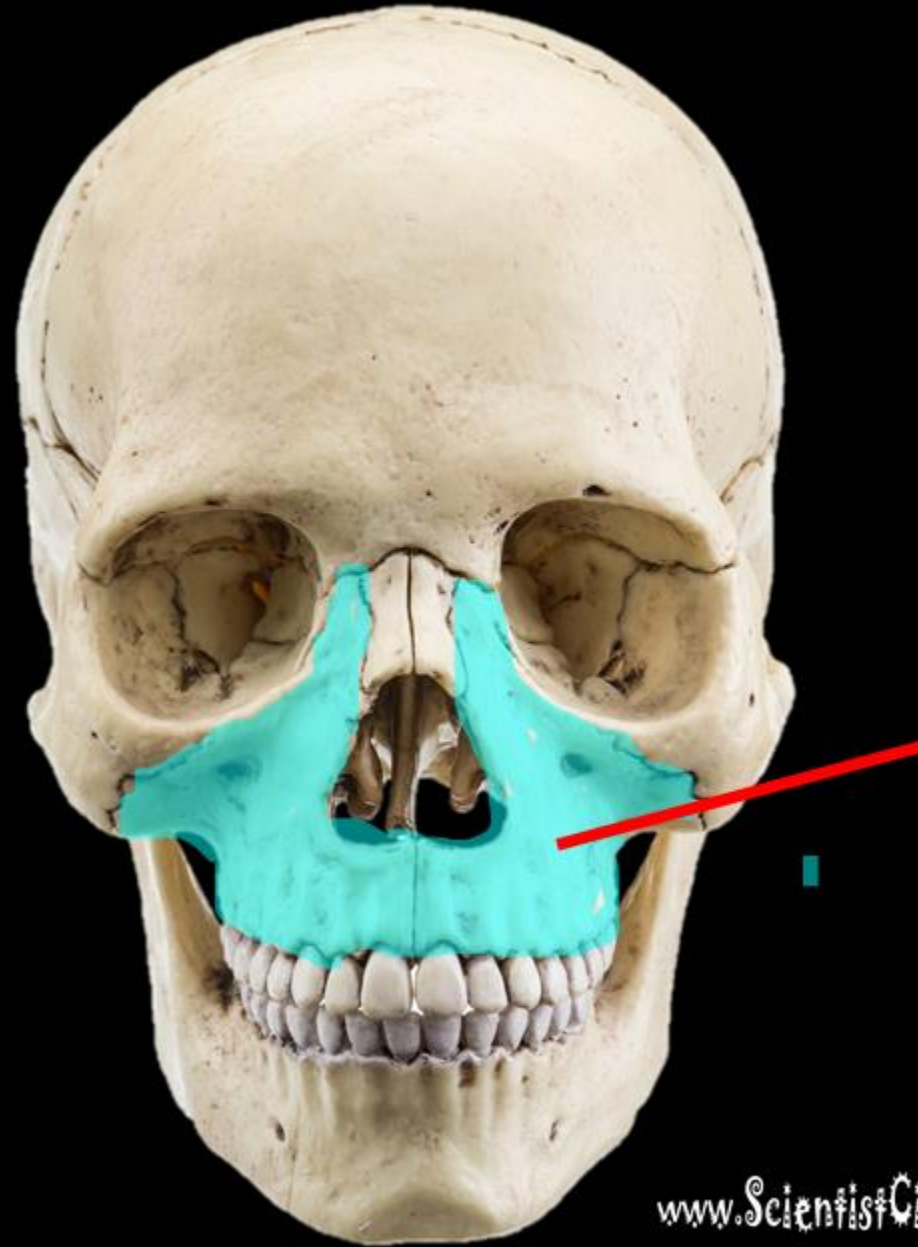


Name the
Bone.



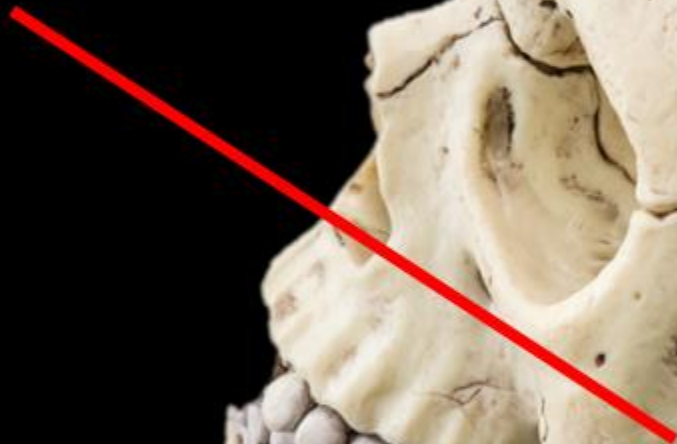
Name the bone =

MAXILLA



Name the Bone

Name the Structure

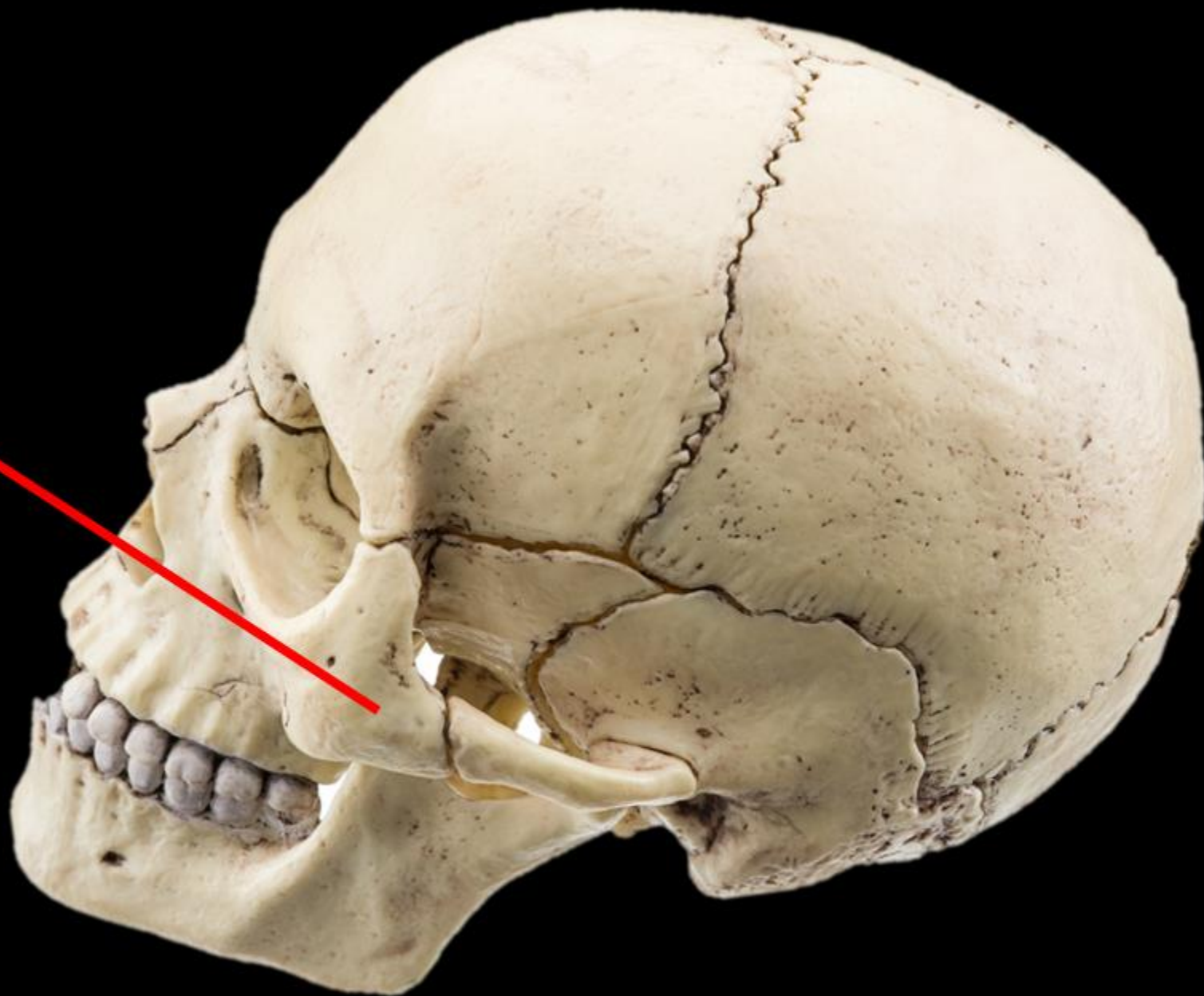


Name the Bone =

ZYGOMA

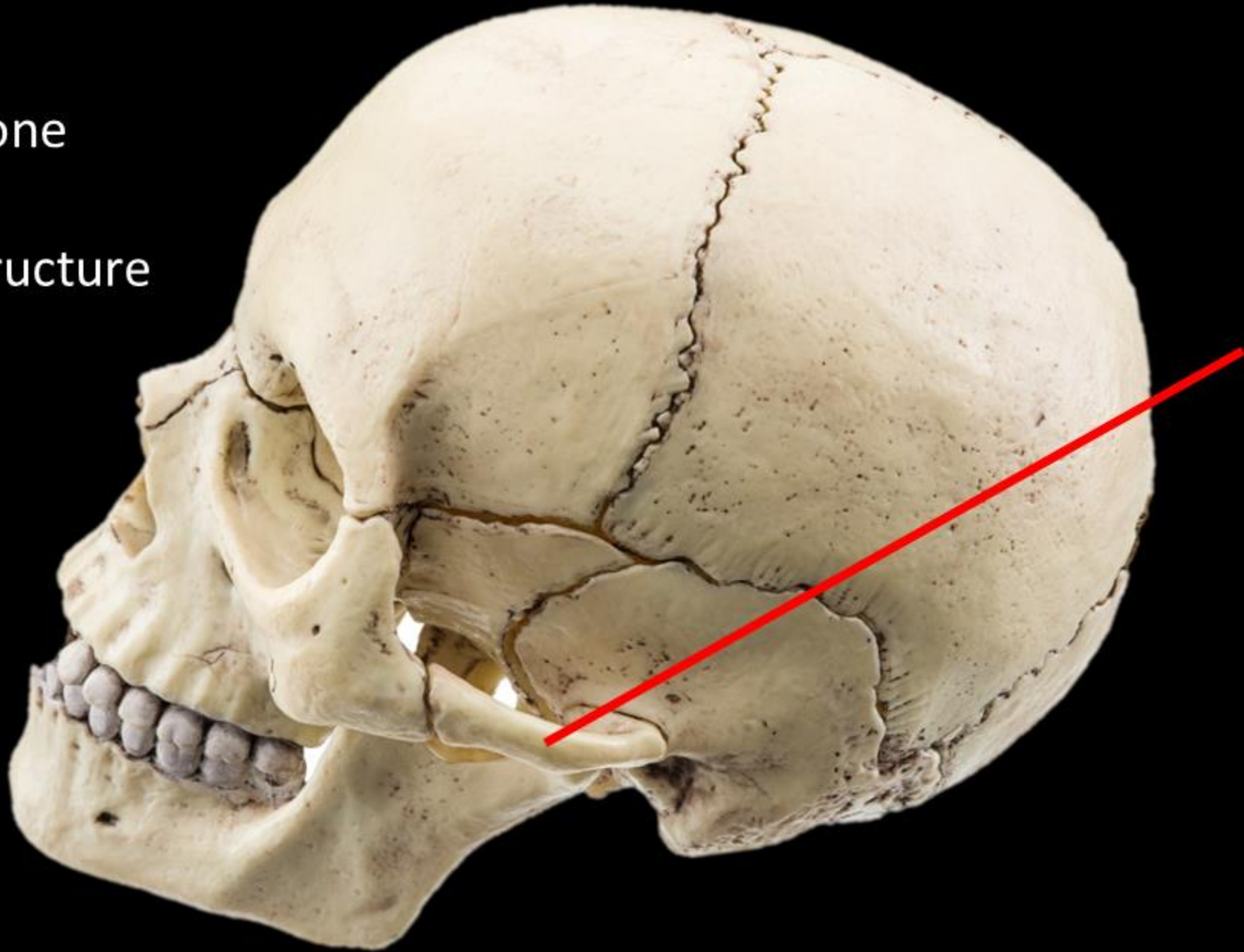
Name the Structure =

Temporal Process of
the Zygomatic Bone



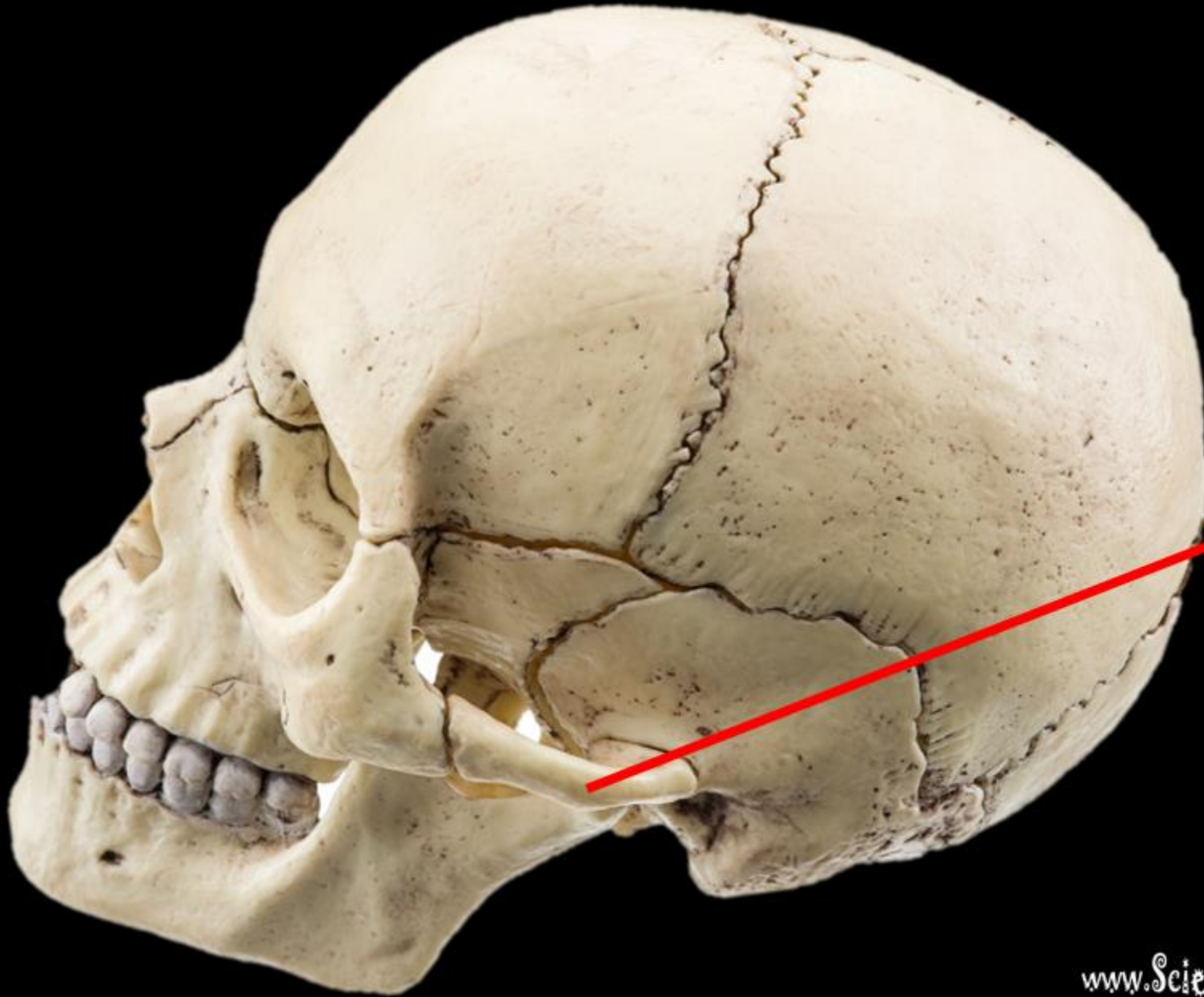
Name the Bone

Name the Structure

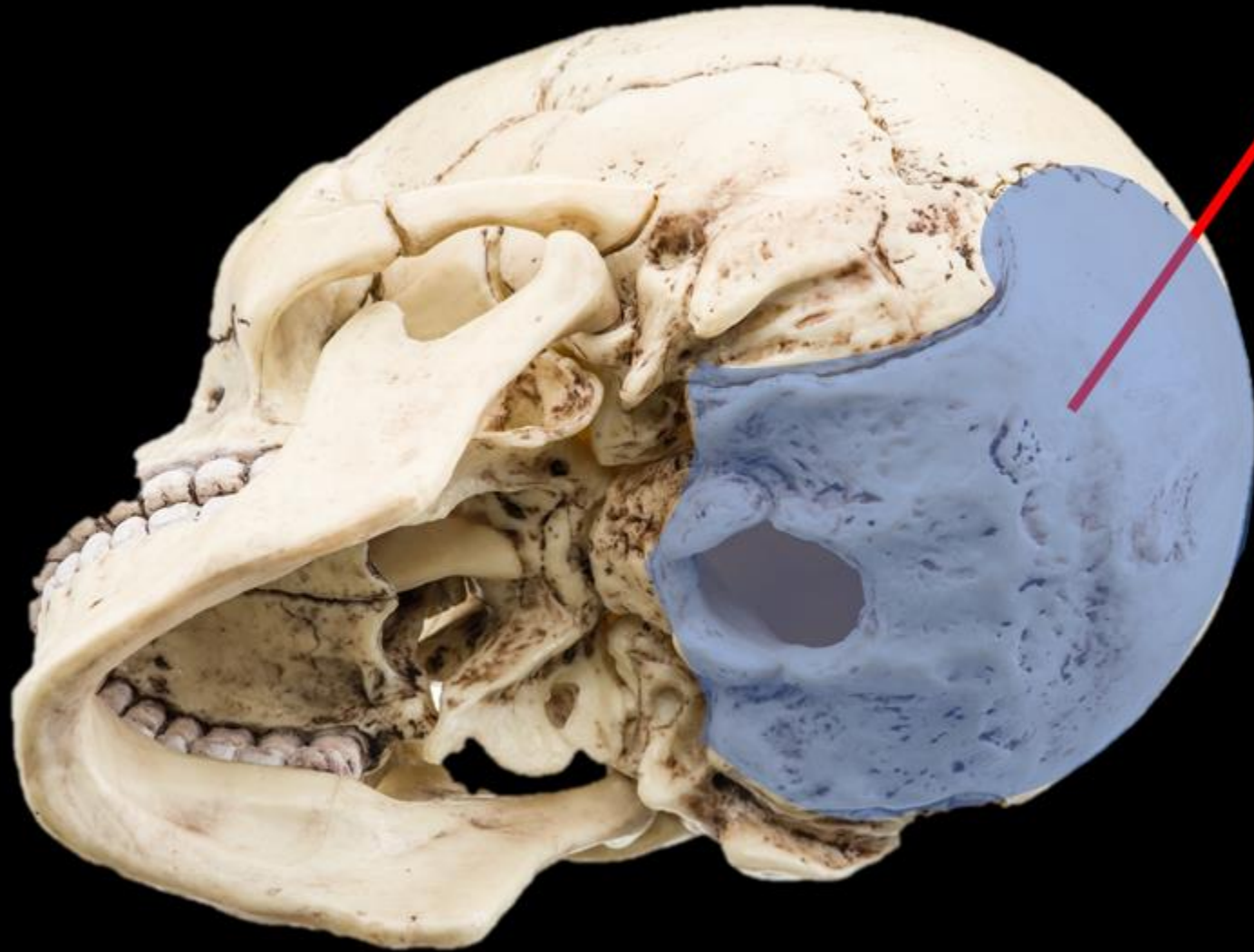

Name the Bone =
TEMPORAL BONE

Name the Structure =
Zygomatic Process
of the
Temporal Bone

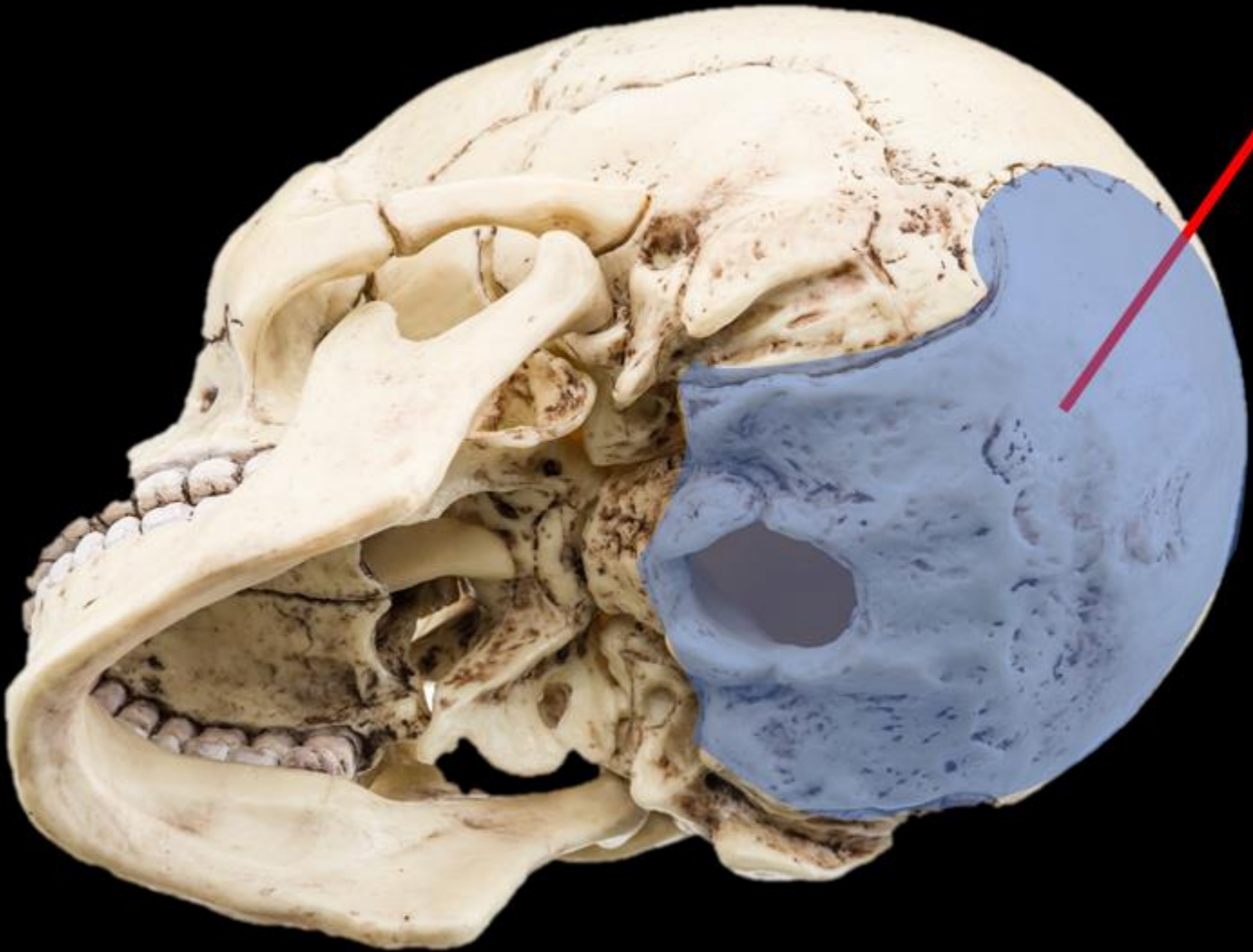


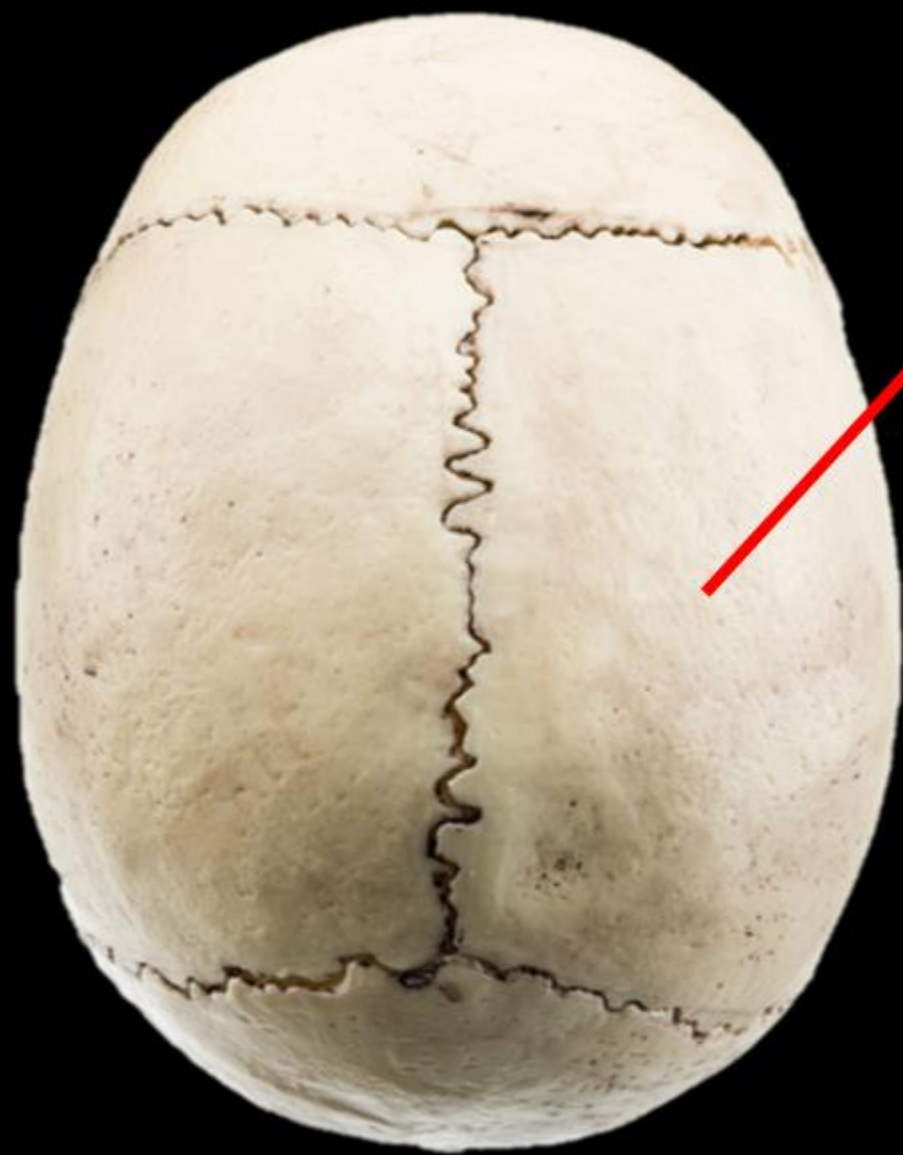NAME THE BONE



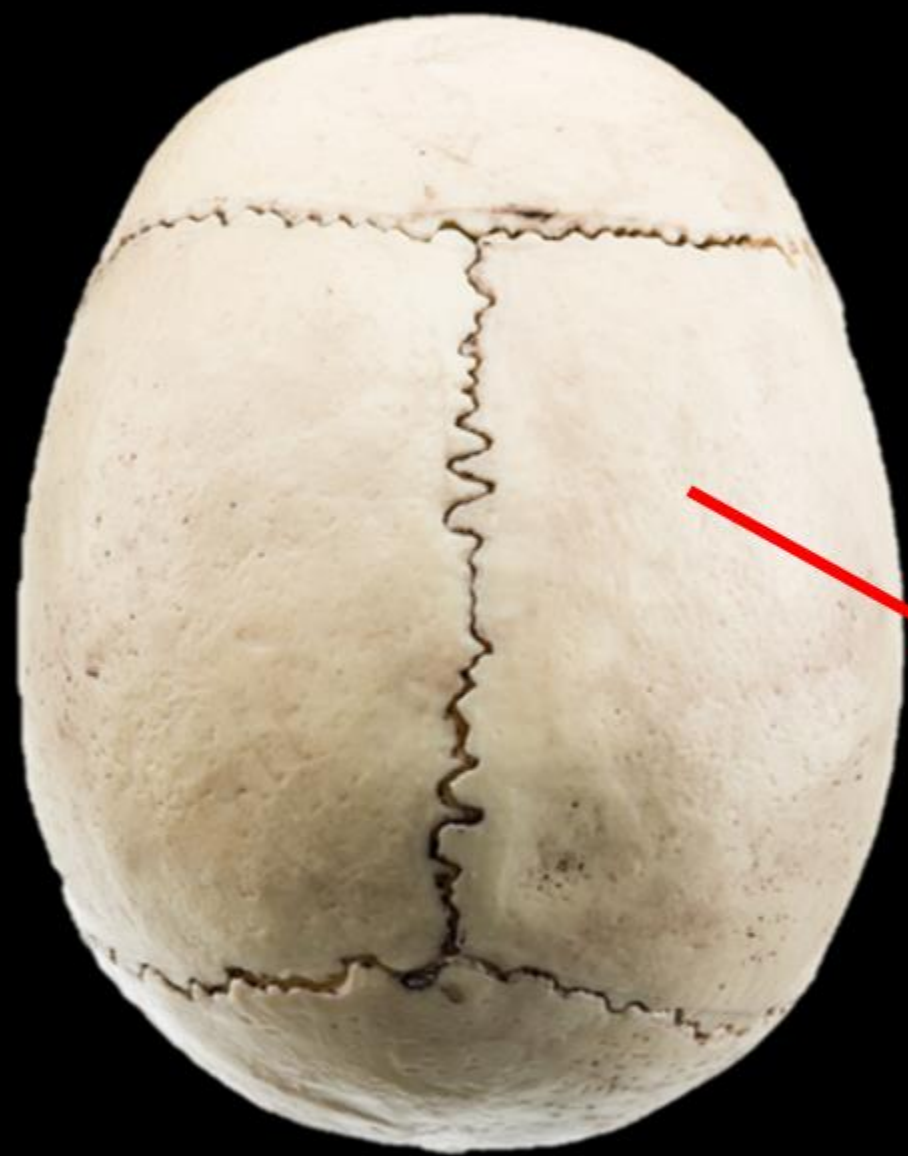NAME THE BONE =

OCCIPITAL BONE =

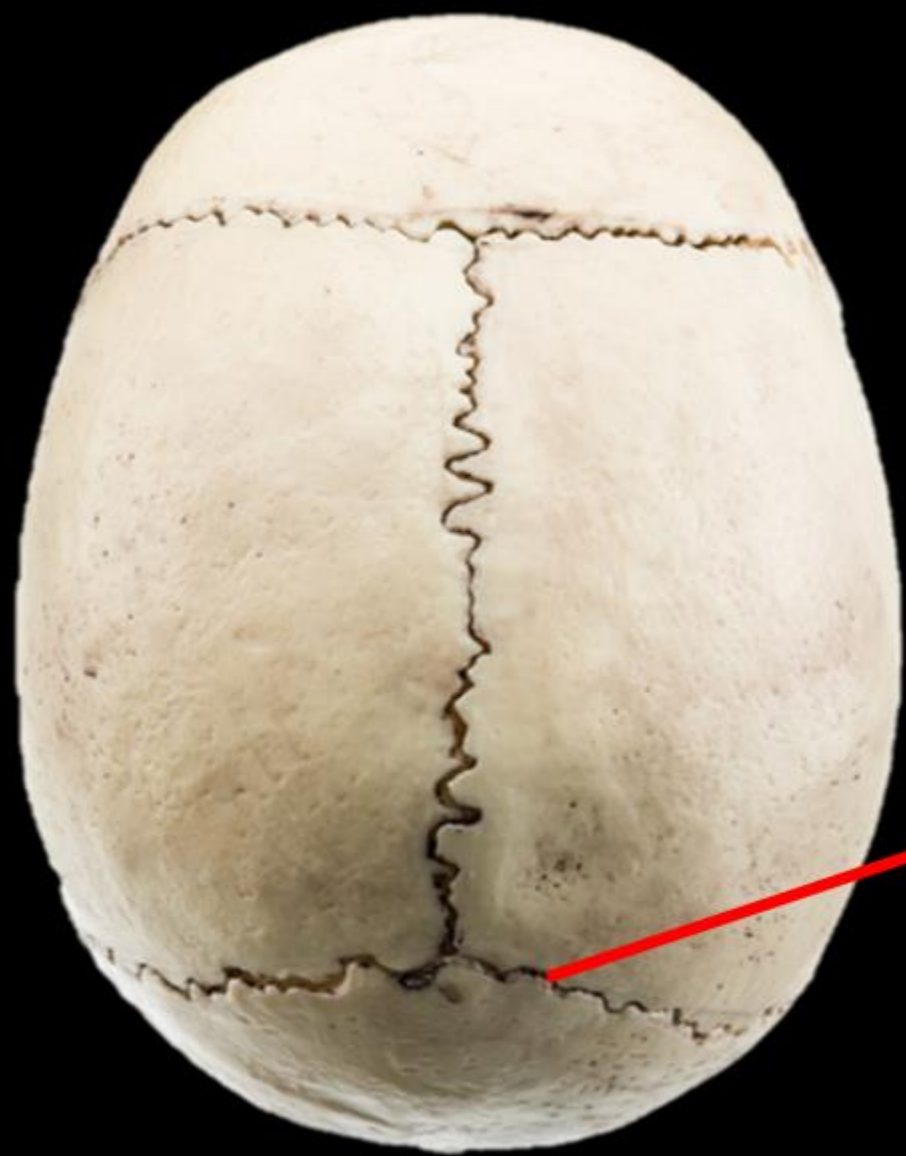



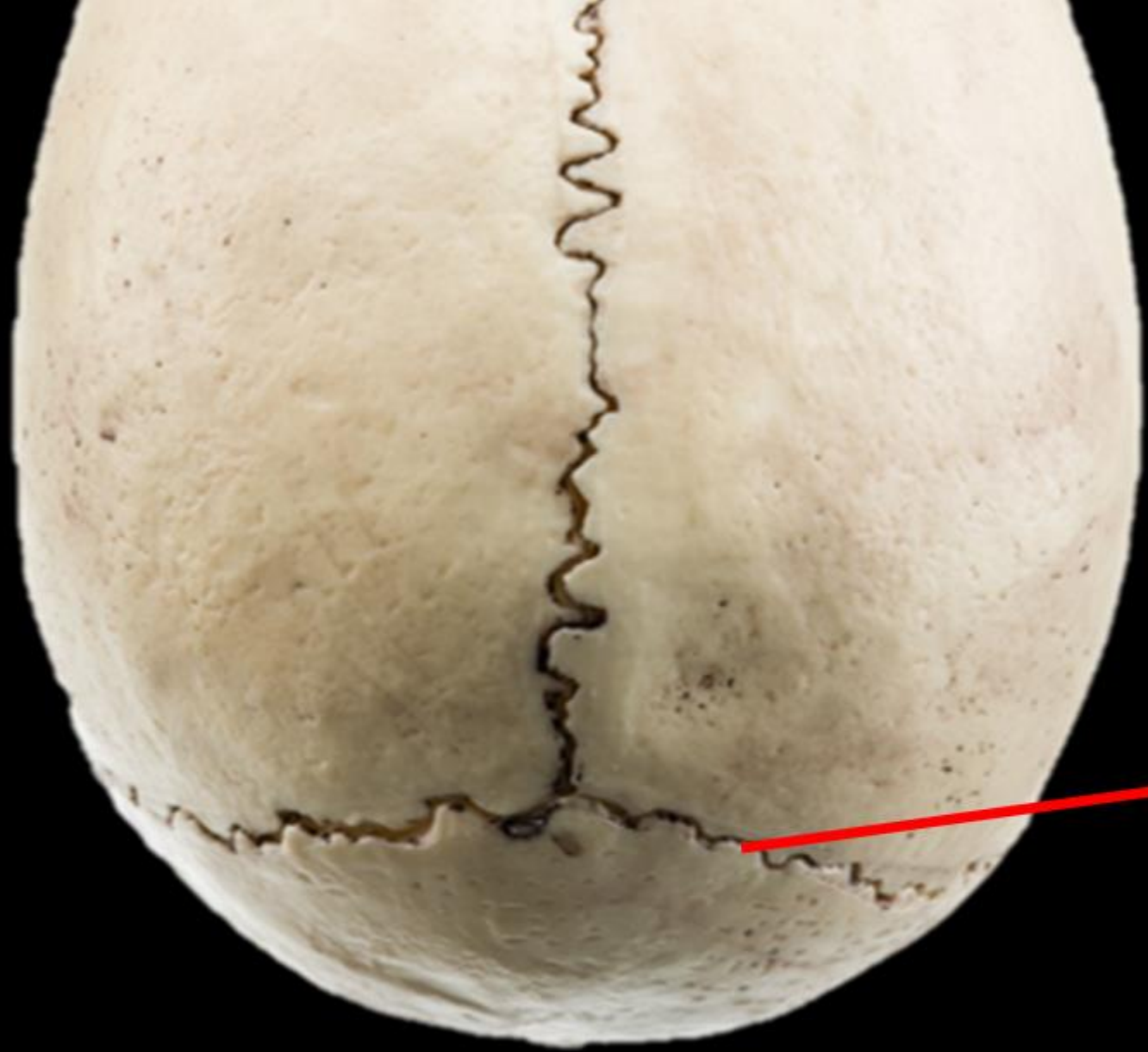NAME THE BONE.



NAME THE BONE.
PARIETAL BONE



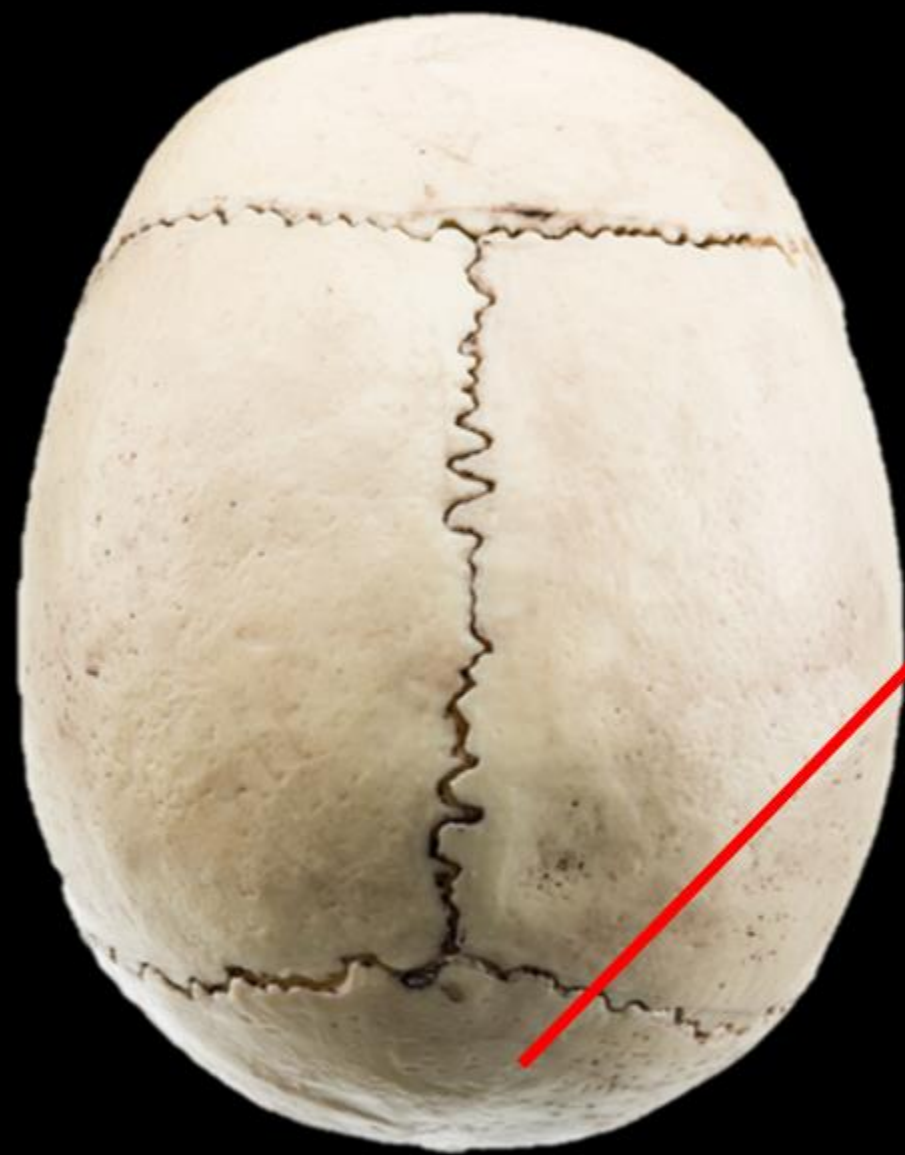NAME THE
STRUCTURE.

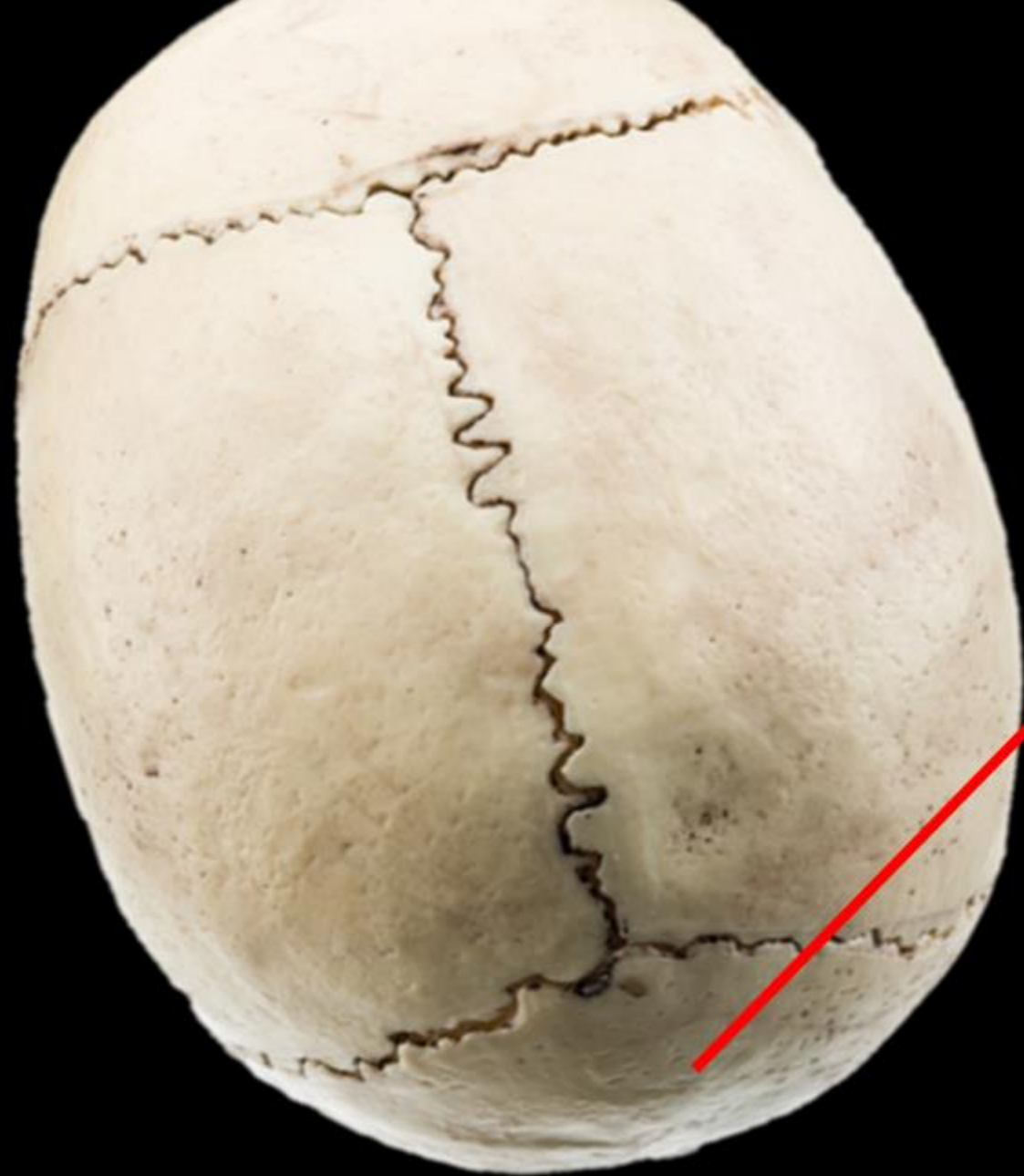

NAME THE
STRUCTURE.

LAMBDOIDAL
SUTURE

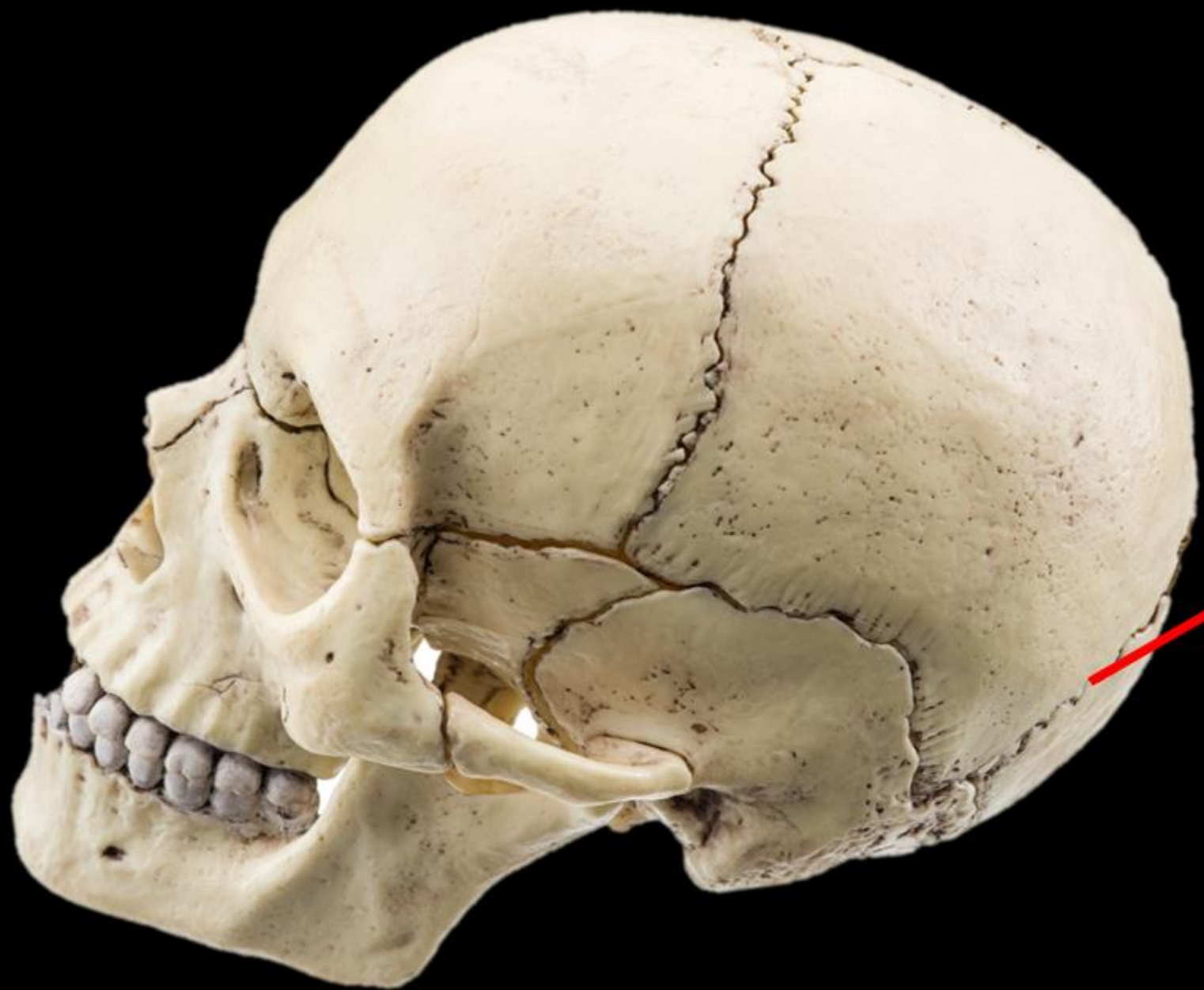NAME THE BONE



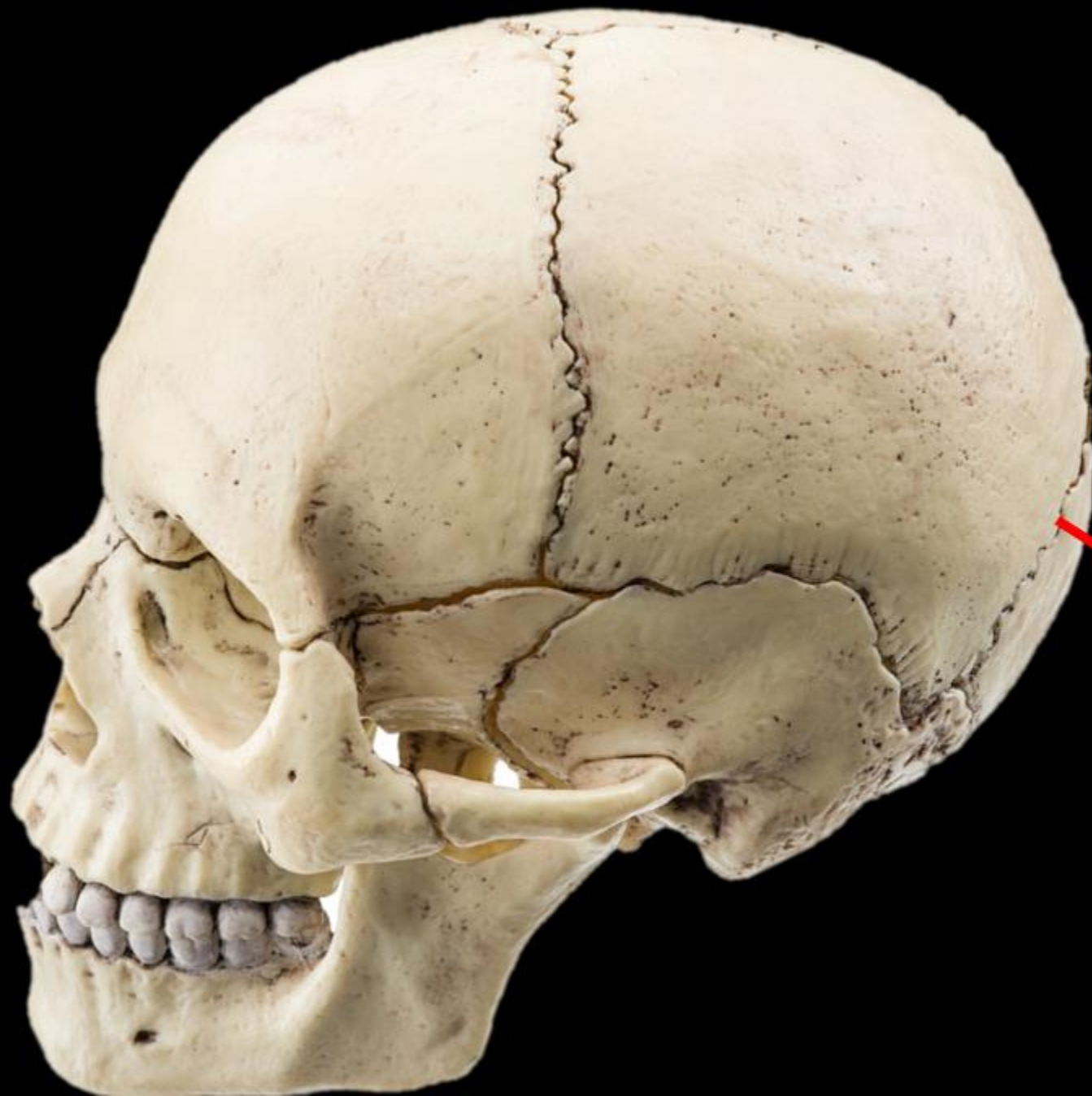

NAME THE BONE

OCCIPITAL BONE



Name the Bone
Name the Structure



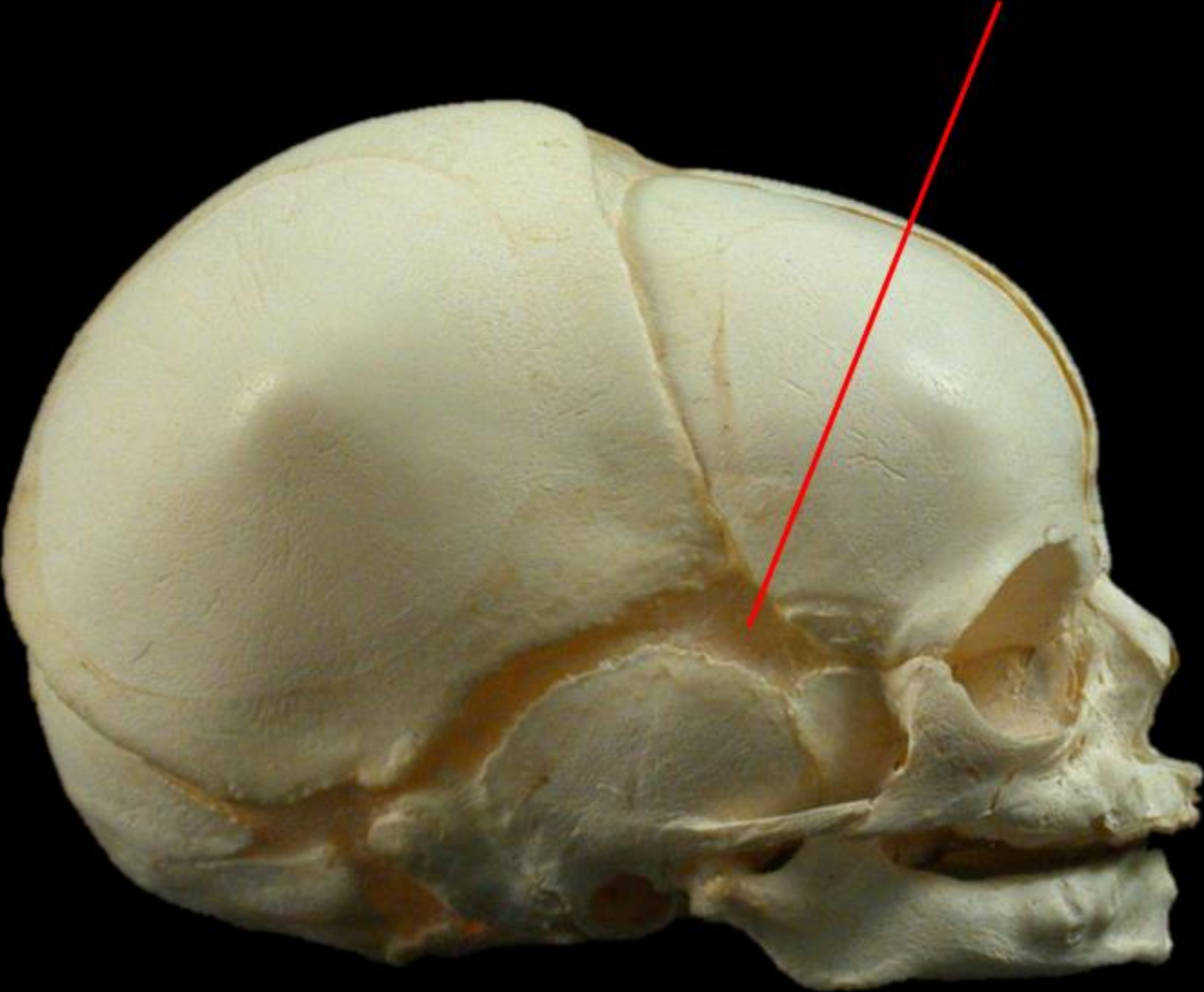
Name the Bone =

OCCIPITAL BONE

Name the Structure =

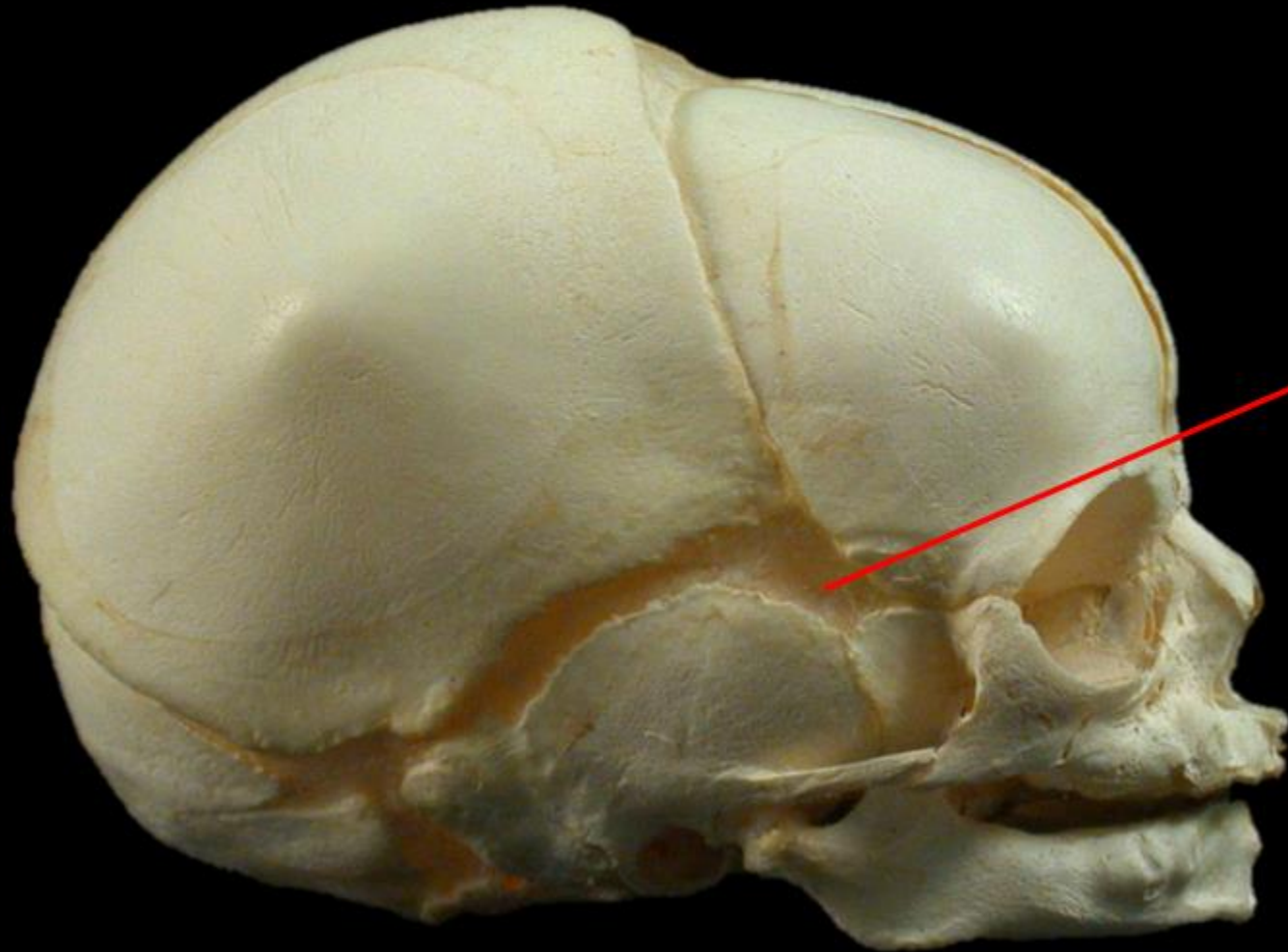
LAMDOIDAL SUTURE

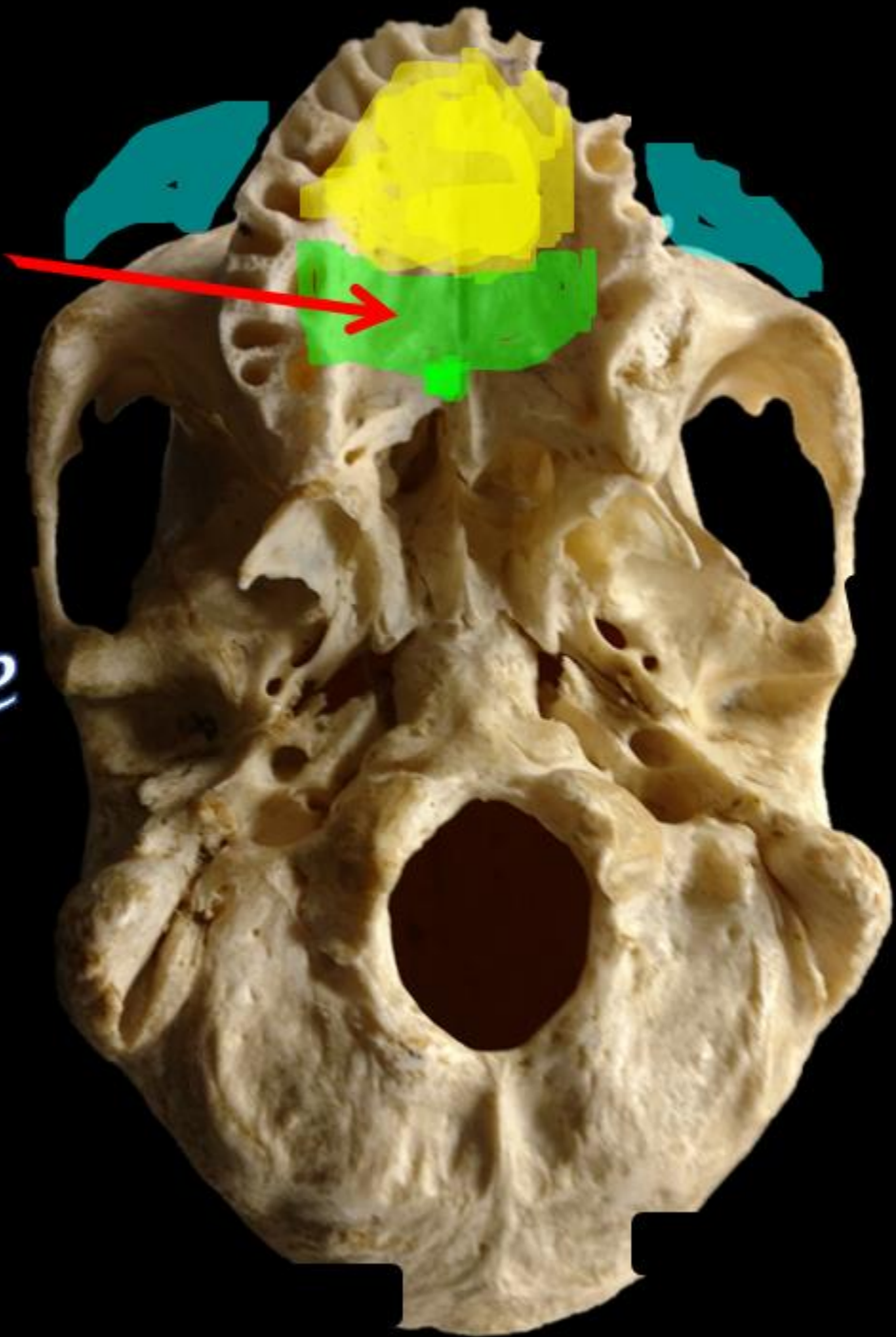
Name the Structure =



Sphenoidal Fontanel

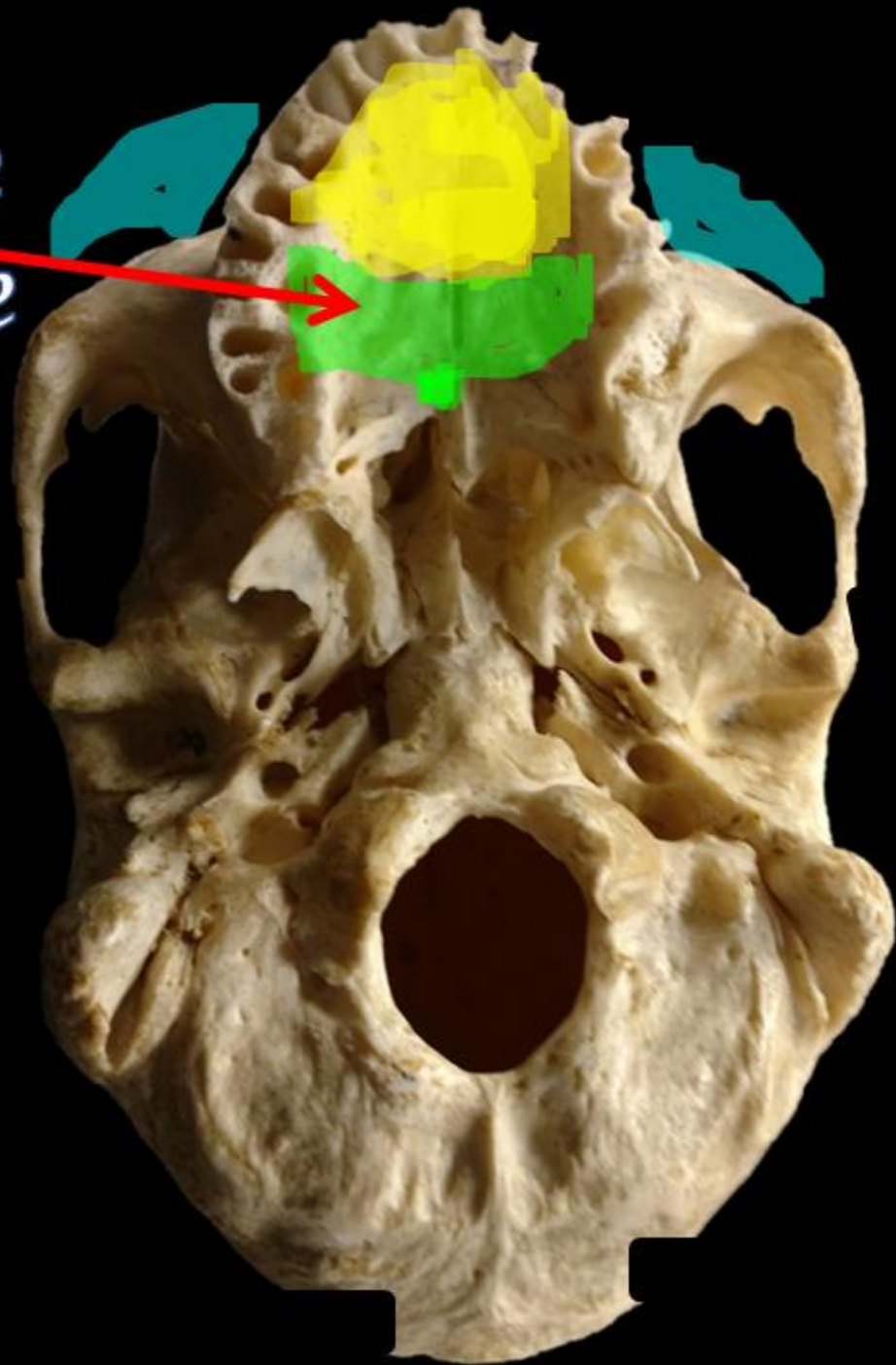
Name the Structure =



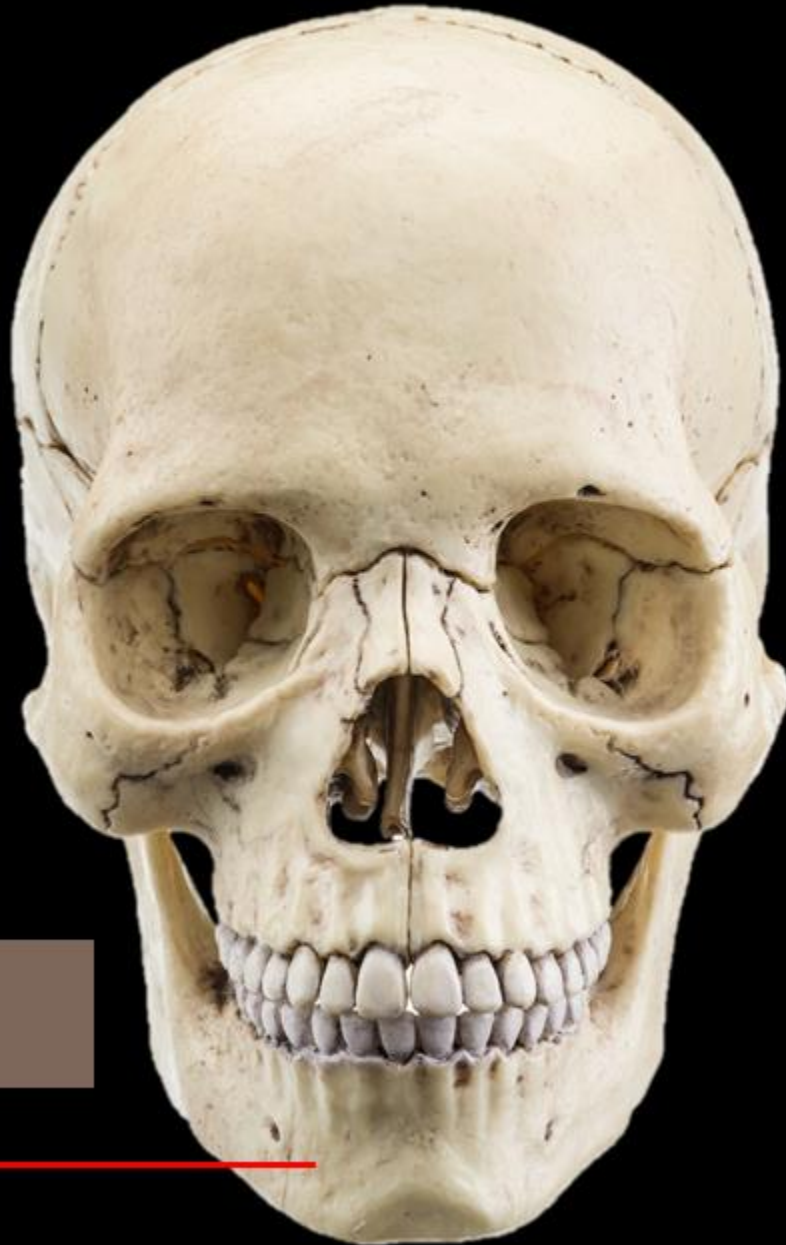

Name the Bone

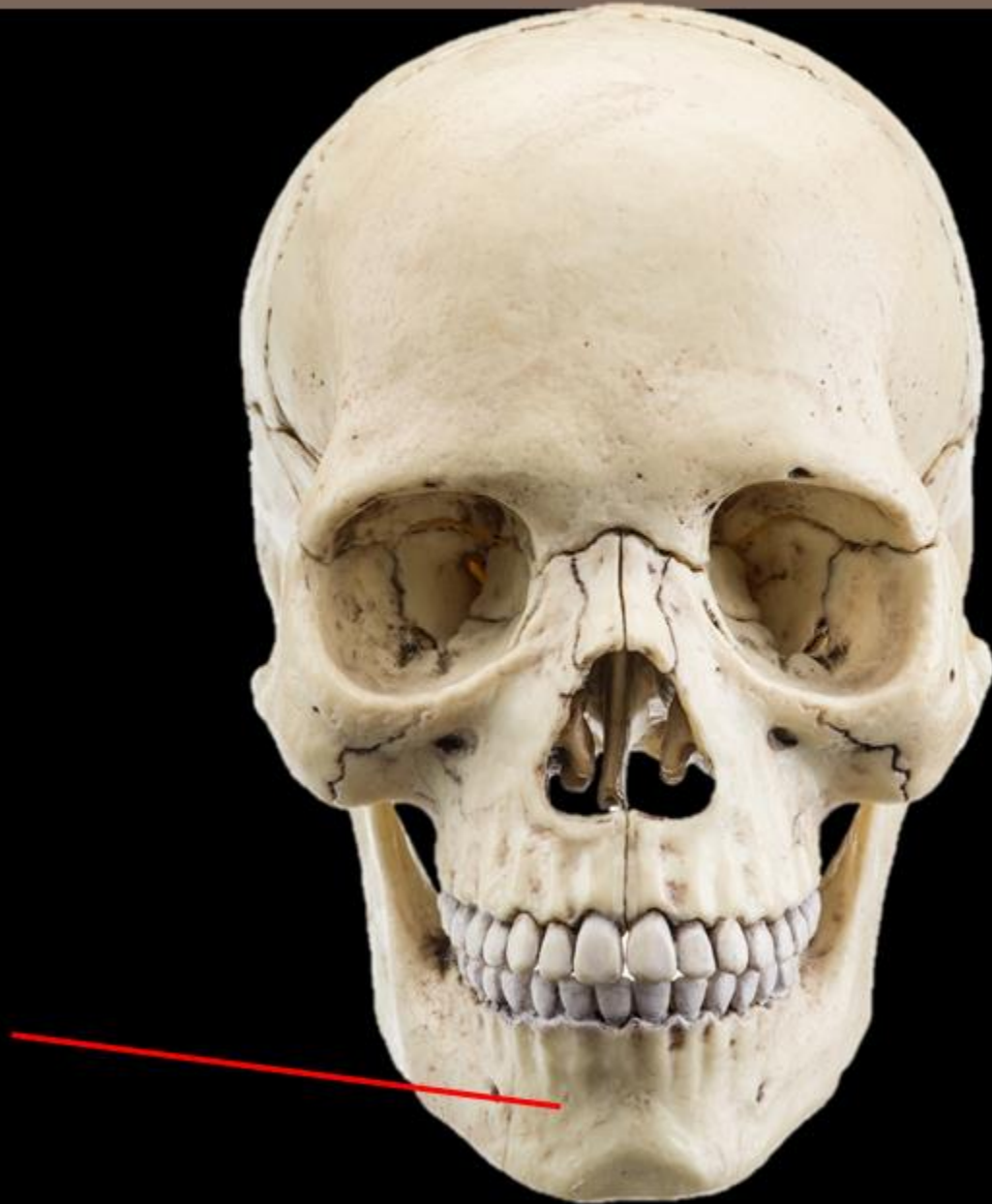*Name the Bone
= Palatine Bone*



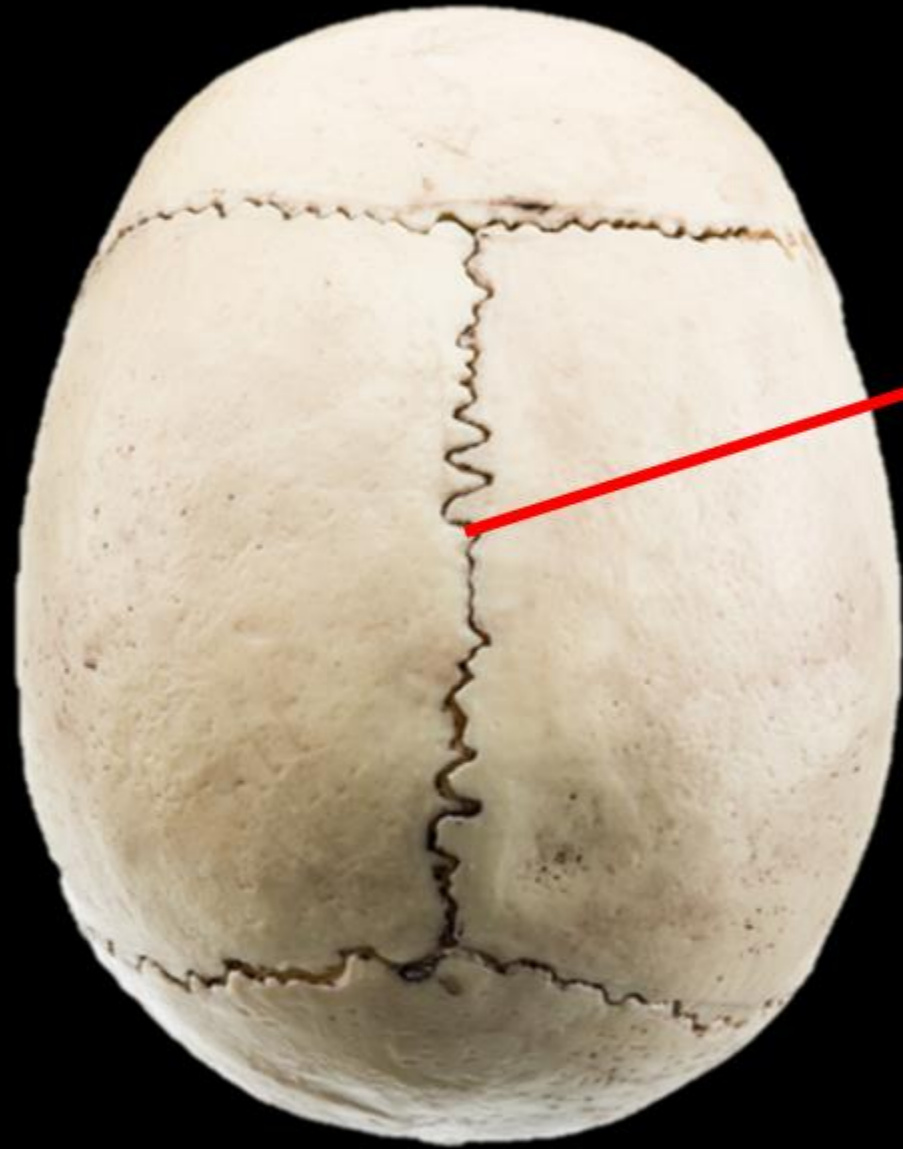Name the Bone

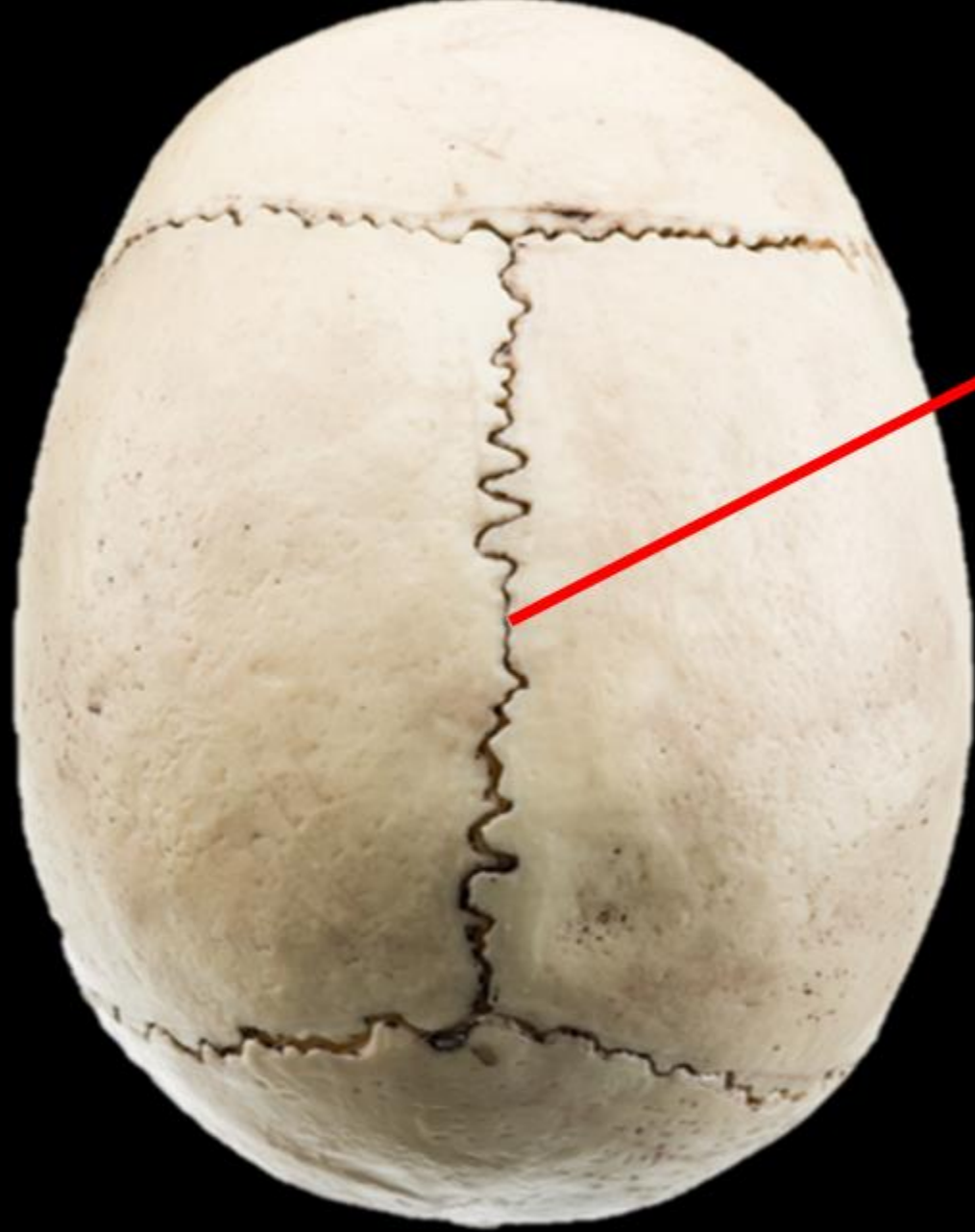

Name the Bone = MANDIBLE



NAME THE
STRUCTURE

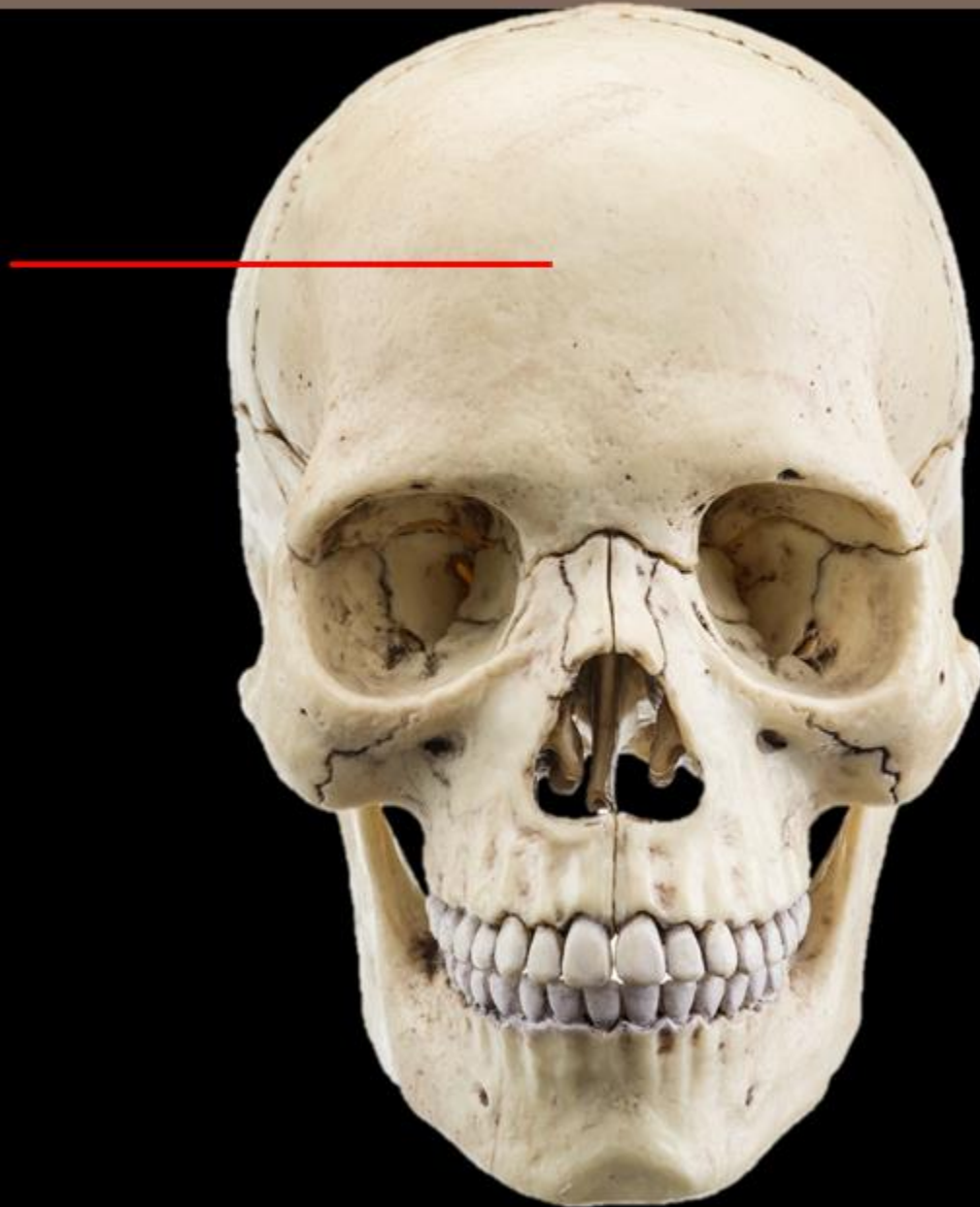


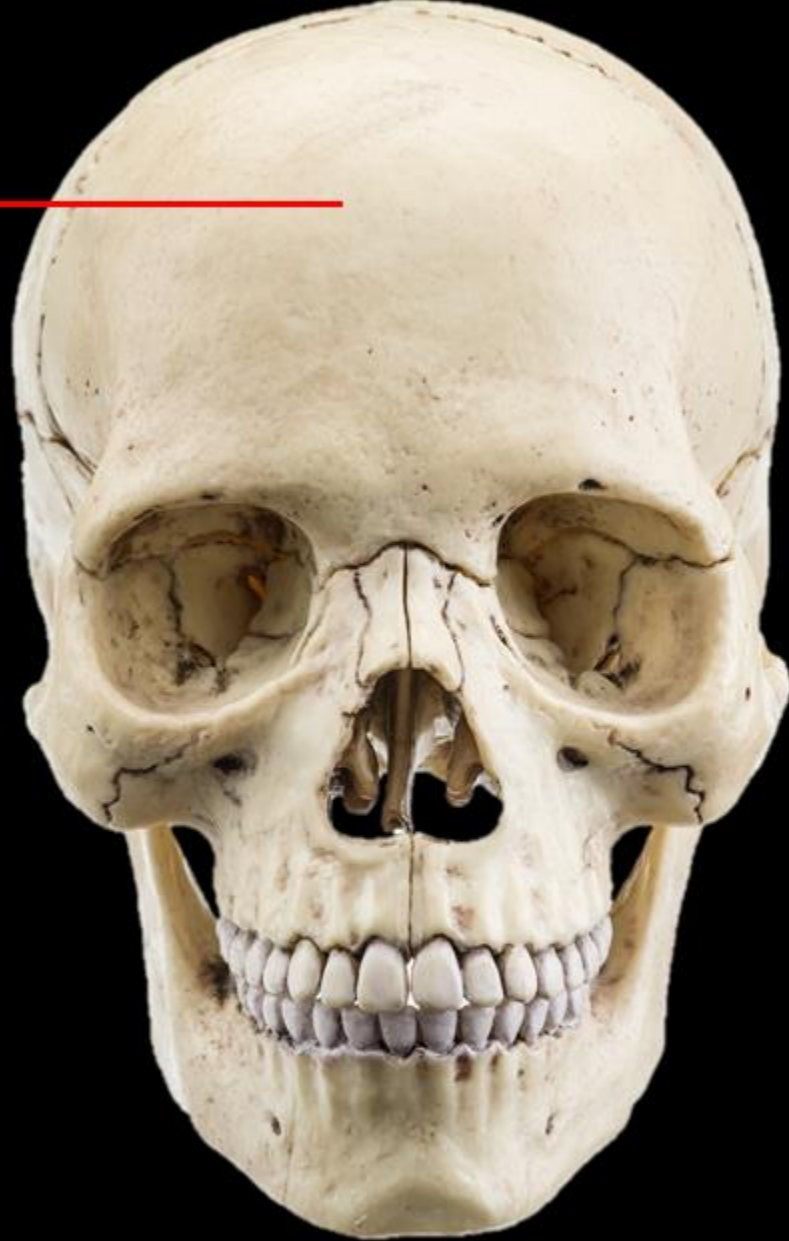
NAME THE
STRUCTURE

SAGITTAL SUTURE

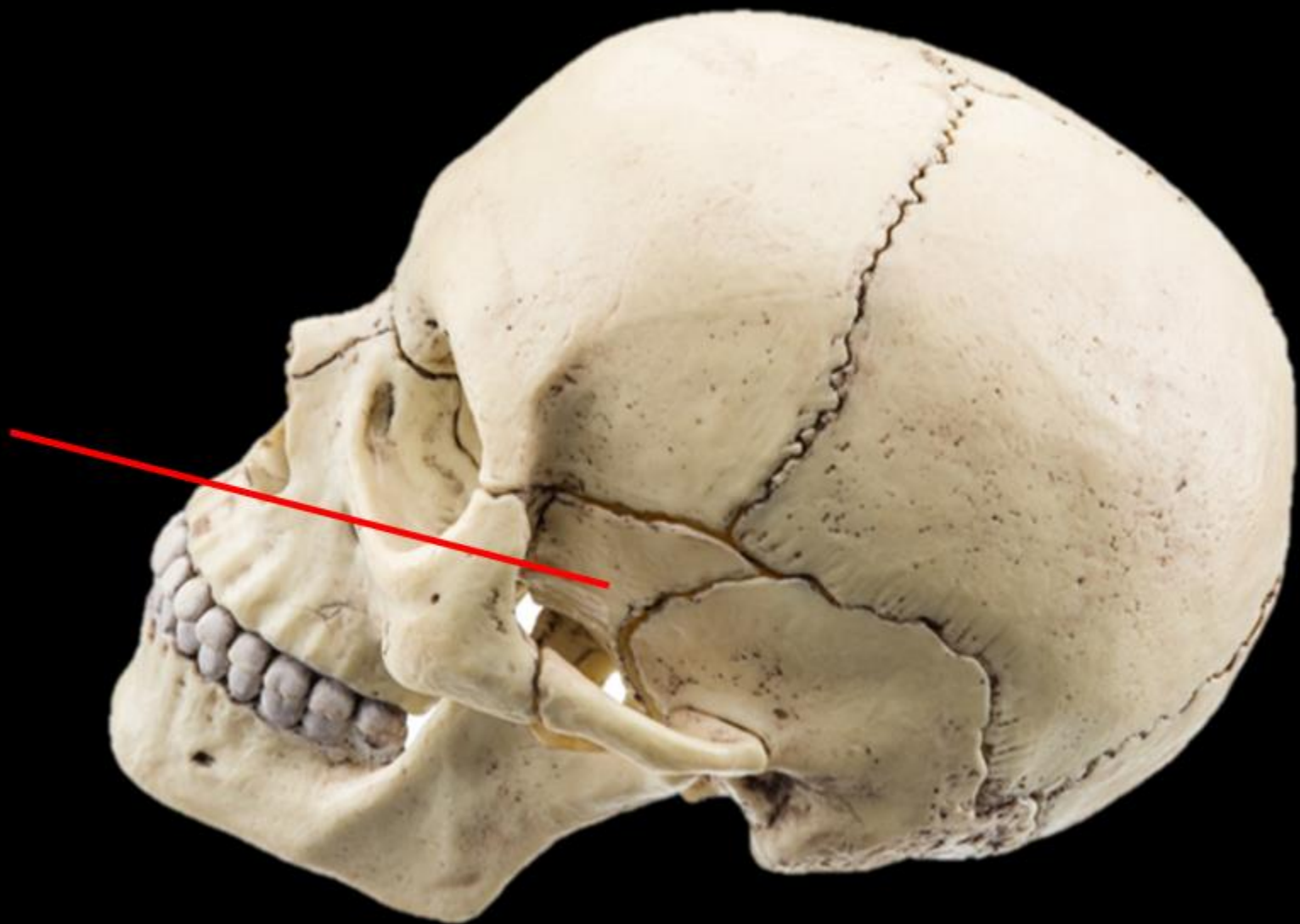
Name the Bone



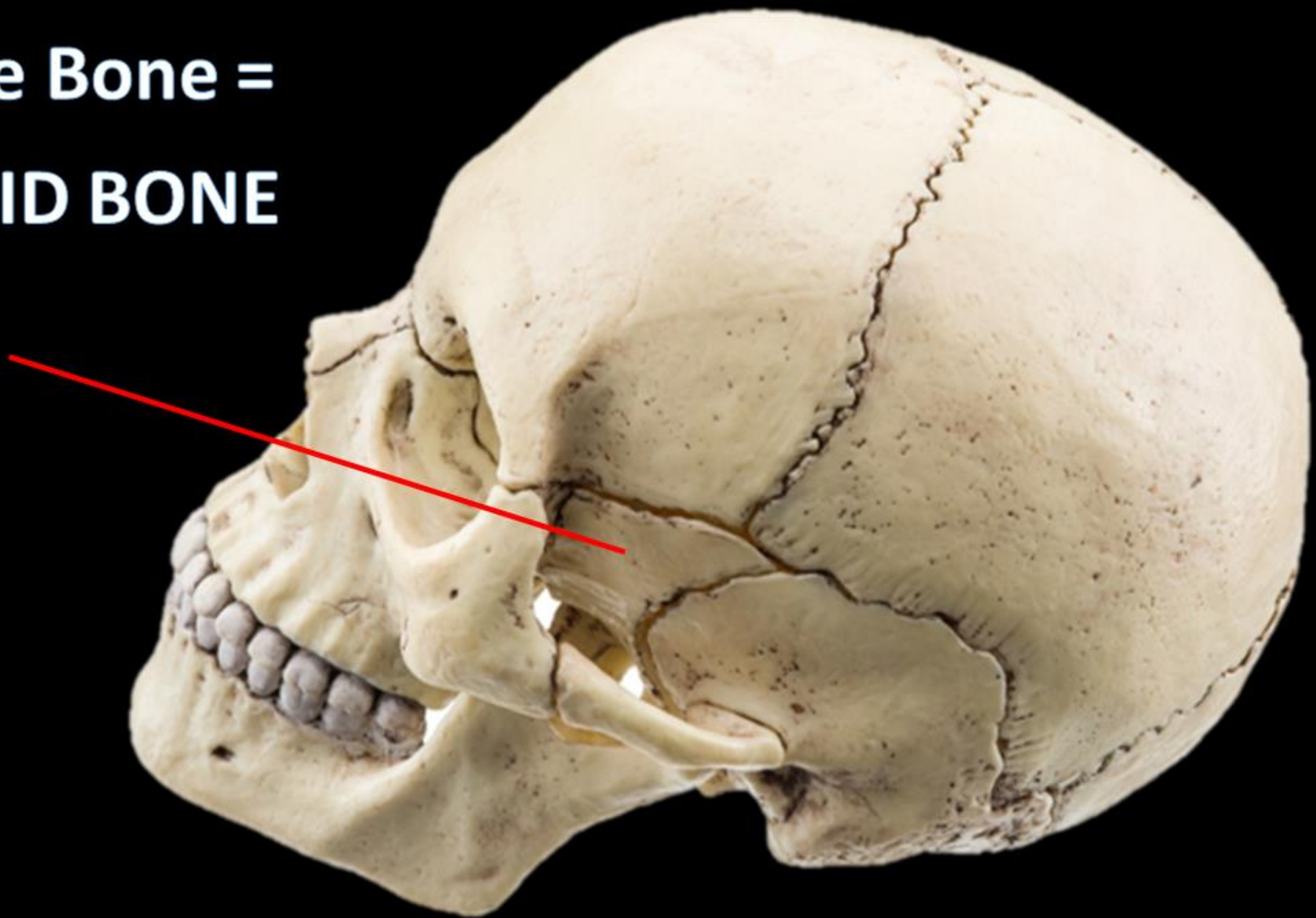


Name the Bone = **FRONTAL BONE**

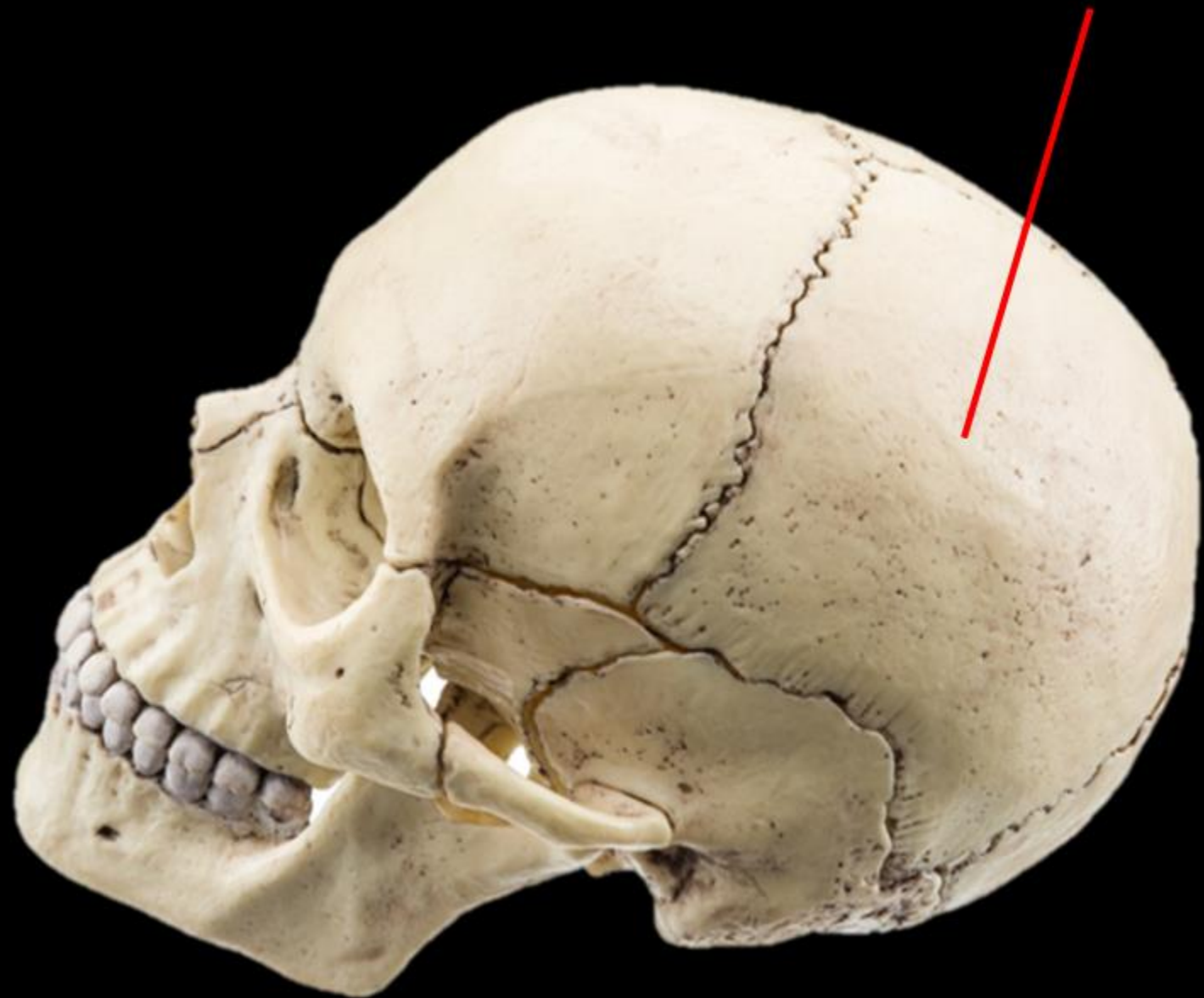
Name the Bone



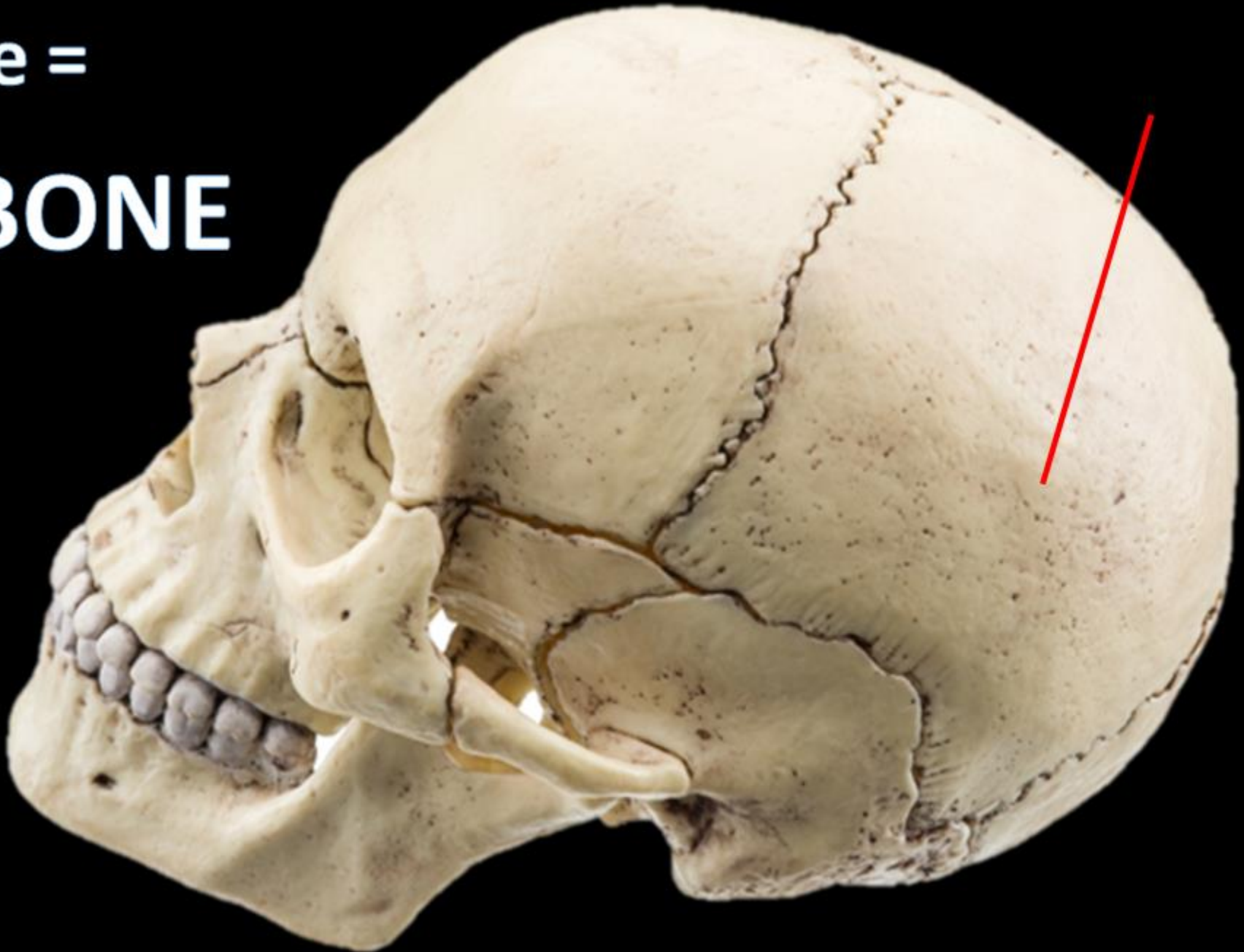
**Name the Bone =
SPHENOID BONE**

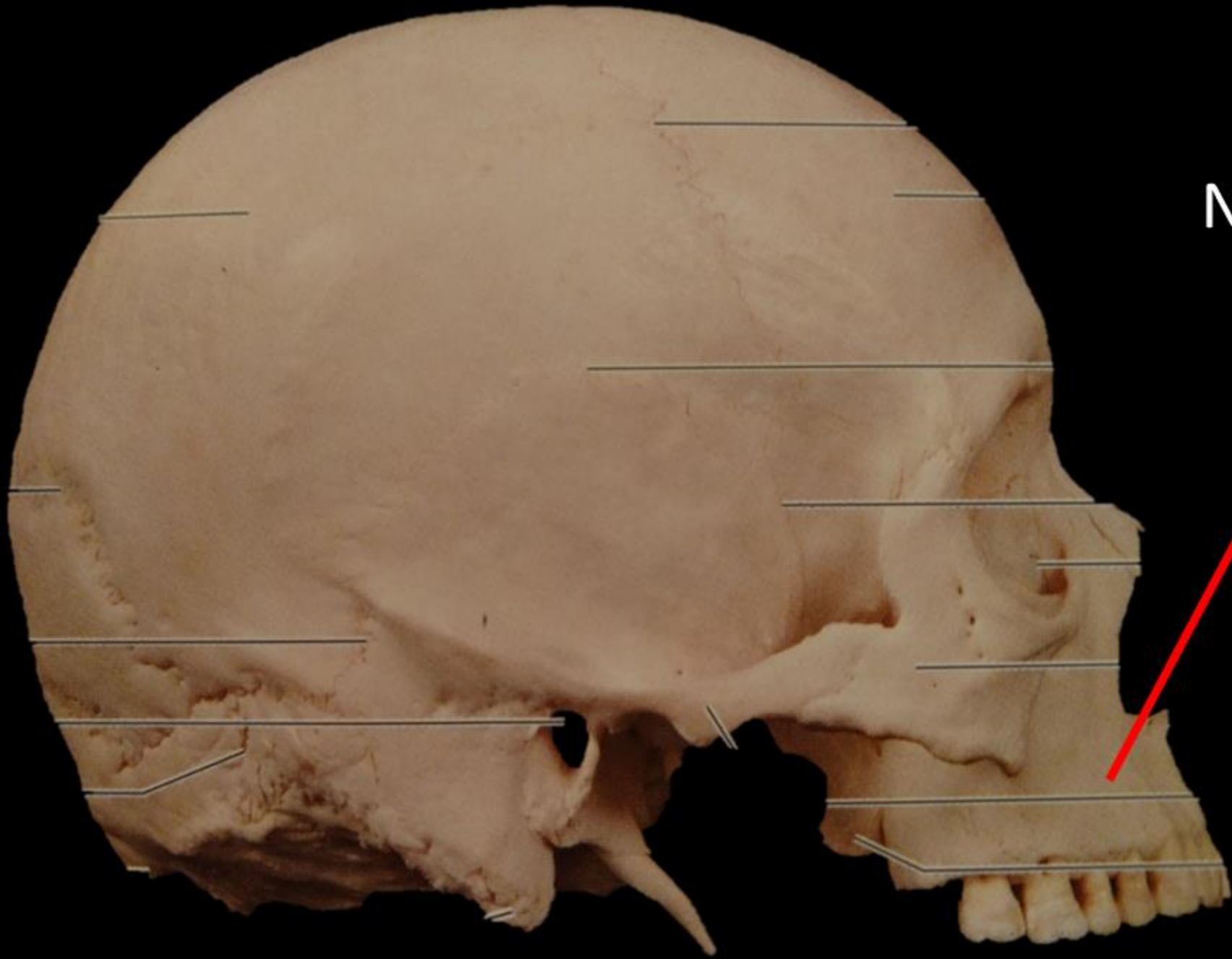

Name the Bone =



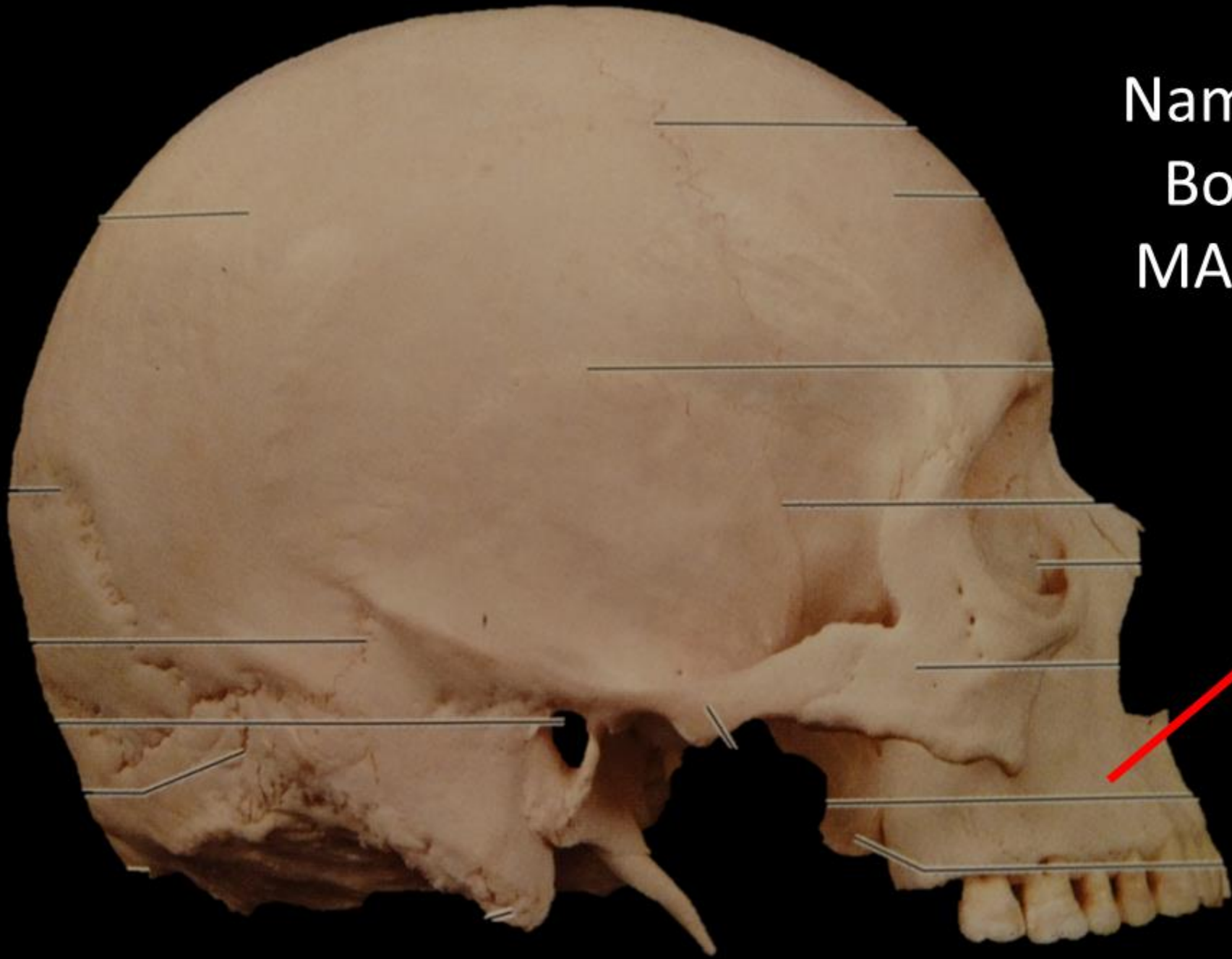Name the Bone =
PARIETAL BONE



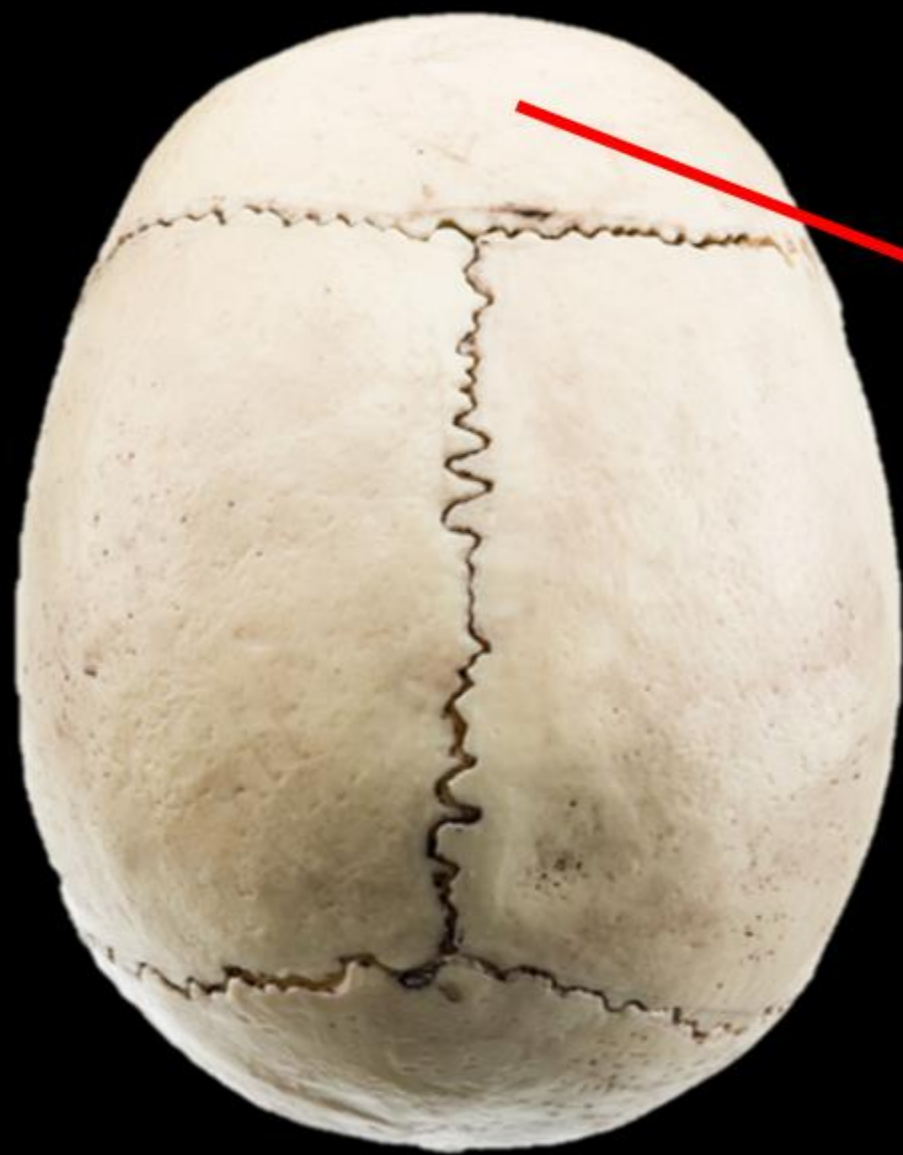


Name the
Bone





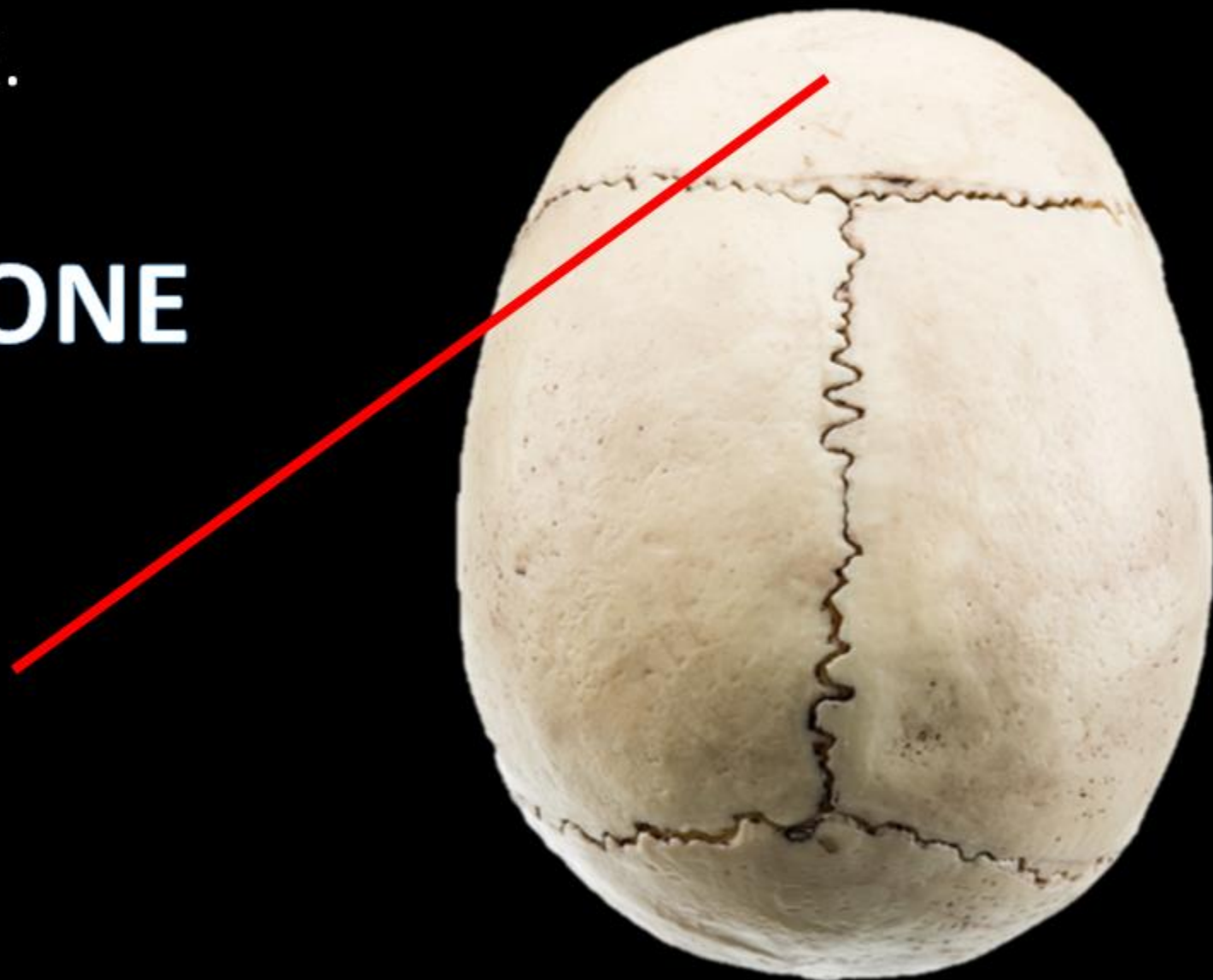
Name the
Bone =
MAXILLA



NAME THE BONE.

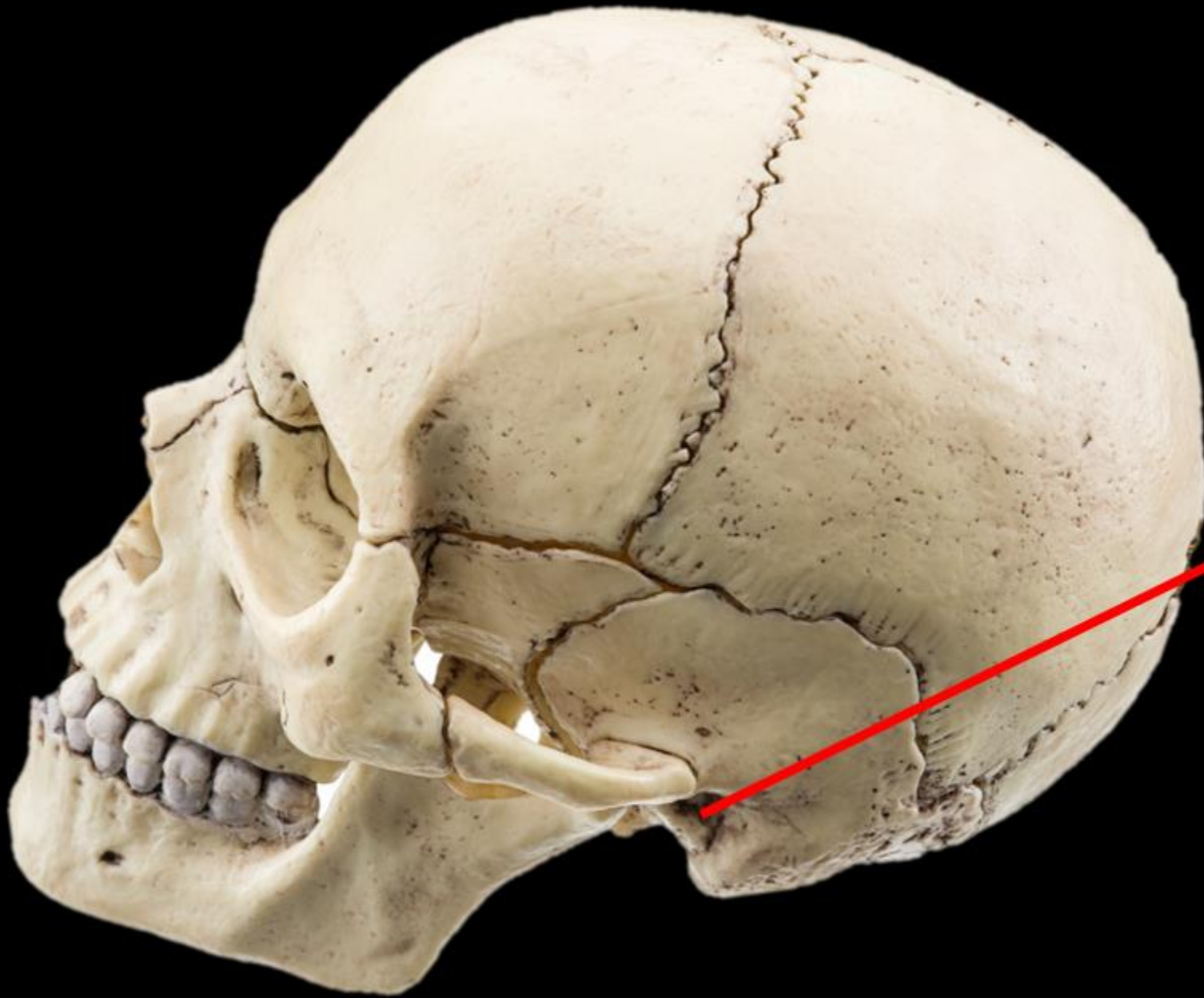
NAME THE BONE.

FRONTAL BONE



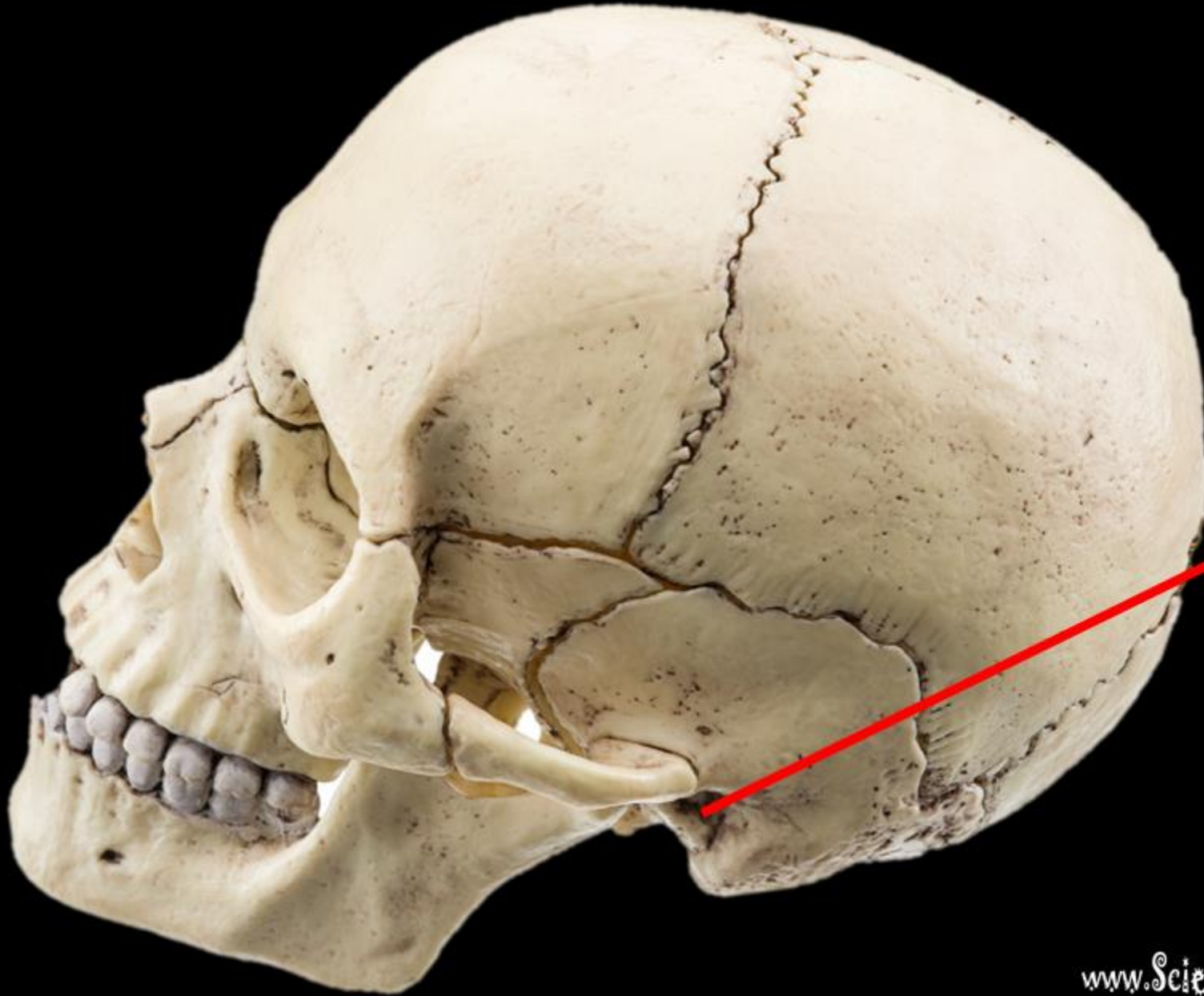
Name the Bone

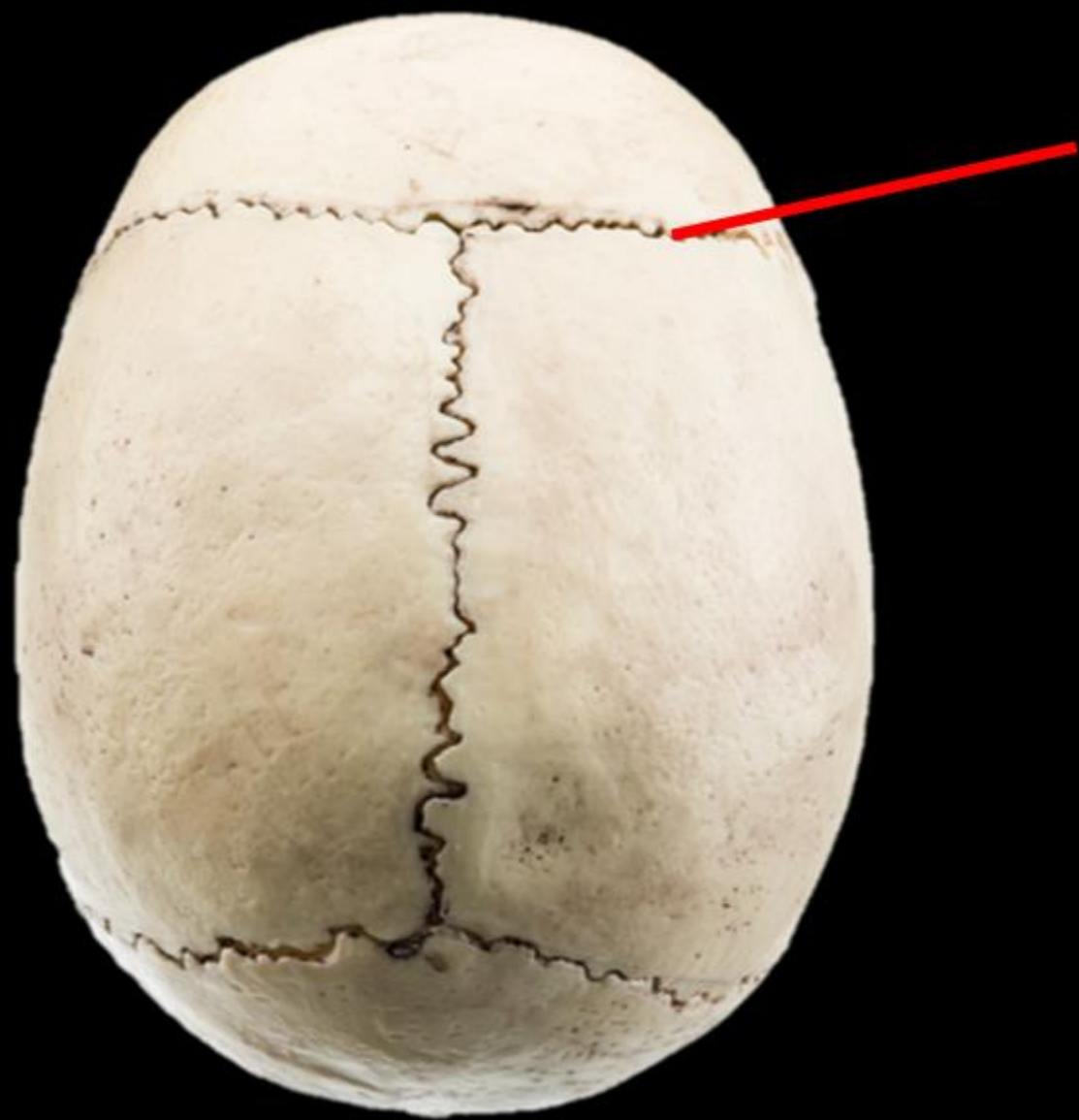
Name the Structure



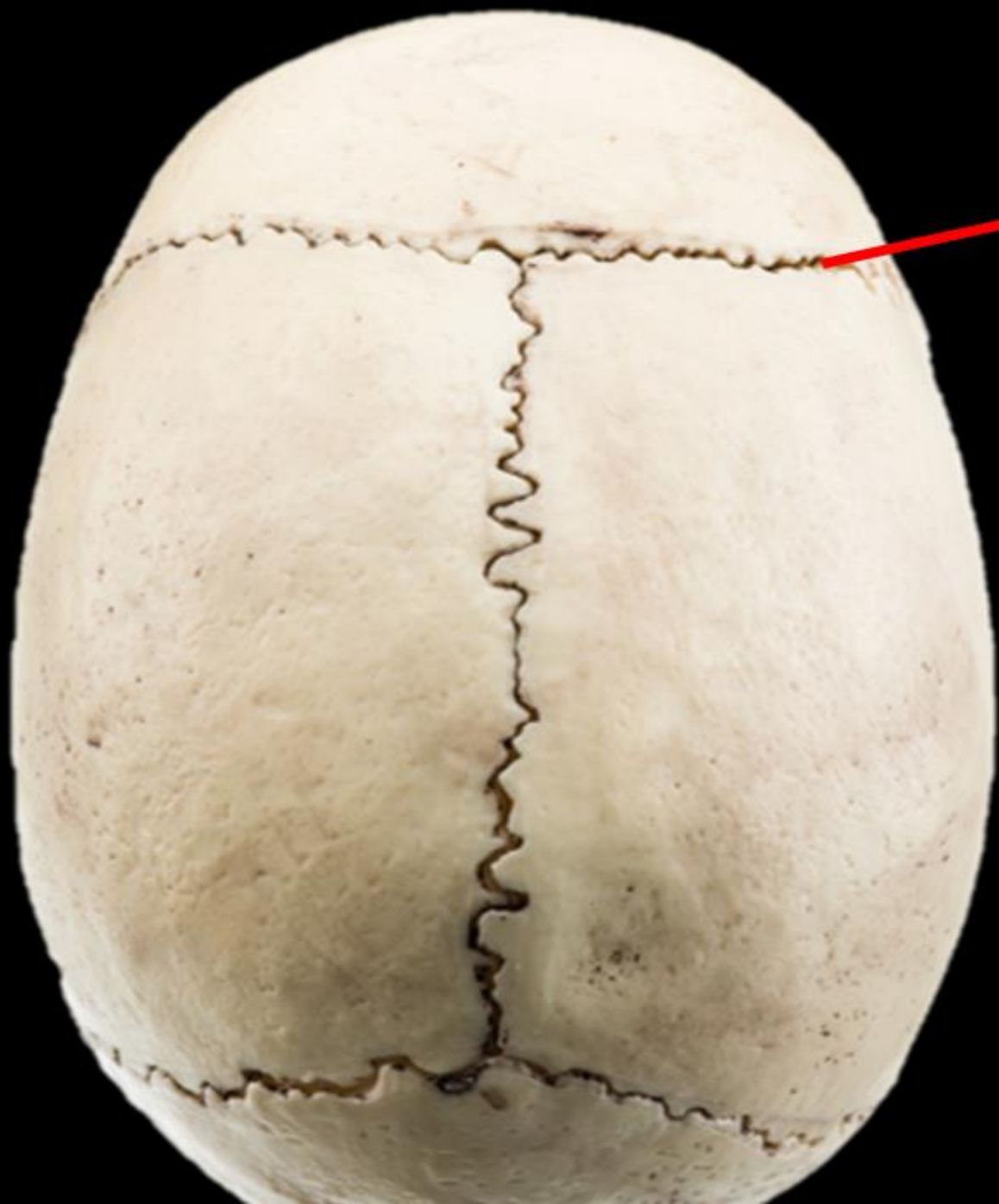Name the Bone =
TEMPORAL BONE

Name the Structure =
**EXTERNAL AUDITORY
MEATUS**



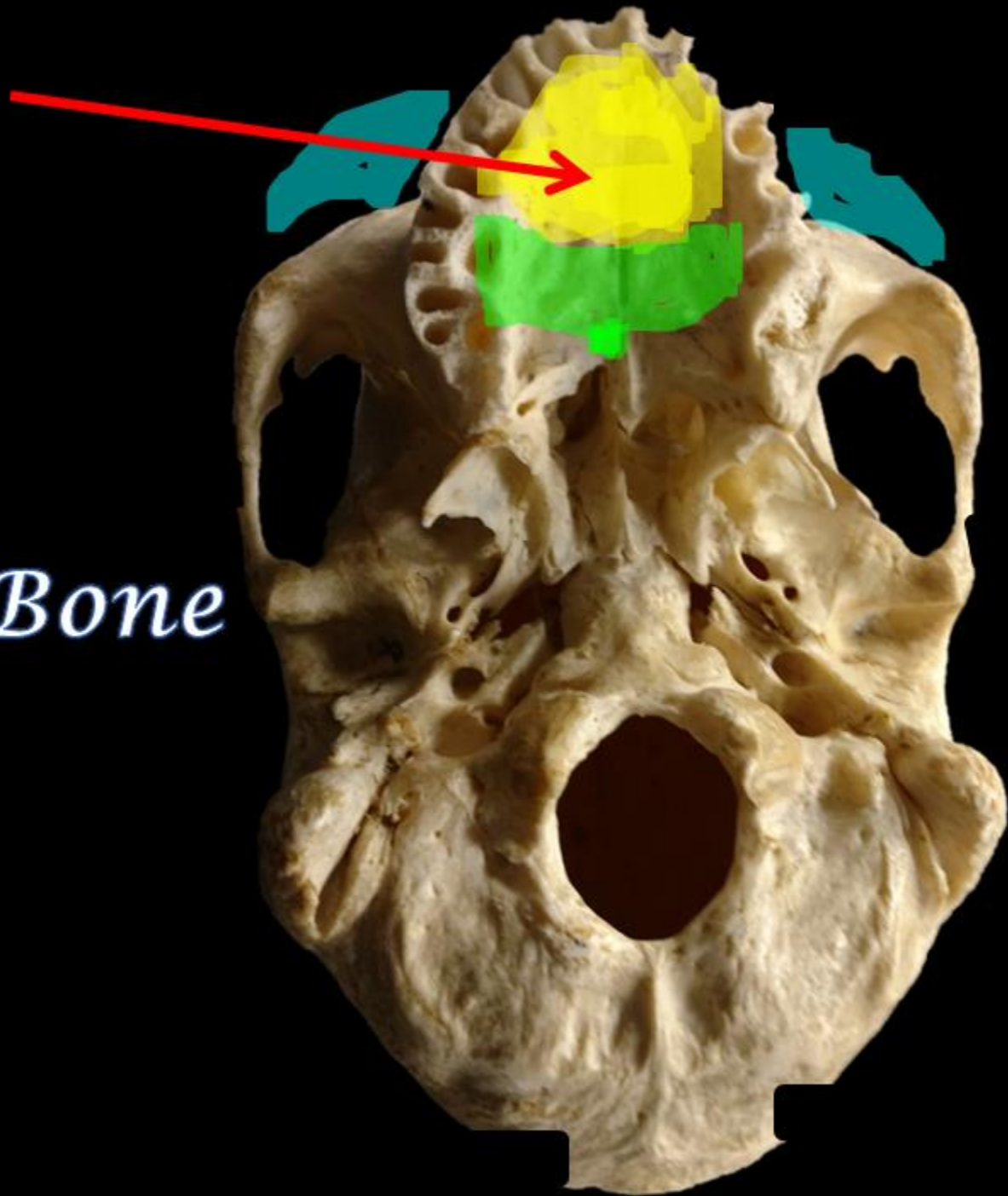


NAME THE
STRUCTURE.



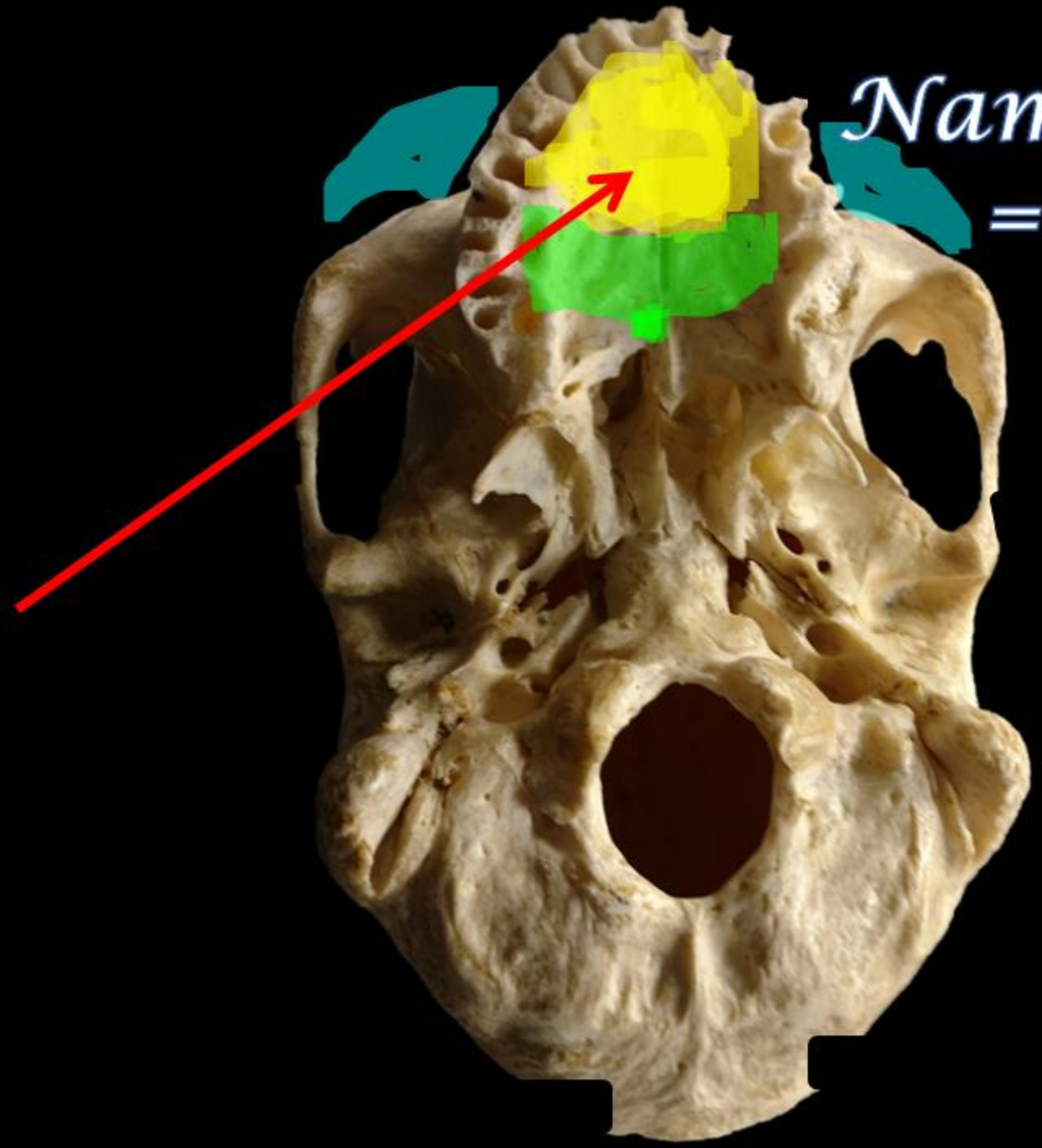
NAME THE
STRUCTURE.

CORONAL SUTURE

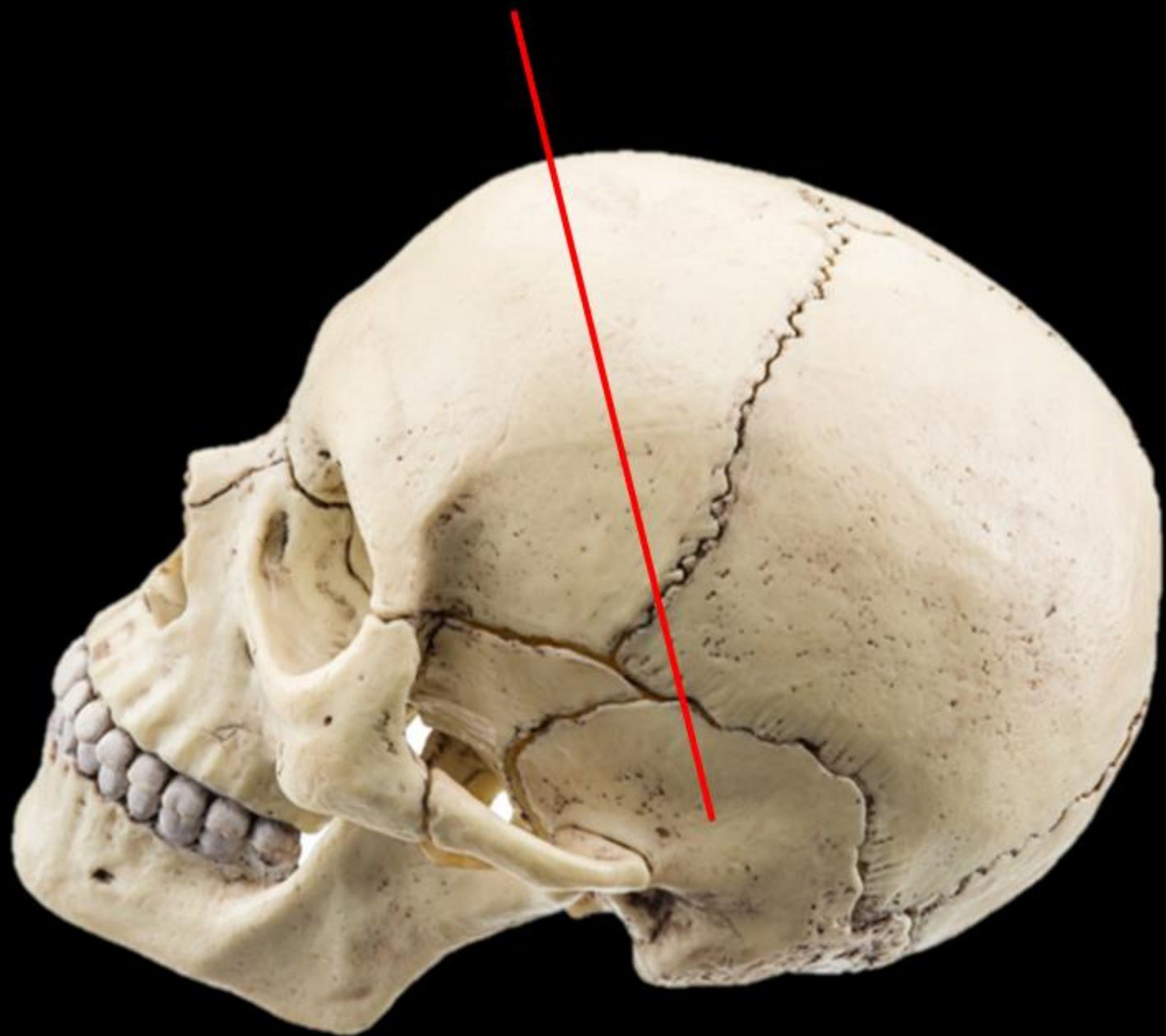


Name the Bone

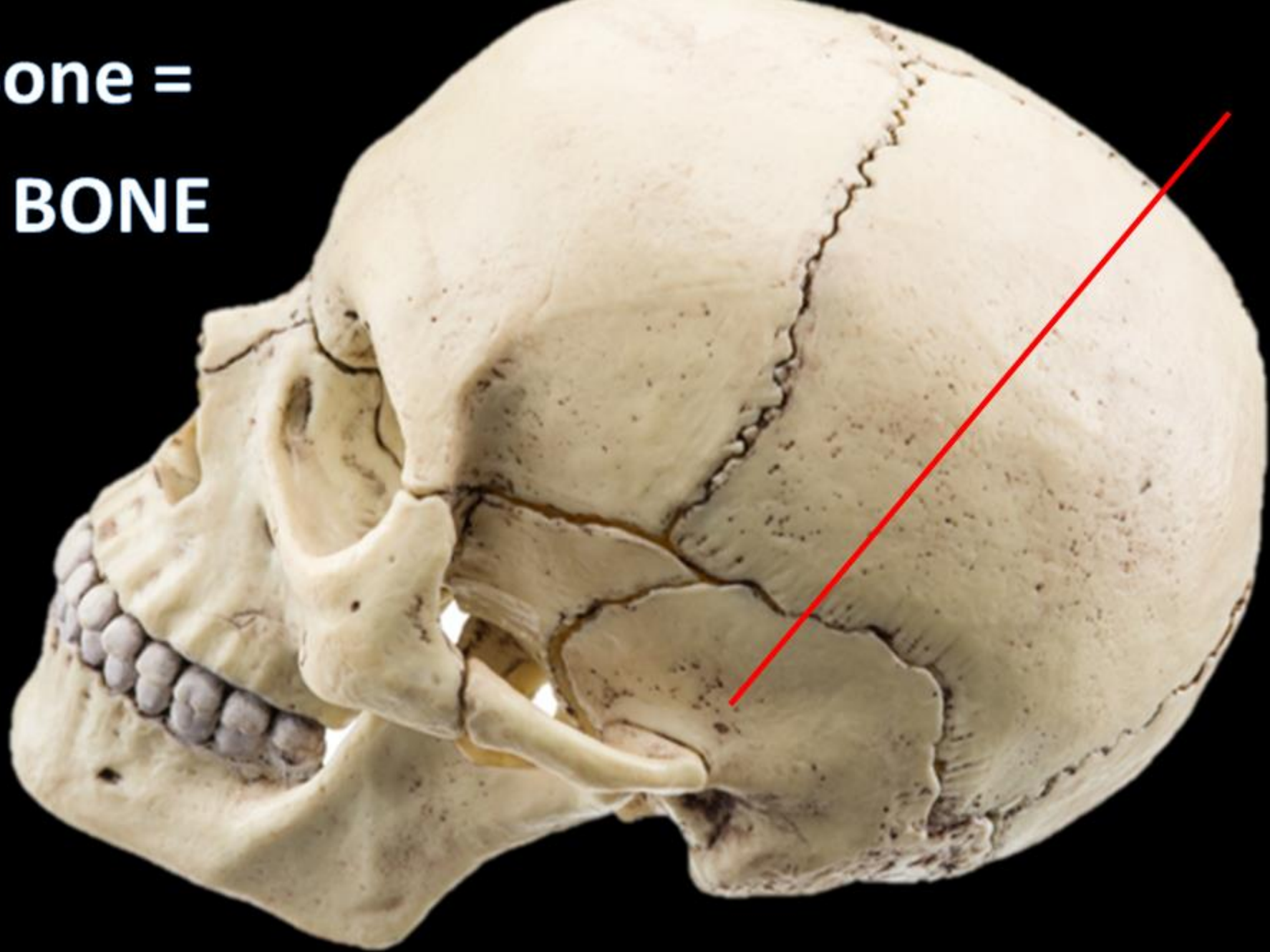
*Name the Bone
= Maxilla*



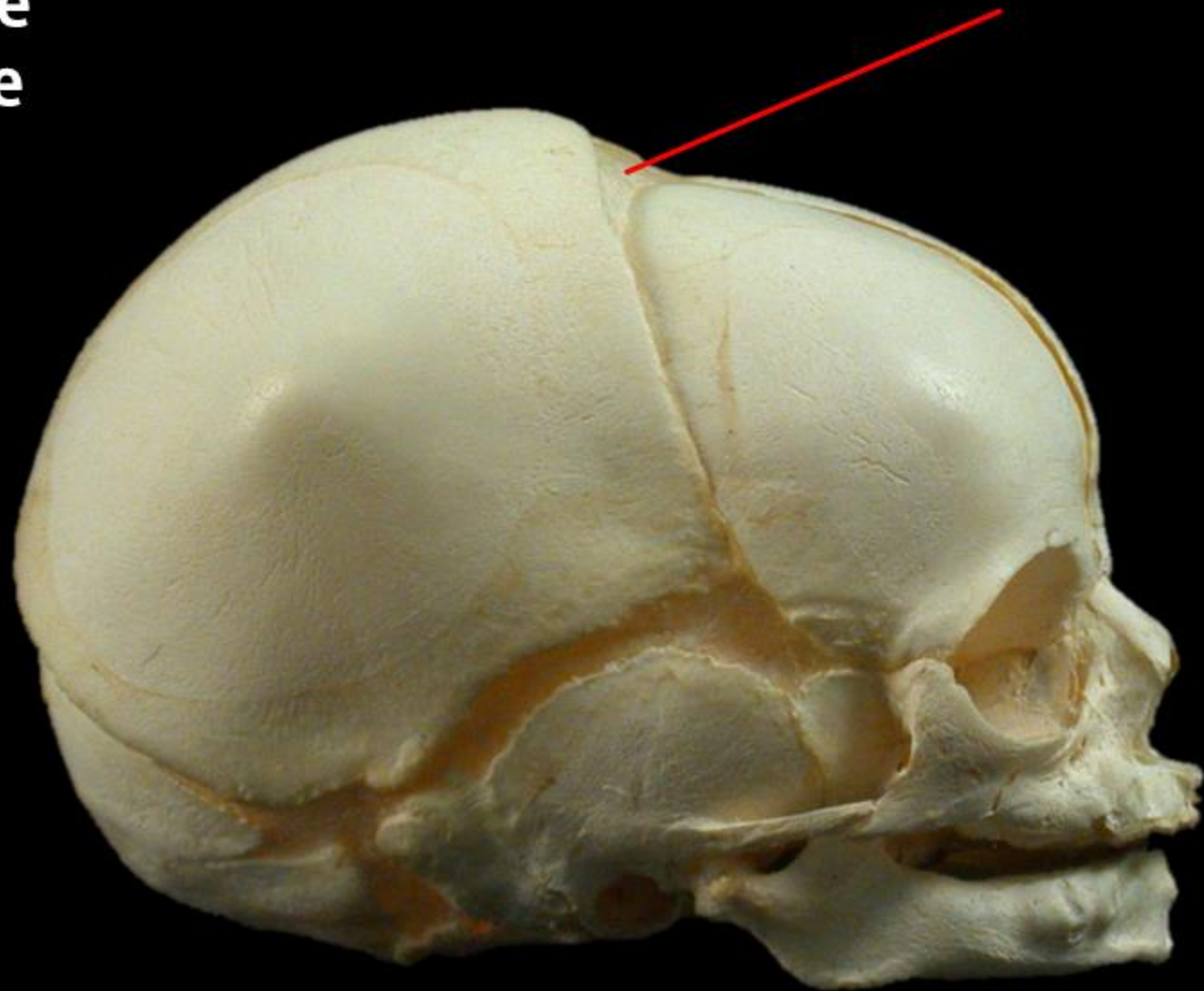
Name the Bone =



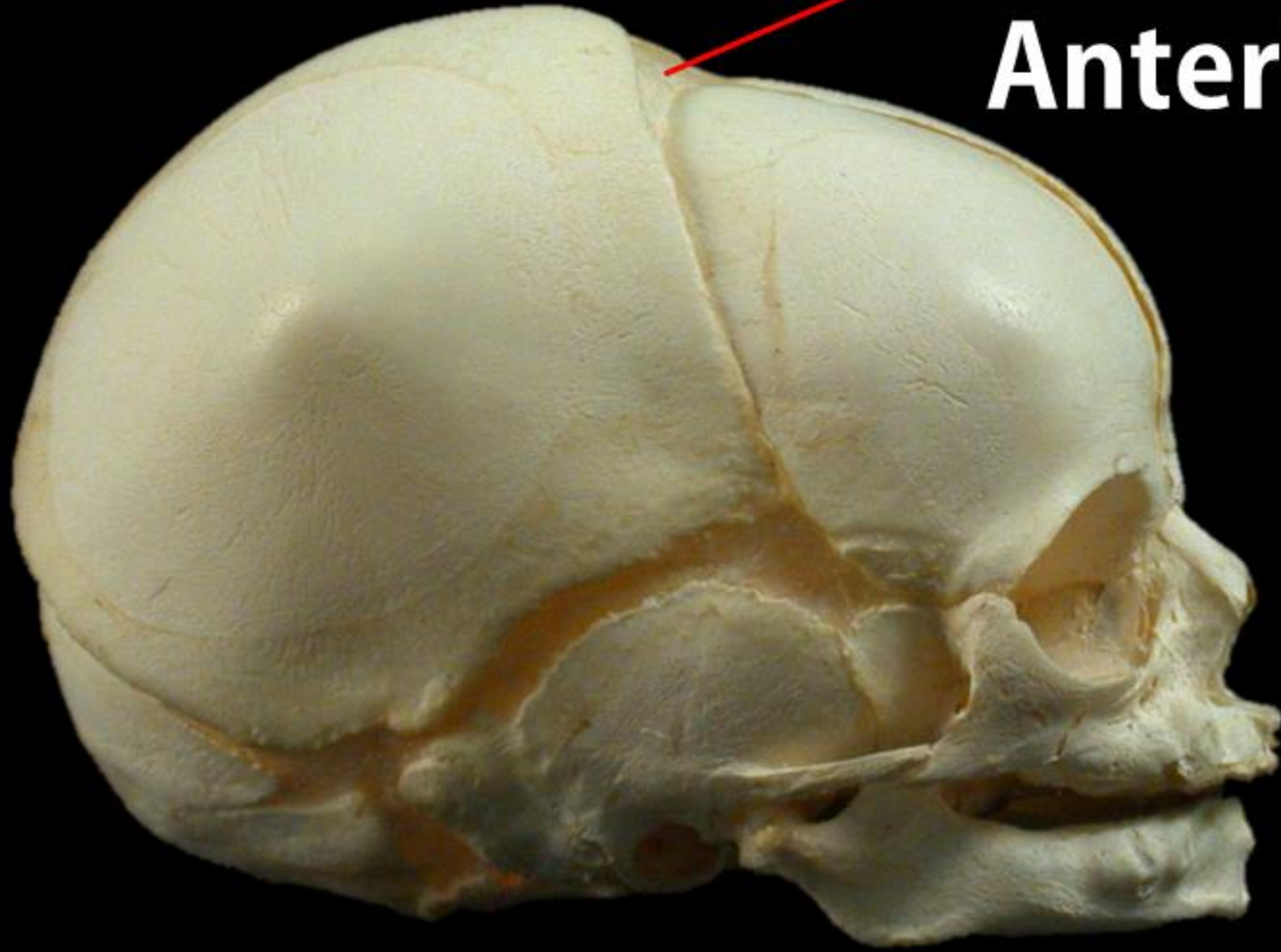
**Name the Bone =
TEMPORAL BONE**



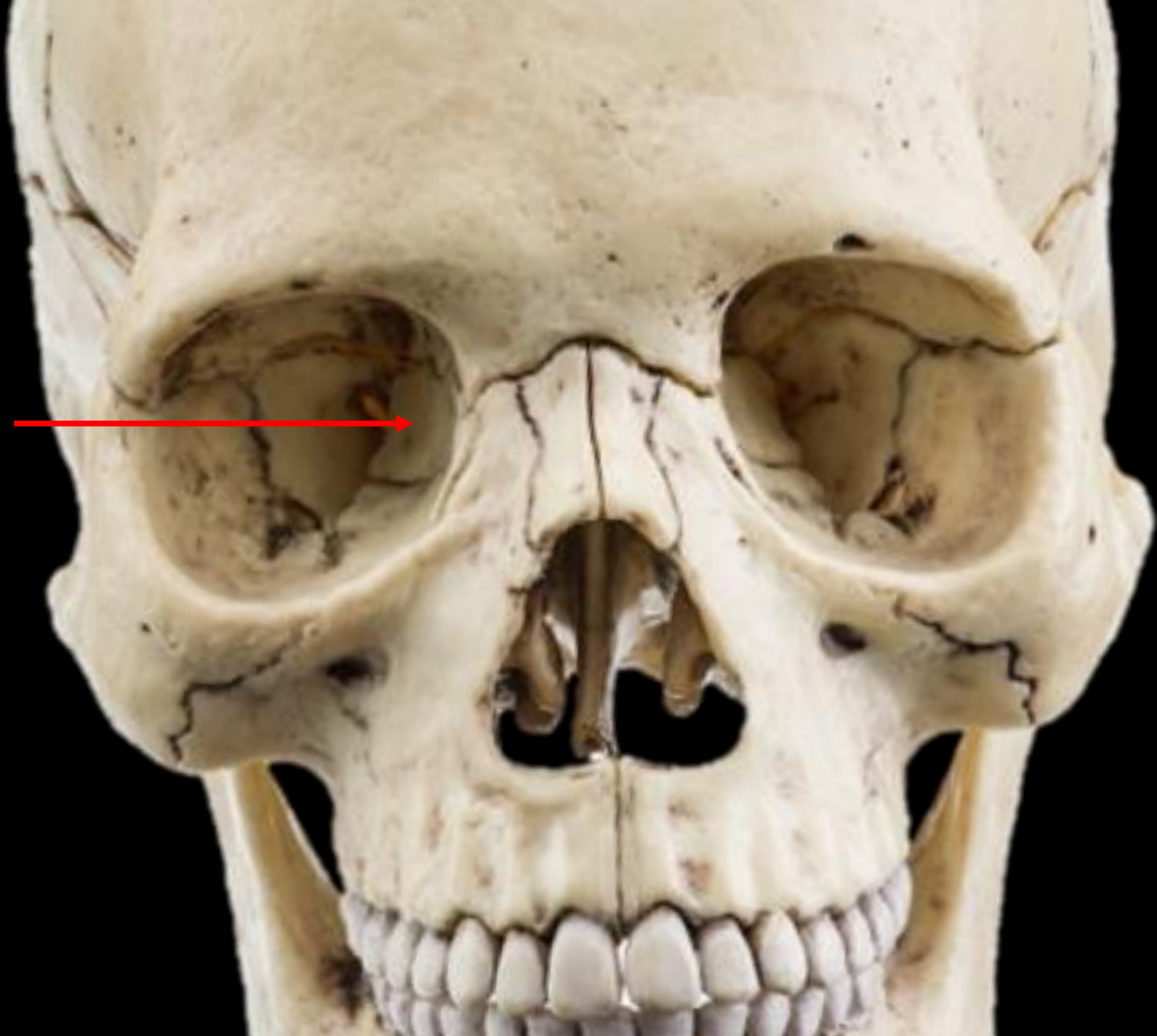**Name the
Structure**



Anterior Fontanel



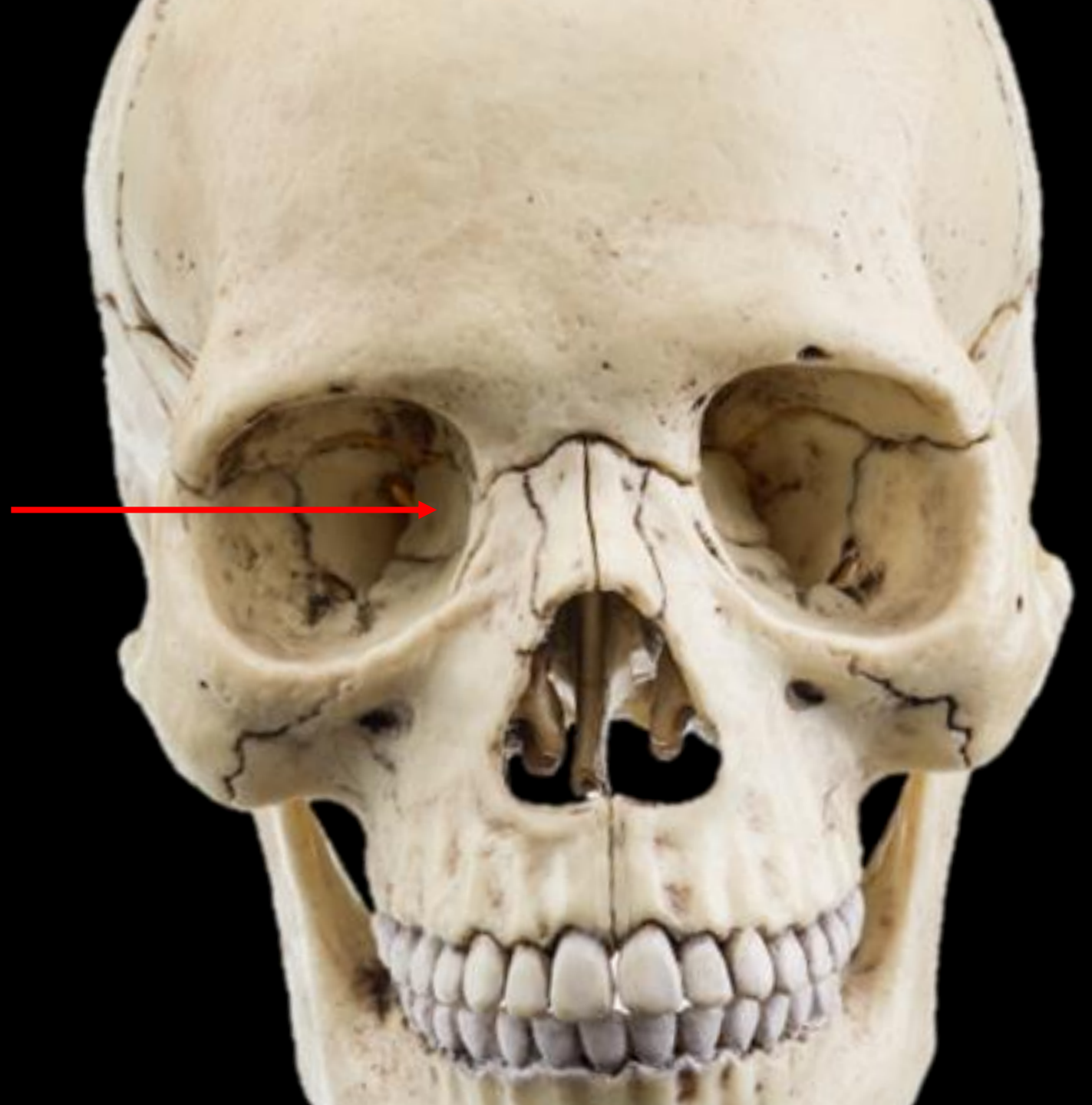What is the bone?



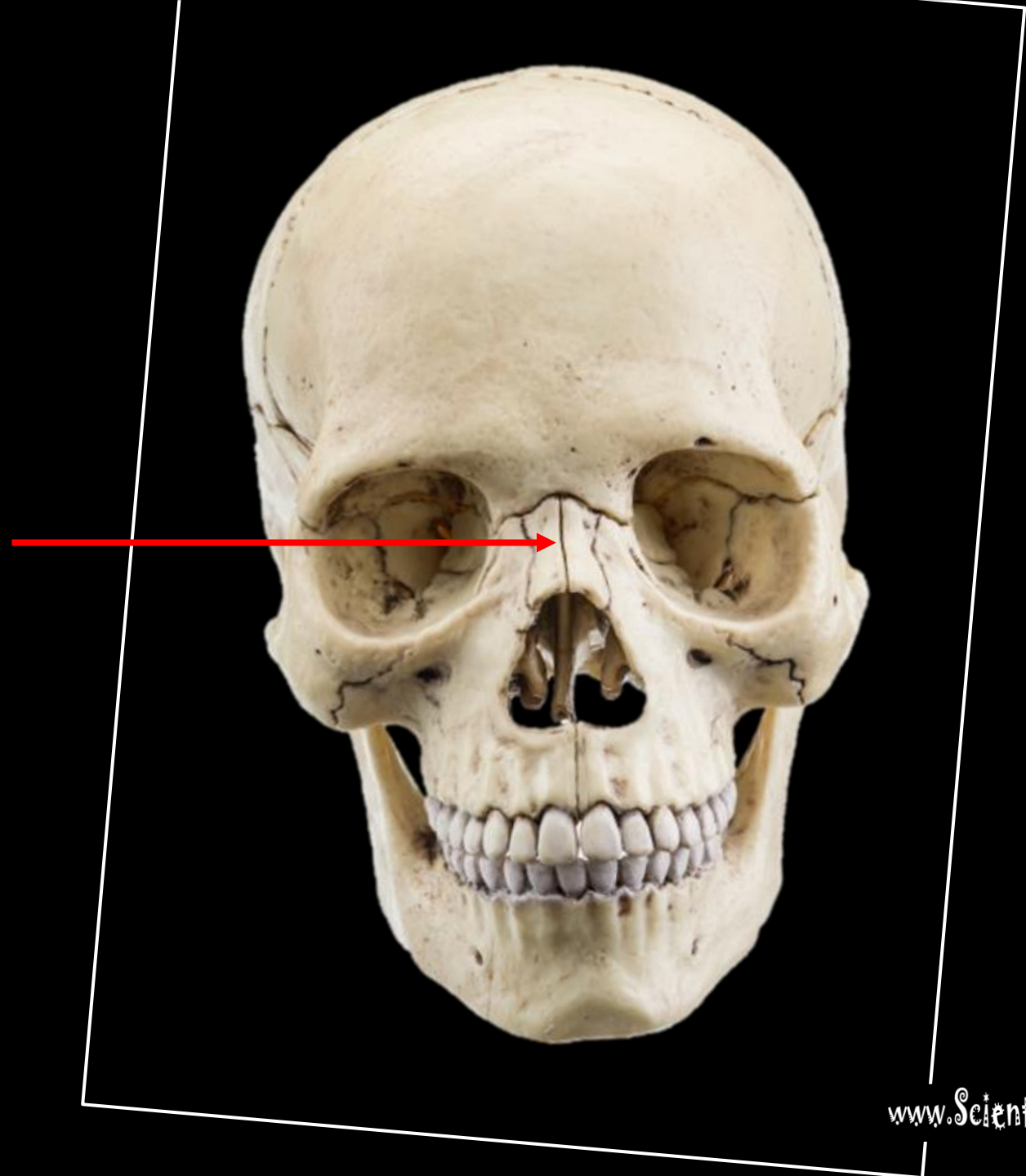
What is the bone?

LACRIMAL BONE

www.ScientistCindy.com

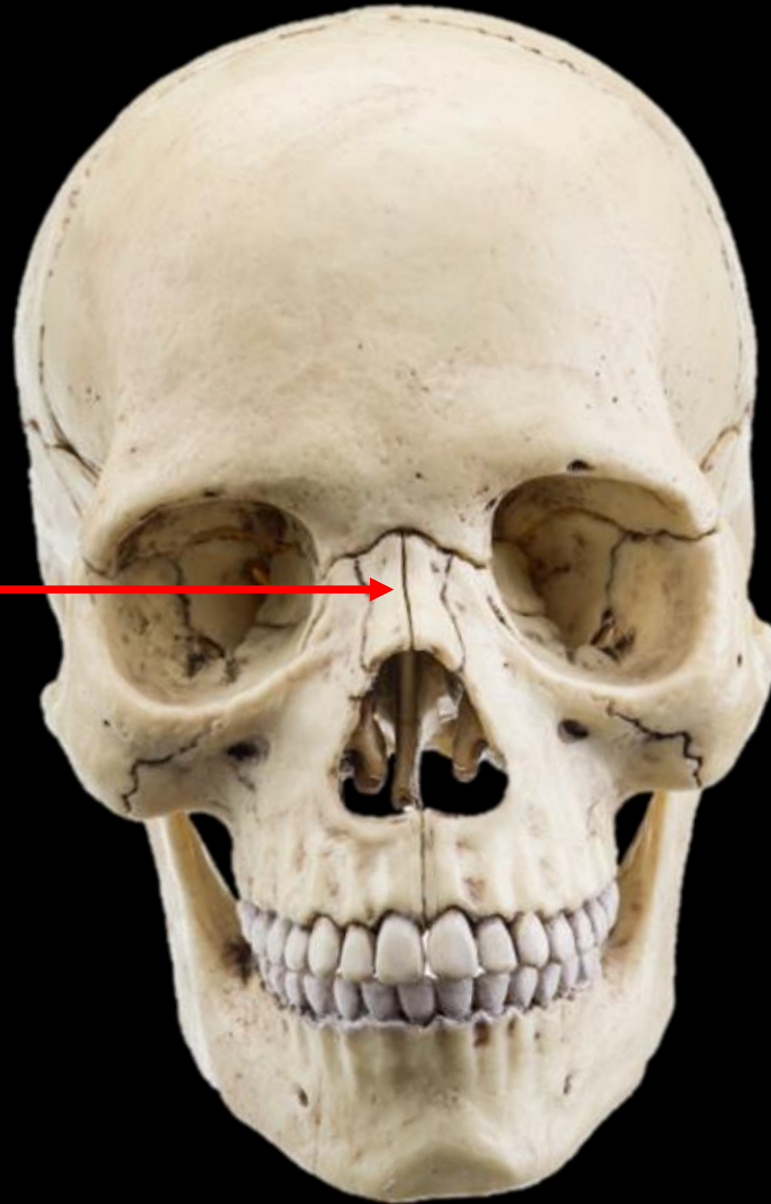


What is the bone?

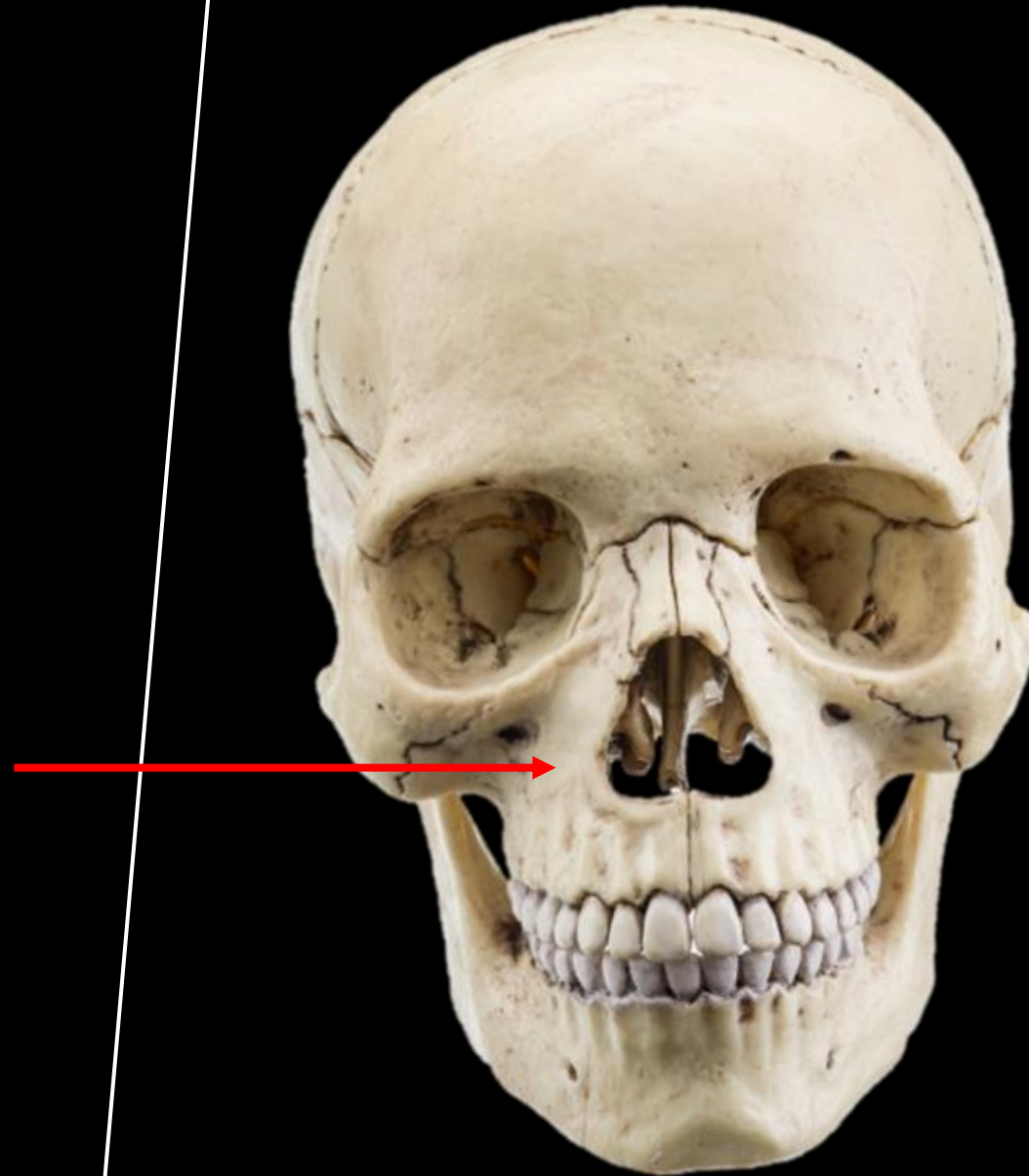


What is the bone?

NASAL BONE

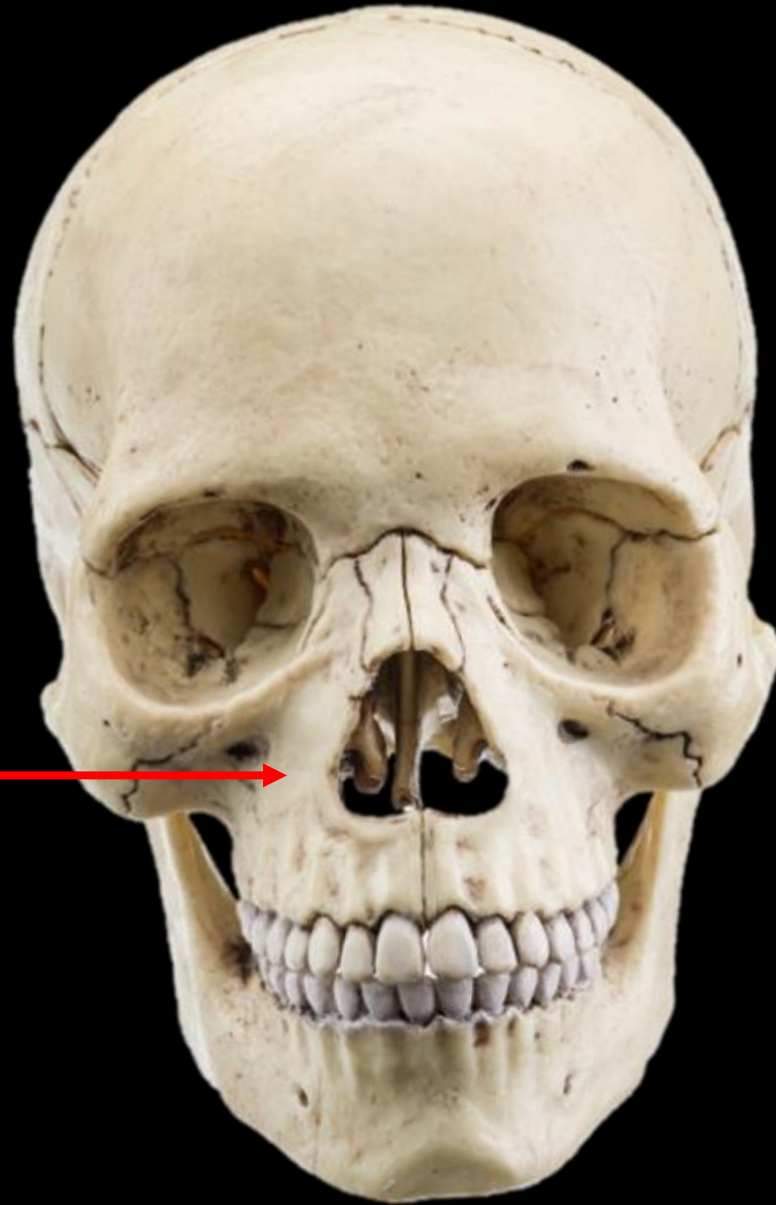

What is the bone?

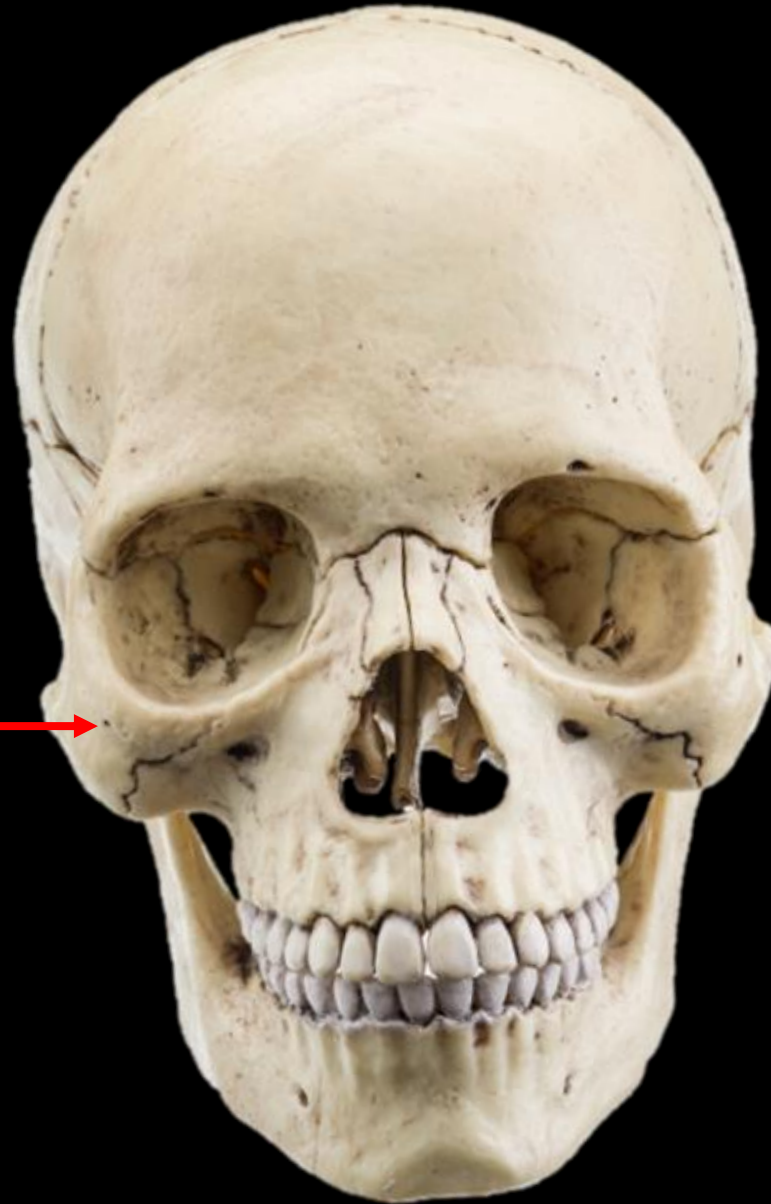

What is the bone?

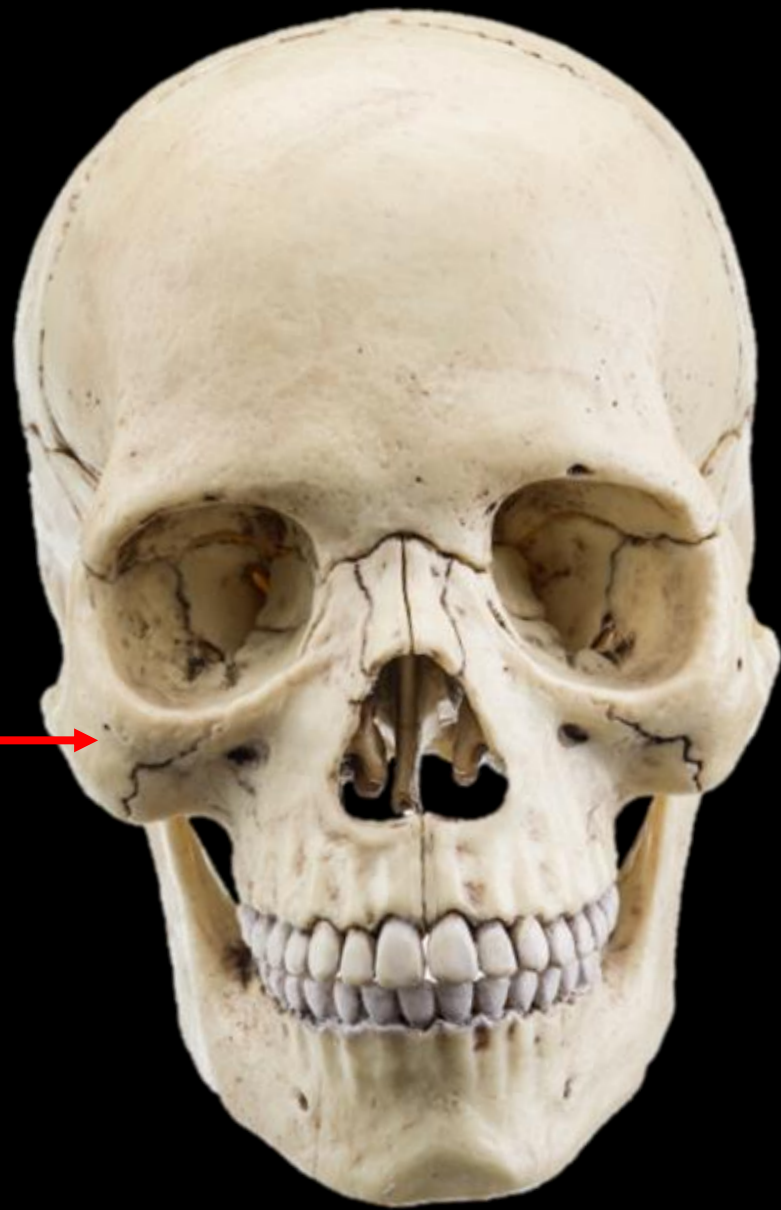MAXILLA



What is the bone?

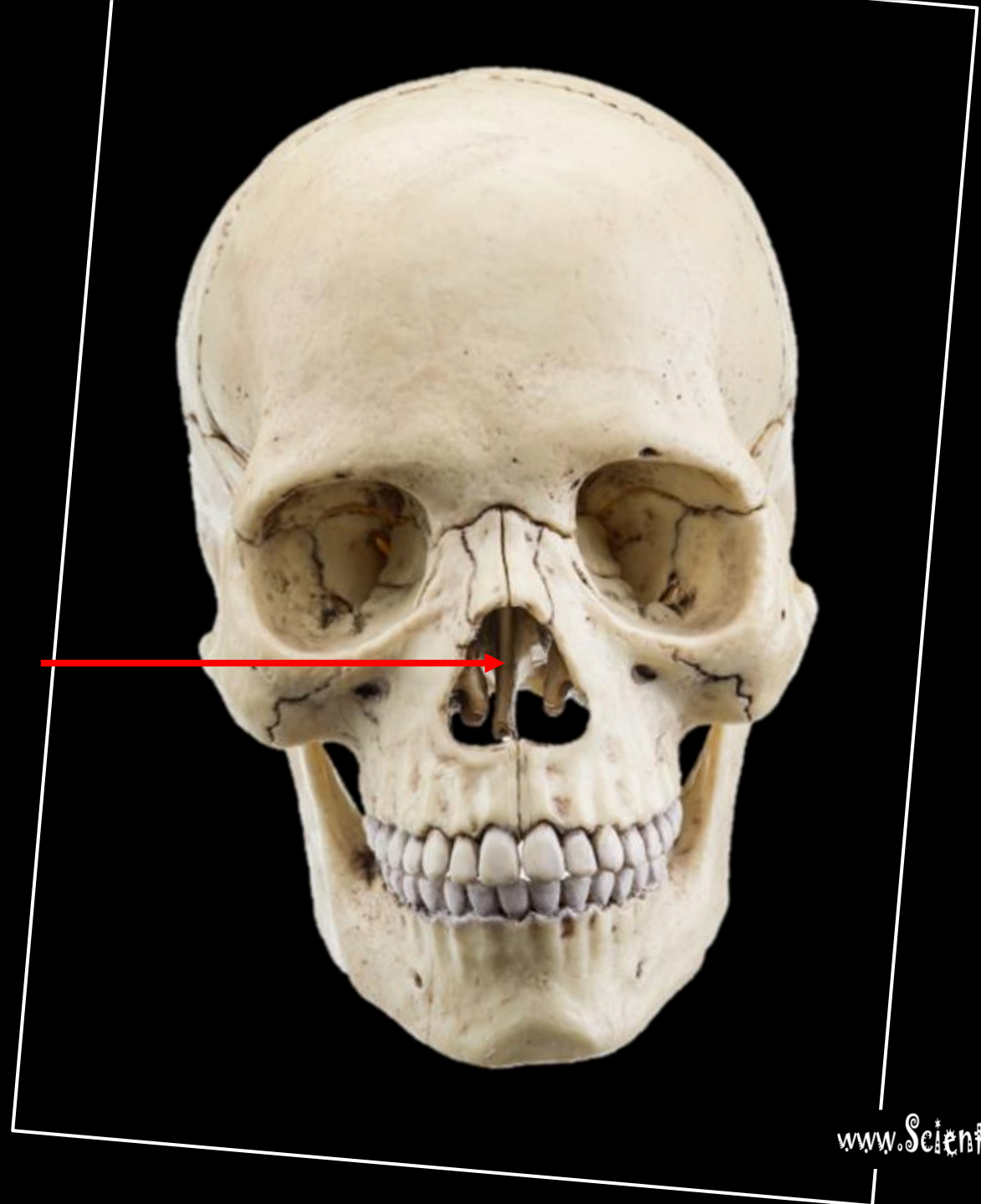


**ZYGOMATIC BONE
(ZYGOMA)**



What is the bone?

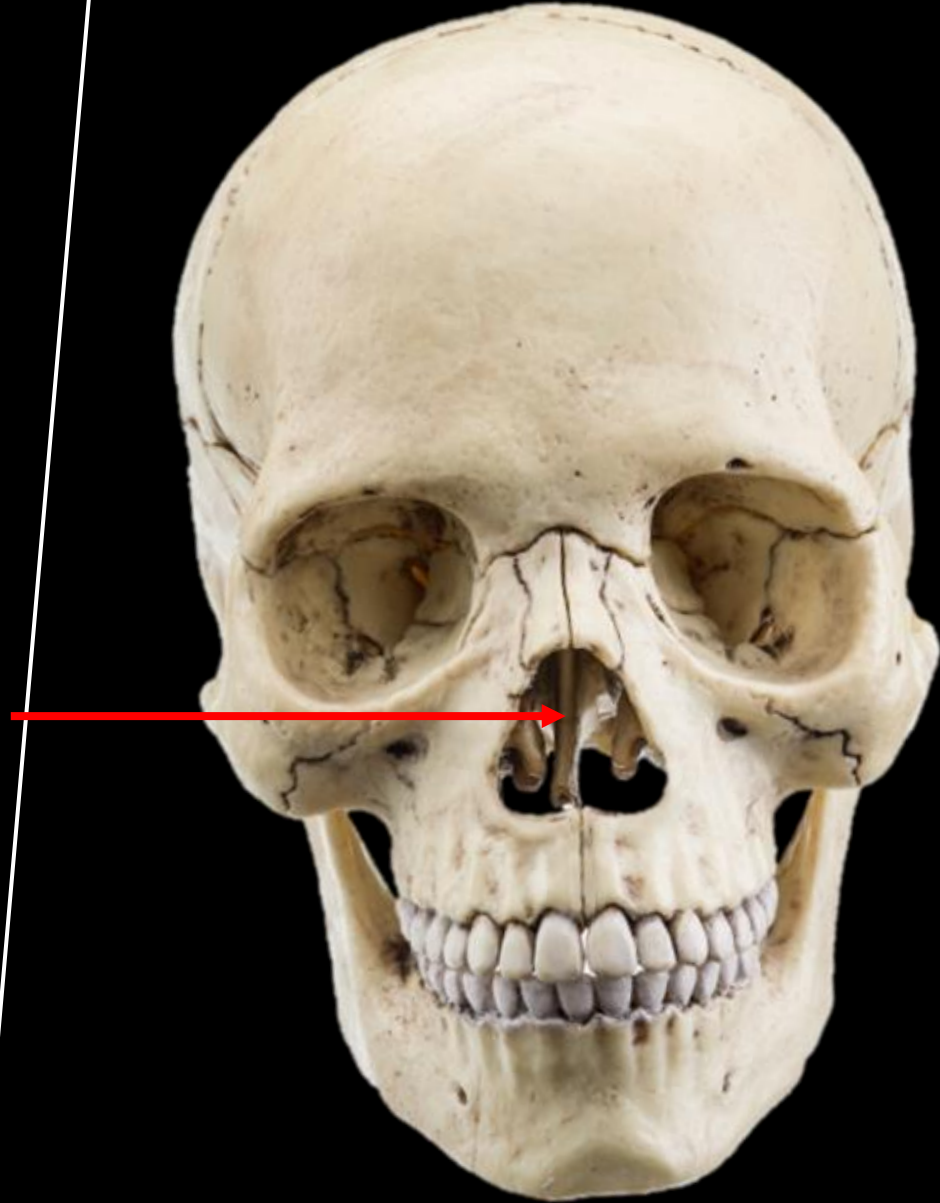
What is the structure?



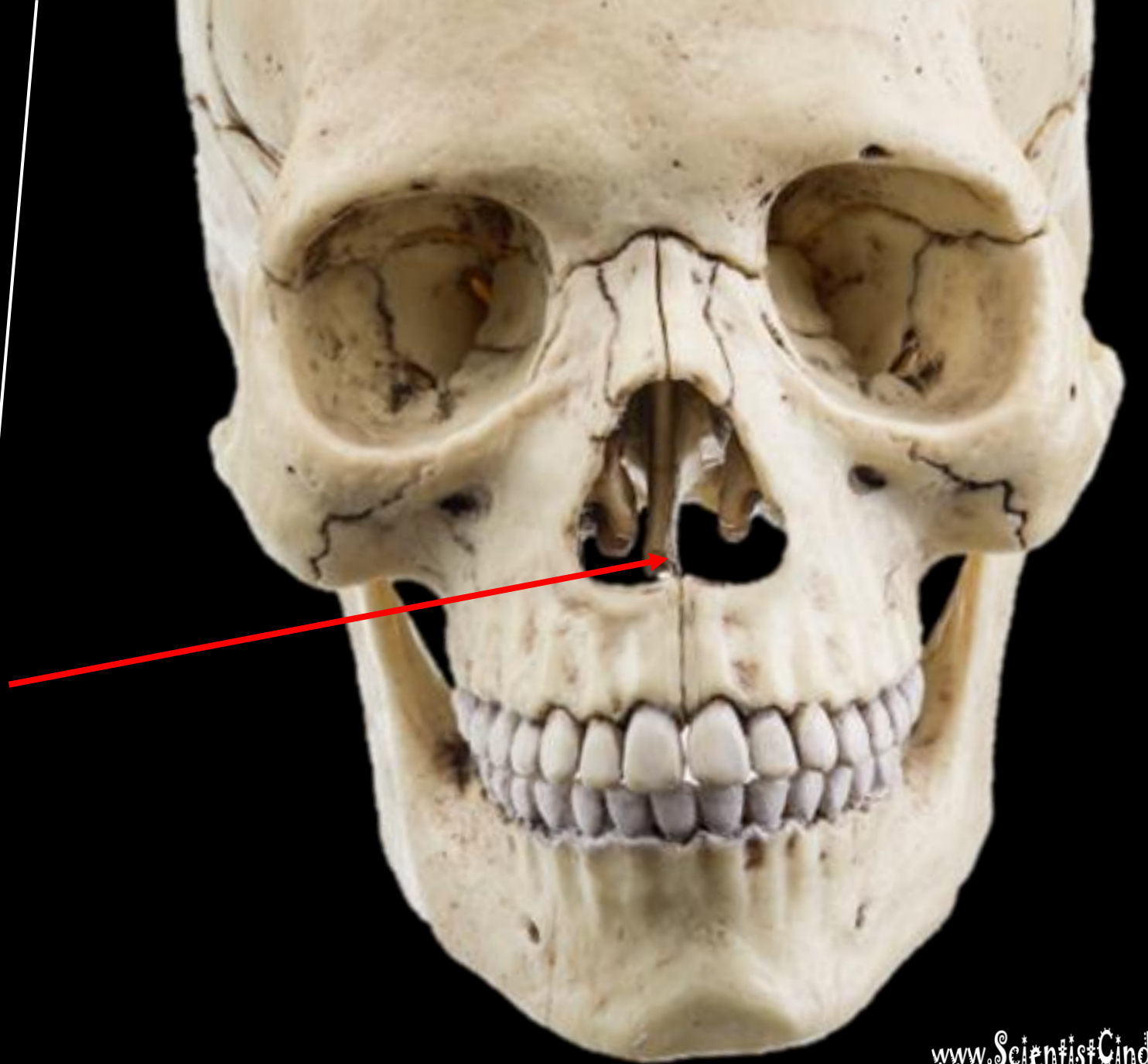
What is the bone?

What is the structure?

THIS IS THE
PERPENDICULAR PLATE OF
THE ETHMOID BONE

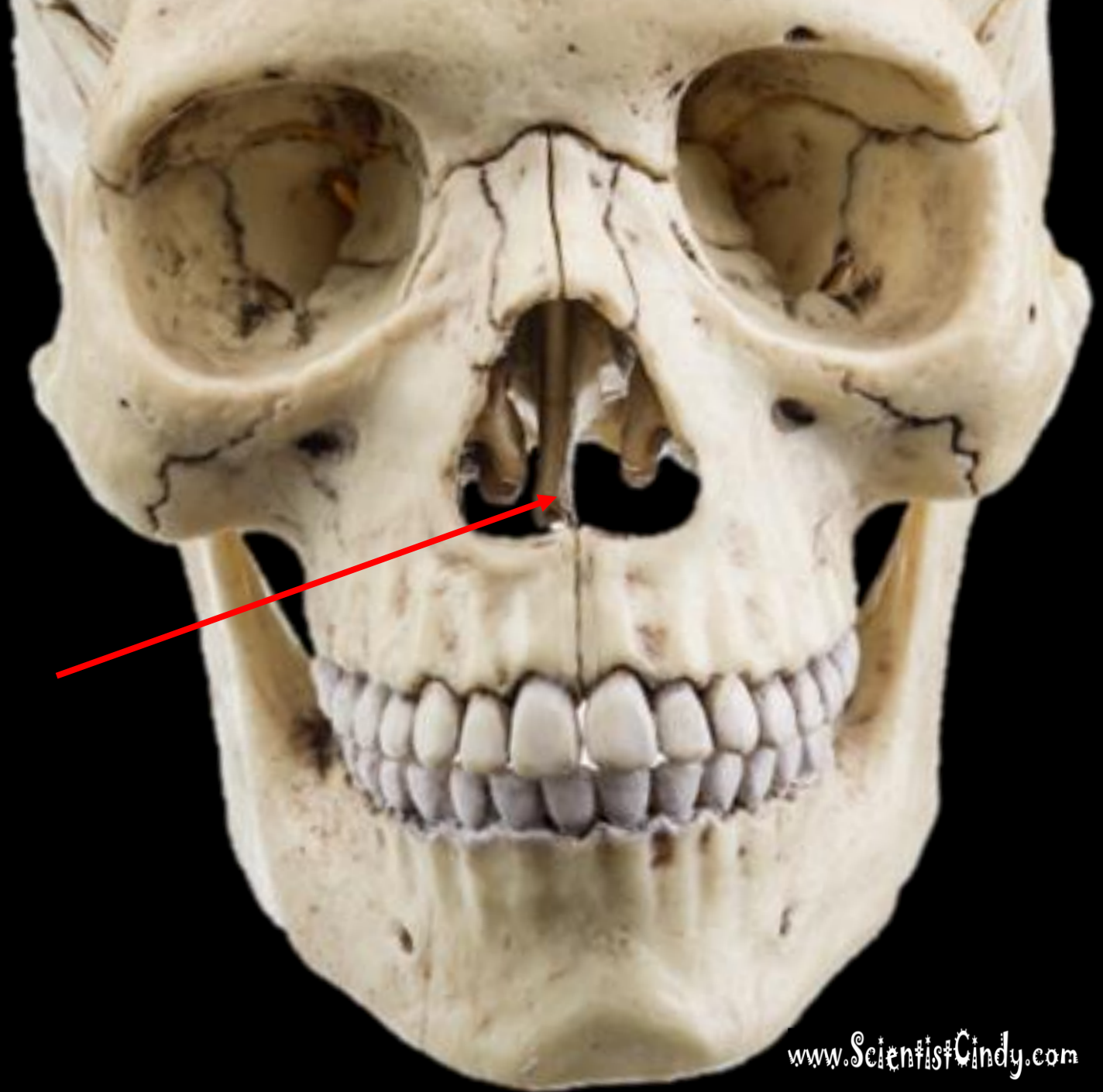


What is the bone?

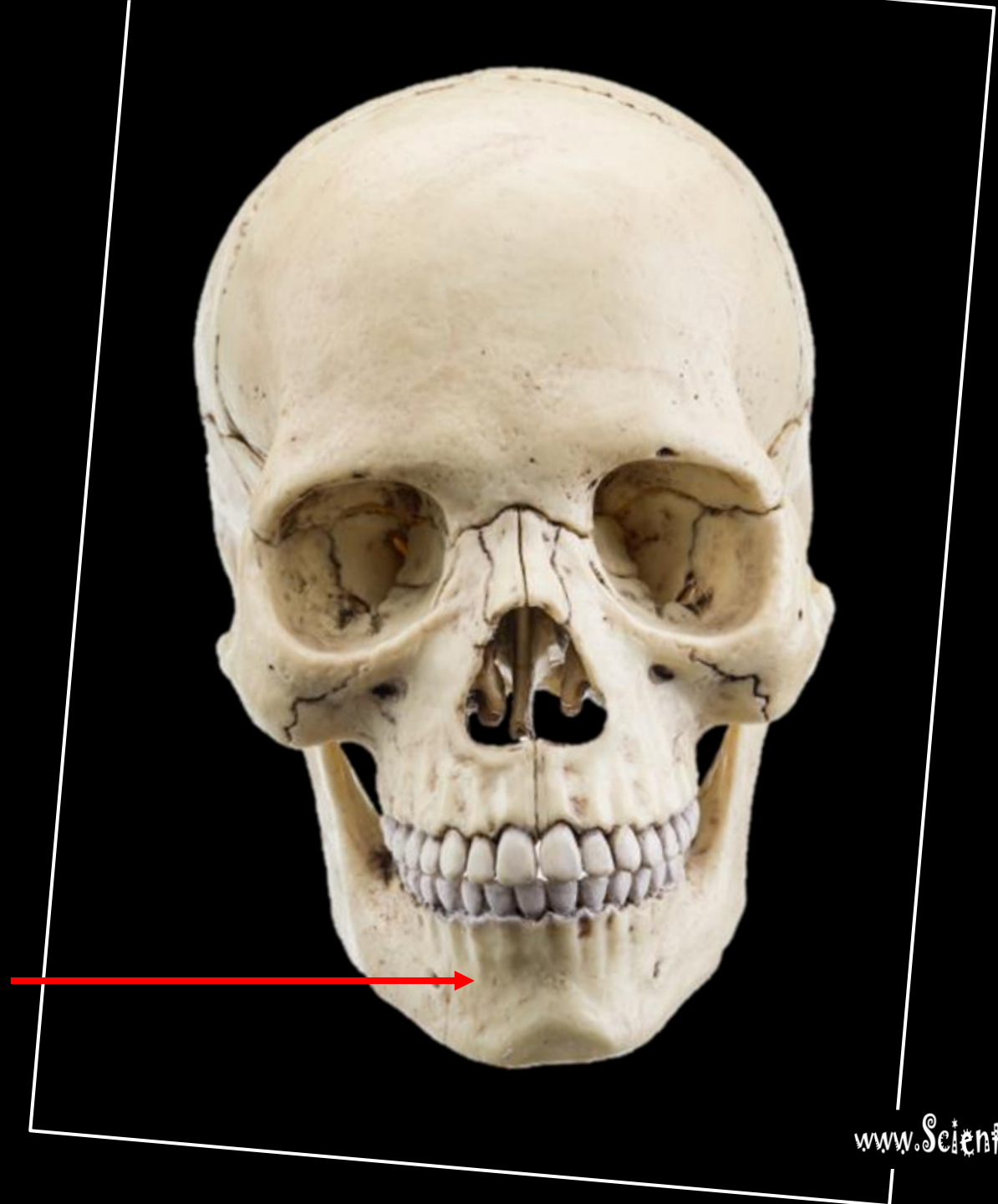

What is the bone?

VOMER

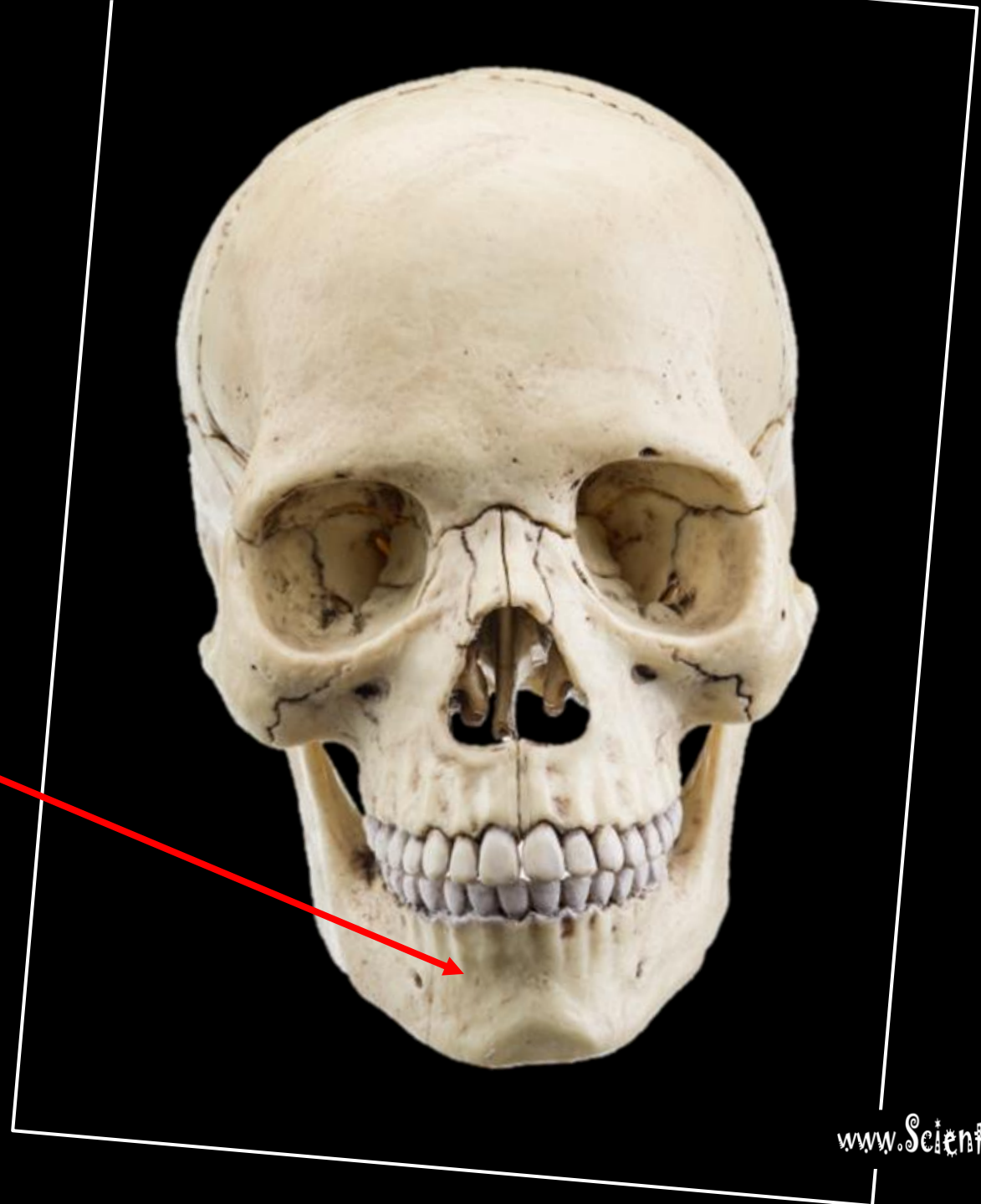


What is the bone?



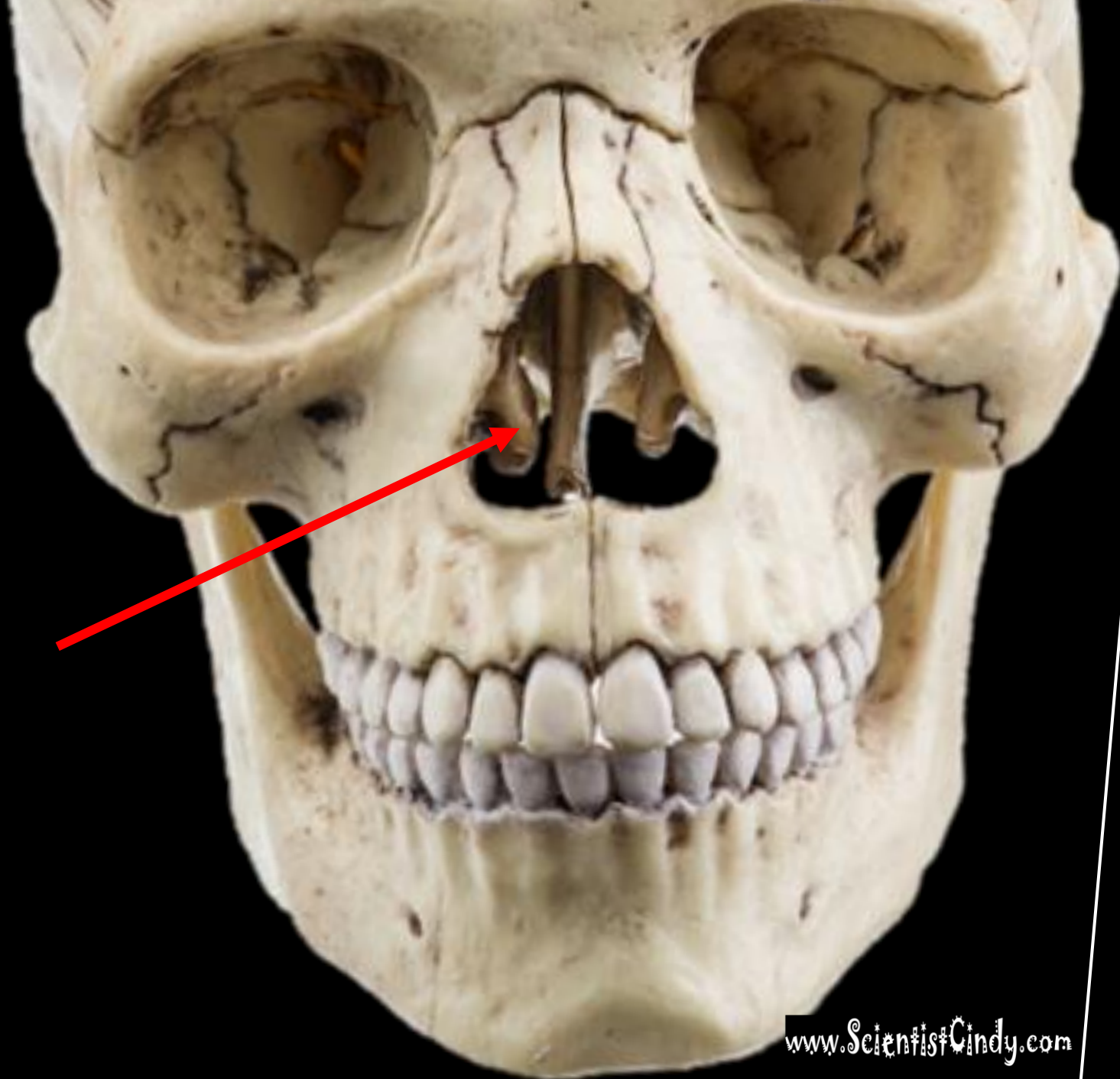
What is the bone?

MANDIBLE



What is the bone?

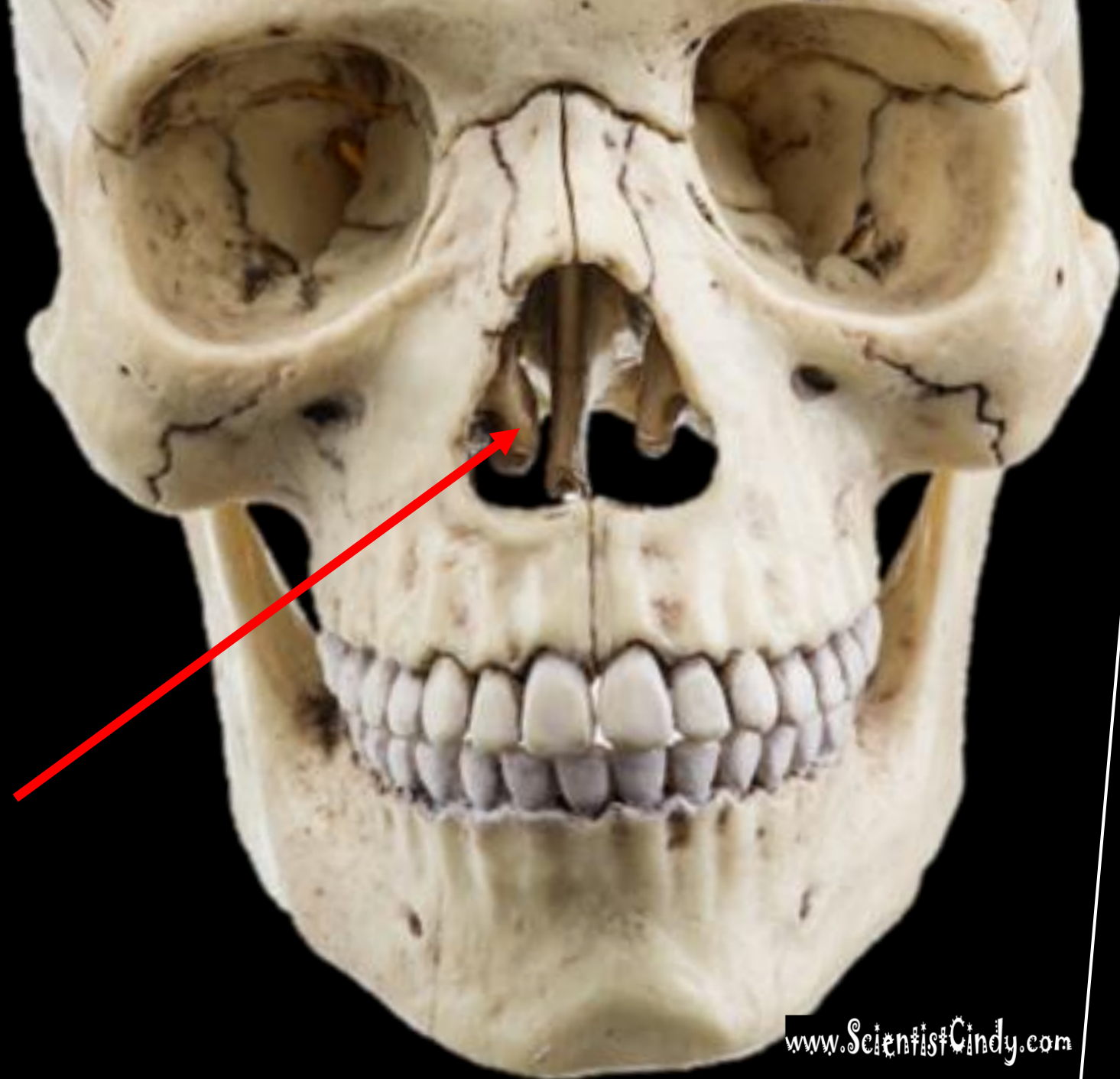
What is the structure?



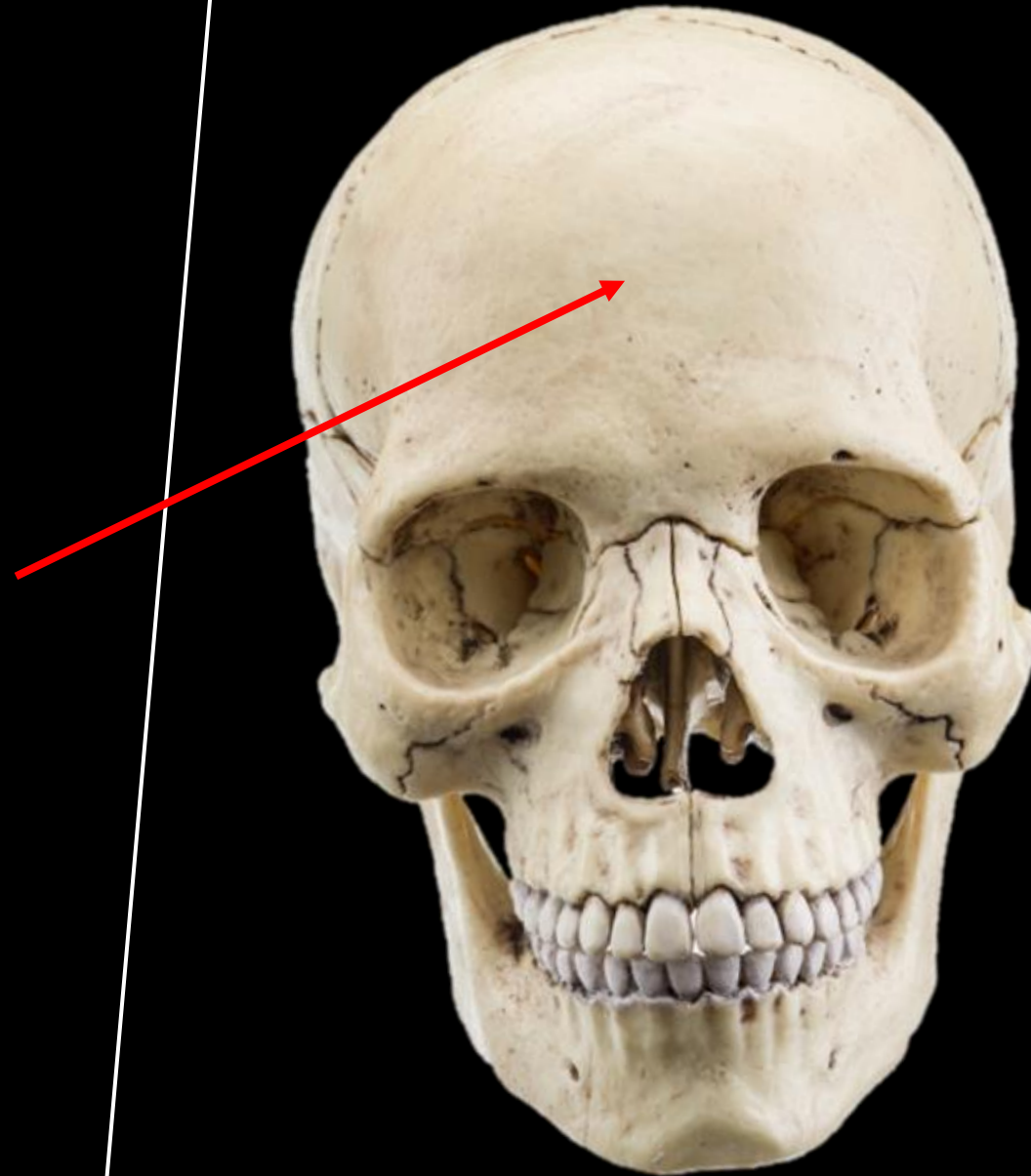
What is the bone?

What is the structure?

THE NASAL
CONCHA
(CONCHAE) OF
THE ETHMOID
BONE

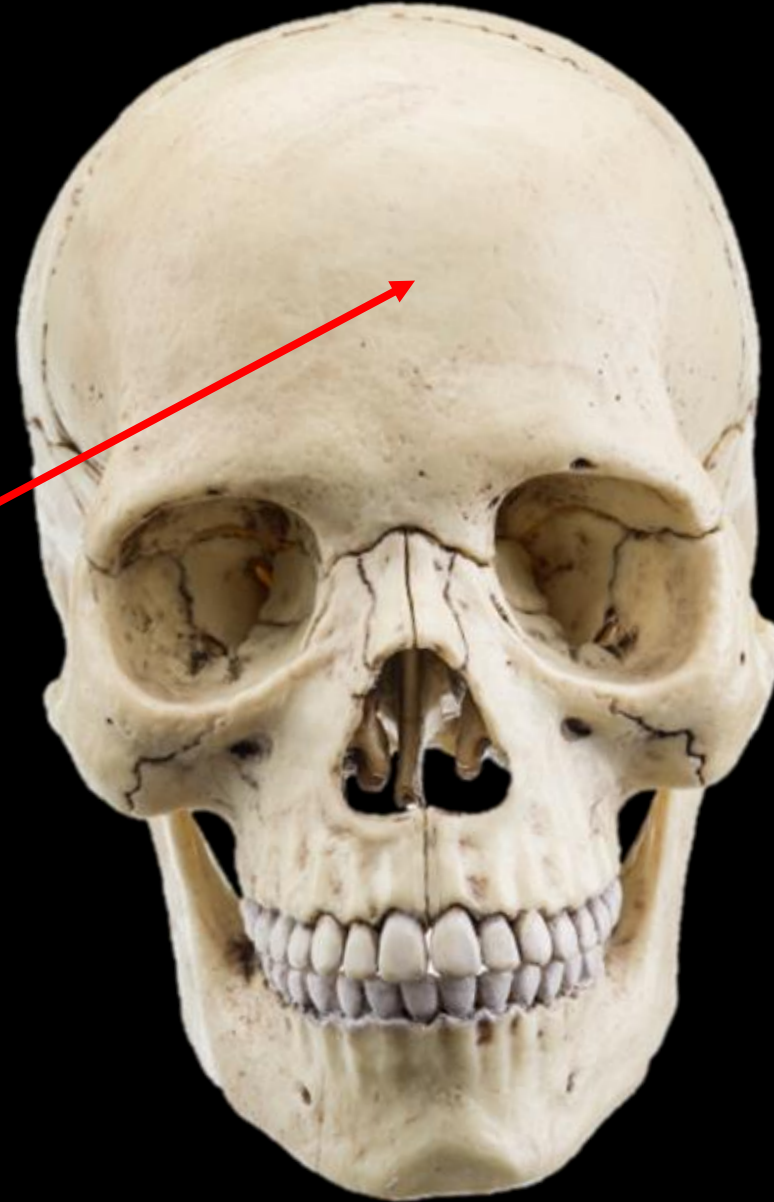

What is the bone?

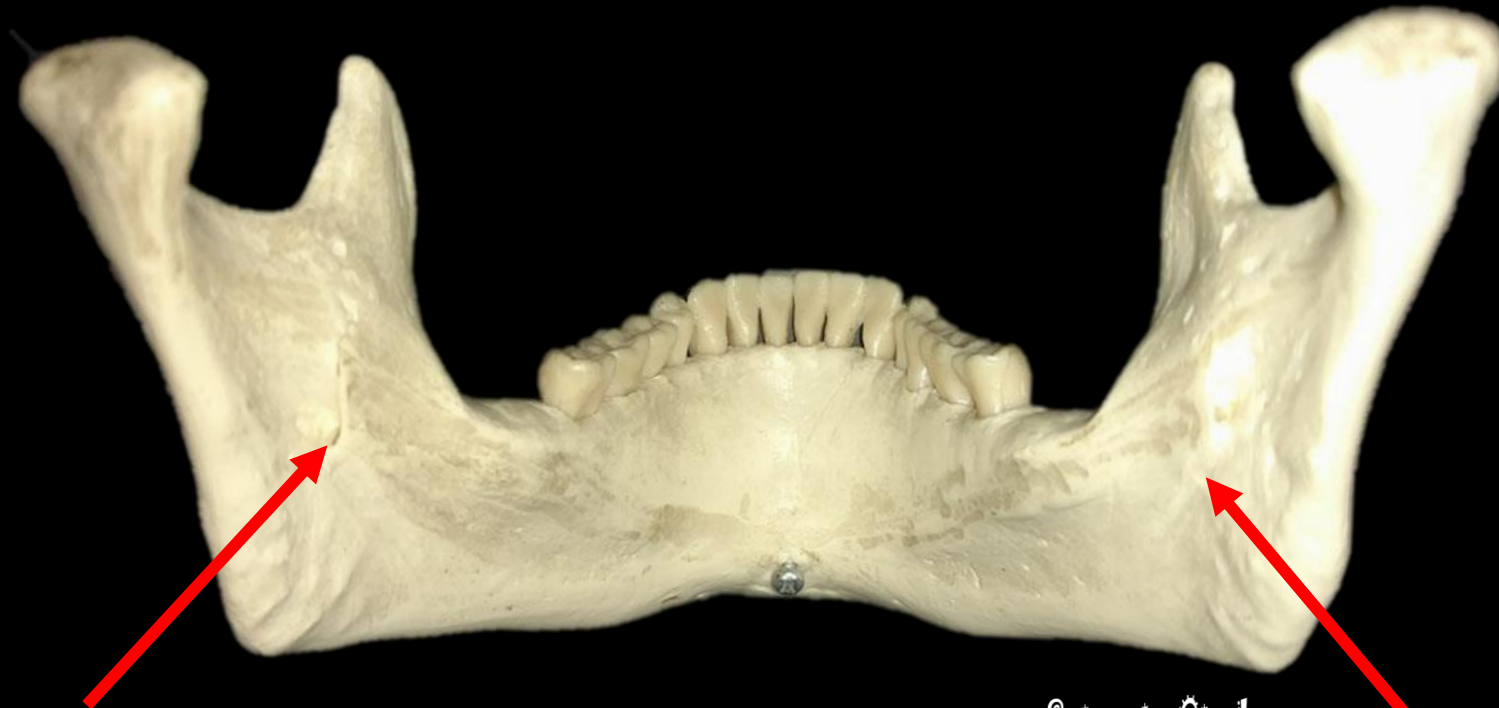


What is the bone?

FRONTAL BONE

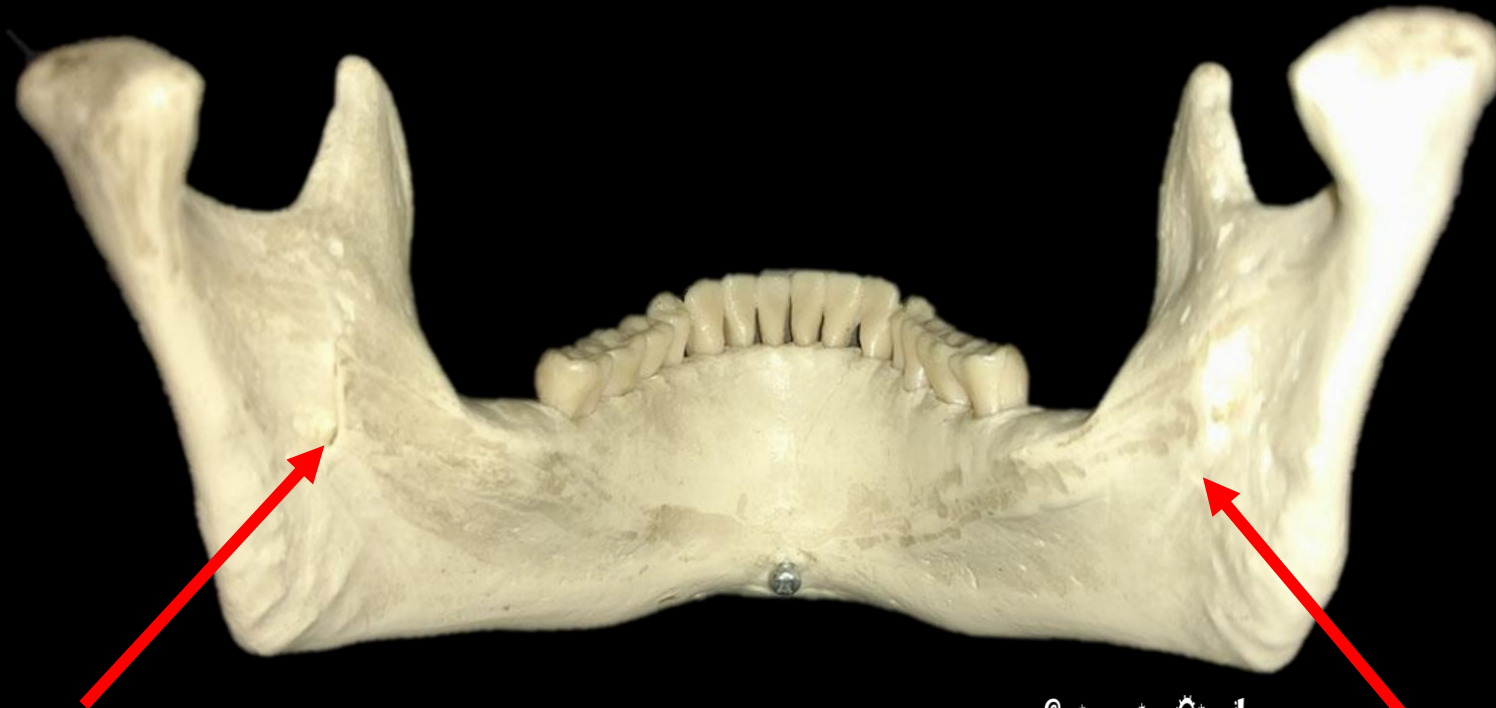


IDENTIFY THE BONE AND THE STRUCTURES.



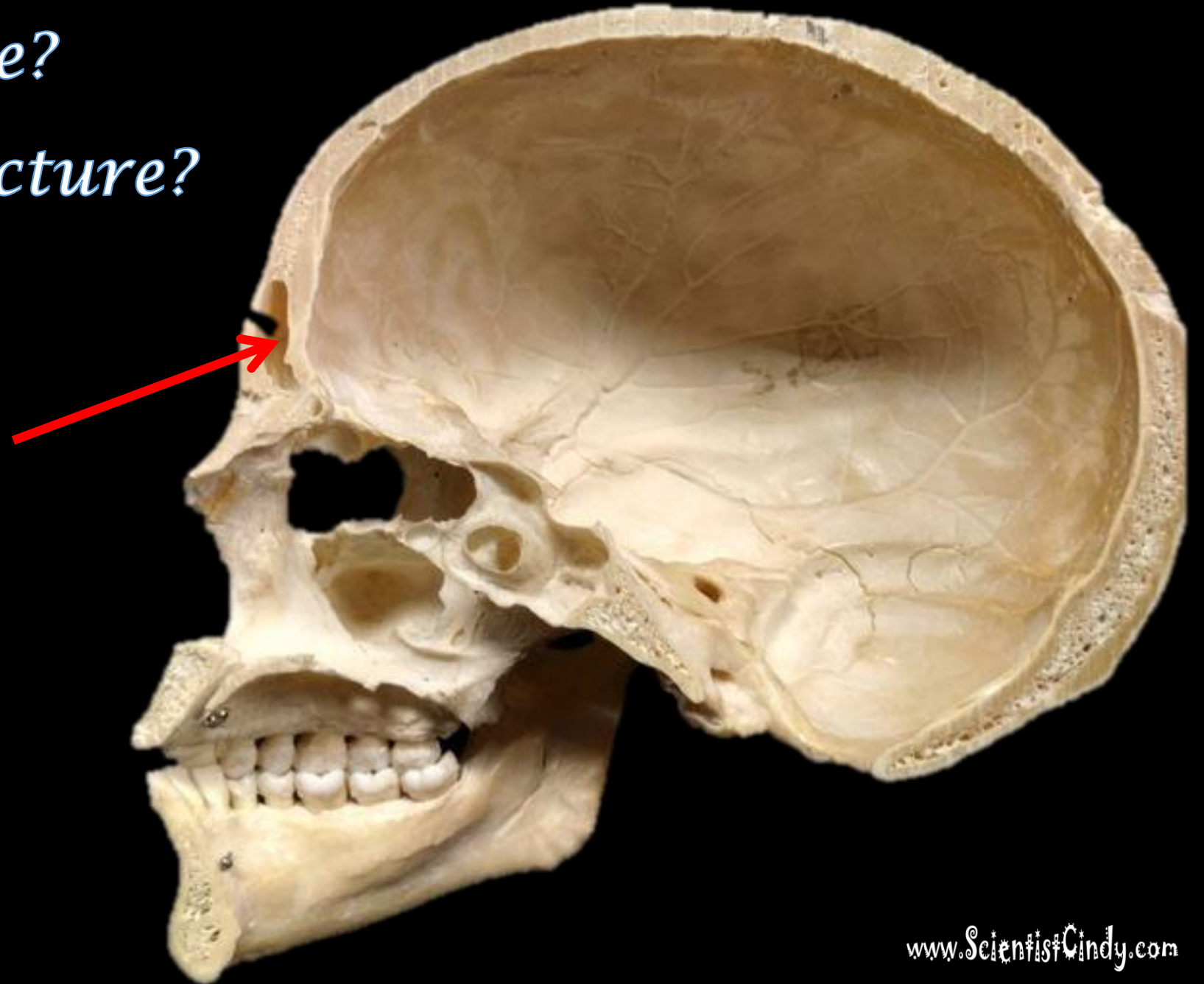
www.ScientistCindy.com

THE MANDIBULAR FORAMINA OF THE MANDIBLE (BONE)



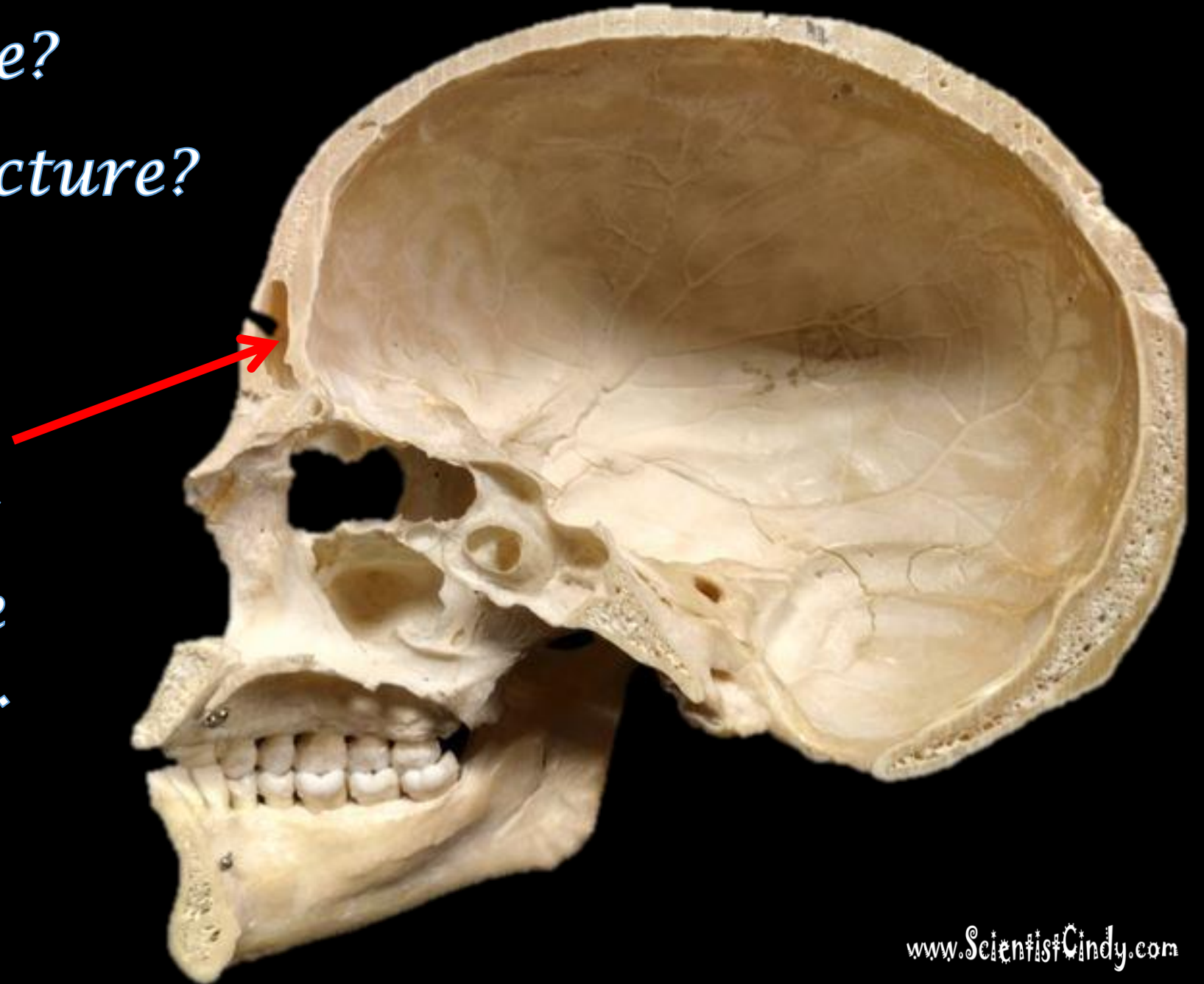
www.ScientistCindy.com

What is the Bone?
What is the Structure?

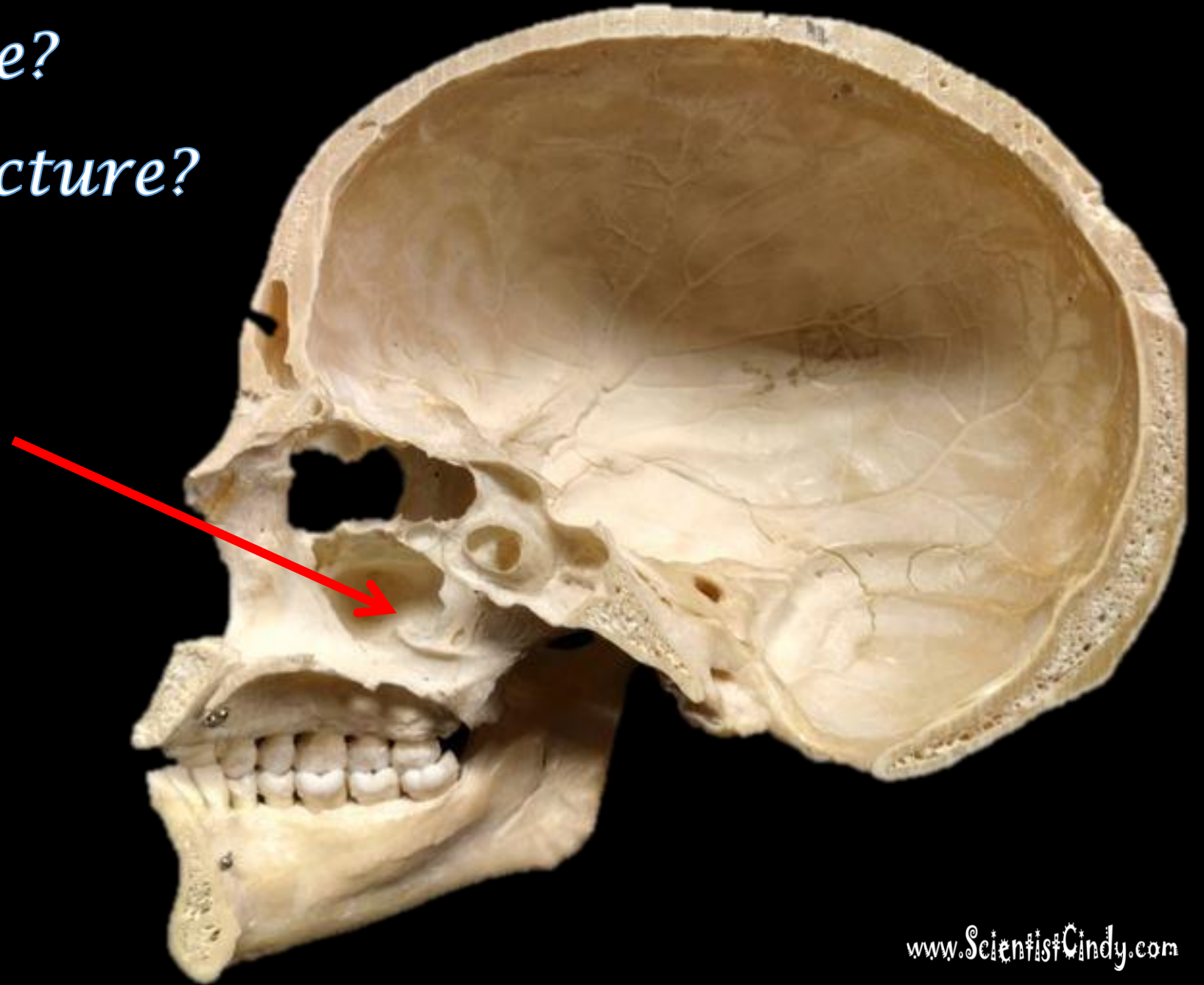


*What is the Bone?
What is the Structure?*

*The Frontal
Sinuses of the
Frontal Bone.*

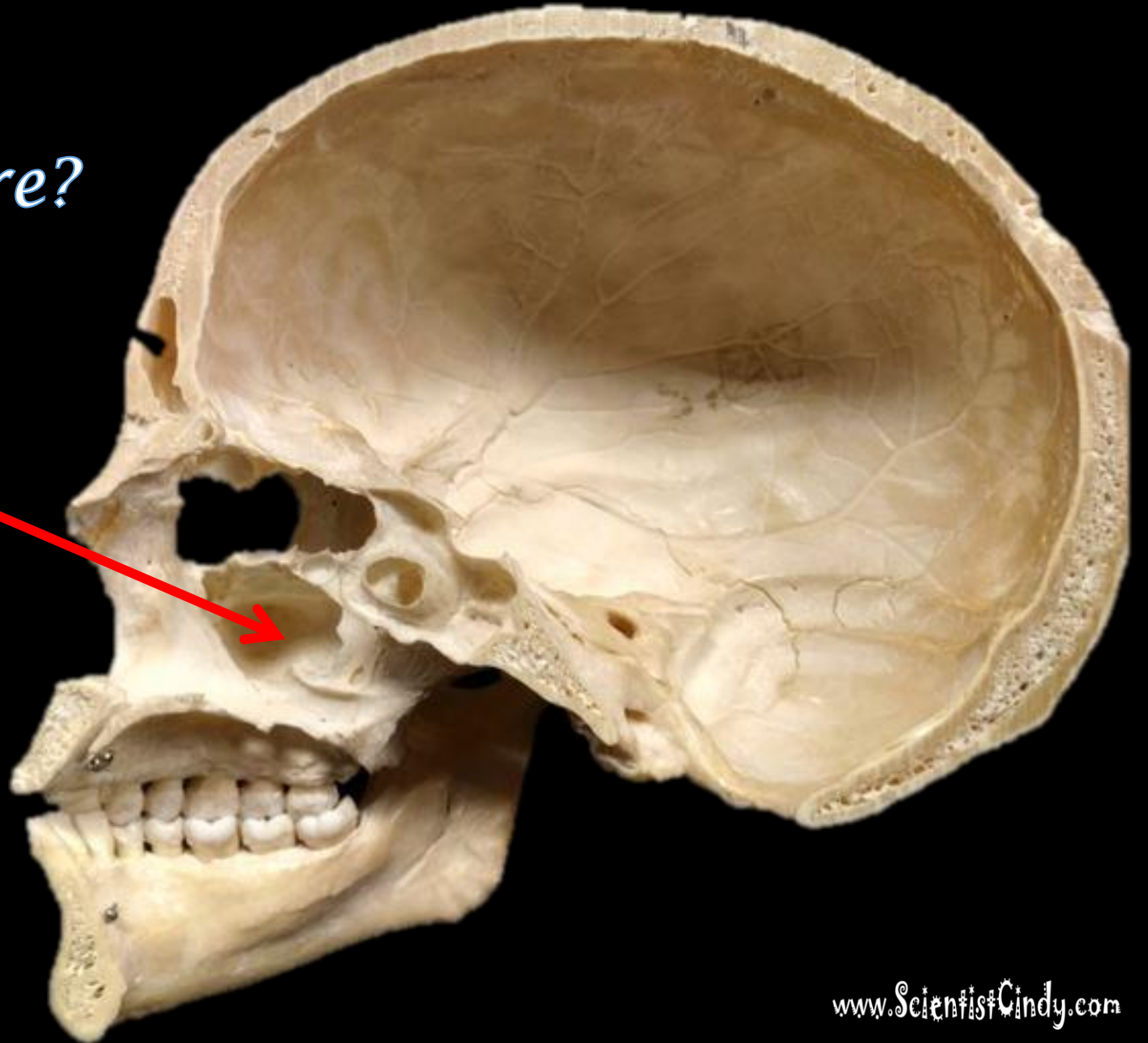


What is the Bone?
What is the Structure?

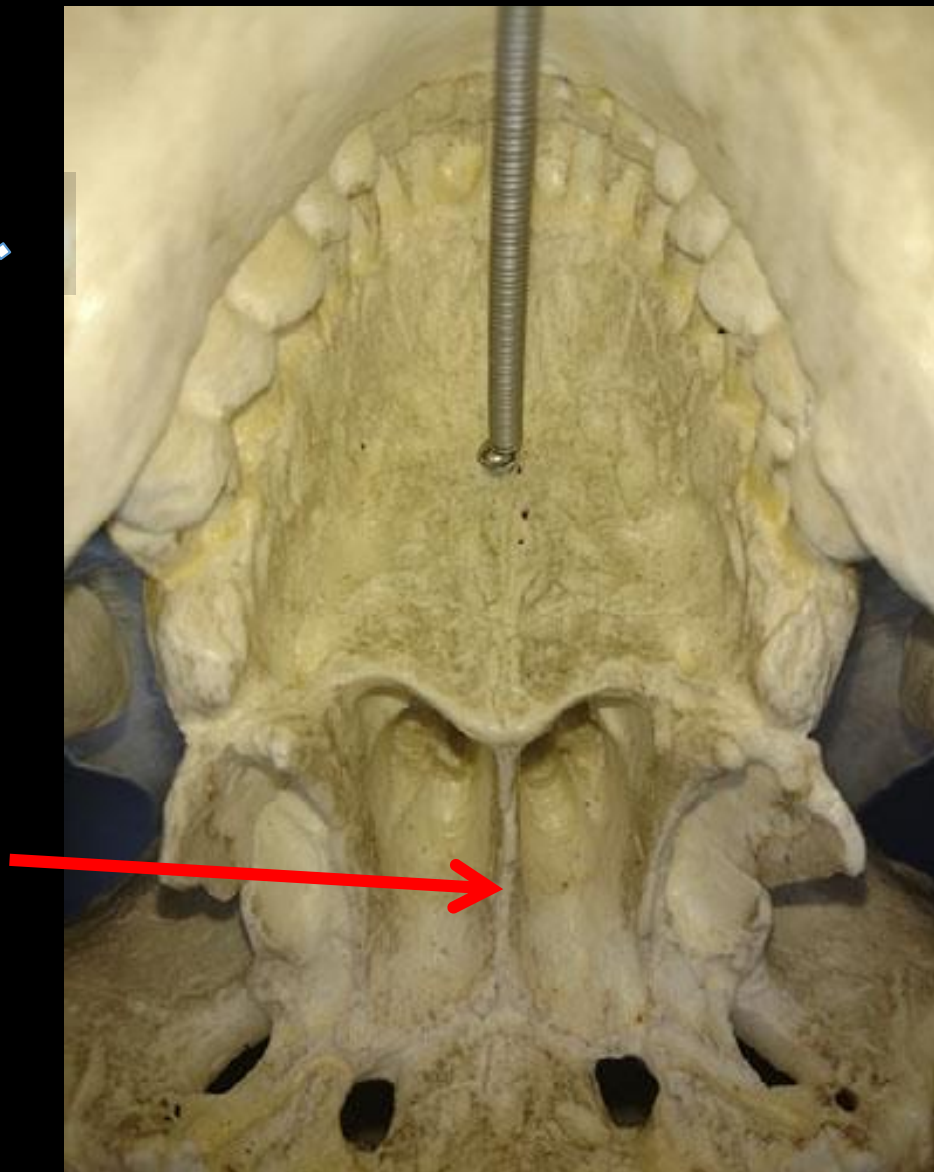


*What is the Bone?
What is the Structure?*

*The Maxillary
Sinuses of the
Maxilla (Bone).*

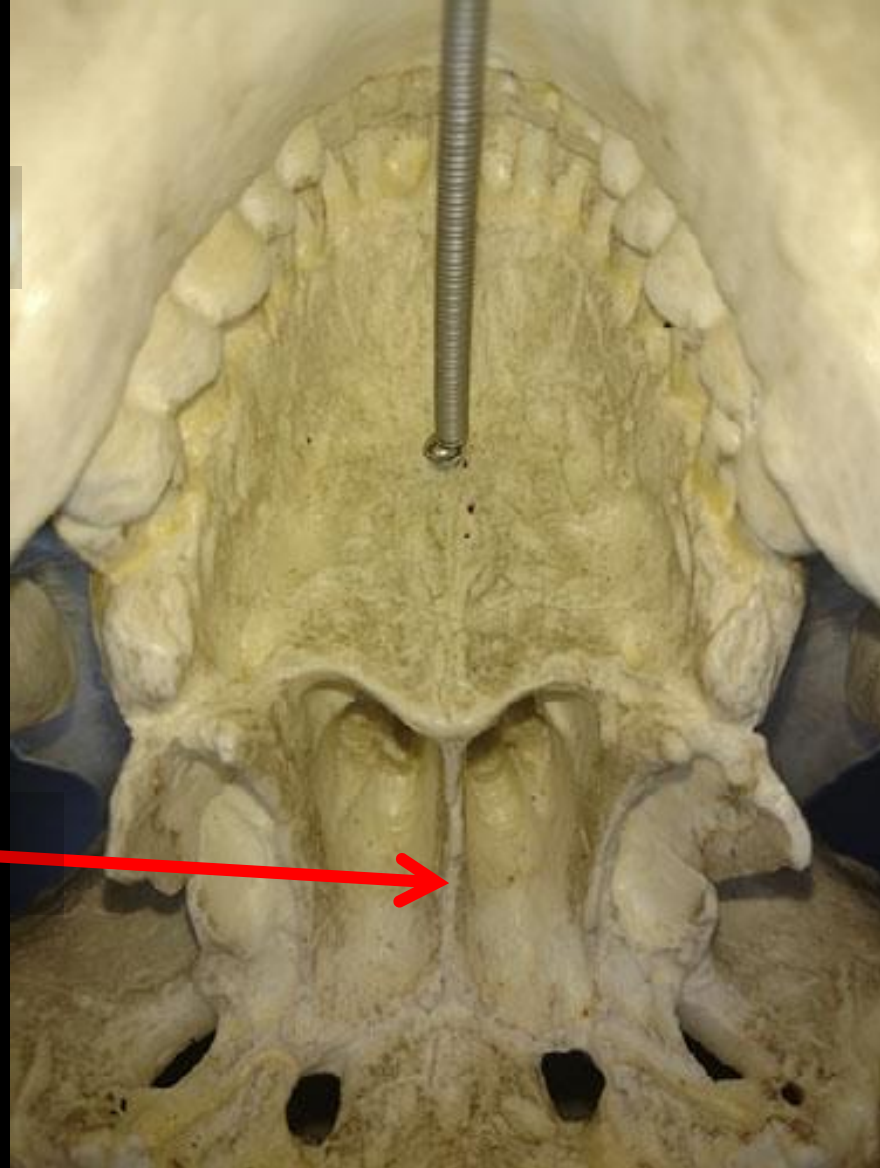


Name the Bone.

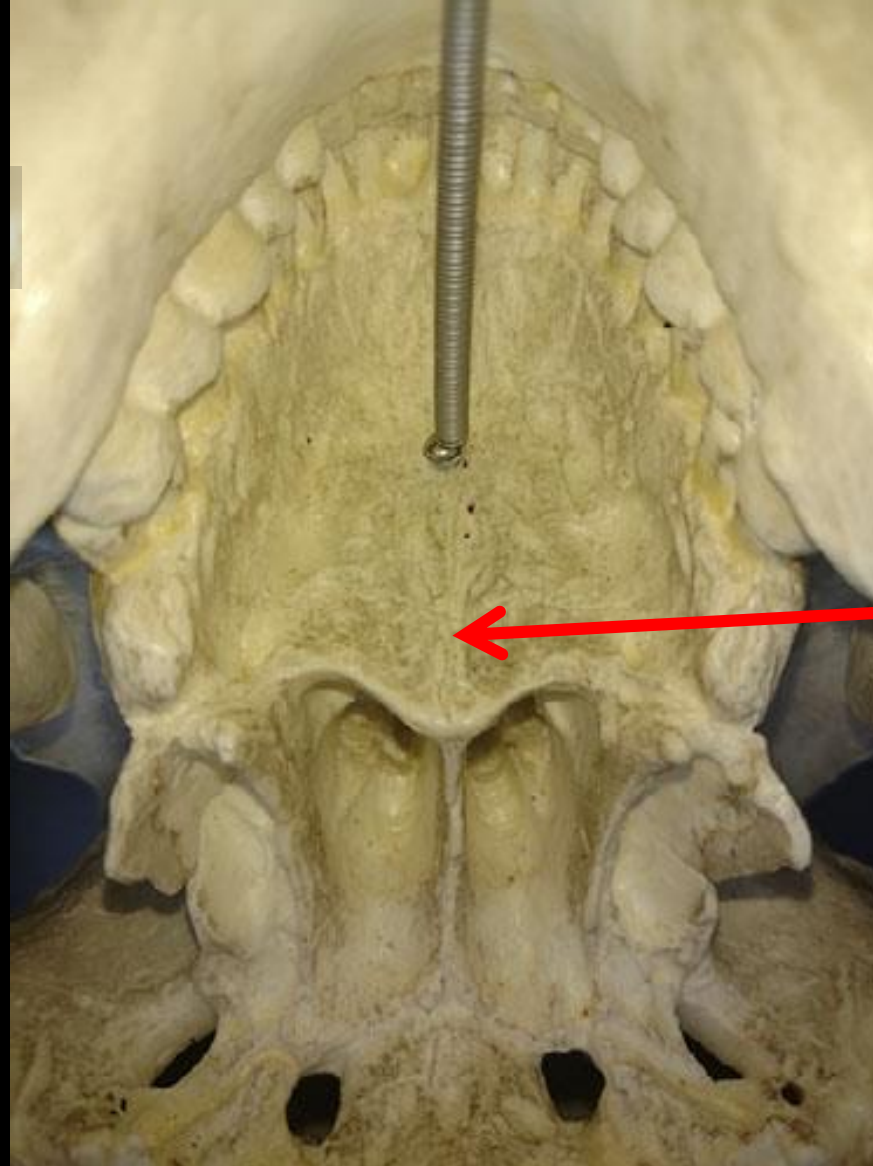


Name the Bone.

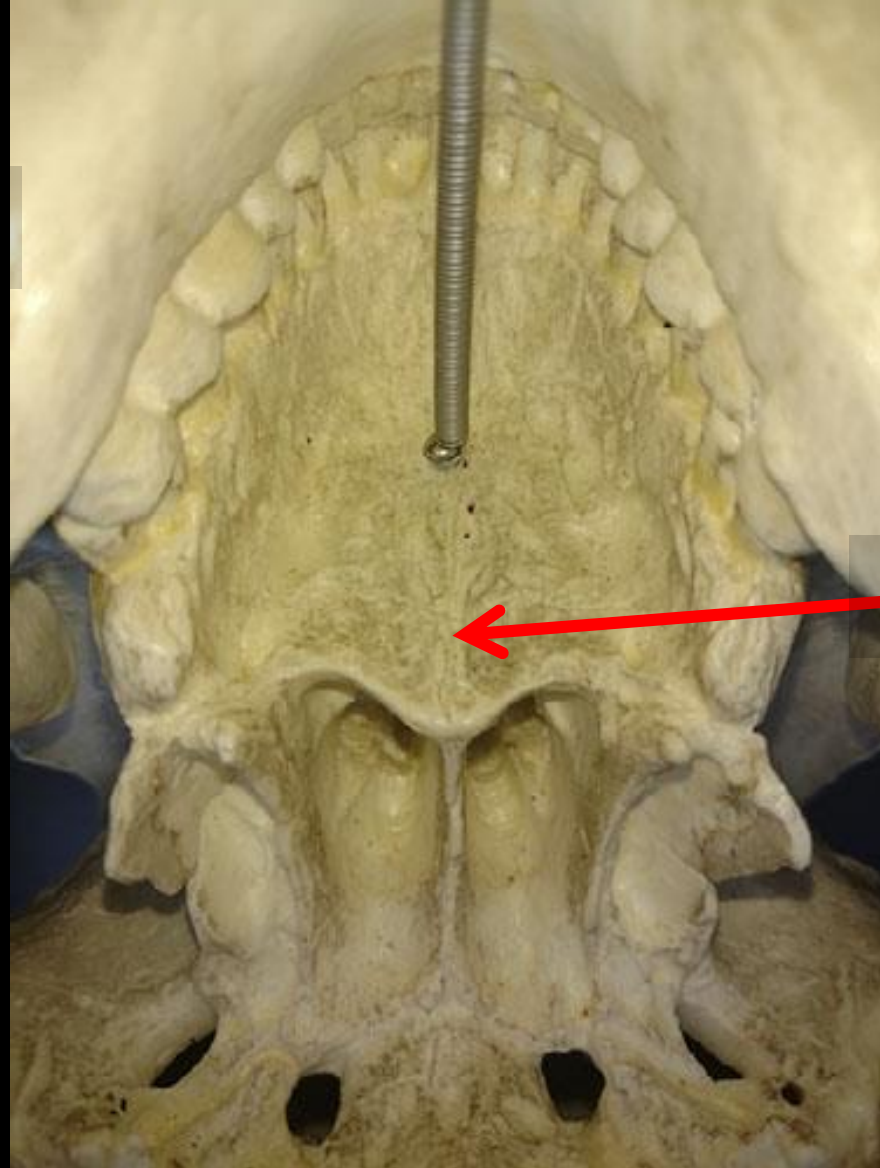
Vomer



Name the Bone.

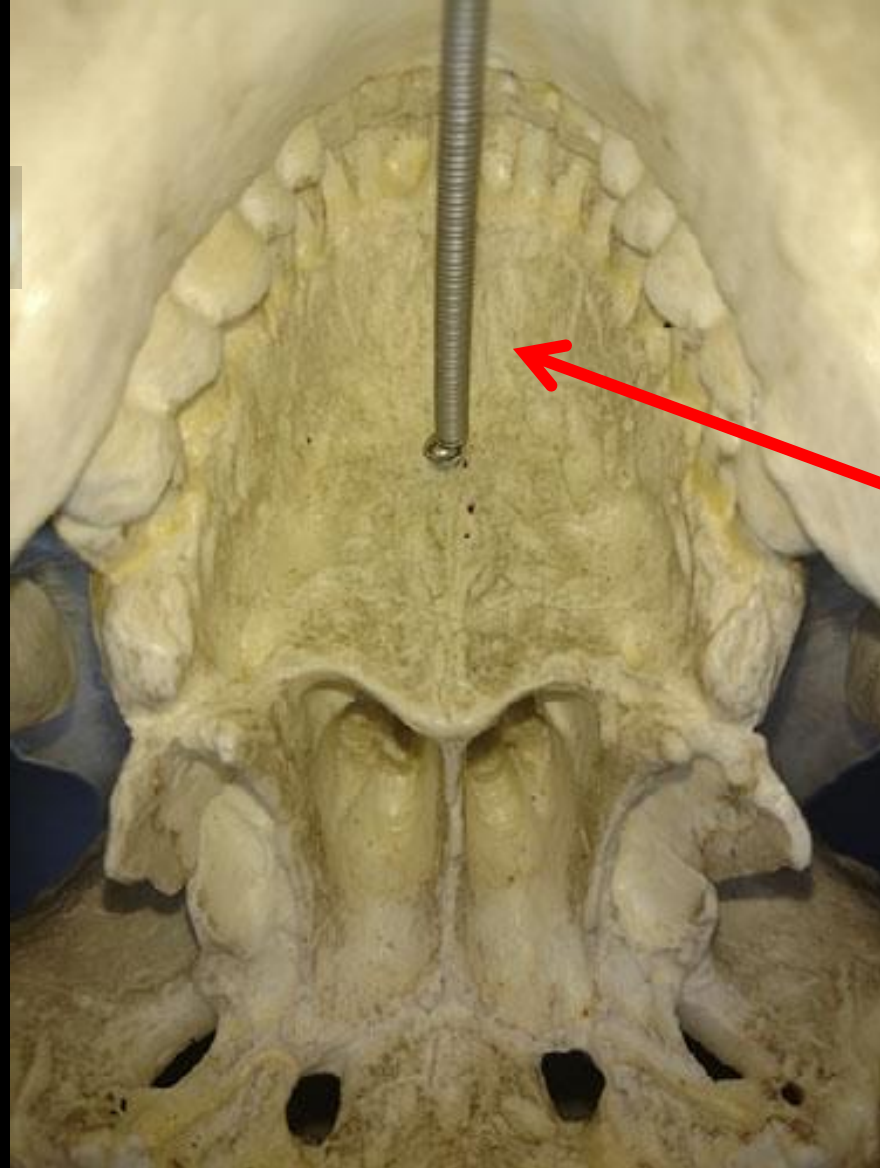


Name the Bone.

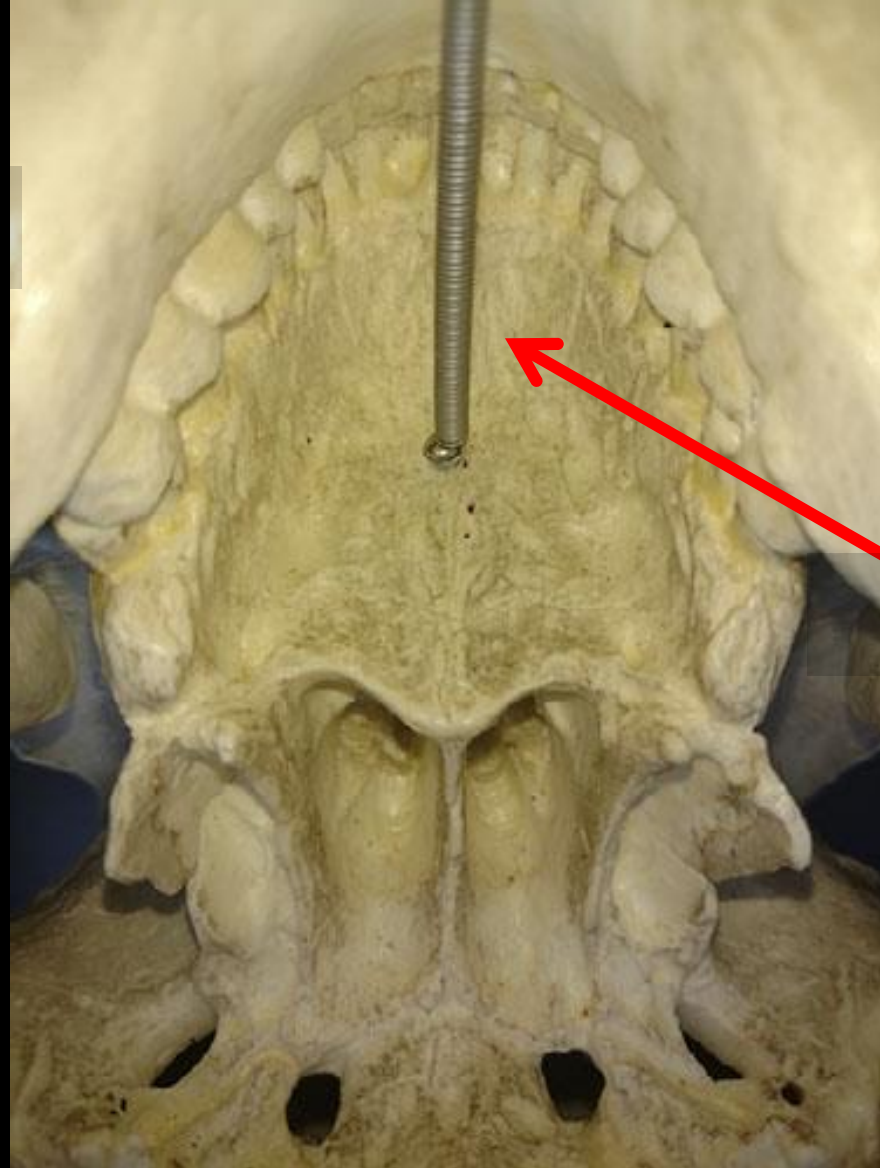


Palatine Bone

Name the Bone.

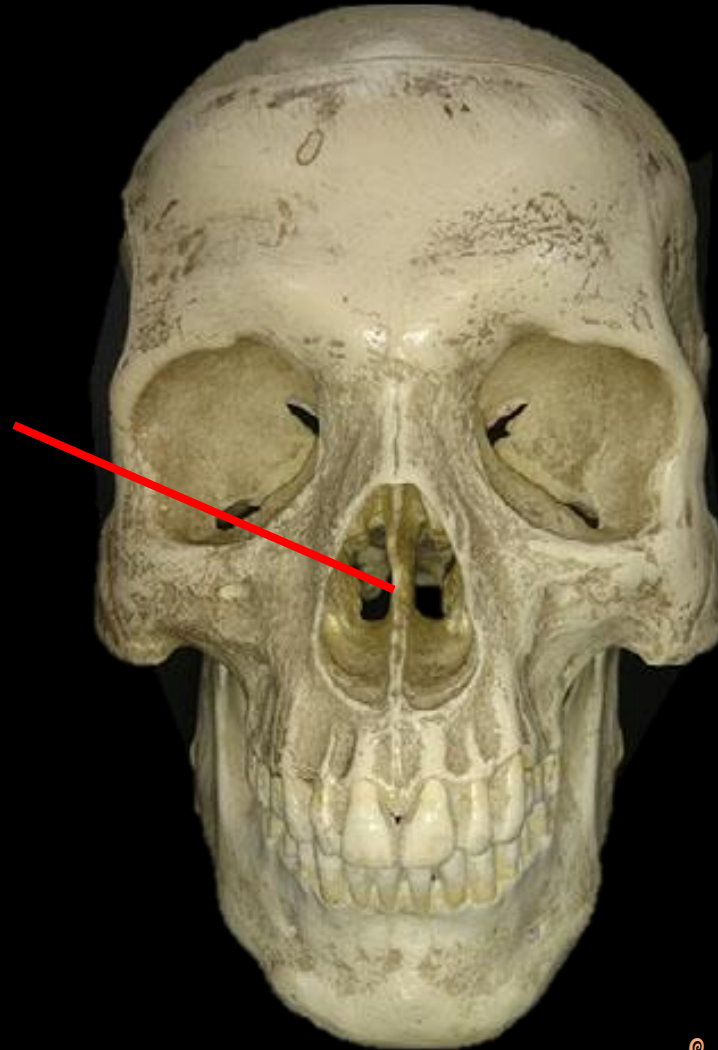


Name the Bone.

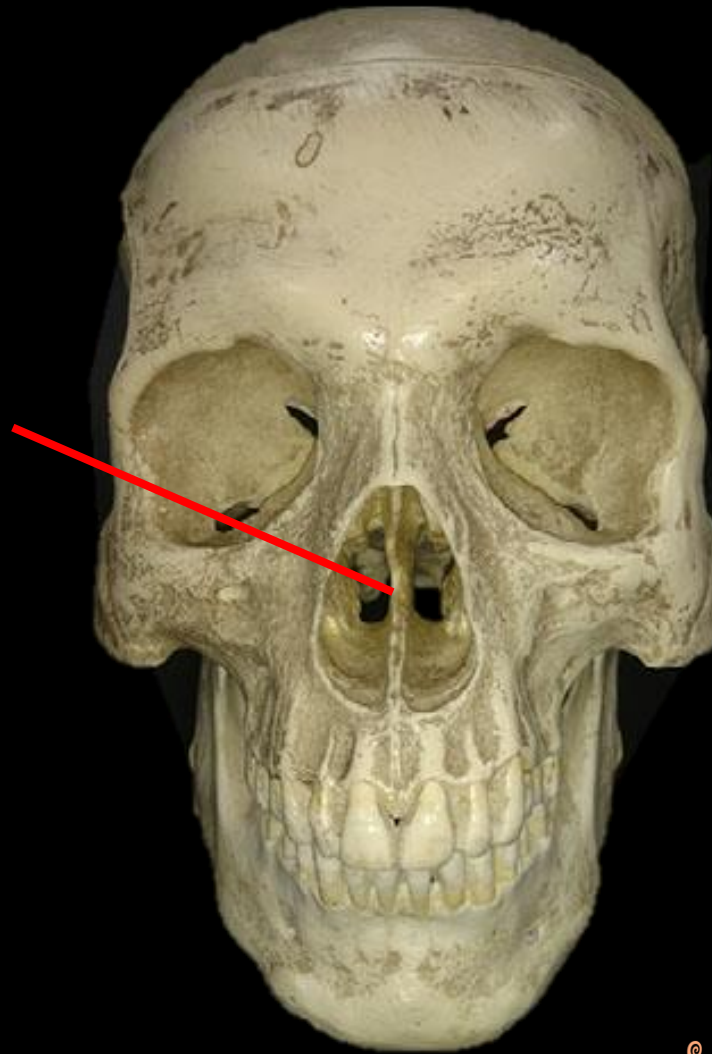


Maxilla

Name The Bone. Name the Structure.

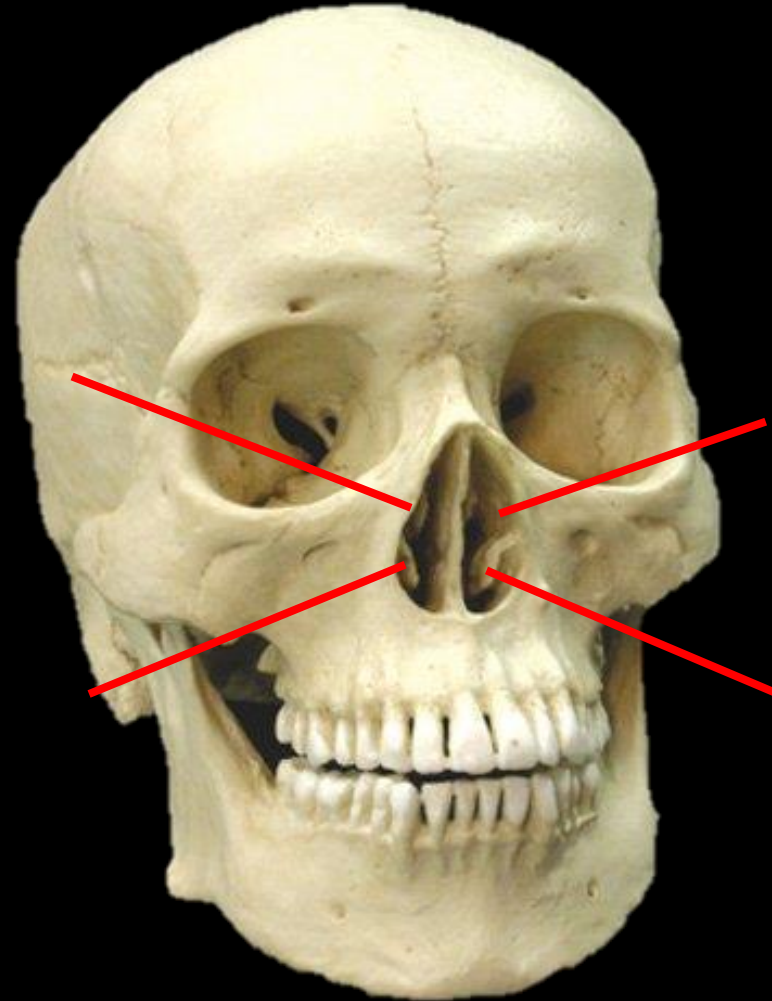
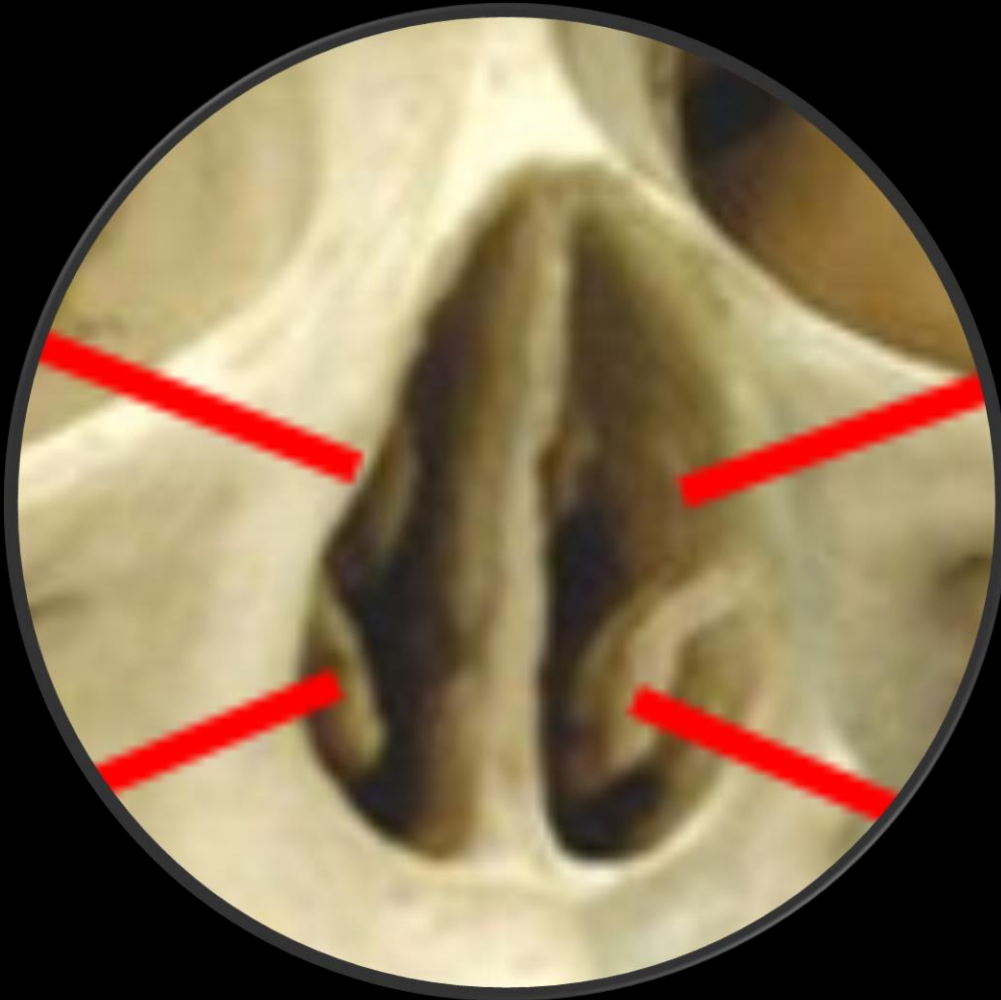

*The
Perpendicular
Plate of the
Ethmoid Bone*



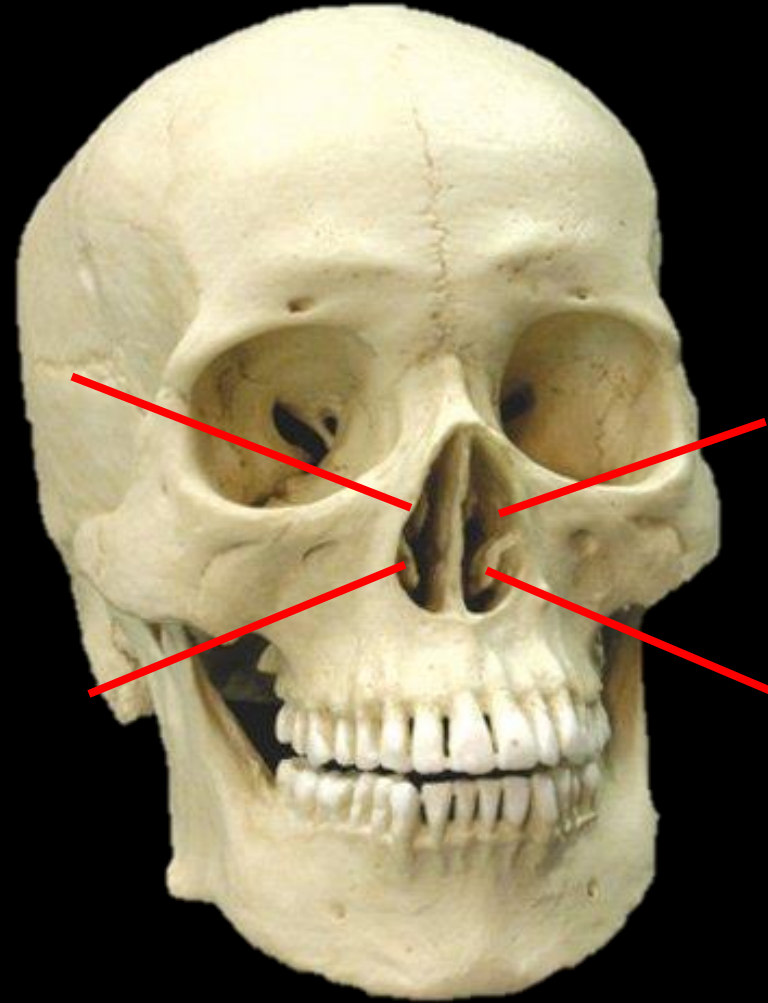
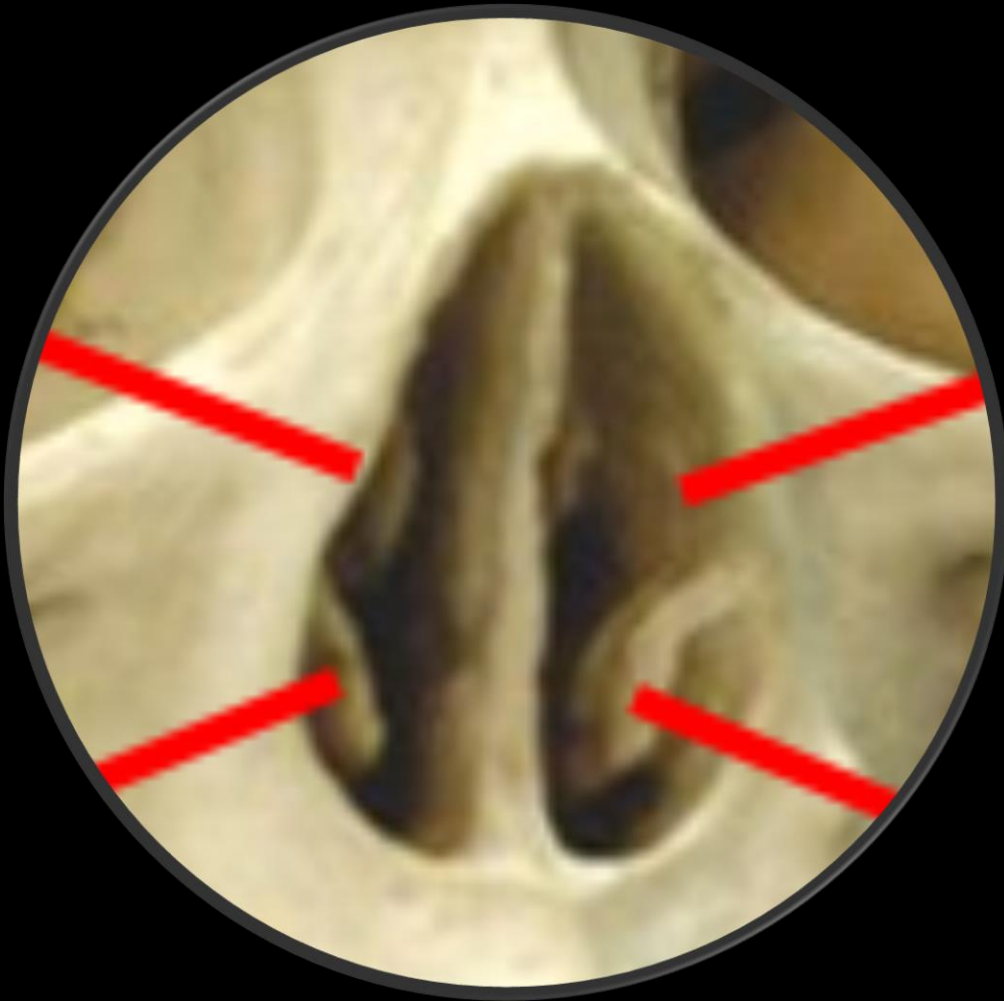Name the Bone and the Structure.

Close Up



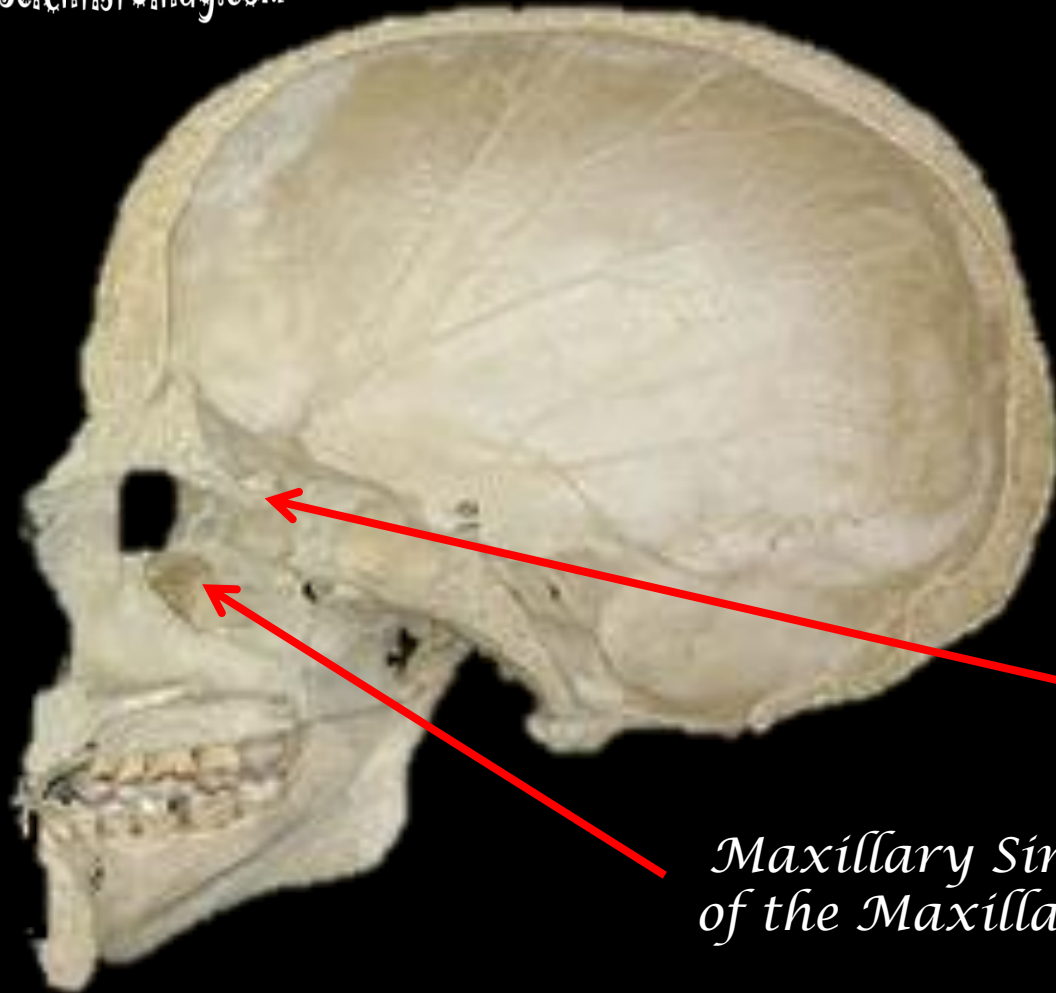
The Nasal Conchae of the Ethmoid Bone.

Close Up



Sinuses of the Sagittal Section of the Human Skull

www.ScientistCindy.com

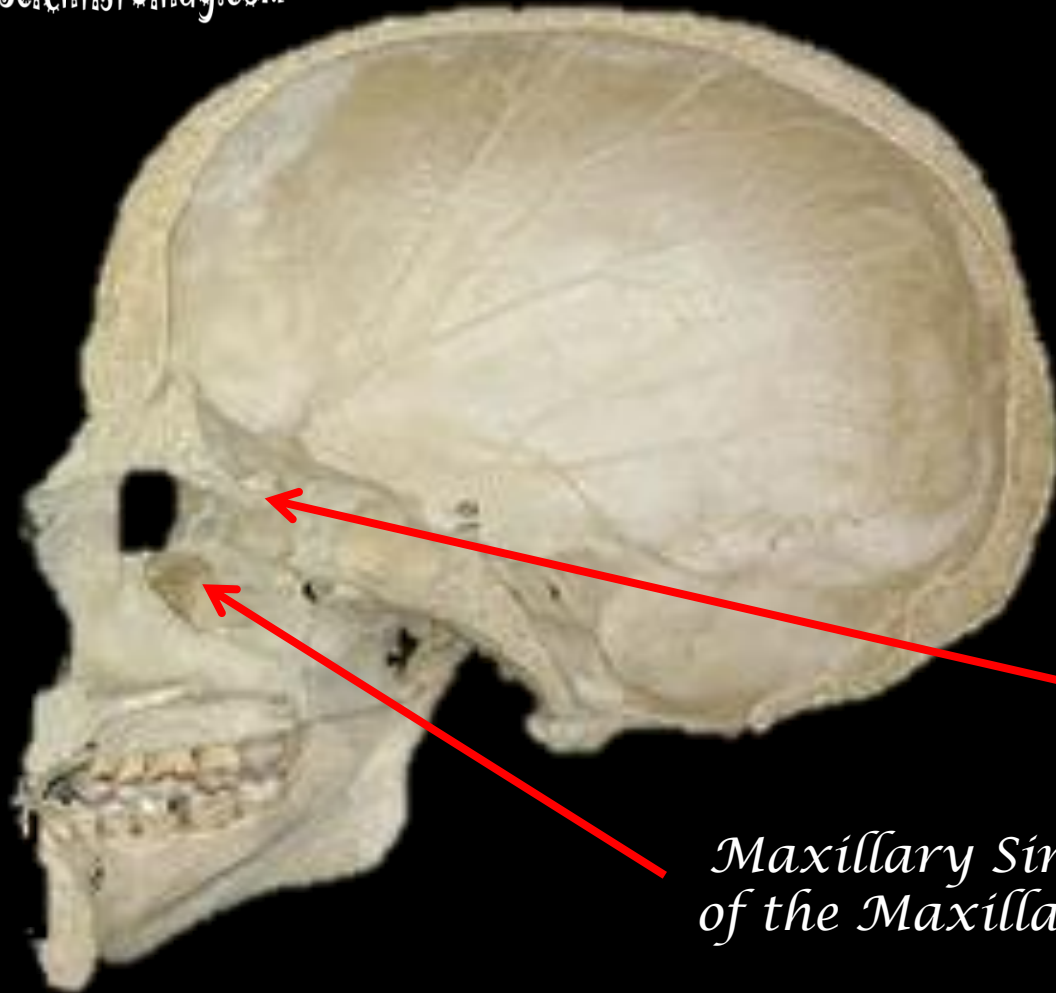


*Ethmoid Sinuses
of the Ethmoid Bone*

*Maxillary Sinuses
of the Maxilla Bone*

Sinuses of the Sagittal Section of the Human Skull

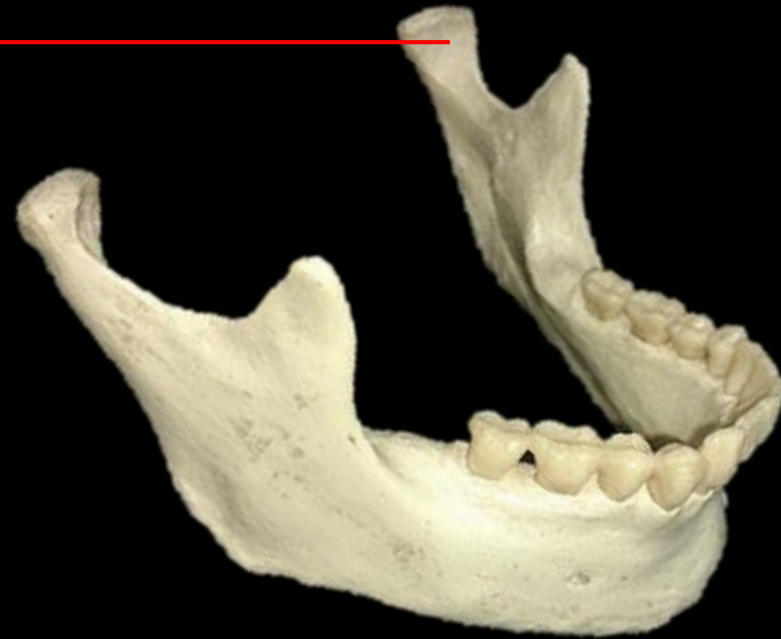www.ScientistCindy.com



*Ethmoid Sinuses
of the Ethmoid Bone*

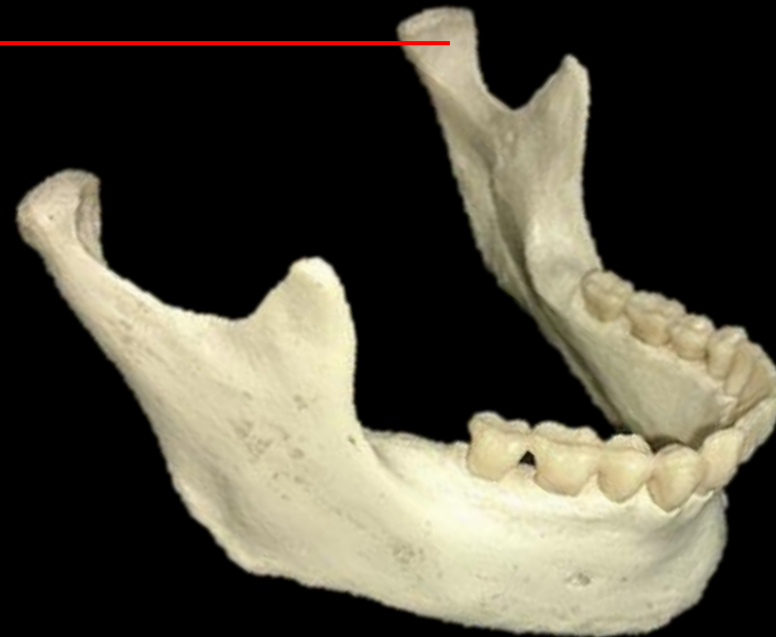*Maxillary Sinuses
of the Maxilla Bone*

What is the Bone and the Structure?

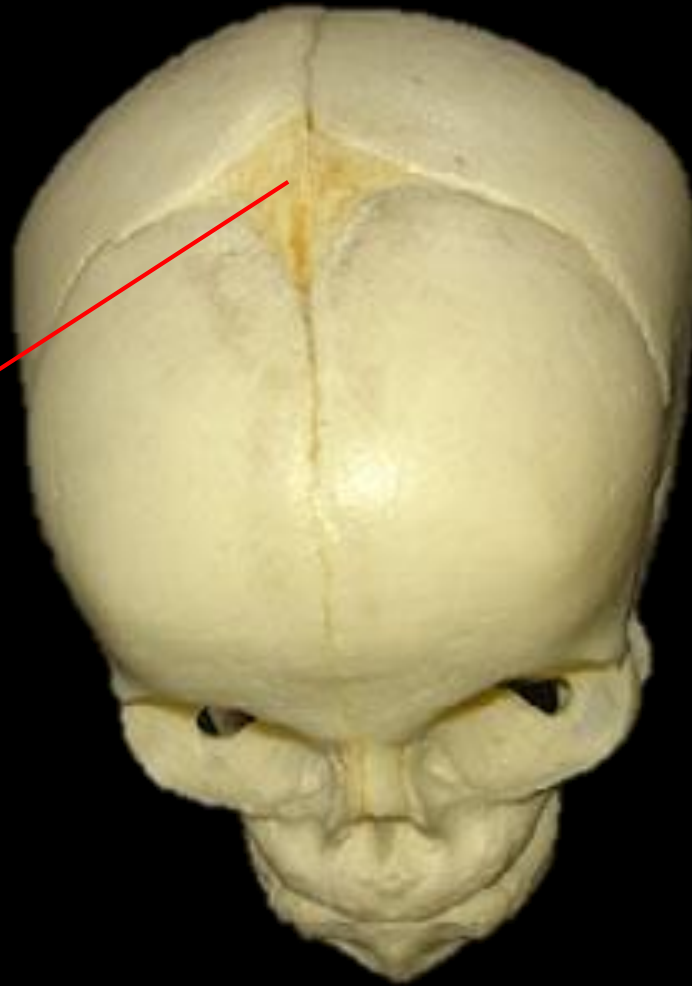

What is the Bone and the Structure?

The Mandibular
Condyle of the
Mandible (Bone).

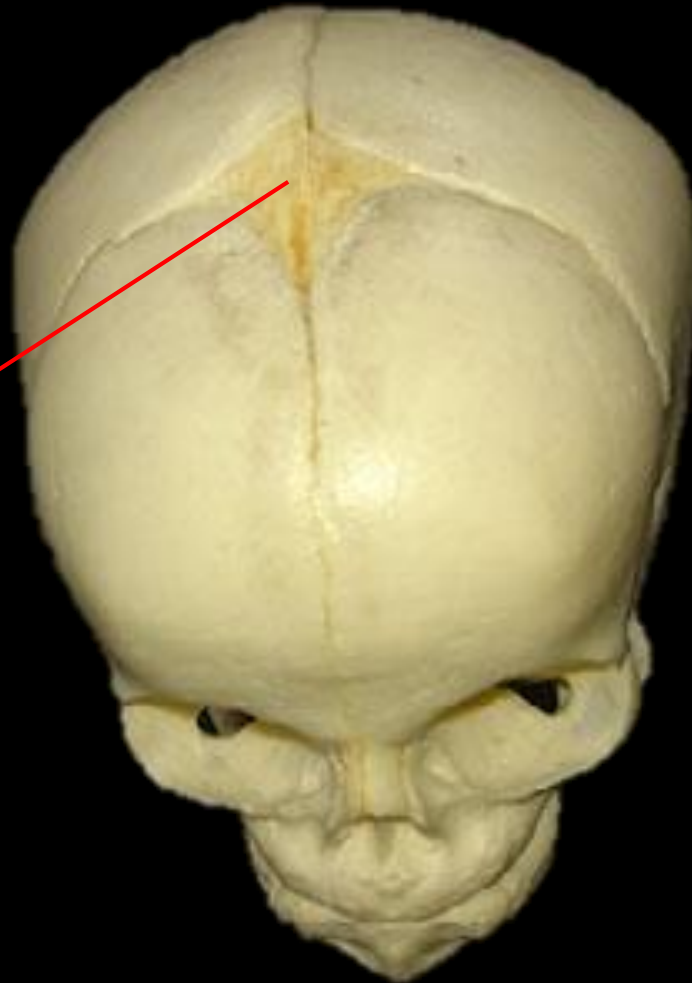

Fetal Skull



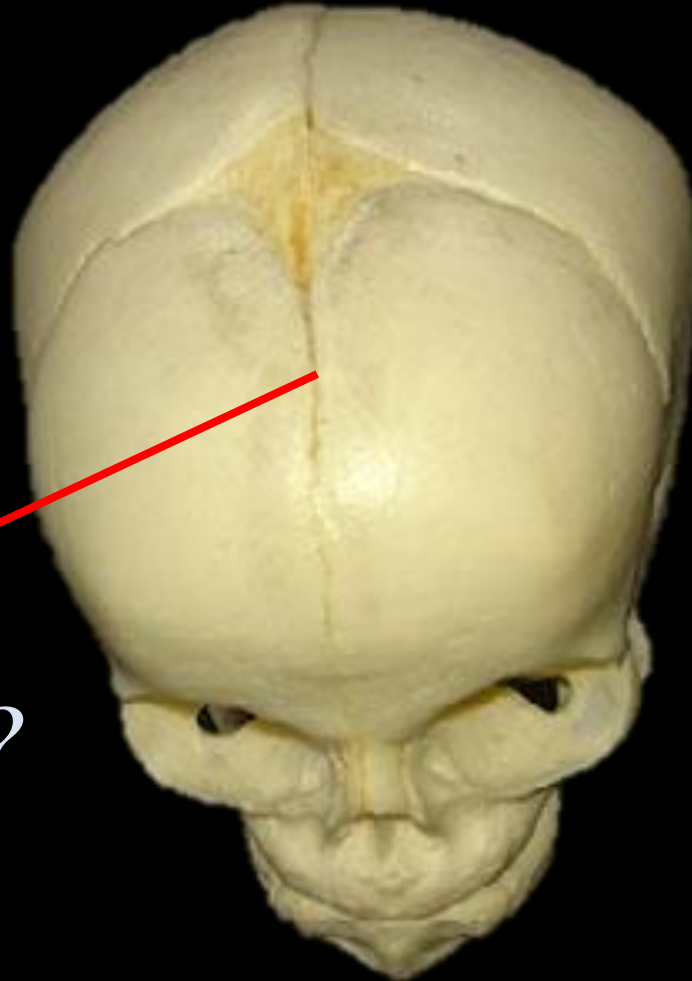
What is this?

Fetal Skull



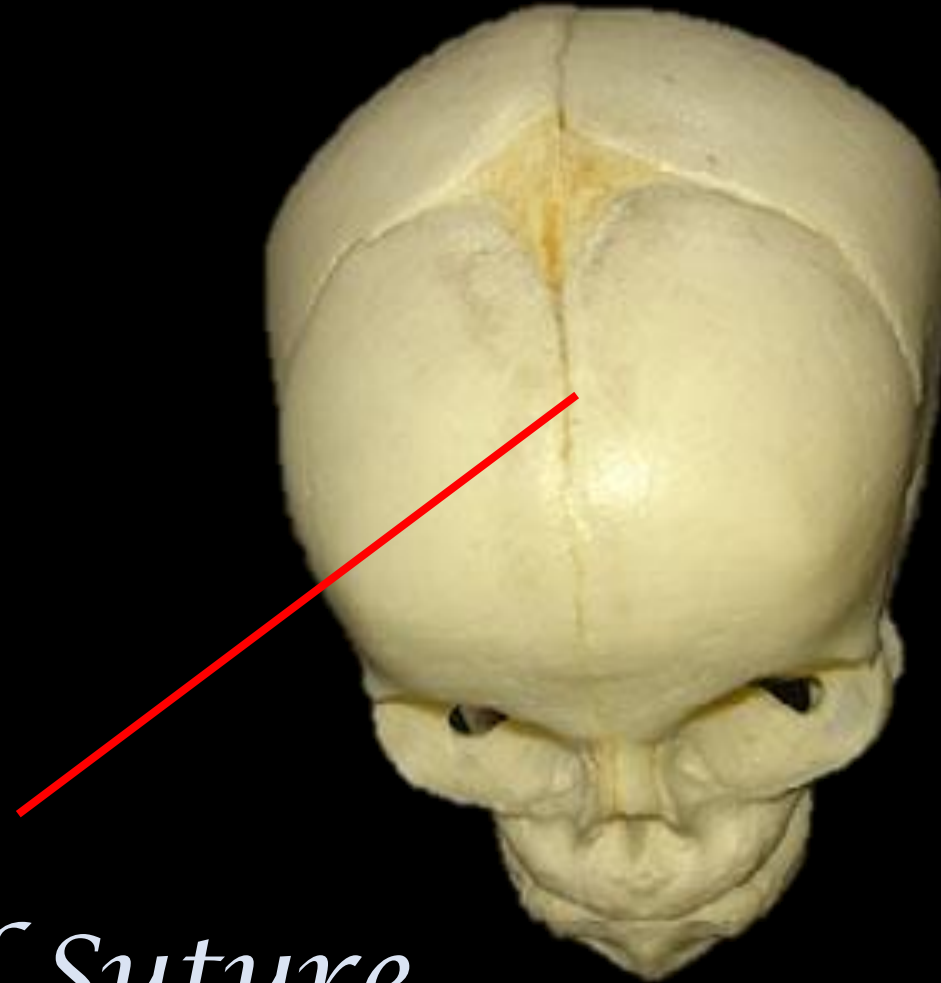
*Anterior
Fontanelle*

Fetal Skull



What is this?

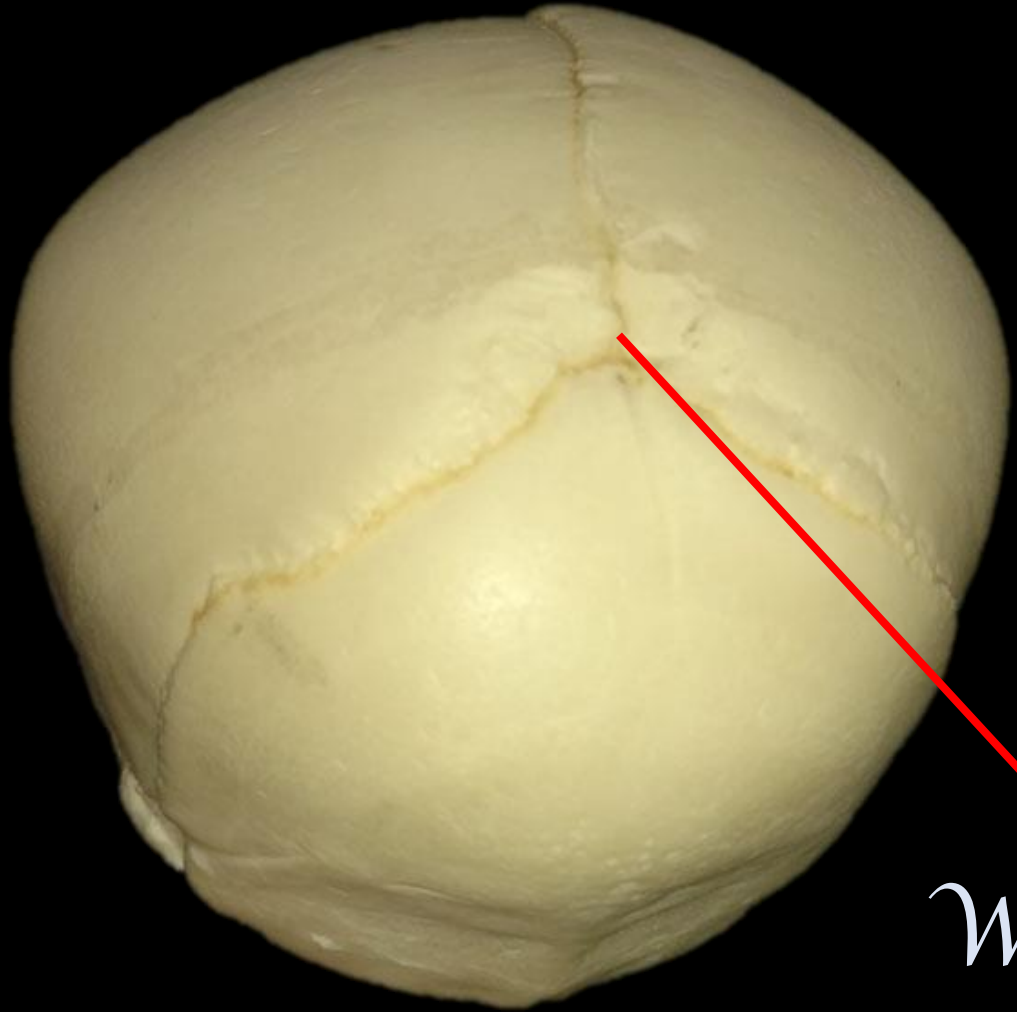
Fetal Skull



Frontal Suture

Fetal Skull

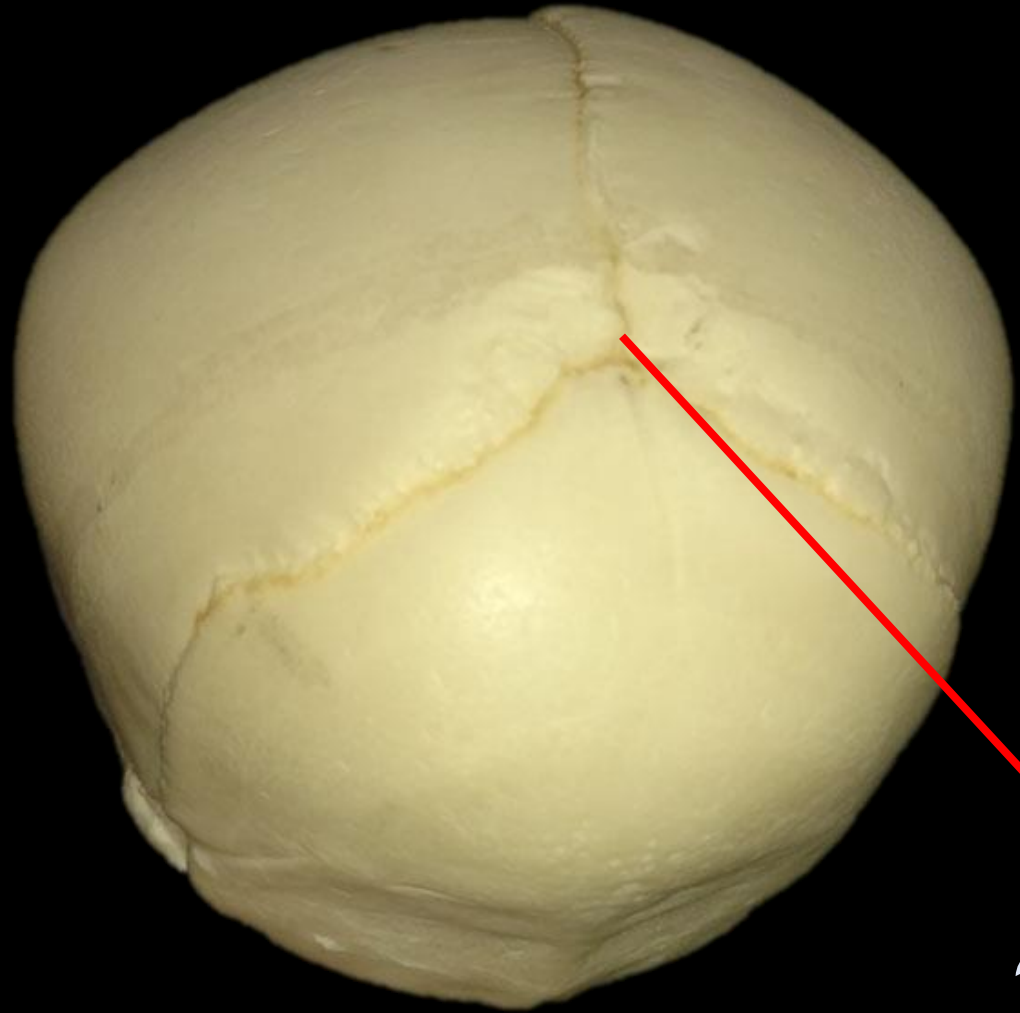
www.ScientistCindy.com



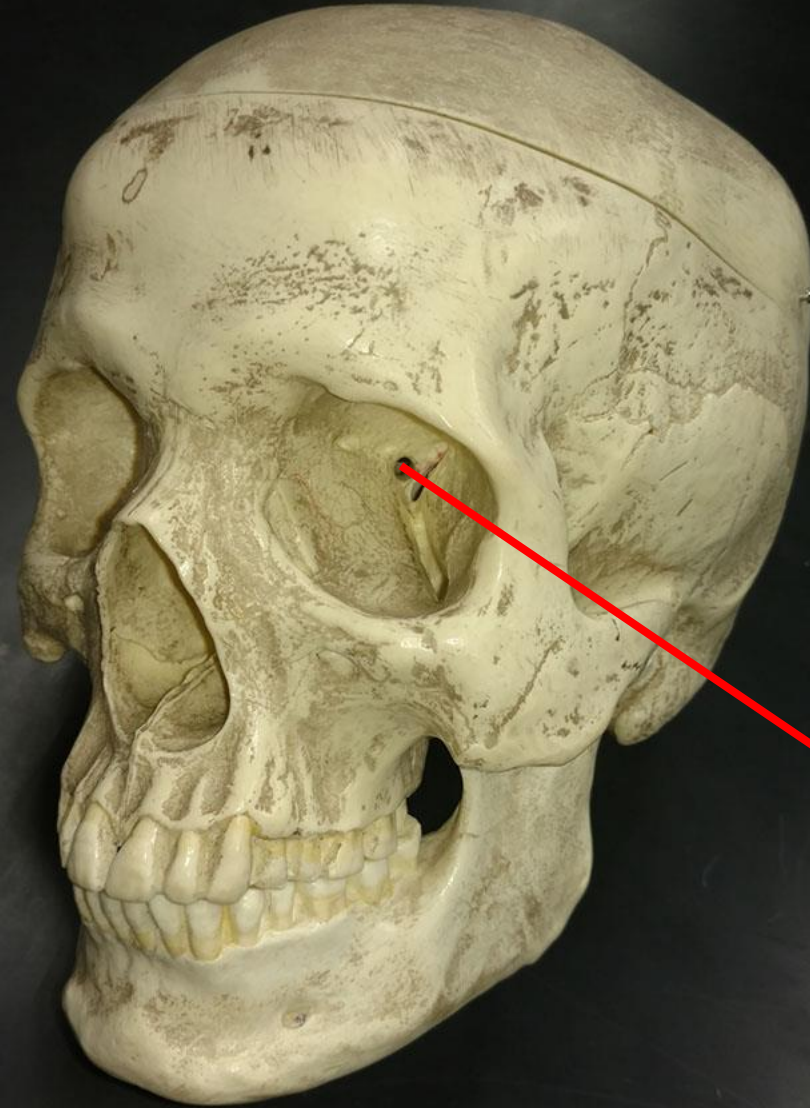
What is This?

Fetal Skull

www.ScientistCindy.com

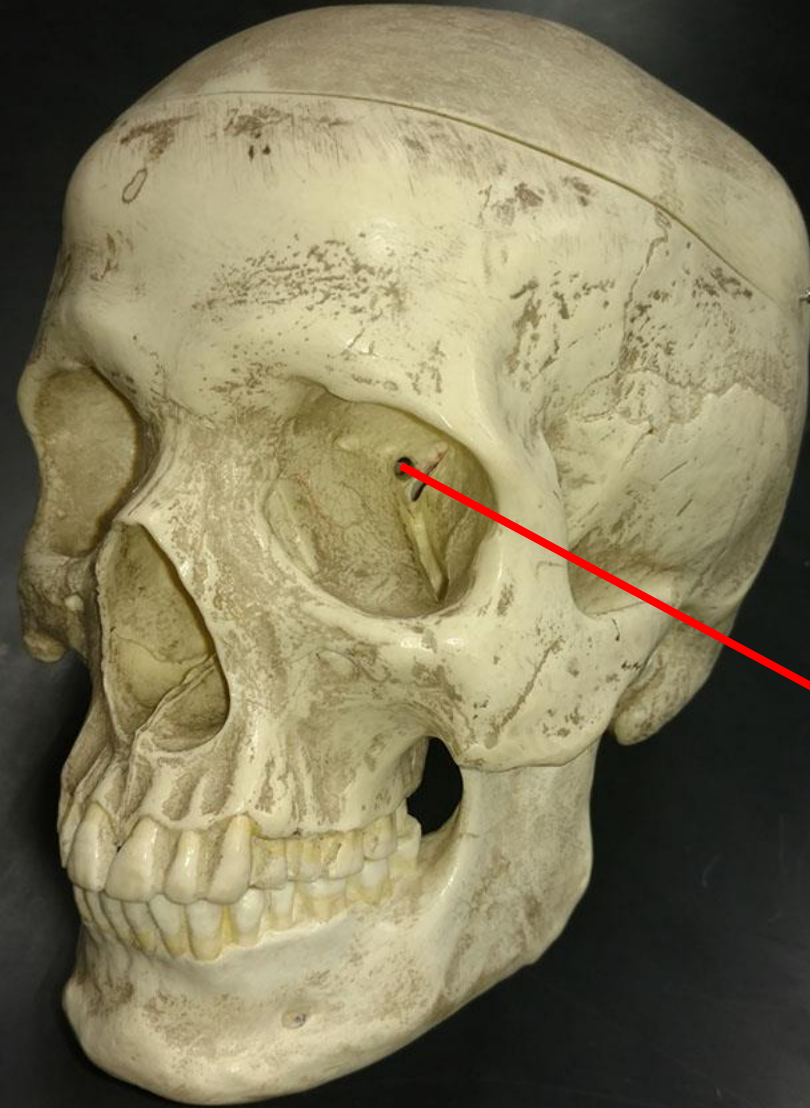


*Posterior
Fontanelle*



*What is the
Bone?*

*What is the
Structure?*



*Optic Foramen
of the
Sphenoid Bone*