



Practical Exam #2
REDEMPTION EXAM

Bones Practical Exam

What is the LEVEL of
the VERTEBRAE?

Thoracic

Axis

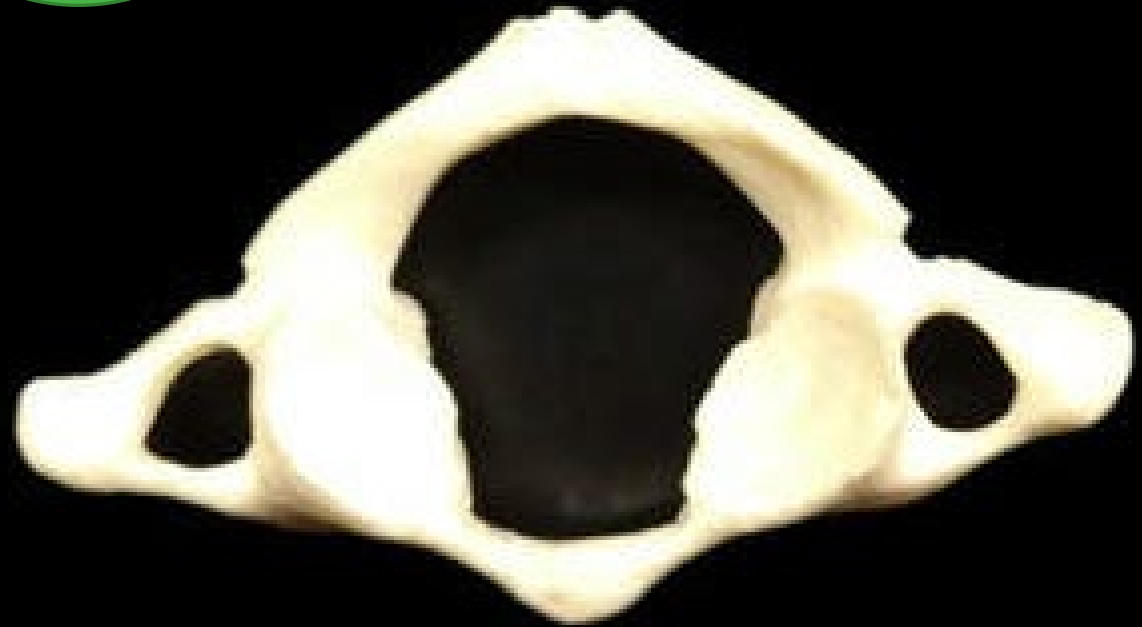Atlas

Cervical

Lumbar

Question

1



What is the LEVEL of
the VERTEBRAE?

Thoracic

Axis

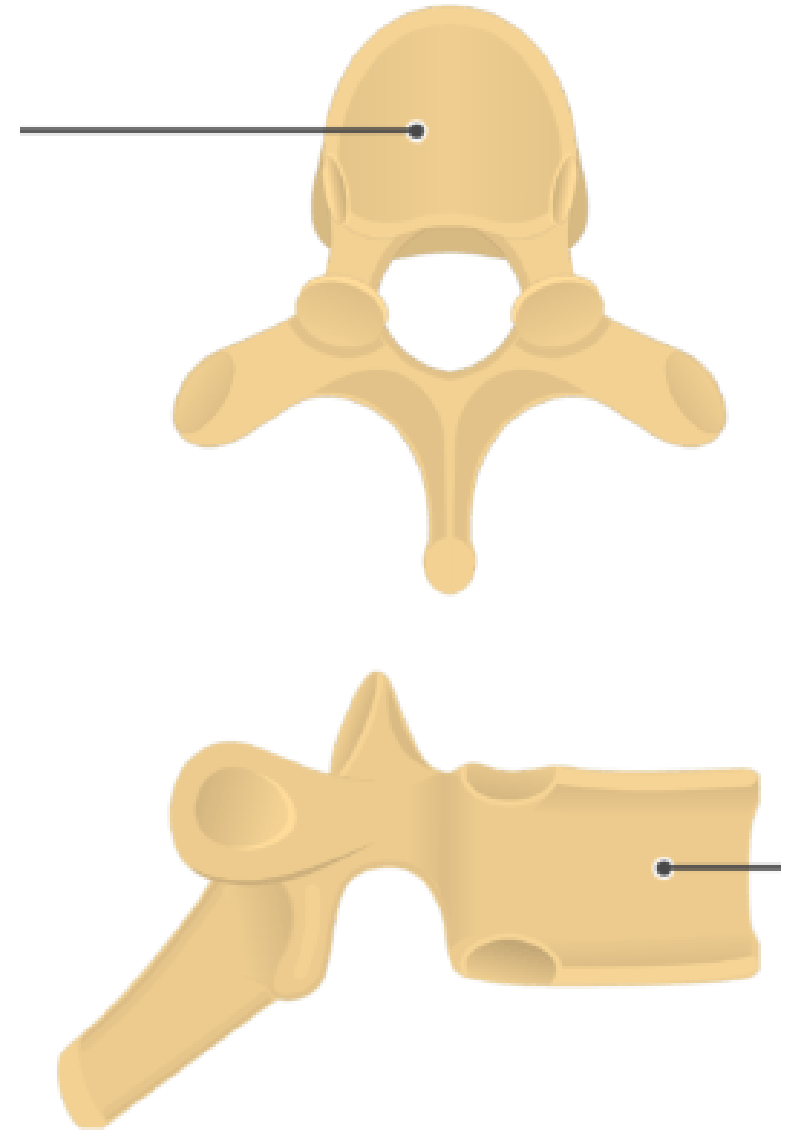
Atlas

Cervical

Lumbar

Question

2



Question

3

What is **STRUCTURE**?

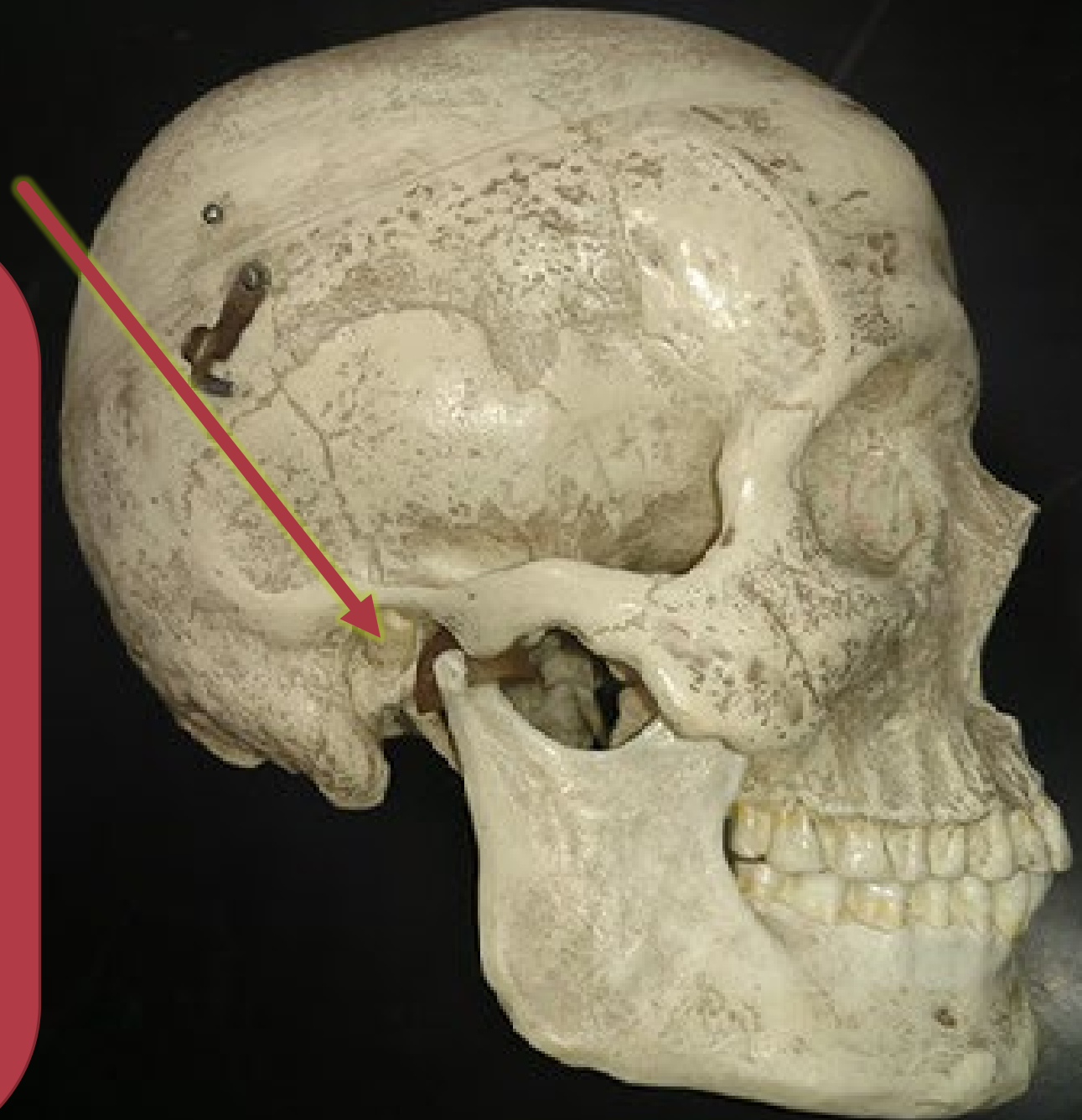
Zygoma

Zygomatic process

Temporal process

External auditory canal

Mandibular fossa



Question

4

What is **STRUCTURE**?

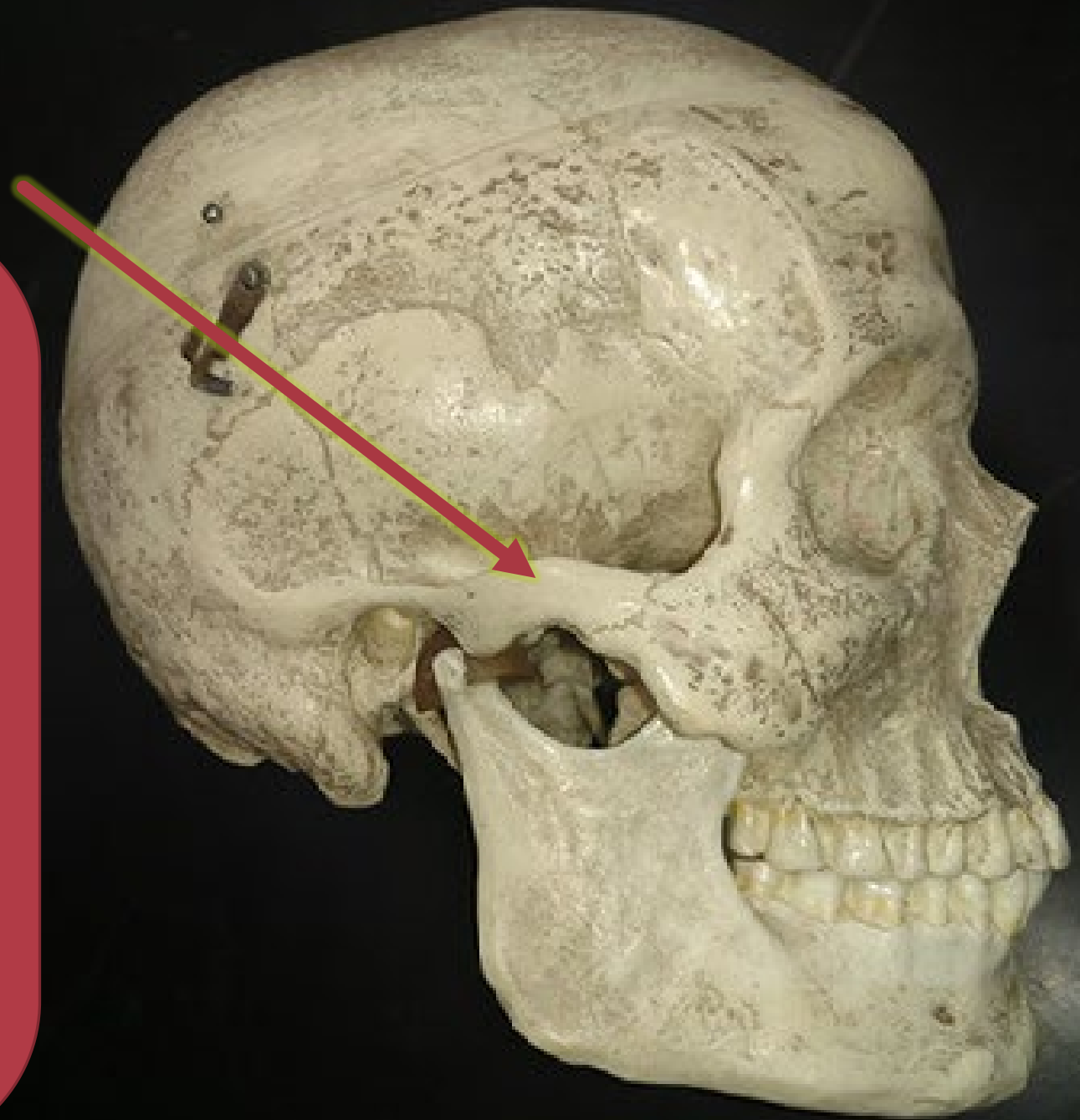
Zygoma

Zygomatic process

Temporal process

External auditory canal

Mandibular fossa



Question

5

What is **STRUCTURE**?

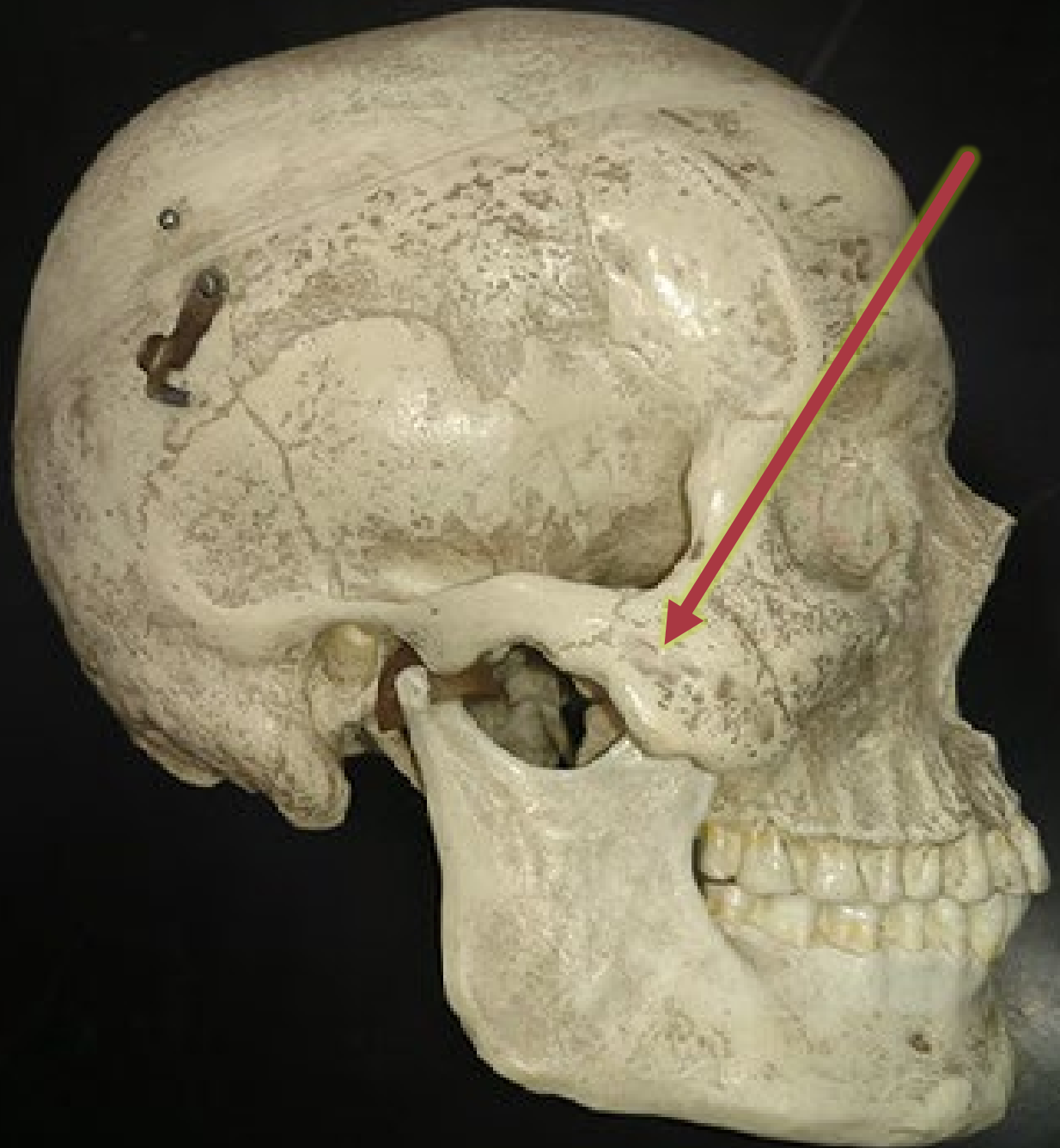Zygoma

Zygomatic process

Temporal process

External auditory canal

Mandibular fossa



Question

6

What is the BONE?

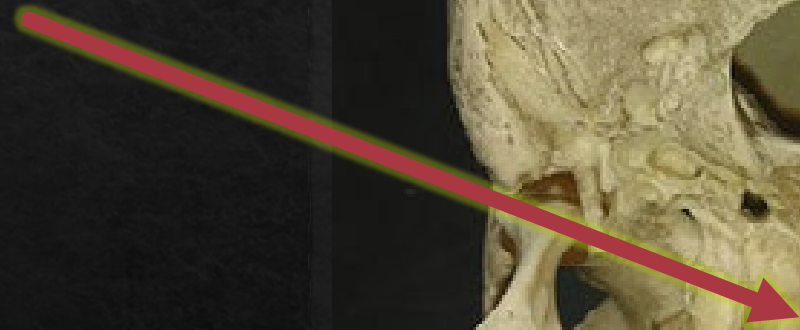Zygoma

Maxilla

Vomer

Palatine Bone

Ethmoid



Question

7

Identify the
STRUCTURES?

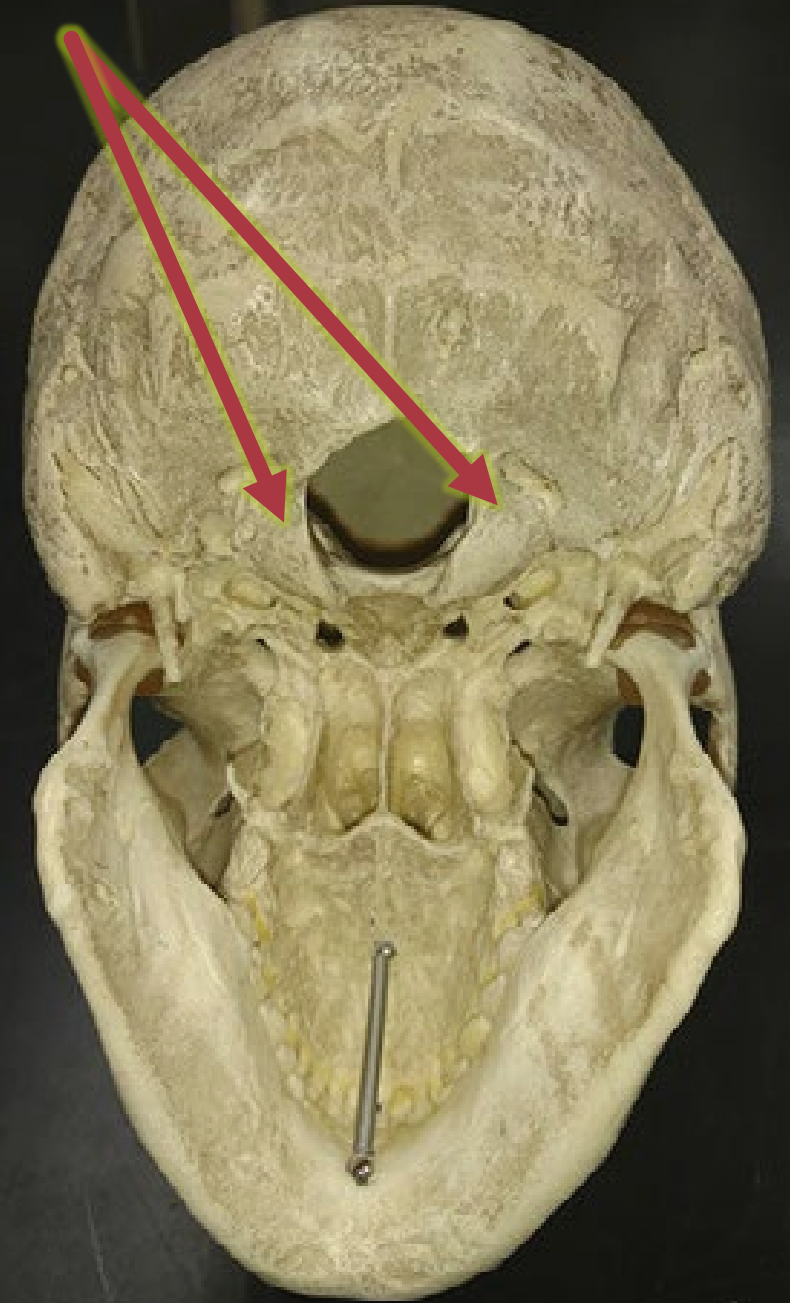
Foramen Magnum

Optic Foramina

Occipital Foramina

Occipital Condyles

Palatine Condyles

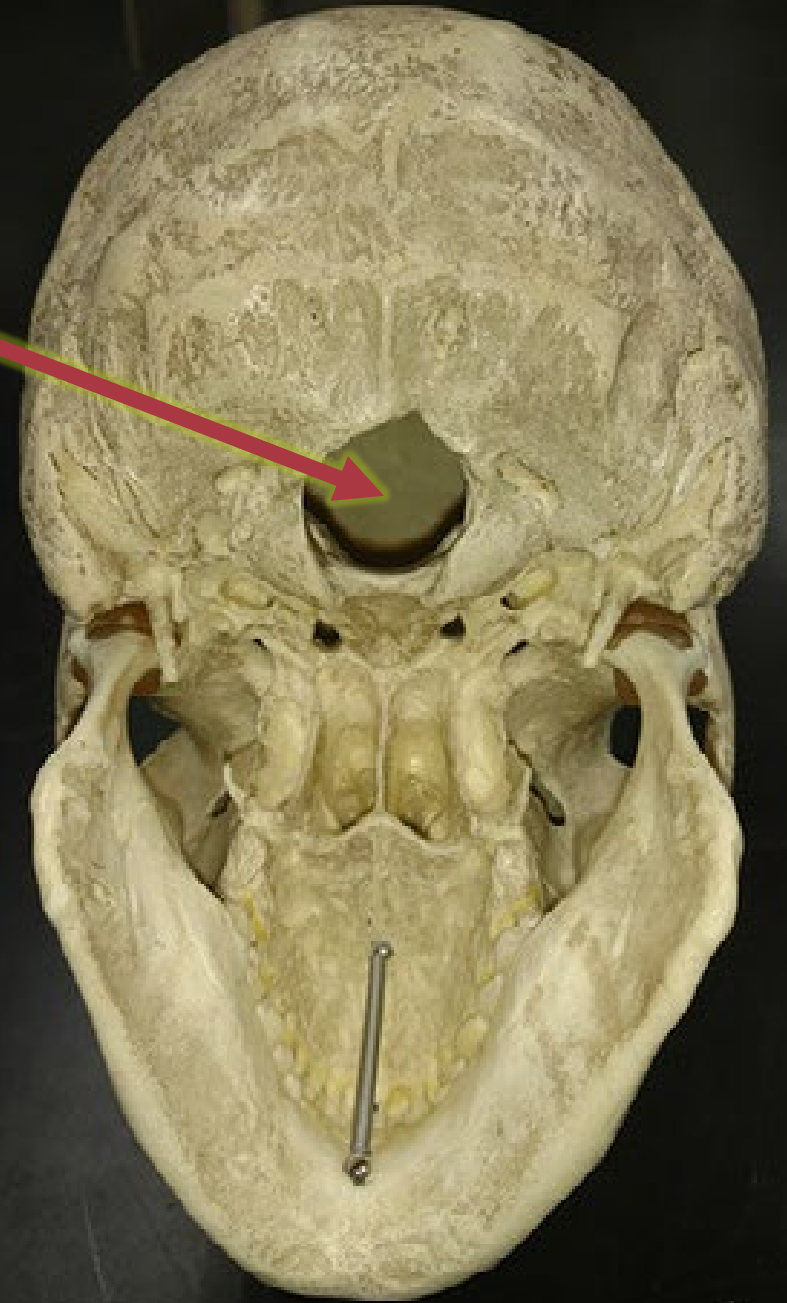


What is the HOLE?

- Foramen Magnum
- Intervertebral Foramen
- Occipital Foramen
- Occipital Condyle
- Transverse Foramen

Question

8



Identify the **STRUCTURE**.

Vomer

Nasal Bone

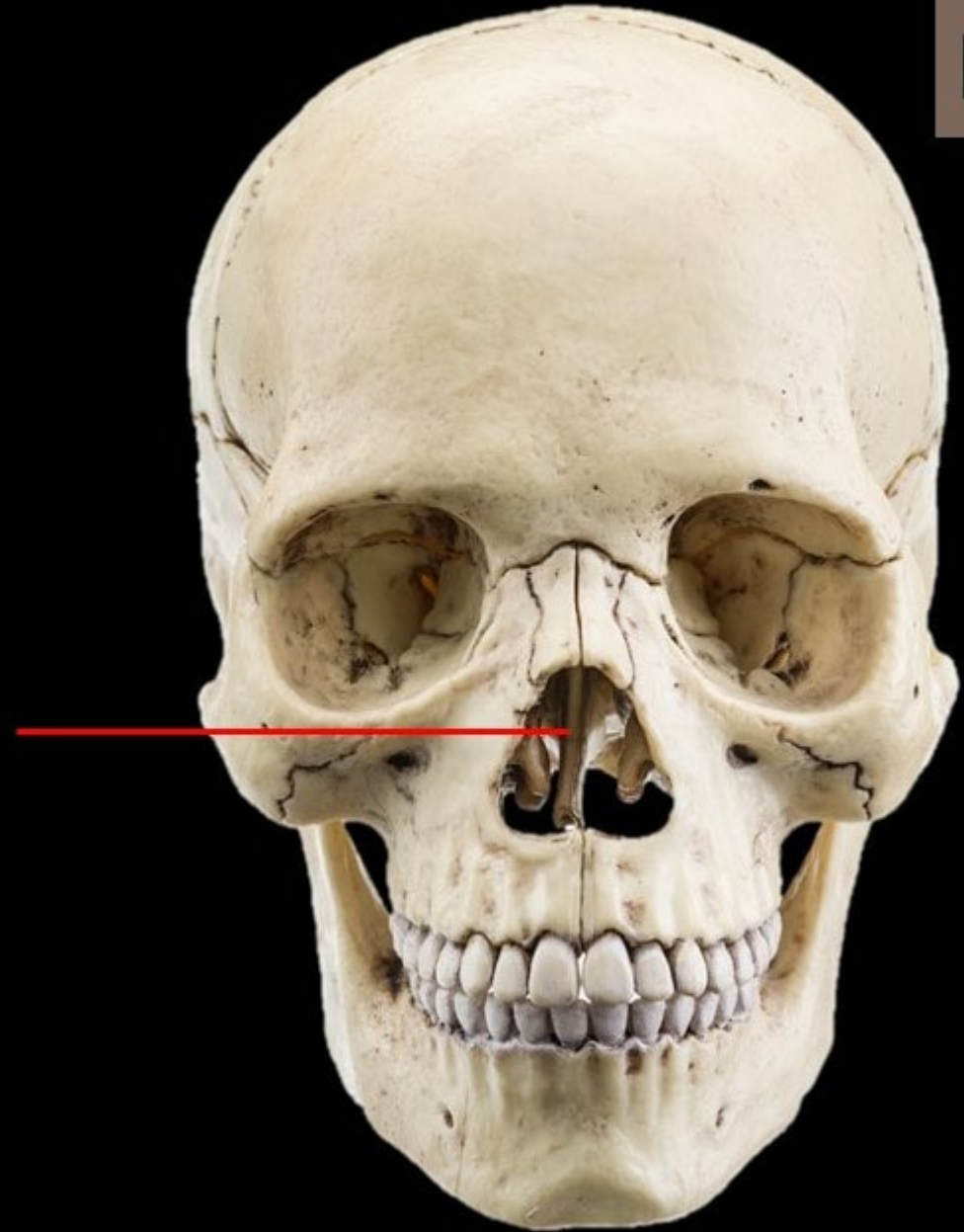
Nasal Conchae

Ethmoid Sinuses

Perpendicular Plate

Question

9



Question

10

Identify the **STRUCTURE**.

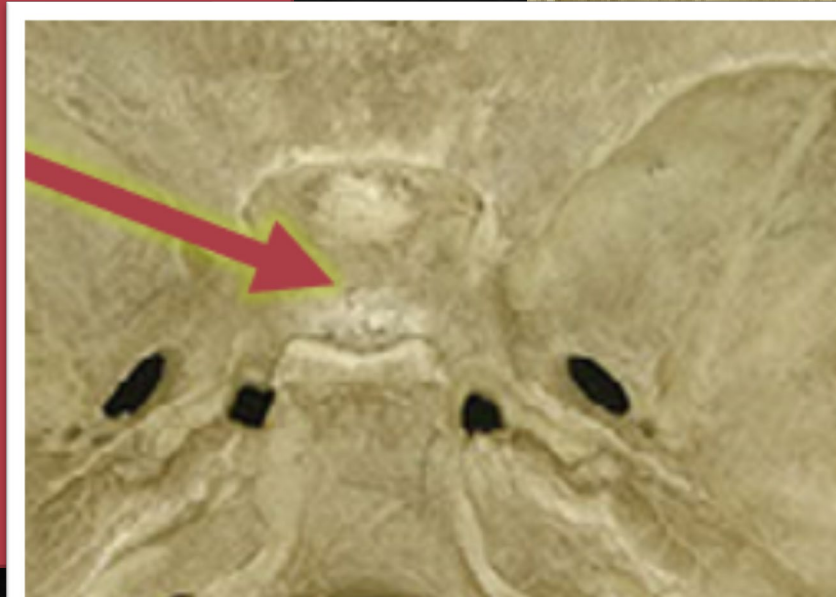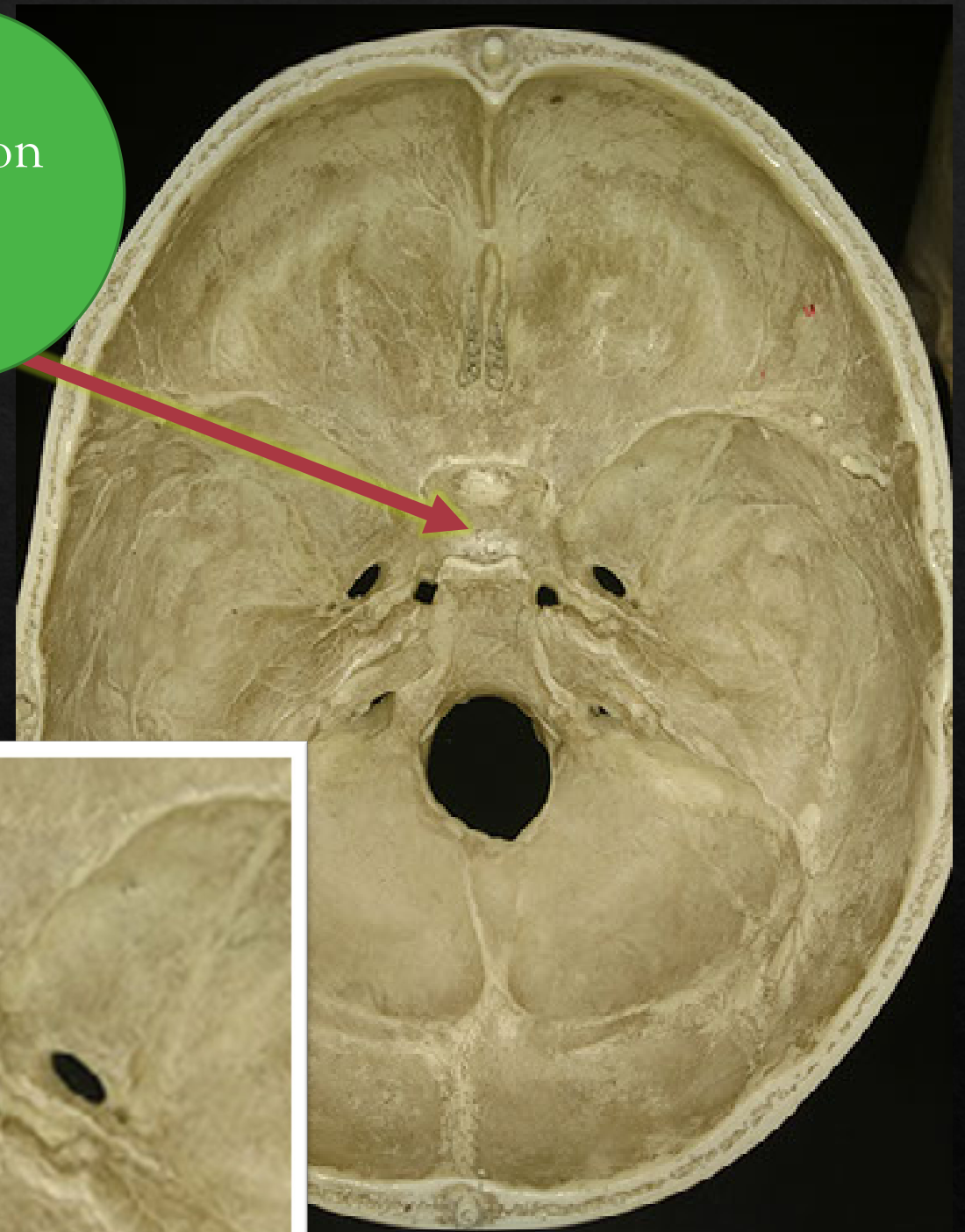
Crista Galli

Sella Turcica

Optic Foramina

Cribriform Plate

Perpendicular Plate



Identify the **STRUCTURE**.

Crista Galli

Sphenoid

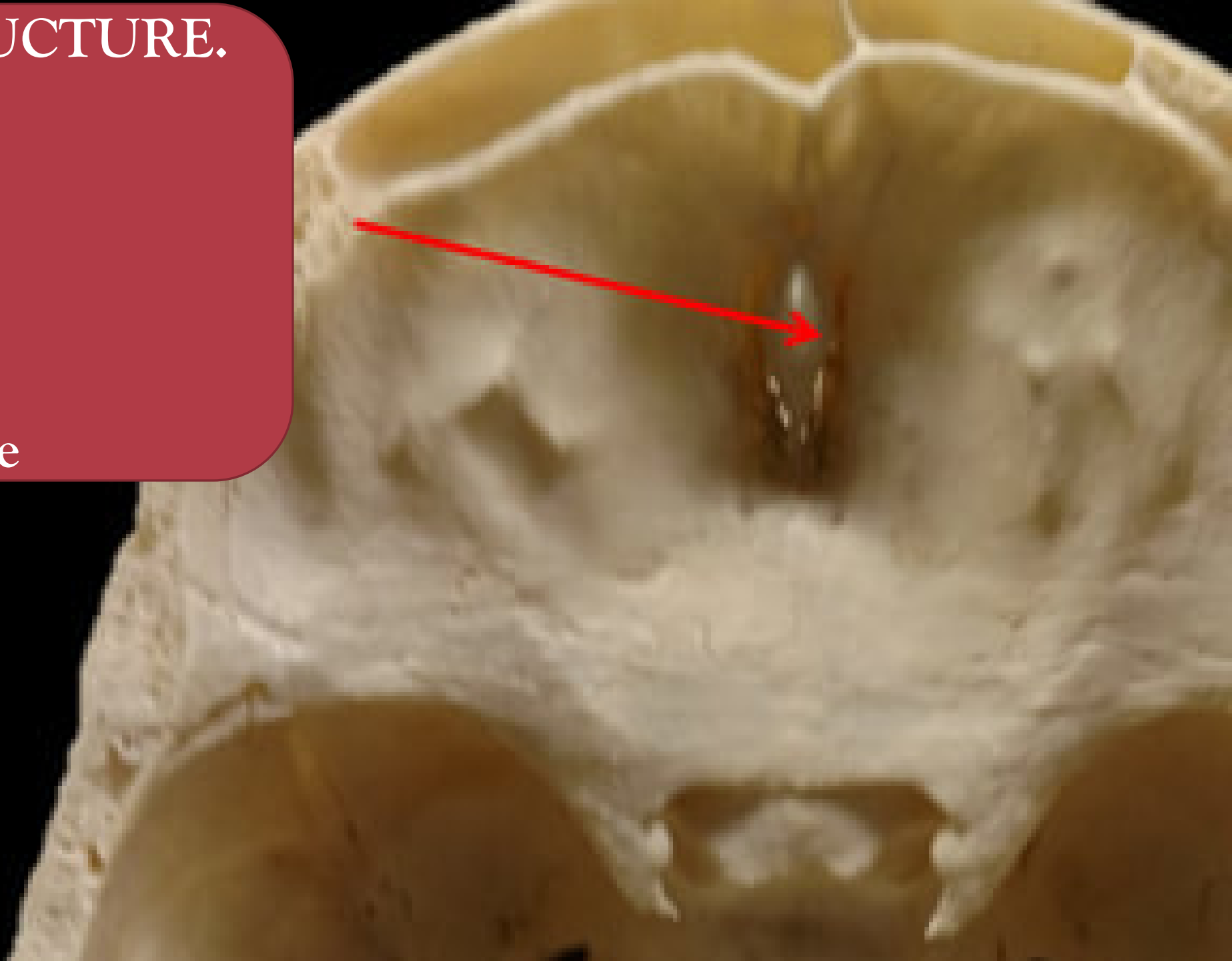
Optic Foramina

Cribriform Plate

Perpendicular Plate

Question

11



Identify the **STRUCTURE**.

Crista Galli

Sphenoid

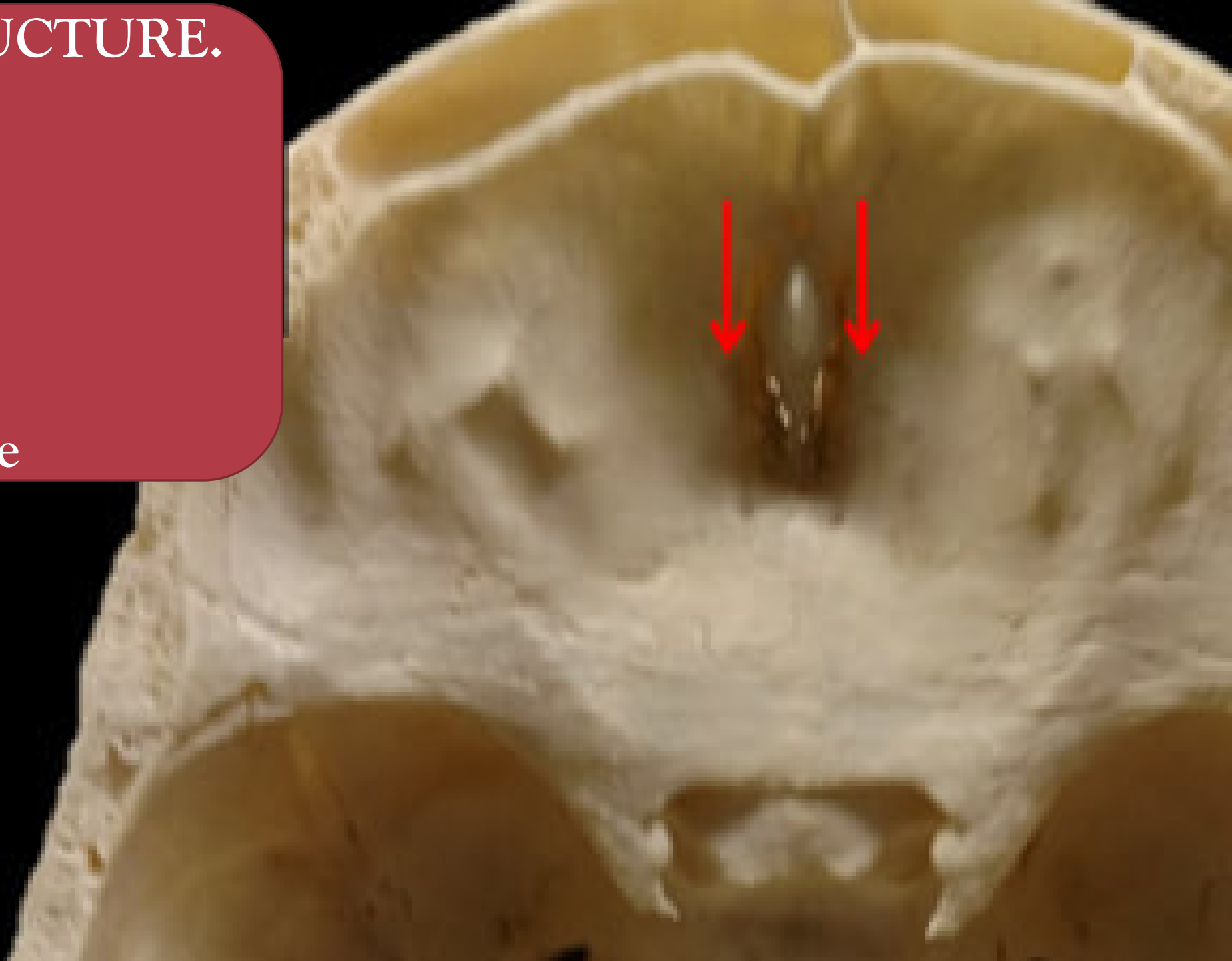
Optic Foramina

Cribriform Plate

Perpendicular Plate

Question

12



Identify the **STRUCTURE**.

Mandibular fossa

Mandibular condyle

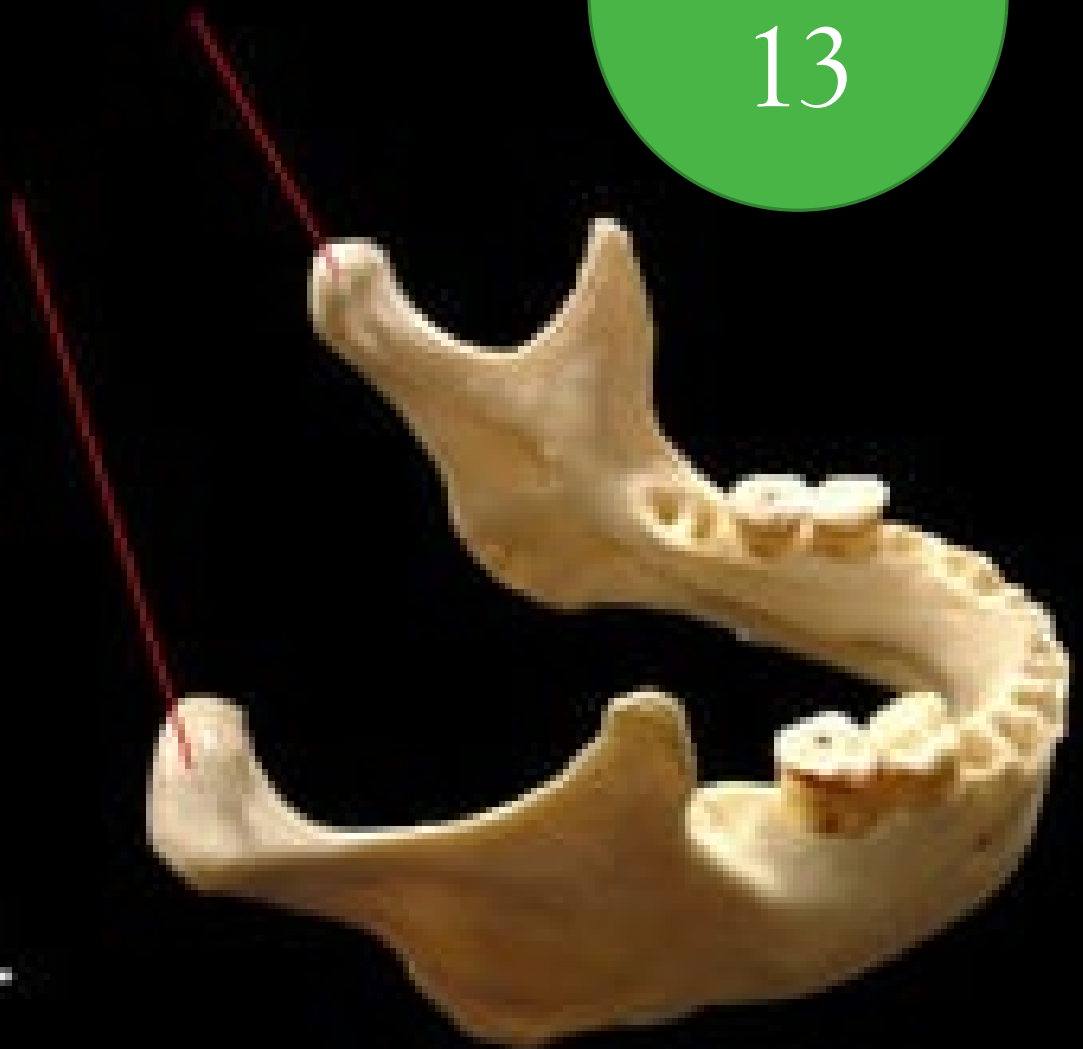Mandibular fossa

Optic Foramina

Cribriform Plate

Question

13



Question

14

Identify the SUTURE.

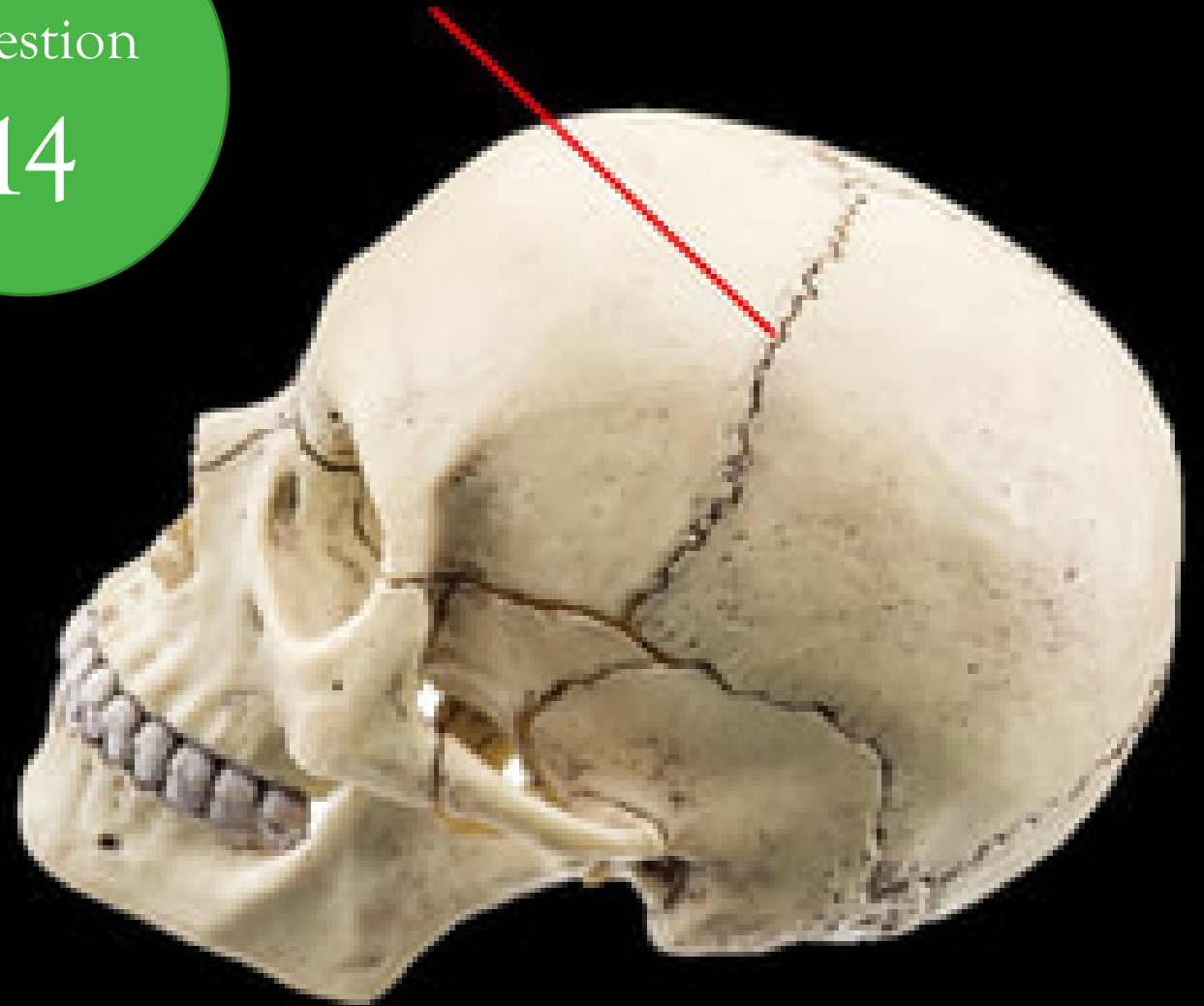
Coronal Suture

Squamosal Suture

Lambdoidal Suture

Sagittal Suture

Transverse Suture



Question

15

Identify the SUTURE.

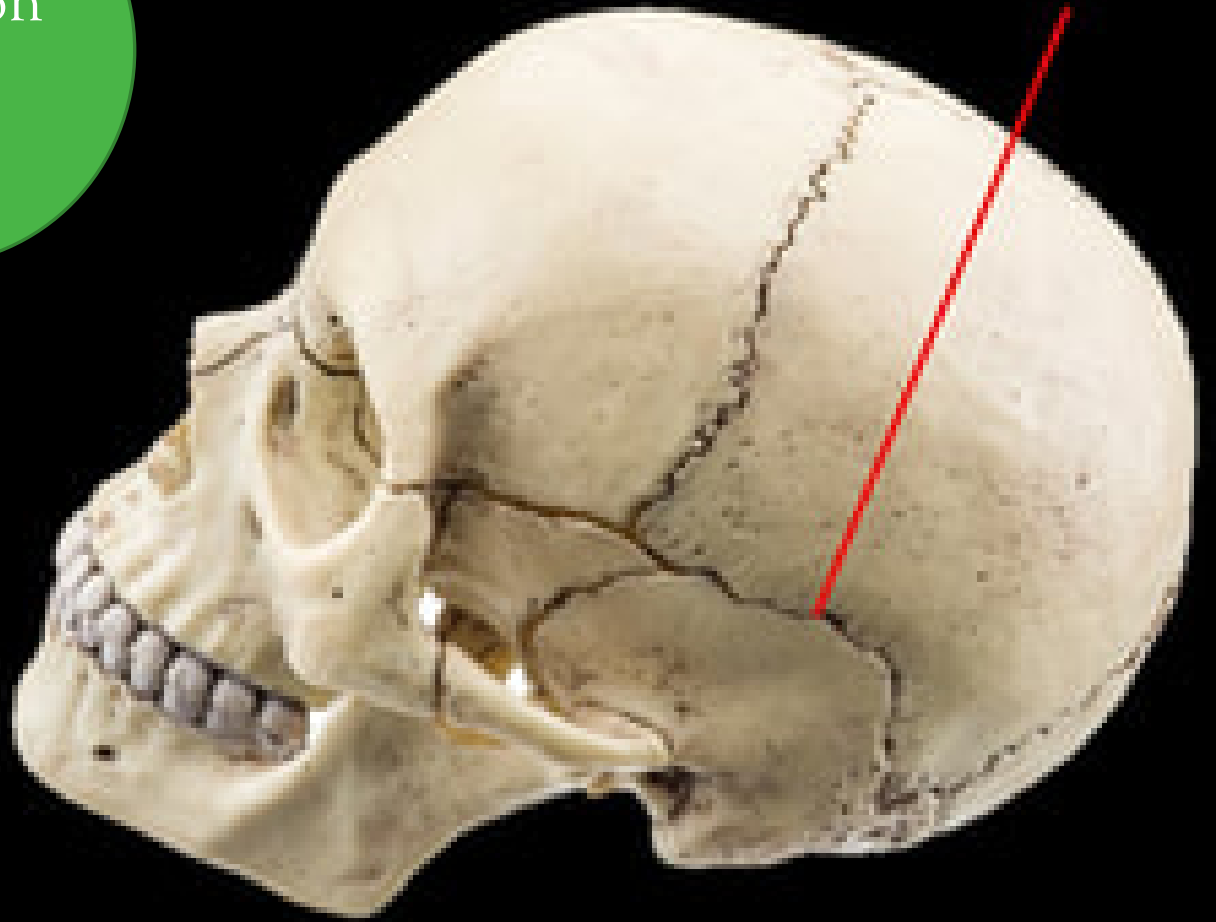
Coronal Suture

Squamosal Suture

Lambdoidal Suture

Sagittal Suture

Transverse Suture



What is the BONE?

Zygoma

Maxilla

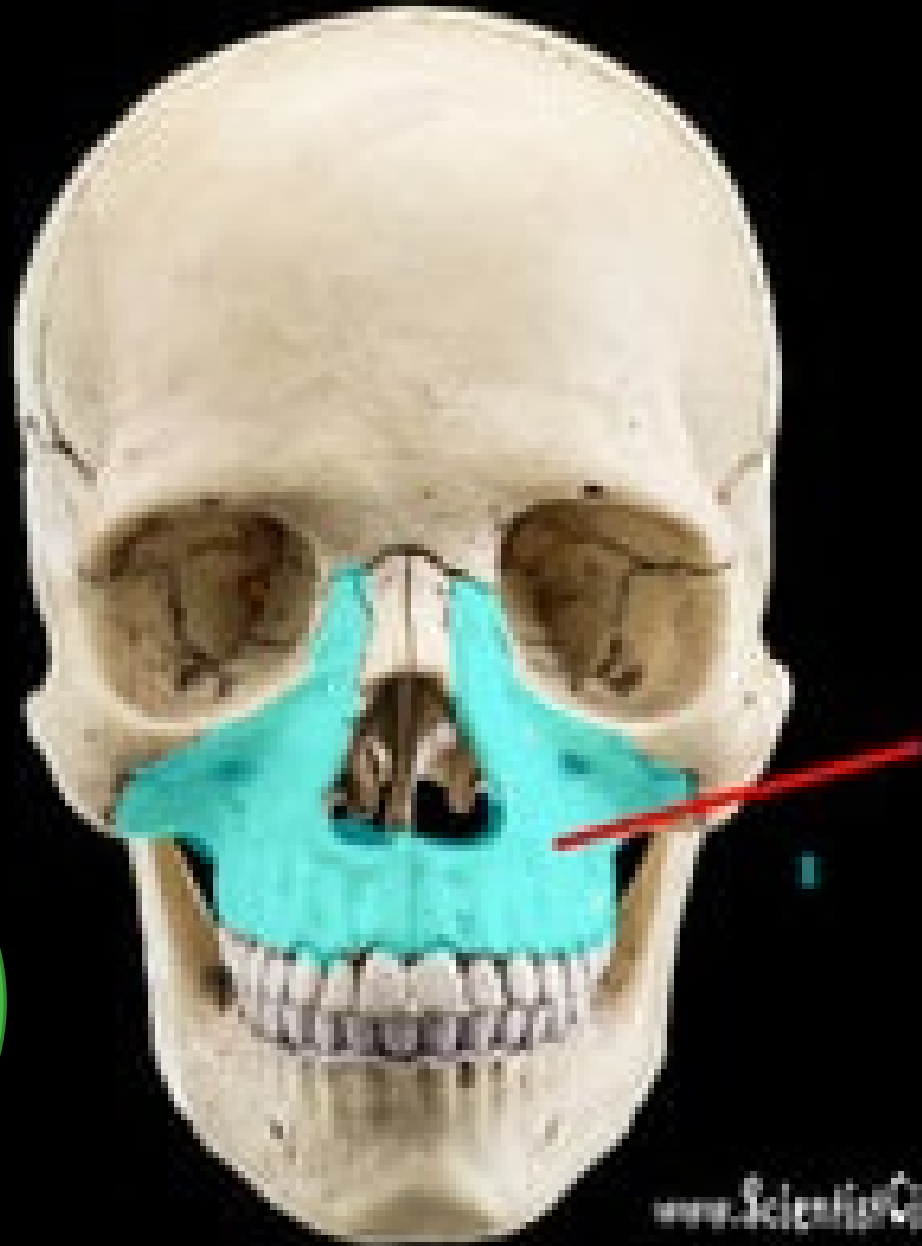Vomer

Palatine Bone

Ethmoid

Question

16



NAME _____

What is the BONE?

Temporal Bone

Occipital Bone

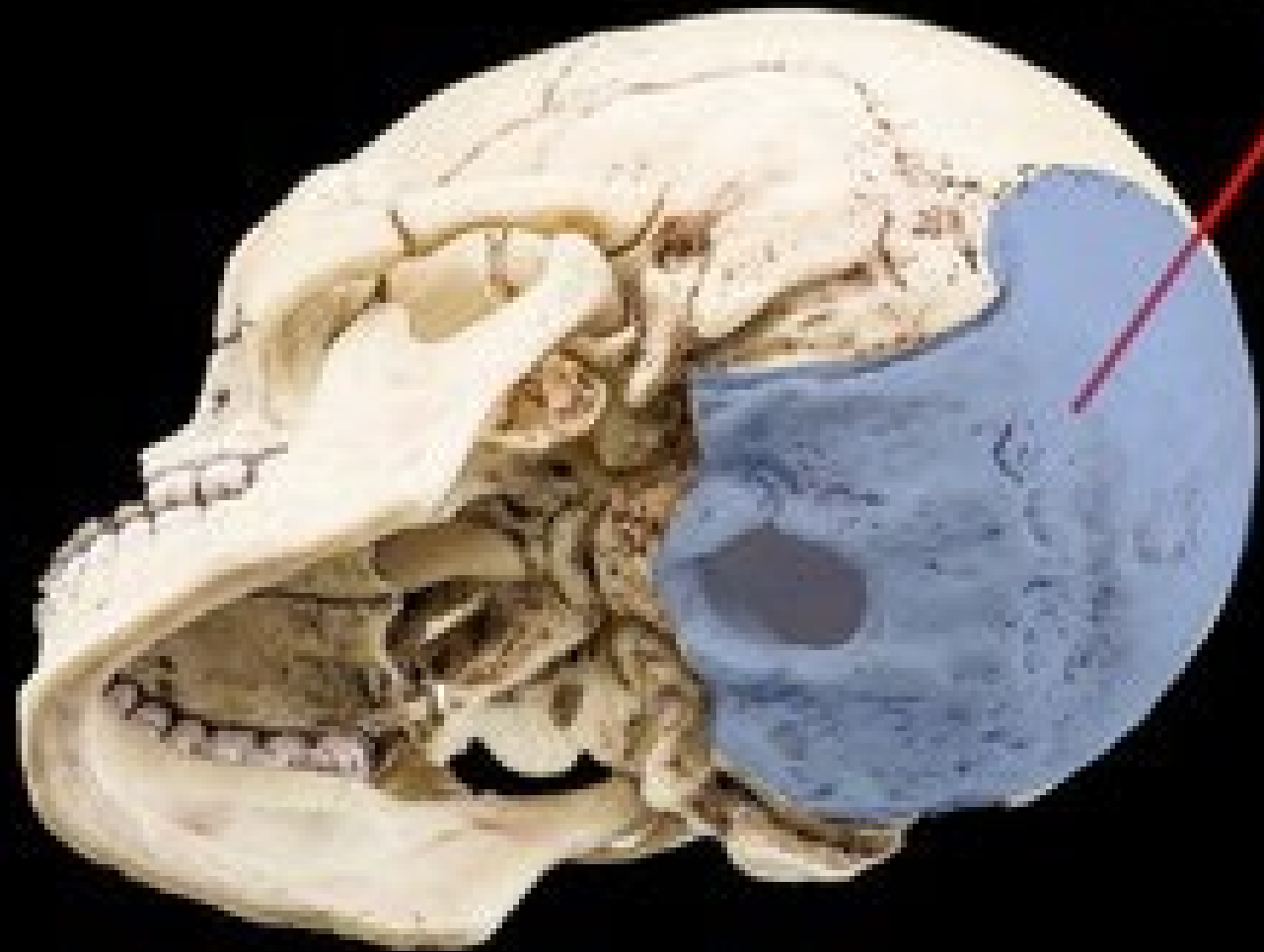Sphenoid

Palatine Bone

Ethmoid

Question

17



Identify the SUTURE.

Coronal Suture

Squamosal Suture

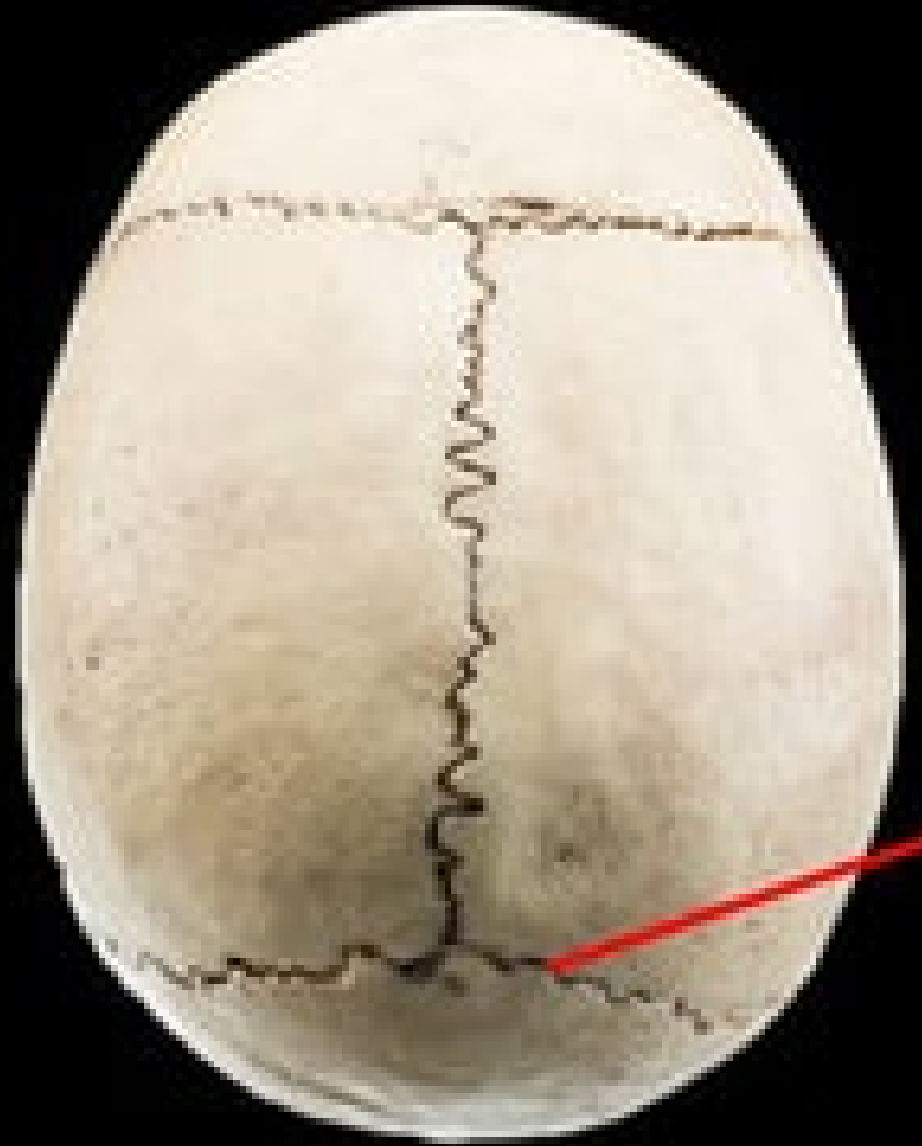Lambdoidal Suture

Sagittal Suture

Transverse Suture

Question

18



Identify the type of rib.

False Ribs

Pseudo-ribs

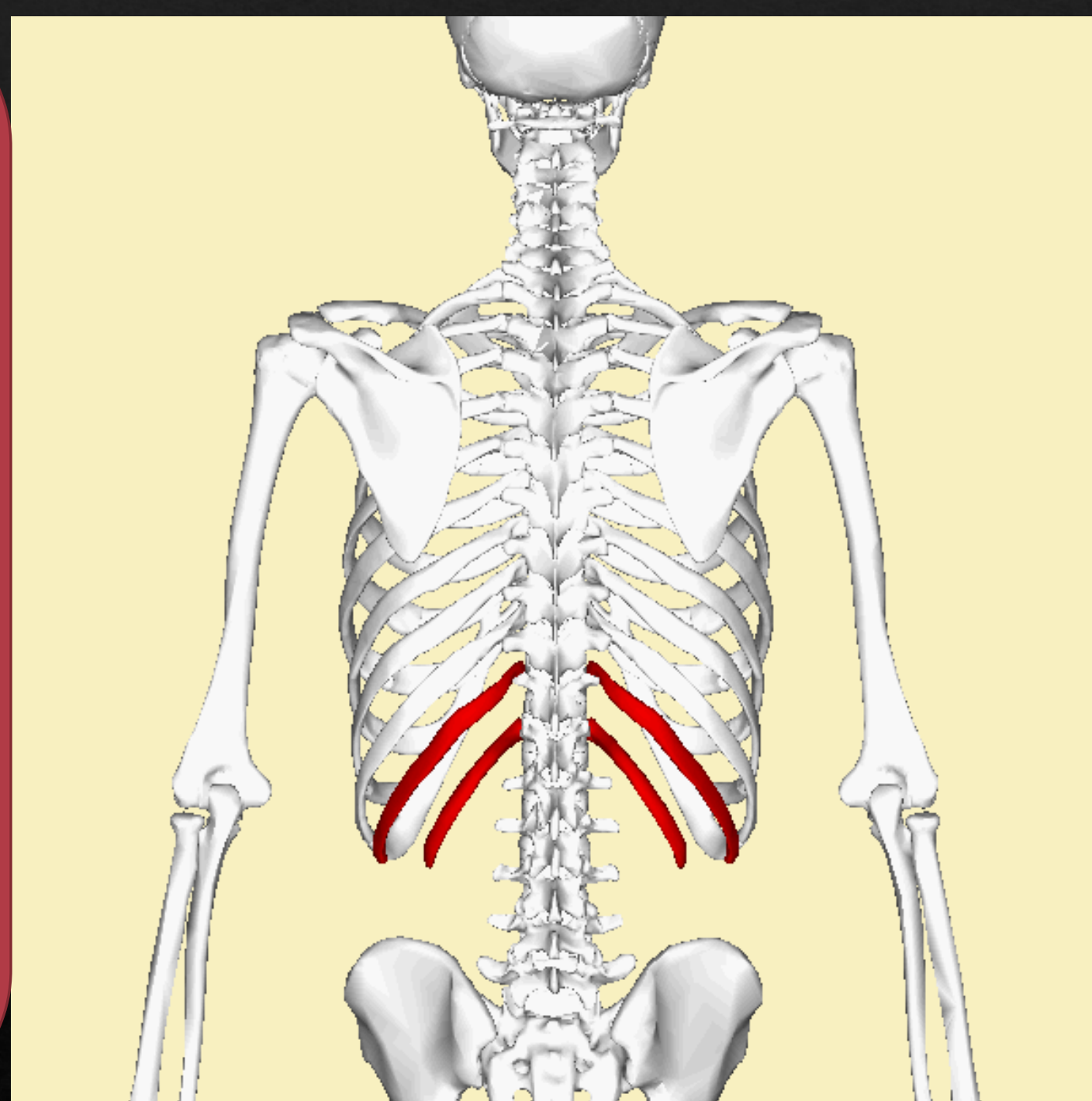
Floating Ribs

True Ribs

Fake Ribs

Question

19



Identify the structure.

Femoral Head

Head of the Humorous

Glenoid Fossa

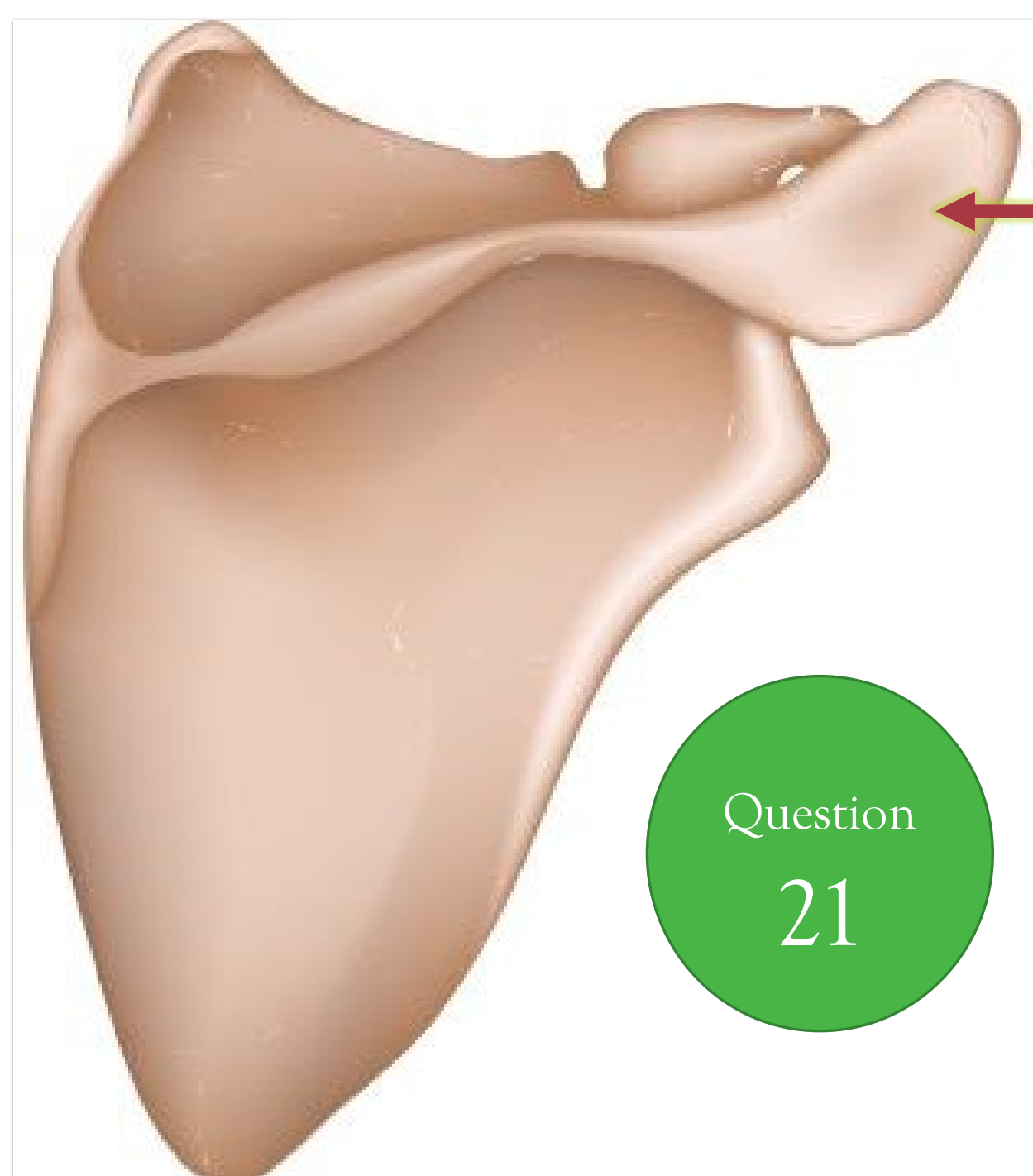Capitulum

Lesser Tubercle

Question

20





Question
21

Identify the structure.

- Spine of the Scapula
- Coracoid Process
- Coronoid Process
- Acromion Process
- Glenoid Fossa

Identify the structure.

Spine of the Scapula

Coracoid Process

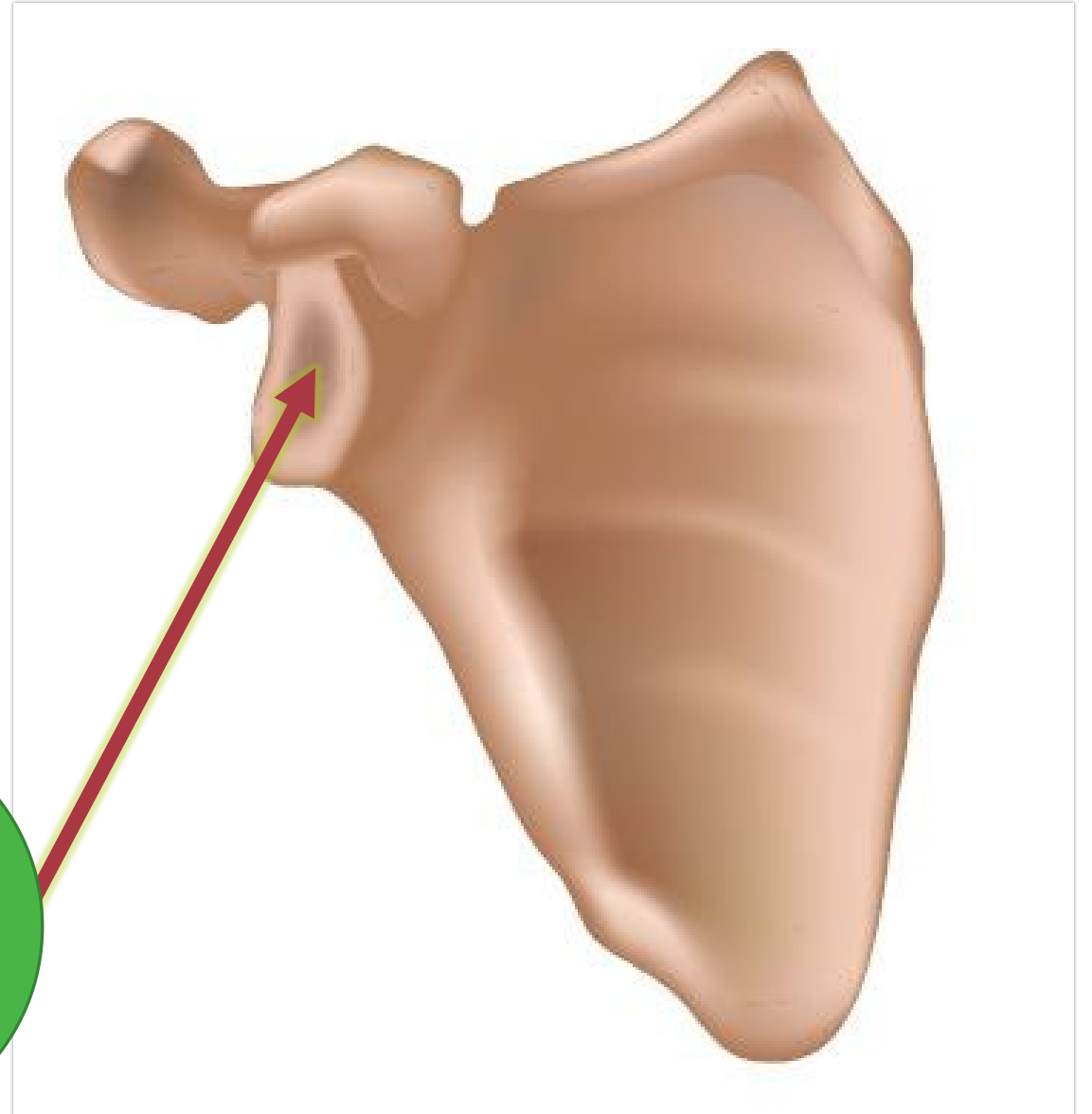
Coronoid Process

Acromion Process

Glenoid Fossa

Question

22



Identify the structure.

Spine of the Scapula
Coracoid Process
Coronoid Process
Acromion Process
Glenoid Fossa

Question

23

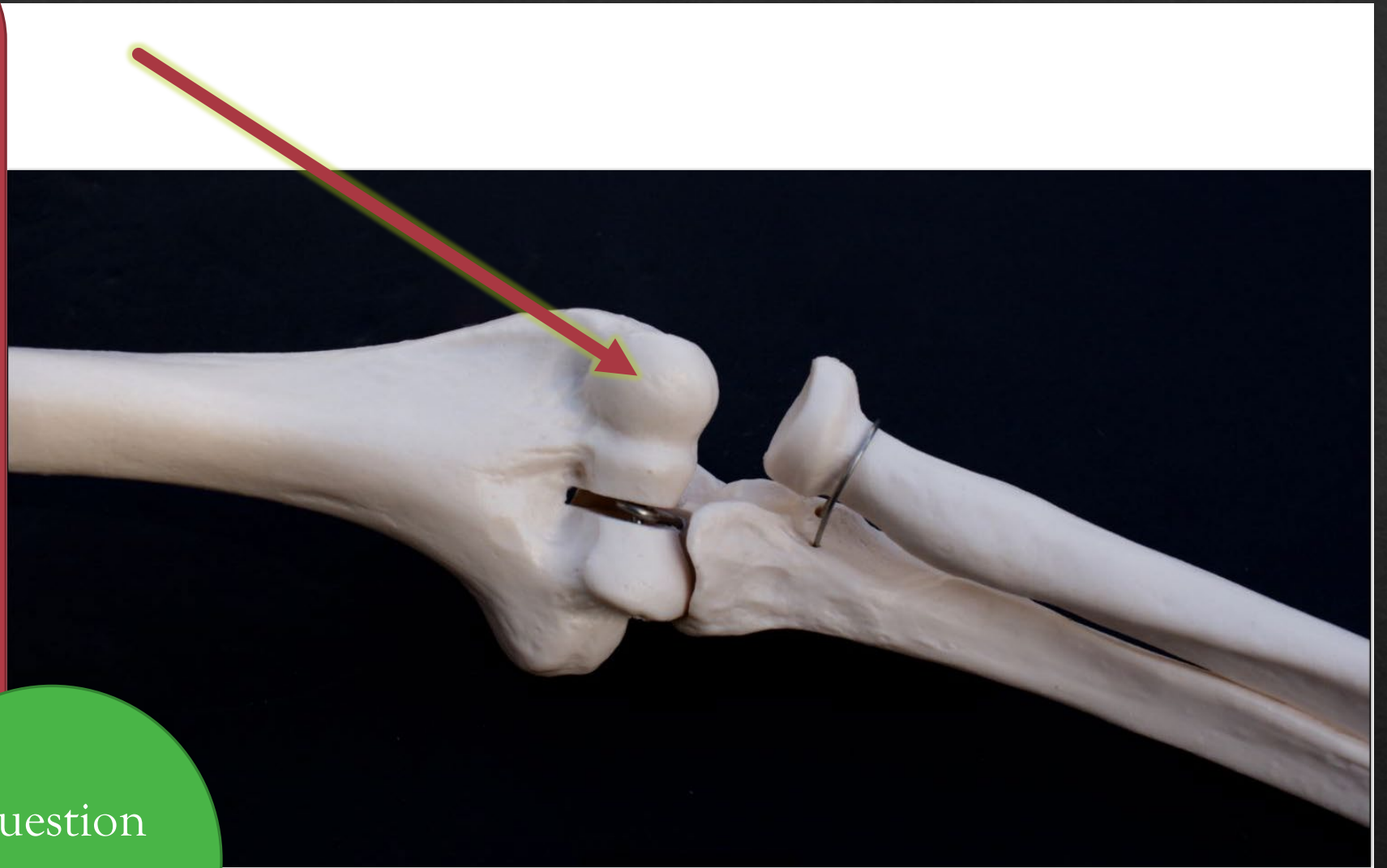


Identify the
structure.

- Capitulum
- Olecranon
- Process
- Coronoid Process
- Trochlea
- Olecranon Fossa

Question

24



Identify the
structure.

Capitulum

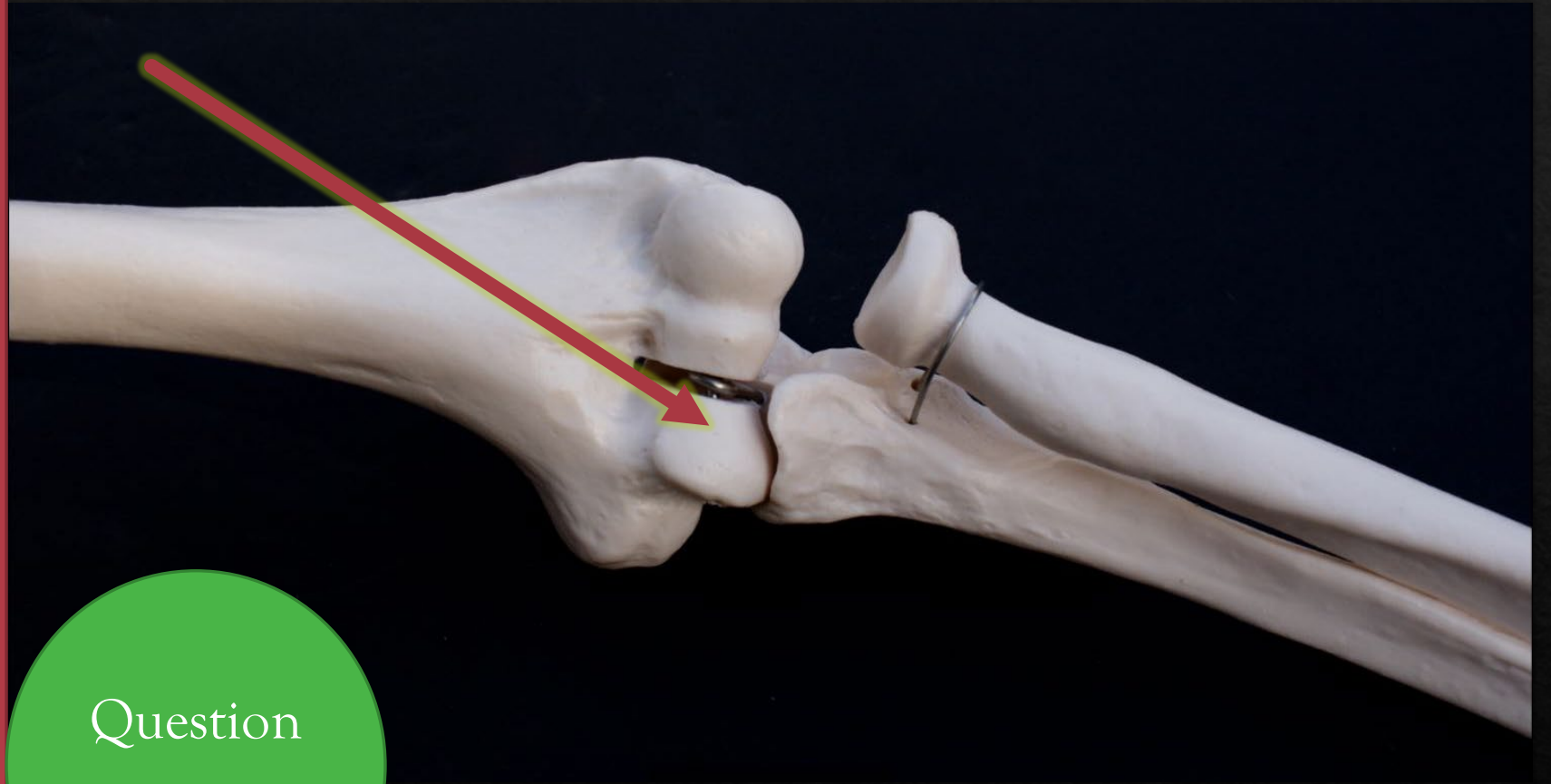
Olecranon

Process

Coronoid Process

Trochlea

Olecranon Fossa



Question

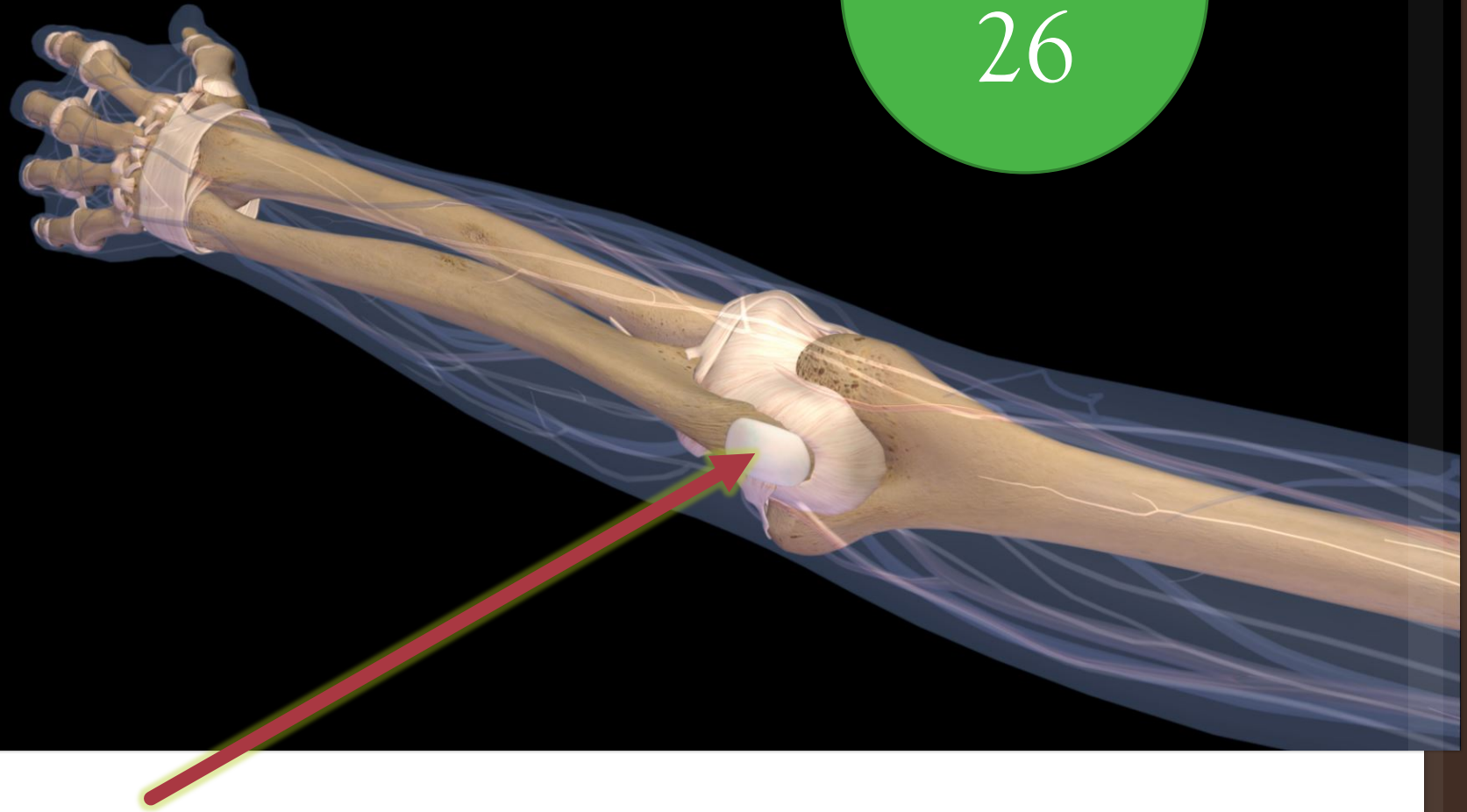
25

Identify the
structure.

Capitulum
Olecranon
Process
Coronoid
Process
Trochlea
Olecranon Fossa

Question

26



Question

27

Identify the
BONE.

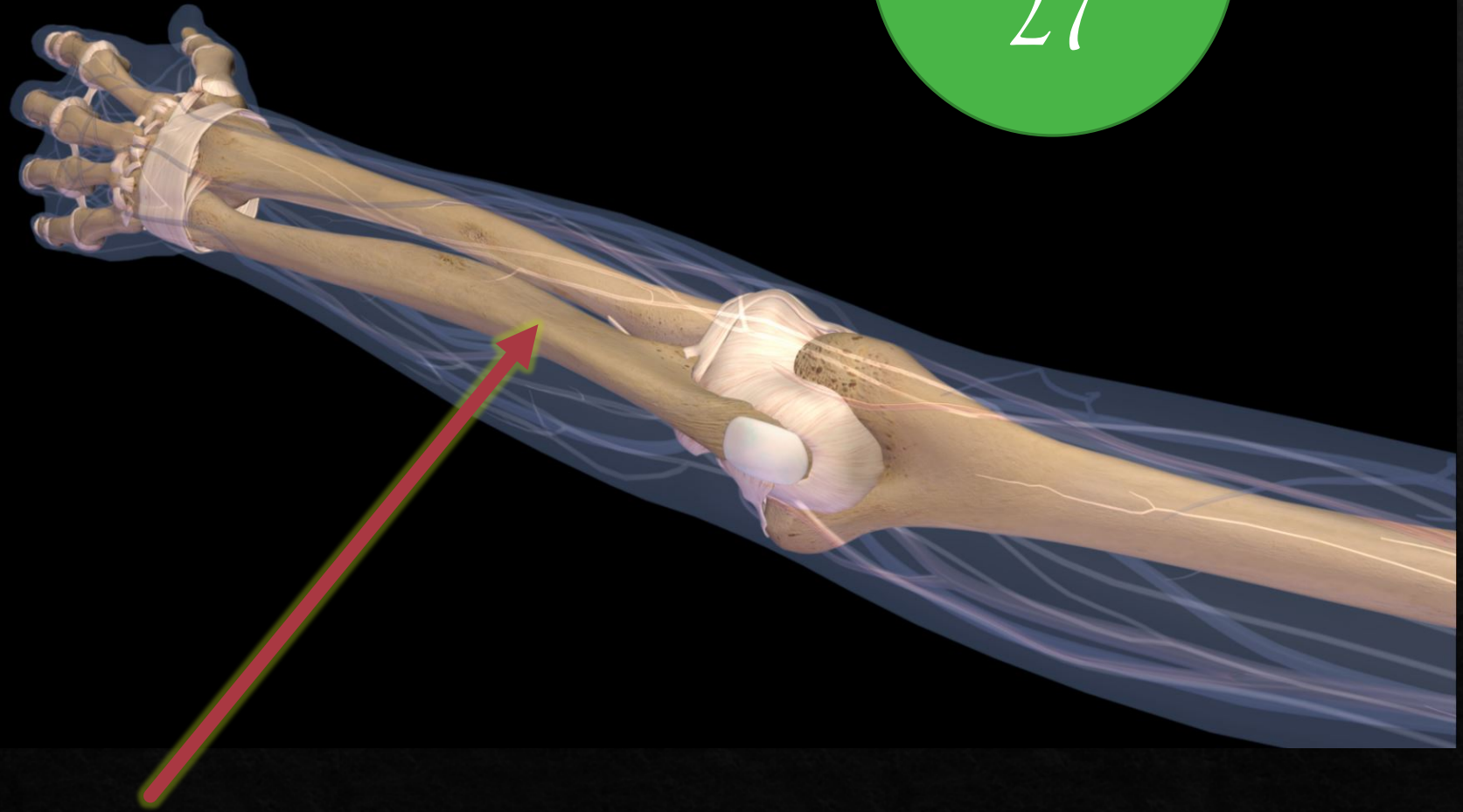
Ulna

Humerus

Radius

Fibula

Clavicle



Identify the BONE.

Question

28



Ulna

Humerus

Radius

Fibula

Clavicle

Identify the STRUCTURE.

Medial condyle

Medial malleolus

Lateral condyle

Fibular condyle

Greater Trochanter

Question

29



Identify the LEVEL.

Cervical

Lumbar

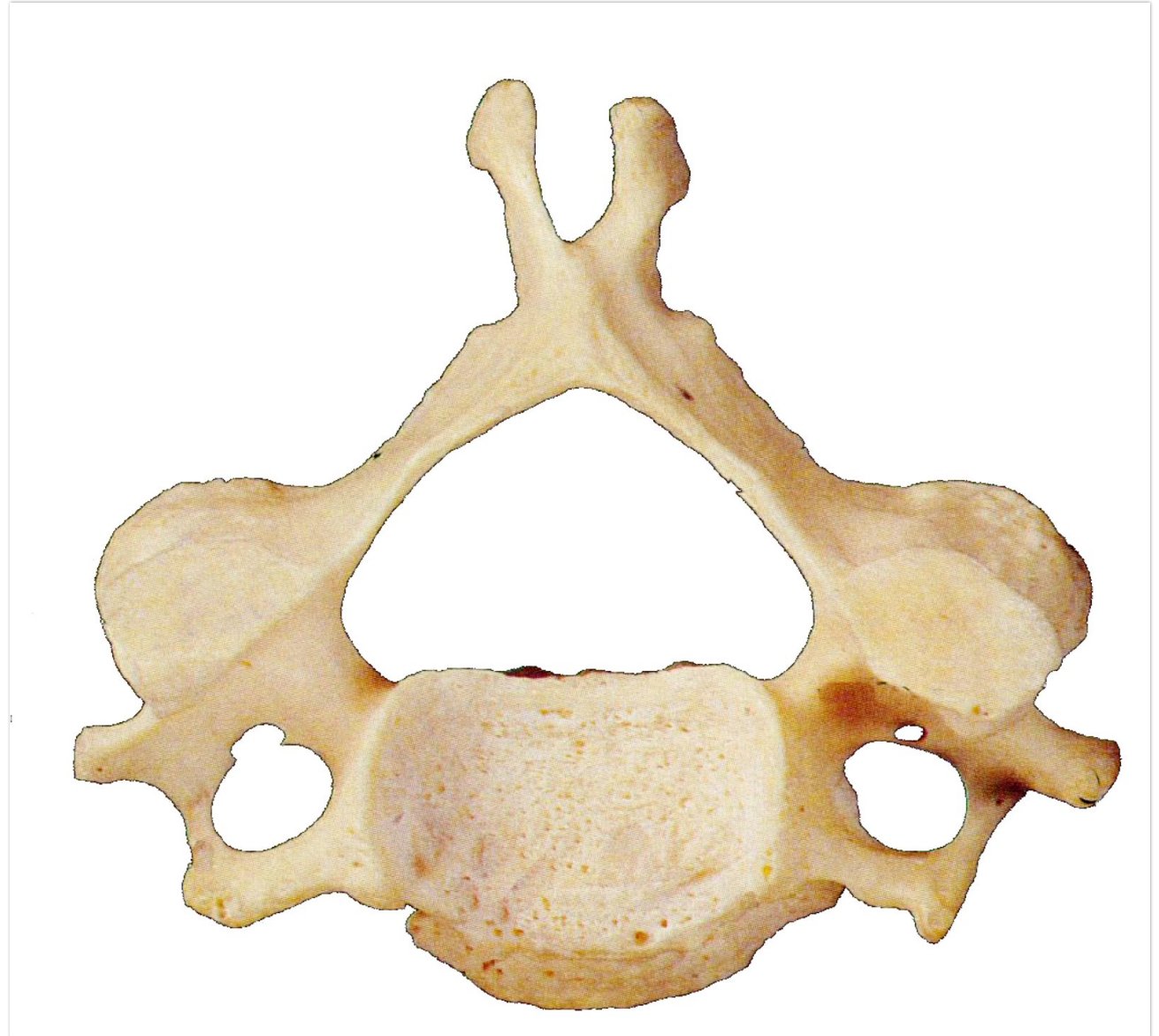
Thoracic

Axis

Atlas

Question

30



Identify the
STRUCTURE.

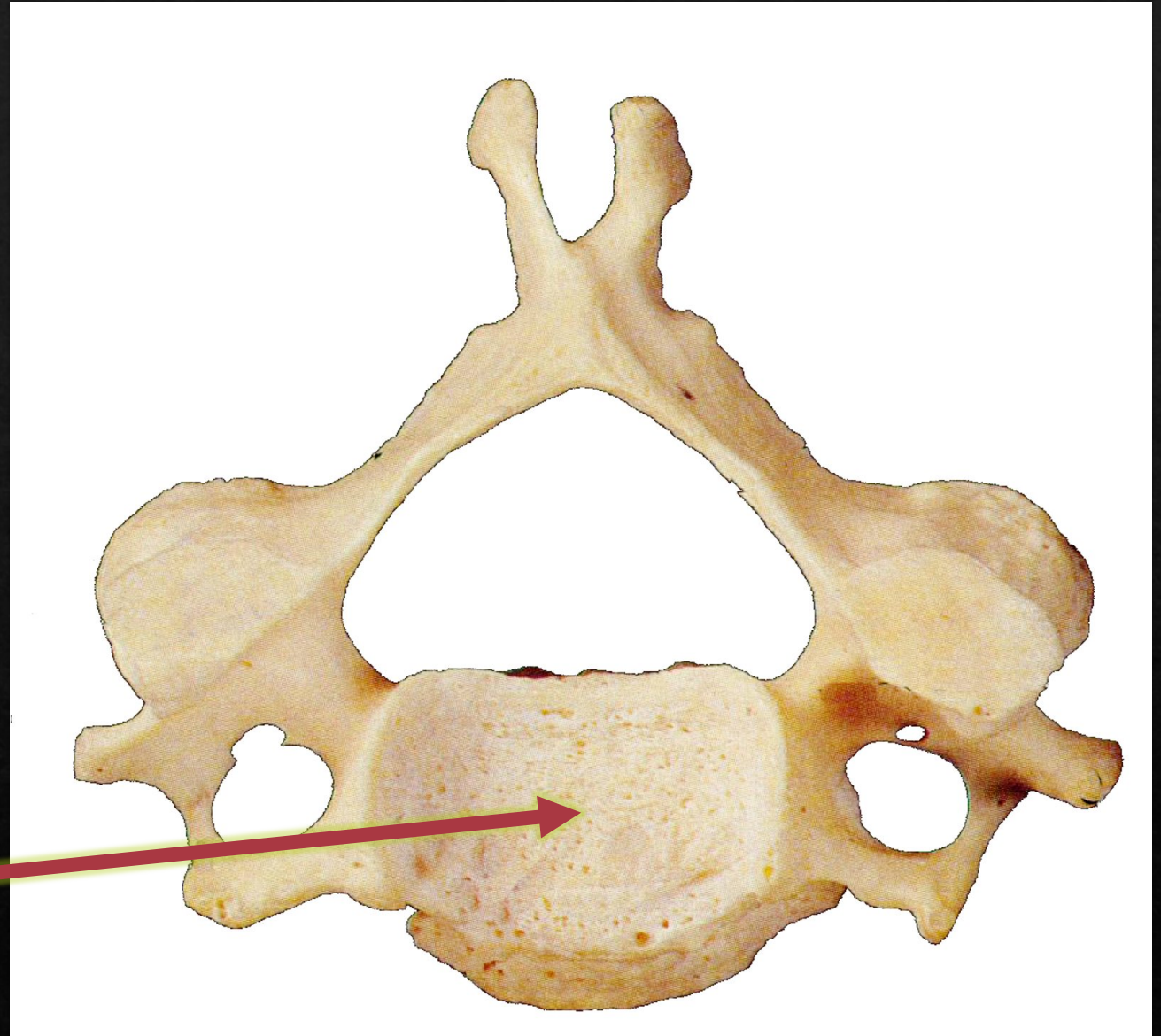
Dens

Transverse process

Spinous process

Body

Transverse foramen



Question

31

Identify the
STRUCTURE.

Dens

Transverse process

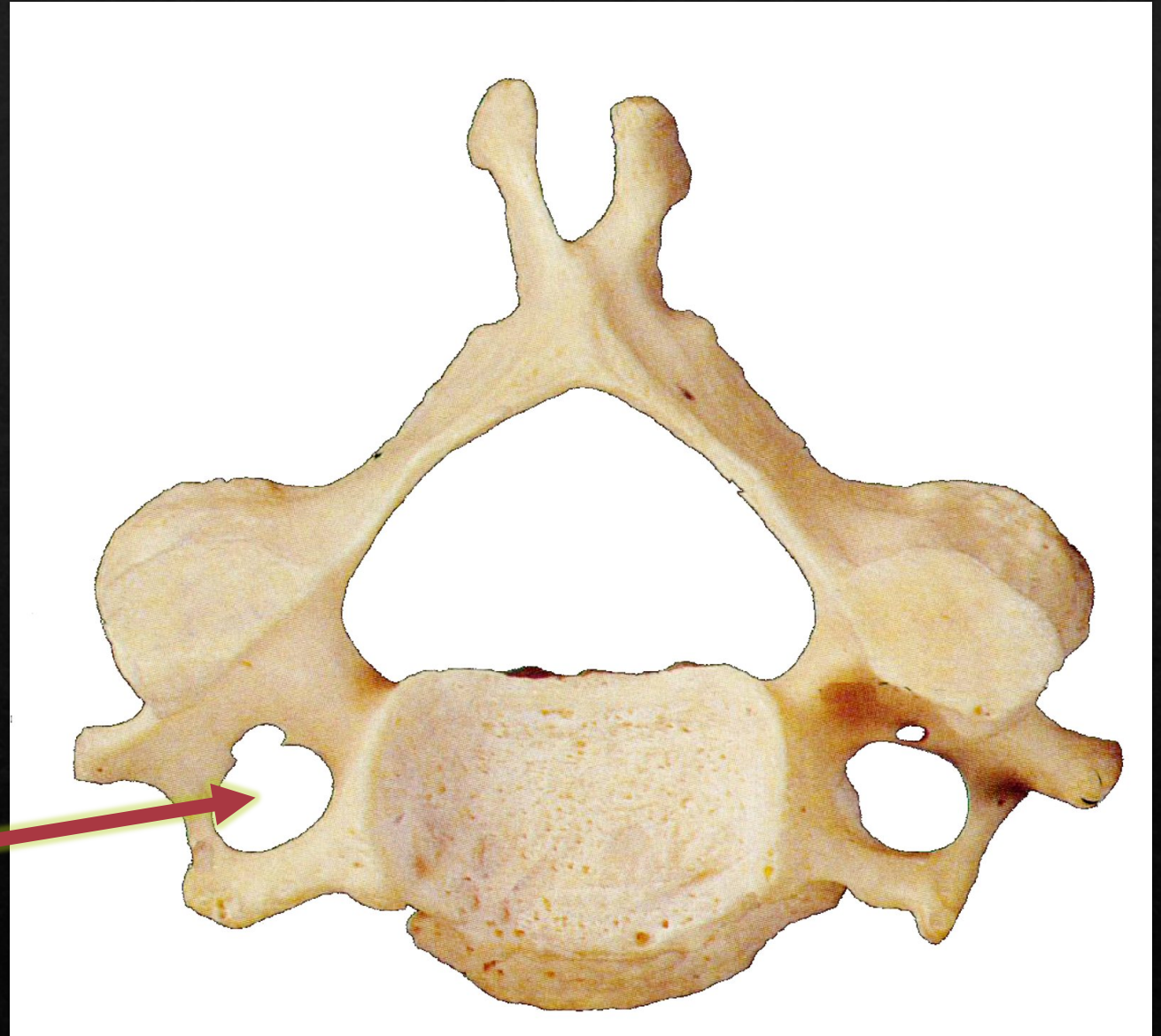
Spinous process

Body

Transverse foramen

Question

32



Identify the
STRUCTURE.

Dens

Transverse process

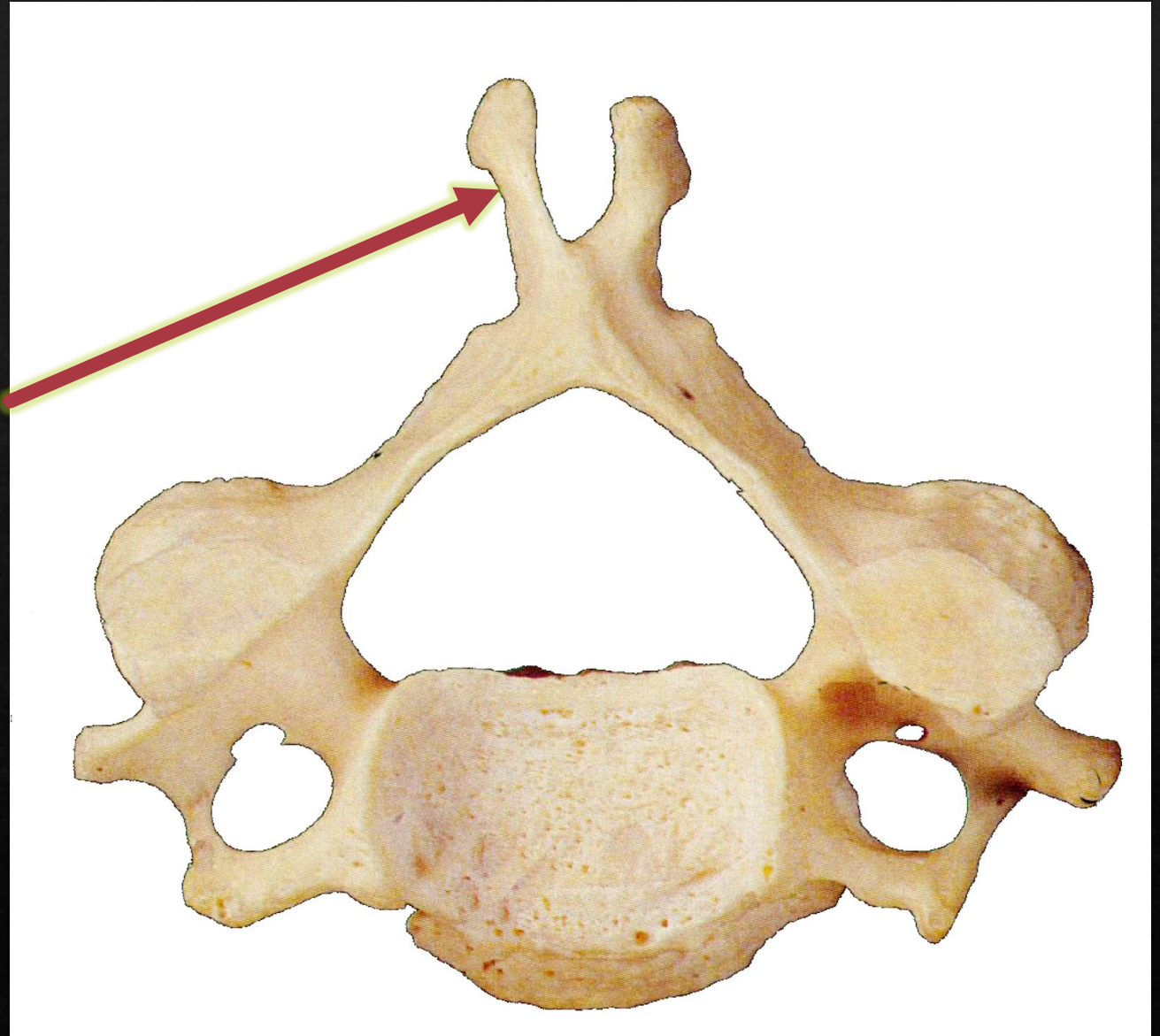
Spinous process

Body

Transverse foramen

Question

33



Identify the
STRUCTURE.

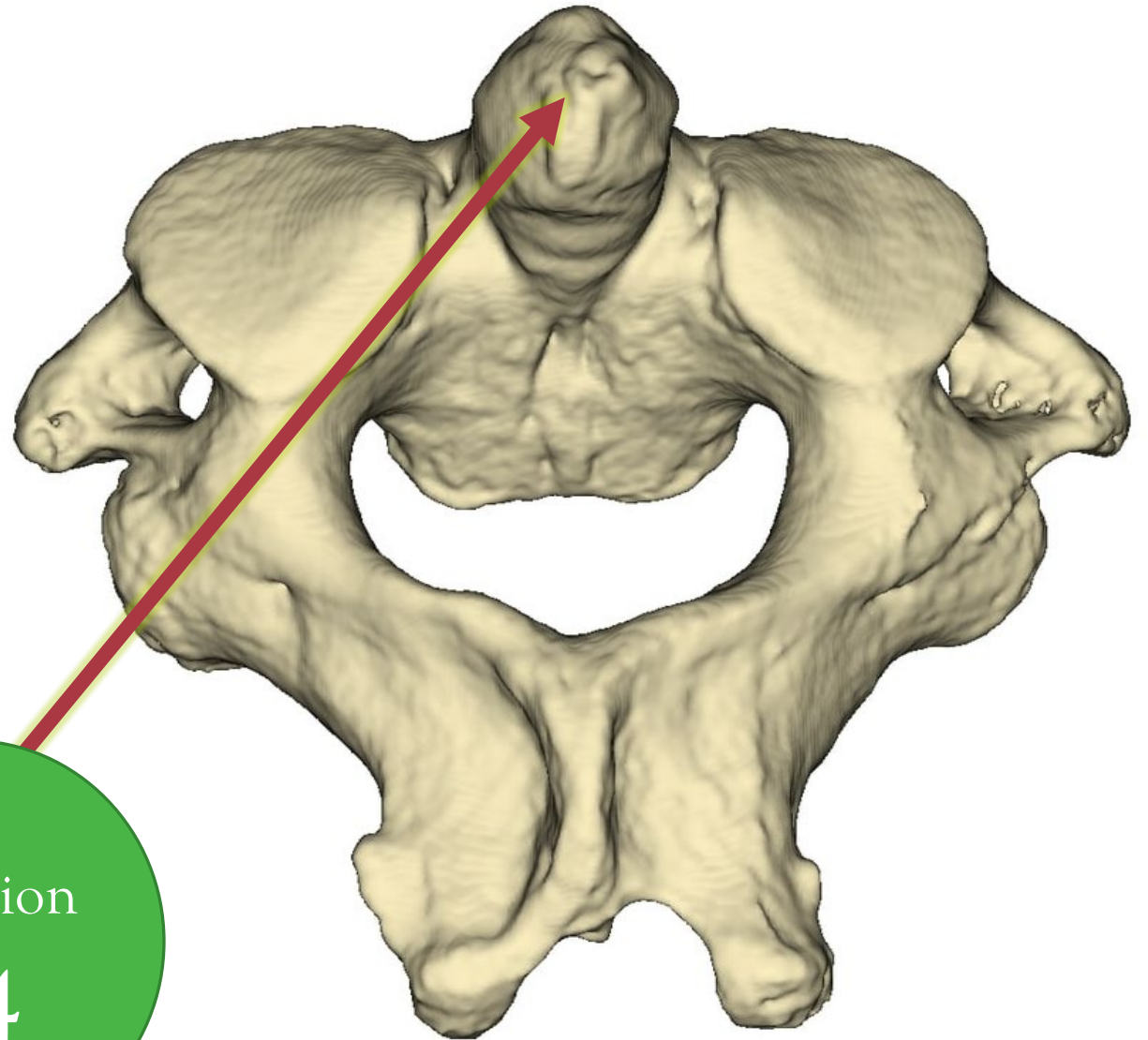
Dens

Transverse process

Spinous process

Body

Transverse process



Question

34

Identify the BONE.

Ulna

Humerus


Radius

Fibula

Clavicle

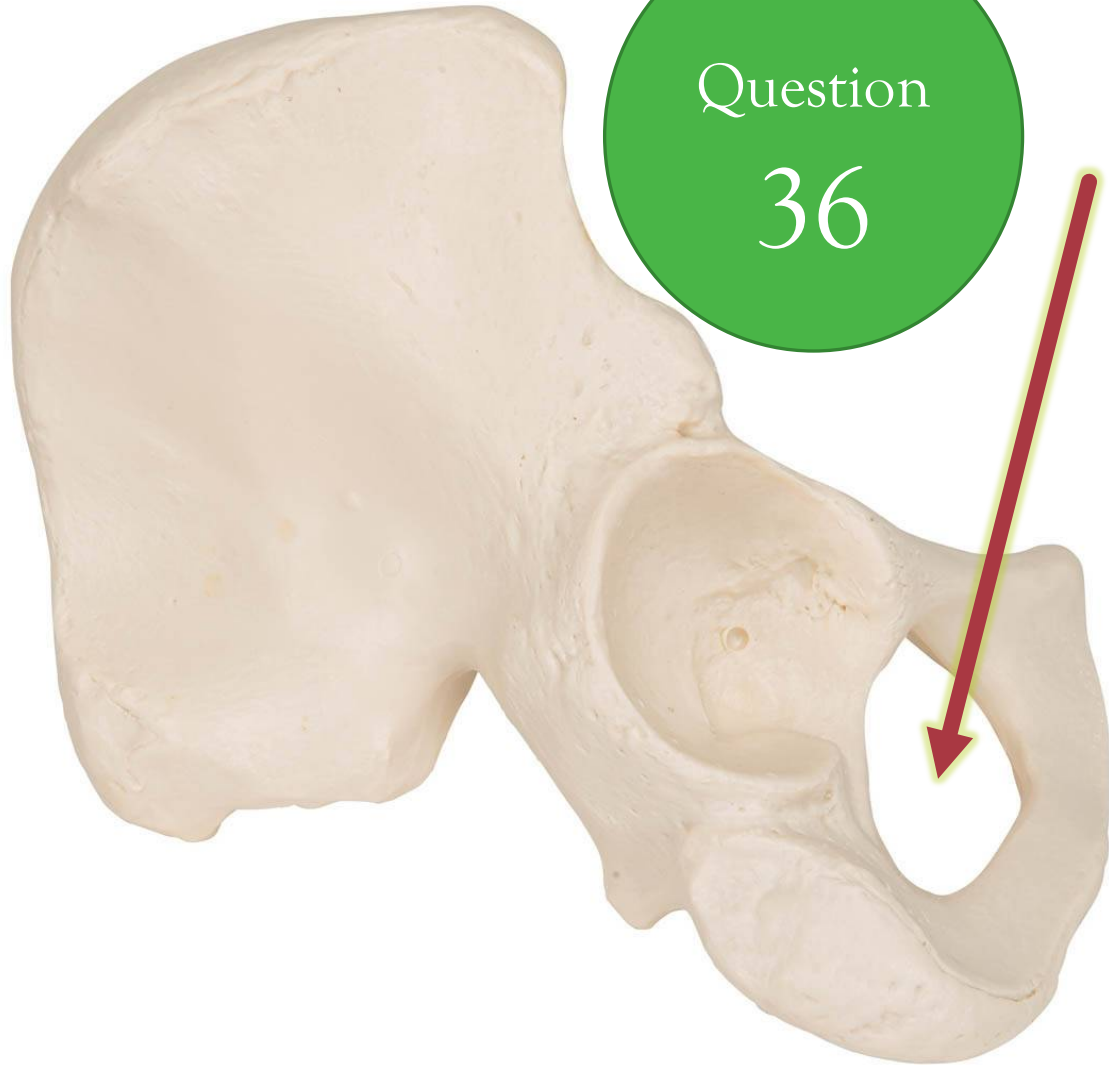
Question

35



Question

36



Identify the **STRUCTURE**.

Foramen magnum

Transverse foramen

Obturator Foramen

Os Coxae

Acetabulum

Question

37

Identify the **STRUCTURE**.

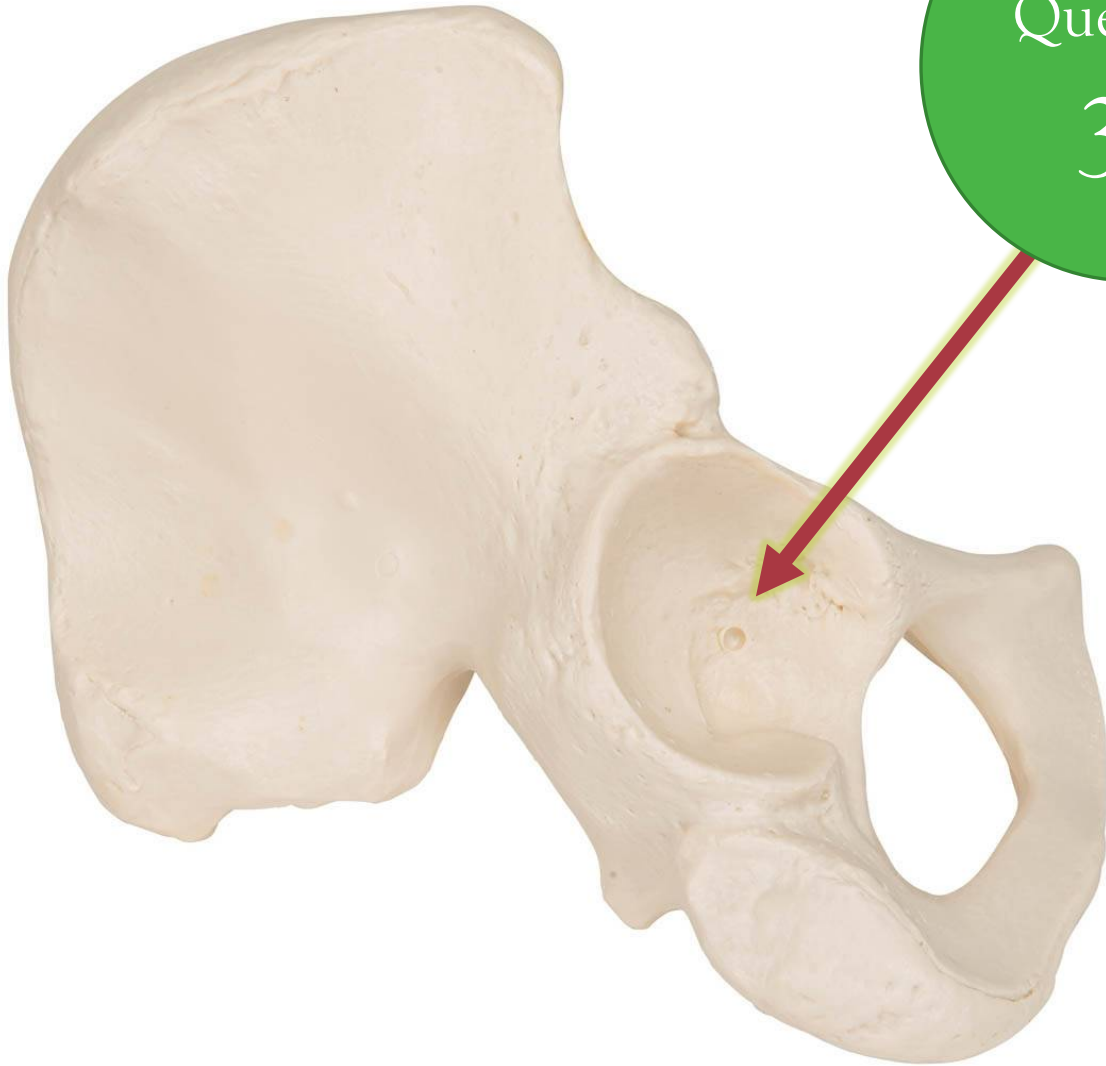Foramen magnum

Transverse foramen

Obturator Foramen

Os Coxae

Acetabulum



Question

38

Identify the **STRUCTURE**.

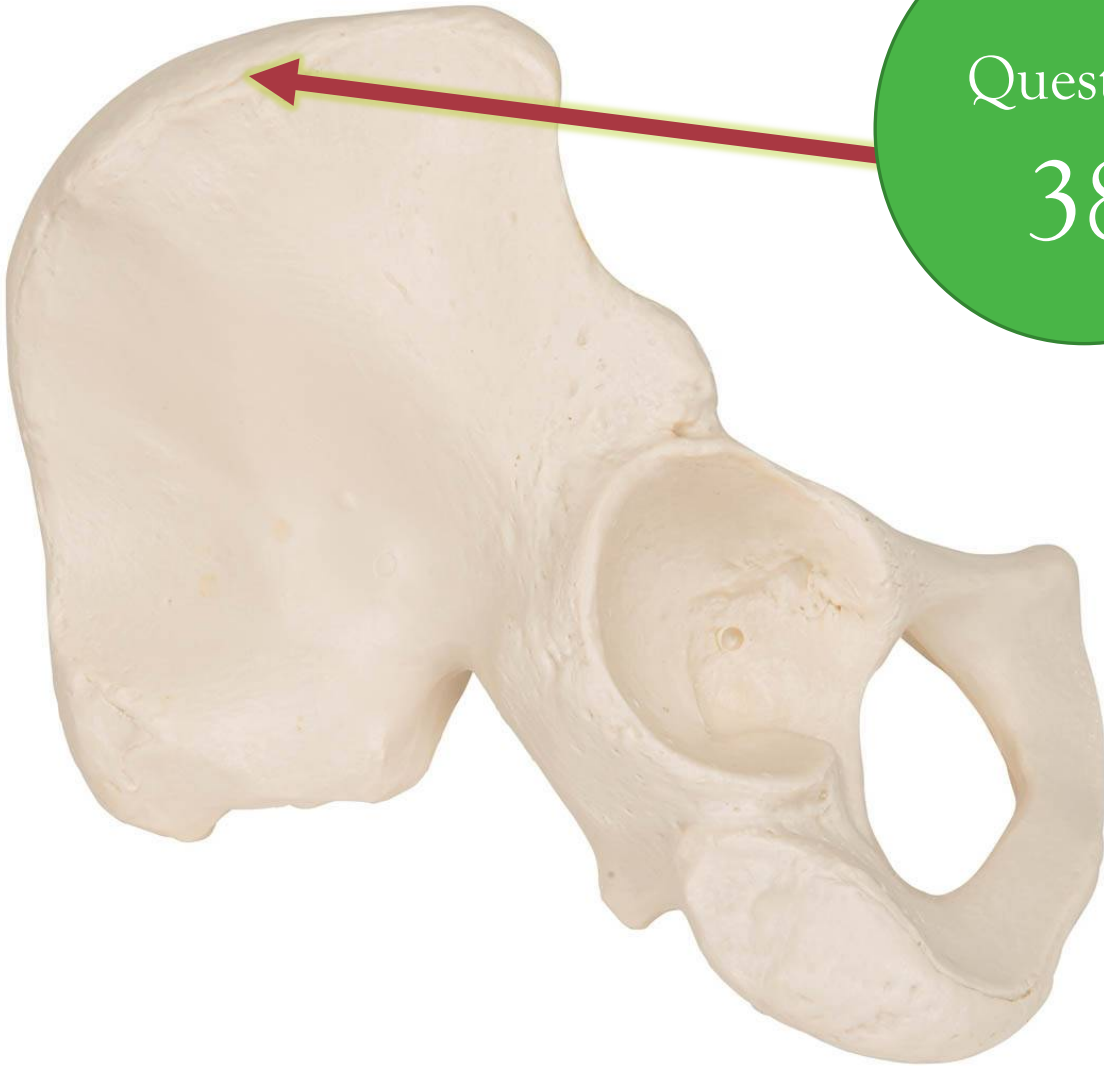Iliac crest

Spinous process

Ischial spine

Coxa Fossa

Acetabulum



Identify the STRUCTURE.

Question

39

Femoral Head

Humeral Head

Head of the Radius

Head of the Tibia

Head of the fibula



Question

40

Identify the STRUCTURE.

Lesser trochanter

Greater tubercle

Greater trochanter

Lesser tubercle

Trochlea



Question

41

Identify the STRUCTURE.

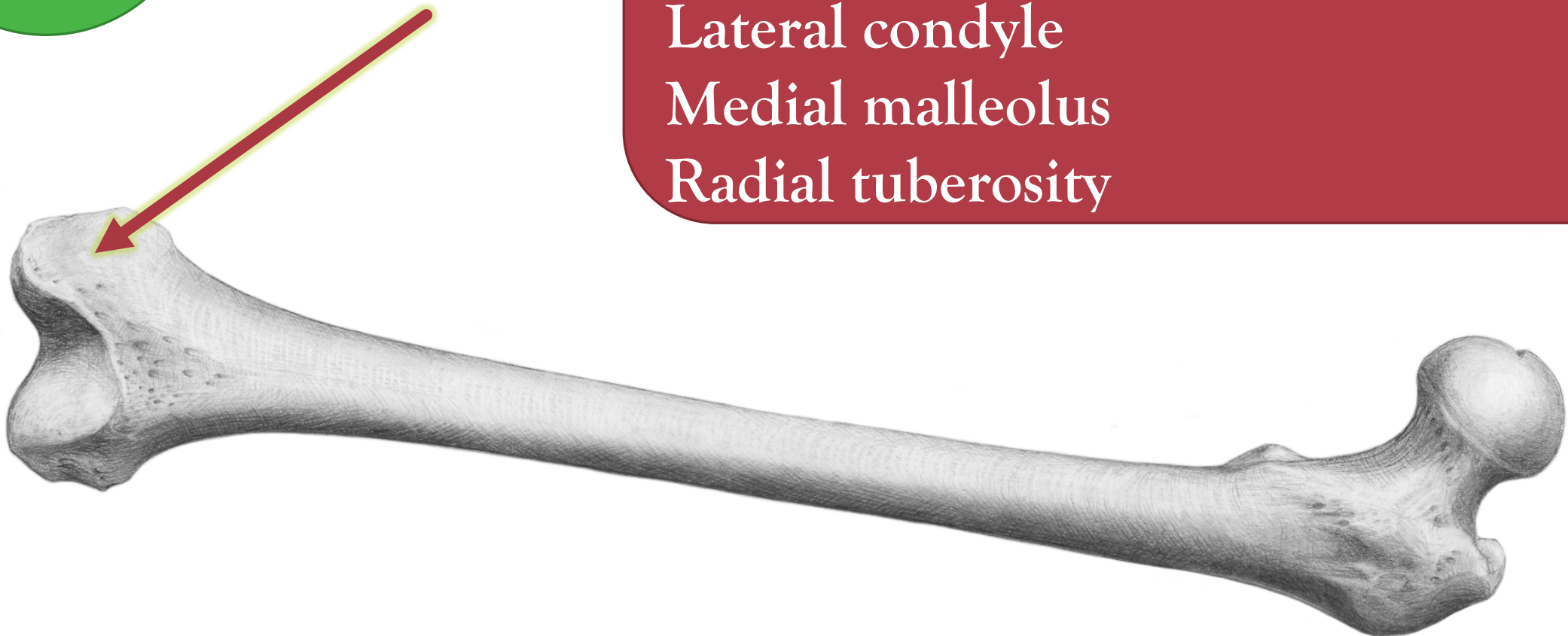
Medial condyle

Lateral fossa

Lateral condyle

Medial malleolus

Radial tuberosity



Question

42

Identify the STRUCTURE.

Medial condyle

Lateral fossa

Lateral condyle

Medial malleolus

Radial tuberosity



Identify the **STRUCTURE**.

- Medial condyle
- Lateral fossa
- Lateral condyle
- Medial malleolus
- Radial tuberosity

Question

43



Identify the **STRUCTURE**.

Femoral Head

Humeral Head

Head of the Radius

Head of the Tibia

Head of the fibula

Question

44



Identify the STRUCTURE.

- Medial condyle
- Lateral fossa
- Lateral condyle
- Medial malleolus
- Radial tuberosity

Question

45



Identify the
STRUCTURE.

Question

46

Olecranon process

Coracoid process

Coronoid process

Trochlear notch

Radial tuberosity

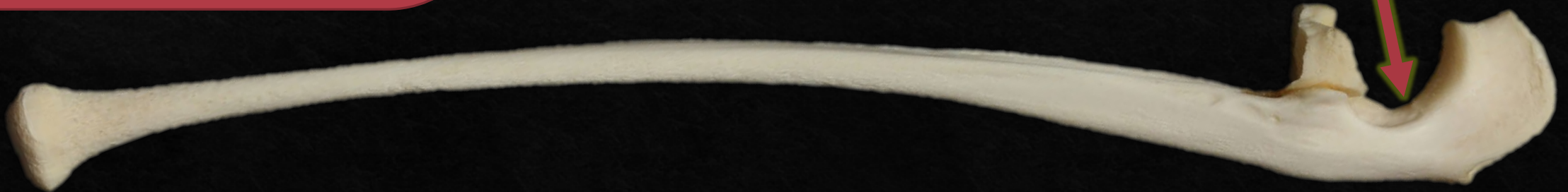

Identify the
STRUCTURE.

- Olecranon process
- Coracoid process
- Coronoid process
- Trochlear notch
- Radial tuberosity

Question

47



Identify the
STRUCTURE.

- Olecranon process
- Coracoid process
- Coronoid process
- Trochlear notch
- Radial tuberosity

Question

48



What is the BONE?

Temporal Bone

Occipital Bone

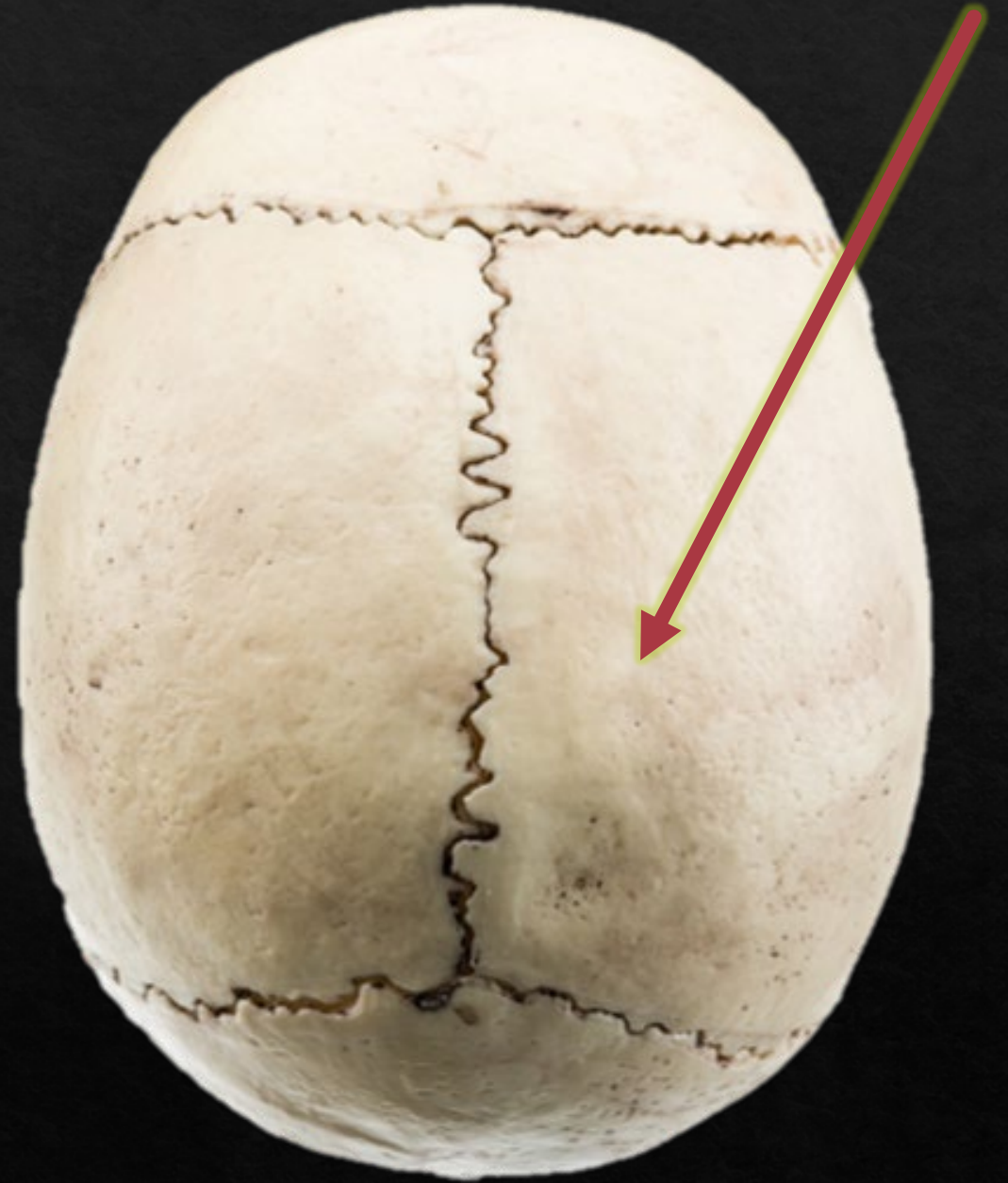Sphenoid

Palatine Bone

Parietal Bone

Question

49



What is the BONE?

Temporal Bone
Occipital Bone
Frontal Bone
Palatine Bone
Ethmoid

Question

50

