

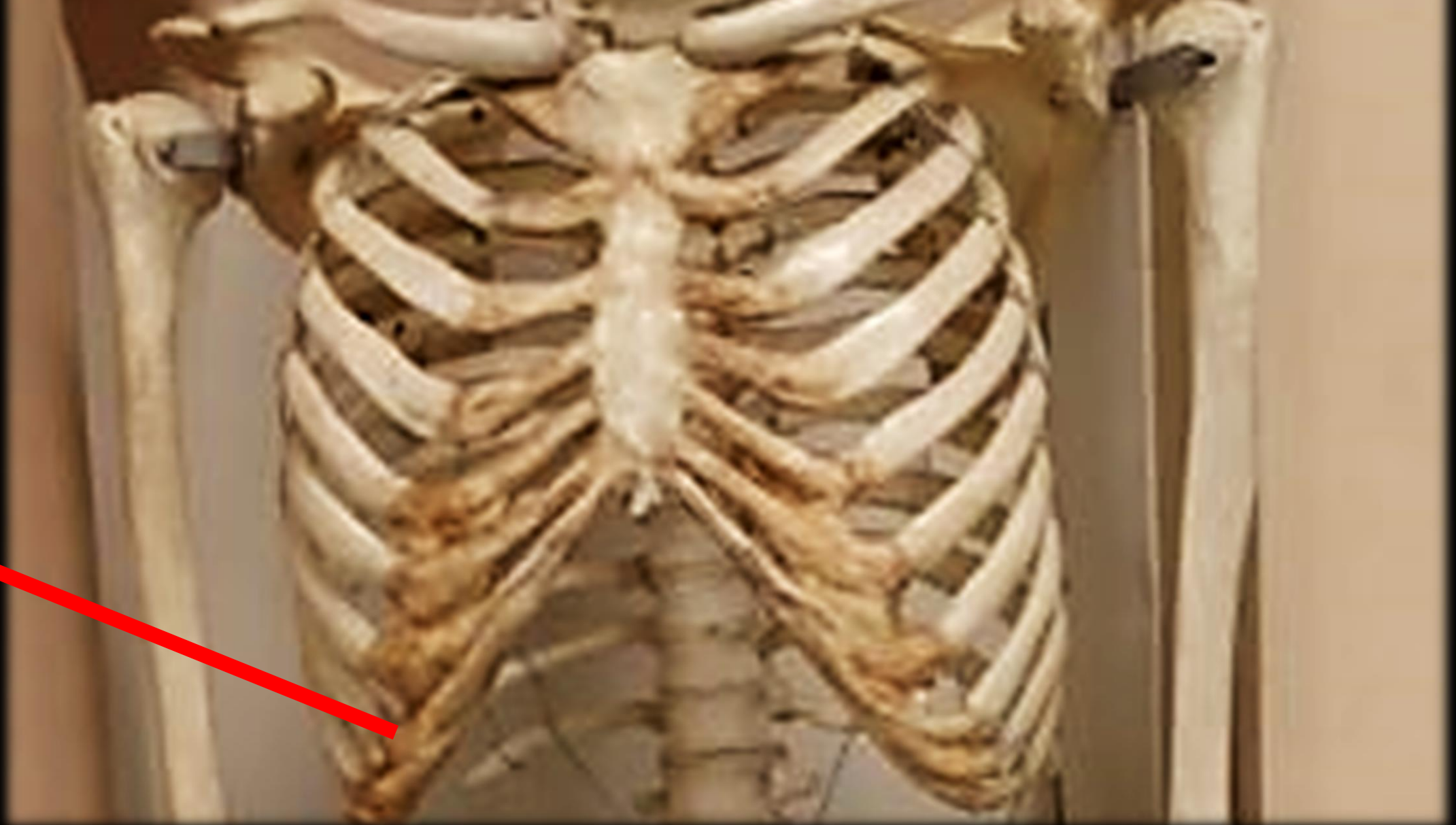
by Scientist Cindy

---

# Photo Album



*What TYPE of rib is this?*

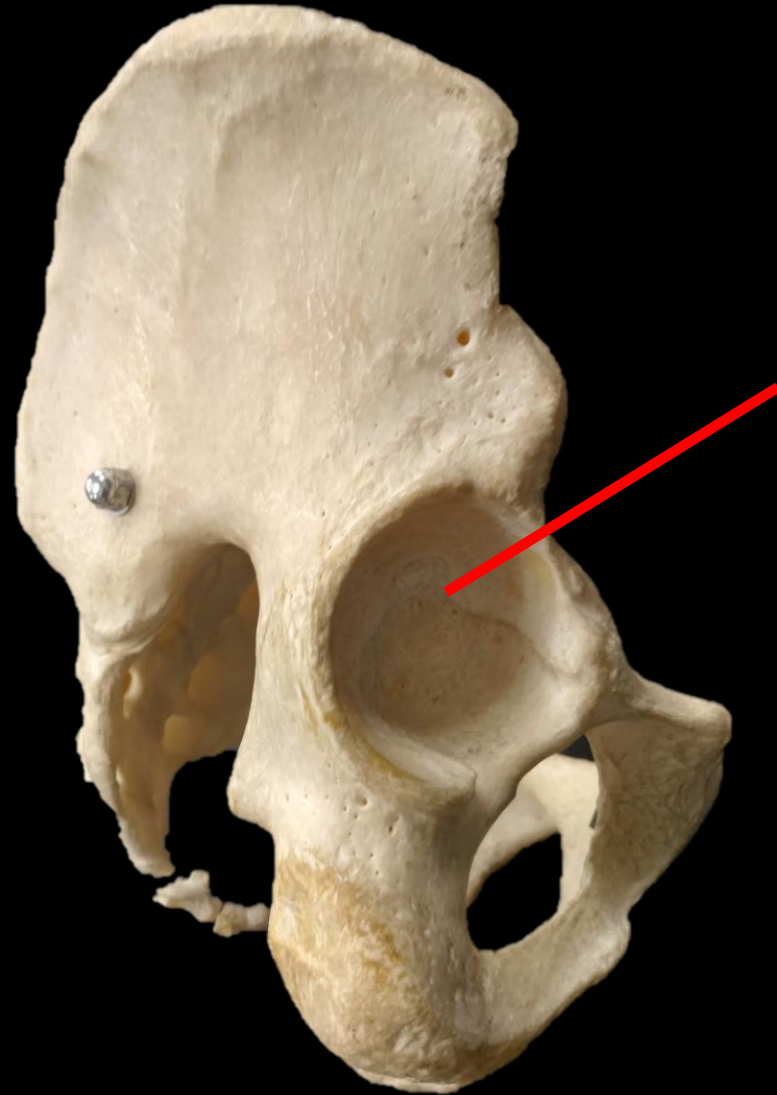


*What TYPE of rib is this?*

*False Rib*

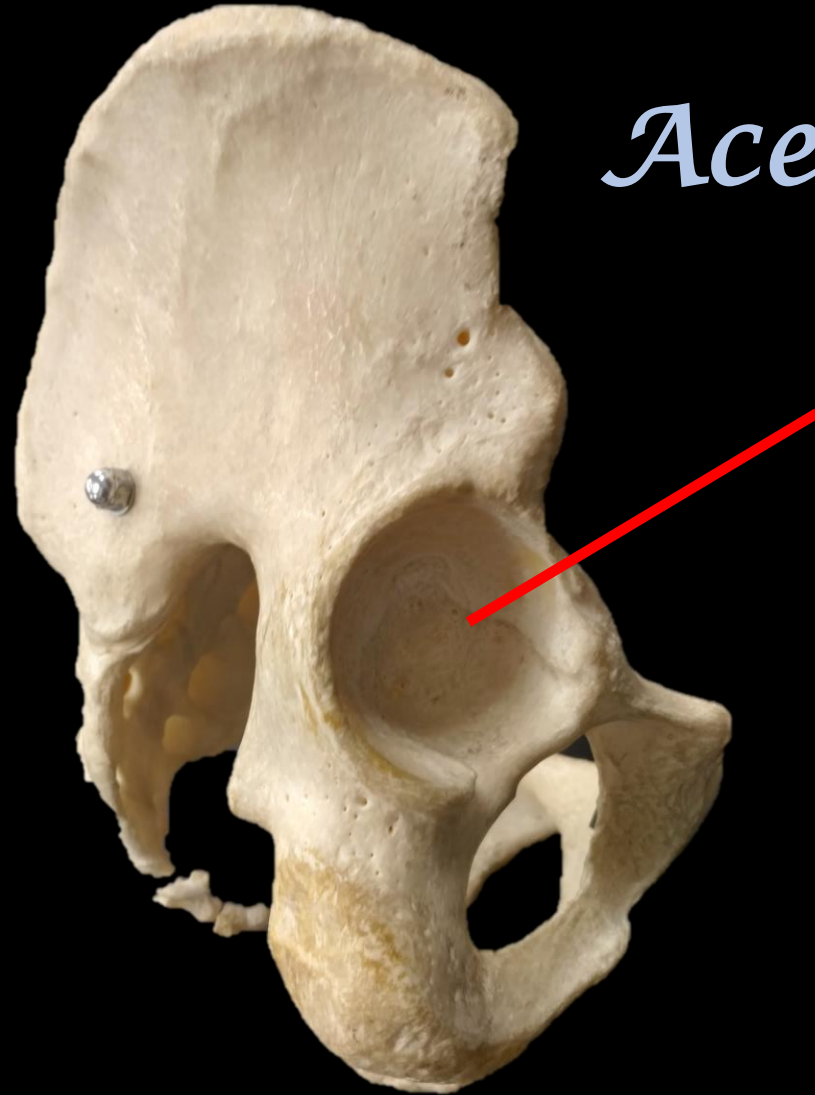

*What is the Bone? What is the Structure?*



*What is the Bone? What is the Structure?*

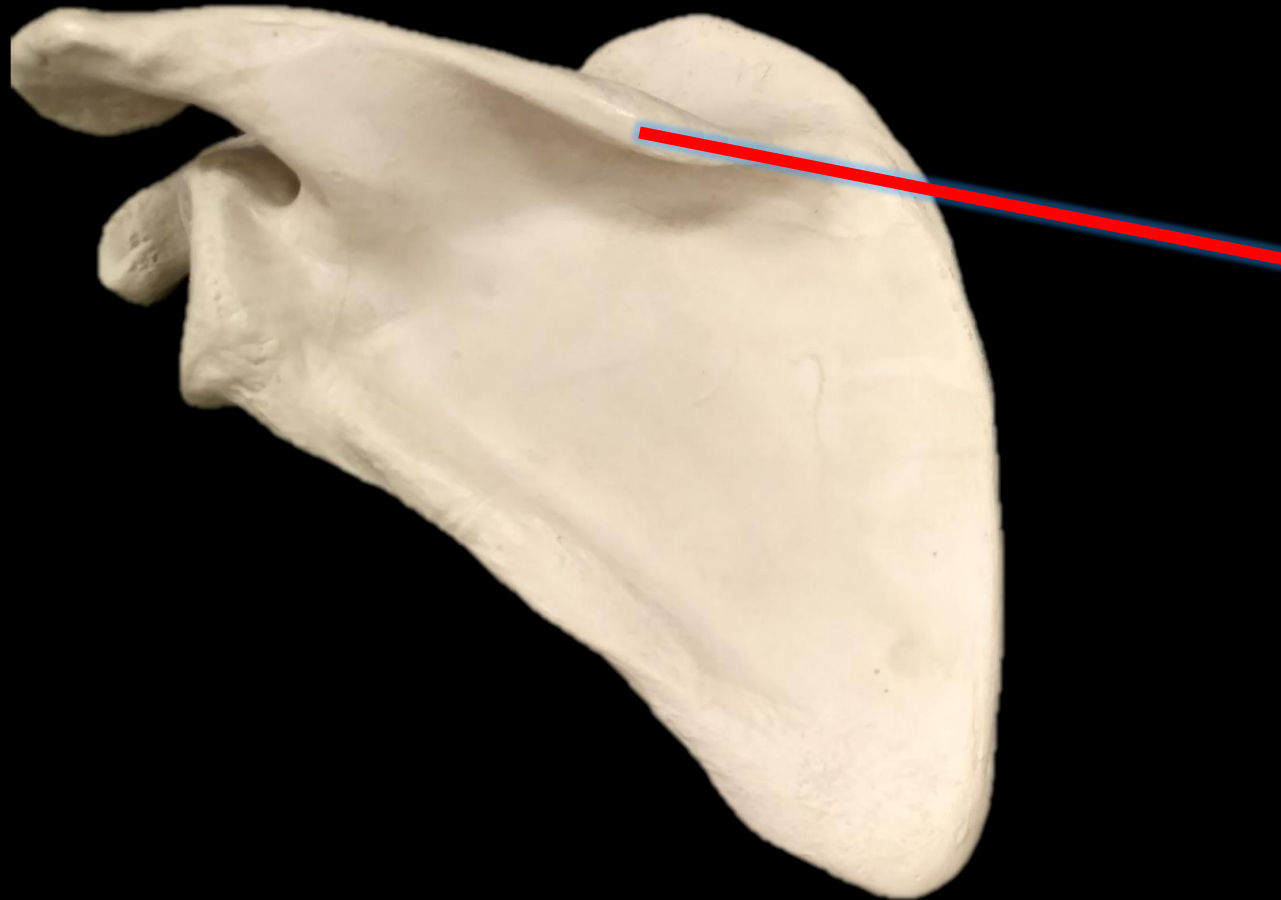
*The Coxal  
Bone*



*Acetabulum*

*What is the Bone?*

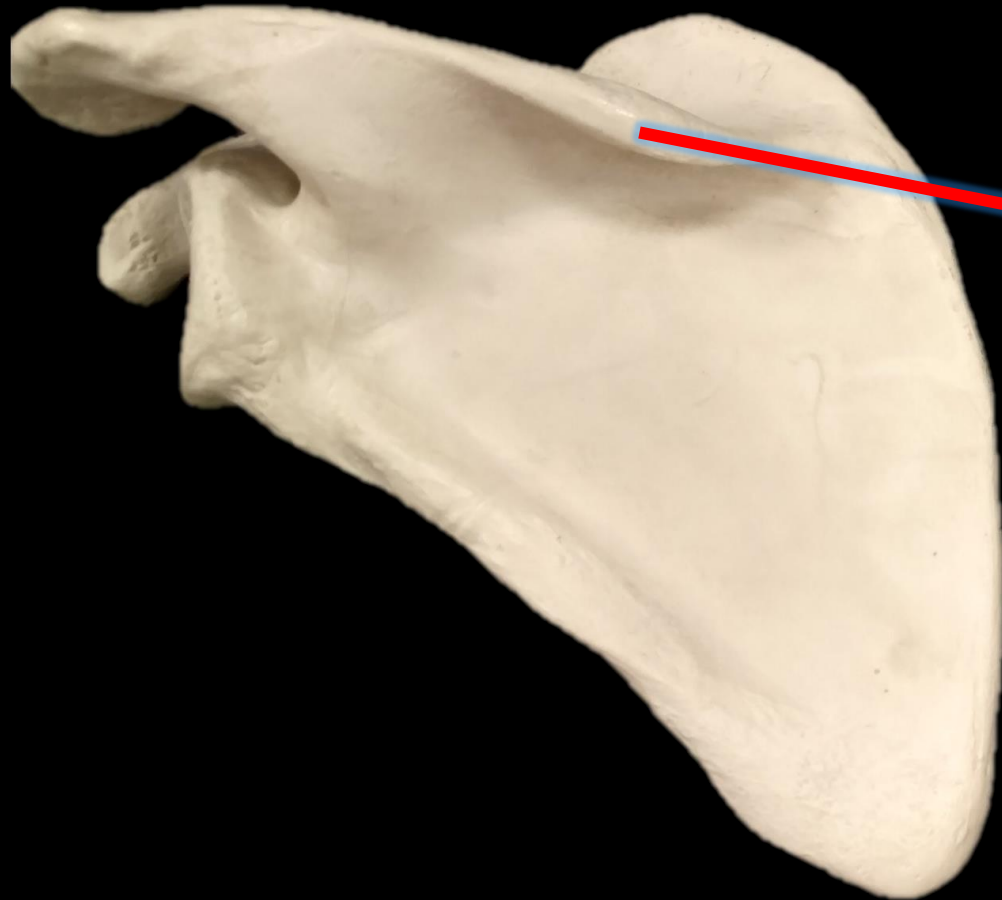
*What is the Structure?*



*What is the Bone?*

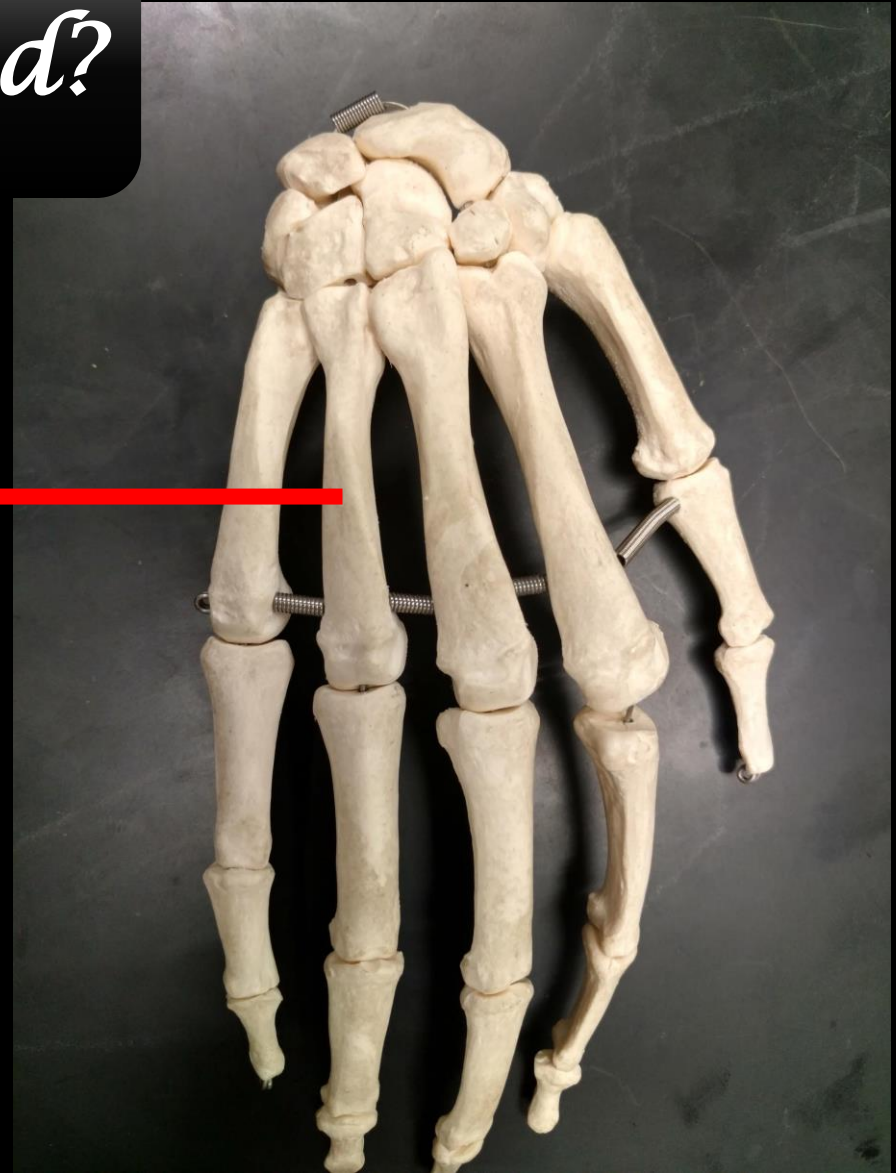*What is the Structure?*

*Bone = Scapula*



*Spine of the  
Scapula*

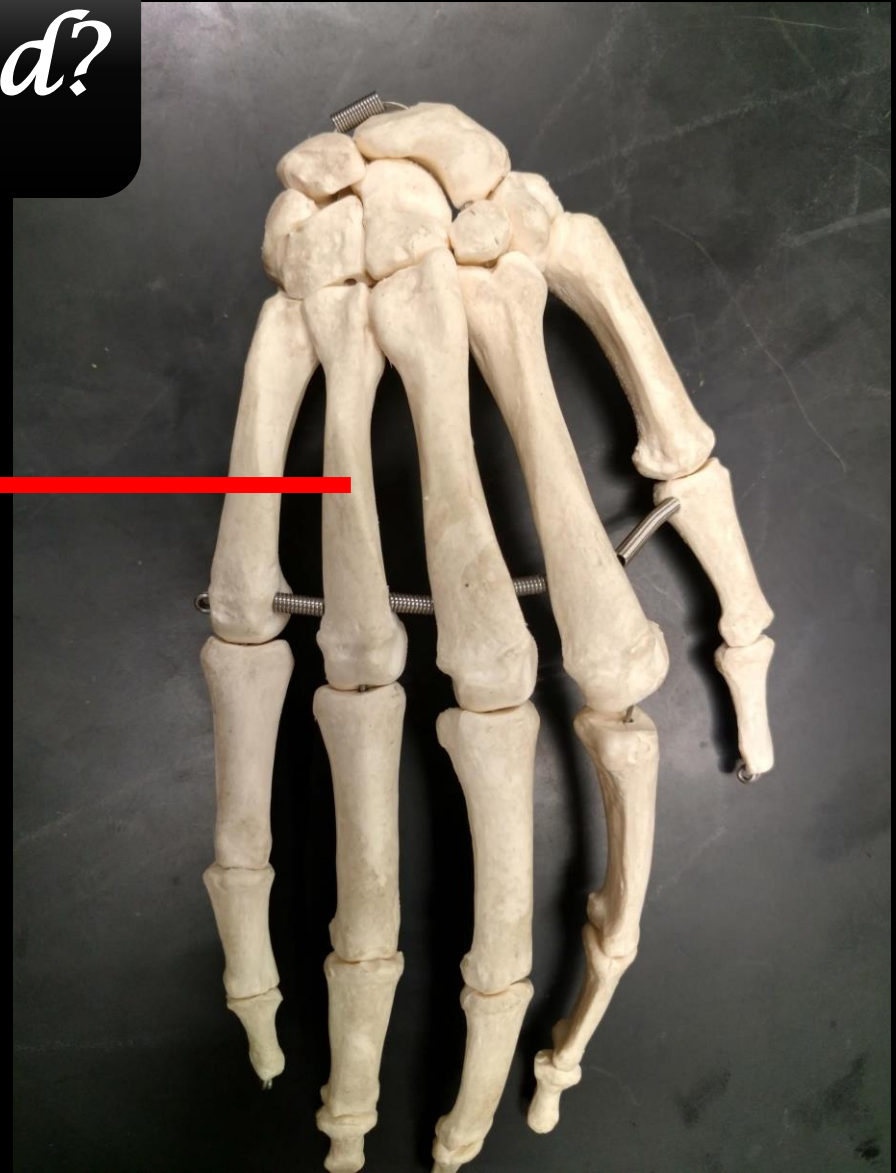
*What are these Bones called?*



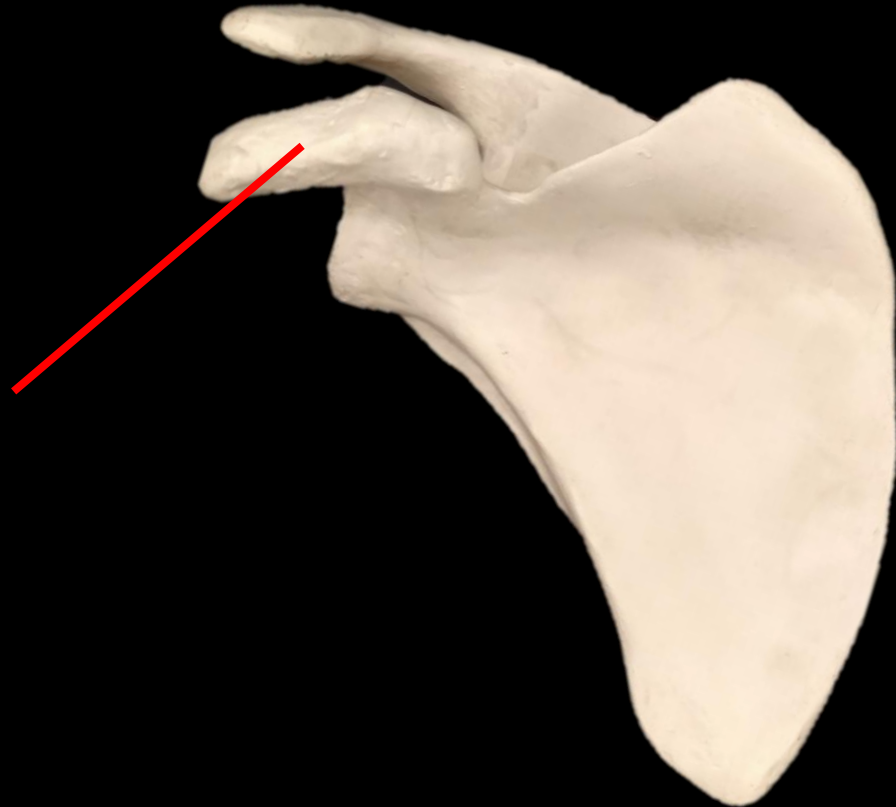


*What are these Bones called?*

*Metacarpals*



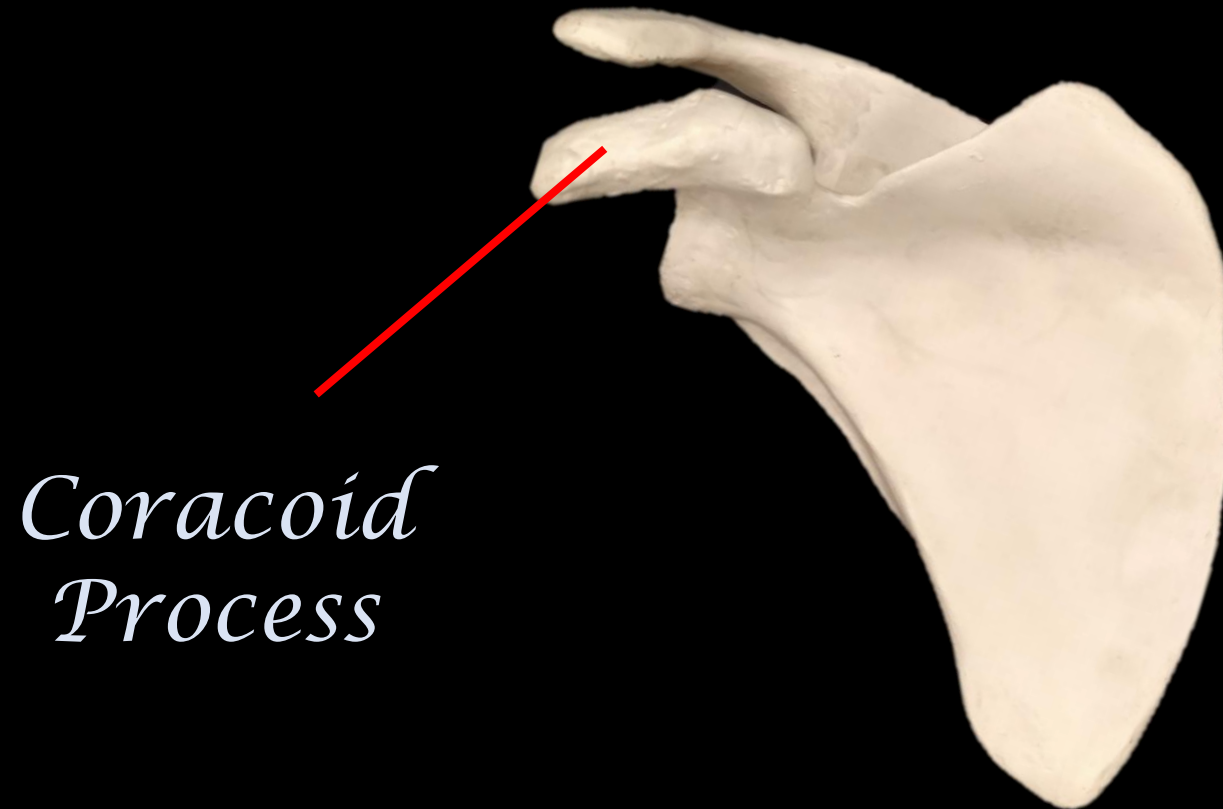
*What is the Bone?*  
*What is the Structure?*



*What is the Bone?*

*What is the Structure?*

*This is the scapula.*



*Coracoid  
Process*

**What is the Bone?**



**What is the Structure?**

**What is the Bone?**

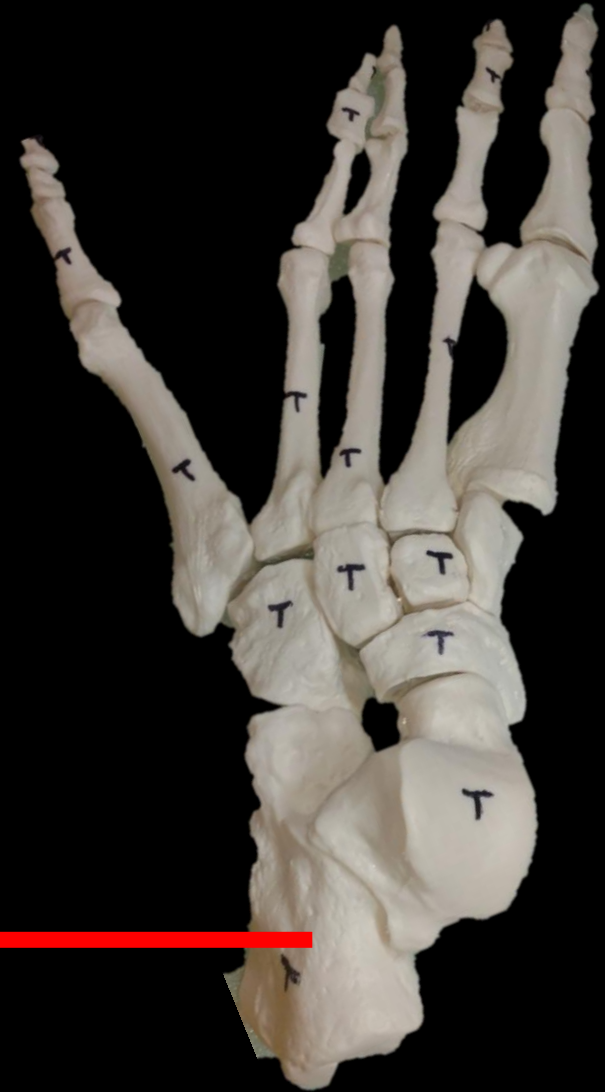**The Humerus**



**What is the Structure?**

**The Coronoid Fossa**

*What are these Bones called?*

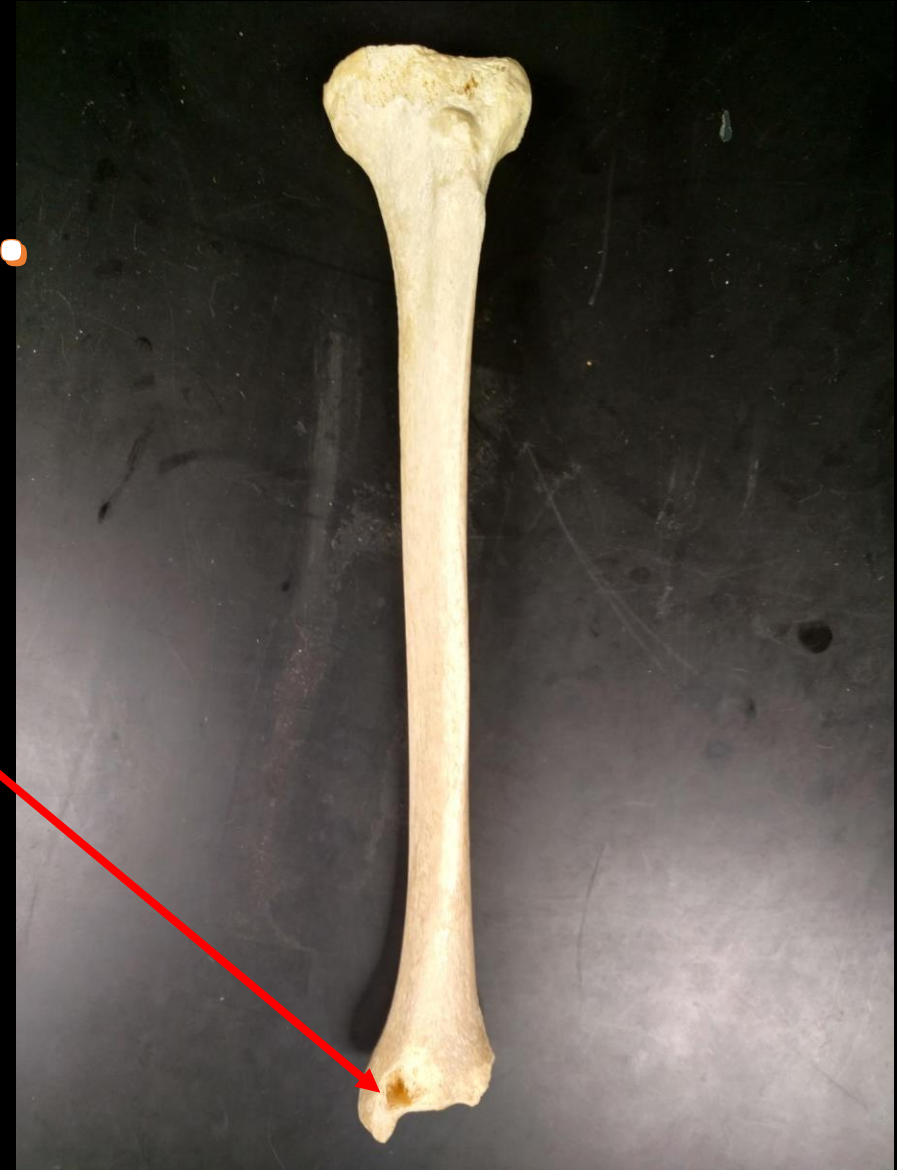

*What are these Bones called?*

*Calcaneas*



**Identify the Bone.**  
**Identify the Structure.**

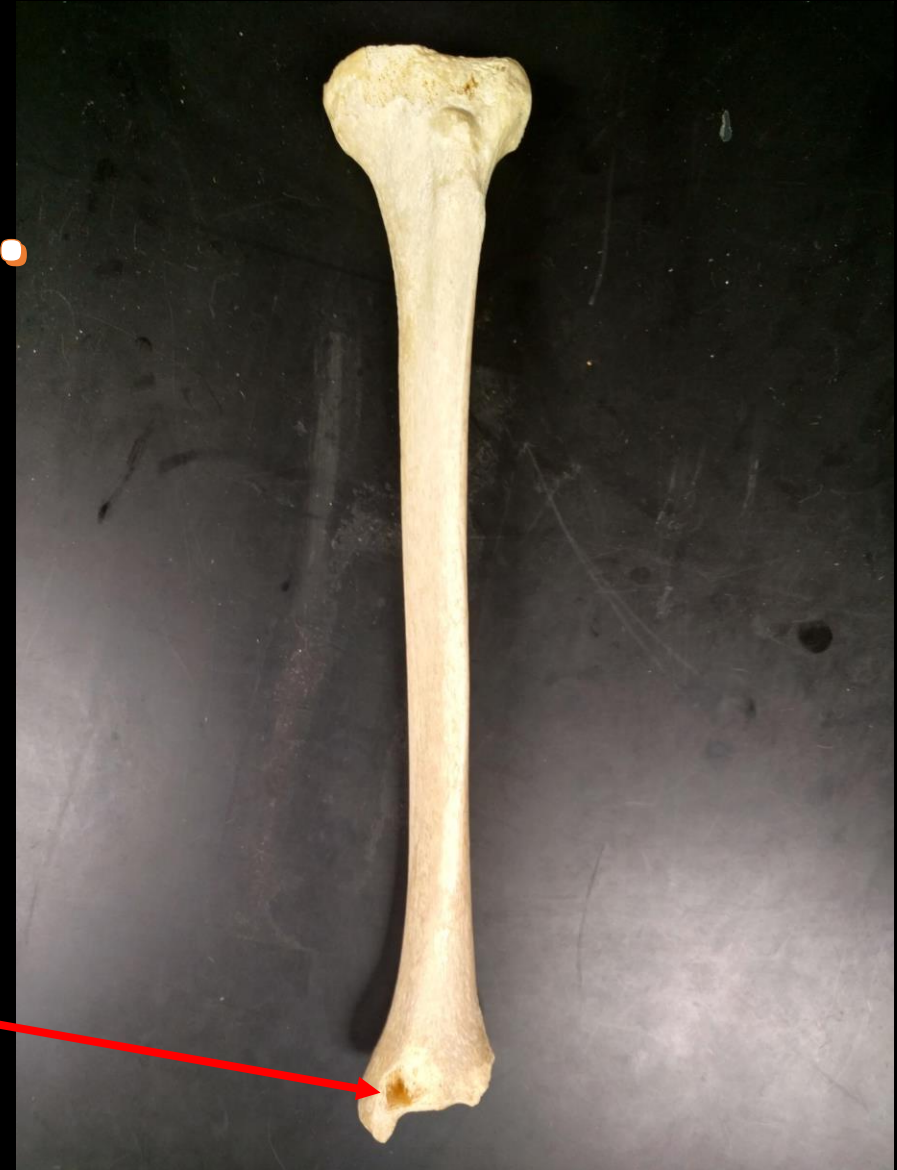



**Identify the Bone.**  
**Identify the Structure.**

**Bone = Tibia**

**Medial  
Malleolus**



**What is the Bone?**



**What is the Structure?**

**What is the Bone?**

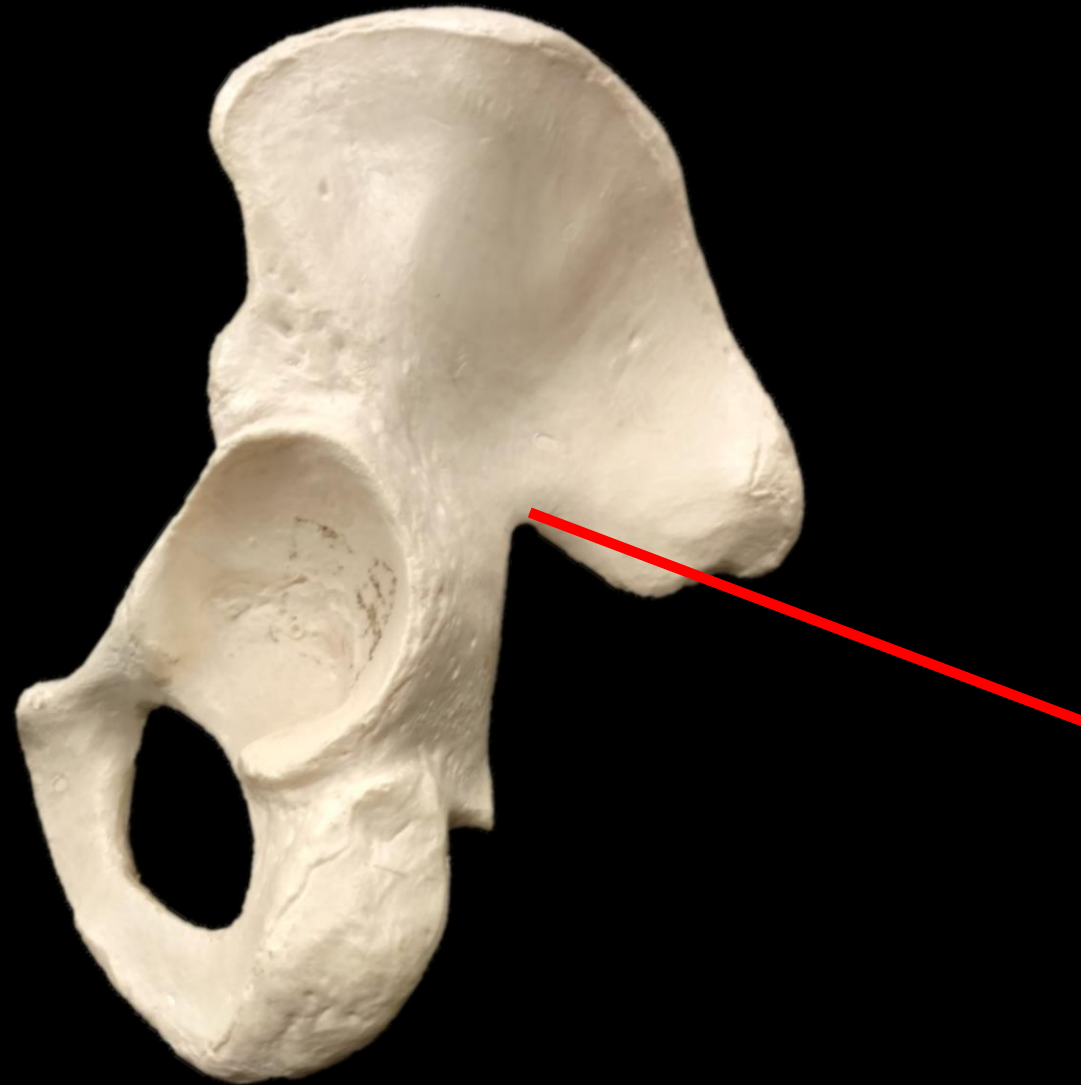
**The Humerus**



**What is the Structure?**

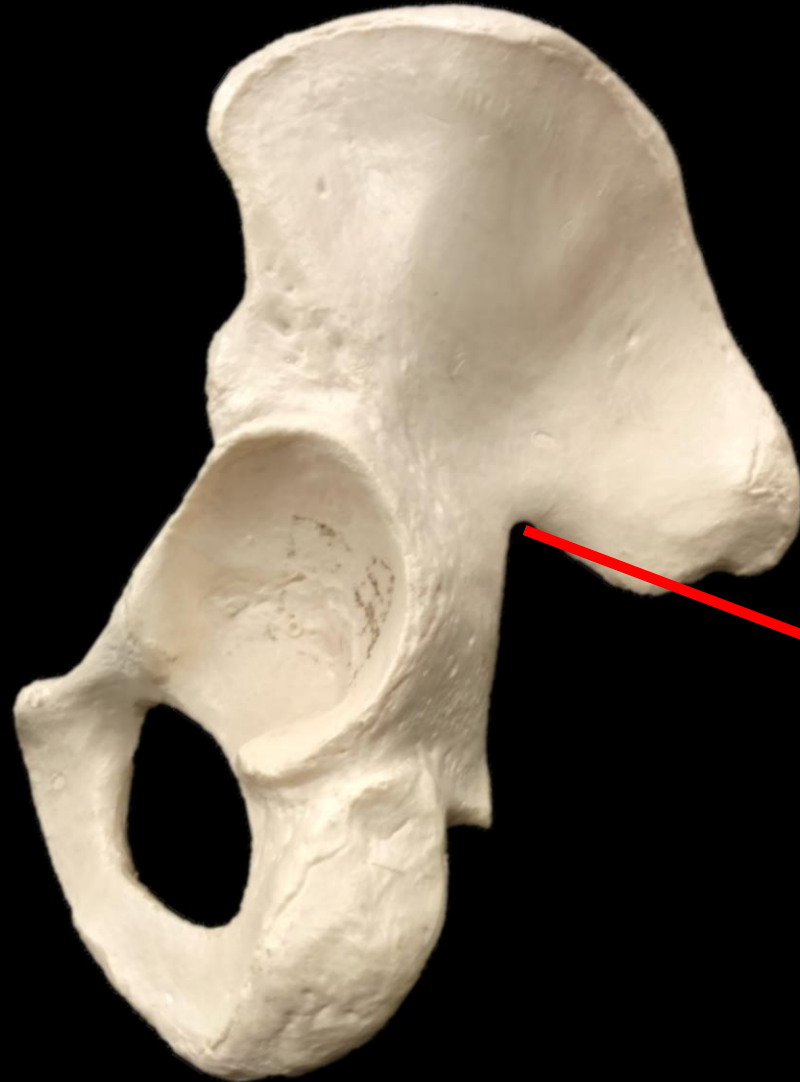**The Trochlea**

*What is the Bone? What is the Structure?*



*What is the Bone? What is the Structure?*

*The Coxal  
Bone*



*The Greater  
Sciatic Notch*

**What is the Bone?**



**What is the Structure?**

**What is the Bone?**

**Radius**

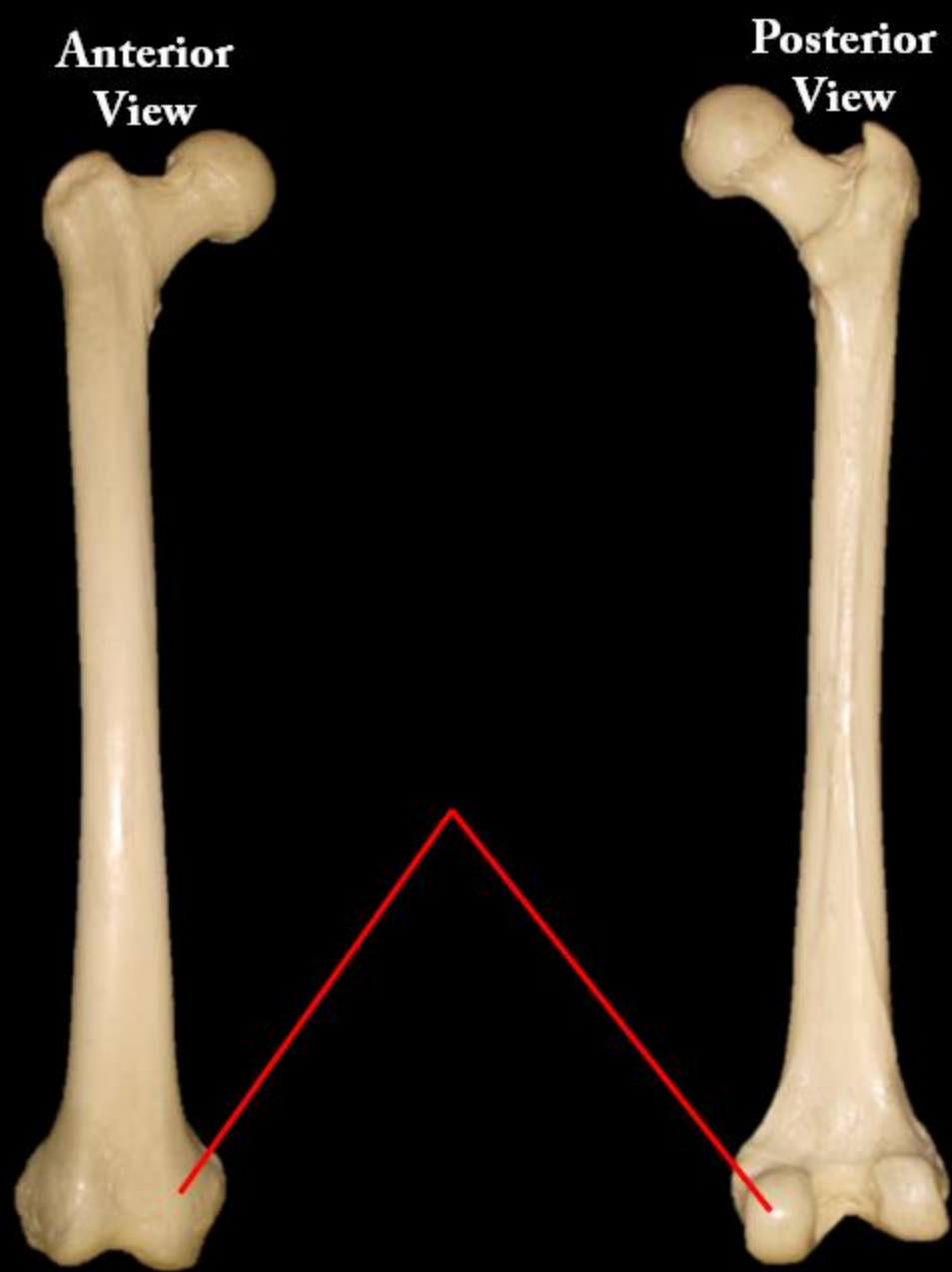


**What is the Structure?**

**The Head of the Radius**

Name the Bone

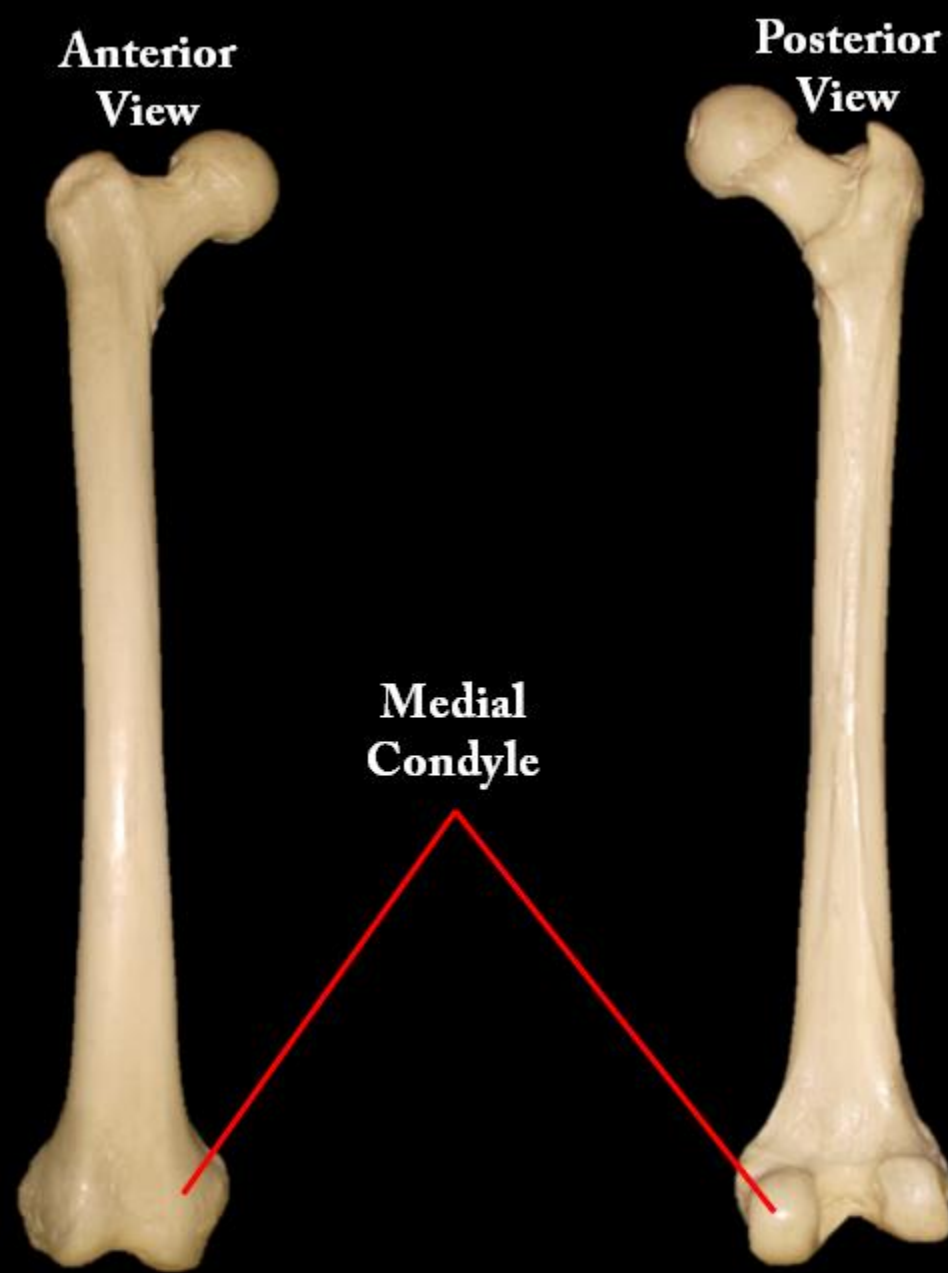
Name the Structure





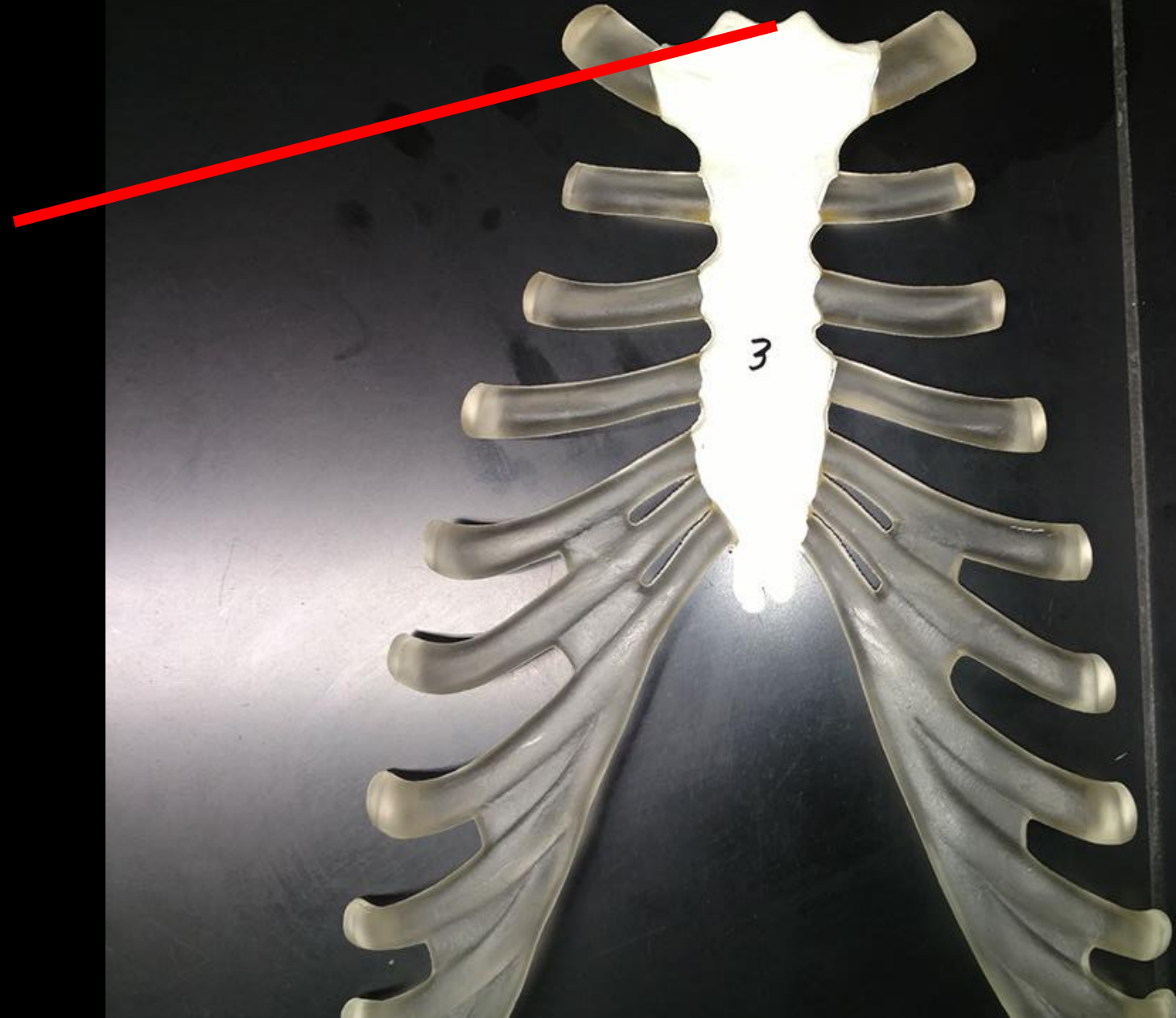
Name the Bone  
= Femur

Name the Structure  
= Medial Condyle



What is the  
Bone?

What is the  
Structure?

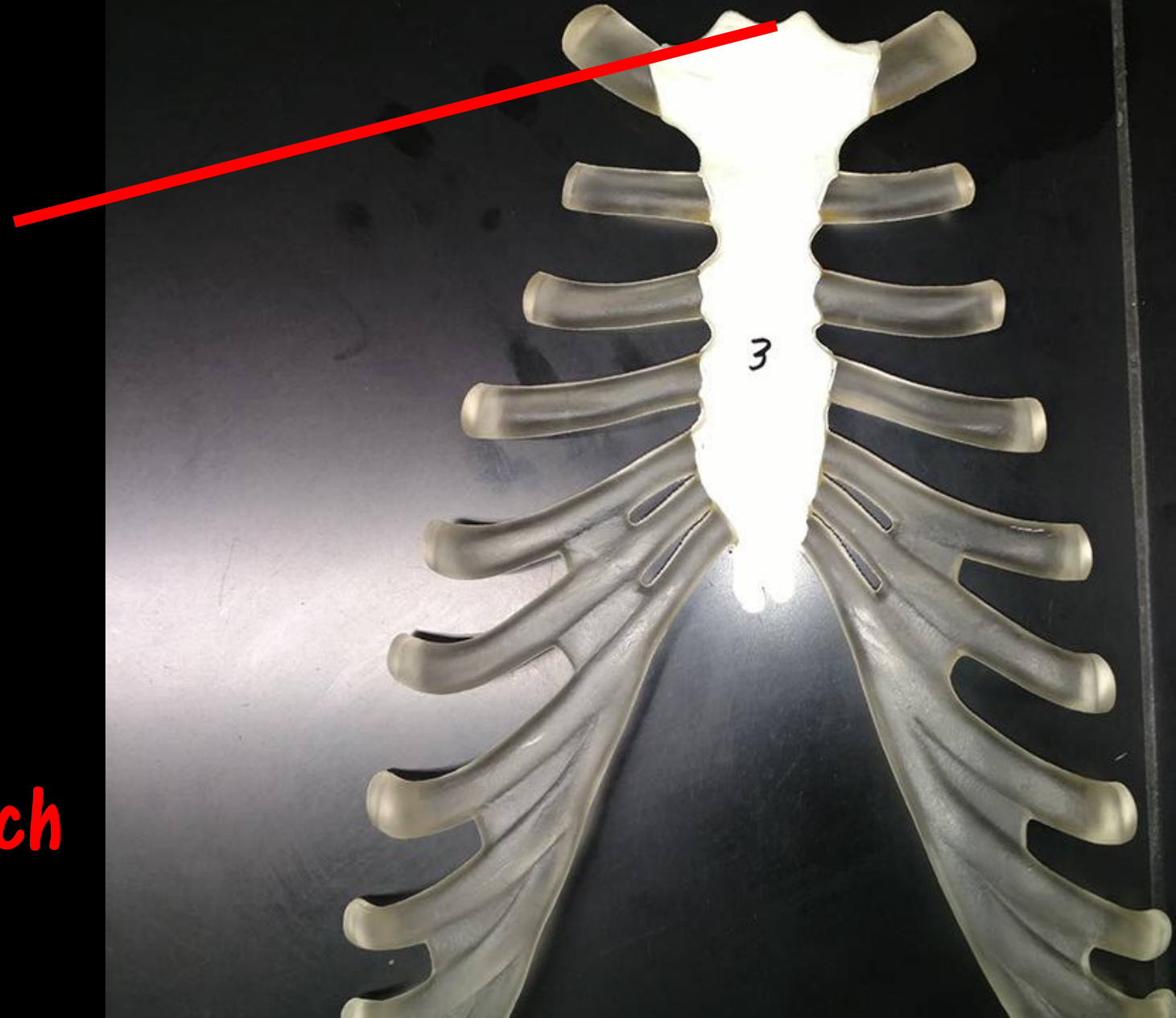


What is the  
Bone?

**Sternum**

What is the  
Structure?

**Jugular Notch**



**What is the Bone?**



**What is the Structure?**

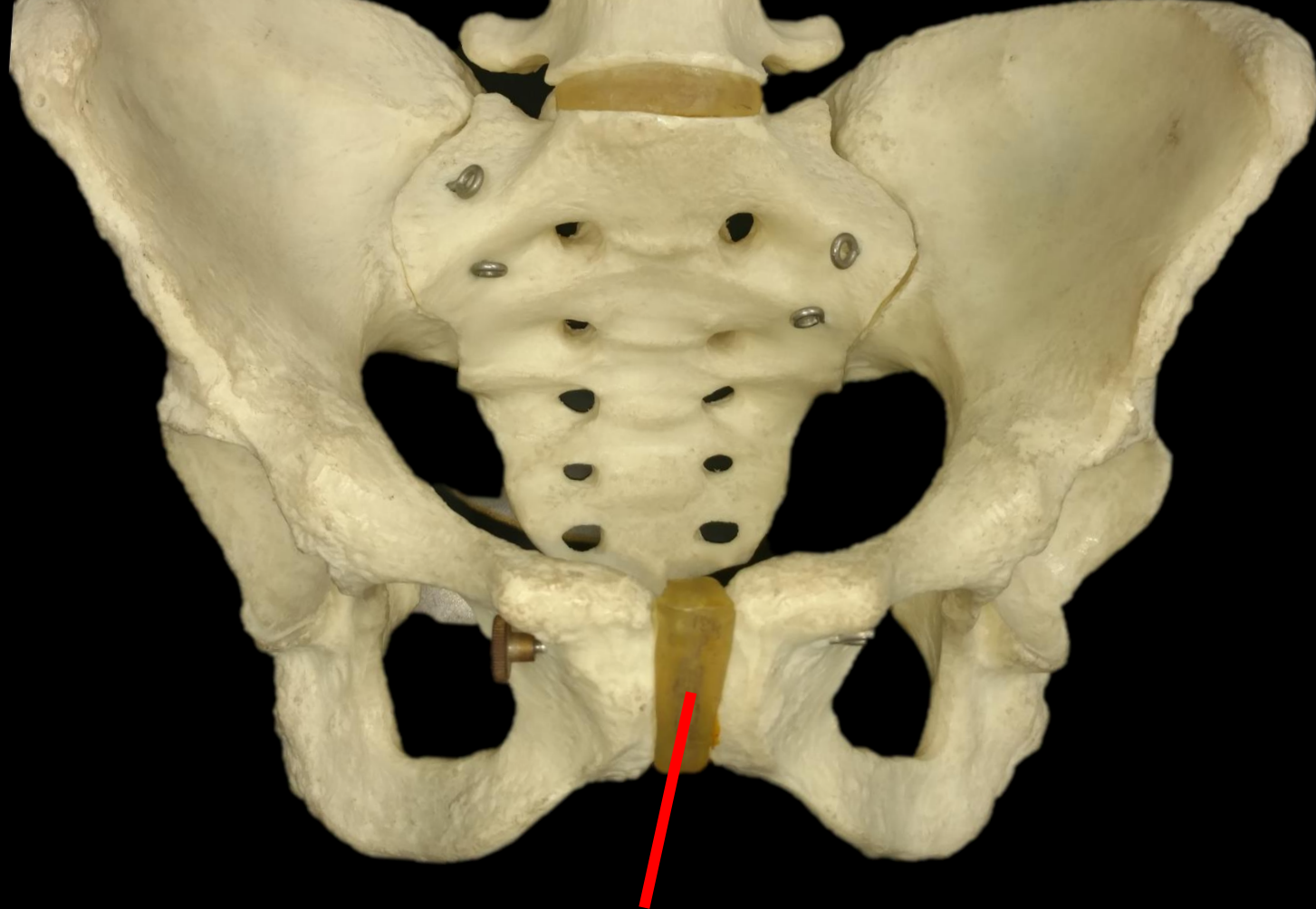
**What is the Bone?**

**The Humerus**

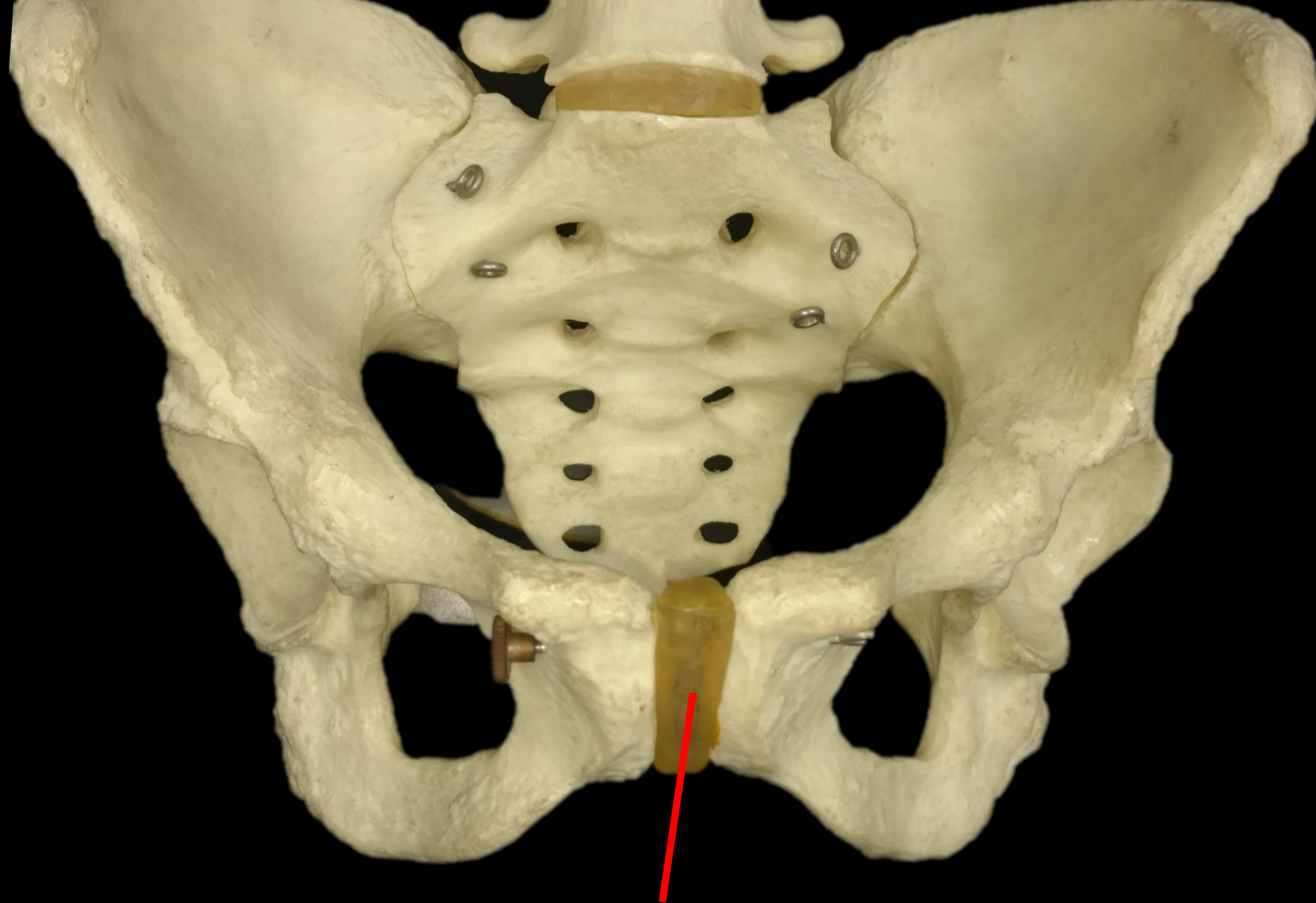


**What is the Structure?**

**Lesser Tubercle**

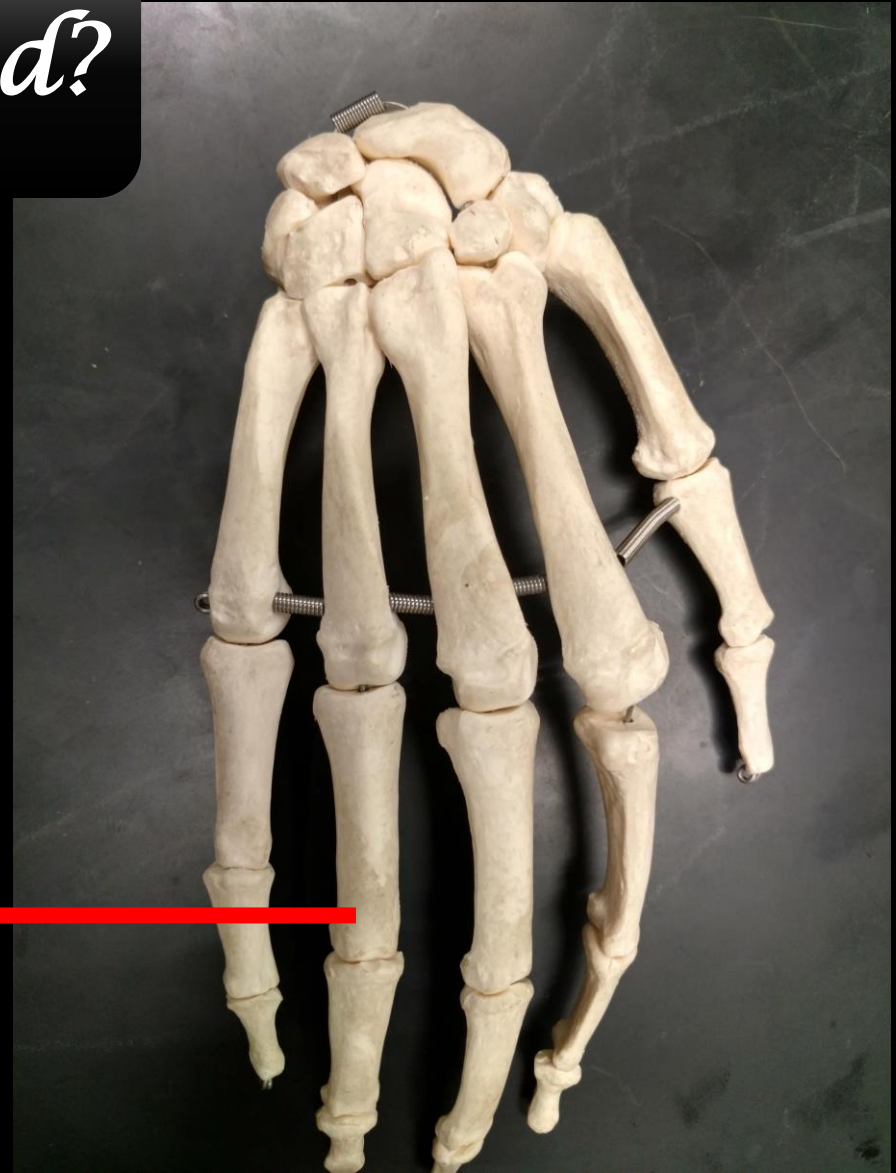

*What is this?*



*Pubic Symphysis*

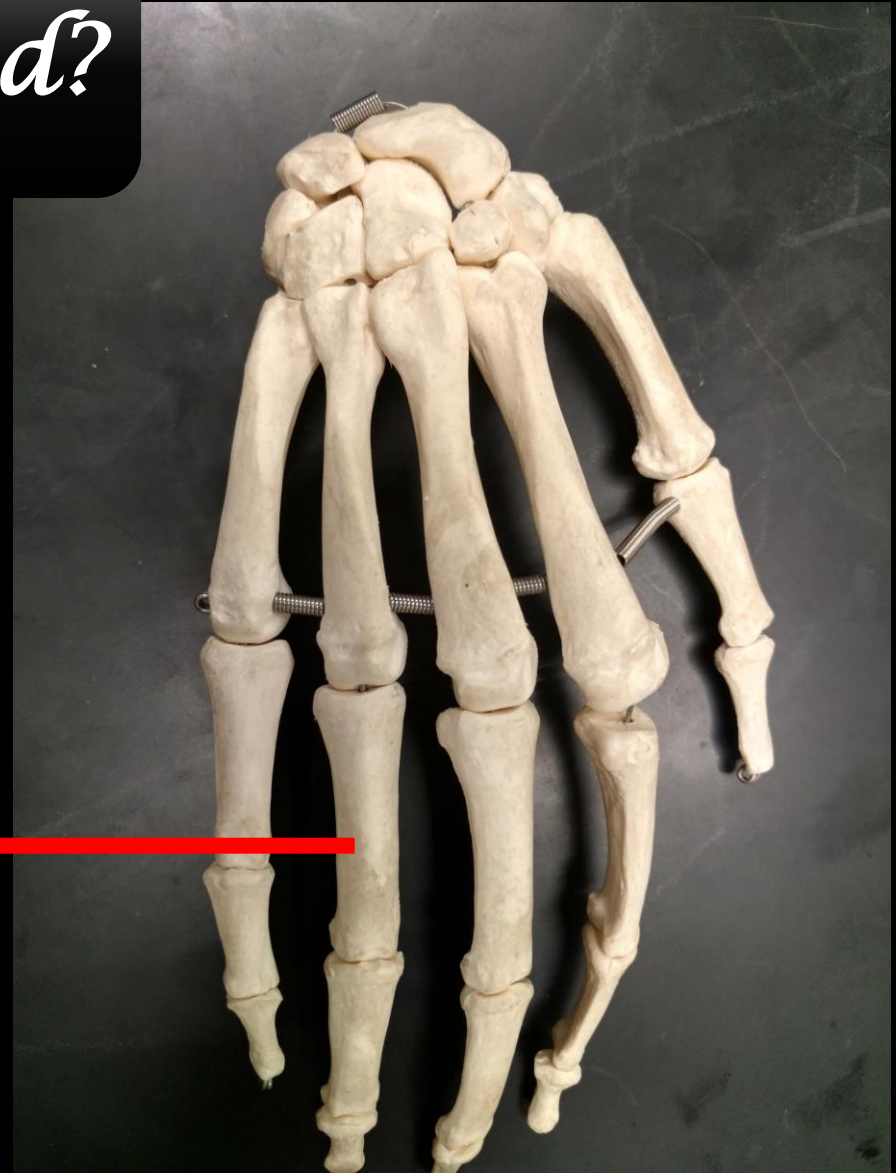
*What are these Bones called?*





*What are these Bones called?*

*Phalanges*



**What is the Bone?**



**What is the Structure?**

**What is the Bone?**

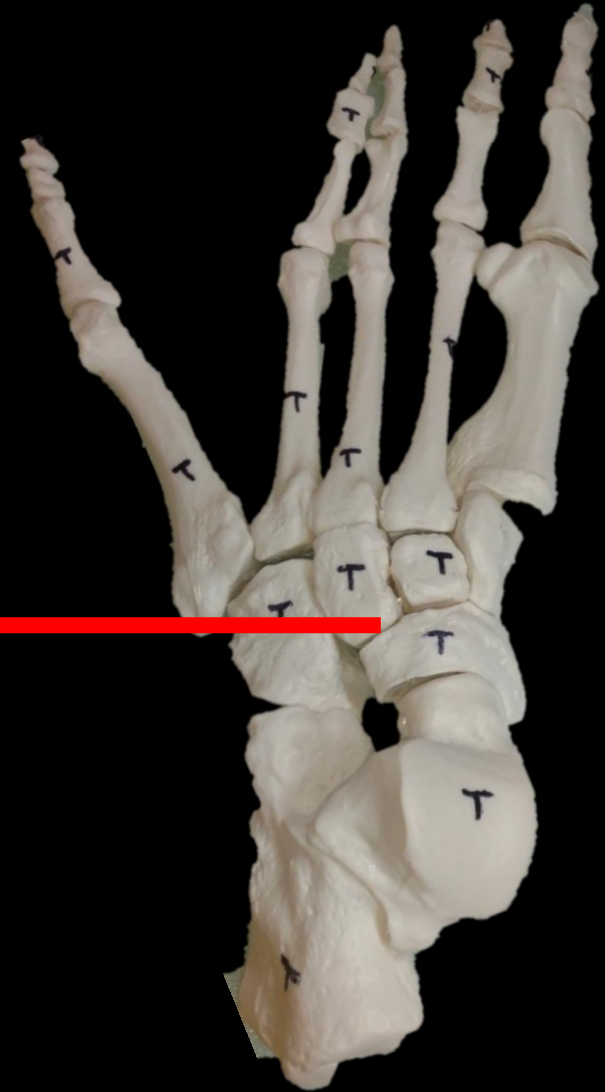
**The Tibia**



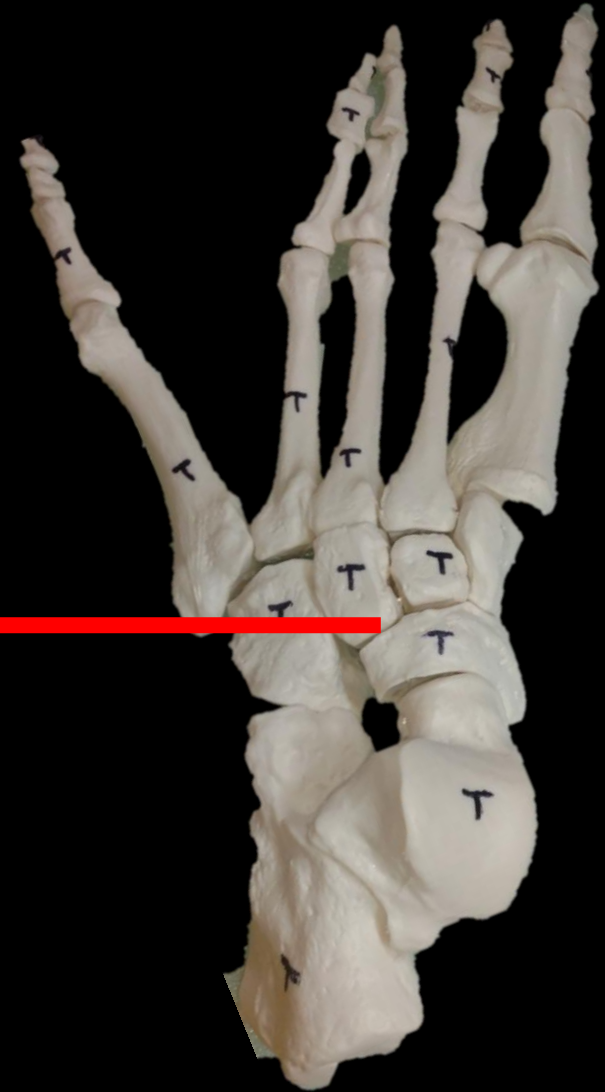
**What is the Structure?**

**Medial Condyle**

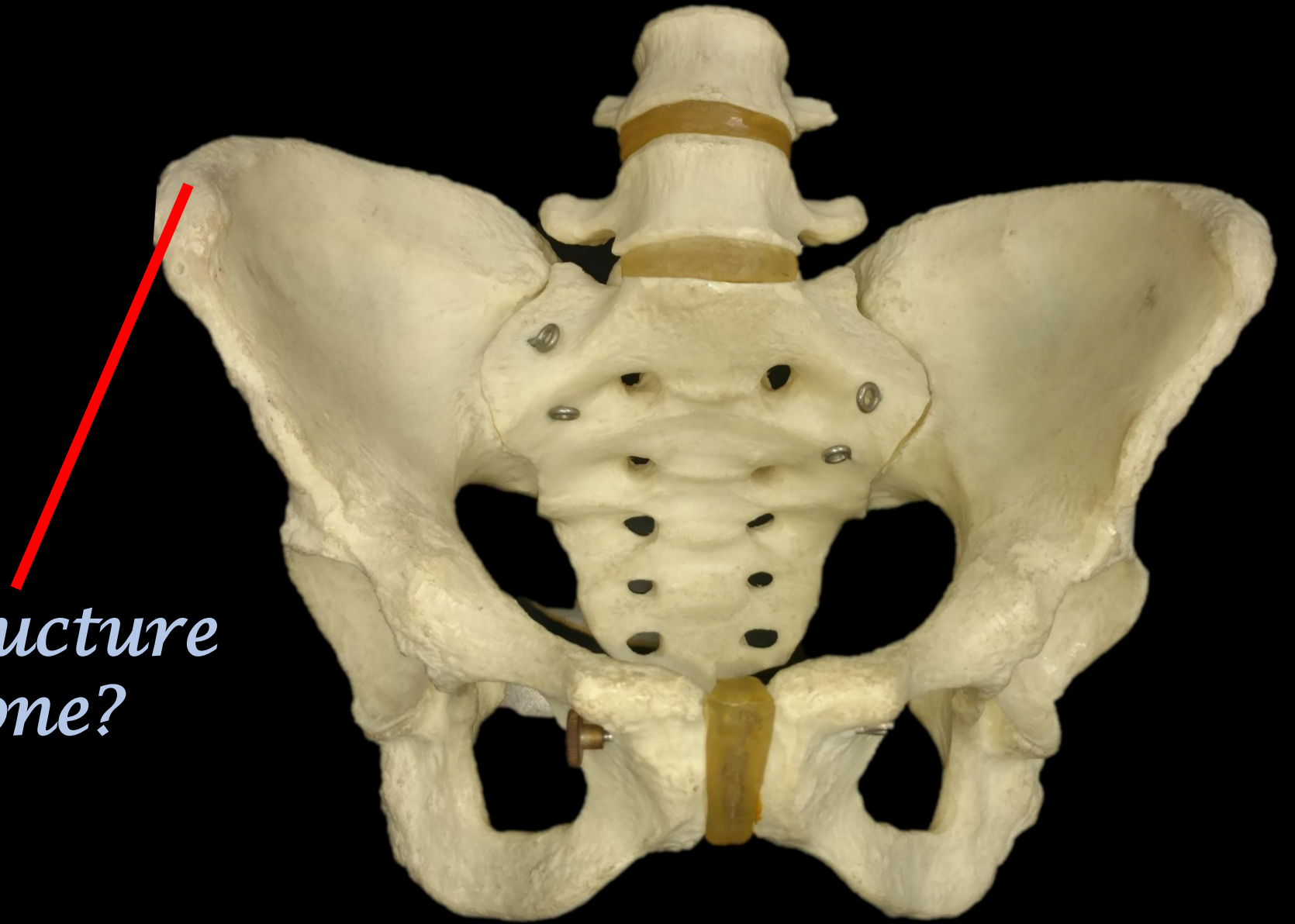*What are these Bones called?*



*What are these Bones called?*



*Tarsals*



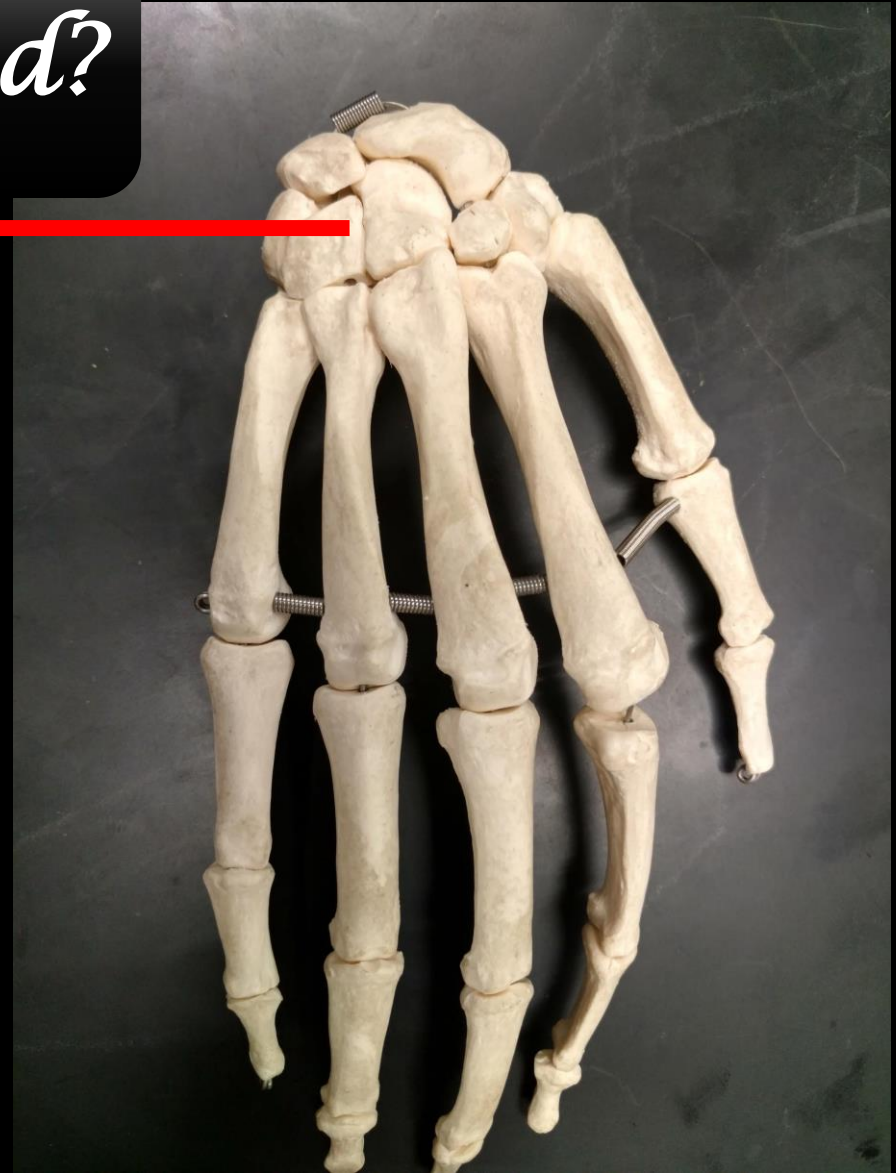
*Name the Structure  
and the Bone?*



*Iliac Crest*

*Coxal Bone*

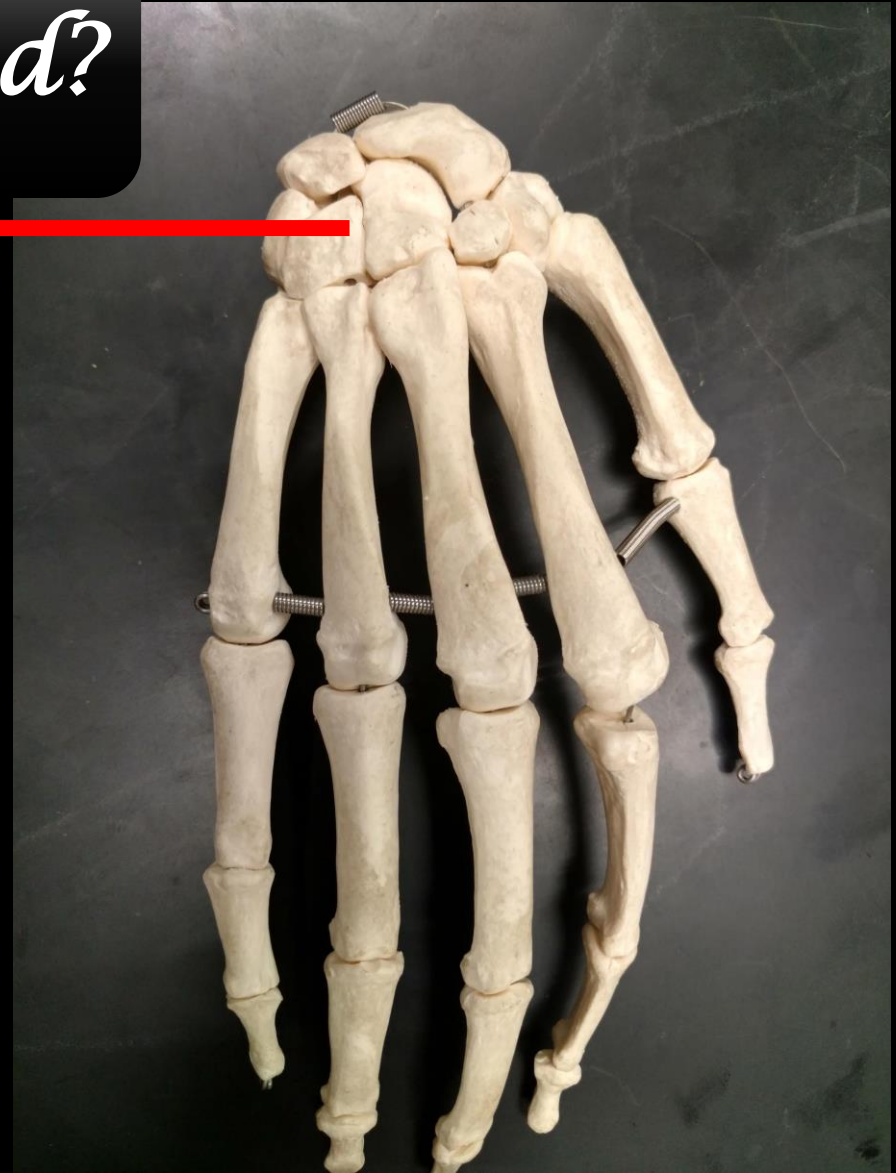
*What are these Bones called?*



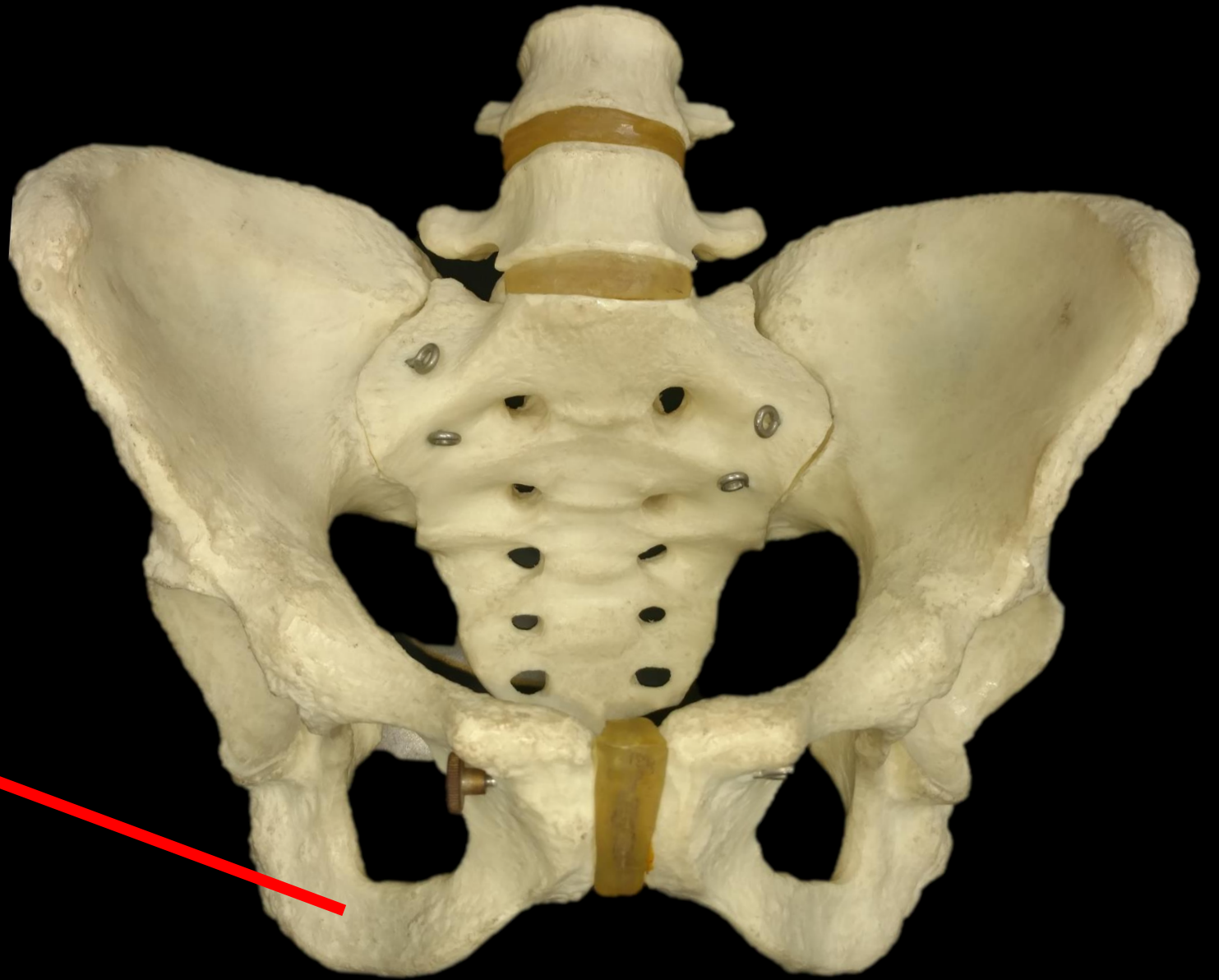

*What are these Bones called?*

*Carpals*



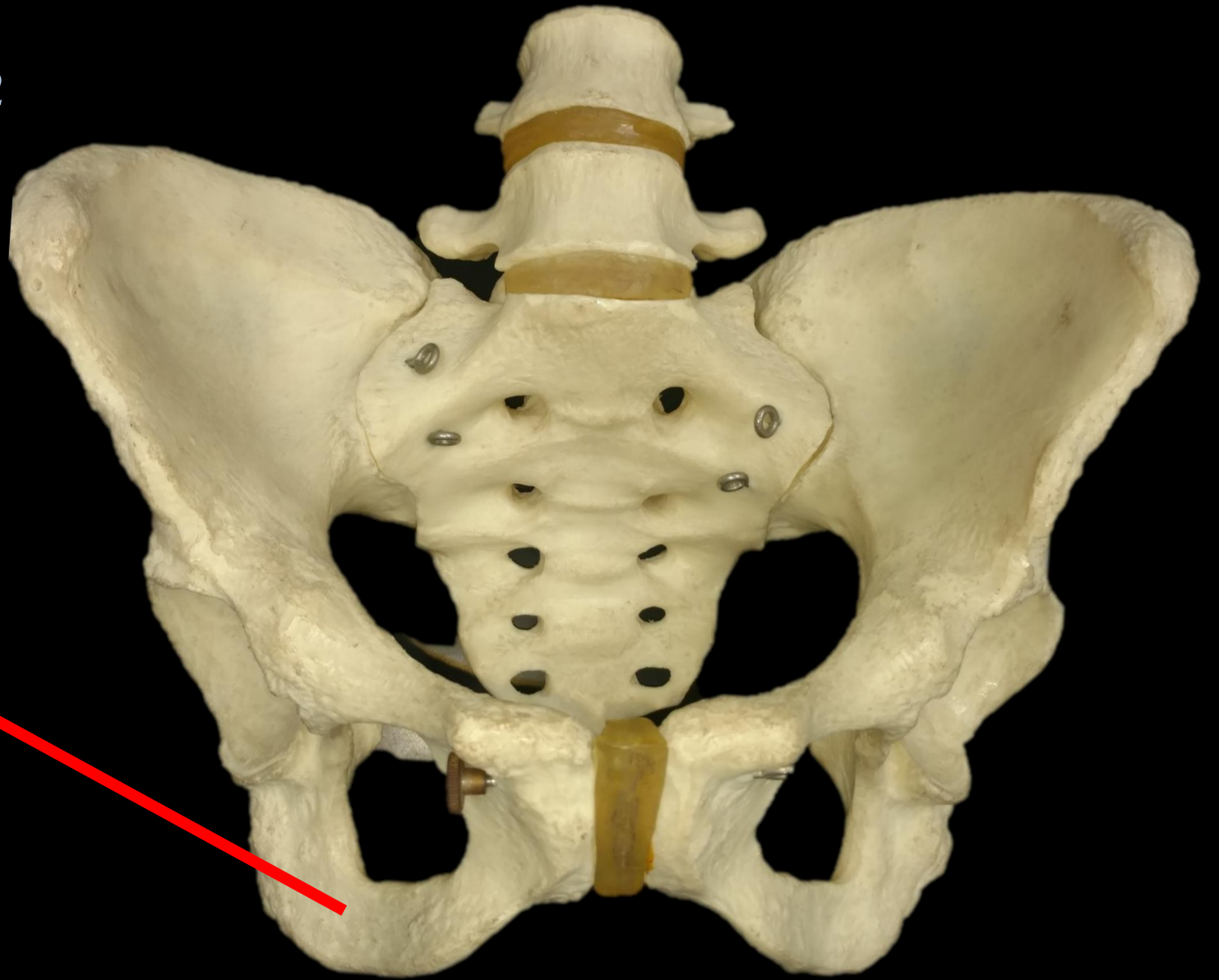
*Name the Structure  
and the Bone?*



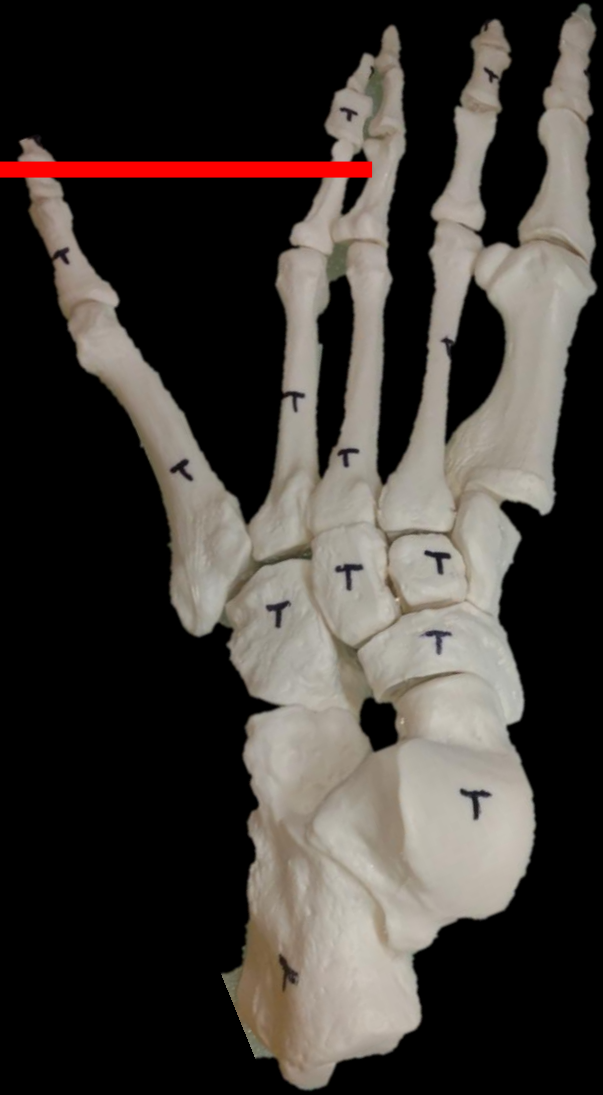*Name the Structure  
and the Bone?*

*The Ischium*

*The Coxal Bone*



*What are these Bones called?*

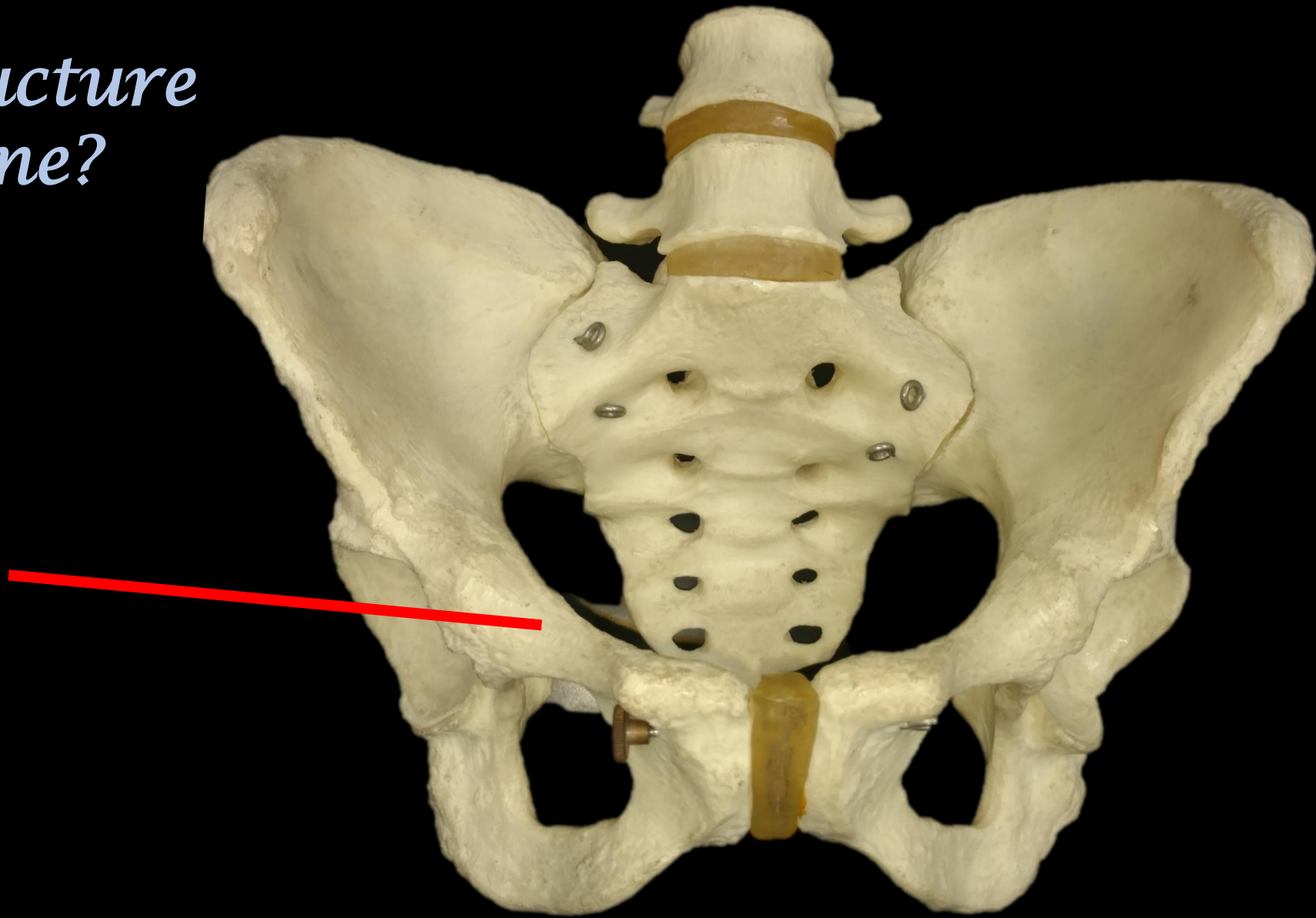


*What are these Bones called?*



*Phalanges*

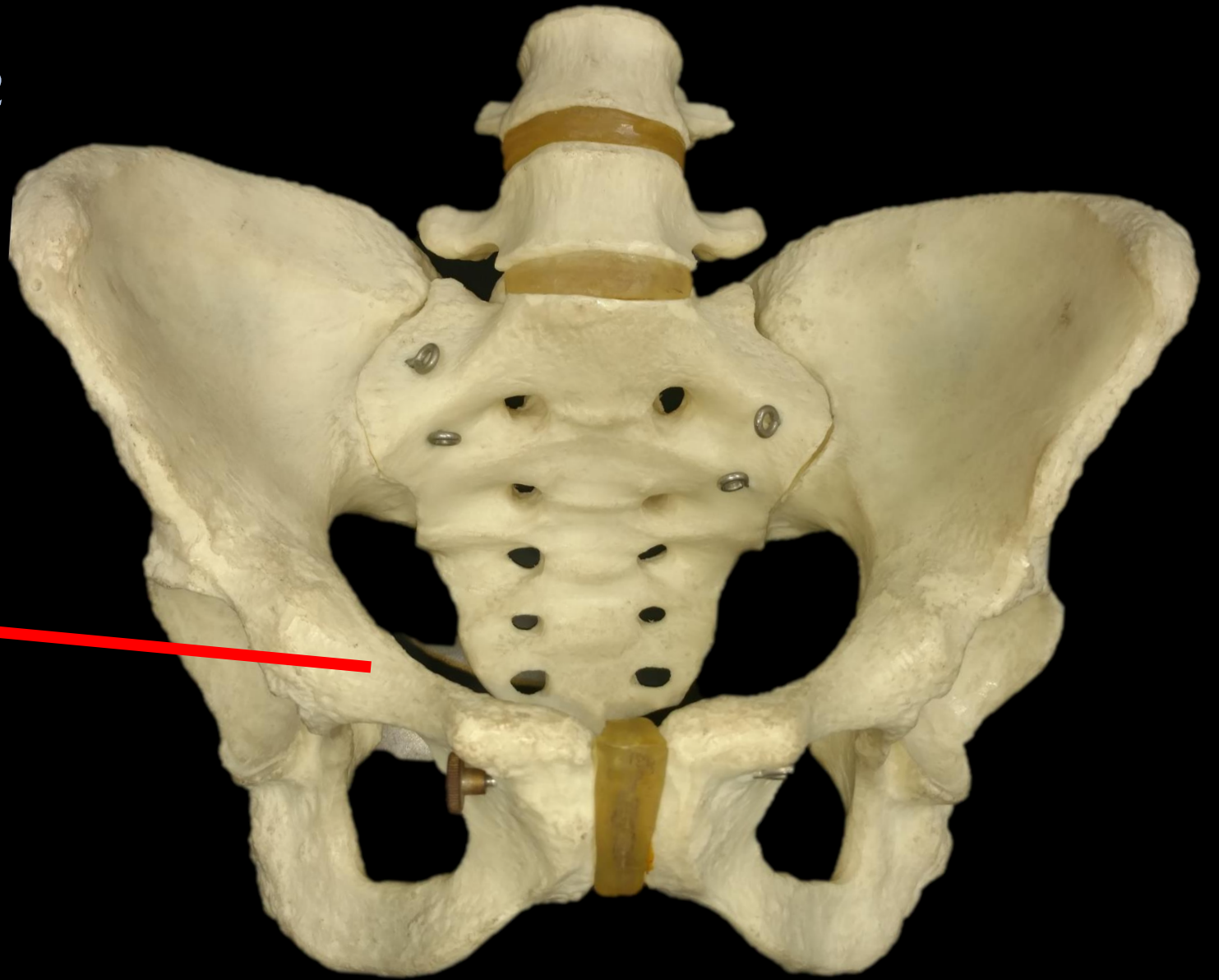
*Name the Structure  
and the Bone?*



*Name the Structure  
and the Bone?*

*The Pubis*

*The Coxal Bone*



**What is the Bone?**



**What is the Structure?**



**What is the Bone?**

**The Humerus**



**What is the Structure?**

**Greater Tubercle**

Can You Name  
This Bone?



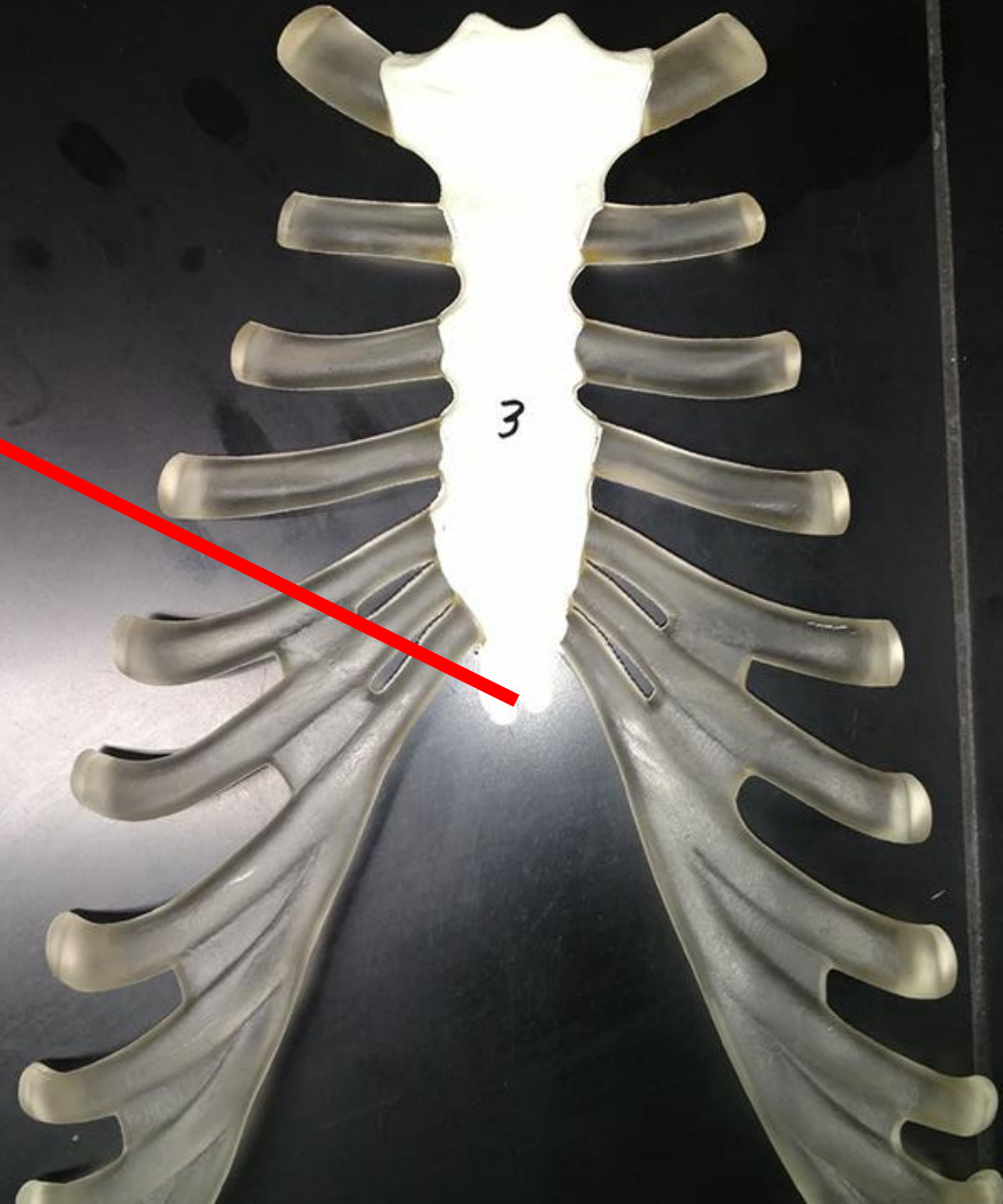
Can You Name  
This Bone?

• **HYOID BONE**



What is the  
Bone?

What is the  
Structure?

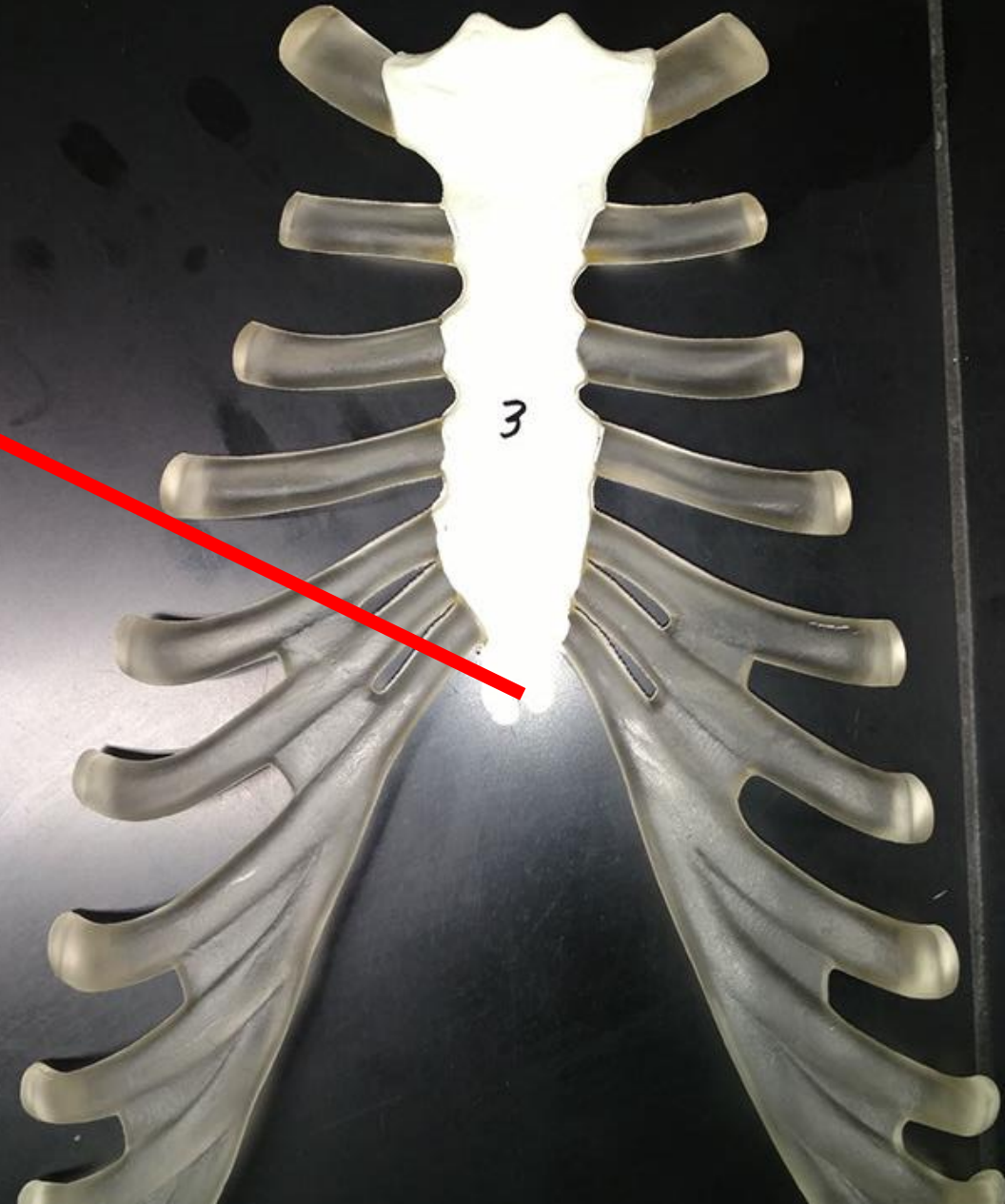


What is the  
Bone?

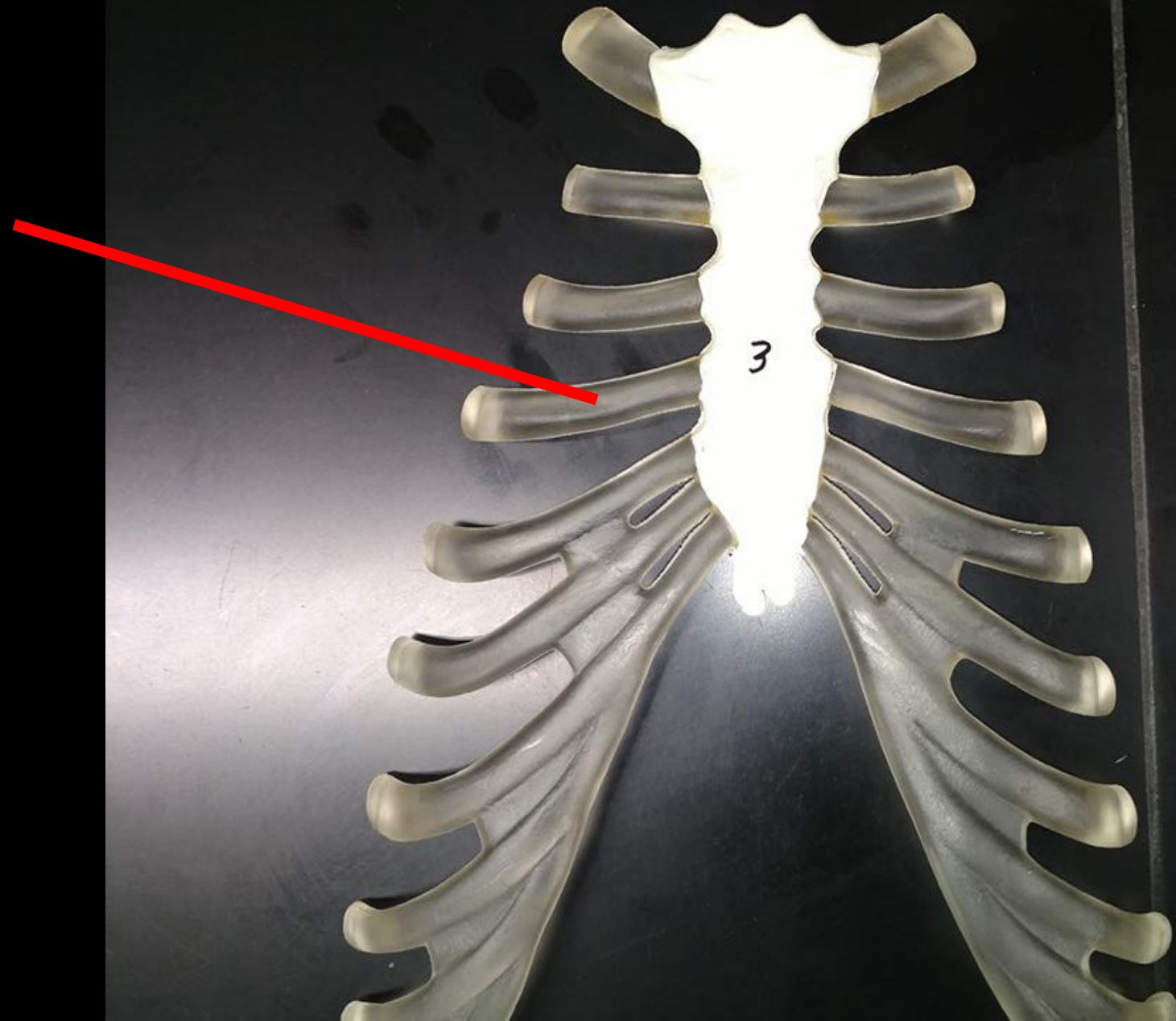
**Sternum**

What is the  
Structure?

**Xiphoid  
(Xiphoid Process)**

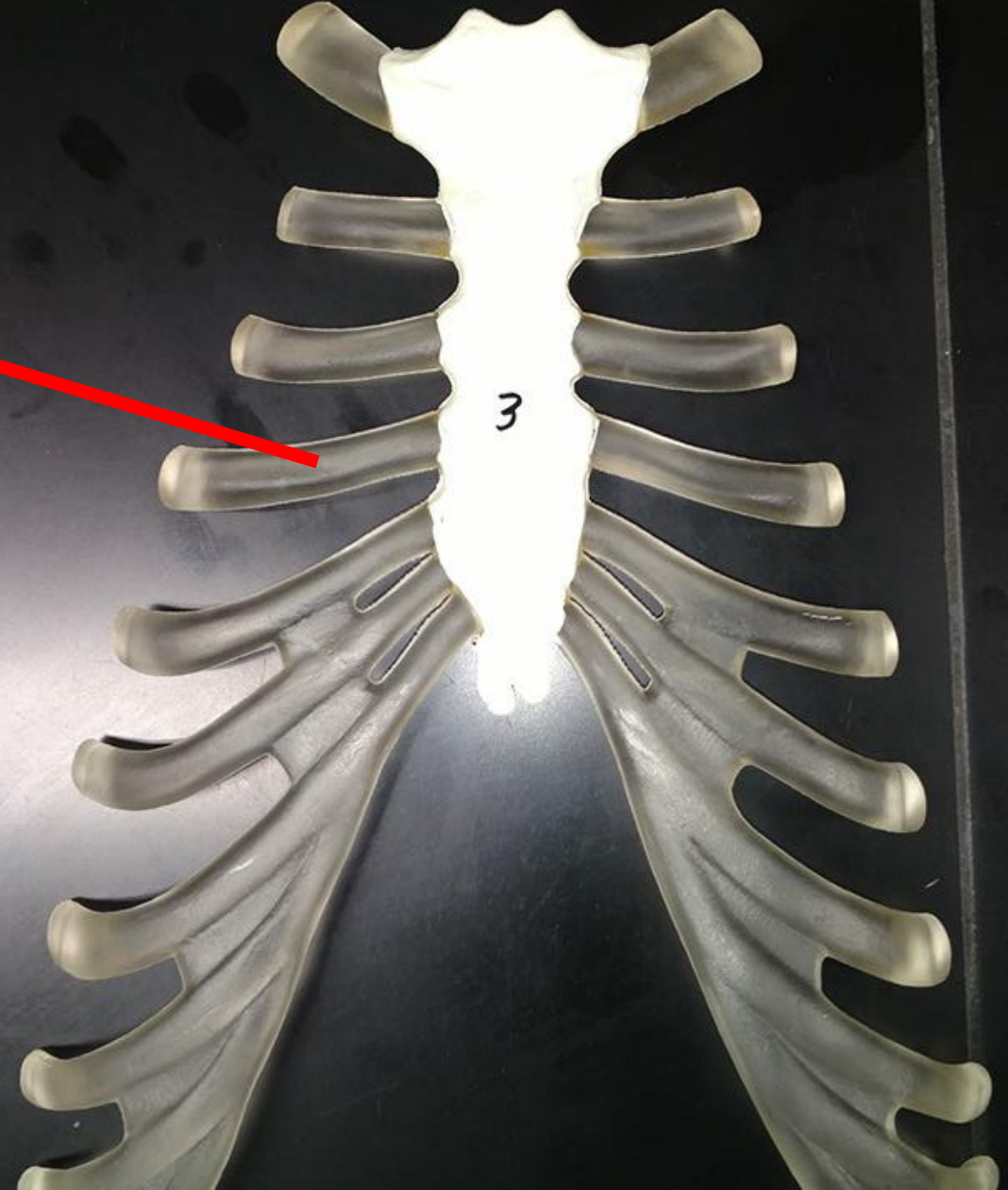


What is This?

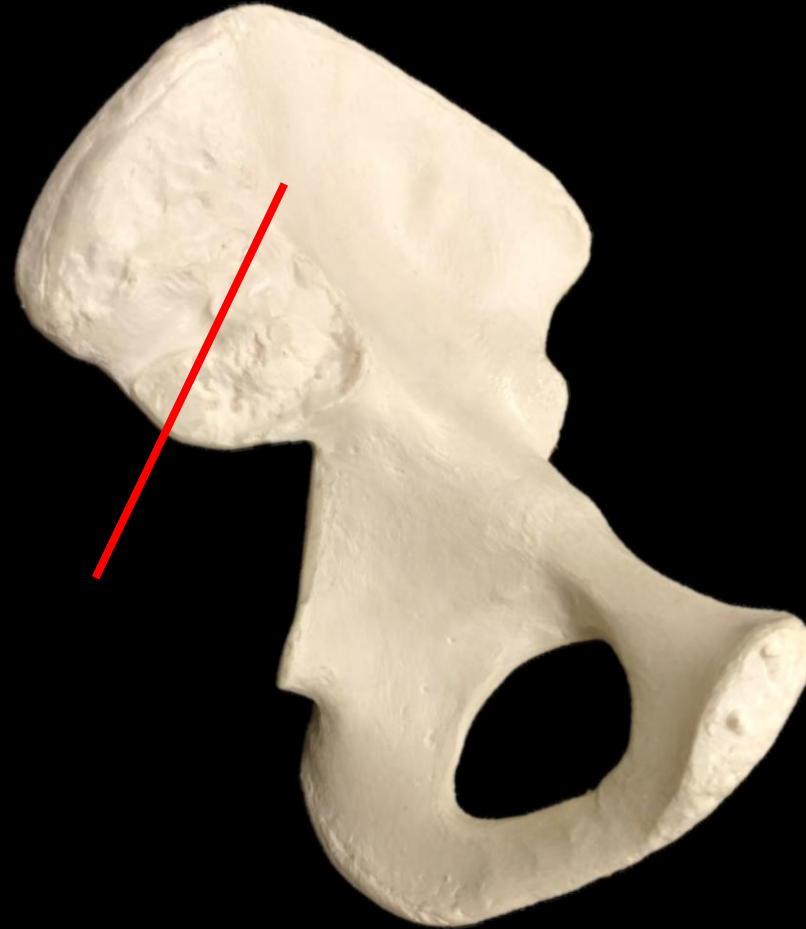

What is This?

Costal Cartilage



# *What is the Bone? What is the Structure?*

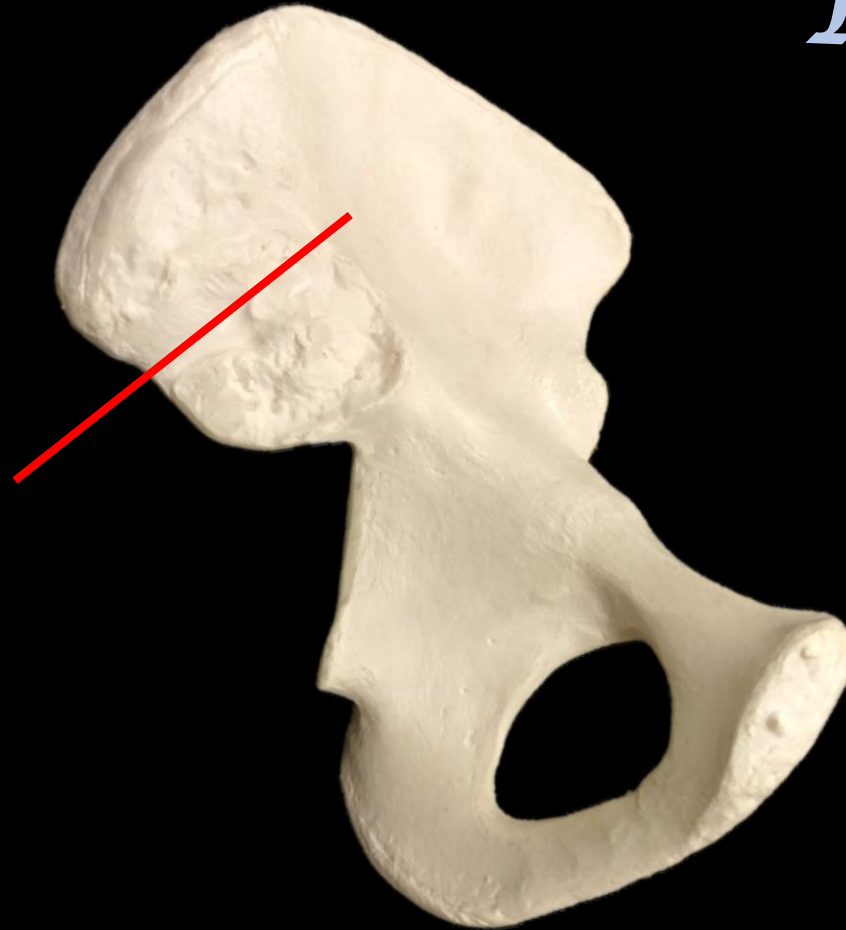




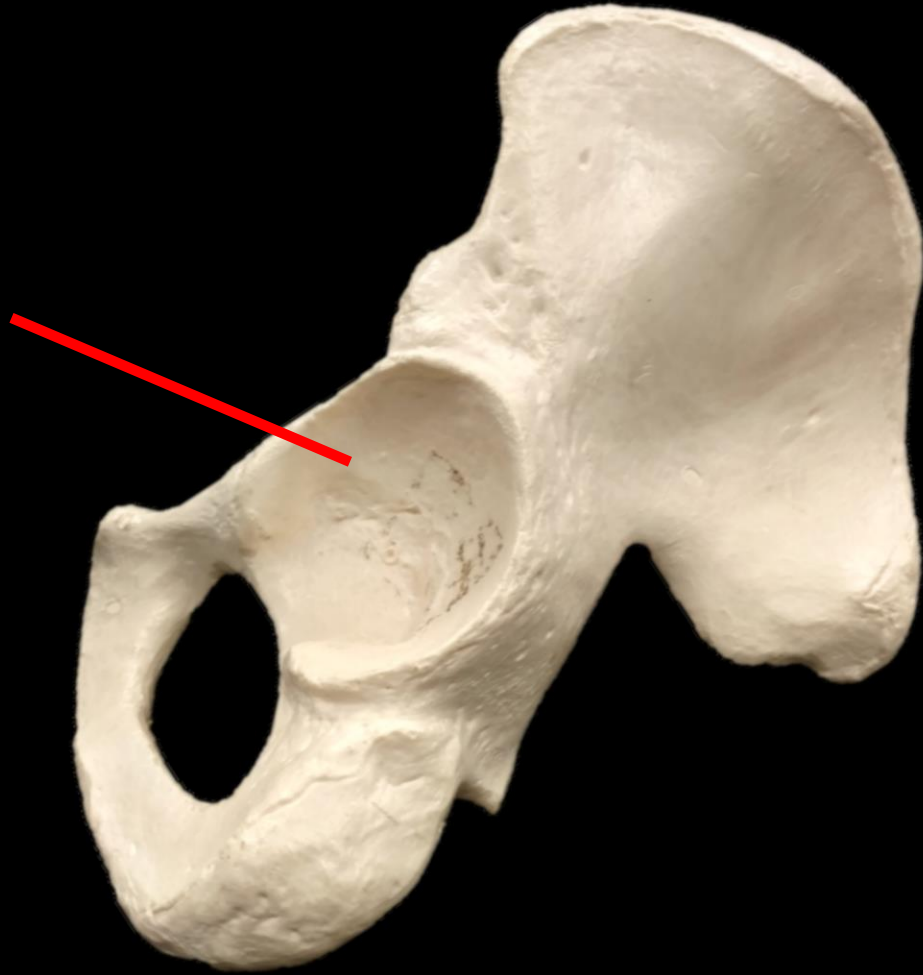# *What is the Bone? What is the Structure?*

## *The Coxal Bone*

*Ilium*



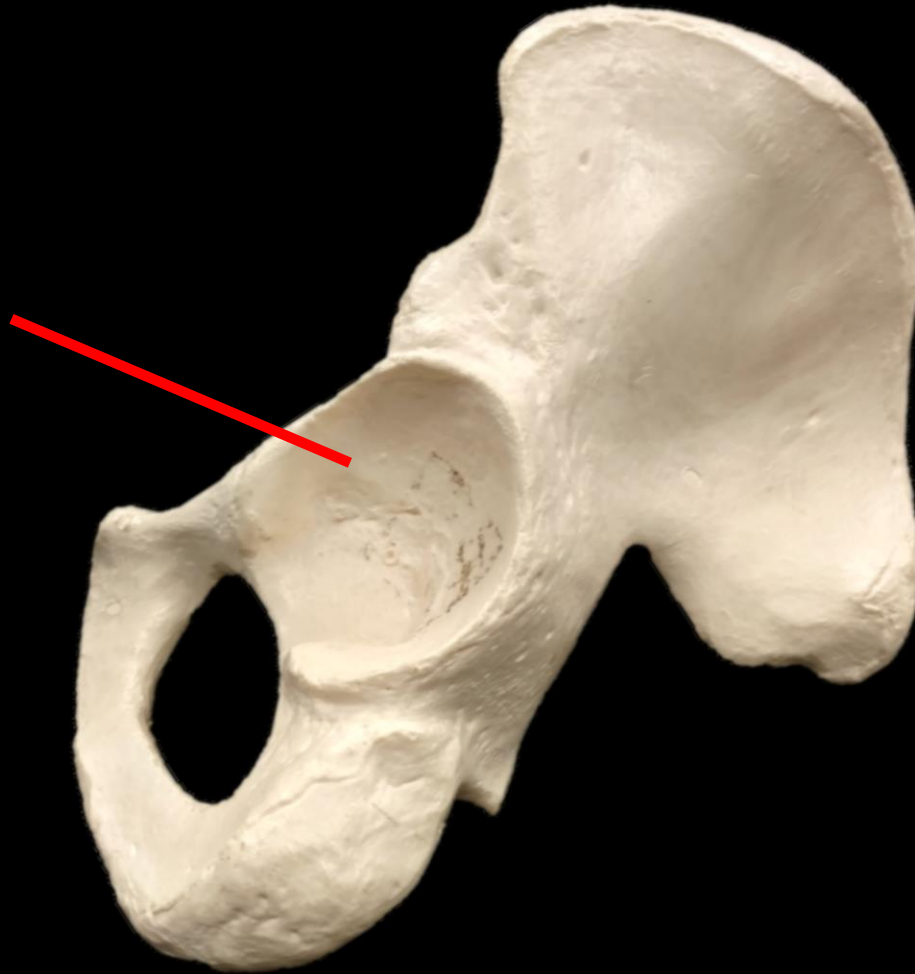*What is the Bone? What is the Structure?*



*What is the Bone? What is the Structure?*

*The Coxal  
Bone*

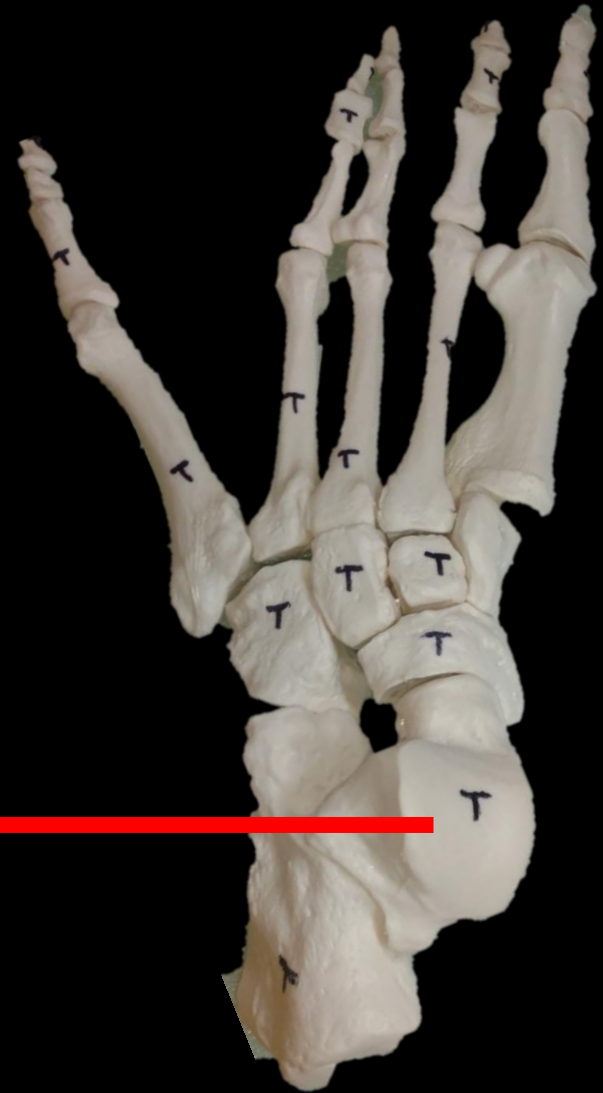*Acetabulum*





*What are these Bones called?*

*Talus*



*What is the Bone?*



*What is the Structure??*

*What is the Bone?*

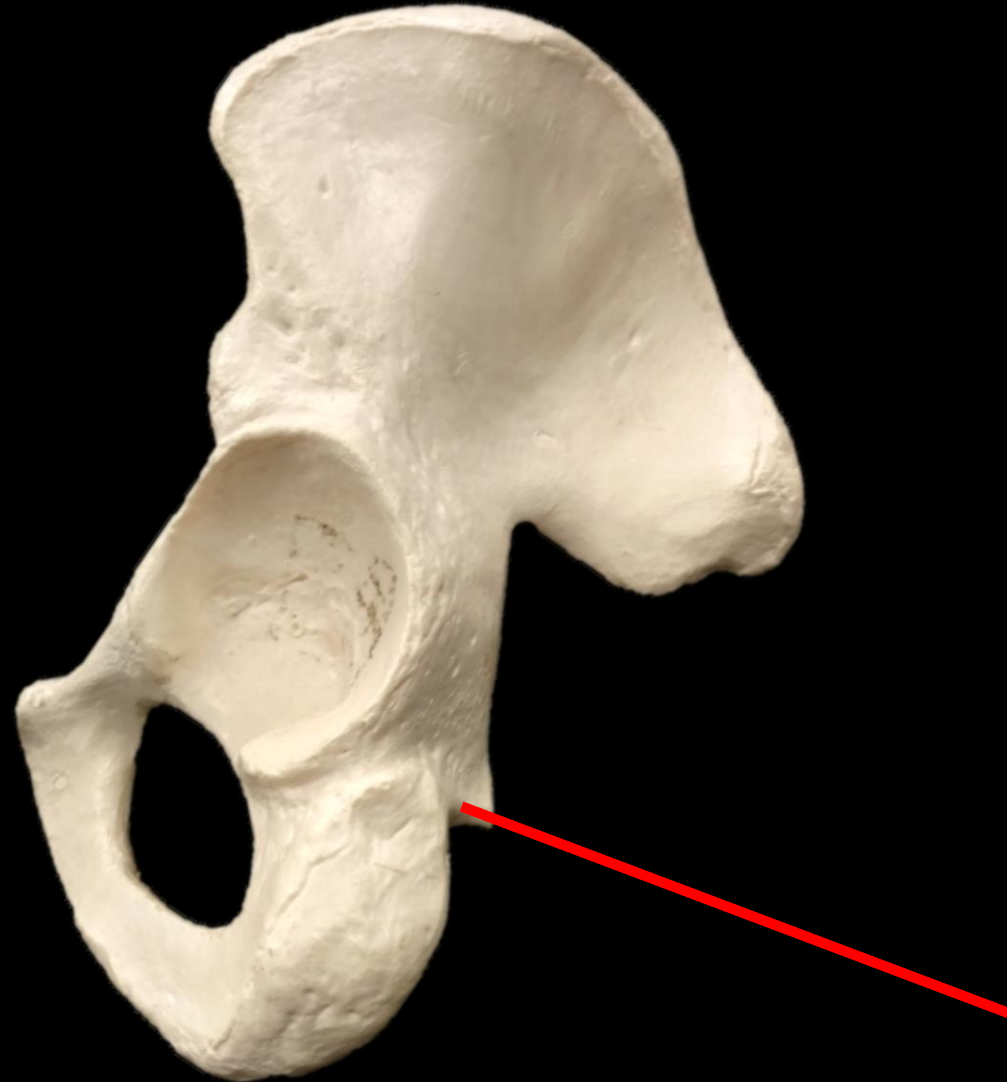*Femur*



*What is the Structure?*

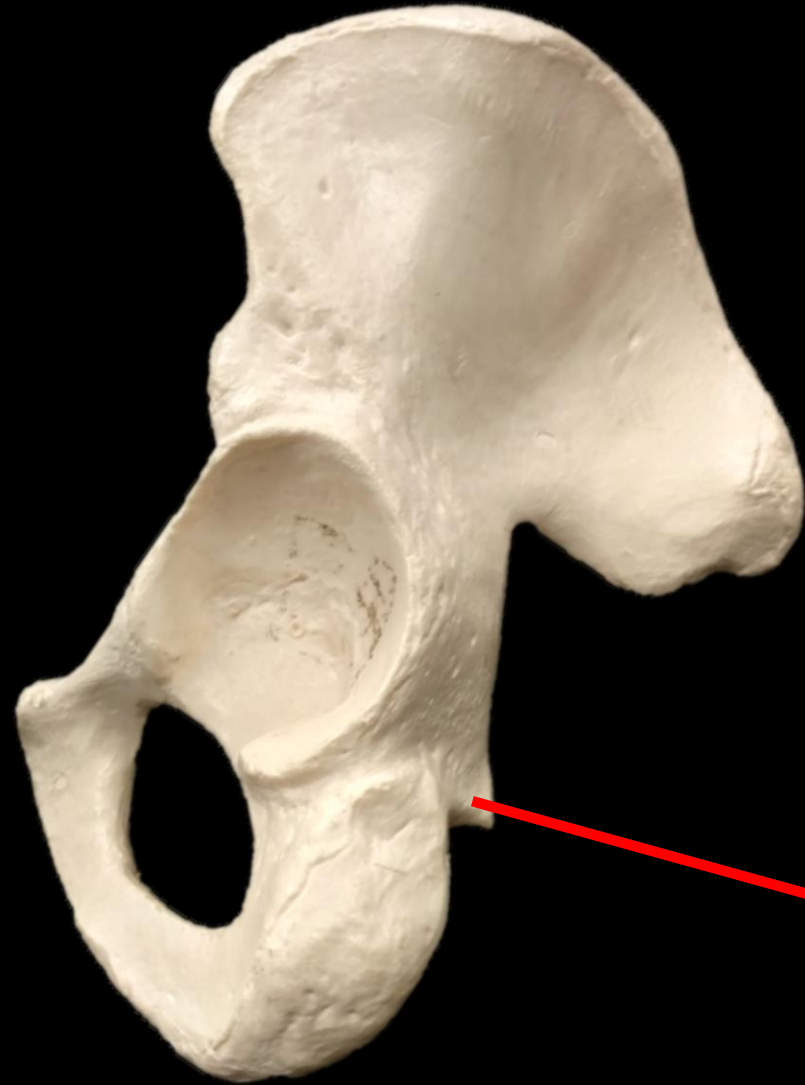*Línea Aspera*

*What is the Bone? What is the Structure?*





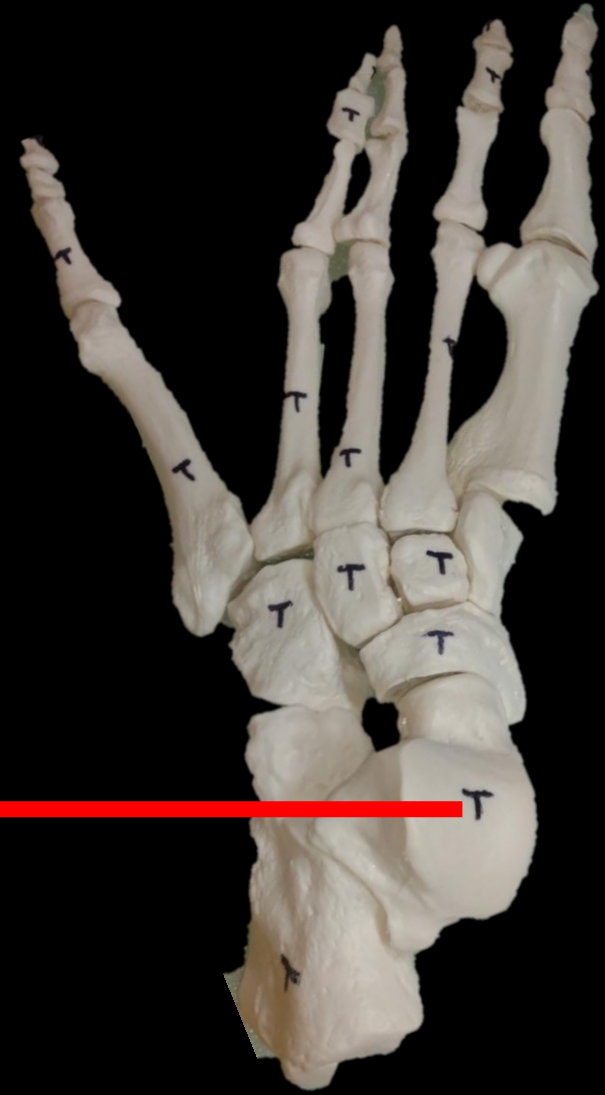*What is the Bone? What is the Structure?*



*The Coxal  
Bone*

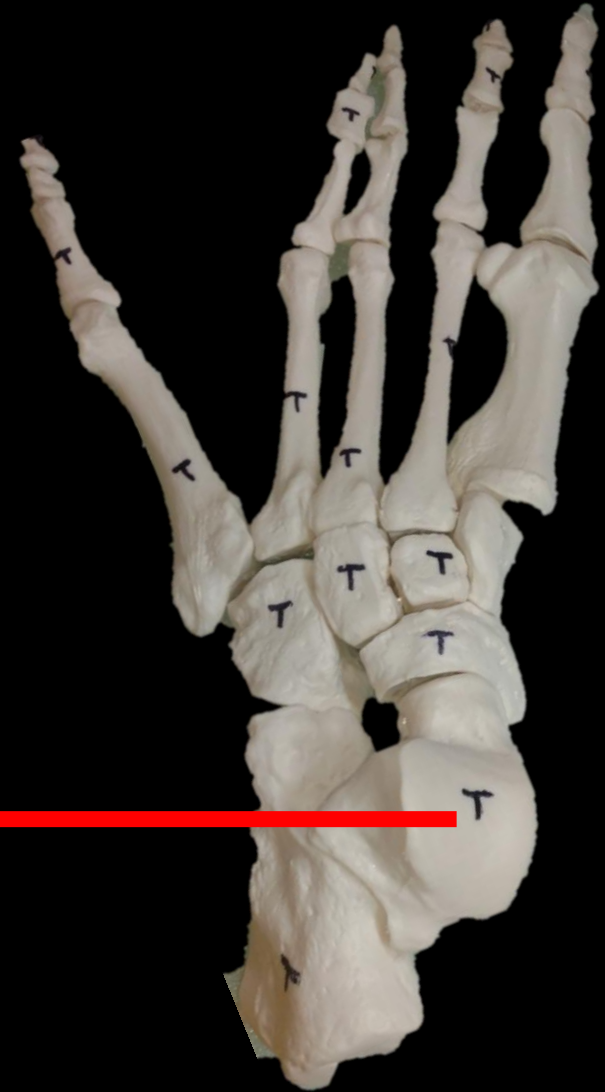*Ischial Spine*

*What are these Bones called?*

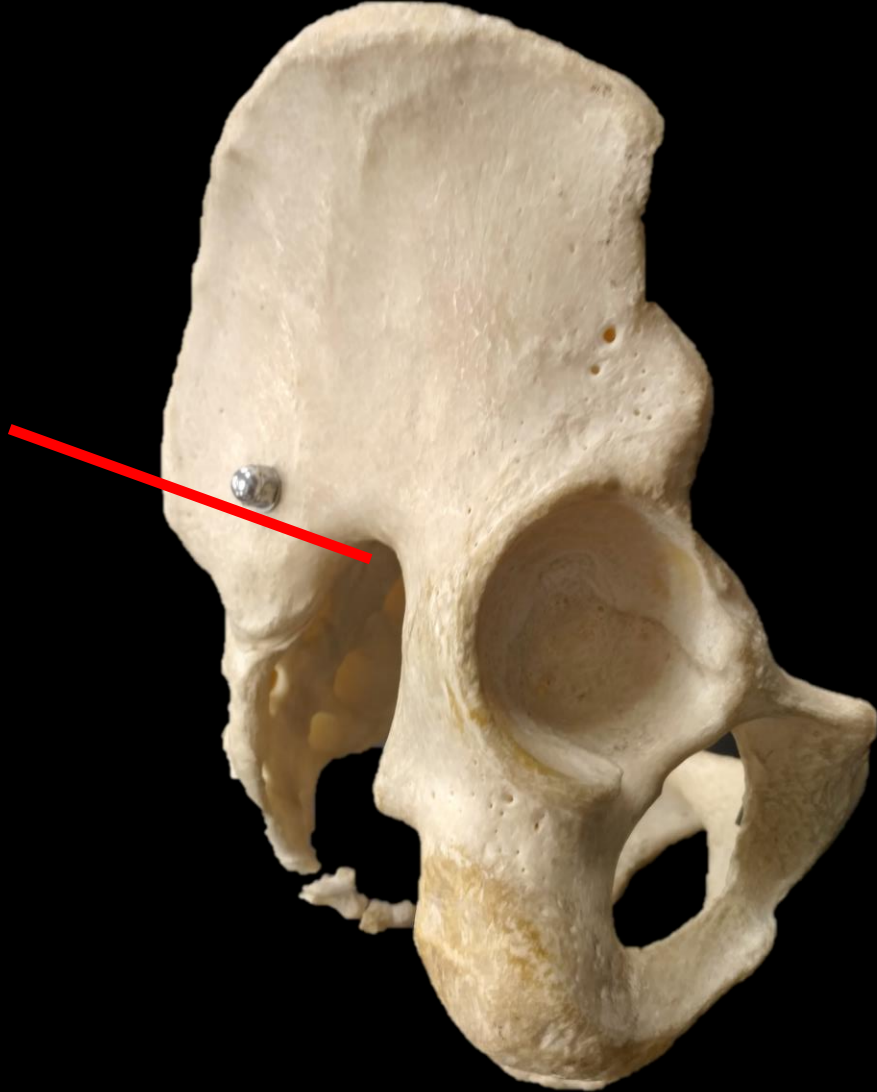


*What are these Bones called?*

*TALUS*



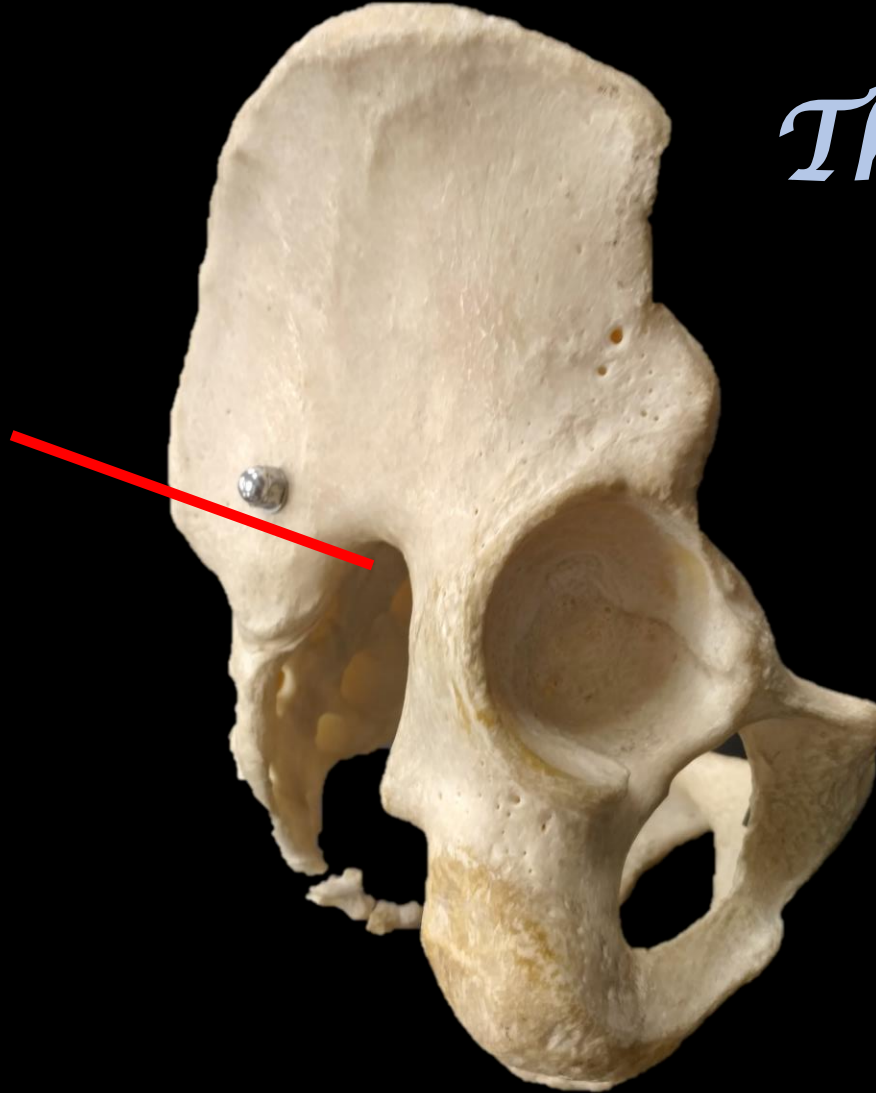
*What is the Bone? What is the Structure?*

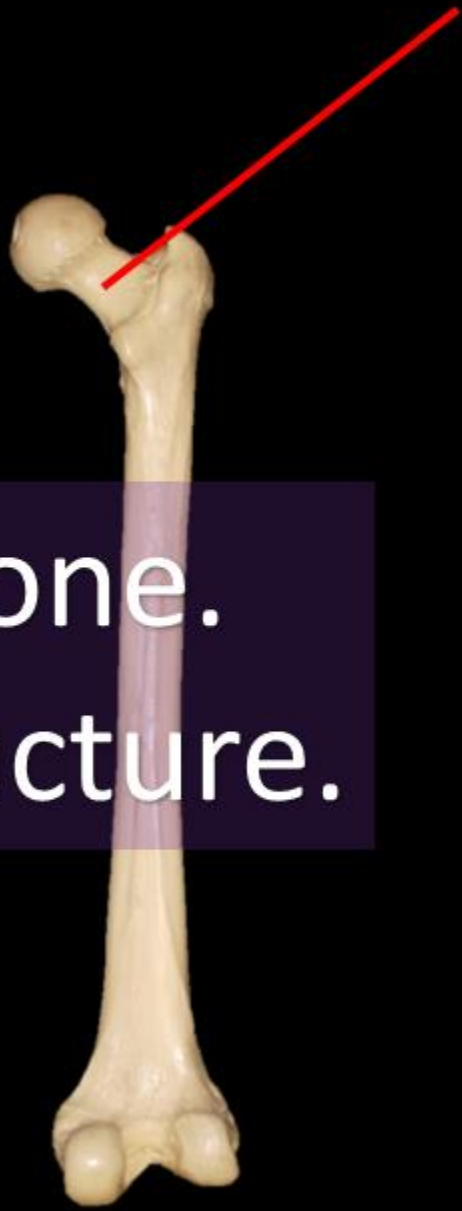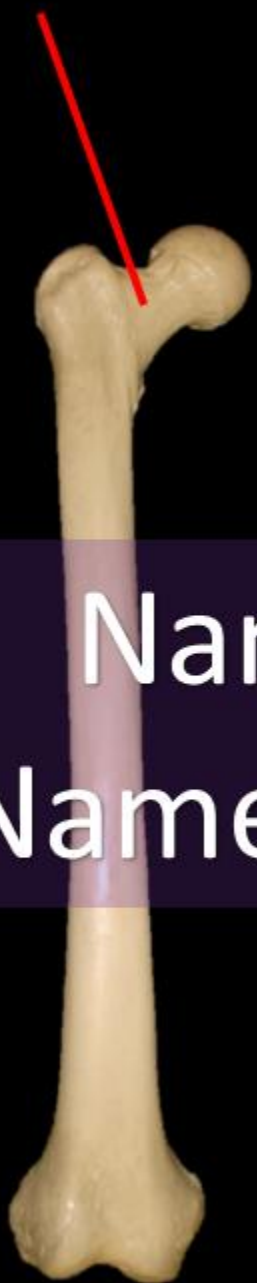


*What is the Bone? What is the Structure?*

*The Coxal  
Bone*

*Greater  
Sciatic  
Notch*





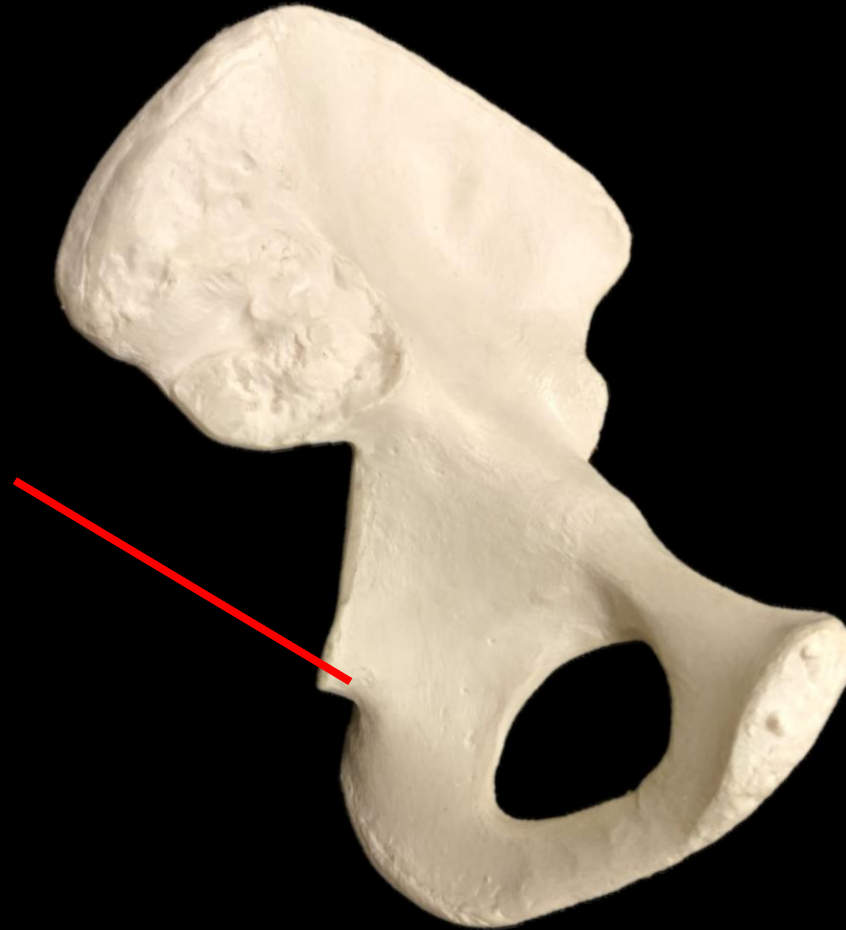
Name the Bone.  
Name the Structure.



Name the Bone = FEMUR  
Name the Structure = NECK

The image shows two views of a human femur (thigh bone). The bone is light yellow and has a long, cylindrical shaft. At the top, there is a rounded head and a smaller, rounded neck. A red arrow points to the neck of the bone in both views. The bone is shown against a black background.

# *What is the Bone? What is the Structure?*

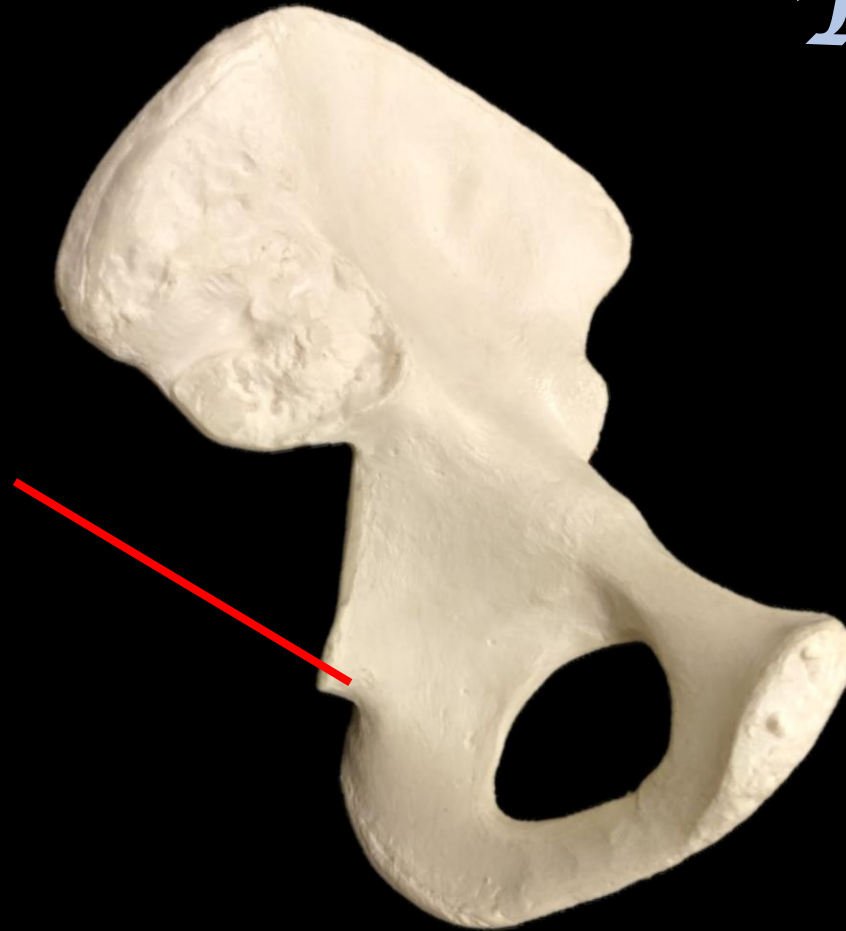


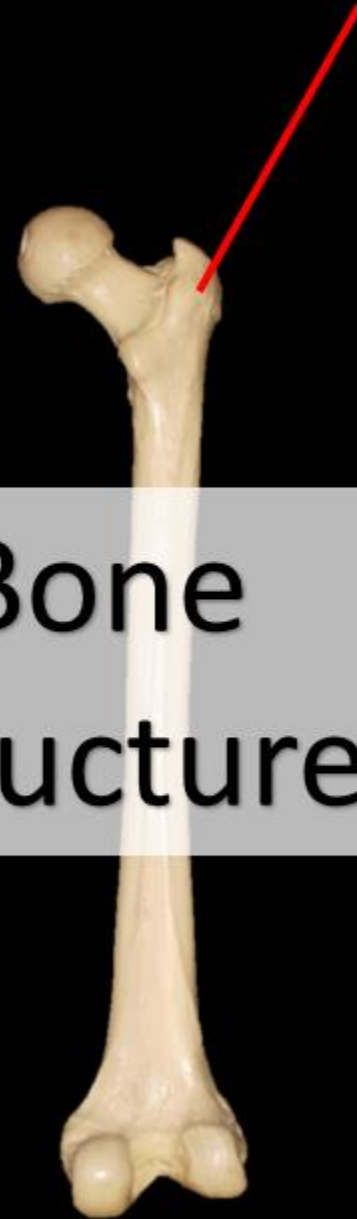
*What is the Bone? What is the Structure?*

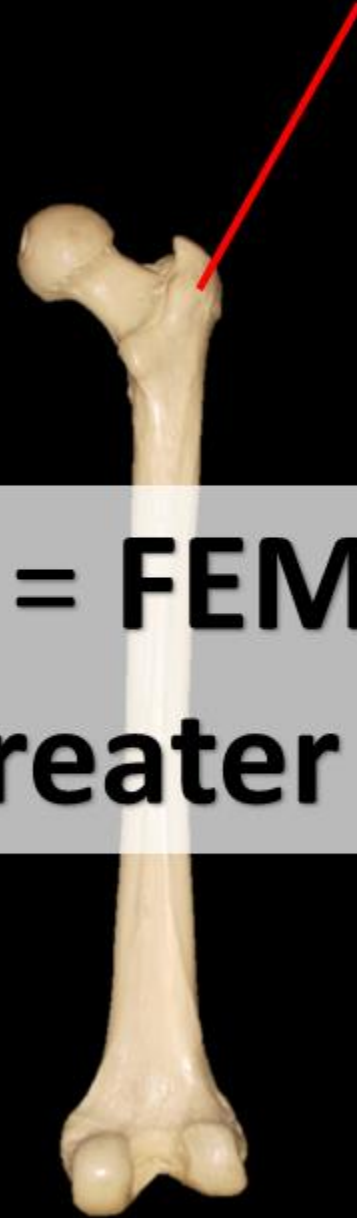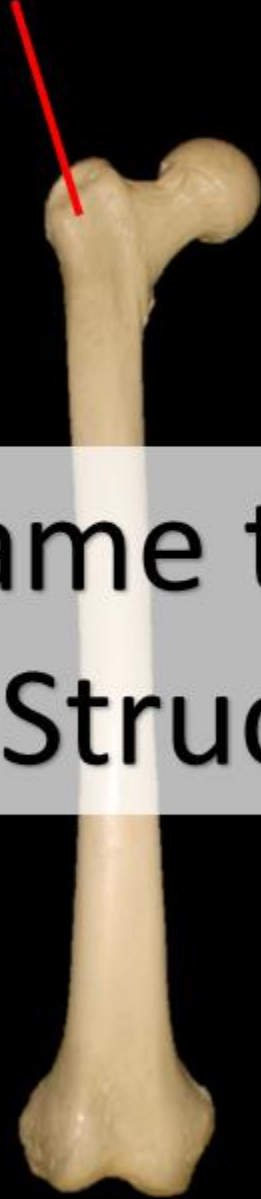*The Coxal  
Bone*

*Ischial  
Spine*



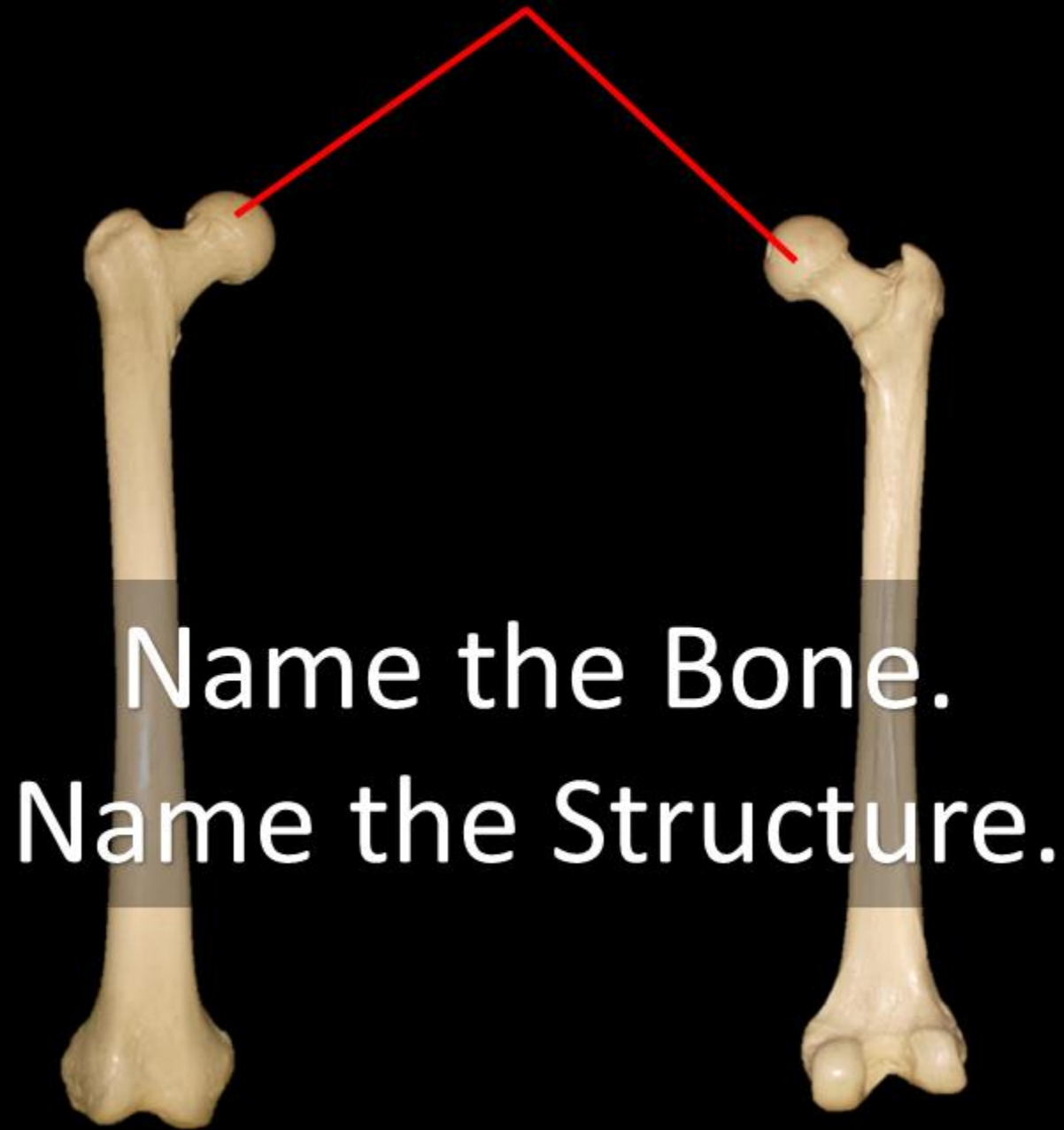


Name the Bone  
Name the Structure



Name the Bone = **FEMUR**

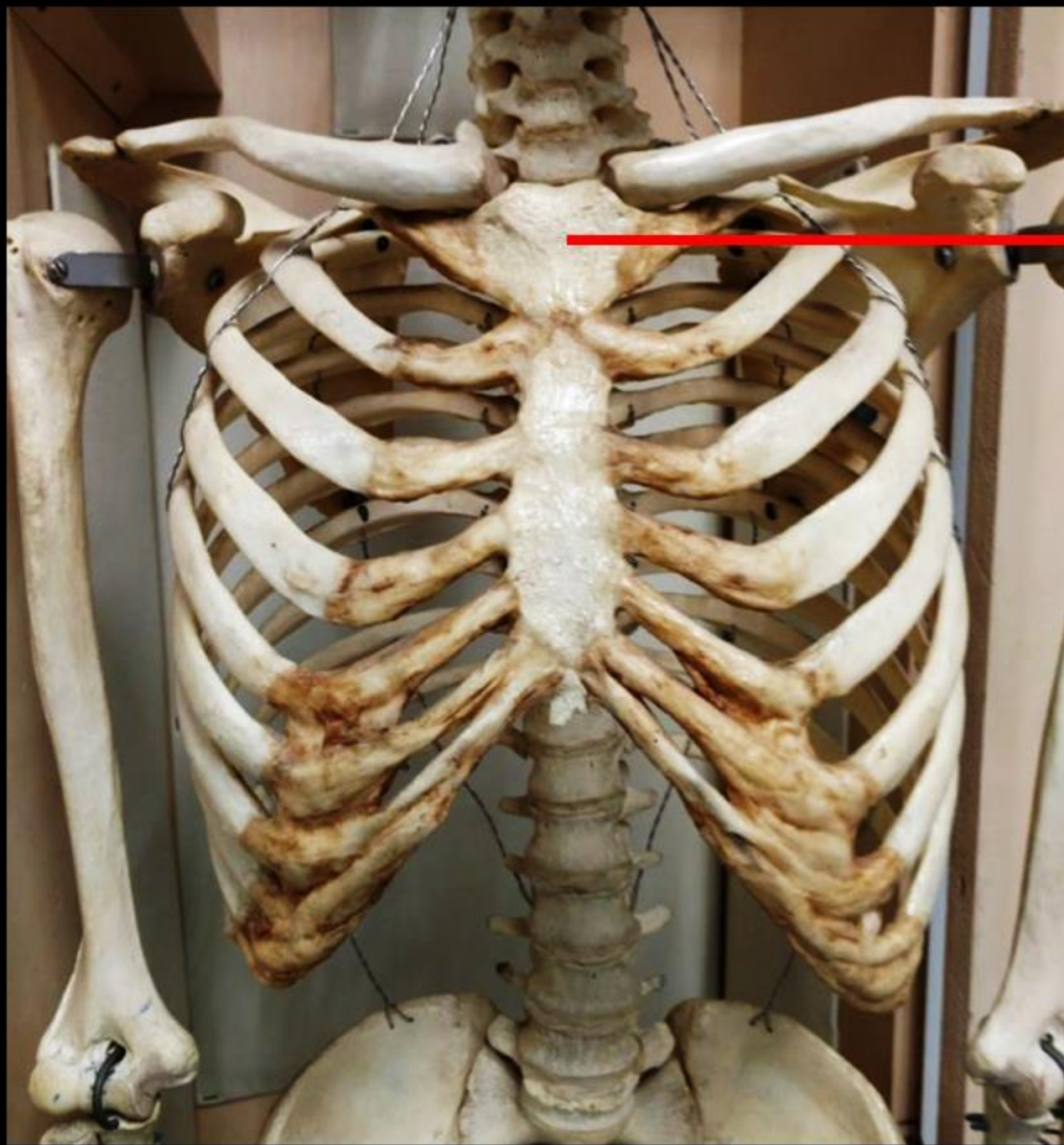
Name the Structure = **Greater Trochanter**



Name the Bone.  
Name the Structure.

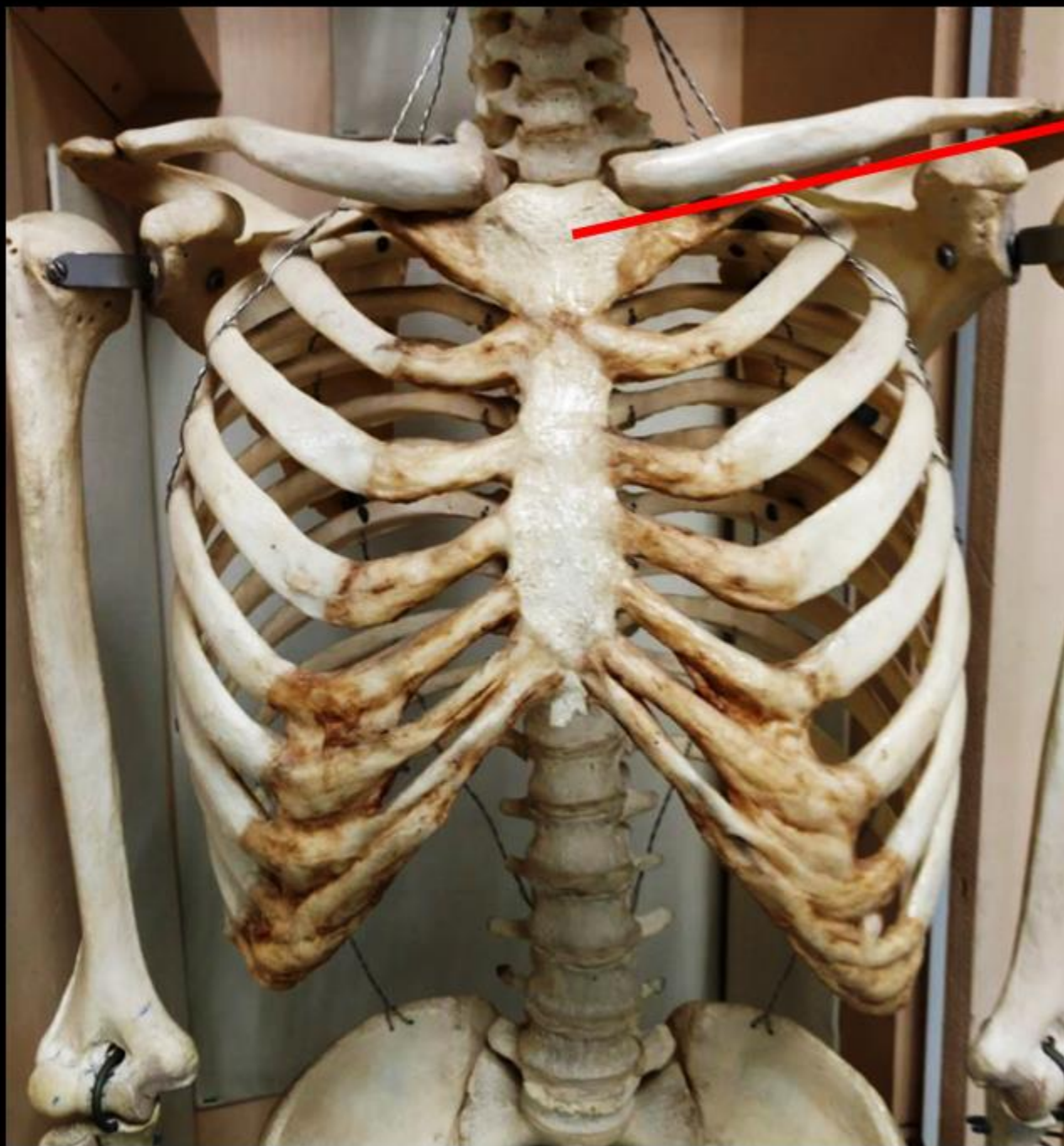
Two femur bones are shown against a black background. The bone on the left is oriented vertically with its head at the top. The bone on the right is oriented vertically with its head at the top and its distal end at the bottom. Two red arrows point from the top of the image towards the heads of the bones. The text 'Name the Bone = FEMUR' and 'Name the Structure = HEAD' is centered between the two bones.

Name the Bone = **FEMUR**  
Name the Structure = **HEAD**



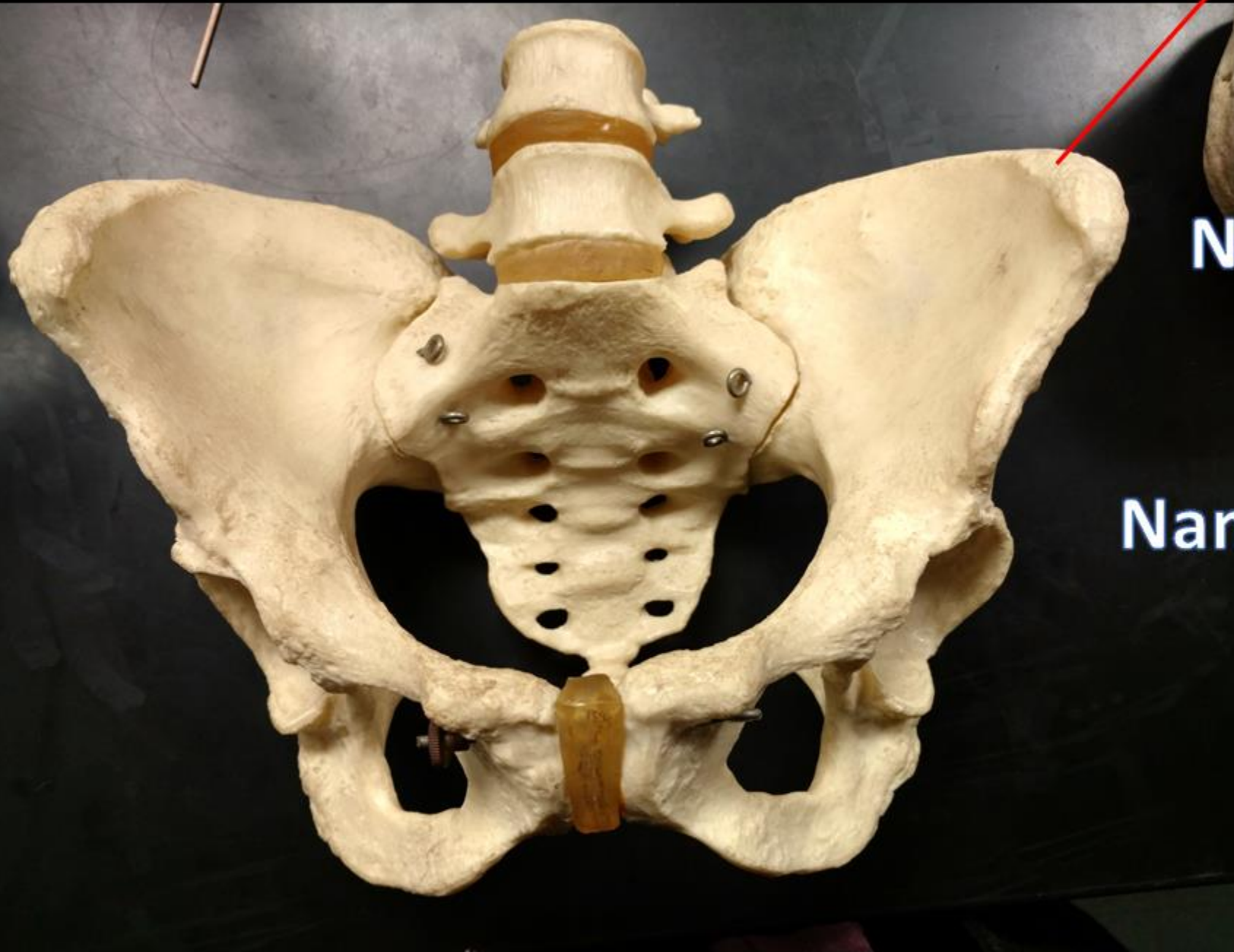**Name the Bone.**

**Name the Structure.**



**Name the Bone  
= STERNUM**

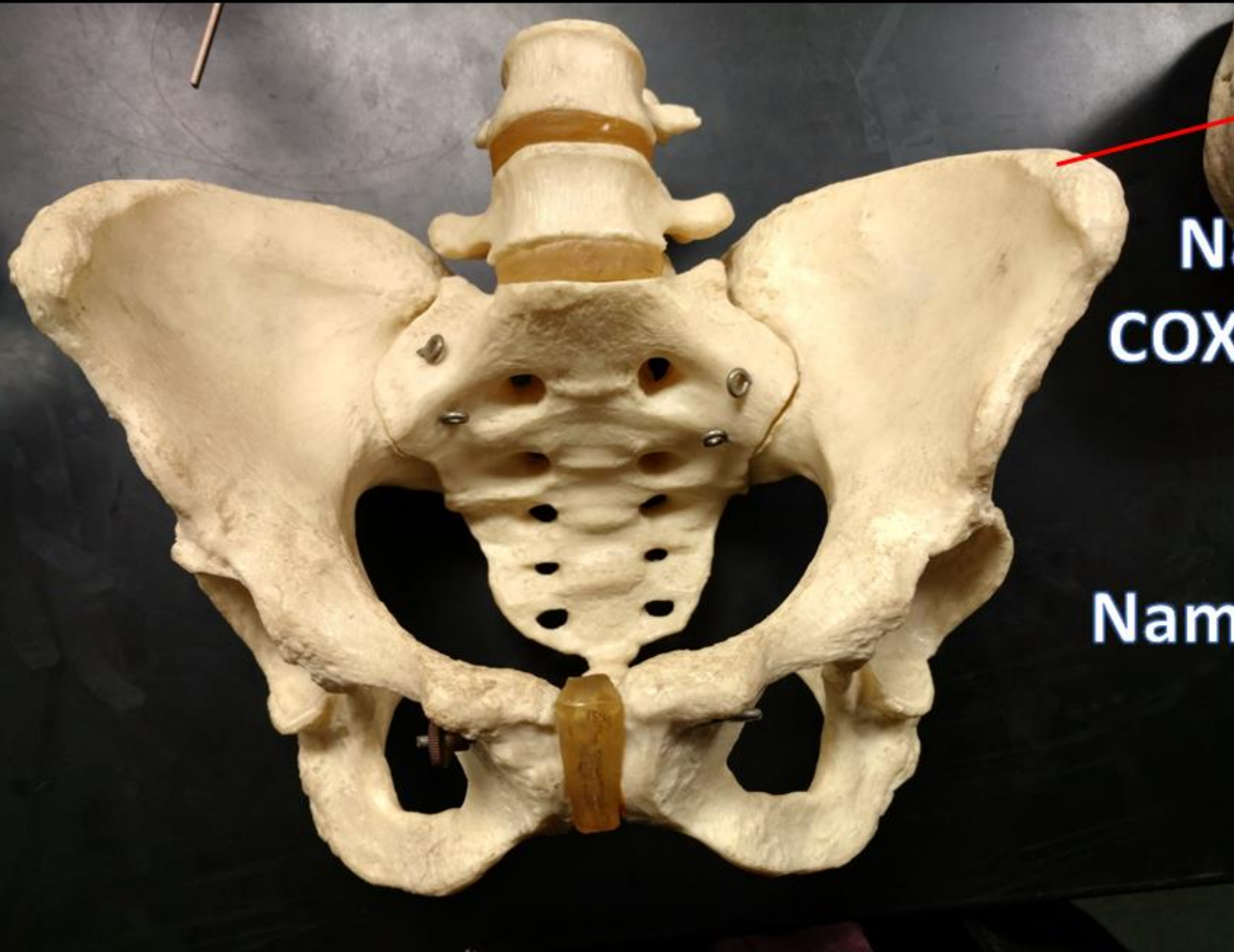**Name the Structure  
= MANUBRIUM**



**Name the bone**

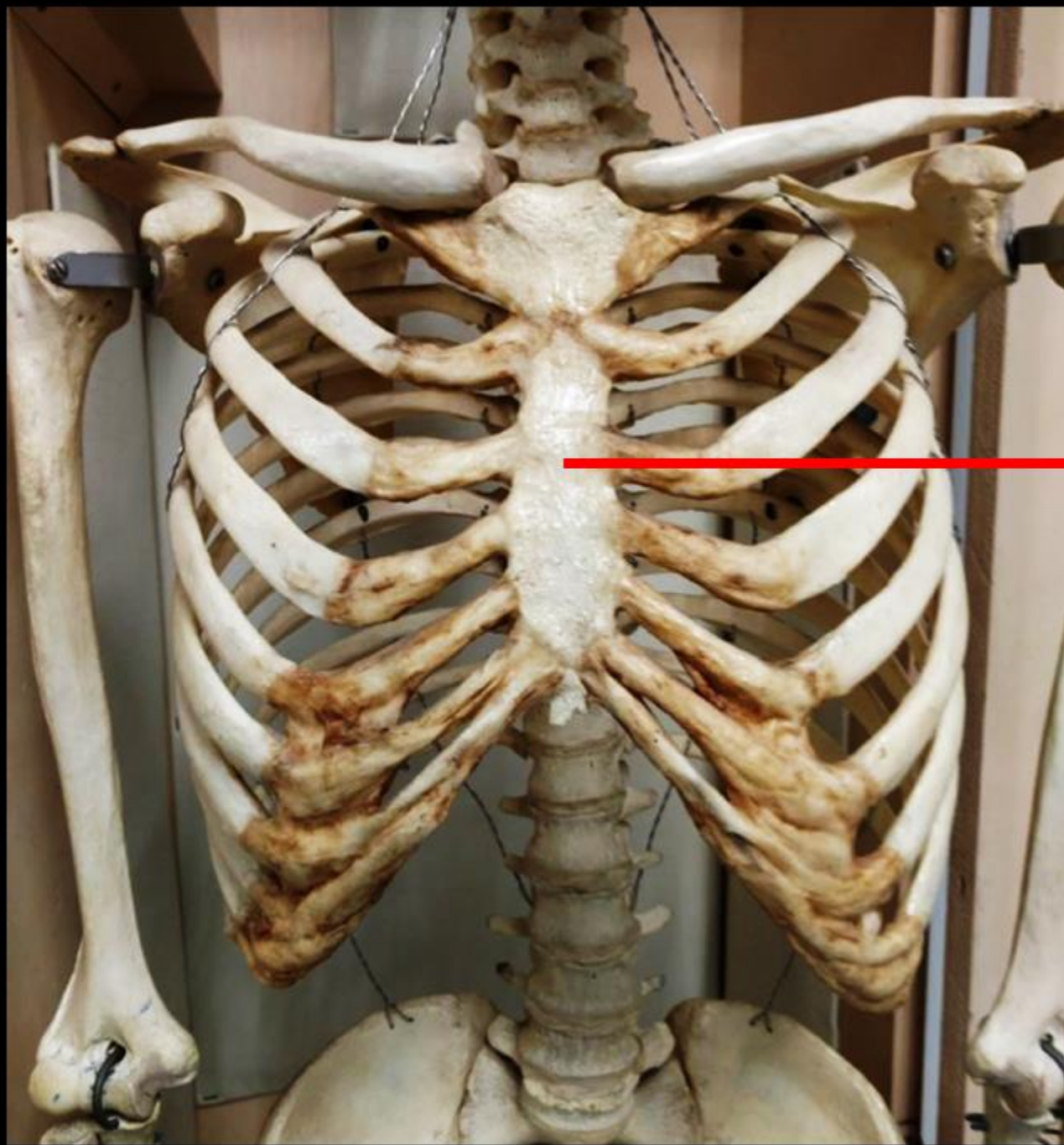
**Name the Structure**





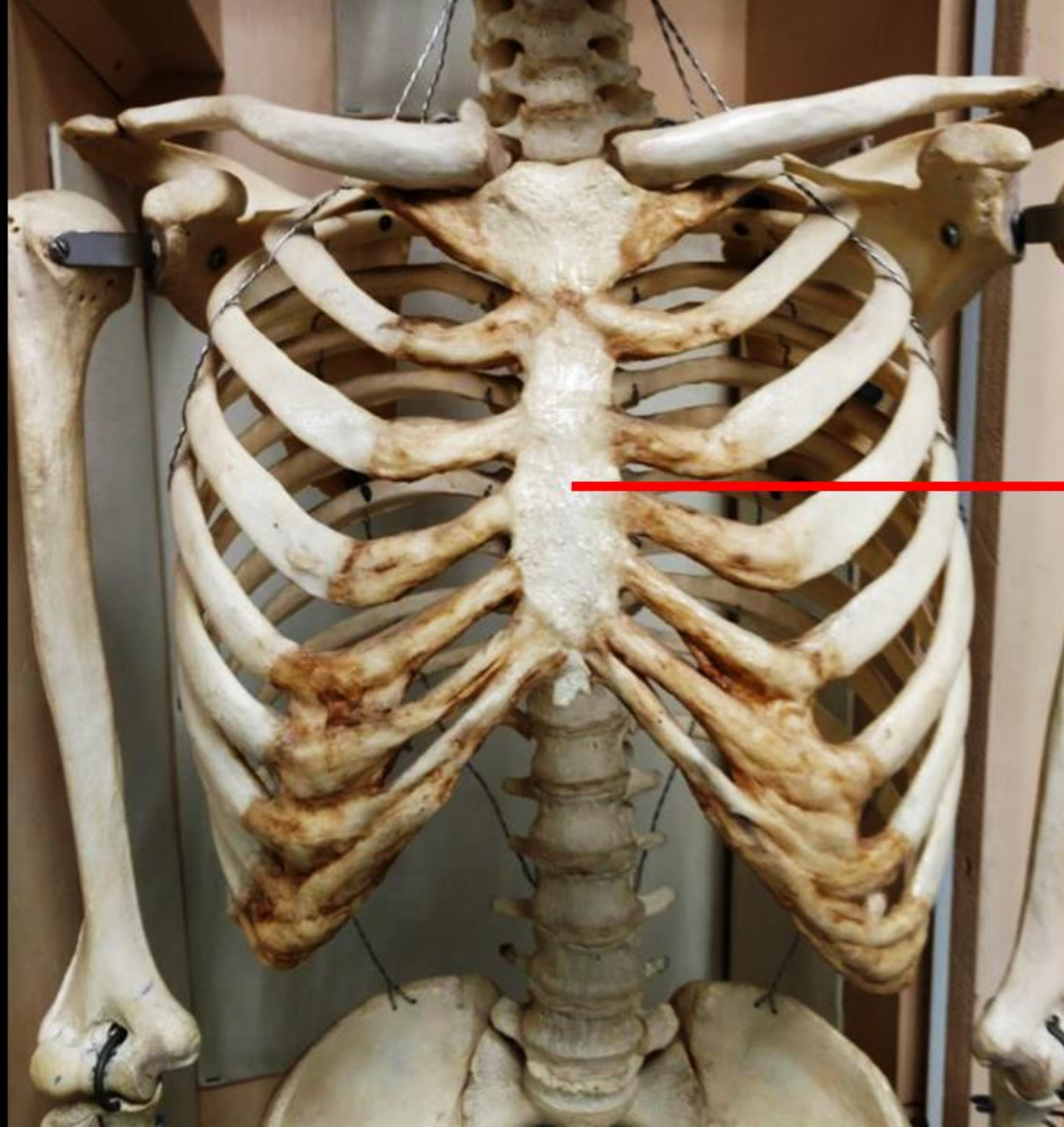
**Name the bone.  
COXAL / OS COXAE /  
HIP/ PELVIC**

**Name the Structure =  
ILIAC CREST**



**Name the Bone.**

**Name the Structure.**

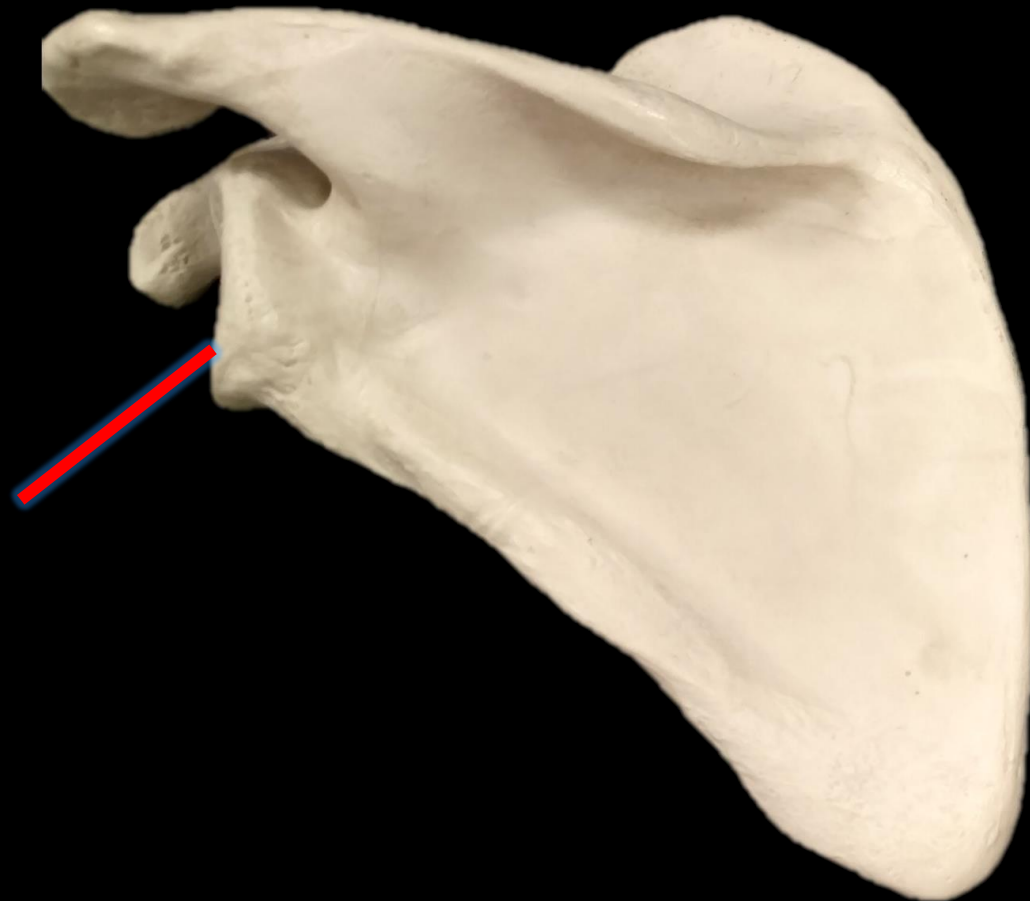


**Name the Bone  
= STERNUM**

**Name the Structure  
= BODY**

*What is the Bone?*

*What is the Structure?*

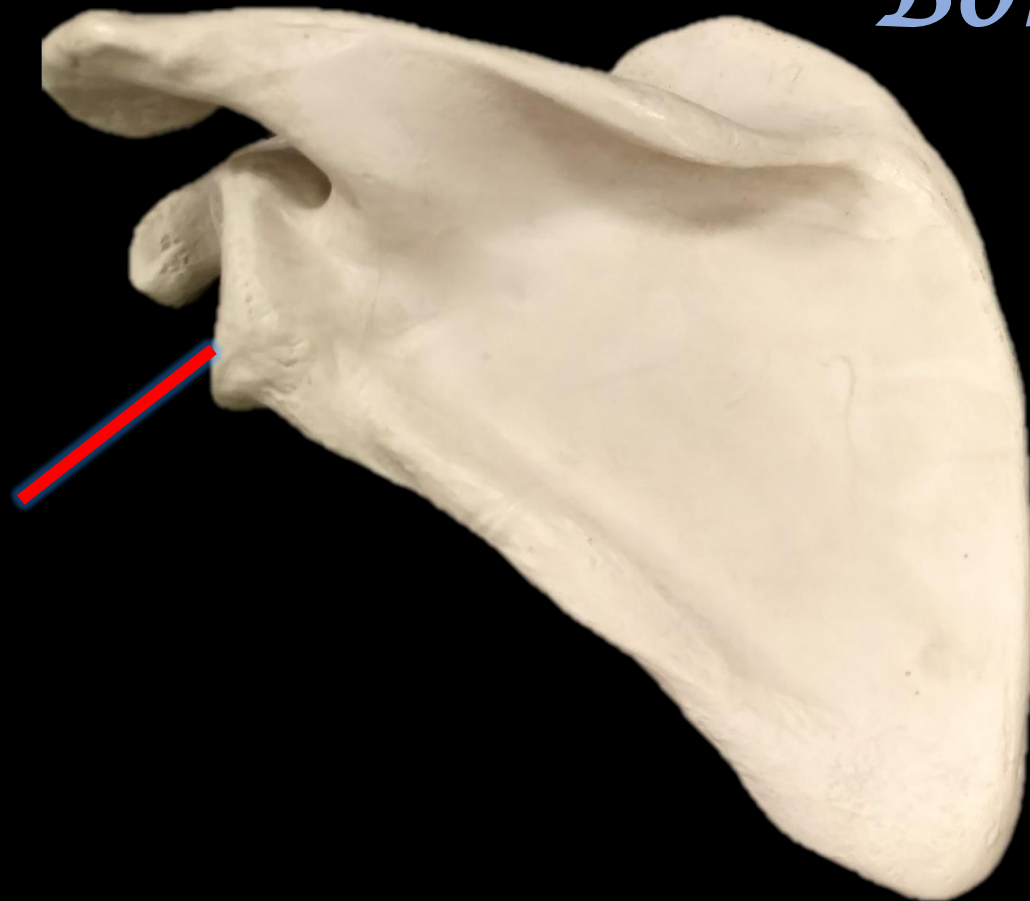


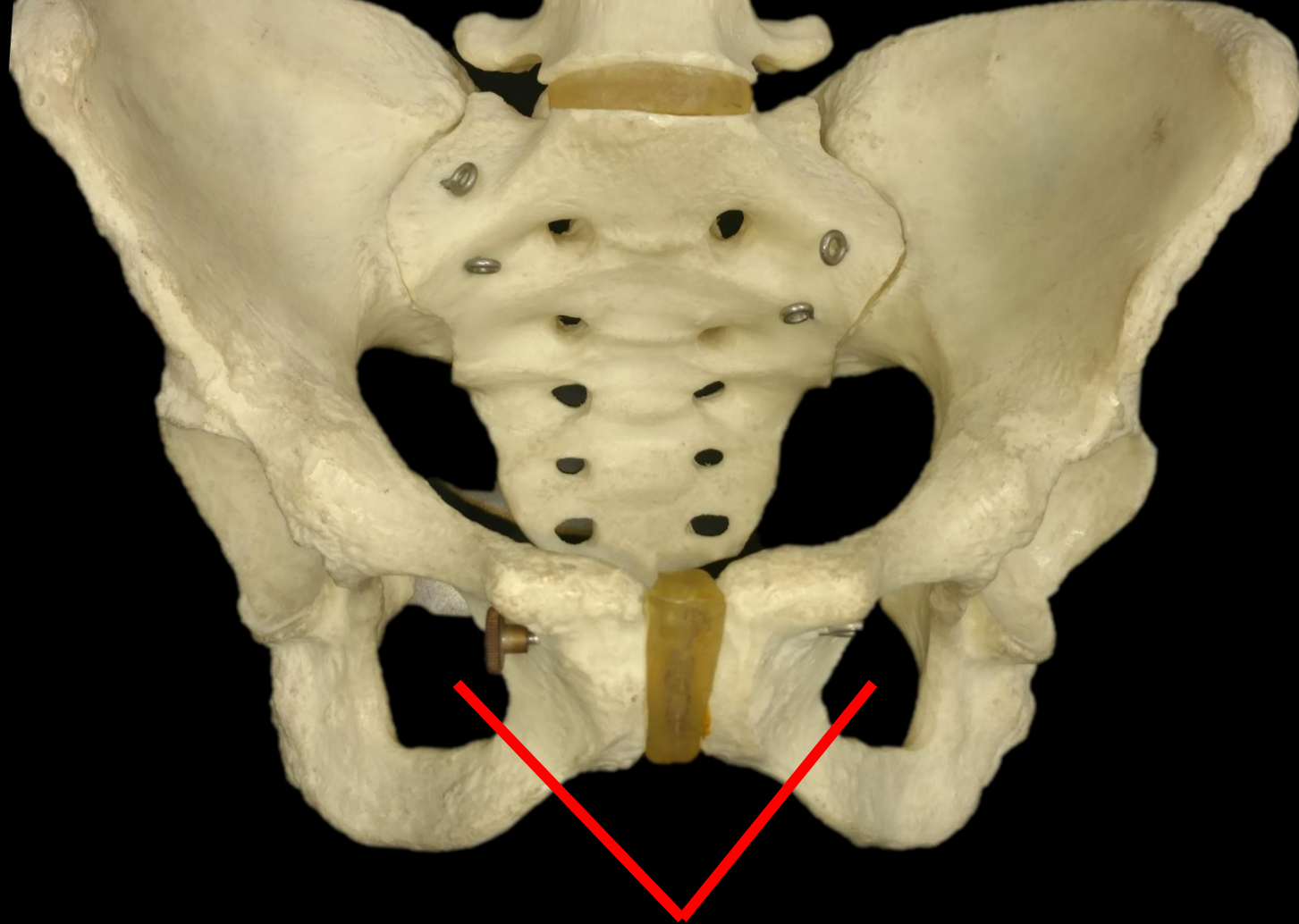
*What is the Bone?*

*What is the Structure?*

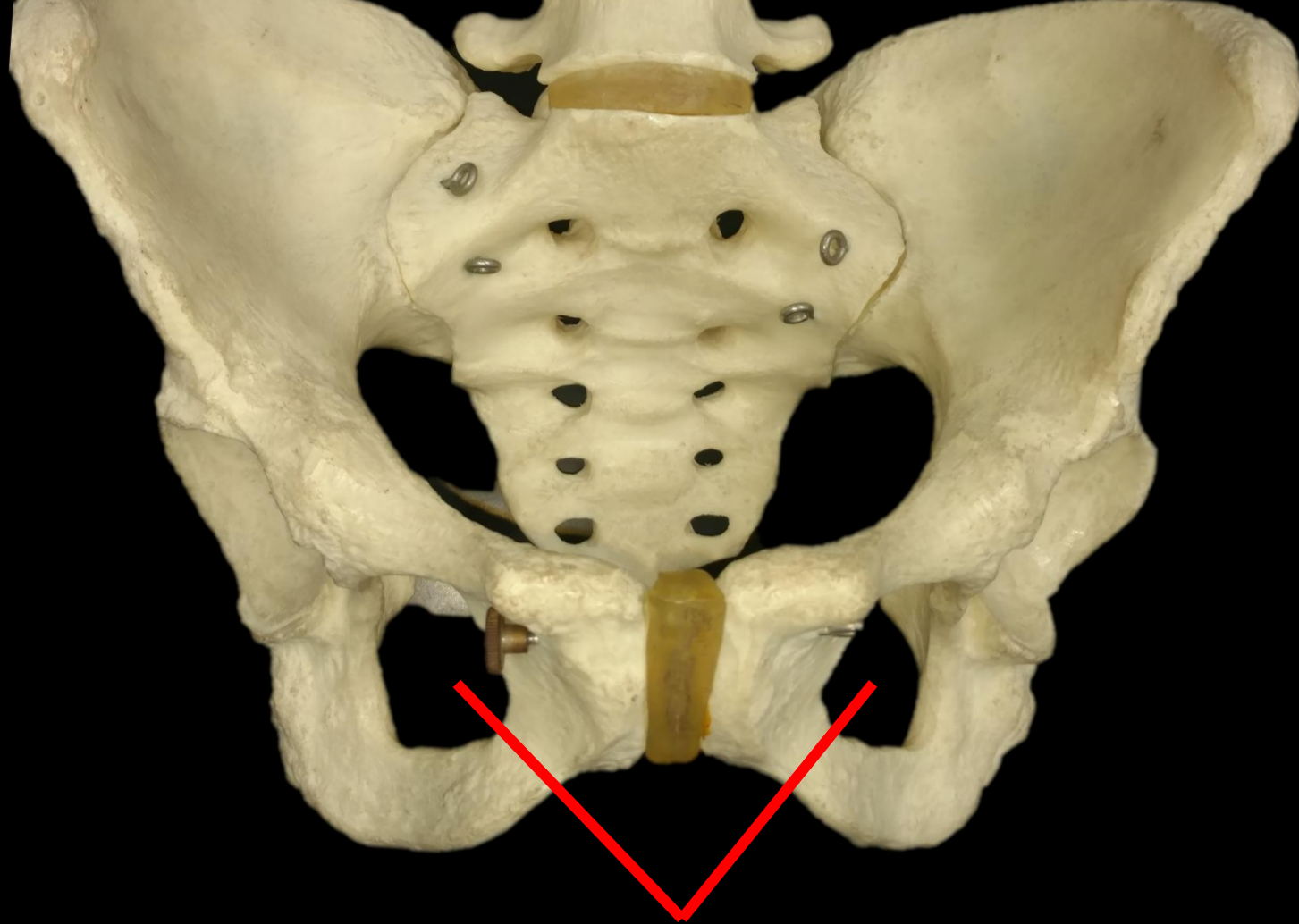
*Bone = Scapula*

*Glenoid  
Cavity*

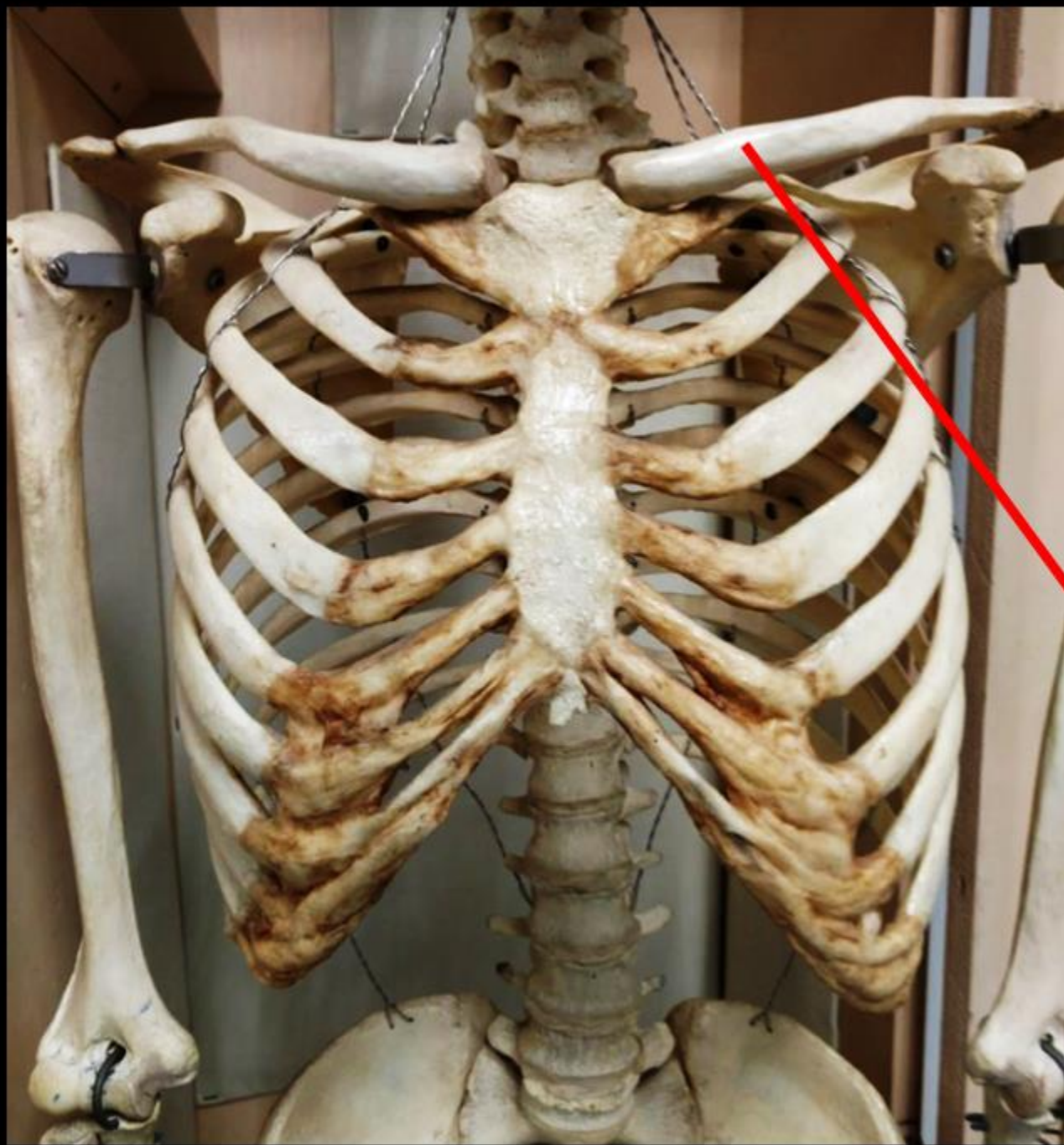




*What are These?*

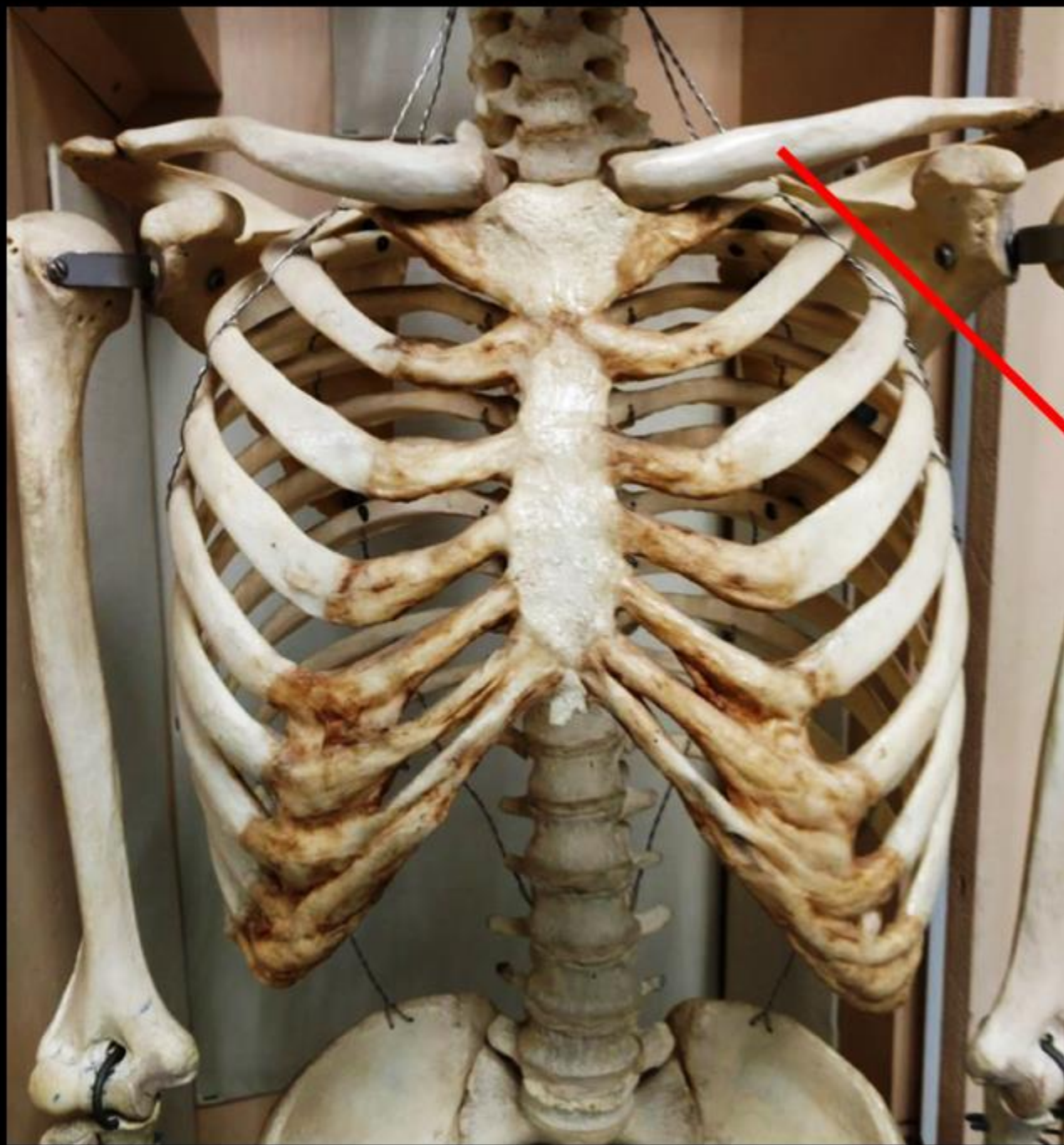


*Obturator Foramen (Foramina)*



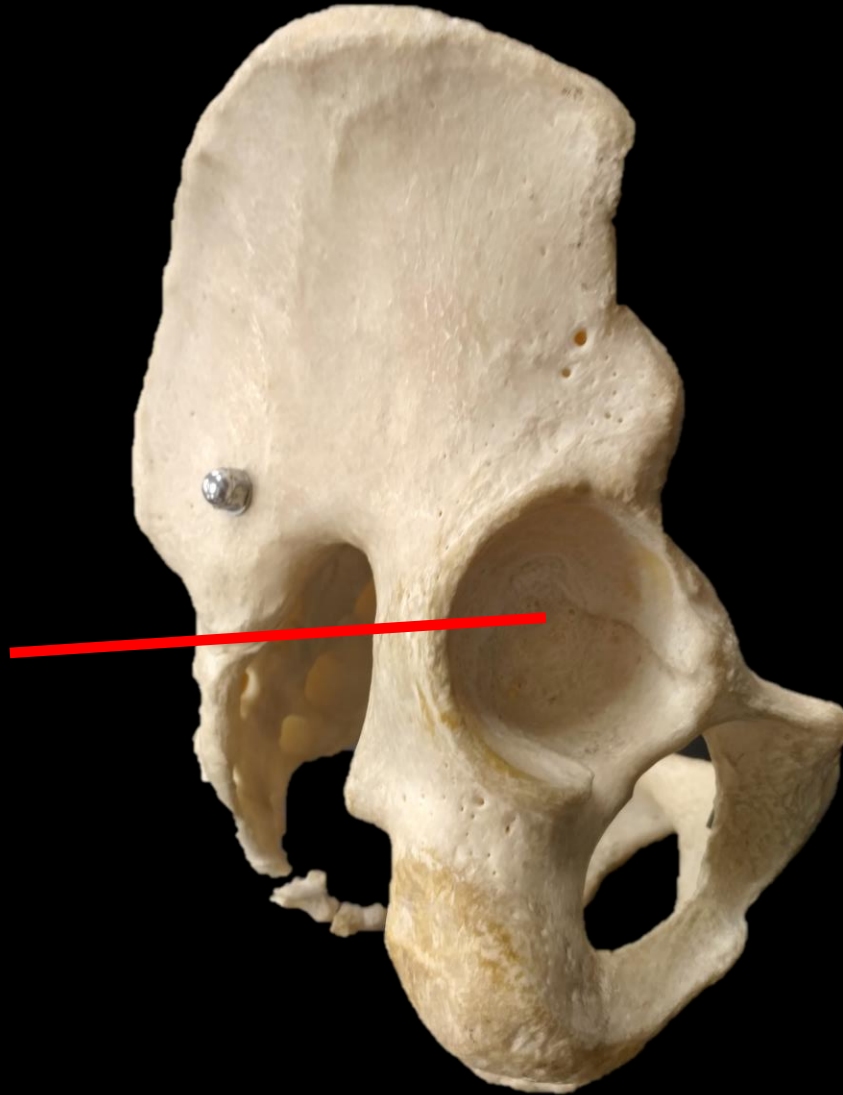
**Name the Bone.**





**Name the Bone  
= CLAVICLE**

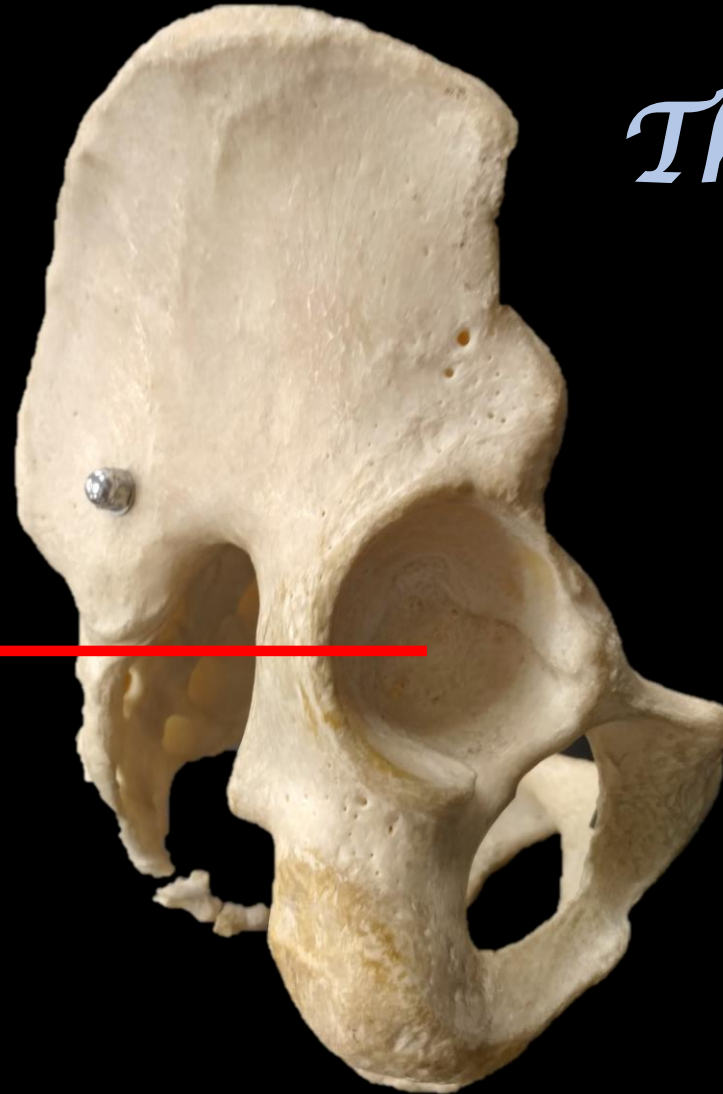
*What is the Bone? What is the Structure?*

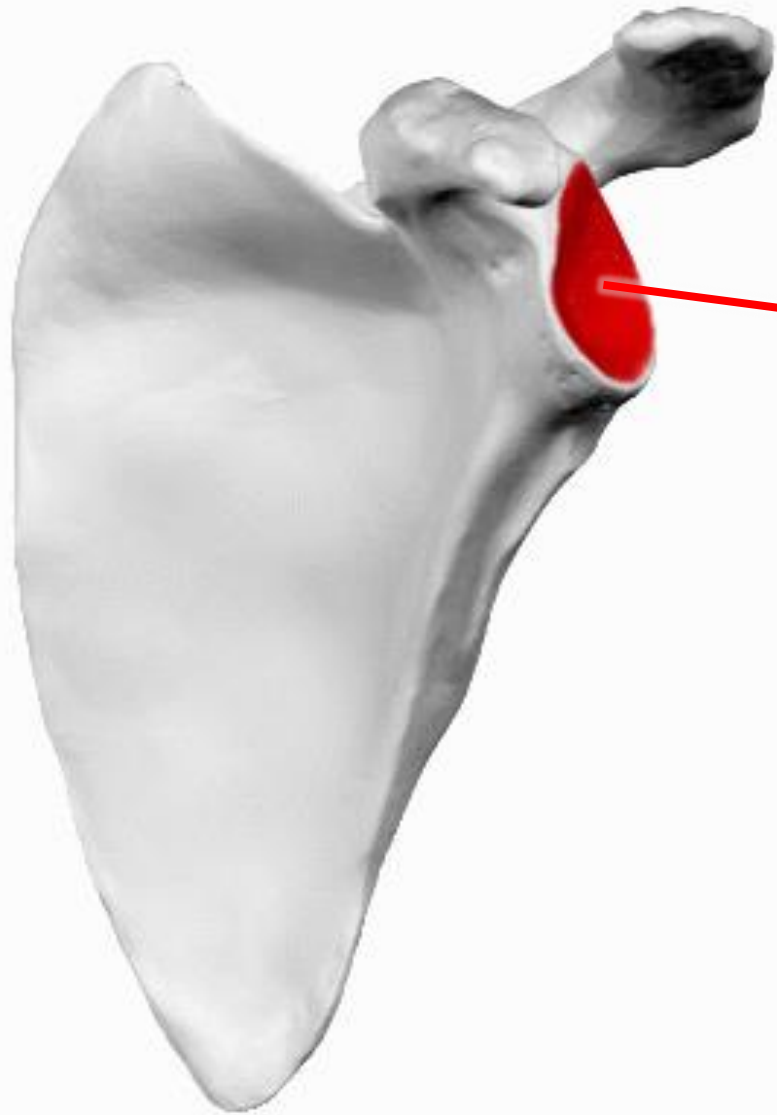


*What is the Bone? What is the Structure?*

*The Coxal  
Bone*

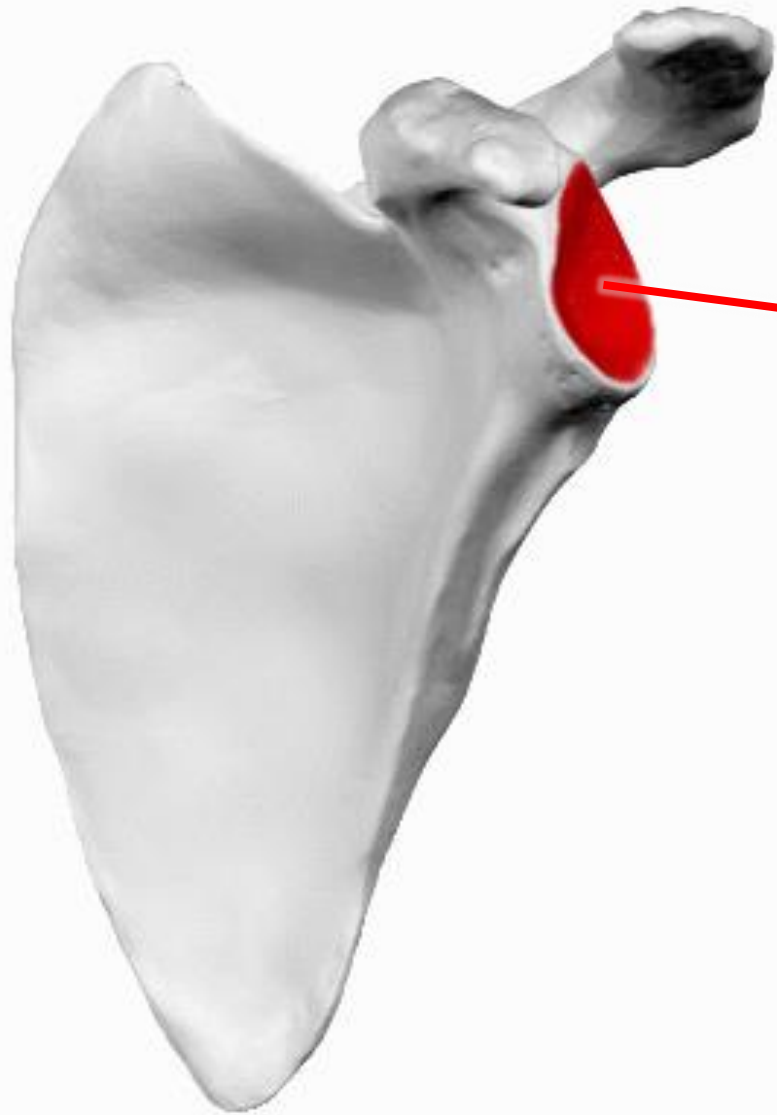
*Acetabulum*





Name the bone

Name the structure



Name the bone

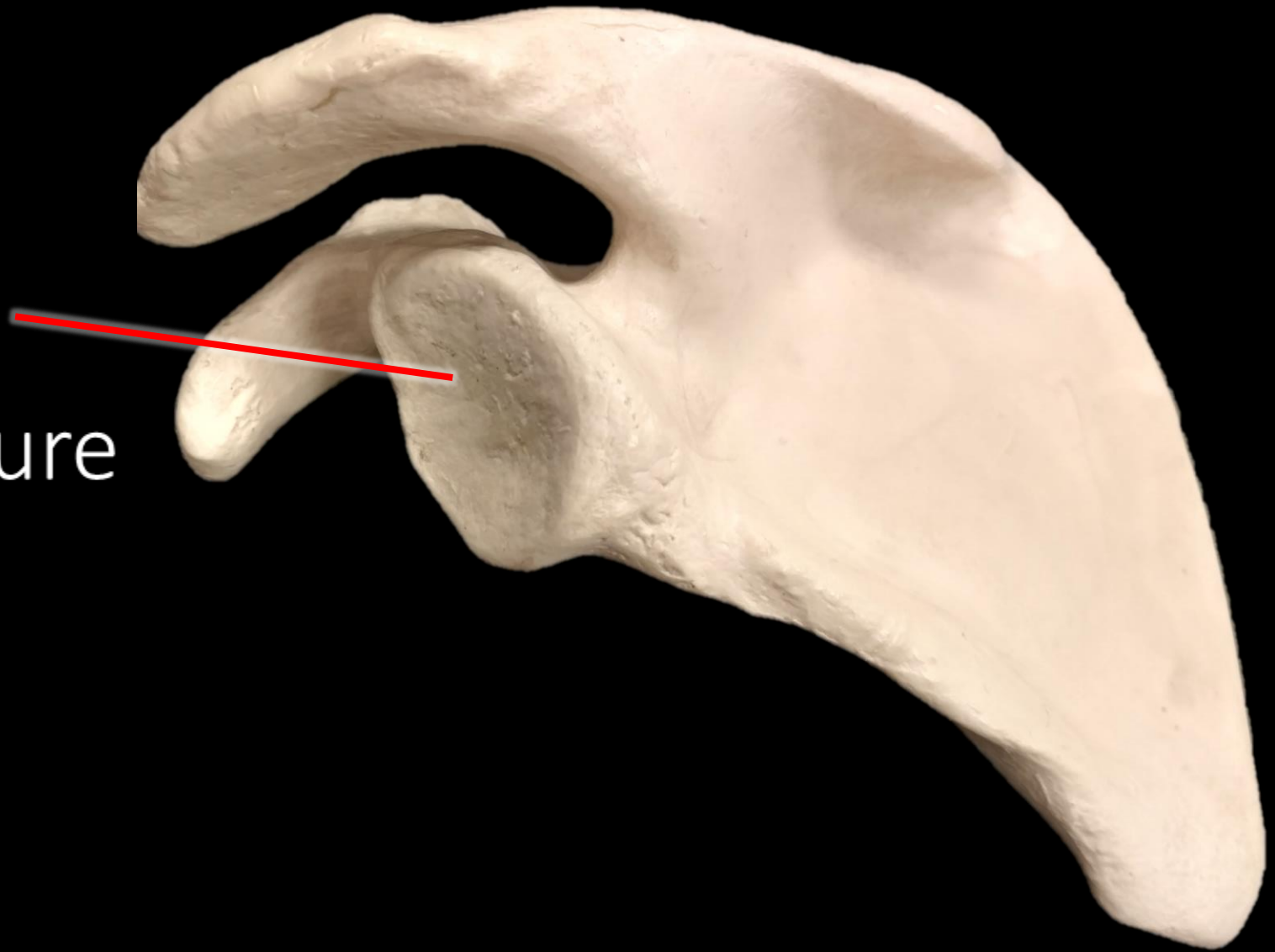
**SCAPULA**

Name the structure

**GLENOID  
CAVITY**

Name the bone

Name the structure

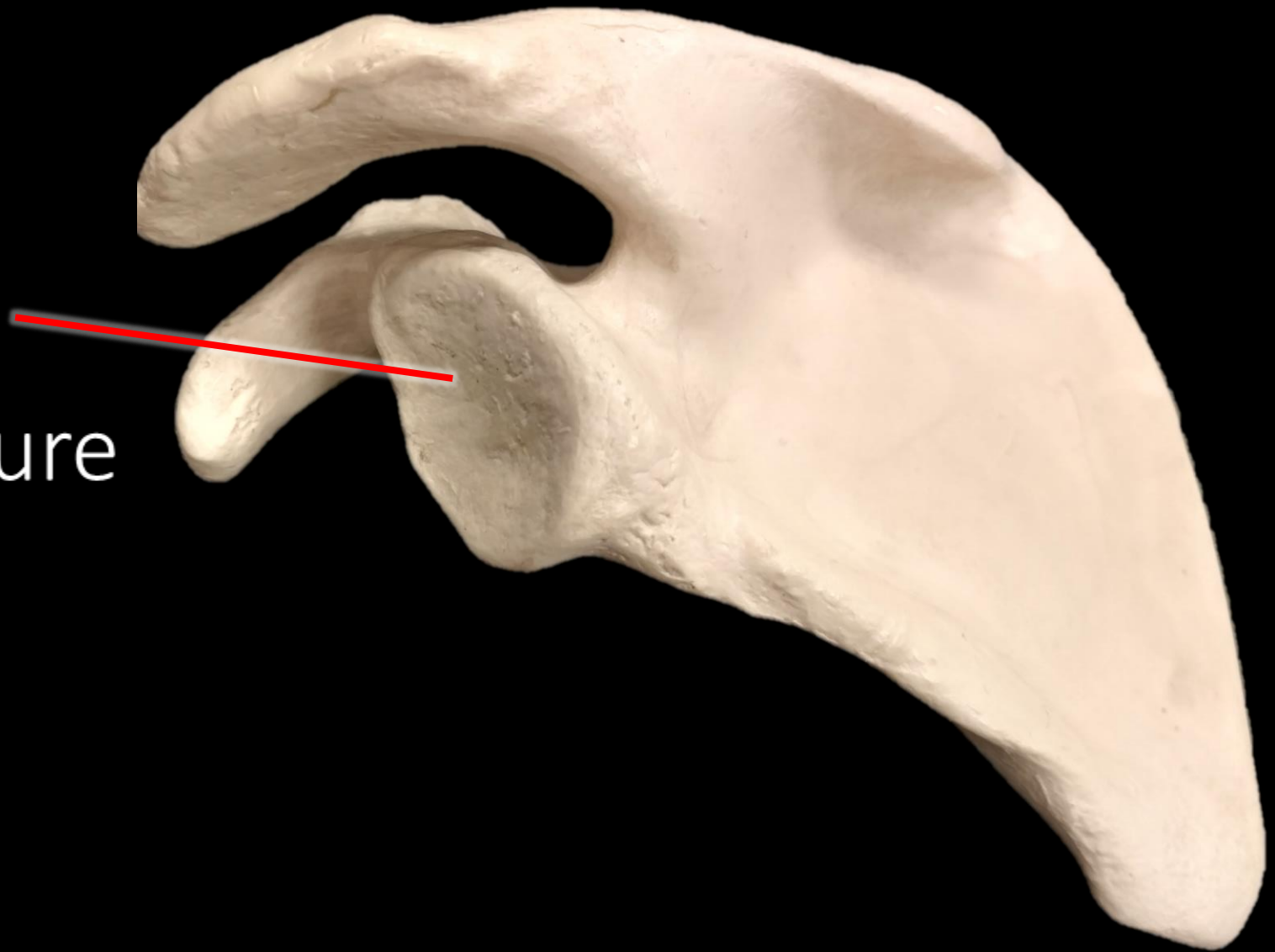


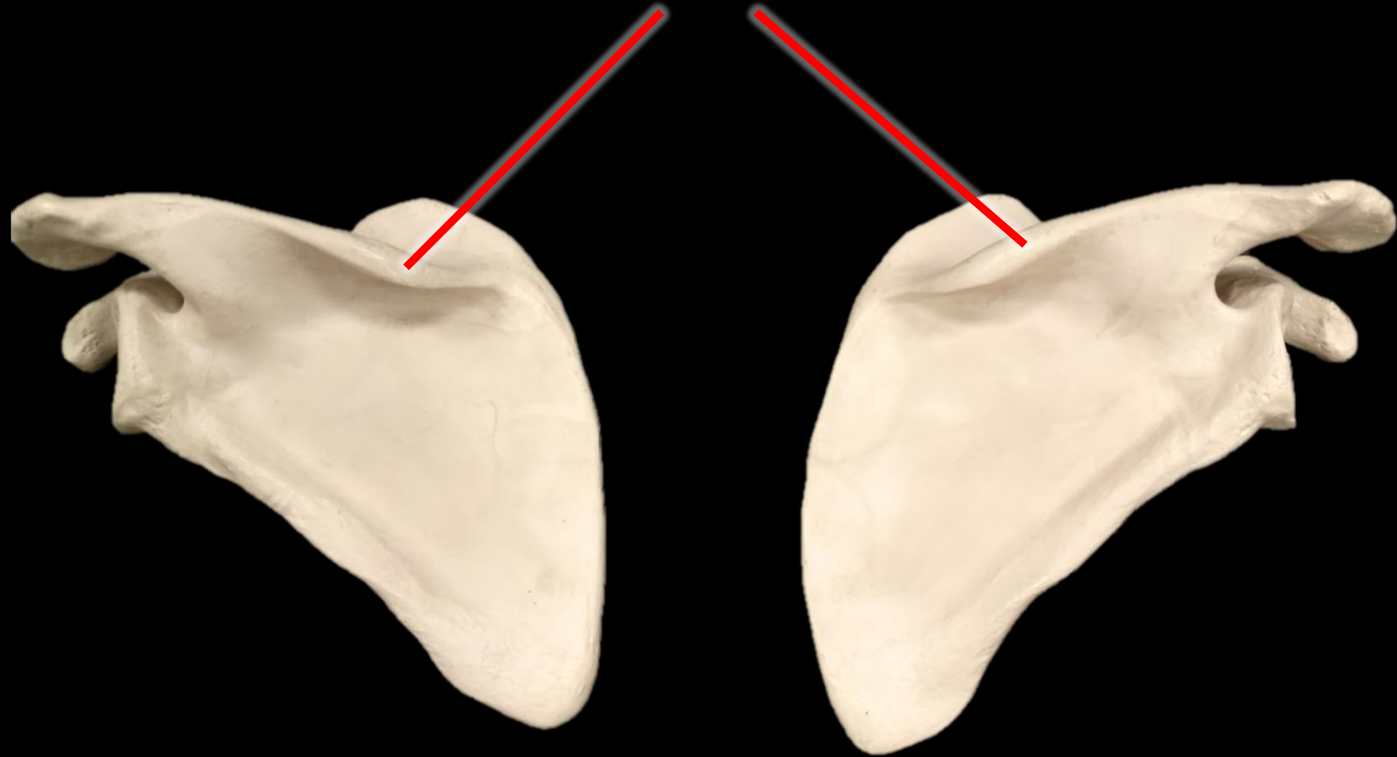
Name the bone

**SCAPULA**

Name the structure

**GLENOID  
CAVITY**



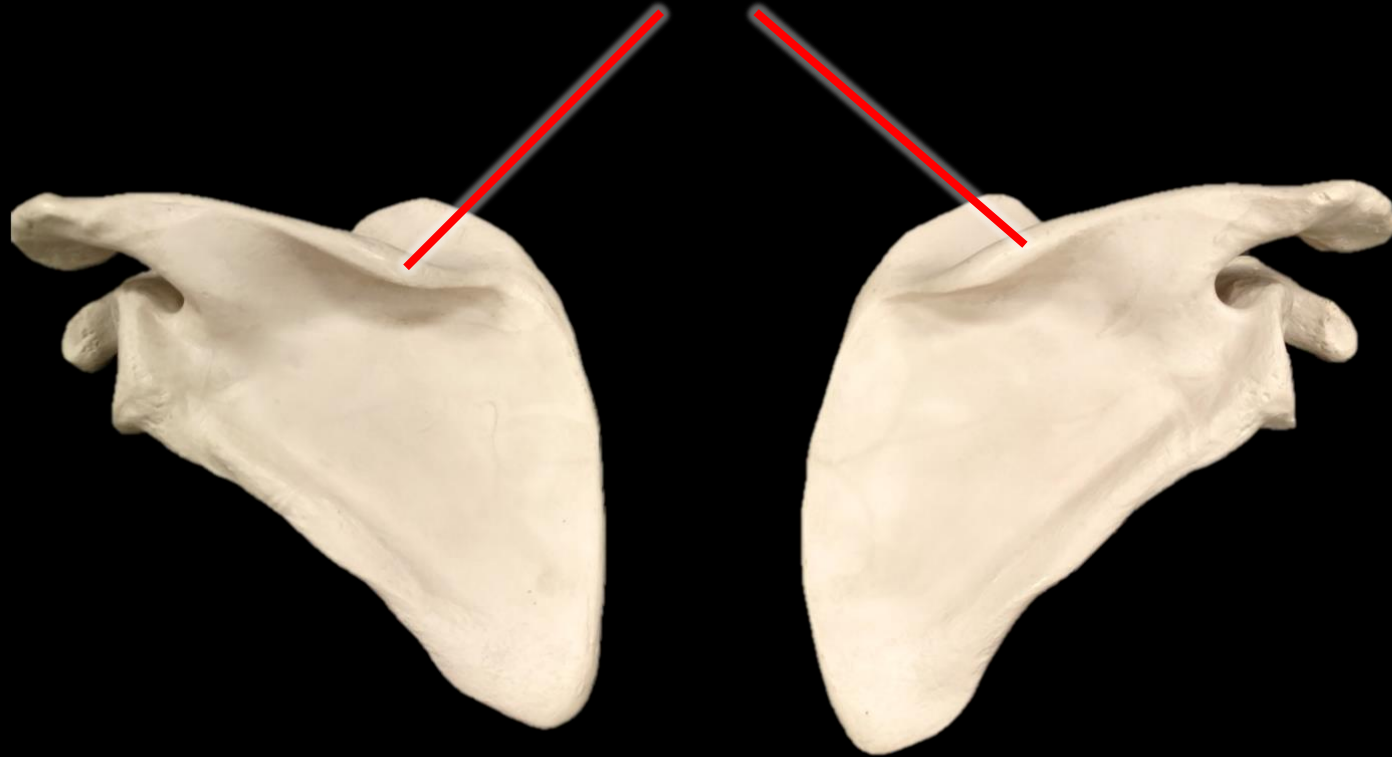


*What is the  
Bone?*

*What is the  
Structure?*



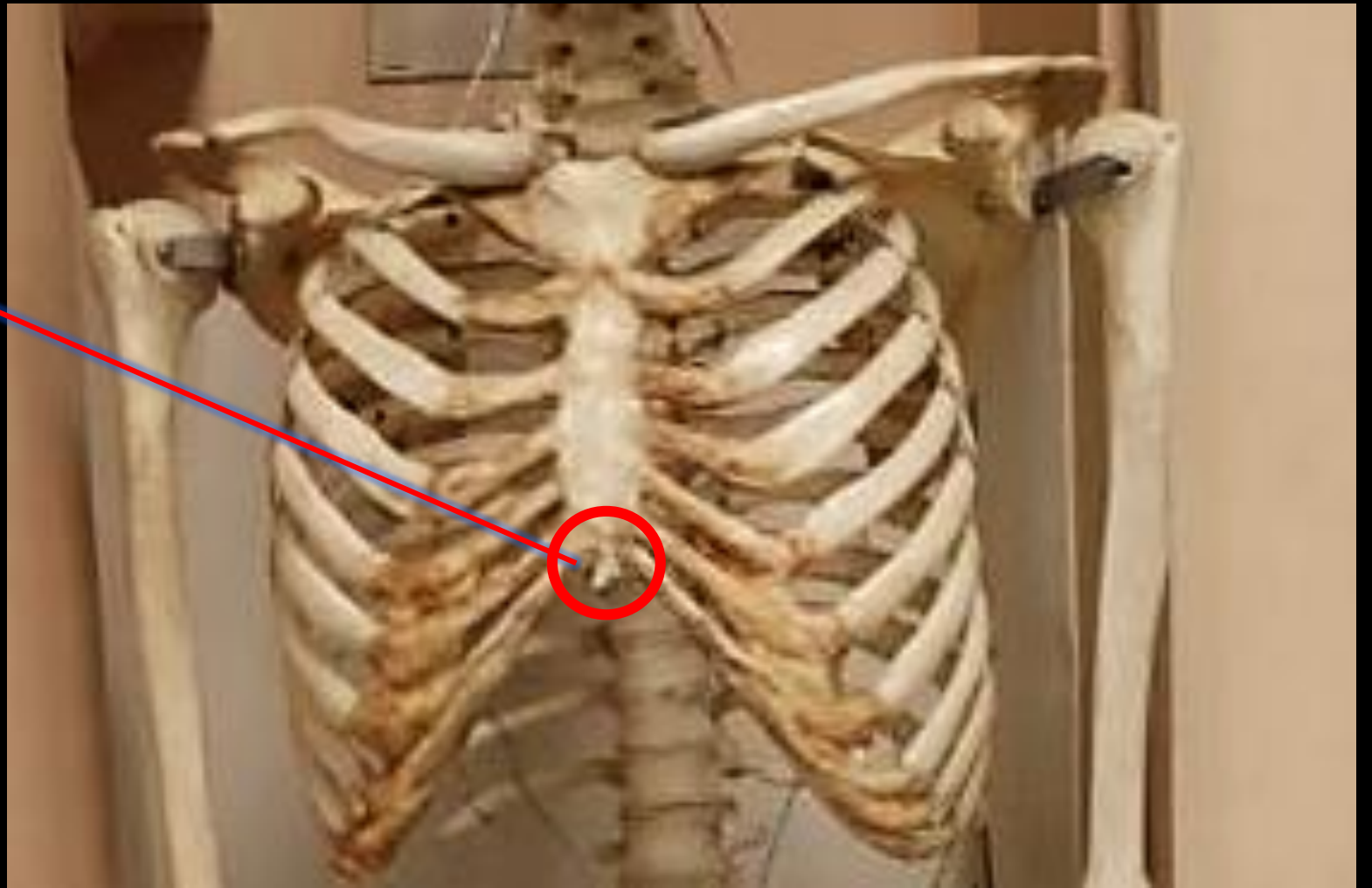# *The Spine of the Scapula*



*What is the  
Bone?*

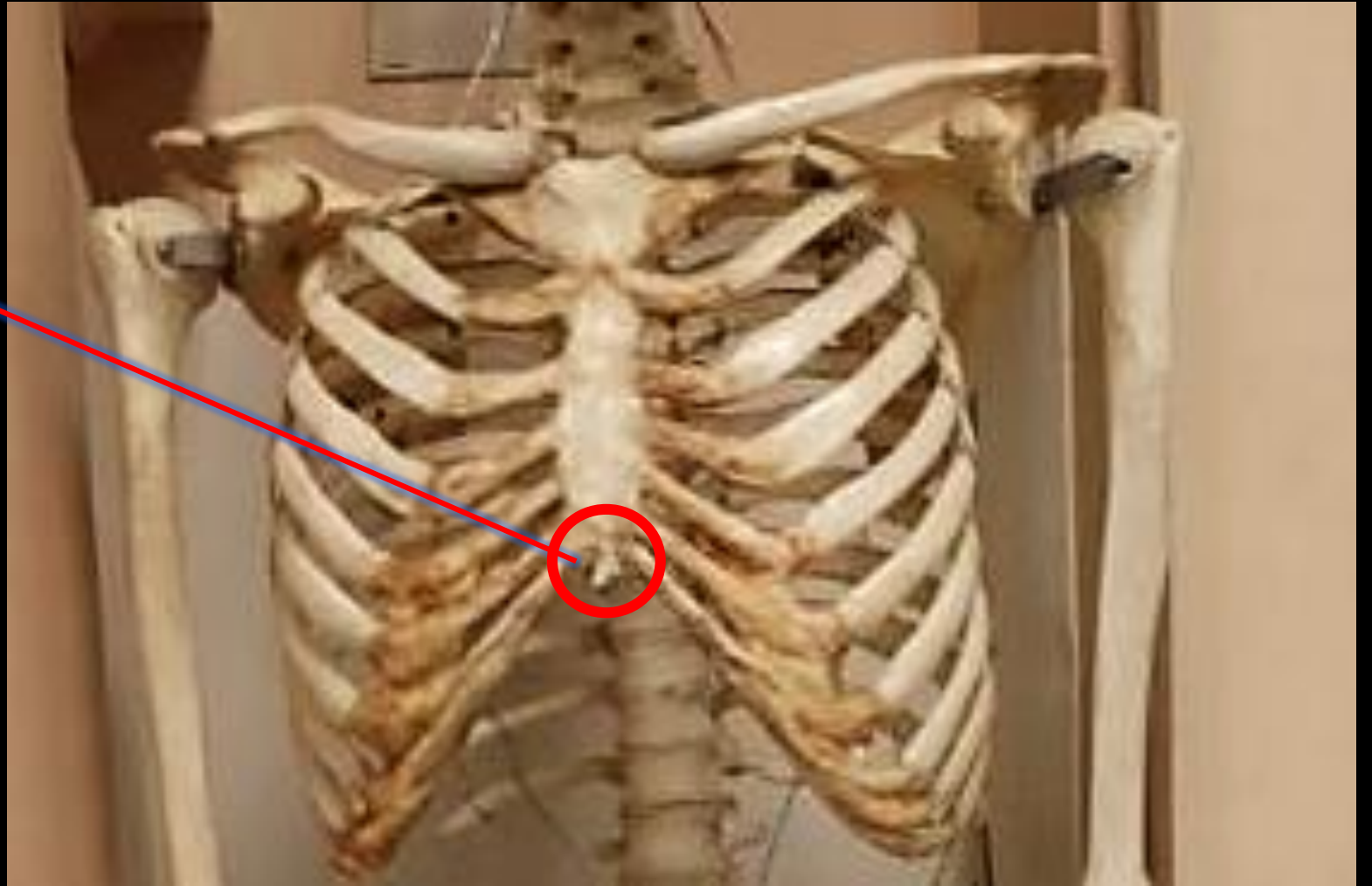*What is the  
Structure?*

Name the Bone.  
Name the  
Structure.



Name the Bone.  
Name the  
Structure.

The Bone is the  
Sternum.  
The Structure is  
the Xiphoid.



*What is the Bone?*



*What is the Structure?*

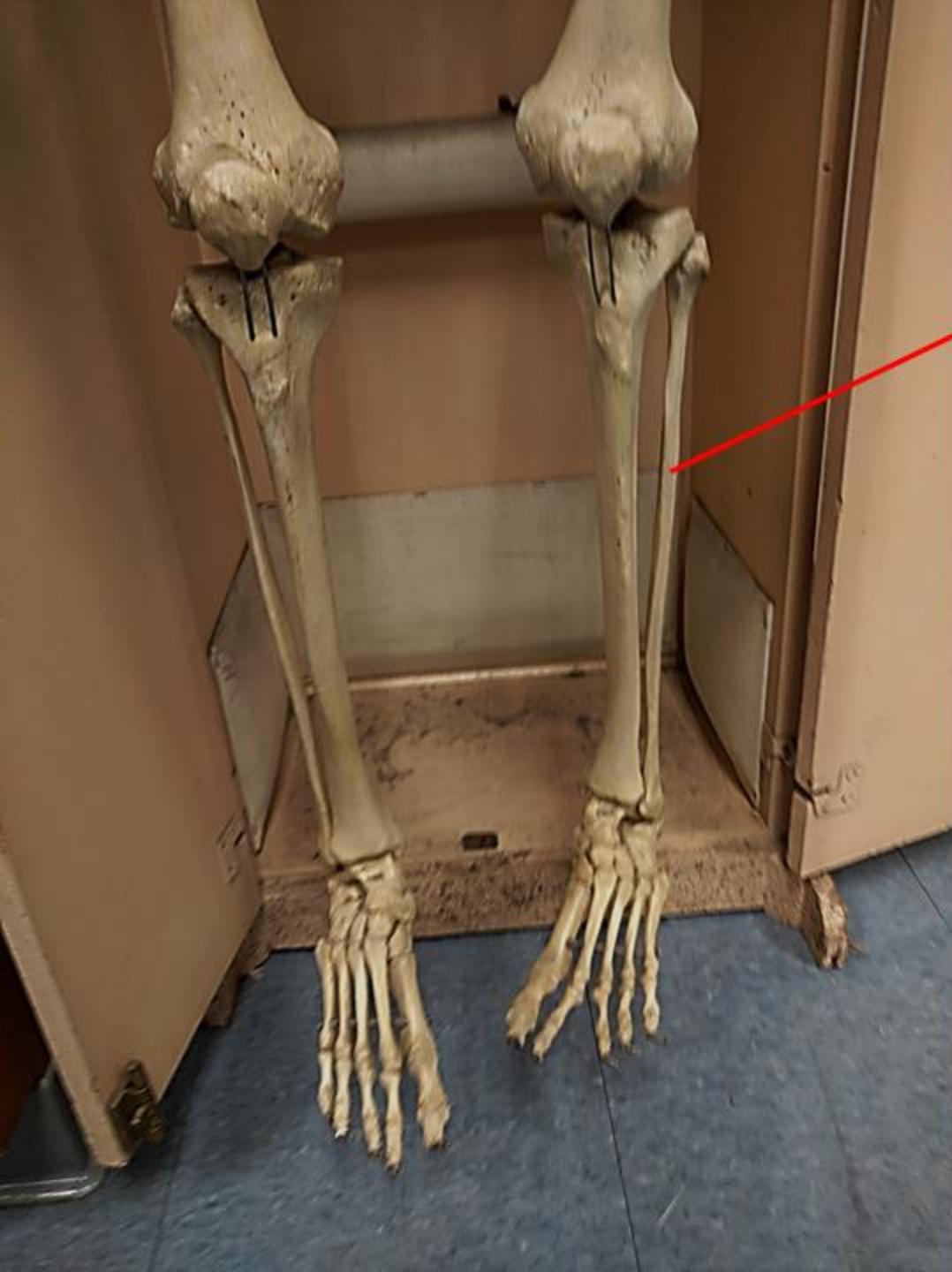*What is the Bone?*

*Ulna*

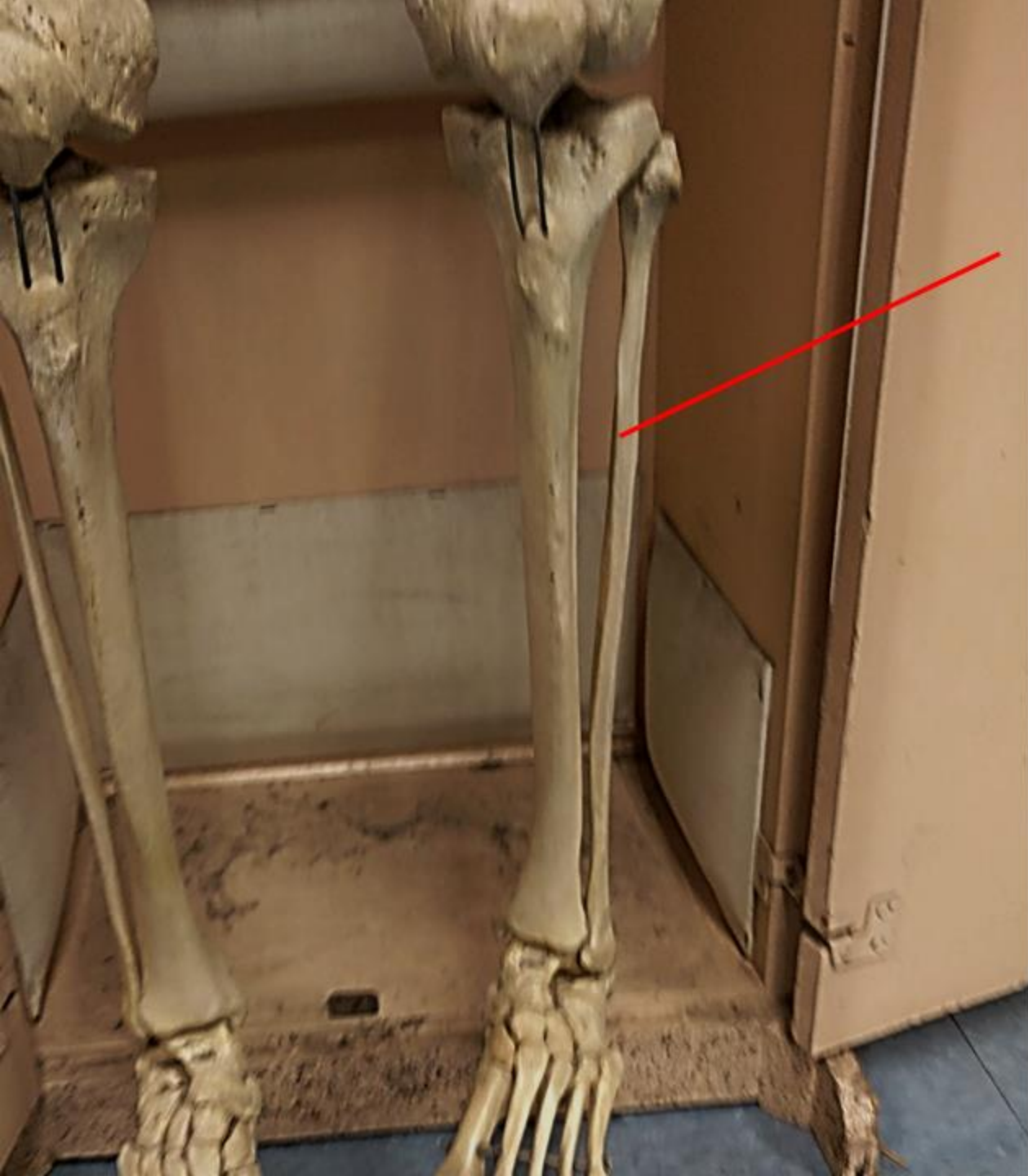

*What is the Structure?*

*The Coronoid Process*



Name the Bone



Name the Bone = Fibula

*What is the Bone?*



*What is the Structure?*



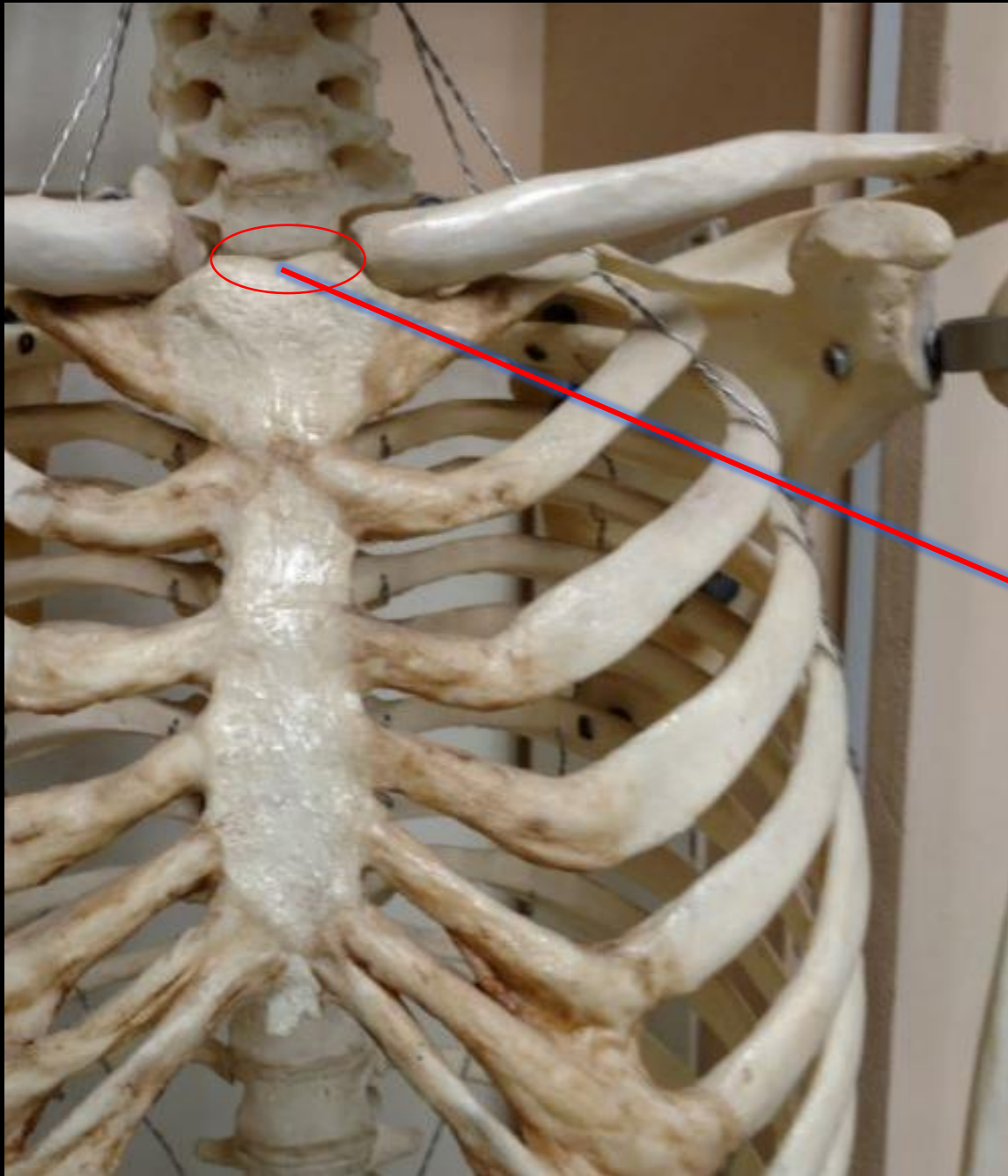
*What is the Bone?*

*Ulna*



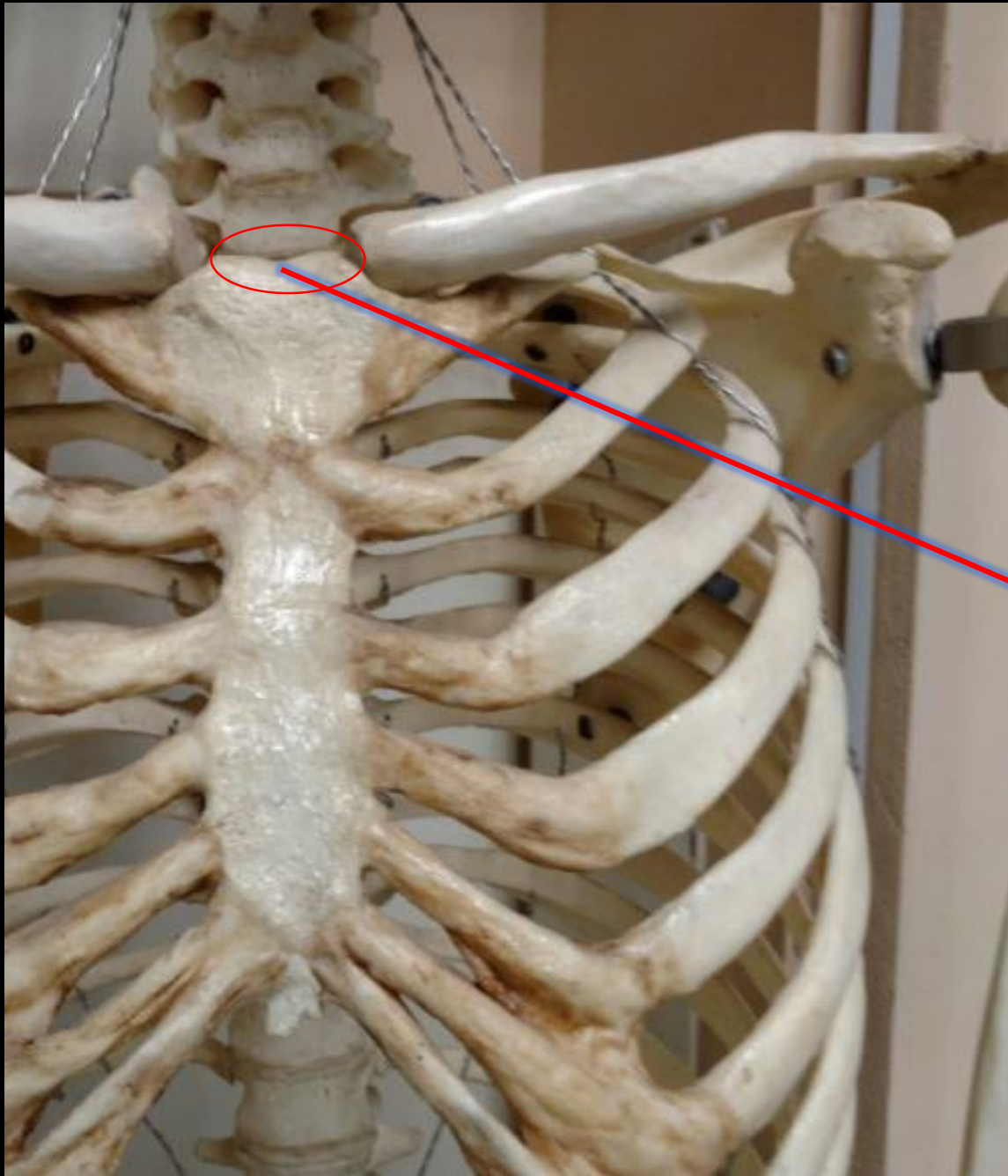
*What is the Structure?*

*The Olecranon Process*



What is the Bone?

What is the Structure?



What is the Bone?  
What is the Structure?

**The Bone is the Sternum**  
**This is the Jugular Notch**

**What is the Bone?**

**What is the Structure?**



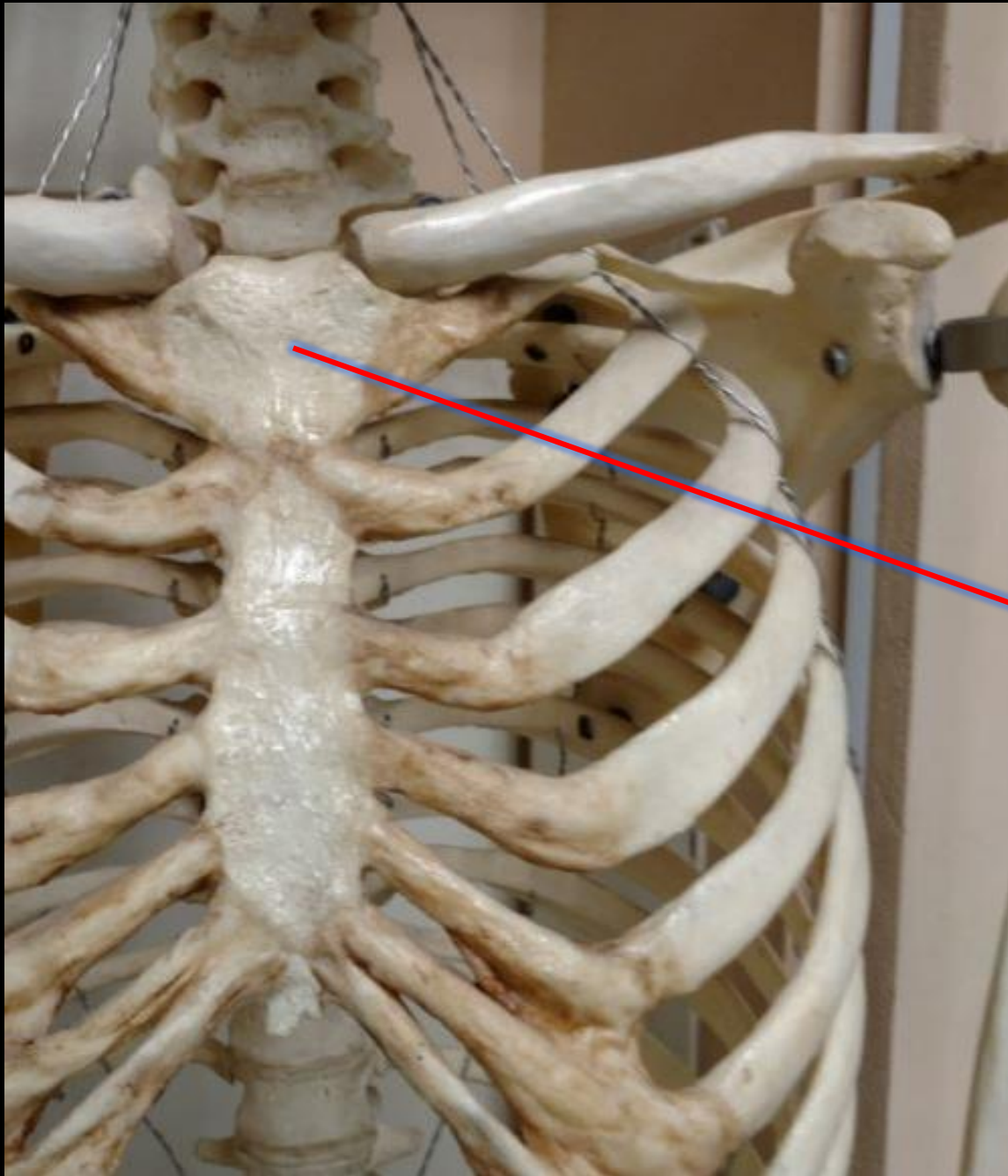
**What is the Bone?**

**What is the Structure?**

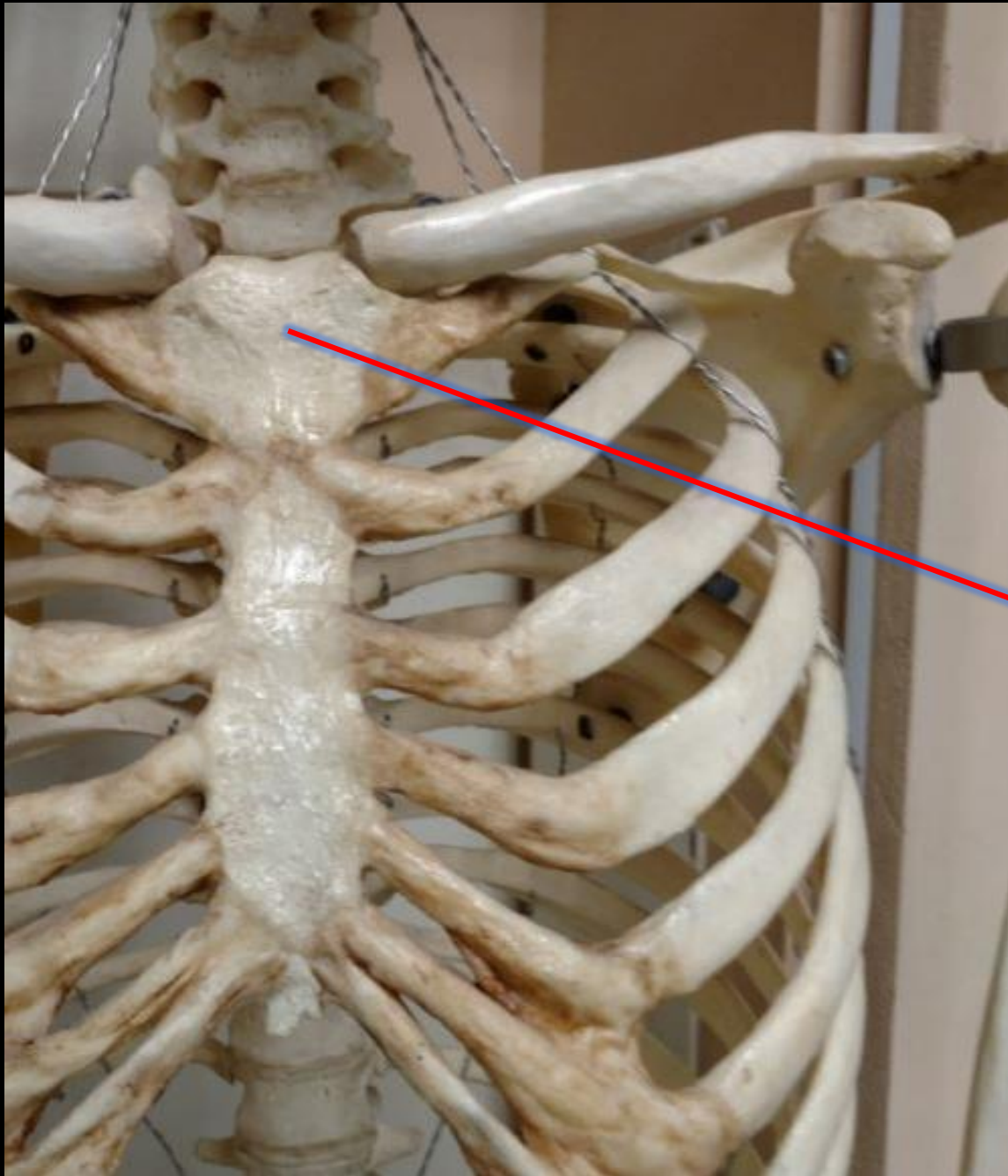
**The Humerus**



**The Head of the Humerus**



What is the Bone?  
What is the Structure?

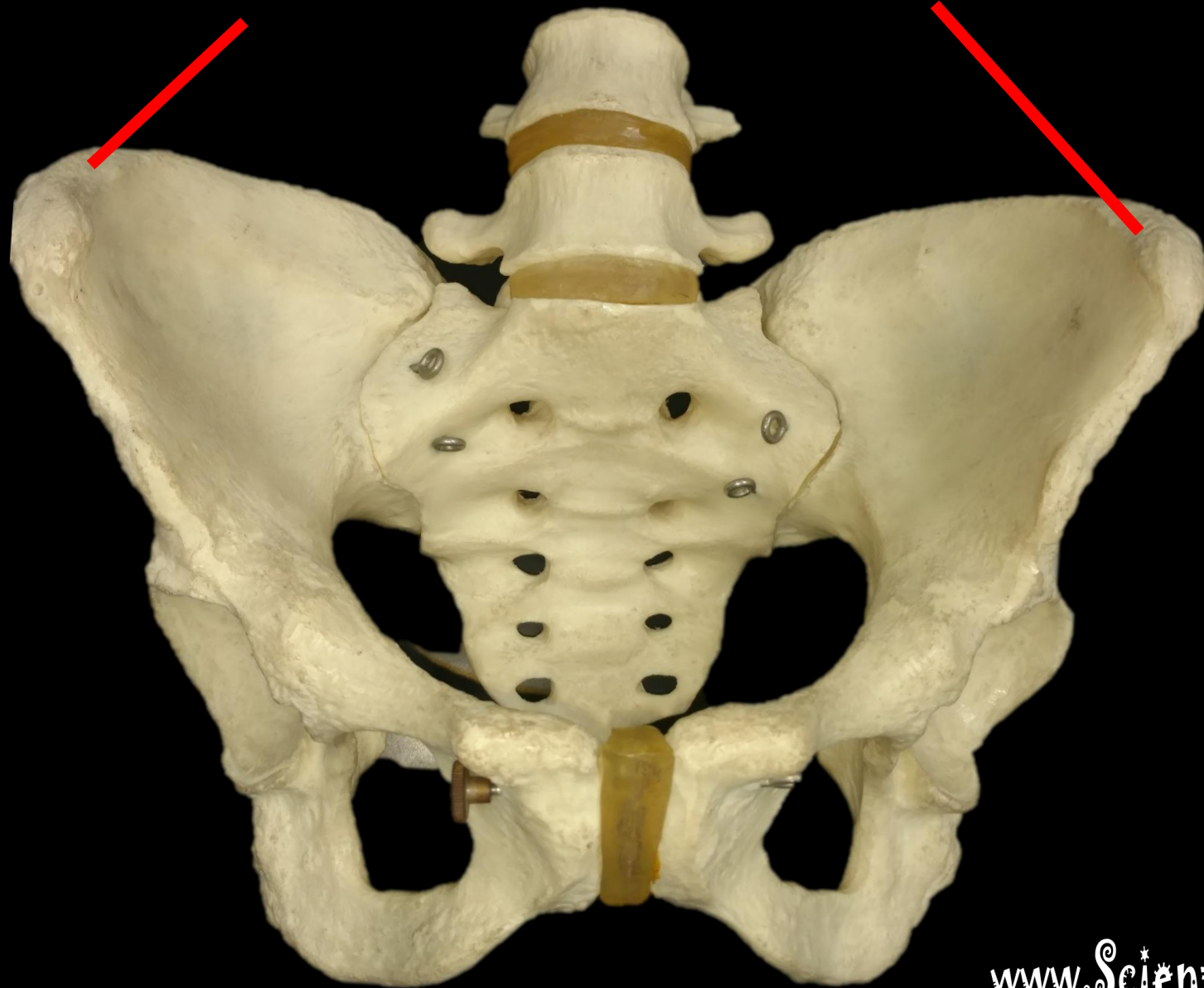


What is the Bone?  
What is the Structure?

**The Bone is the Sternum**

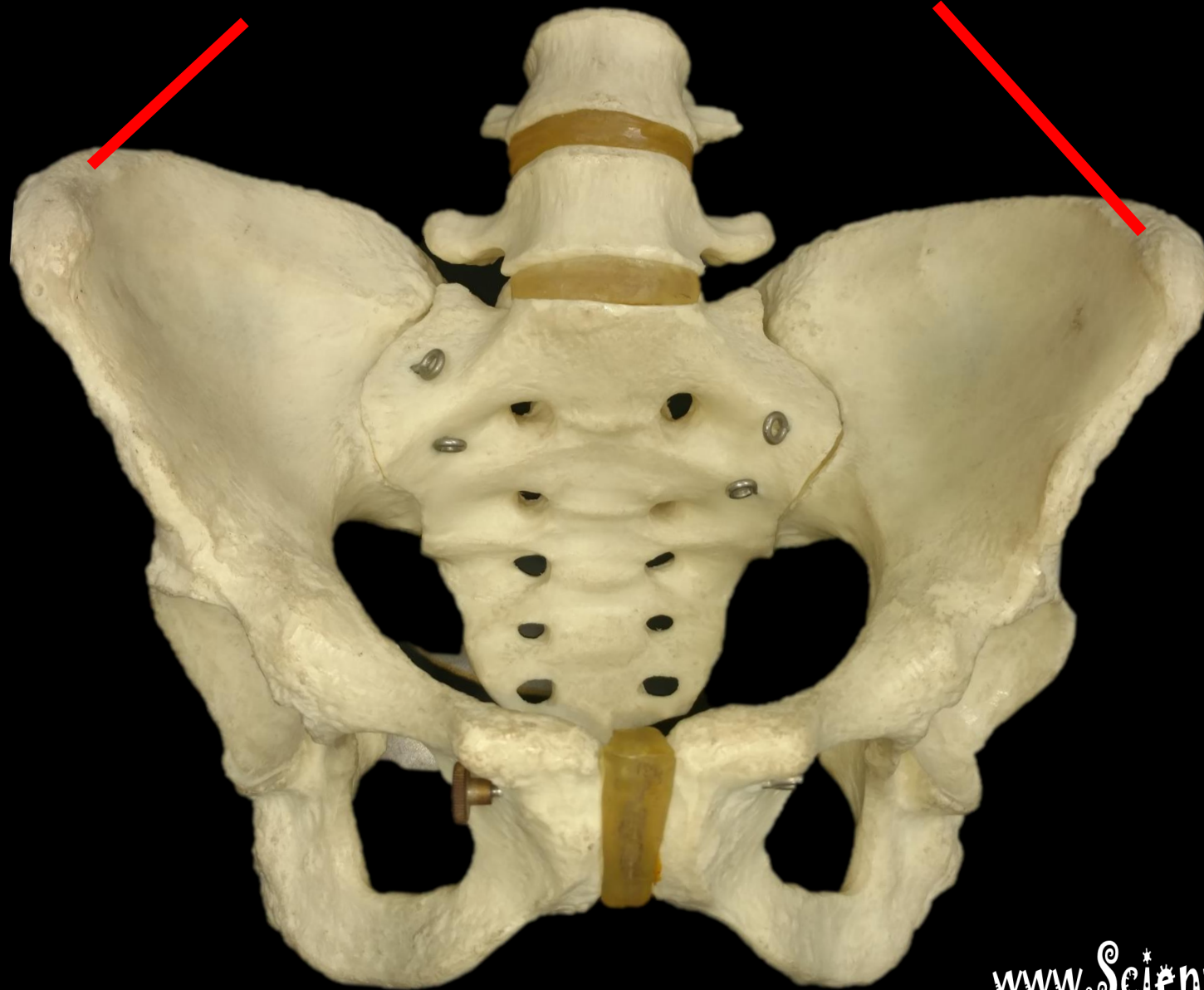
**This is the Manubrium**

*What is this Structure?*

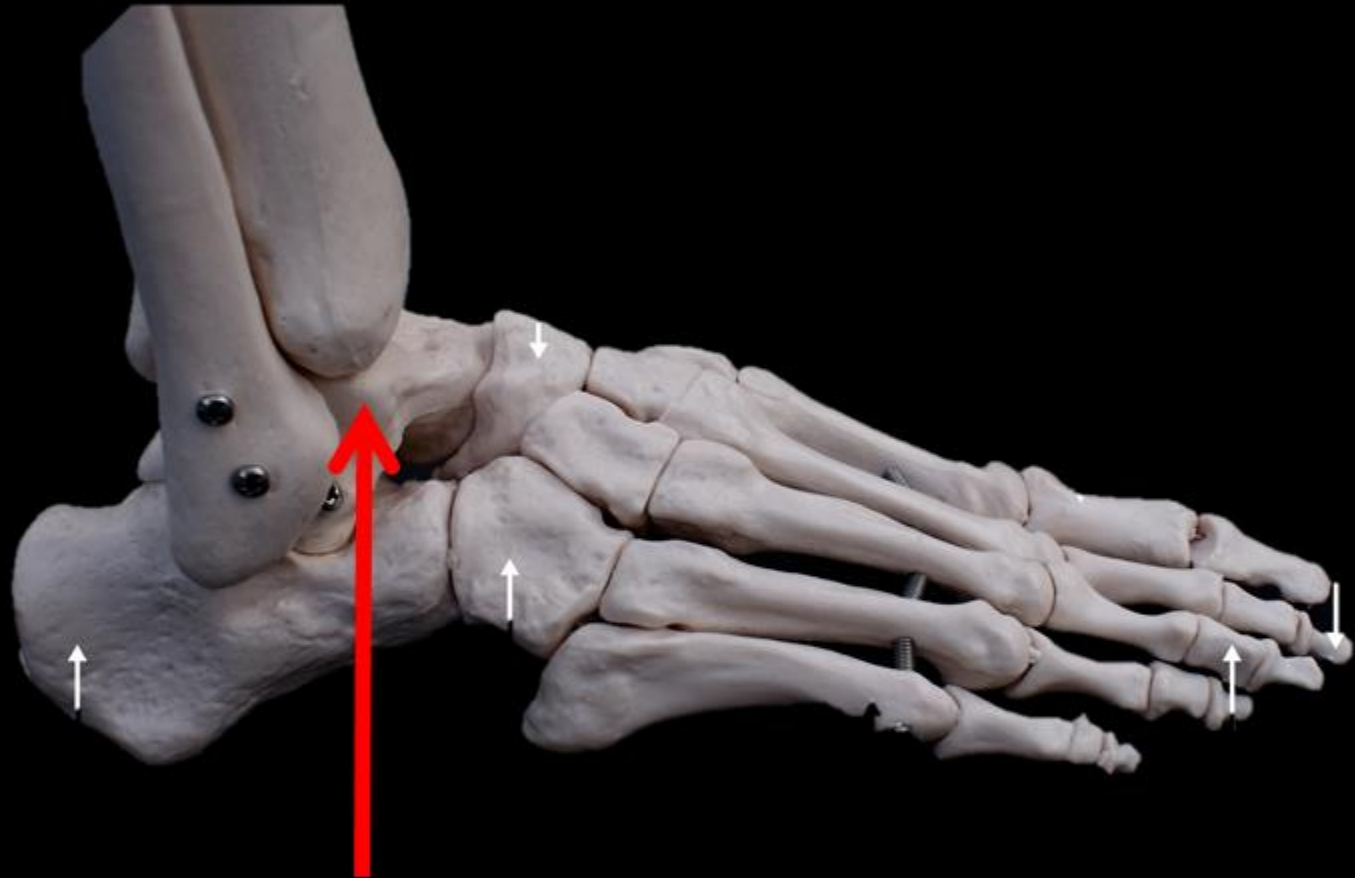




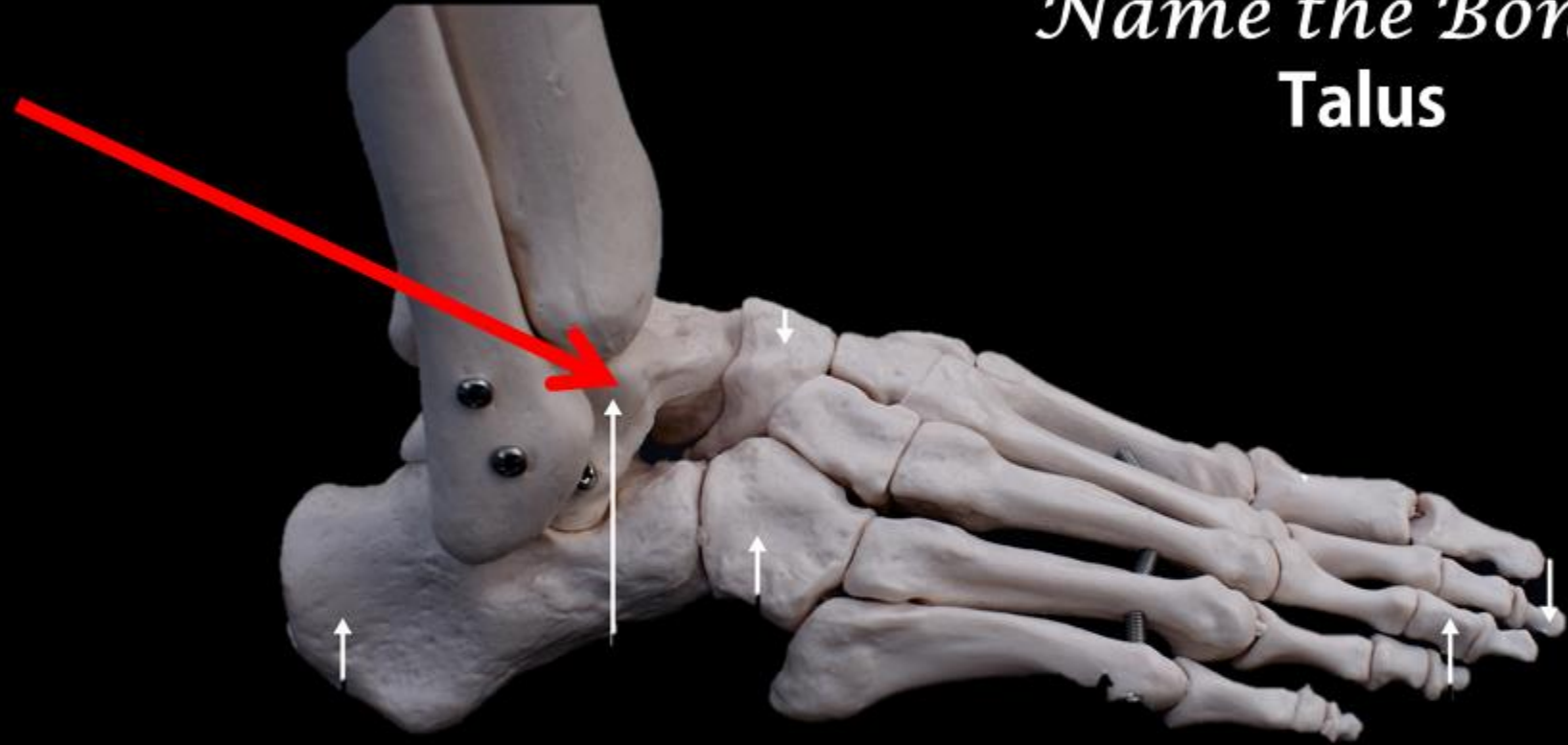
# *The Iliac Crest*



*Name the Bone*



*Name the Bone =*  
**Talus**



**Identify the Bone.**

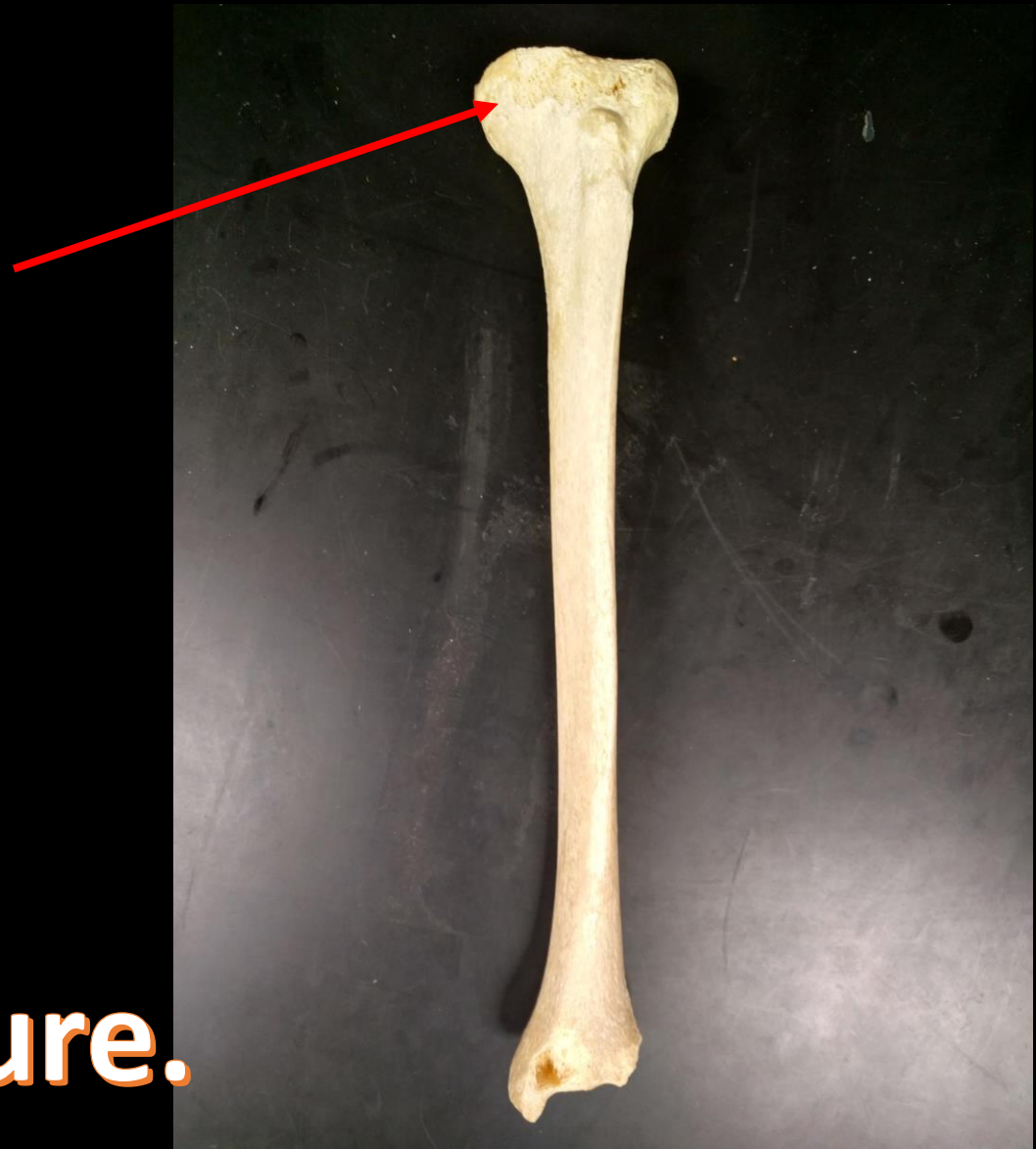

**Identify the Bone.**



**The Clavicle.**

**Identify the Bone.**  
**Identify the Structure.**



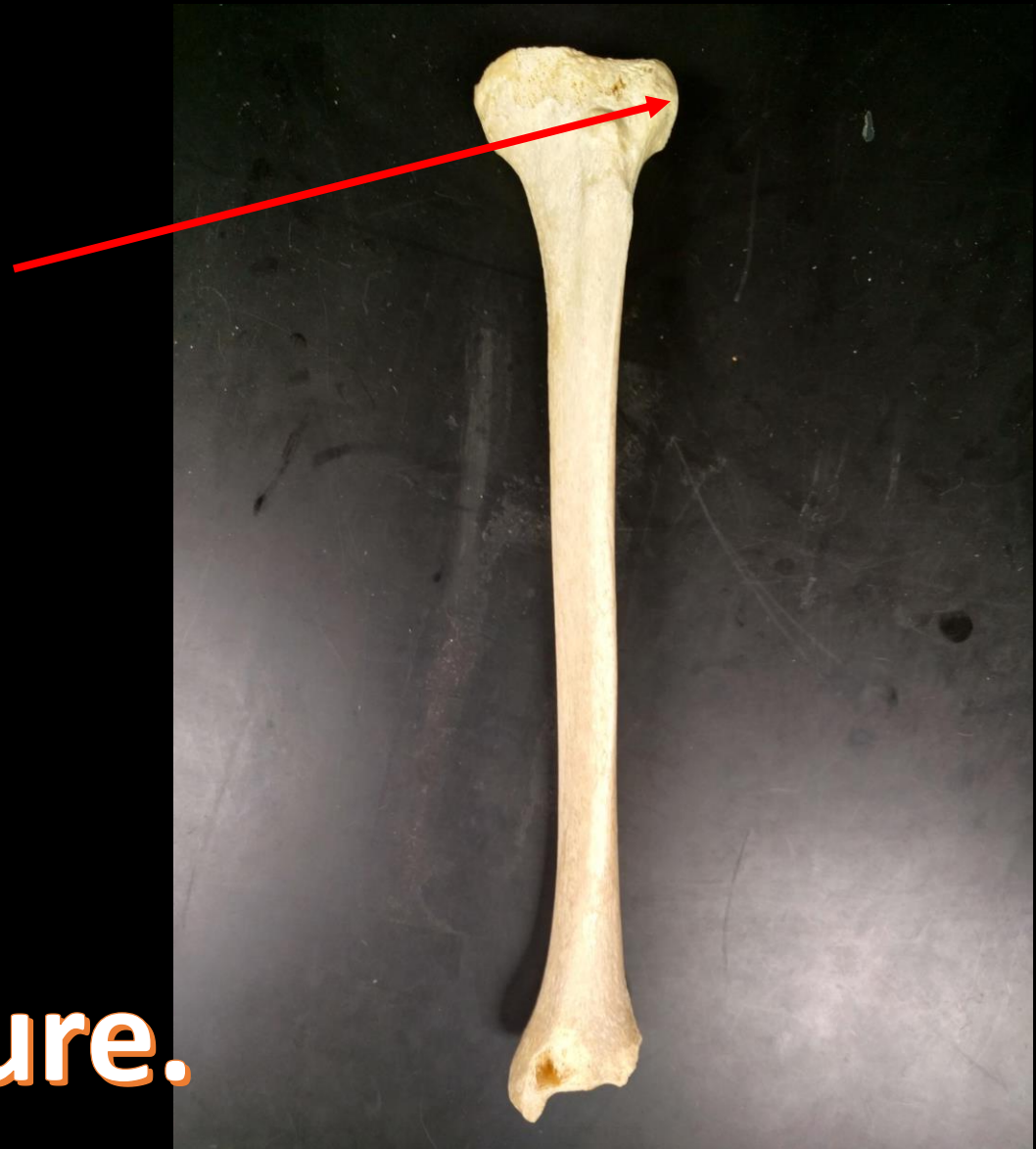
**Bone = Tibia**

**Medial  
Condyle**

**Identify the Bone.  
Identify the Structure.**



**Identify the Bone.**  
**Identify the Structure.**

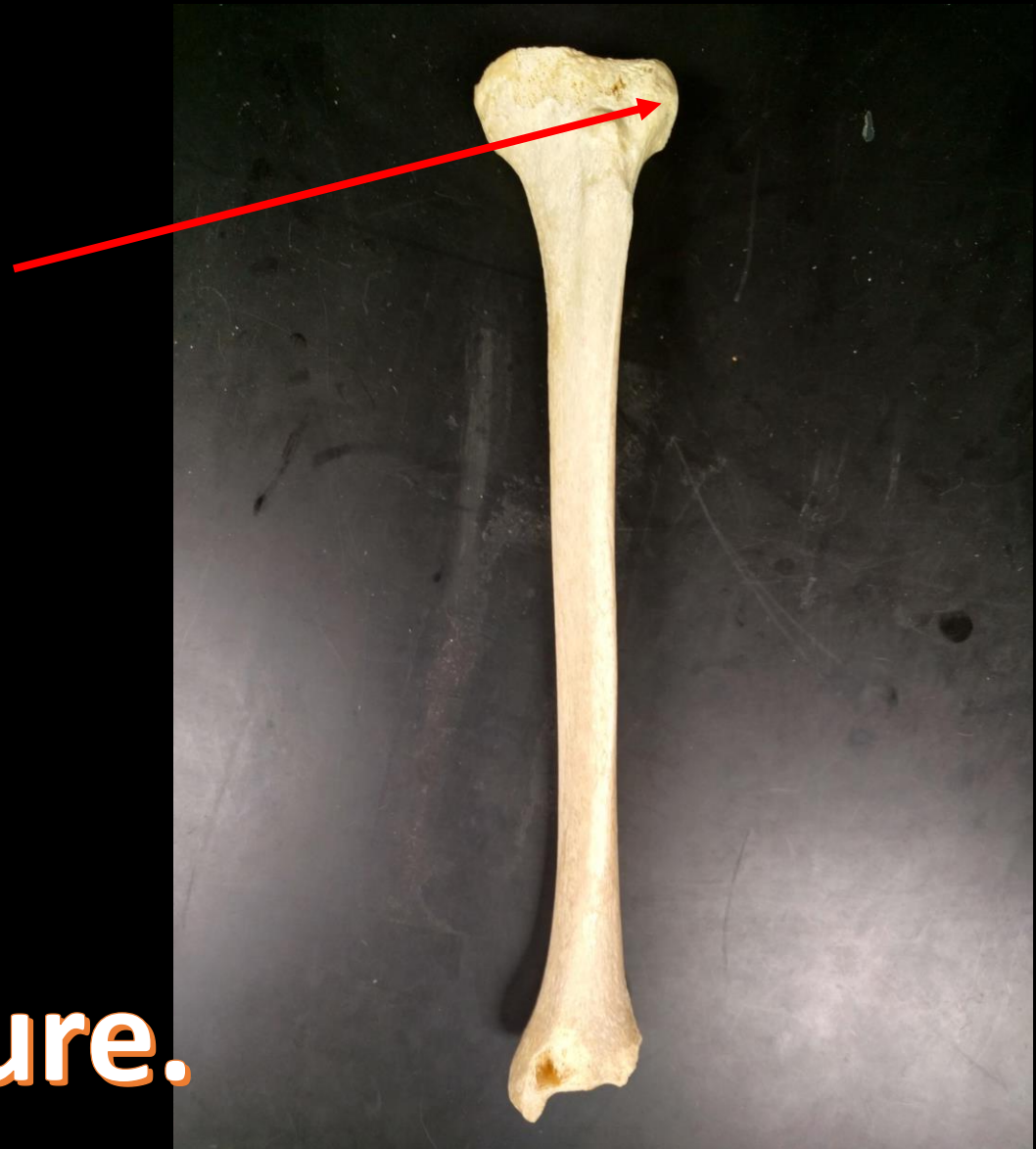




**Bone = Tibia**

**Lateral  
Condyle**

**Identify the Bone.  
Identify the Structure.**



**Can You Identify This Bone?**



**Can You Identify This Bone?**



**This is the Fibula.**

**What is the Bone?**

**What is the Structure?**



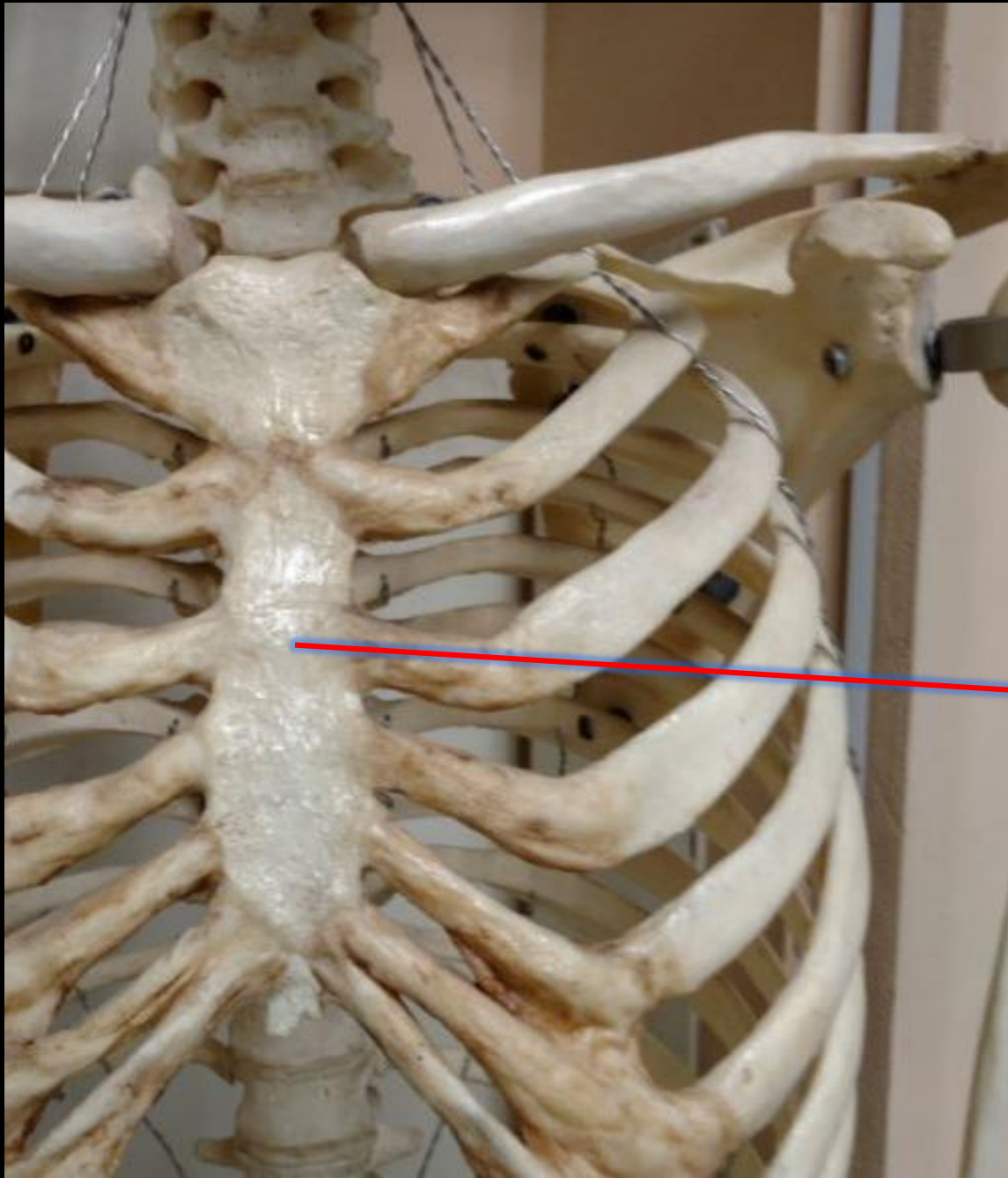
**What is the Bone?**

**What is the Structure?**

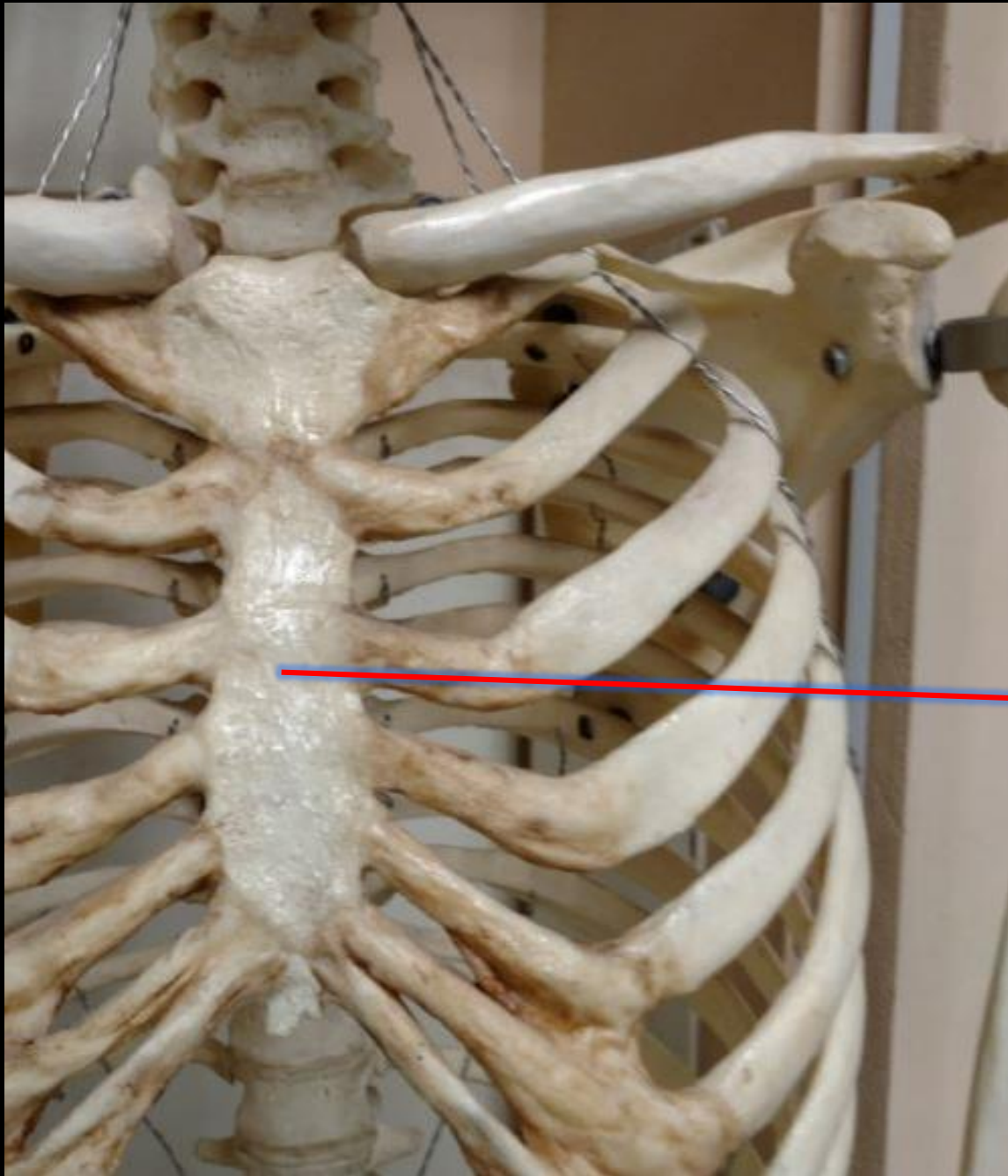
**The Humerus**



**The Greater Tubercle**



What is the Bone?  
What is the Structure?



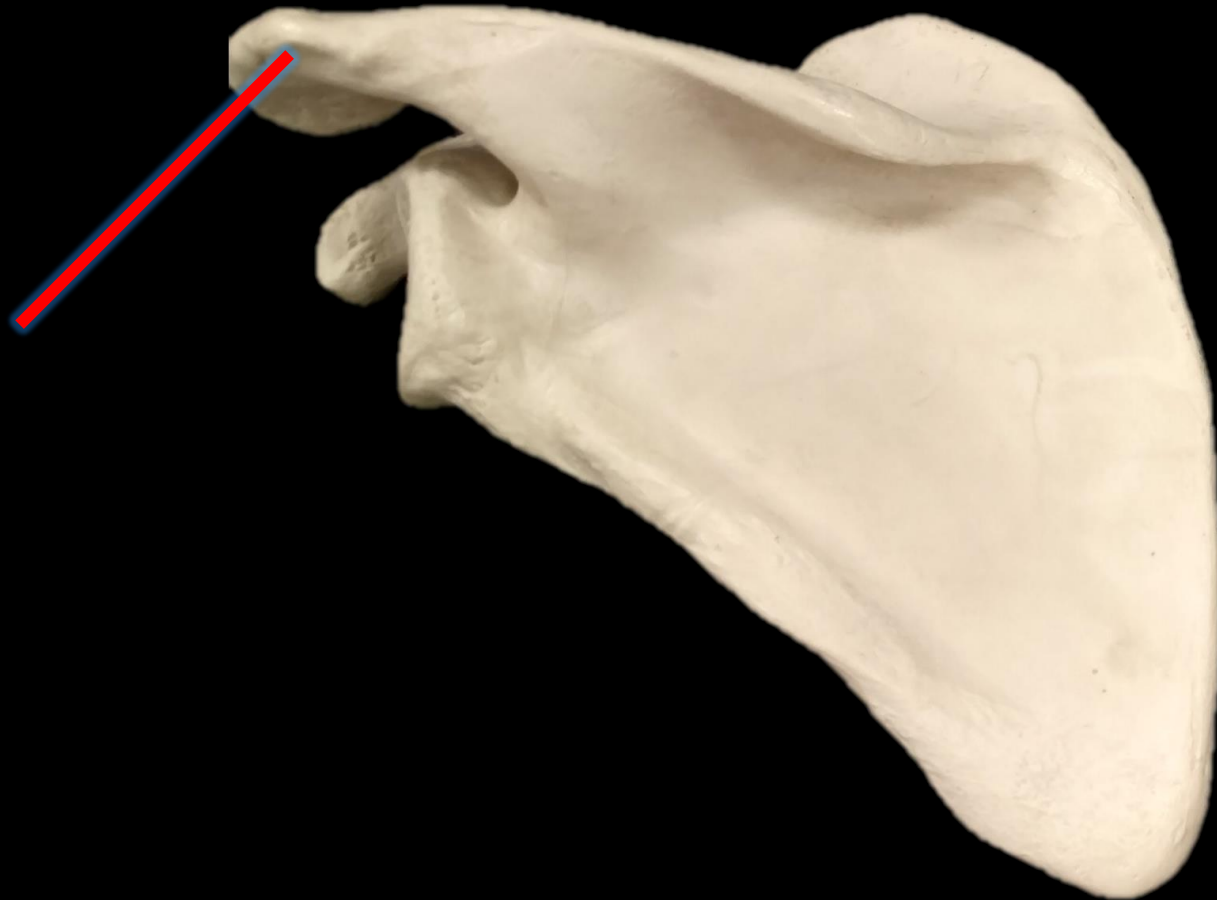
What is the Bone?  
What is the Structure?

**The Bone is the Sternum**

**This is the Body of the Sternum**

*What is the Bone?*

*What is the Structure?*

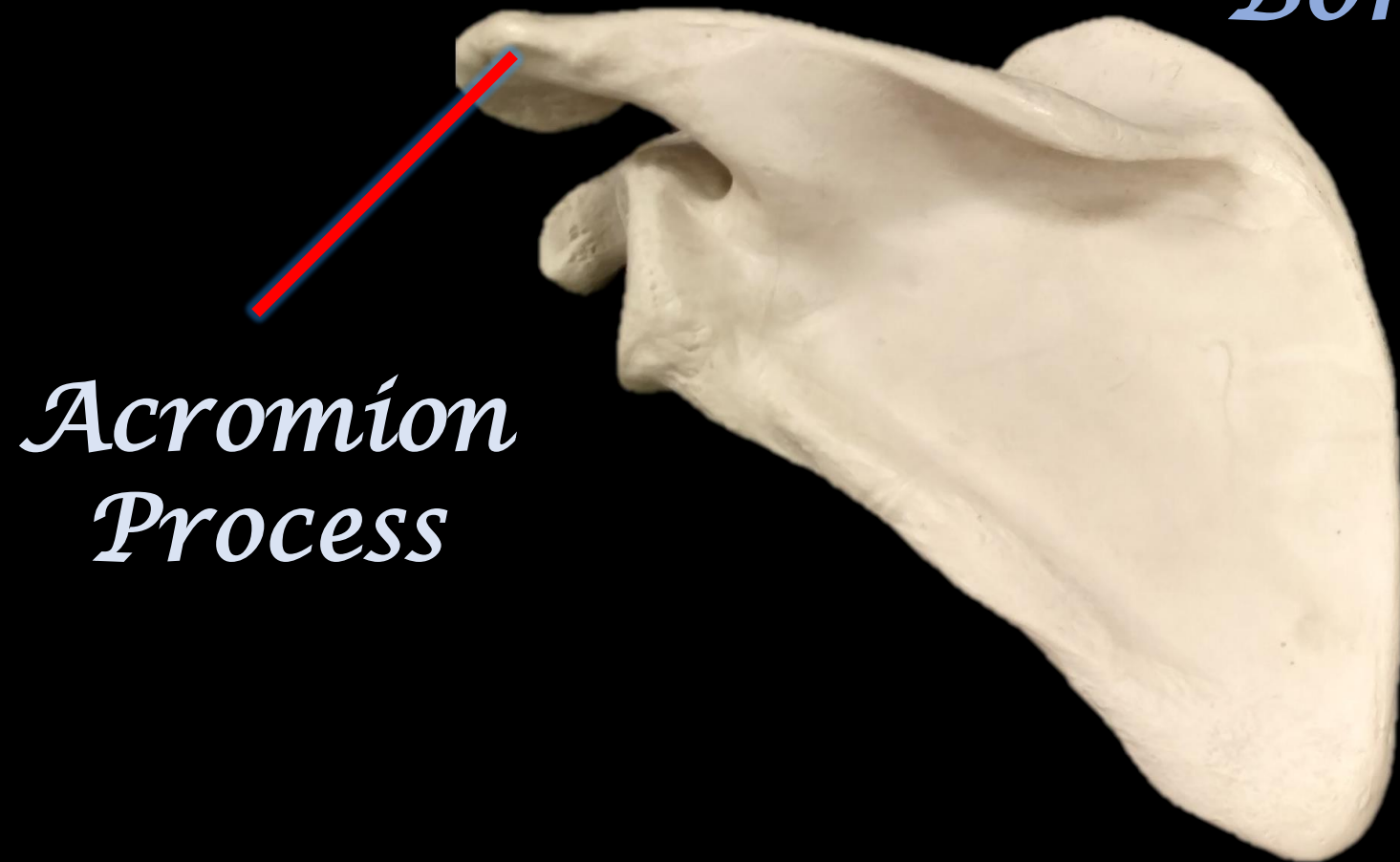



*What is the Bone?*

*What is the Structure?*

*Bone = Scapula*



*Acromion  
Process*

**What is the Bone?**

**What is the Structure?**



**What is the Bone?**

**What is the Structure?**

**The Humerus**



**Olecranon Fossa**

**What is the Bone?**



**What is the Structure?**

**What is the Bone?**

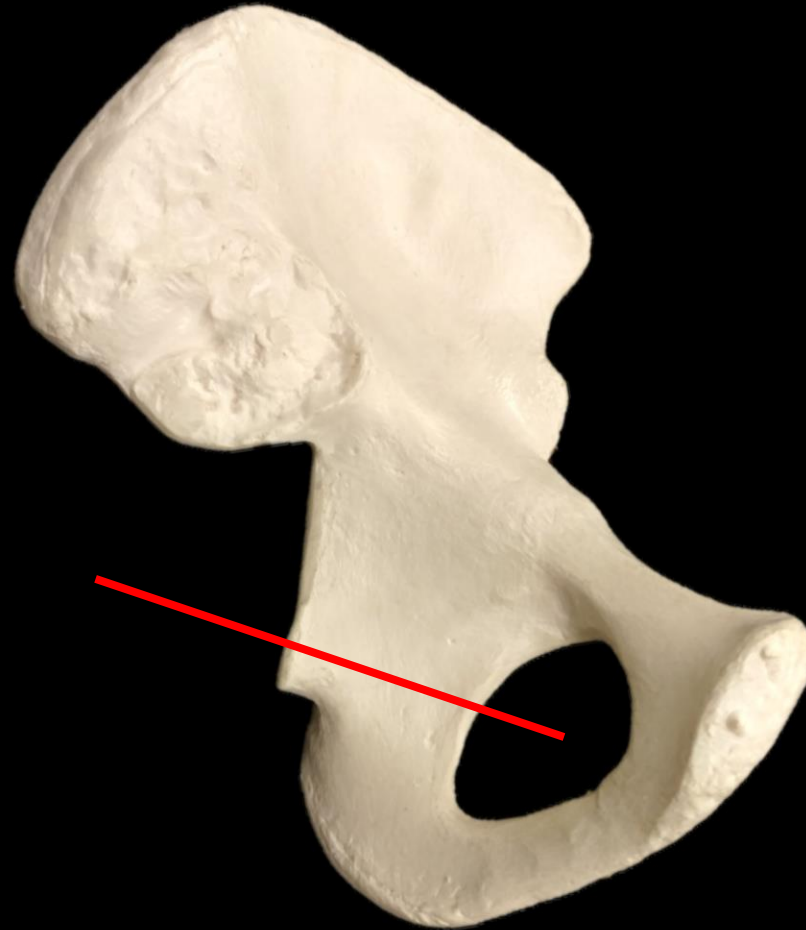
**Radius**



**What is the Structure?**

**Radial Tuberosity**

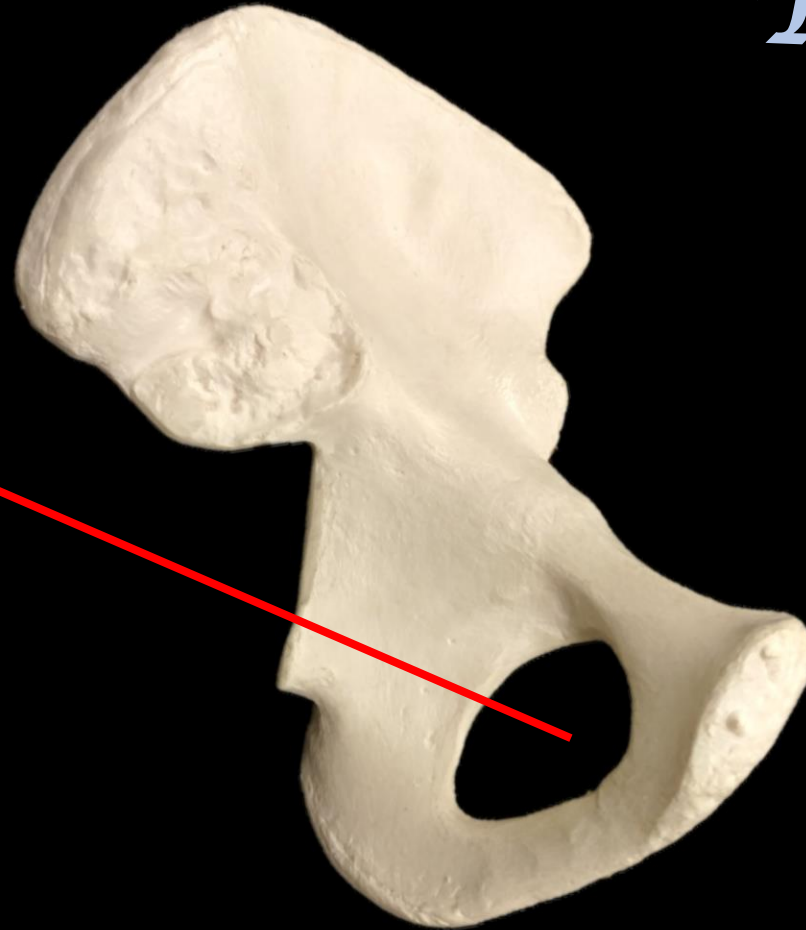
# *What is the Bone? What is the Structure?*



*What is the Bone? What is the Structure?*

*The Coxal  
Bone*

*Obturator  
foramen*



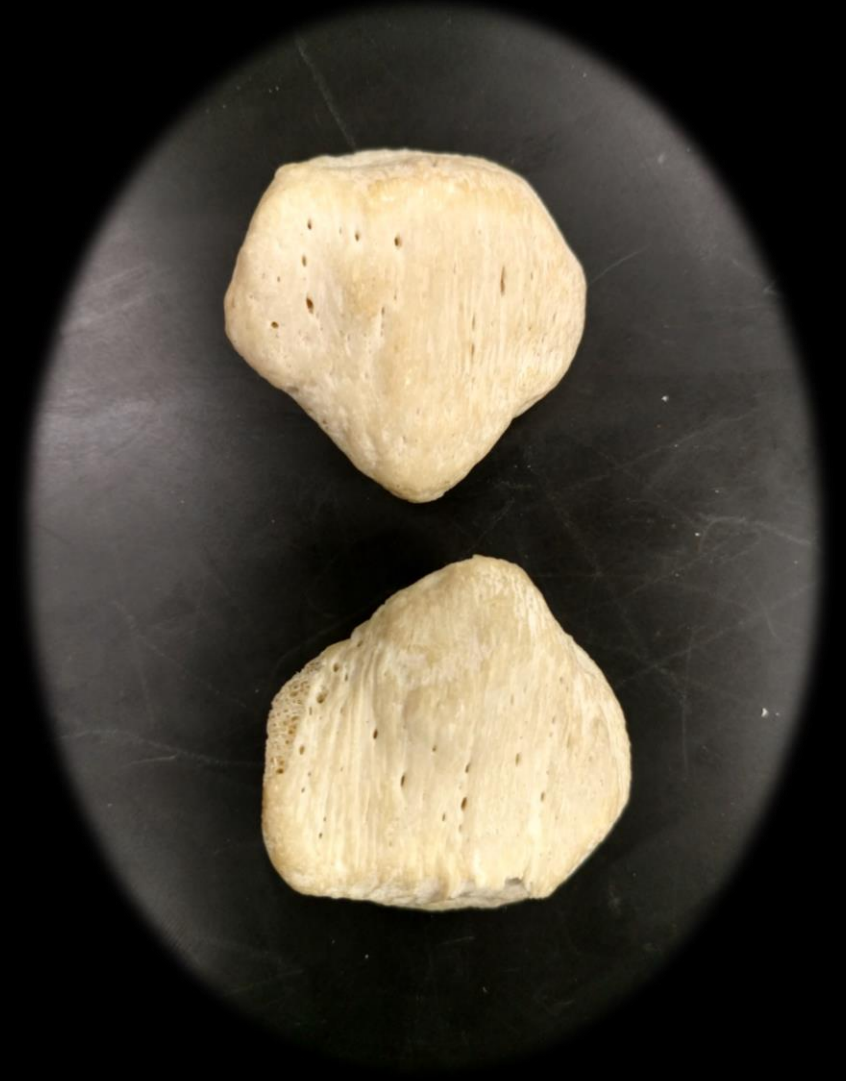**What is the Bone?**





**What is the Bone?**

**The Patella**



**What is the Bone?**



**What is the Structure?**

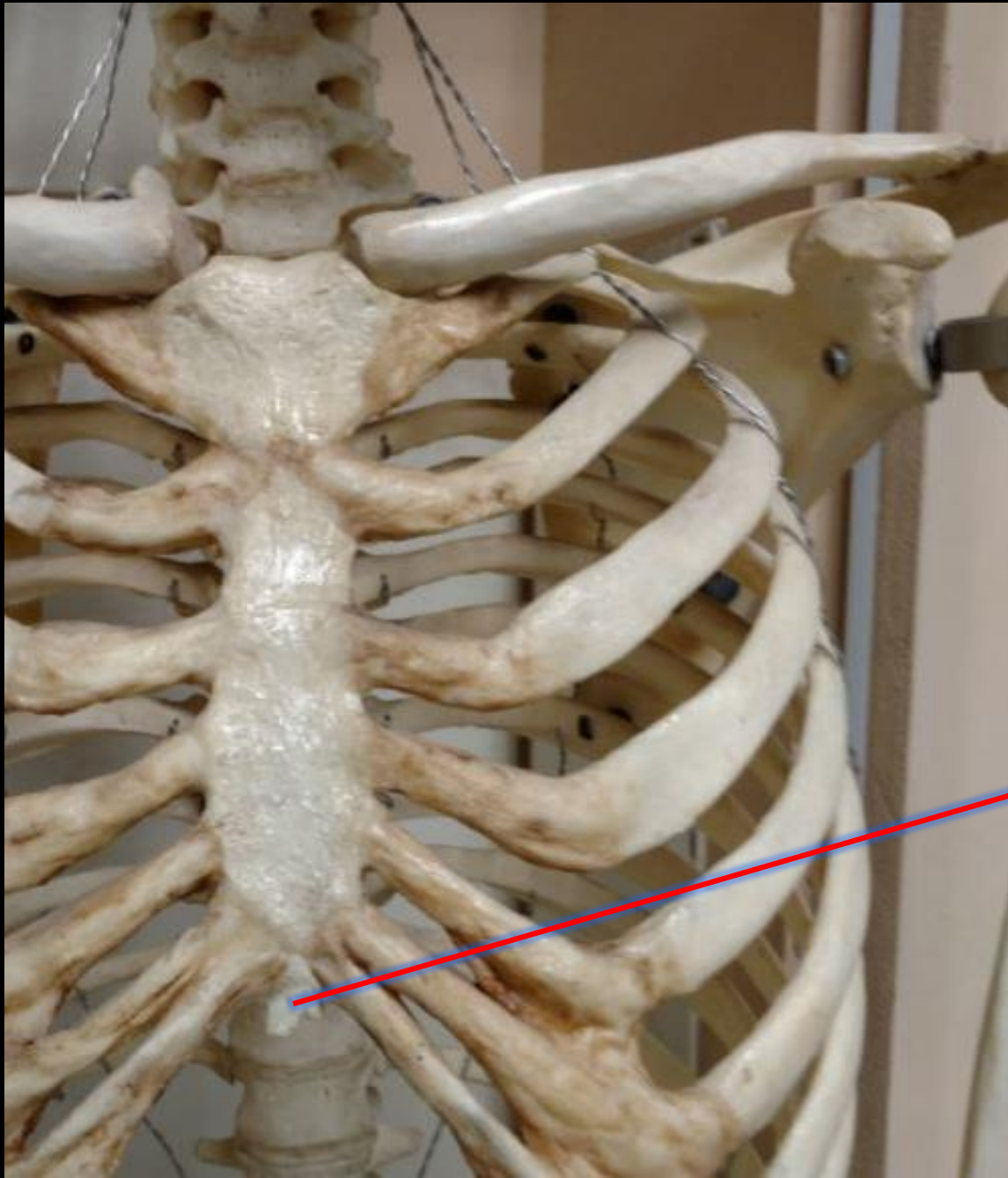
**What is the Bone?**

**The Tibia**



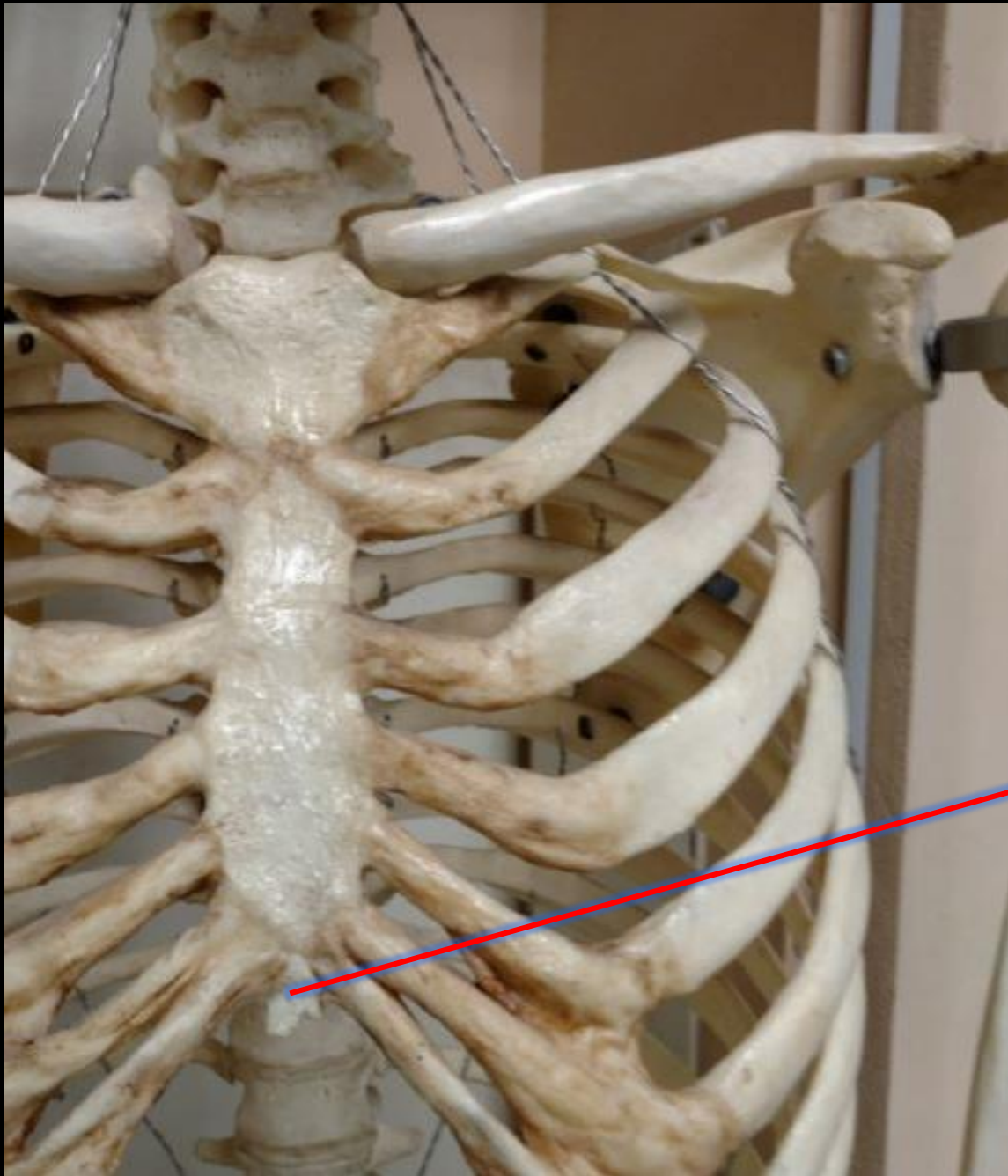
**What is the Structure?**

**The Medial Malleolus**



What is the Bone?

What is the Structure?



What is the Bone?  
What is the Structure?

**The Bone is the Sternum**

**This is the Xiphoid of the Sternum**

**What is the Bone?**



**What is the Structure?**

**What is the Bone?**

**The Tibia**

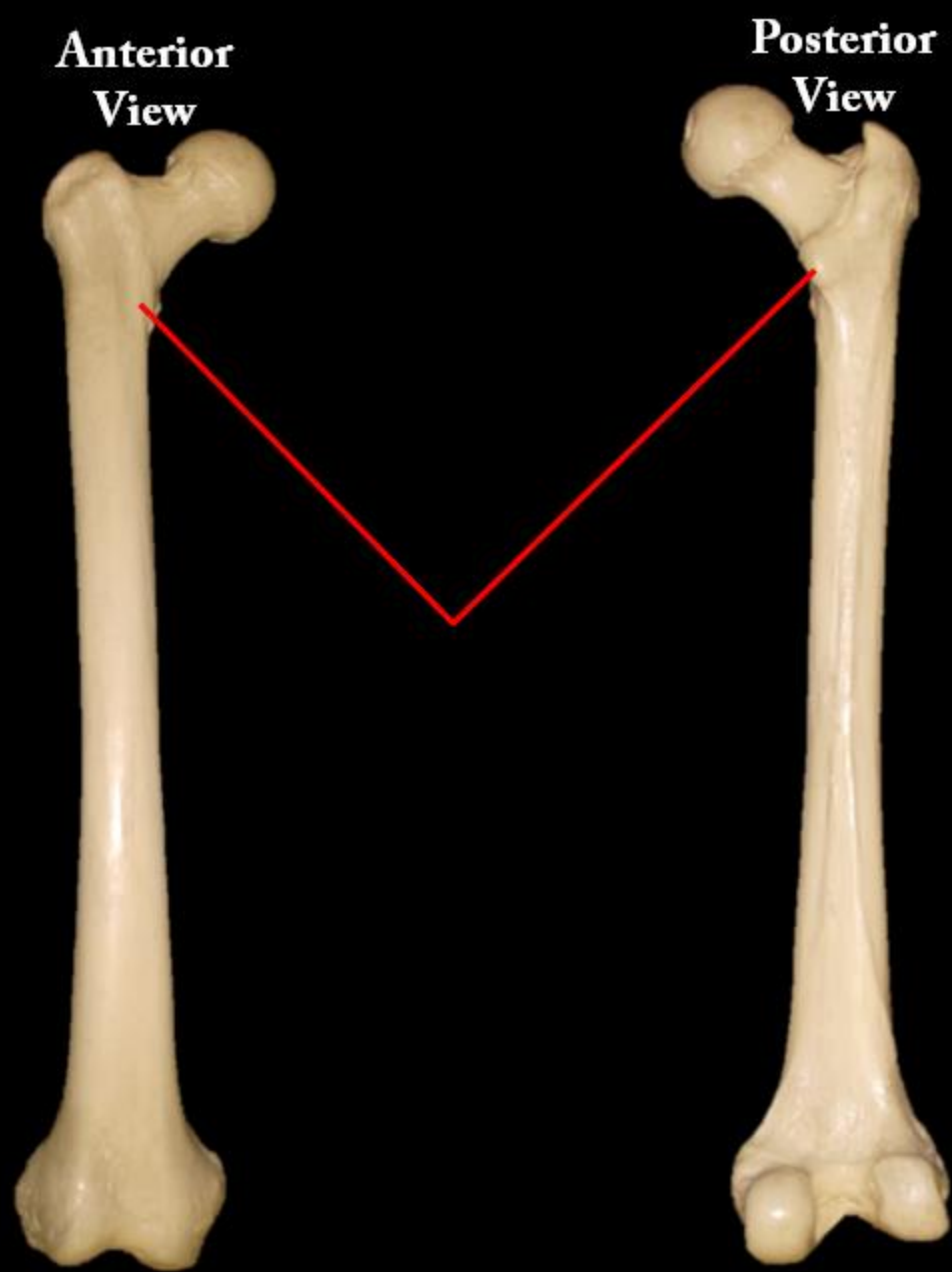


**What is the Structure?**

**Lateral Condyle**

Name the Bone

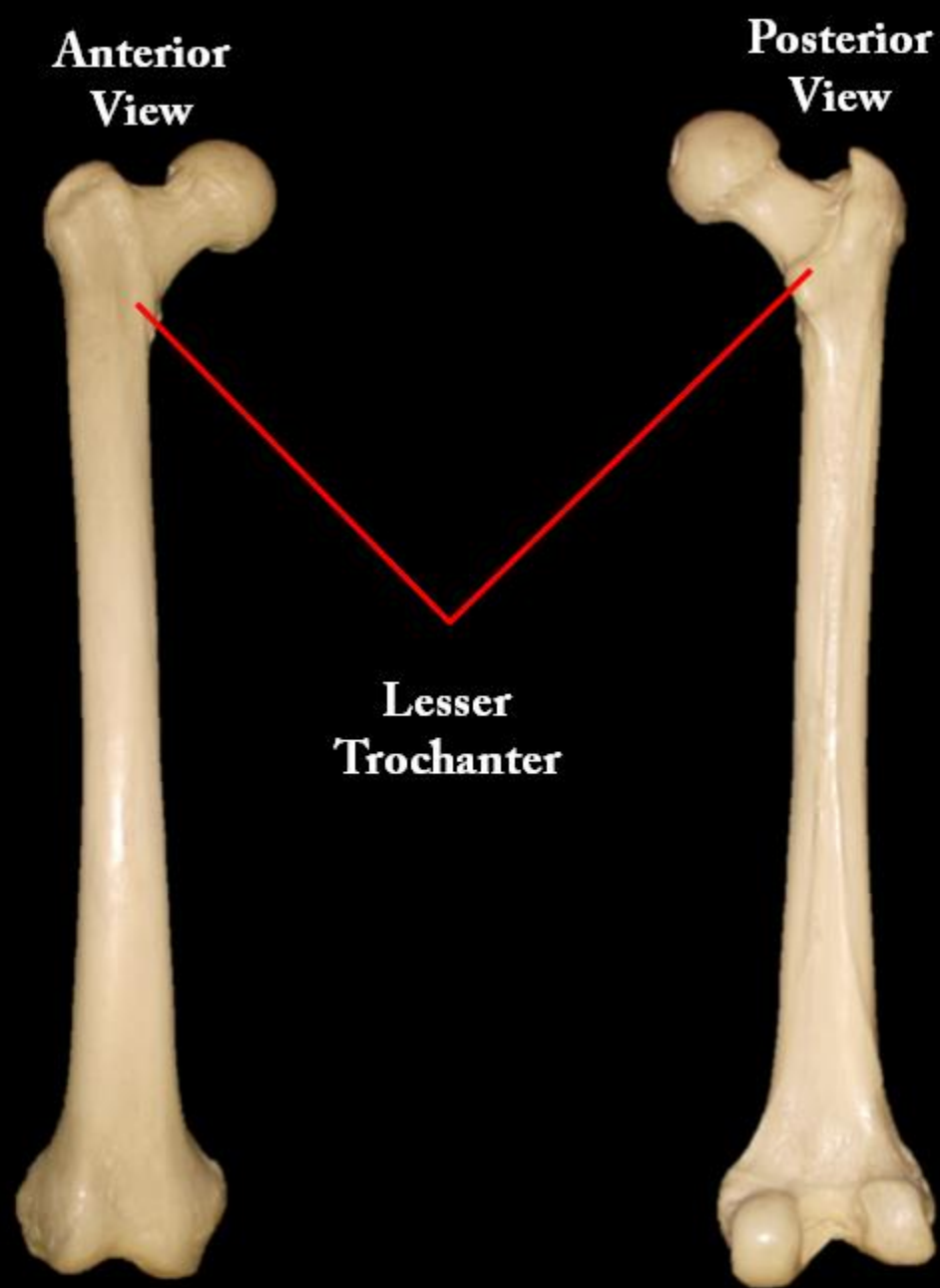
Name the Structure

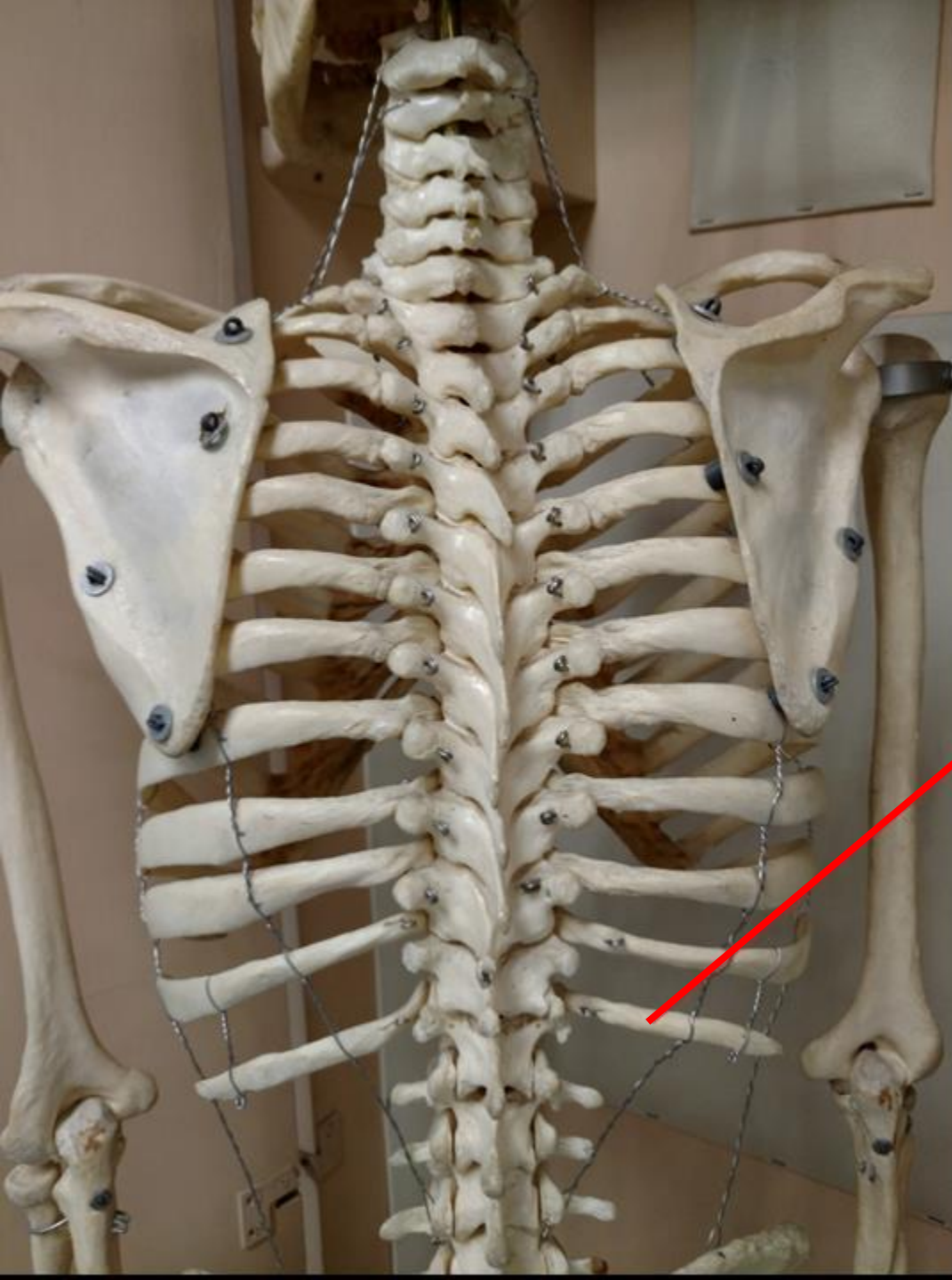




Name the Bone  
= Femur

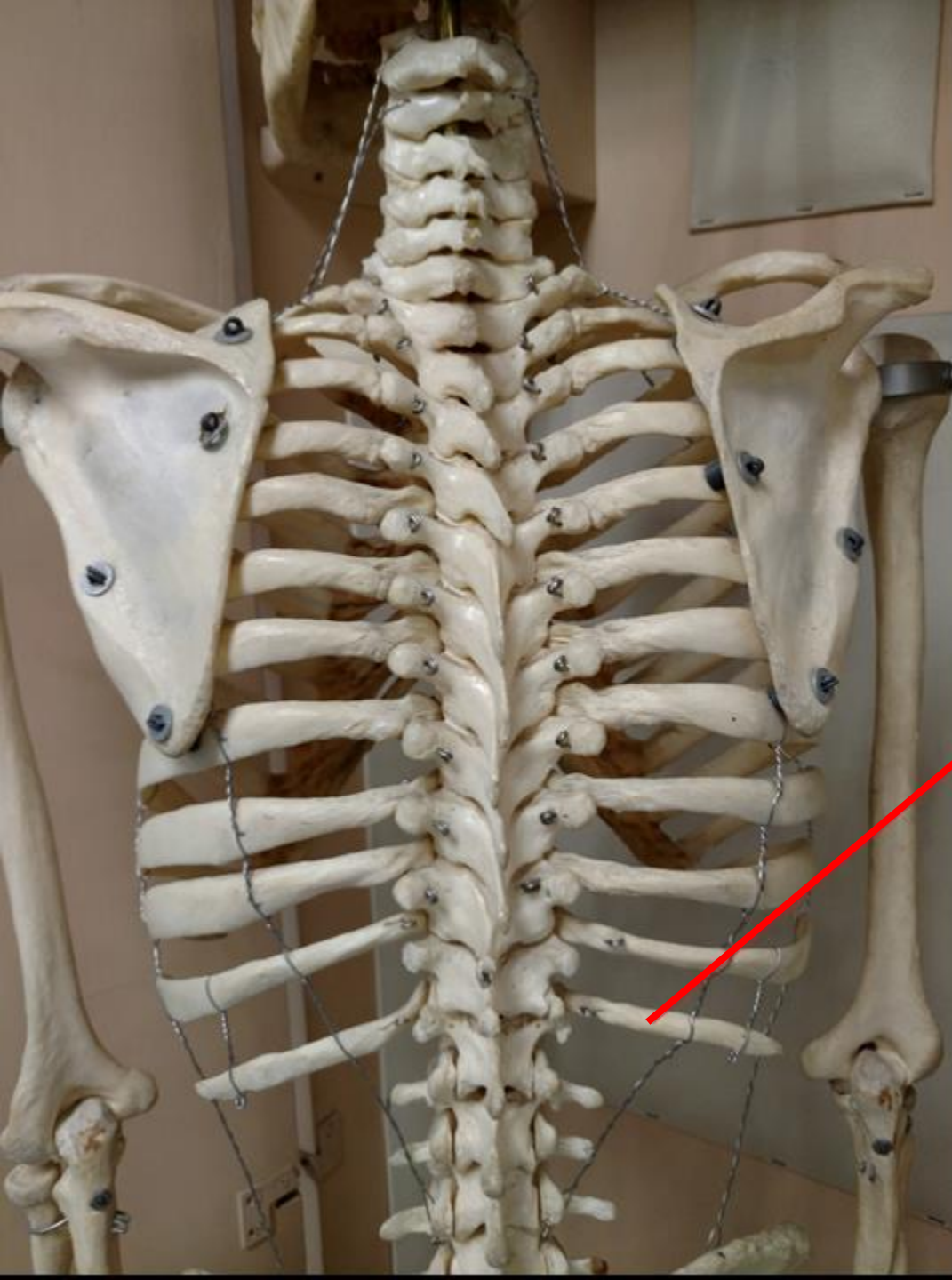
Name the Structure  
= Lesser Trochanter





Name the Bone =

WHAT TYPE IS IT?



Name the Bone =  
RIB

WHAT TYPE IS IT?  
FLOATING RIB

**What is the Bone?**

**What is the Structure?**



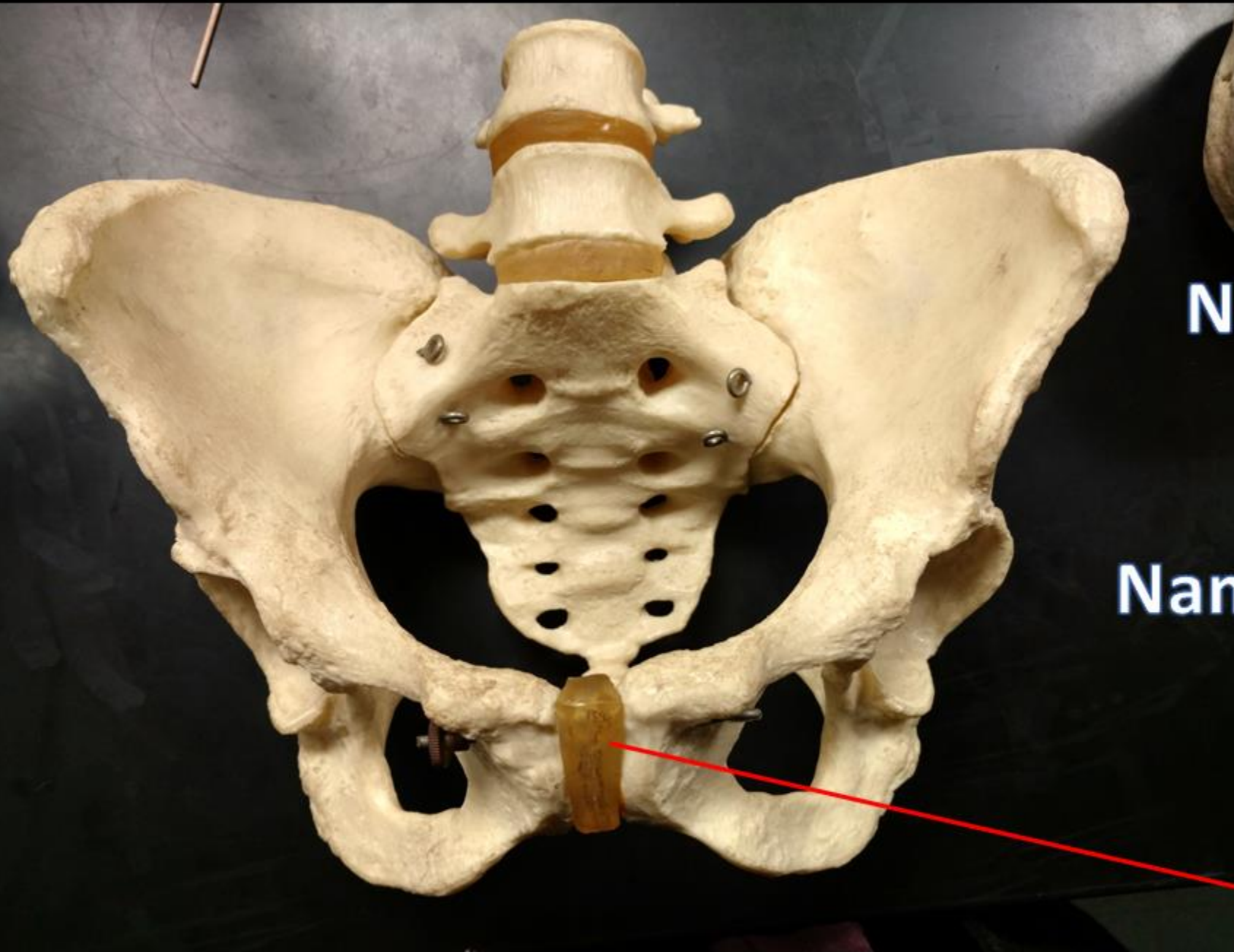
**What is the Bone?**

**What is the Structure?**

**The Humerus**

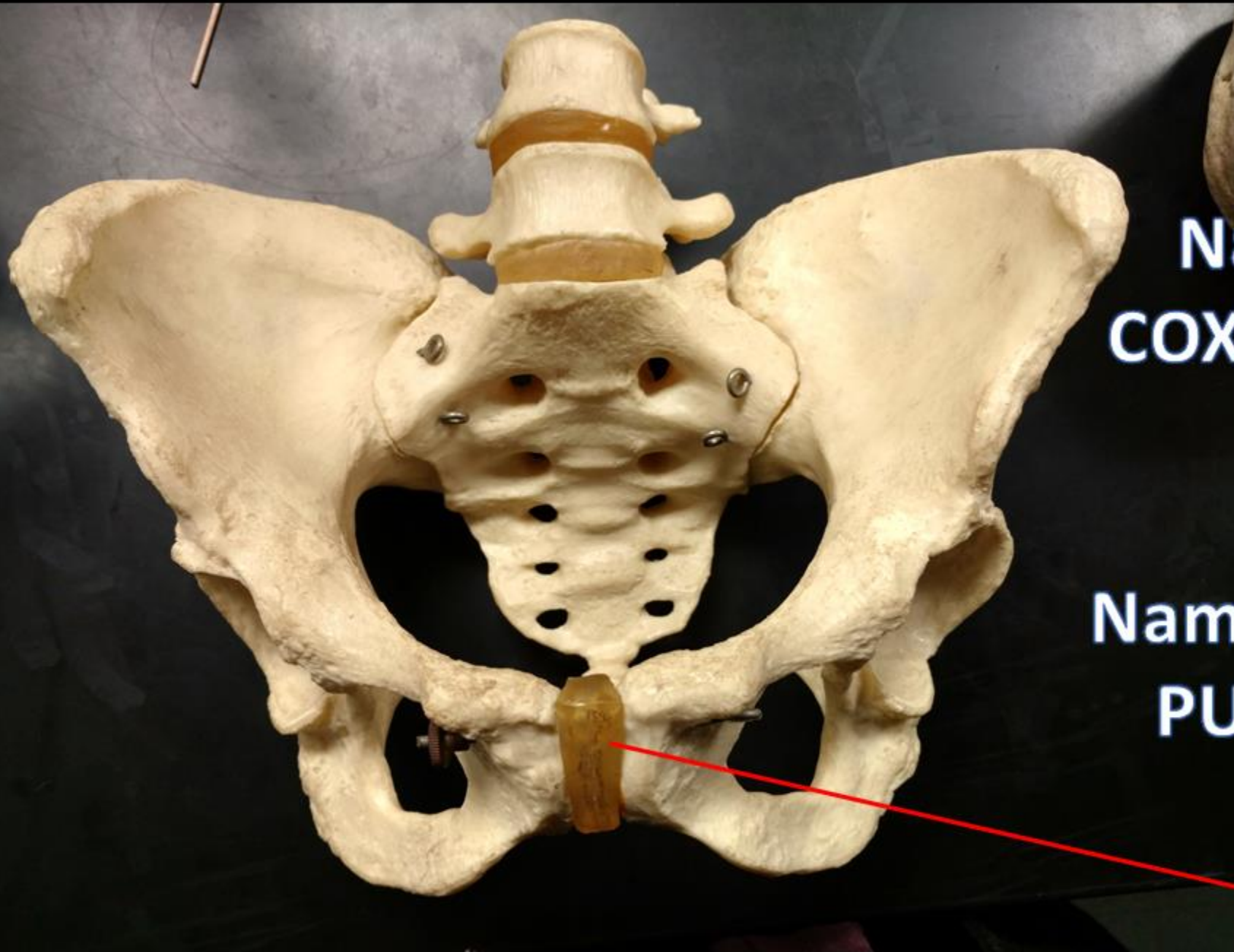


**Trochlea**



**Name the bone.**

**Name the Structure.**



**Name the bone.  
COXAL / OS COXAE /  
HIP/ PELVIC**

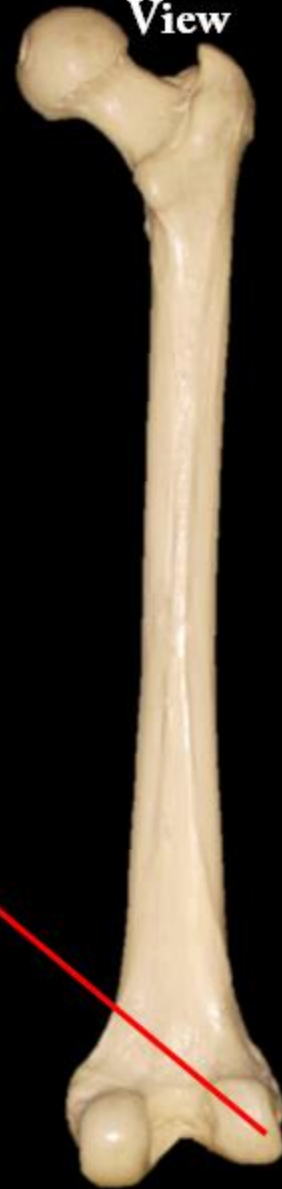
**Name the Structure =  
PUBIC SYMPHYSIS**

**Anterior  
View**

**Posterior  
View**

Name the Bone

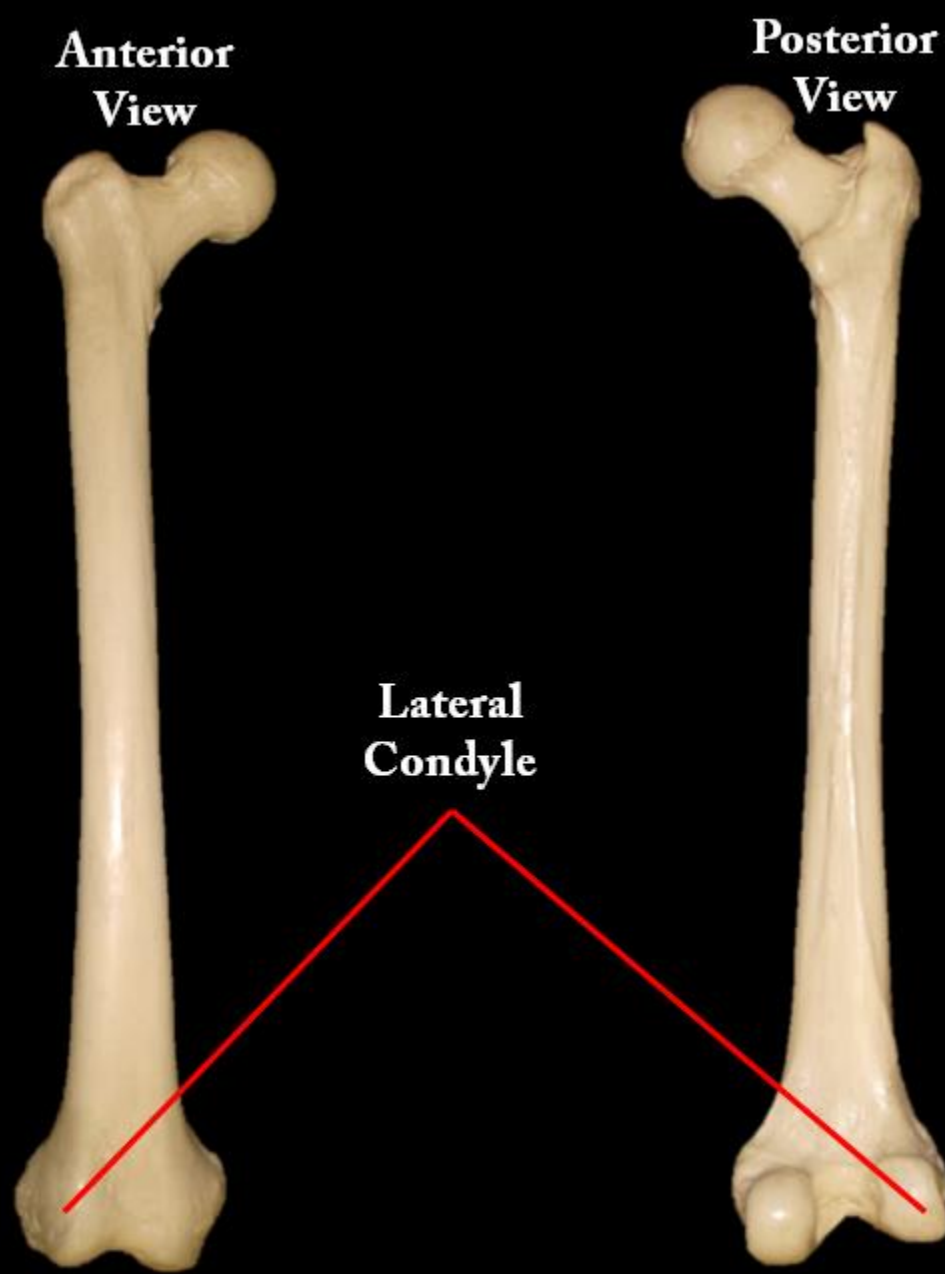
Name the Structure

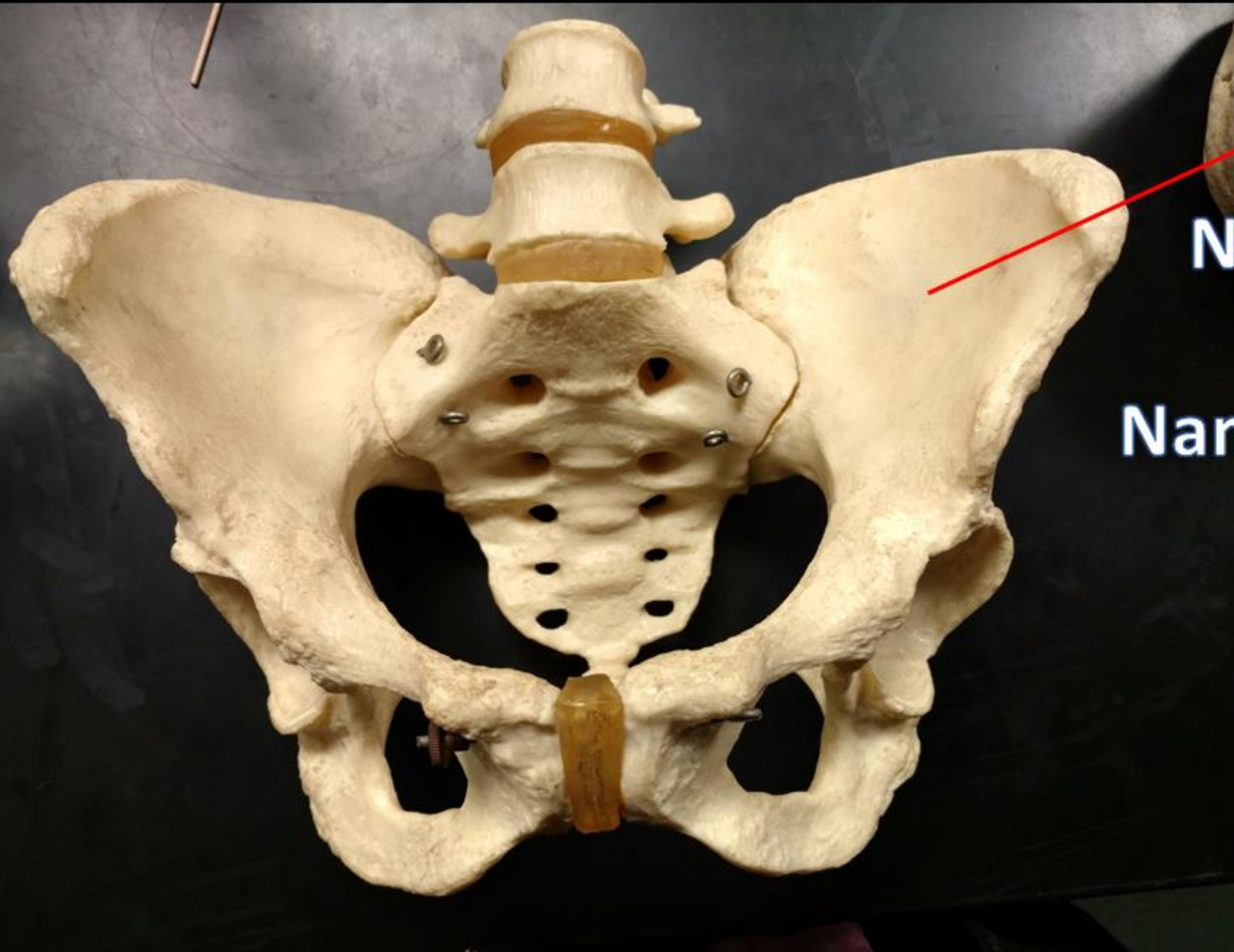




Name the Bone  
= Femur

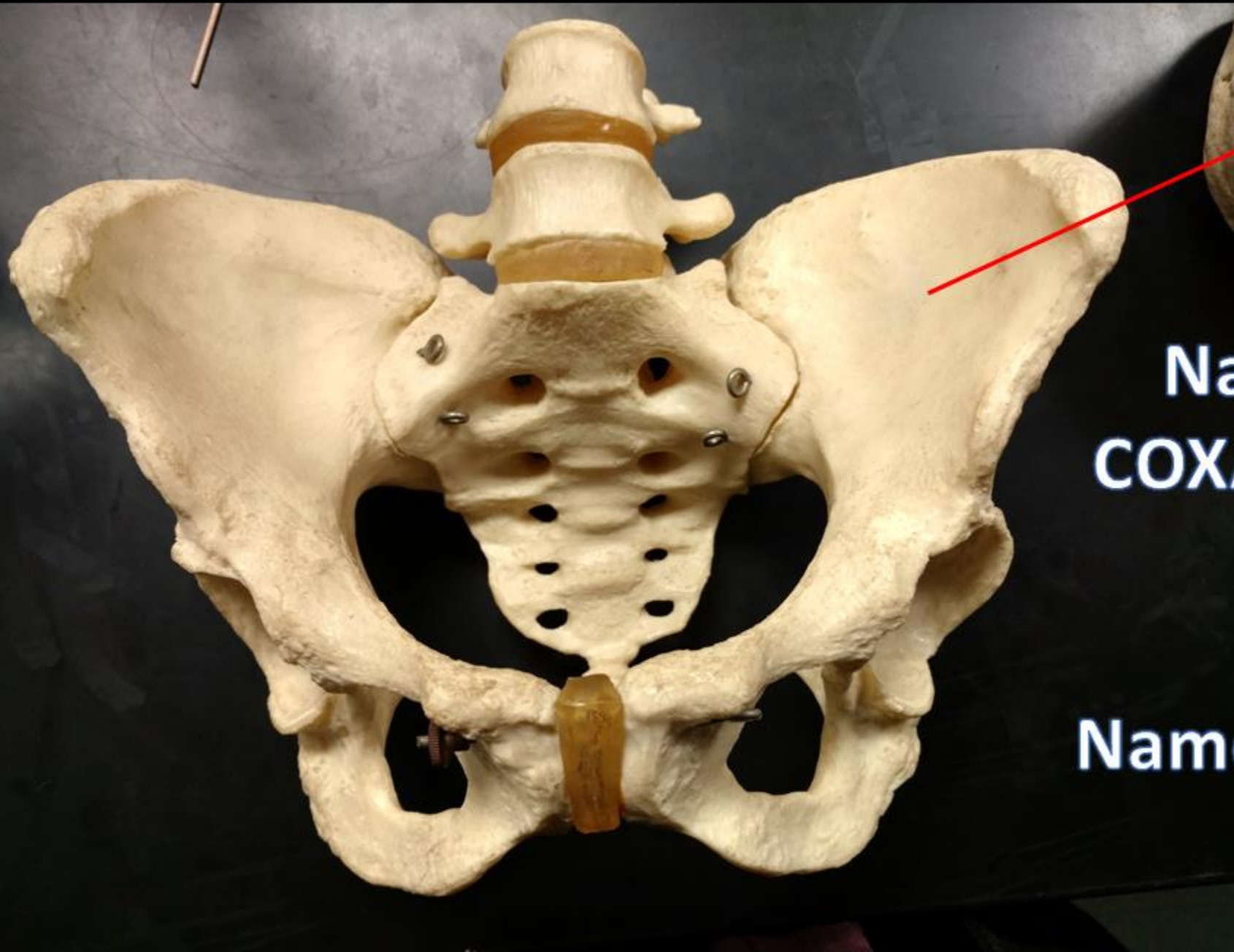
Name the Structure  
= Lateral Condyle





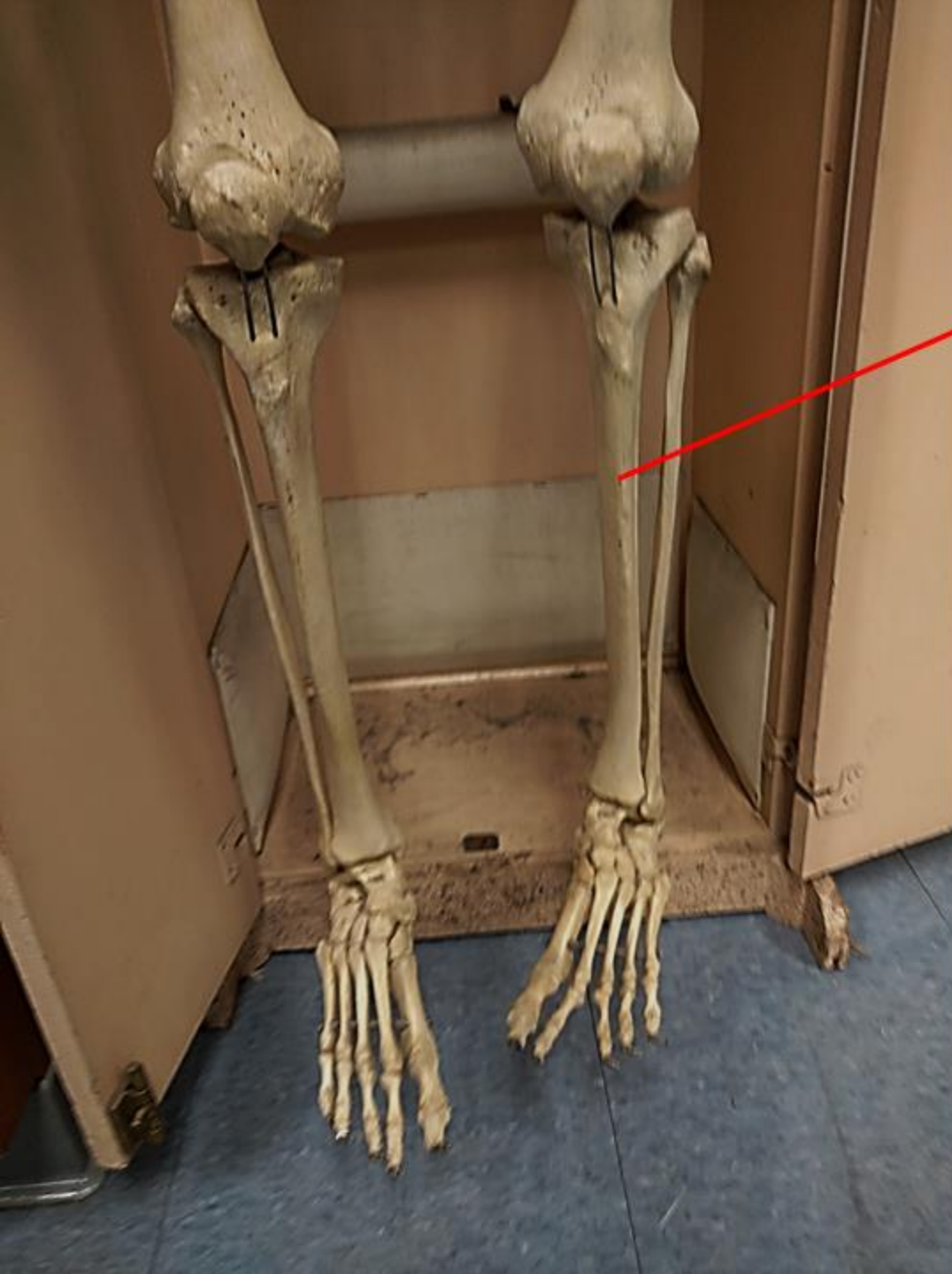
**Name the bone**

**Name the Structure**




**Name the bone.  
COXAL / OS COXAE /  
HIP/ PELVIC**

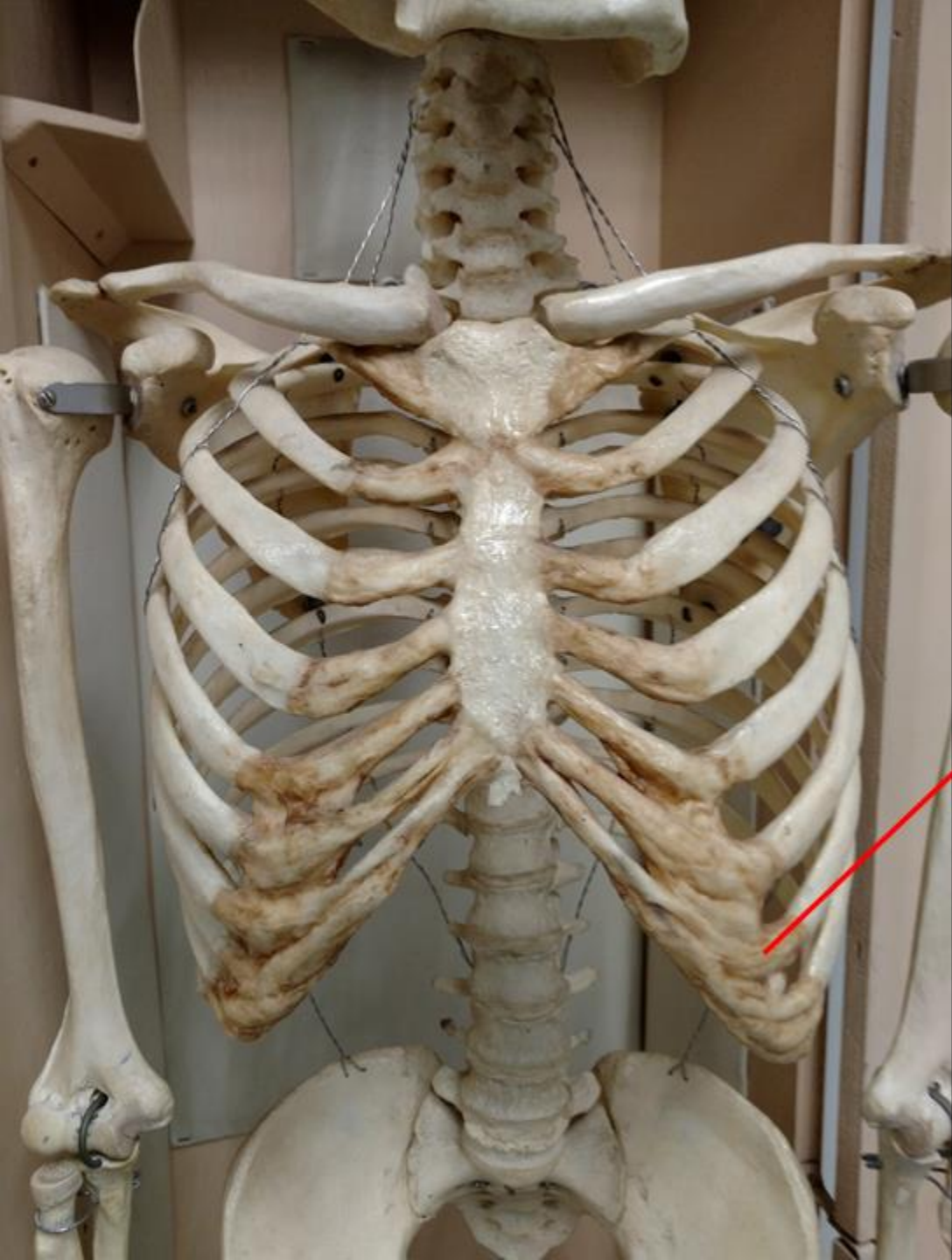**Name the Structure =  
ILIUM**



Name the Bone



Name the Bone = Tibia



Name the Bone.

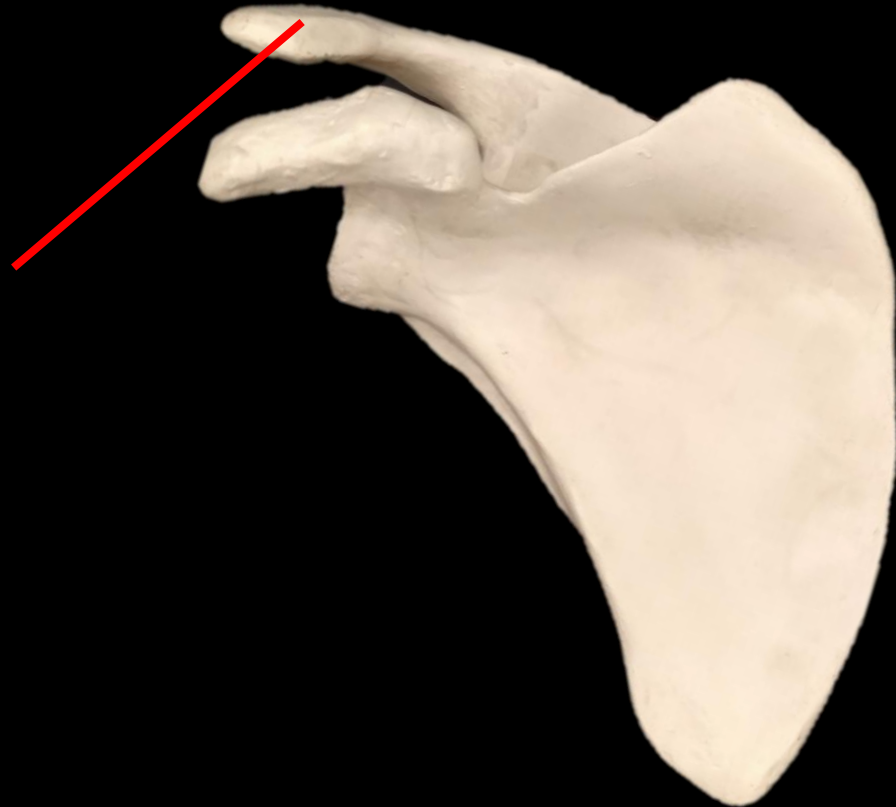
What TYPE is it?



Name the Bone.  
RIB

What TYPE is it?  
FALSE RIB

*What is the Bone?*  
*What is the Structure?*

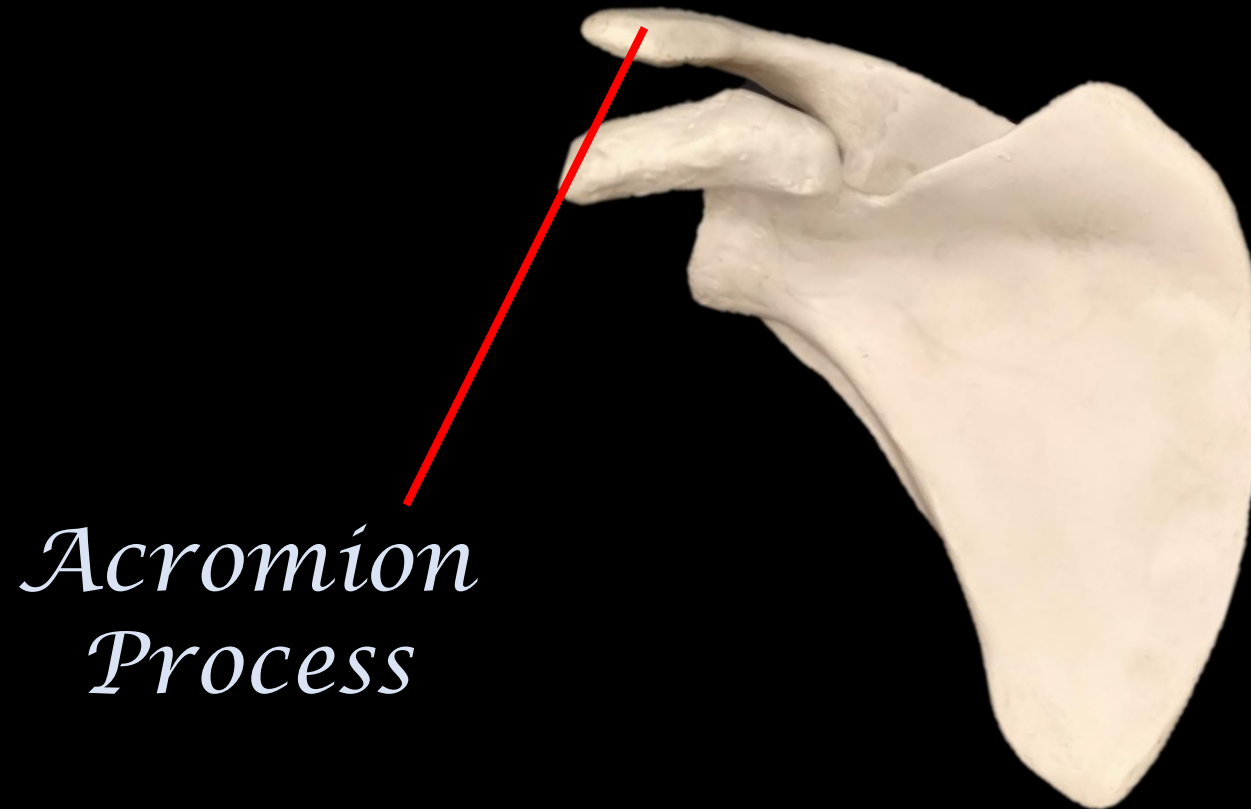




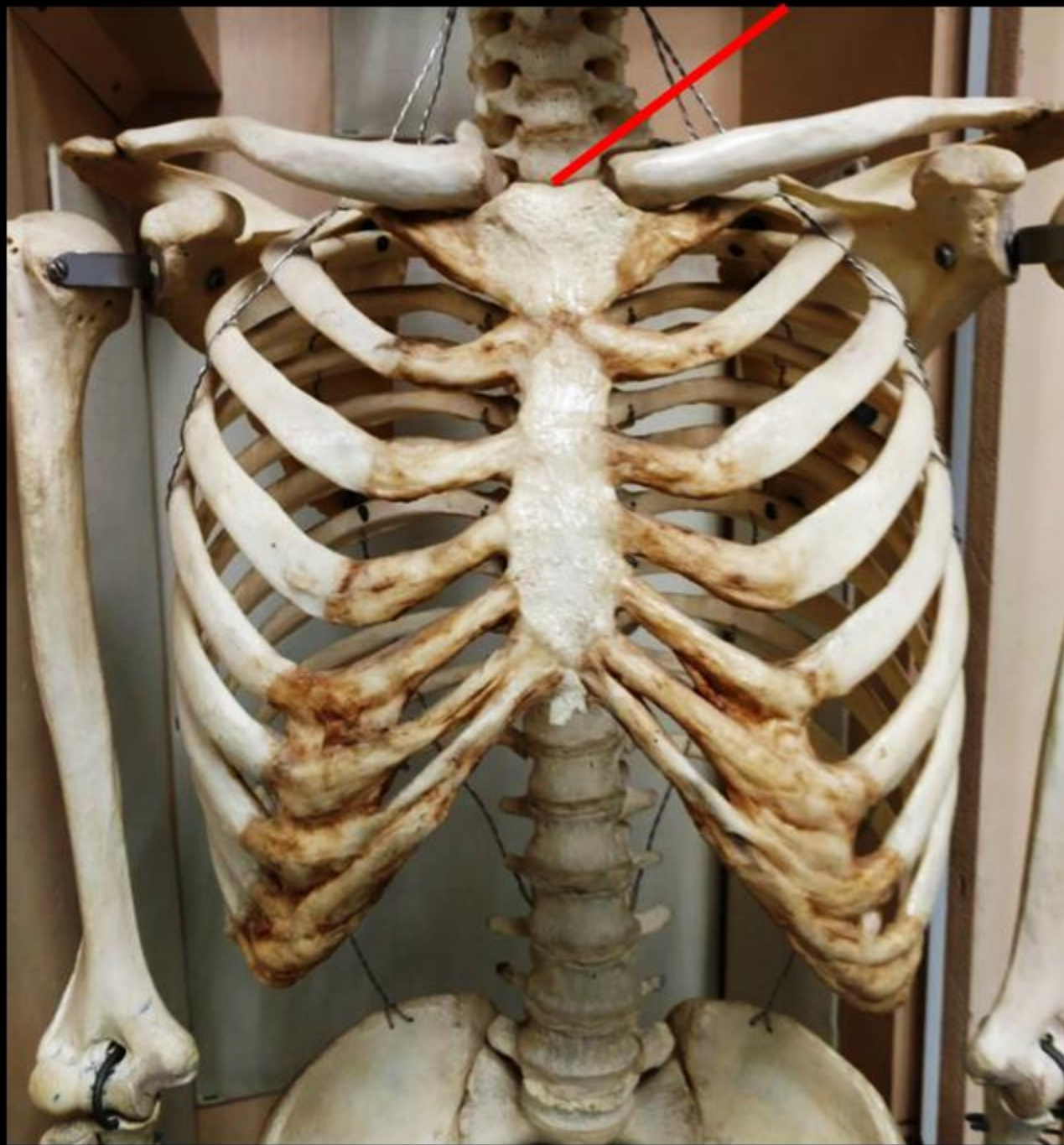
*What is the Bone?*

*What is the Structure?*

*This is the scapula.*

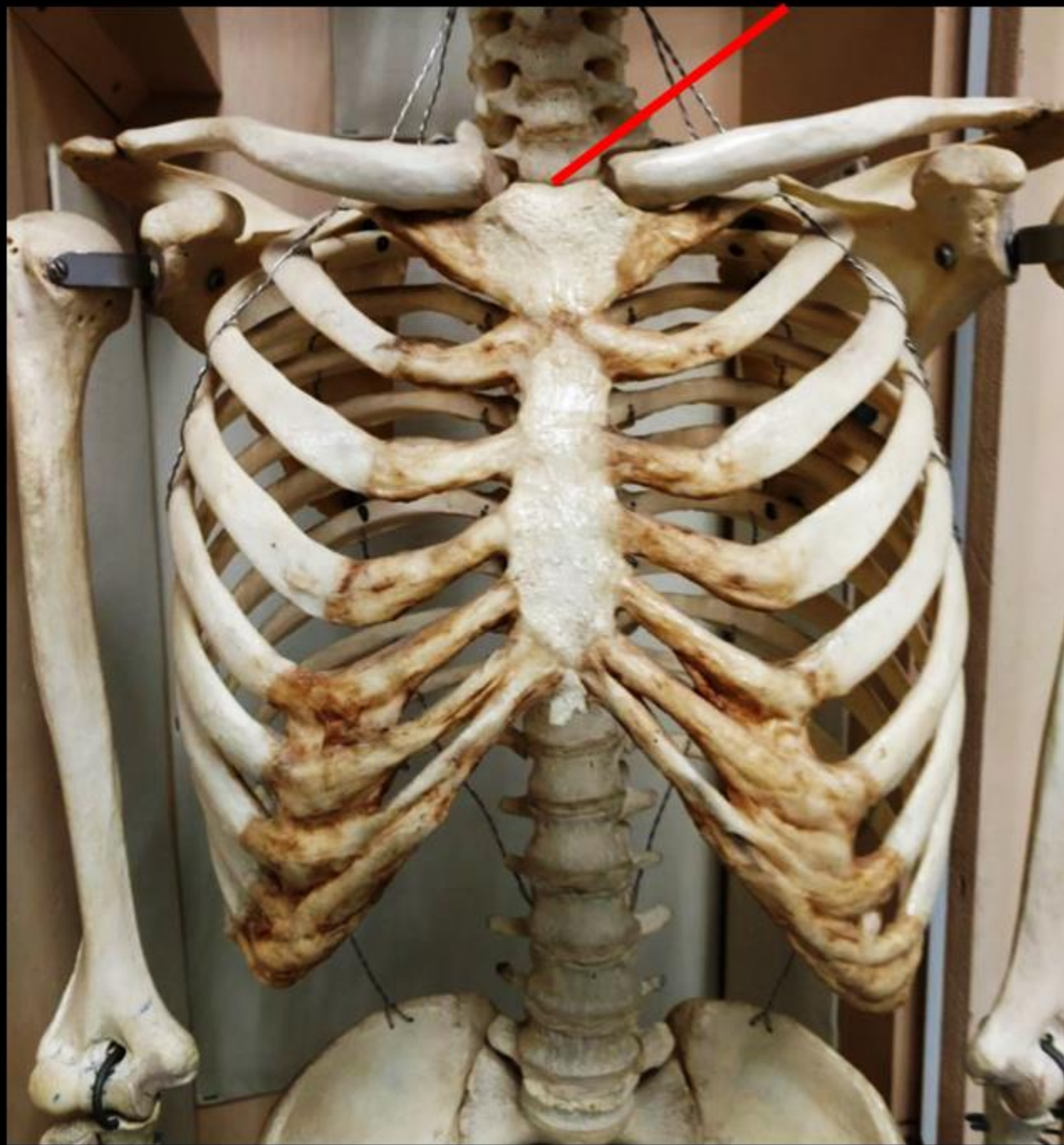


*Acromion  
Process*



**Name the Bone.**

**Name the Structure.**



**Name the Bone  
= STERNUM**

**Name the Structure  
= JUGULAR NOTCH**

*What is the Bone?*



*What is the Structure?*

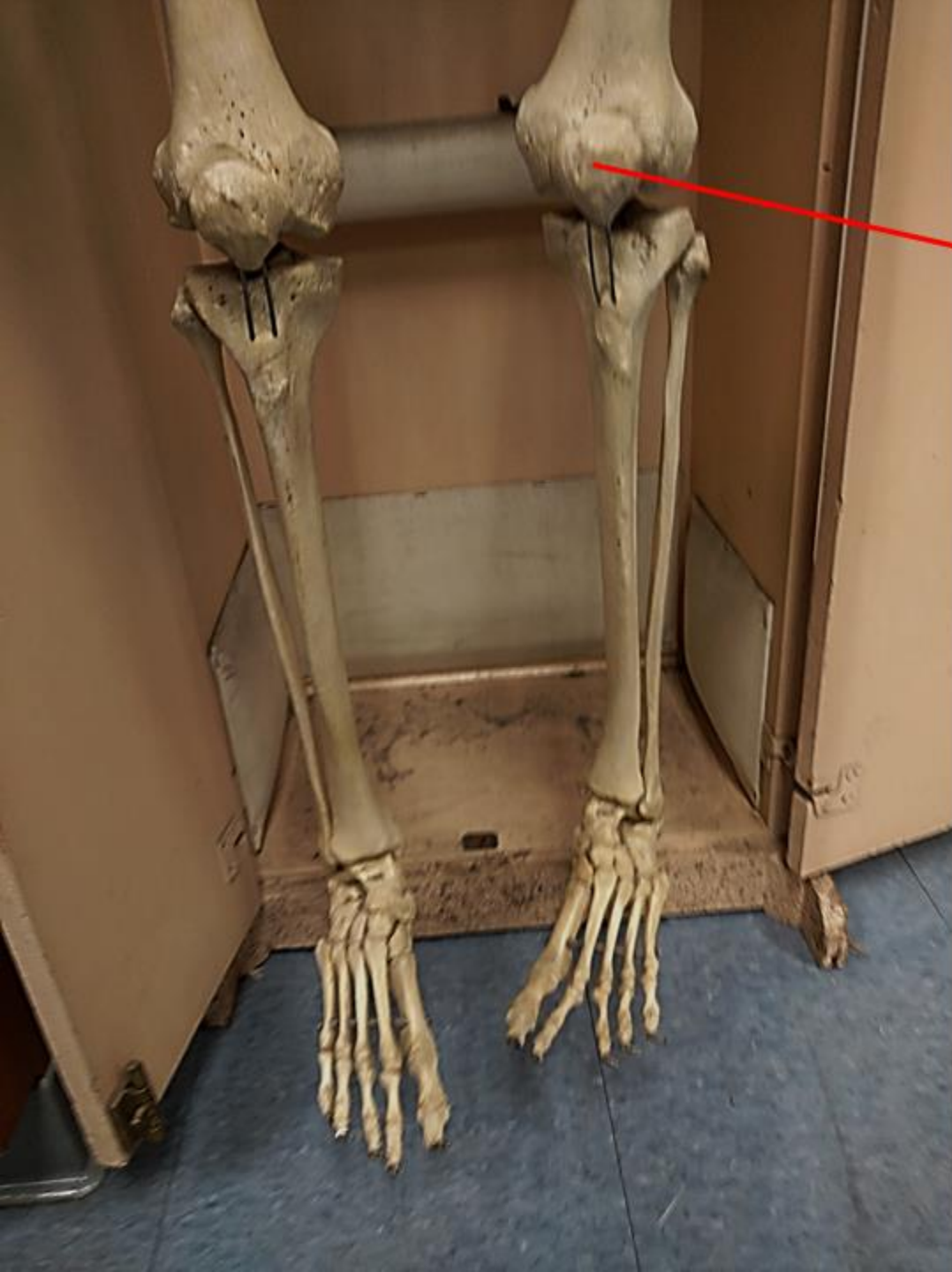
*What is the Bone?*

*Ulna*

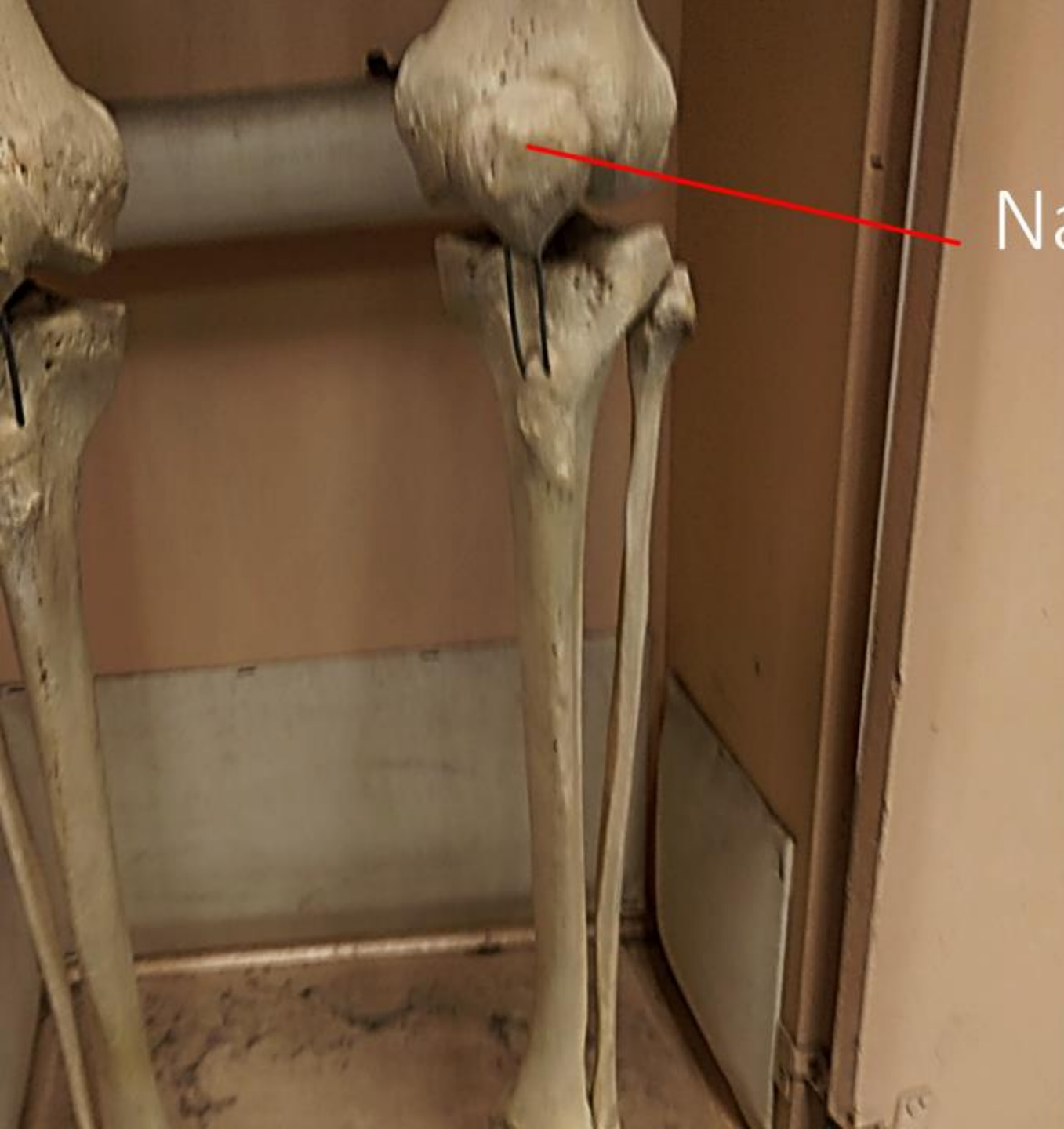


*What is the Structure?*

*The Trochlear Notch*



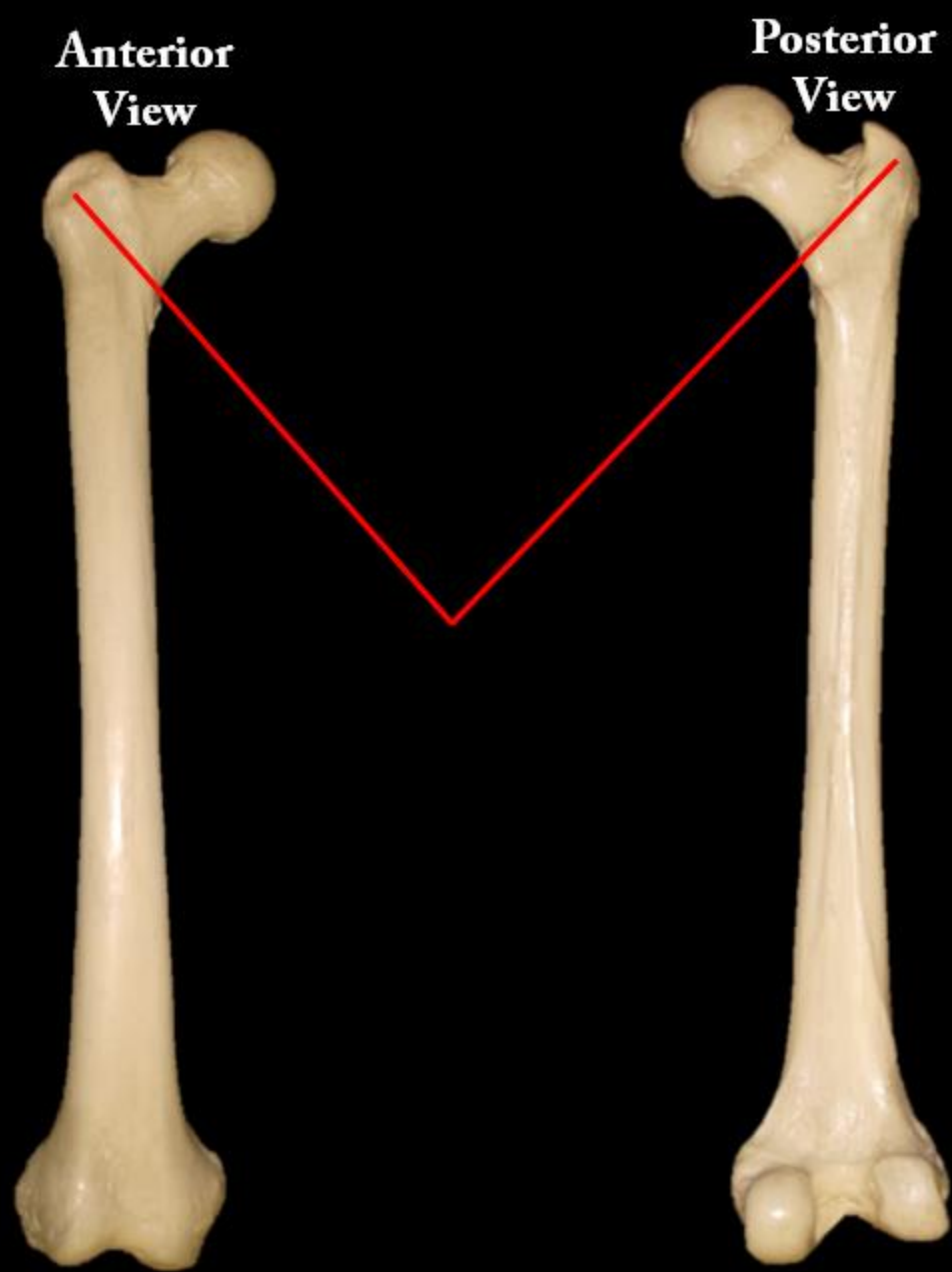
Name the Bone



Name the Bone = Patella

Name the Bone

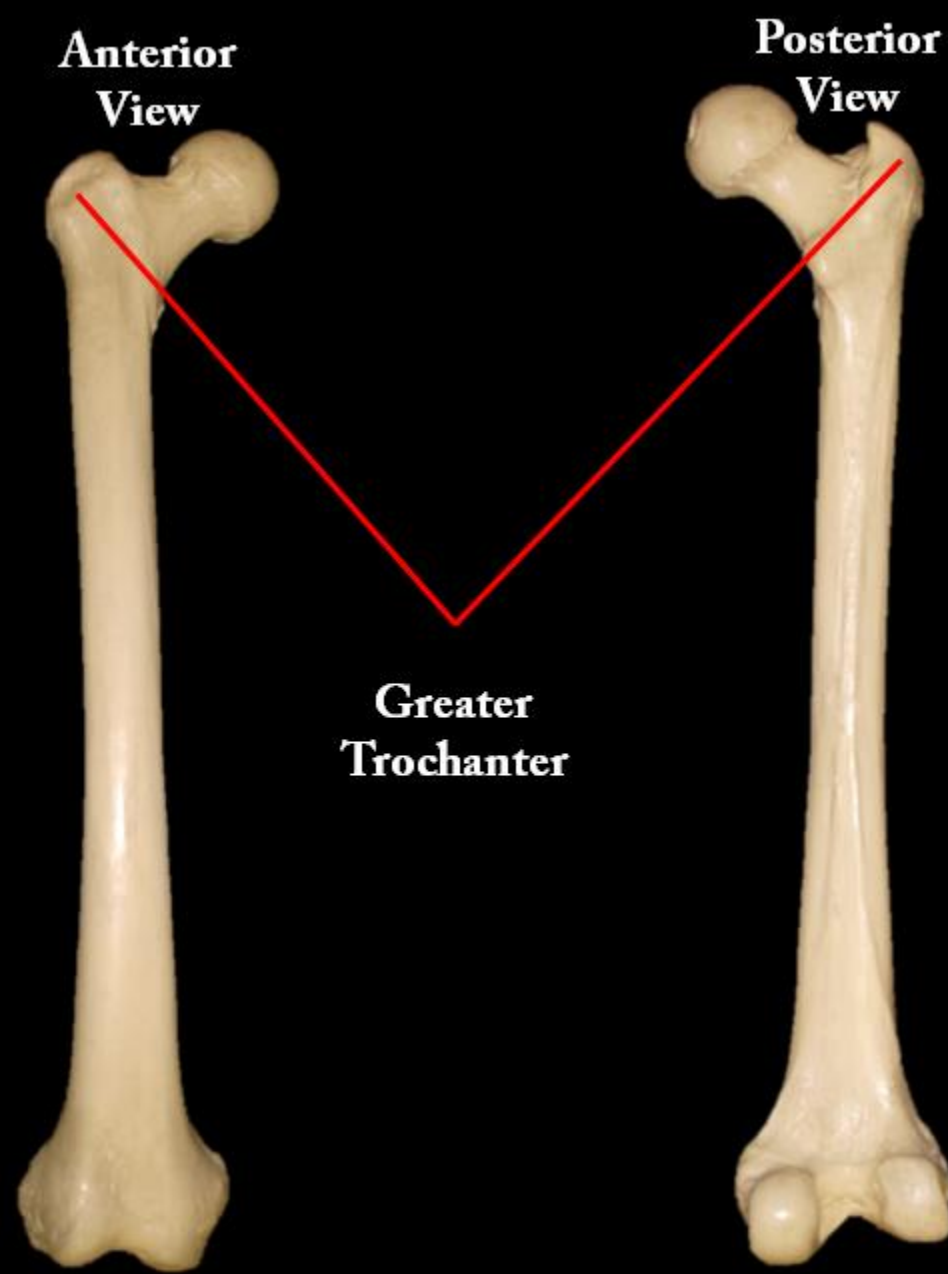
Name the Structure

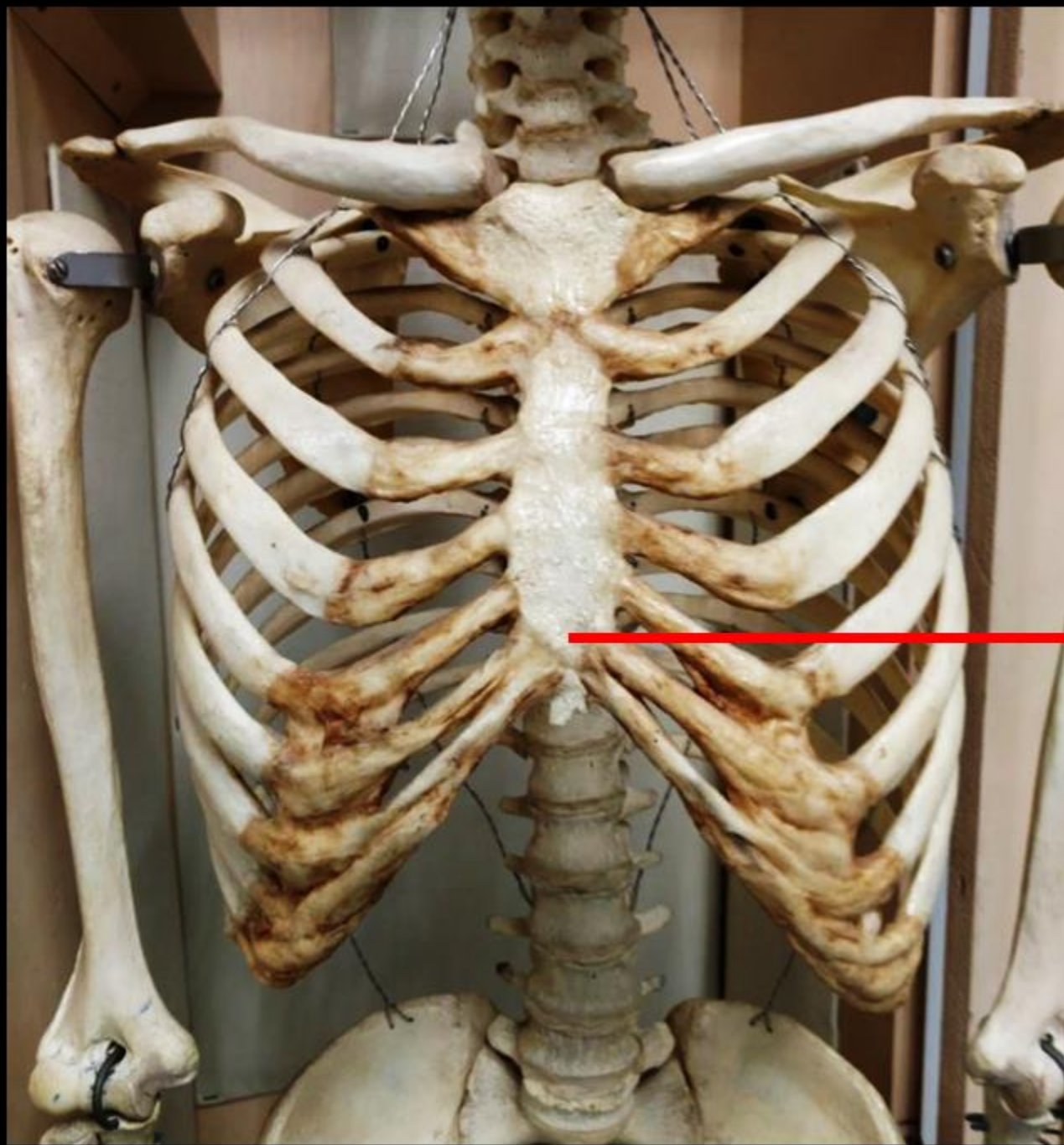




Name the Bone  
= Femur

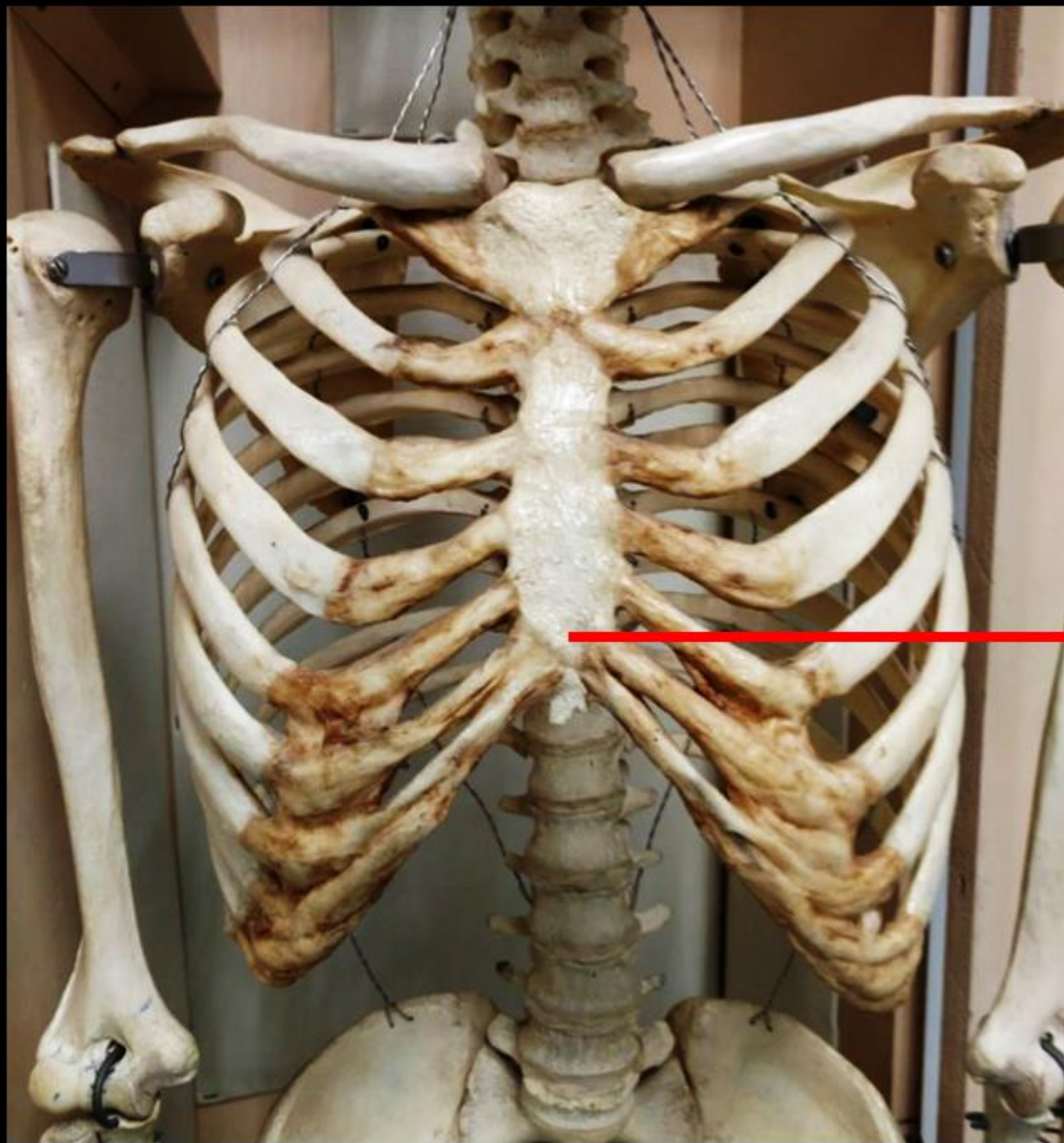
Name the Structure  
= Greater Trochanter





**Name the Bone.**

**Name the Structure.**

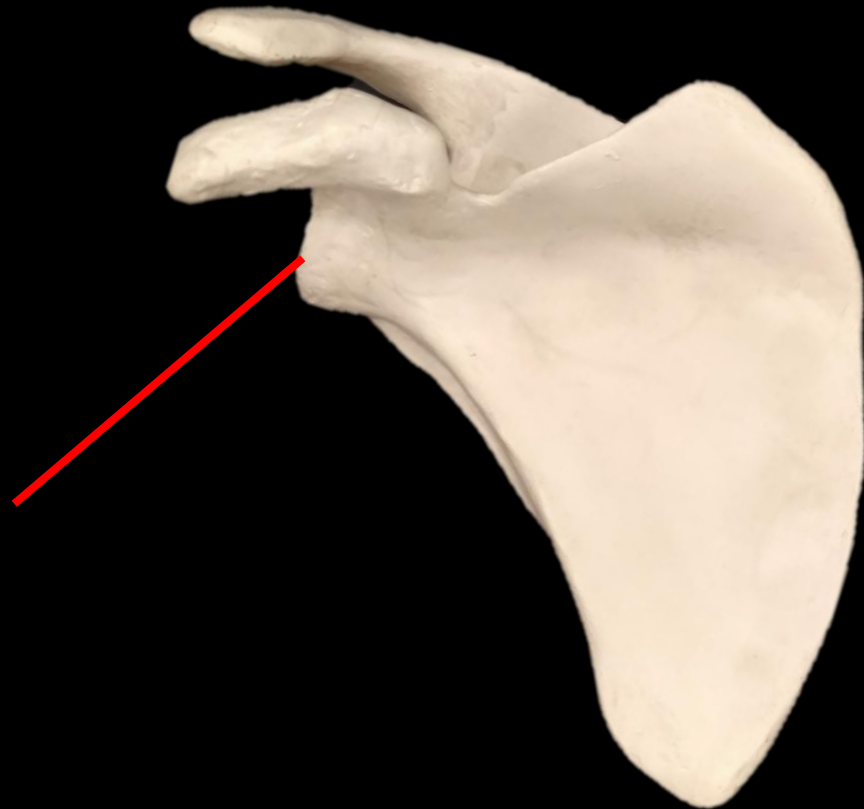

**Name the Bone  
= STERNUM**

**Name the Structure  
= XIPHOID PROCESS**

---

*What is the Bone?*  
*What is the Structure?*

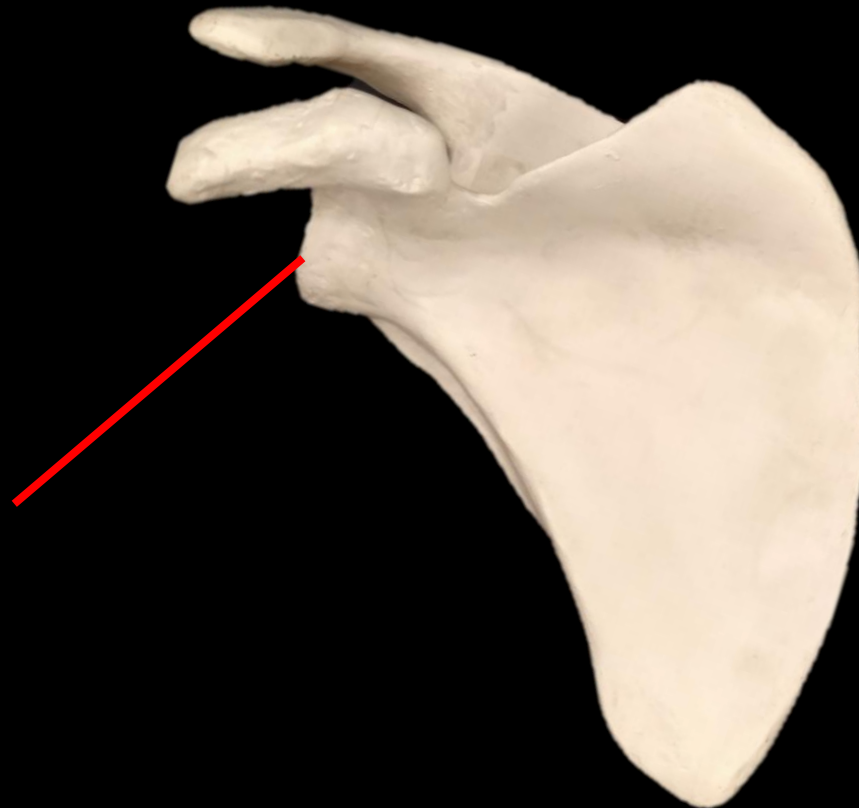

*What is the Bone?*

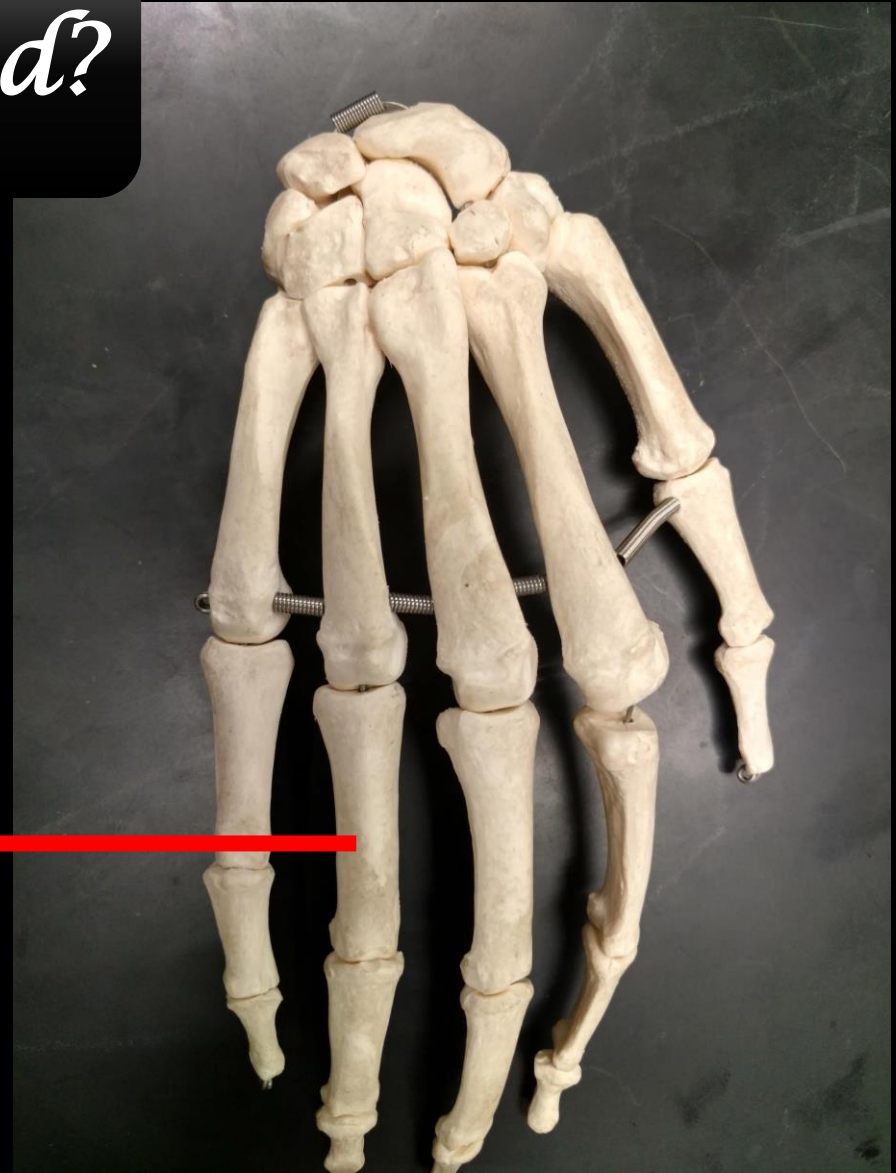
*What is the Structure?*

*This is the scapula.*

*Glenoid  
Cavity*

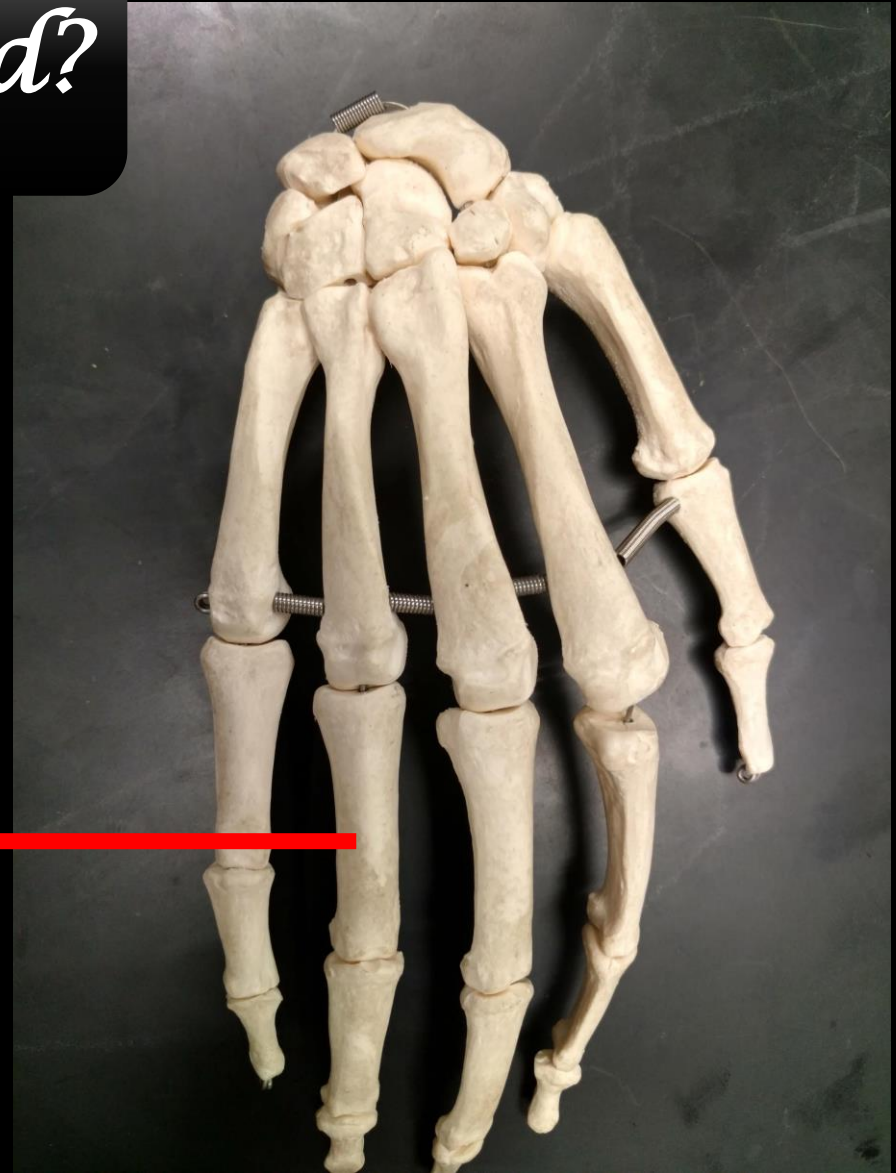

*What are these Bones called?*

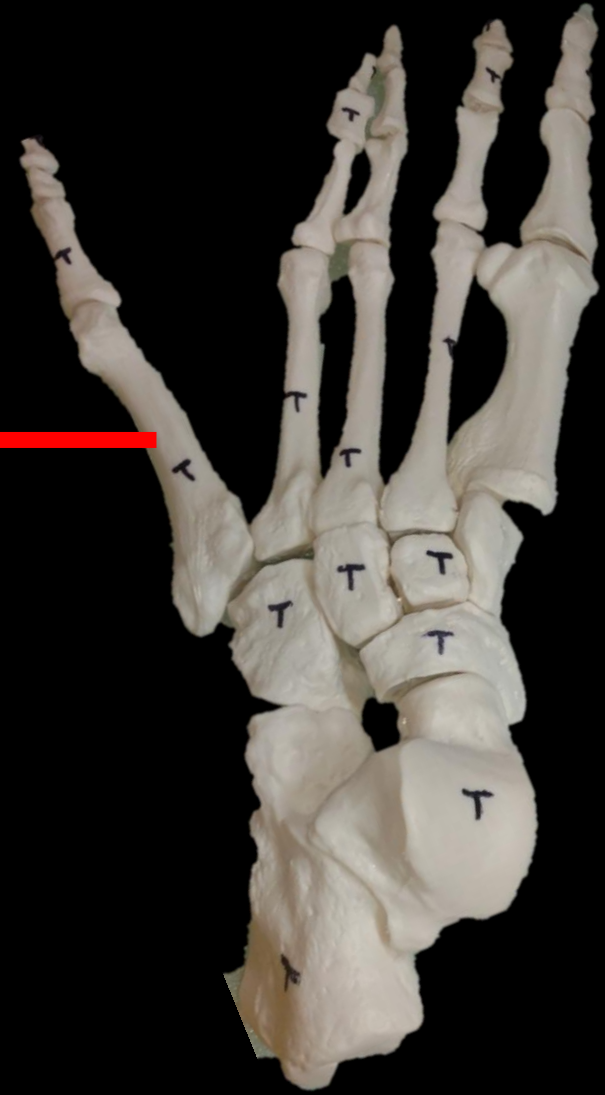


*What are these Bones called?*

*Phalanges*

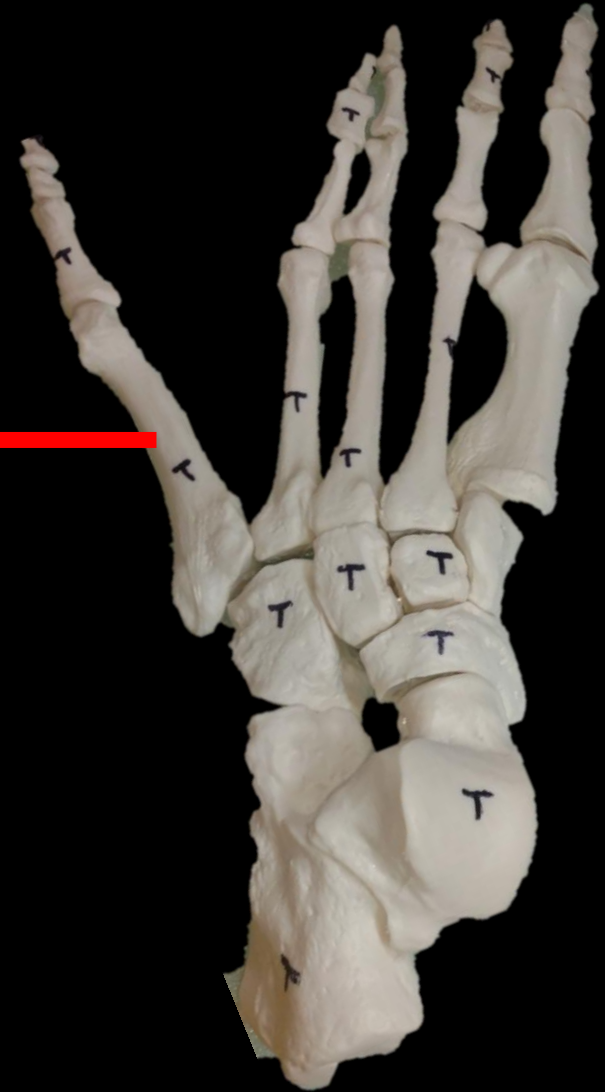


*What are these Bones called?*





*What are these Bones called?*



*Metatarsals*

**What is the Bone?**



**What is the Structure?**

**What is the Bone?**

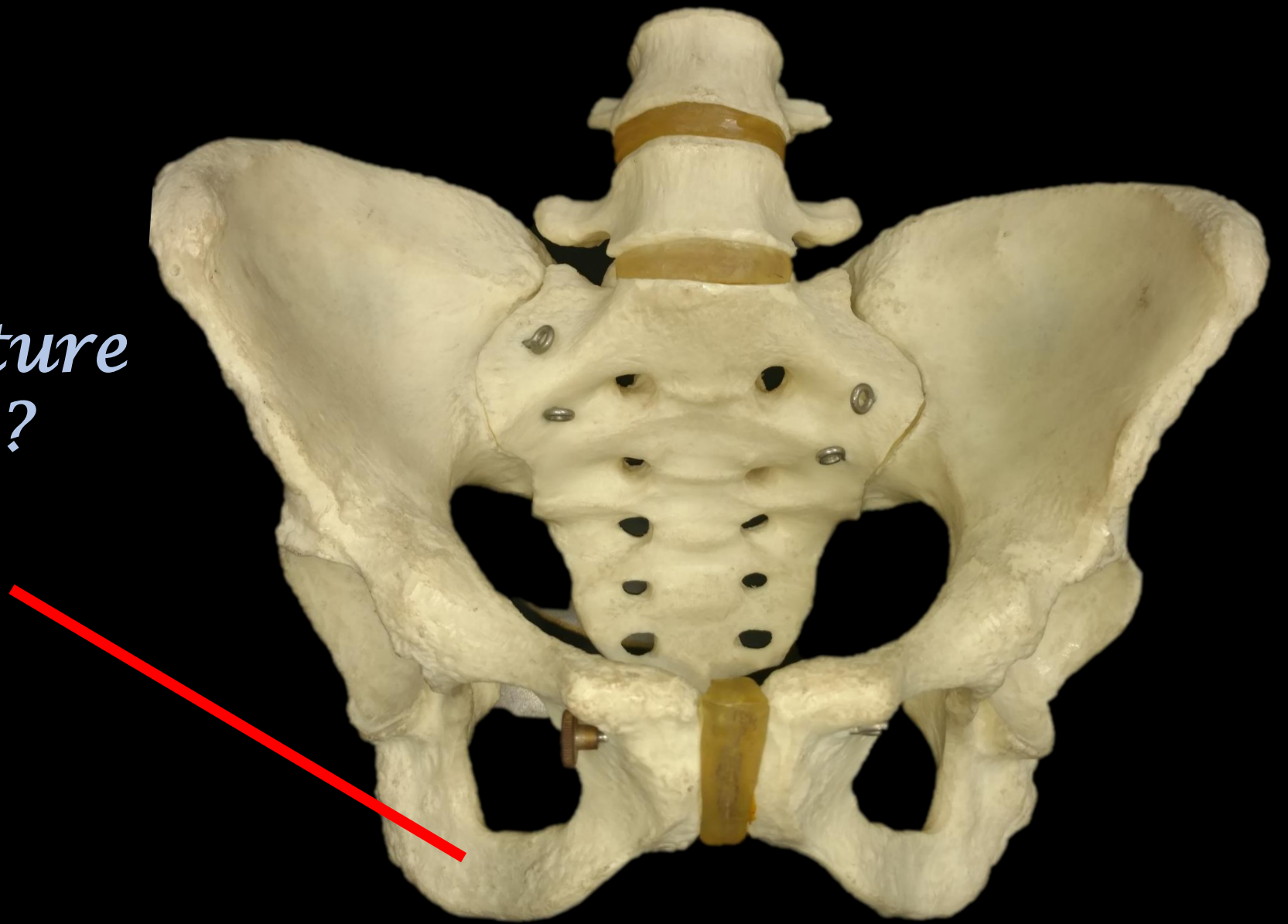
**The Humerus**



**What is the Structure?**

**The Capitulum**

*Name the Structure  
and the Bone?*



*Name the Structure  
and the Bone?*

*The Ischium*

*The Coxal Bone*

