

Laboratory Manual for Anatomy & Physiology

SEVENTH EDITION

Elaine N. Marieb, R.N., Ph.D.
Holyoke Community College

Lori A. Smith, Ph.D.
American River College



Editor-in-Chief: Serina Beuparlant
Senior Courseware Portfolio Manager: Lauren Harp
Managing Producer: Nancy Tabor
Content & Design Manager: Michele Mangelli, Mangelli
Productions, LLC
Courseware Editorial Assistant: Lidia Bayne
Production Supervisor: David Novak
Proofreader: Martha Ghent

Compositor: SPi Global
Interior & Cover Designer: Hespenheide Design
Illustrators: Imagineering STA Media Services, Inc.
Rights & Permissions Management: Ben Ferrini
Manufacturing Buyer: Stacey Weinberger
Product Marketing Manager: Wendy Mears
Director of Product Marketing, Science: Allison Rona
Senior Anatomy & Physiology Specialist: Derek Perrigo

Cover Photo Credit: Jacek Chabraszewski/Shutterstock

Copyright © 2020, 2017, 2014 Pearson Education, Inc. 221 River Street, Hoboken, NJ 07030. All Rights Reserved. Printed in the United States of America. This publication is protected by copyright, and permission should be obtained from the publisher prior to any prohibited reproduction, storage in a retrieval system, or transmission in any form or by any means, electronic, mechanical, photocopying, recording, or otherwise. For information regarding permissions, request forms and the appropriate contacts within the Pearson Education Global Rights & Permissions department.

Acknowledgements of third-party content appear on page 373, which constitutes an extension of this copyright page.

Unless otherwise indicated herein, any third-party trademarks that may appear in this work are the property of their respective owners and any references to third-party trademarks, logos or other trade dress are for demonstrative or descriptive purposes only. Such references are not intended to imply any sponsorship, endorsement, authorization, or promotion of Pearson's products by the owners of such marks, or any relationship between the owner and Pearson Education, Inc. or its affiliates, authors, licensees or distributors.

The Author and Publisher believe that the lab experiments described in this publication, when conducted in conformity with the safety precautions described herein and according to the school's laboratory safety procedures, are reasonably safe for the students to whom this lab manual is directed. Nonetheless, many of the described experiments are accompanied by some degree of risk, including human error, the failure or misuse of laboratory or electrical equipment, mismeasurement, spills of chemicals, and exposure to sharp objects, heat, bodily fluids, blood, or other biologics. The Author and Publisher disclaim any liability arising from such risks in connection with any of the experiments contained in this manual. If students have any questions or problems with materials, procedures, or instructions on any experiment, they should always ask their instructor for help before proceeding.

Contents

THE HUMAN BODY: ORIENTATION

- 1 The Language of Anatomy 1**
- 1 Locating Body Landmarks 1
 - 2 Practicing Using Correct Anatomical Terminology 3
 - 3 Observing Sectioned Specimens 4
 - 4 Locating Abdominopelvic Surface Regions 6
- [Review Sheet 7](#)

- 2 Organ Systems Overview 9**
- 1 Studying the Organ Systems of the Body and Their Functions 9
- Dissection* Rat Dissection and/or Observation 9
- 2 Observing External Structures 11
 - 3 Examining the Mouth (Oral Cavity) 11
 - 4 Opening the Ventral Body Cavity 11
 - 5 Examining the Ventral Body Cavity 12
 - 6 Examining the Human Torso Model 15
- [Review Sheet 17](#)

THE CELL

- 3 The Cell—Anatomy and Division 19**
- 1 Identifying Parts of a Cell 19
 - 2 Identifying Components of a Plasma Membrane 20
 - 3 Locating Organelles 21
 - 4 Examining the Cell Model 21
 - 5 Observing Differences and Similarities in Cell Structure 22
 - 6 Identifying the Mitotic Stages 24
 - 7 Creating Mitotic Figures 24
- [Review Sheet 25](#)

- 4 Cell Membrane Transport Mechanisms 29**
- 1 Observing Diffusion of Dye Through Agar Gel 30
 - 2 Observing Diffusion Through Nonliving Membranes 31
 - 3 Investigating Diffusion Through Living Membranes 33
 - 4 Observing the Process of Filtration 33
- [Review Sheet 35](#)

BASIC TISSUES AND THE SKIN

- 5 Classification of Tissues 37**
- 1 Examining Epithelial Tissue Under the Microscope 42
 - 2 Examining Connective Tissue Under the Microscope 42

- 3 Examining Muscle Tissue Under the Microscope 47
 - 4 Examining Nervous Tissue Under the Microscope 49
 - 5 Constructing a Concept Map of the Tissues 50
- [Review Sheet 51](#)

- 6 The Integumentary System 55**
- 1 Locating Structures on a Skin Model 56
 - 2 Visualizing Changes in Skin Color Due to Continuous External Pressure 57
 - 3 Viewing Two Types of Pressure Receptors Microscopically 58
 - 4 Determining the Two-Point Threshold 58
 - 5 Testing Tactile Localization 58
 - 6 Demonstrating Adaptation of Touch Receptors 59
 - 7 Plotting the Distribution of Sweat Glands 59
 - 8 Examining a Skin Slide 61
 - 9 Identifying Nail Structures 62
- [Review Sheet 63](#)

THE SKELETAL SYSTEM

- 7 Overview of the Skeleton 67**
- 1 Examining and Classifying Bones 70
 - 2 Examining a Long Bone 70
 - 3 Comparing the Relative Contributions of Bone Salts and Collagen Fibers in Bone Matrix 71
 - 4 Examining the Effects of Heat and Nitric Acid on Bones 71
 - 5 Examining the Microscopic Structure of Compact Bone 72
- [Review Sheet 75](#)

- 8 The Axial Skeleton 79**
- 1 Identifying the Bones of the Adult Skull 79
 - 2 Palpating Skull Markings 83
 - 3 Examining Spinal Curvatures 85
 - 4 Palpating the Spinous Processes 86
 - 5 Examining Vertebral Structure 87
 - 6 Examining the Relationship Between Ribs and Vertebrae 88
- [Review Sheet 89](#)

- 9 The Appendicular Skeleton 95**
- 1 Examining and Identifying Bones of the Appendicular Skeleton 95
 - 2 Palpating the Surface Anatomy of the Pectoral Girdle and the Upper Limb 98
 - 3 Palpating the Surface Anatomy of the Pelvic Girdle 99
 - 4 Comparing Male and Female Pelves 101

- 5 Palpating the Surface Anatomy of the Lower Limb 104
- 6 Constructing a Skeleton 104
- [Review Sheet](#) 105

10 Joints and Body Movements 109

- 1 Identifying Fibrous Joints 109
- 2 Identifying Cartilaginous Joints 109
- 3 Examining Synovial Joint Structure 110
- 4 Demonstrating the Importance of Friction-Reducing Structures 112
- 5 Identifying Types of Synovial Joints 112
- 6 Demonstrating Movements of Synovial Joints 113
- 7 Demonstrating Uniaxial, Biaxial, and Multiaxial Movements 116
- [Review Sheet](#) 117

THE MUSCULAR SYSTEM

11 Microscopic Anatomy and Organization of Skeletal Muscle 121

- 1 Examining Skeletal Muscle Cell Anatomy 123
- 2 Observing Muscle Fiber Contraction 123
- 3 Observing the Structure of a Skeletal Muscle 124
- 4 Studying the Structure of a Neuromuscular Junction 126
- [Review Sheet](#) 127

12 Gross Anatomy of the Muscular System 131

- 1 Identifying Head and Neck Muscles 131
- 2 Identifying Muscles of the Trunk 136
- 3 Demonstrating Operation of Trunk Muscles 136
- 4 Identifying Muscles of the Upper Limb 138
- 5 Identifying Muscles of the Hip and Lower Limb 140
- 6 Palpating Muscles of the Hip and Lower Limb 142
- 7 Making a Muscle Painting 142
- [Review Sheet](#) 145

REGULATORY SYSTEMS: NEURAL AND ENDOCRINE

13 Neuron Anatomy and Physiology 151

- 1 Identifying Parts of a Neuron 153
- 2 Examining the Microscopic Structure of a Nerve 157
- [Review Sheet](#) 159

14 Gross Anatomy of the Brain and Cranial Nerves 163

- 1 Identifying External Brain Structures 163
- 2 Identifying Internal Brain Structures 167

- 3 Tracing the Pathway of Cerebrospinal Fluid in the Brain 168
- 4 Identifying and Testing the Cranial Nerves 171
- [Dissection](#) The Sheep Brain 171
- [Review Sheet](#) 175

15 Spinal Cord and Spinal Nerves 181

- 1 Identifying Structures of the Spinal Cord 181
- [Dissection](#) Spinal Cord 182
- 2 Identifying the Major Nerve Plexuses and Peripheral Nerves 186
- [Review Sheet](#) 187

16 Human Reflex Physiology 189

- 1 Initiating Stretch Reflexes 190
- 2 Initiating the Plantar Reflex 191
- 3 Initiating the Corneal Reflex 192
- 4 Initiating the Gag Reflex 192
- 5 Initiating Pupillary Reflexes 192
- [Review Sheet](#) 193

17 The Special Senses 195

- 1 Identifying Accessory Eye Structures 197
- 2 Identifying Internal Structures of the Eye 198
- [Dissection](#) The Cow (Sheep) Eye 199
- 3 Demonstrating the Blind Spot 200
- 4 Determining Near Point of Vision 201
- 5 Testing Visual Acuity 201
- 6 Testing for Astigmatism 202
- 7 Testing for Color Blindness 202
- 8 Demonstrating Reflex Activity of Intrinsic and Extrinsic Eye Muscles 202
- 9 Identifying Structures of the Ear 203
- 10 Examining the Ear with an Otoscope (Optional) 204
- 11 Examining the Microscopic Structure of the Cochlea 205
- 12 Conducting Laboratory Tests of Hearing 205
- 13 Conducting Laboratory Tests on Equilibrium 208
- 14 Identification of Papillae on the Tongue 210
- 15 Stimulating Taste Buds 211
- 16 Examining the Combined Effects of Smell, Texture, and Temperature on Taste 211
- [Review Sheet](#) 213

18 Functional Anatomy of the Endocrine Glands 221

- 1 Examining the Microscopic Structure of the Thyroid Gland 223
- 2 Palpating the Thyroid Gland 223
- 3 Examining the Microscopic Structure of the Pancreas to Identify Alpha and Beta Cells 225
- 4 Observing the Effects of Hyperinsulinism 225
- 5 Identifying the Endocrine Organs 226
- [Review Sheet](#) 227

THE CIRCULATORY SYSTEM

19 Blood 231

- 1 Determining the Physical Characteristics of Plasma 232
- 2 Examining the Formed Elements of Blood Microscopically 232
- 3 Determining the Hematocrit 234
- 4 Determining Hemoglobin Concentration 235
- 5 Determining Coagulation Time 237
- 6 Typing for ABO and Rh Blood Groups 238

Review Sheet 241

20 Anatomy of the Heart 245

- 1 Using the Heart Model to Study Heart Anatomy 248
- 2 Tracing the Path of Blood Through the Heart 249
- 3 Examining Cardiac Muscle Cells 250

Dissection The Sheep Heart 250

Review Sheet 253

21 Anatomy of Blood Vessels 257

- 1 Examining the Microscopic Structure of Arteries and Veins 259
- 2 Locating Arteries on an Anatomical Chart or Model 264
- 3 Identifying the Systemic Veins 267
- 4 Identifying Vessels of the Pulmonary Circulation 267
- 5 Tracing the Hepatic Portal Circulation 269
- 6 Tracing the Arterial Supply of the Brain 269

Review Sheet 271

22 Human Cardiovascular Physiology— Blood Pressure and Pulse Determinations 277

- 1 Auscultating Heart Sounds 279
- 2 Palpating Superficial Pulse Points 280
- 3 Taking an Apical Pulse 280
- 4 Using a Sphygmomanometer to Measure Arterial Blood Pressure Indirectly 281
- 5 Observing the Effect of Various Factors on Blood Pressure and Heart Rate 282
- 6 Examining the Effect of Local Chemical and Physical Factors on Skin Color 284

Review Sheet 287

THE RESPIRATORY SYSTEM

23 Anatomy of the Respiratory System 291

- 1 Identifying the Upper Respiratory System Organs 291
- 2 Identifying the Lower Respiratory System Organs 294
- 3 Demonstrating Lung Inflation in a Sheep Pluck 296

- 4 Examining Prepared Slides of Trachea and Lung Tissue 296

Review Sheet 297

24 Respiratory System Physiology 301

- 1 Operating the Model Lung 301
- 2 Measuring Respiratory Volumes 303
- 3 Visualizing Respiratory Variations 305

Review Sheet 307

OTHER MAJOR SYSTEMS

25 Functional Anatomy of the Digestive System 311

- 1 Observing the Histological Structure of the Alimentary Canal Wall 314
- 2 Identifying Alimentary Canal Organs 314
- 3 Examining the Villus Model 317
- 4 Identifying Types of Teeth 318
- 5 Studying Internal Tooth Anatomy 319
- 6 Locating the Salivary Glands 320
- 7 Examining the Histology of Salivary Gland Tissue 320
- 8 Locating the Liver, Pancreas, and Associated Structures 320
- 9 Examining the Histology of the Liver 320
- 10 Assessing Protein Digestion by Trypsin 322
- 11 Demonstrating the Action of Bile on Fats 323
- 12 Observing Movements and Sounds of Digestion 323
- 13 Viewing Segmental and Peristaltic Movements 324

Review Sheet 325

26 Functional Anatomy of the Urinary System 331

- 1 Identifying Urinary System Organs 331
- Dissection Gross Internal Anatomy of the Pig or Sheep Kidney 333
- 2 Studying Nephron Structure 334
 - 3 Analyzing Urine Samples 337

Review Sheet 339

27 Anatomy of the Reproductive System 343

- 1 Identifying Male Reproductive Organs 343
- 2 Viewing Sperm Microscopically 345
- 3 Identifying Female Reproductive Organs 346
- 4 Conducting a Microscopic Study of the Ovary 349

Review Sheet 351

Histology Atlas 355

Appendix A: The Microscope 365

Credits 373

Index 375

Preface

Students in two-semester allied health–related programs typically encounter a fast-paced anatomy and physiology course that leaves little time for leisurely learning. These students are intently focused on achieving their goals, which requires a course that includes a brief, hands-on laboratory experience to flesh-out and clarify the lecture sessions. This challenge is what provided the impetus for developing this concise laboratory manual.

Basic Pedagogical Approach

The Seventh Edition offers a variety of experiments to give the instructor the flexibility to choose which will best supplement what is being taught in lecture. This manual is a stand-alone resource that can complement any textbook. Because each experiment is preceded by pertinent background information, students will not find it necessary to carry their textbooks to the lab.

Although length and content have been rigorously controlled, the 27 exercises in this manual still provide fairly complete coverage of the routine topics of human anatomy and physiology.

For instructors who wish their students to have experience using a microscope, this manual also includes a complete exercise on its use and care (see Appendix A).

Pedagogy and Special Features

1. The art and photo program includes tissue tables with photomicrographs, realistic muscle art, and large illustrations that highlight and differentiate important structures and help students recognize important relationships between structure and function. Photographs supplement the art to show isolated organ specimens for dissection and observation.
2. Each exercise is preceded by a list of materials needed for conducting the laboratory, followed by learning outcomes, summaries of key concepts, step-by-step instructions, and efficient tear-out review sheets that can be used for pre-lab or post-lab review.
3. Body structures are studied from simple to complex. Histology lessons will be expedited by slides set up by the instructor at demonstration areas for student viewing, so students do not have to spend time trying to find the “right” section. These, along with physiology experiments (written to be conducted in limited time periods and with inexpensive, widely available equipment and supplies) allow ample opportunity for student observation, manipulation, and experimentation.
4. All exercises involving body fluids (blood, saliva, etc.) incorporate current Centers for Disease Control and Prevention guidelines for handling body fluids. A safety icon alerts students to observe special precautions.
5. An *Instructor’s Guide* is available to instructors upon request (0-13-520203-5). This Guide contains answers to

activity and review sheet questions, and information on laboratory supply houses.

For information on creating a custom version of this manual, visit www.pearsonhighered.com/collections/, or contact your Pearson representative for details.

New to the Seventh Edition: Highlights

- **Dozens of new, full-color illustrations, and photos** replace many black and white line drawings to help students differentiate among structures and more easily interpret diagrams.
- **New Clinical Application Questions** have been added to the Exercise Review Sheets to challenge students to apply lab concepts and critical thinking skills to real-world clinical scenarios.
- **Improved Interior design** incorporates more saturated colors in headings and exercise tabs to improve readability.
- **Content and illustration updates** have been made throughout the Seventh Edition. Please contact your Pearson representative for more details.

Also Available

- *The Anatomy & Physiology Coloring Workbook, Twelfth Edition* by Elaine Marieb and Simone Brito. (0-13-445936-9)
- *The Anatomy Coloring Book, Fourth Edition* by Wynn Kapit and Lawrence Elson. (0-321-83201-9)
- *The Physiology Coloring Book, Second Edition* by Wynn Kapit, Robert Macey, and Esmail Meisami. (0-321-03663-8)
- *MasteringA&P™ for Anatomy & Physiology, Seventh Edition* is highly recommended. Mastering is the most effective and widely used online homework, tutorial, and assessment system for the sciences. To learn more, ask your Pearson representative for details or a demo.

Acknowledgments

Many thanks to the Pearson Education product team: Lauren Harp, Senior Acquisitions Editor and Wendy Mears, Marketing Manager. Kudos as usual to Mangelli Productions and to David Novak, our production supervisor for this project.

As always, we invite users of this edition to send us their comments and suggestions for subsequent editions.

Elaine N. Marieb and Lori A. Smith
Pearson Education, Anatomy and Physiology
50 California Street, San Francisco, CA 94111

The Language of Anatomy

Materials

- Human torso model (dissectible)
- Human skeleton
- Scalpel
- Demonstration area:
Station 1: Sectioned and labeled kidneys (three separate kidneys uncut or cut so that (a) entire, (b) transverse, and (c) median sectional views are visible)
Station 2: Gelatin-spaghetti molds

Learning Outcomes

- Describe the anatomical position verbally or by demonstrating it.
- Demonstrate proficiency in using terms describing body landmarks, directions, planes, and surfaces.
- Name the body cavities, and indicate important organs in each cavity.

Most of us are naturally curious about our bodies. This curiosity is apparent even in infants, who are fascinated with their own waving hands or their mother's nose. Unlike the infant, however, an anatomy student must learn to identify body structures formally.

This exercise presents some of the most important anatomical terms you will be using to describe the body and introduces you to **gross anatomy**, the study of body structures you can see with your naked eye.

Anatomical Position

When anatomists or doctors refer to specific areas of the human body, they do so relative to a standard position called the **anatomical position**. In the anatomical position, the human body is erect, with head and toes pointed forward and arms hanging at the sides with palms facing forward (**Figure 1.1a**).

- Assume the anatomical position. Notice that it is not particularly comfortable because you must hold your hands unnaturally forward.

Surface Anatomy

The body is divided into two main regions, the axial and appendicular regions. The **axial region** includes the head, neck, and trunk; it runs along the vertical axis of the body. The **appendicular region** includes the limbs, which are also called the appendages or extremities. The body is also divided up into smaller regions within those two main divisions. Several of these are described on the following pages.

Activity 1

Locating Body Landmarks

Anterior Body Landmarks

Identify and use anatomical terms to correctly label the following regions in Figure 1.1a:

Abdominal: Anterior body trunk region inferior to the ribs

Acromial: Point of the shoulder

Antebrachial: Forearm

Text continues on next page. →

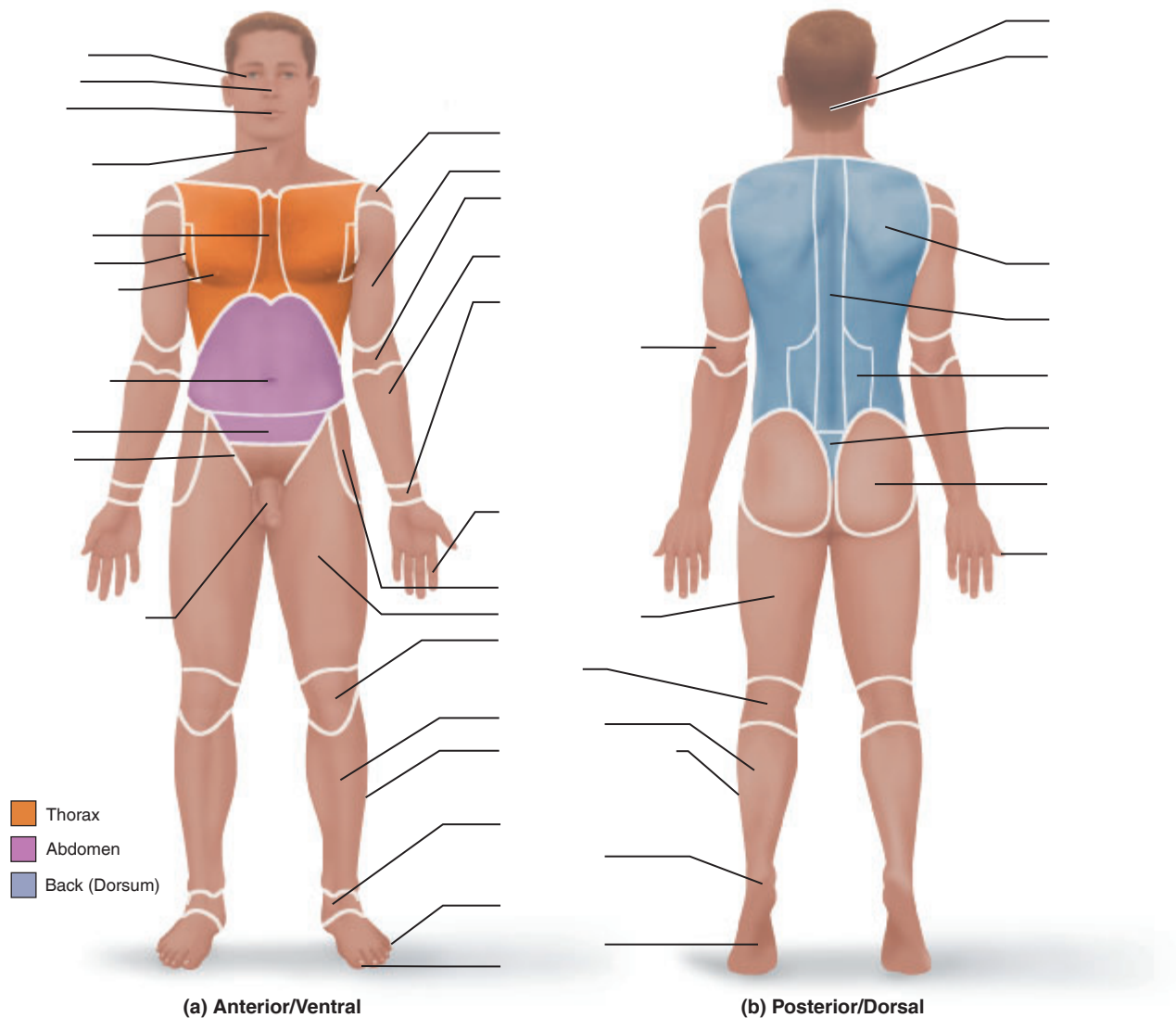


Figure 1.1 Surface anatomy.

Antecubital: Anterior surface of the elbow

Axillary: Armpit

Brachial: Arm

Buccal: Cheek

Carpal: Wrist

Cervical: Neck

Coxal: Hip

Crural: Leg (lower portion of the lower limb)

Digital: Fingers or toes

Femoral: Thigh

Fibular: Side of the leg

Hallux: Great toe

Inguinal: Groin

Mammary: Breast

Manus: Hand

Nasal: Nose

Oral: Mouth

Orbital: Bony eye socket (orbit)

Patellar: Kneecap

Pelvic: Pelvis

Pollex: Thumb

Pubic: Genital

Sternal: Breastbone

Tarsal: Ankle

Thoracic: Chest

Umbilical: Navel

Posterior Body Landmarks

Identify and appropriately label the following body surface regions in Figure 1.1b:

Brachial: Arm (upper portion of the upper limb)

Calcaneal: Heel of the foot

Cephalic: Head

Cervical: Neck

Femoral: Thigh

Fibular: Side of the leg

Gluteal: Buttocks

Lumbar: Lower back

Occipital: Back of the head

Olecranal: Back of the elbow

Otic: Ear

Popliteal: Back of the knee

Sacral: Posterior region between the hip bones

Scapular: Shoulder blade

Sural: Calf

Vertebral: Spine

Body Orientation and Direction

Study the terms below, referring to **Figure 1.2** as a visual aid.

Superior/inferior (*above/below*): These terms refer to the location of a structure along the long axis of the body. For example, the nose is superior to the mouth.

Anterior/posterior (*front/back*): In humans, the most anterior structures are those that are most forward—the face, chest, and abdomen. Posterior structures are those toward the backside of the body.

Medial/lateral (*toward the midline/away from the midline or median plane*): Medial structures are closer to the body

midline (which is the spine in humans). Lateral structures are farther away from the midline.

The terms described above assume the person is in the anatomical position. The next four pairs of terms are more absolute. They do not relate to a particular body position, and they have the same meaning in humans and four-legged animals.

Cephalad/caudal (*toward the head/toward the tail*): In humans, these terms are used interchangeably with *superior* and *inferior*. But in four-legged animals, they are synonyms of *anterior* and *posterior*, respectively.

Ventral/dorsal (*belly side/backside*): In humans, the terms *ventral* and *dorsal* are used interchangeably with the terms *anterior* and *posterior*; but in four-legged animals, *ventral* and *dorsal* are synonymous with *inferior* and *superior*, respectively.

Proximal/distal (*nearer the trunk or attached end/farther from the trunk or point of attachment*): These terms locate various areas along the body limbs or an elongated organ, such as the intestine. For example, the fingers are distal to the elbow; the knee is proximal to the toes. *Note:* The terms *proximal* and *distal* would not be used to describe the relationship of two structures in the torso.

Superficial/deep (*toward or at the body surface/away from the body surface or more internal*): For example, the skin is superficial to the skeletal muscles.

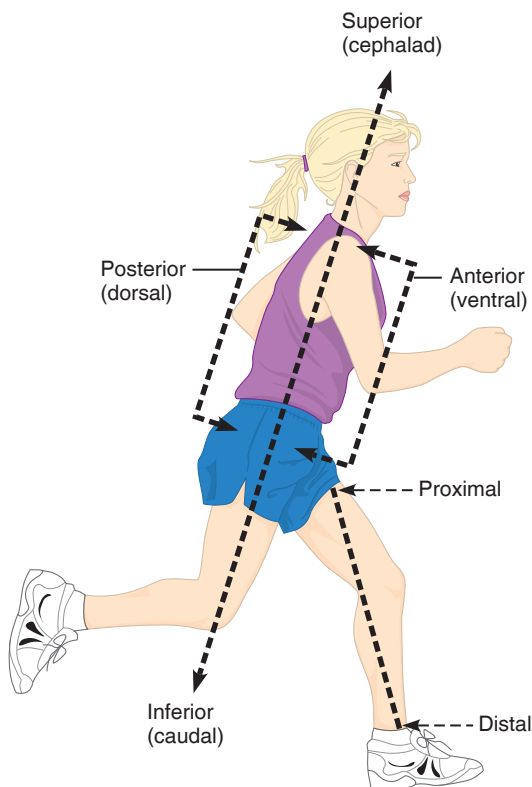


Figure 1.2 Anatomical terminology describing body orientation and direction in a human.

Activity 2

Practicing Using Correct Anatomical Terminology

Use a human torso model, a skeleton, or your own body to specify the relationship between the following structures.

1. The wrist is _____ to the hand.
2. The trachea (windpipe) is _____ to the spine.
3. The brain is _____ to the spinal cord.
4. The kidneys are _____ to the liver.
5. The nose is _____ to the cheekbones.
6. The chest is _____ to the abdomen.

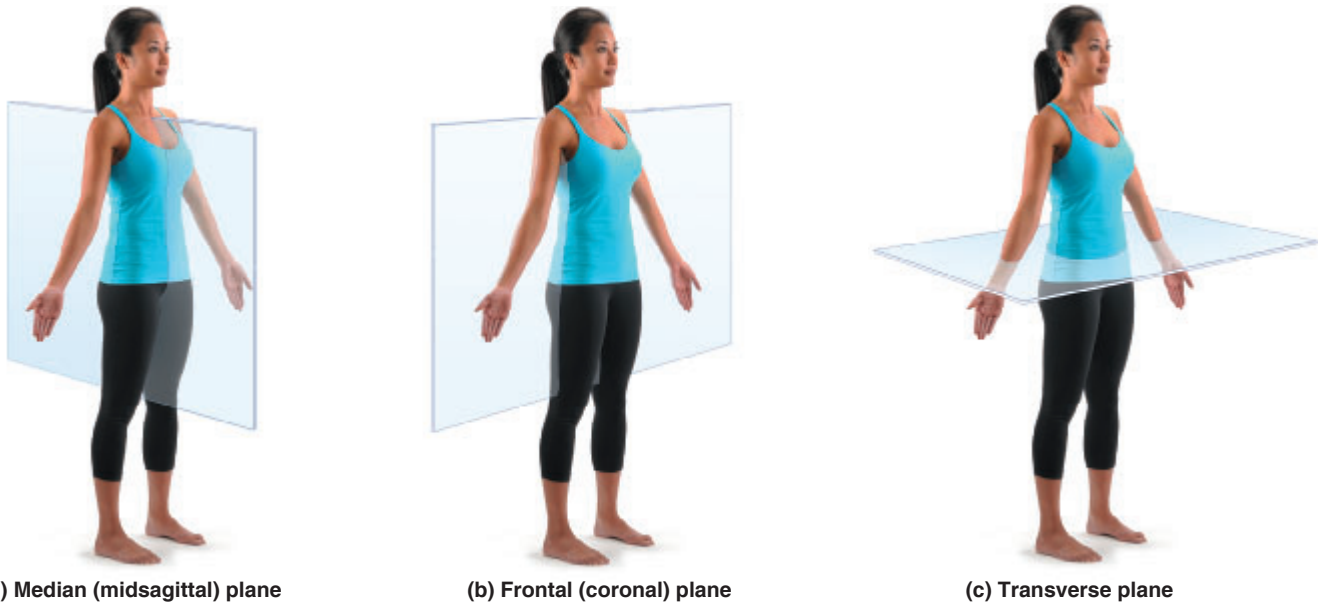


Figure 1.3 Planes of the body.

Body Planes and Sections

The body is three-dimensional. So, in order to observe its internal parts, it helps to make use of a **section**, or cut made along an imaginary surface or line called a **plane**. A section is named for the plane along which it is cut. There are three planes of space (**Figure 1.3**), or sections, that lie at right angles to one another.

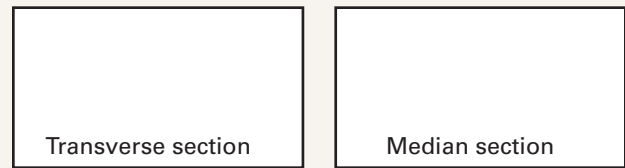
Sagittal plane: A plane that runs lengthwise or longitudinally down the length of the body, dividing it into right and left parts, is a sagittal plane. If it divides the body into equal parts, right down the median plane of the body, it is called a **median**, or **midsagittal**, plane.

Frontal (coronal) plane: A longitudinal plane that divides the body (or an organ) into anterior and posterior parts.

Transverse plane: A plane that runs horizontally, dividing the body into superior and inferior parts. These sections are also commonly called **cross sections**.

A sagittal or frontal section of any nonspherical object, be it a banana or a body organ, provides quite a different view from a transverse section (**Figure 1.4**).

4. Draw the appearance of each of these spaghetti sections below, and verify the accuracy of your section identifications with your instructor.



Activity 3

Observing Sectioned Specimens

1. Go to the demonstration area, and observe the entire (uncut) and transversely and longitudinally cut kidneys at station 1.
2. After completing step 1, obtain a gelatin-spaghetti mold and a scalpel and bring them to your laboratory bench.
3. Cut through the gelatin-spaghetti mold along any plane, and examine the cut surfaces. You should see spaghetti strands that have been cut transversely (XS) and longitudinally (a median section).

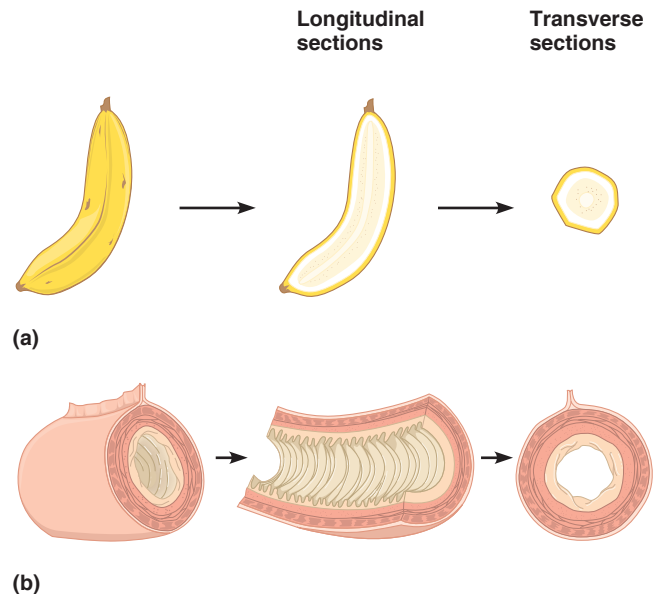


Figure 1.4 Comparison of longitudinal and transverse sections. Sections of (a) a banana and (b) the small intestine.

Body Cavities

The axial region of the body has two main cavities (**Figure 1.5**).

Dorsal Body Cavity

The dorsal body cavity consists of the cranial and spinal cavities. The **cranial cavity**, within the rigid skull, contains the brain. The **spinal cavity**, which runs within the bony vertebral column, protects the spinal cord.

Ventral Body Cavity

Like the dorsal cavity, the ventral body cavity is subdivided. The superior **thoracic cavity** is separated from the rest of the ventral cavity by the muscular diaphragm. The heart and lungs, which are located in the thoracic cavity, are protected by the bony rib cage. The thoracic cavity is further subdivided into the lateral **pleural cavities**, each of which surrounds a lung, and the medial **mediastinum**. The mediastinum contains the **pericardial cavity**, which encloses the heart, and it also surrounds the remaining thoracic organs (esophagus, trachea, and others).

The cavity inferior to the diaphragm is the **abdominopelvic cavity**. Although there is no further physical separation of this part of the ventral cavity, some describe the abdominopelvic cavity in terms of a superior **abdominal**

cavity, the area that houses the stomach, intestines, liver, and other organs, and an inferior **pelvic cavity**, which is partially enclosed by the bony pelvis and contains the reproductive organs, bladder, and rectum.

Abdominopelvic Quadrants and Regions

The abdominopelvic cavity is quite large and contains many organs, so it is helpful to divide it up into smaller areas for study. The medical scheme divides the abdominal surface (and the abdominopelvic cavity deep to it) into four approximately equal regions called **quadrants**, named according to their relative position—that is, *right upper quadrant*, *right lower quadrant*, *left upper quadrant*, and *left lower quadrant* (**Figure 1.6**). *Note*: These directions refer to the patient's left and right—not yours!

Another scheme, commonly used by anatomists, divides the abdominal surface and abdominopelvic cavity into nine separate regions by four planes (**Figure 1.7a**). Read through the descriptions of these nine regions below and locate them in the figure. Notice the organs they contain (refer to **Figure 1.7b**).

Umbilical region: The centermost region, which includes the umbilicus (navel, or “belly button”).

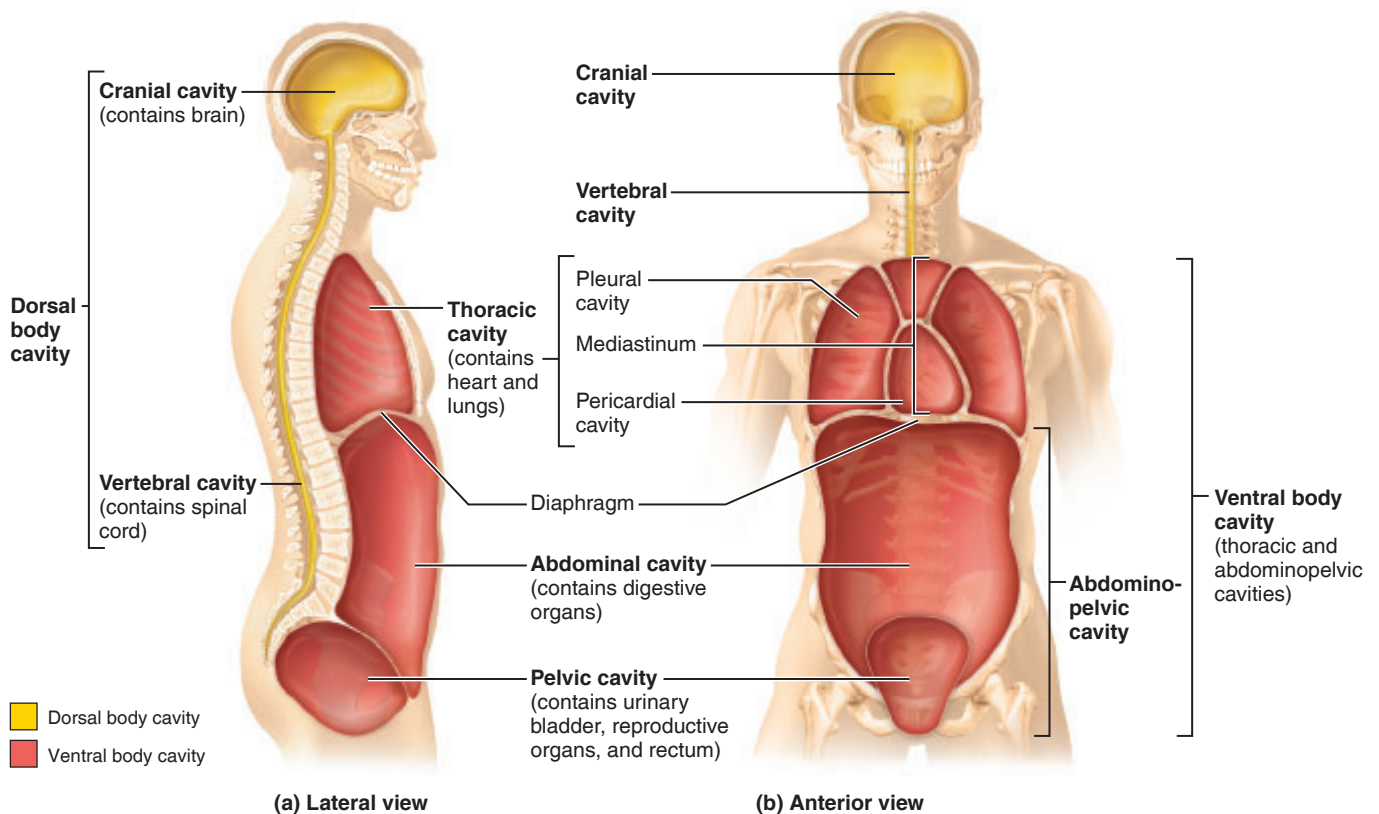


Figure 1.5 Body cavities.

Epigastric region: Immediately superior to the umbilical region; overlies most of the stomach.

Pubic (hypogastric) region: Immediately inferior to the umbilical region; encompasses the pubic area.

Inguinal, or iliac, regions: Lateral to the hypogastric region and overlying the superior parts of the hip bones.

Lateral (lumbar) regions: Between the ribs and the flaring portions of the hip bones; lateral to the umbilical region.

Hypochondriac regions: Flanking the epigastric region laterally and overlying the lower ribs.

1

Activity 4

Locating Abdominopelvic Surface Regions

Locate the regions of the abdominopelvic surface on a torso model and on yourself before continuing.

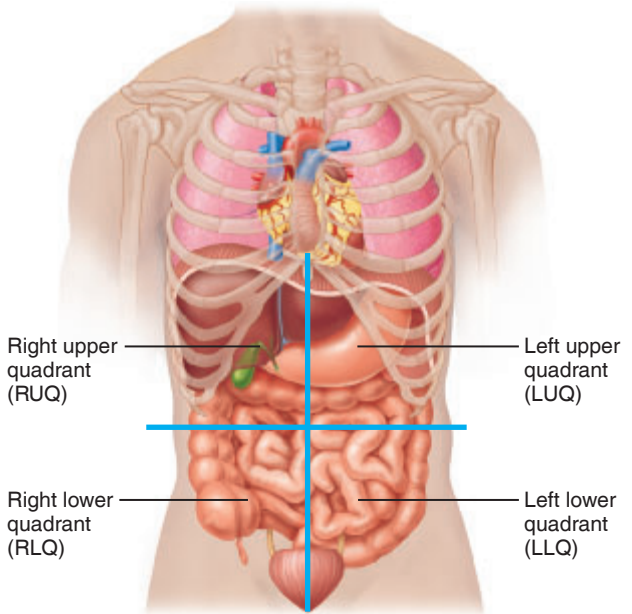
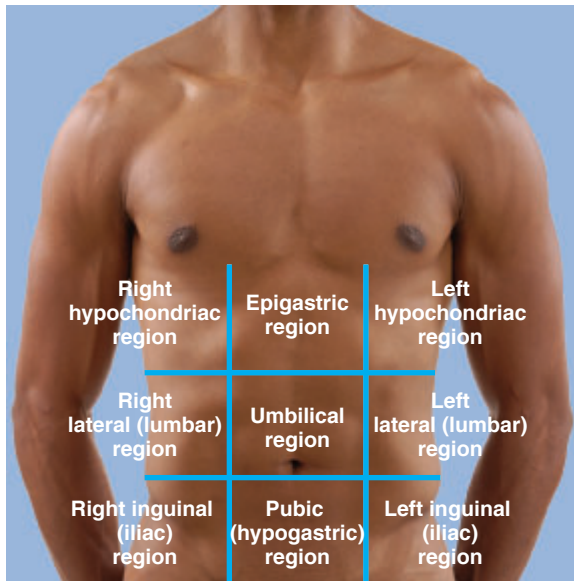
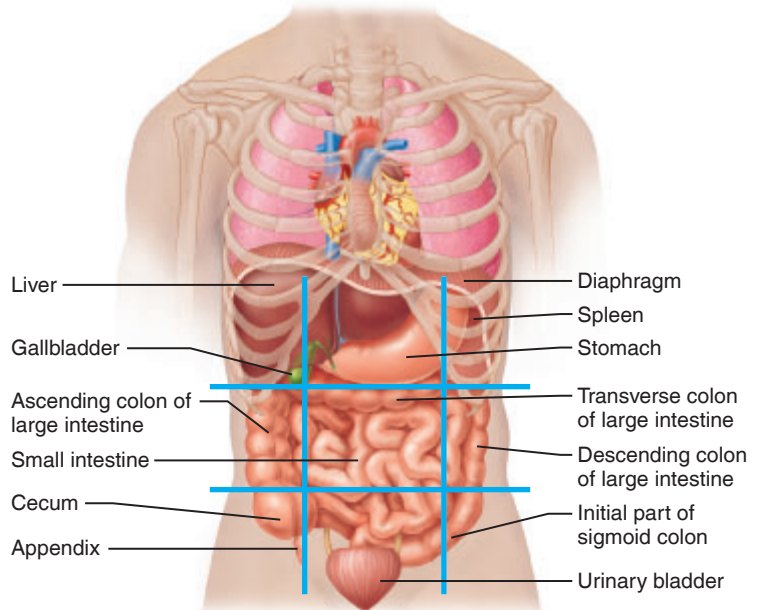


Figure 1.6 Abdominopelvic quadrants. Superficial organs shown in each quadrant.



(a)



(b)

Figure 1.7 Abdominopelvic regions. Nine regions defined by four planes. (a) The superior horizontal plane is just inferior to the ribs; the inferior horizontal plane is at the superior aspect of the hip bones. The vertical planes are just medial to the nipples. (b) Superficial organs are shown in each region.

EXERCISE
1

REVIEW SHEET

The Language of Anatomy

Name _____ Lab Time/Date _____

Surface Anatomy

1. Match each of the following descriptions with a key term, and write the term in front of the description.

Key:	acromial	cervical	patellar	scapular
	brachial	crural	popliteal	vertebral
	carpal	digital		

- | | | | |
|----------|---------------------------------|-----------|-------------------------|
| _____ 1. | lower portion of the lower limb | _____ 6. | anterior aspect of knee |
| _____ 2. | referring to the fingers | _____ 7. | referring to the arm |
| _____ 3. | posterior aspect of the knee | _____ 8. | your backbone, or spine |
| _____ 4. | shoulder blade | _____ 9. | point of the shoulder |
| _____ 5. | wrist area | _____ 10. | referring to the neck |

Body Orientation, Direction, Planes, and Sections

2. Several incomplete statements are listed below. Correctly complete each statement by choosing the appropriate anatomical term from the key. Write the key terms on the correspondingly numbered blanks below. Some terms may be used more than once.

Key:	anterior	inferior	posterior	superior
	distal	lateral	proximal	transverse
	frontal	medial	sagittal	

In the anatomical position, the umbilicus and knees are on the 1 body surface; the calves and shoulder blades are on the 2 body surface; and the soles of the feet are the most 3 part of the body. The ears are 4 and 4 to the shoulders and 5 to the nose. The breastbone is 6 to the vertebral column (spine) and 7 to the shoulders. The elbow is 8 to the shoulder but 9 to the fingers. The thoracic cavity is 10 to the abdominopelvic cavity and 11 to the spinal cavity. In humans, the ventral surface can also be called the 12 surface; however, in quadruped animals, the ventral surface is the 13 surface.

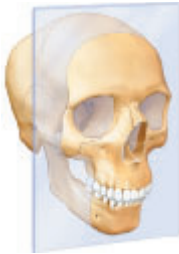If an incision cuts the brain into superior and inferior parts, the section is a 14 section; but if the brain is cut so that anterior and posterior portions result, the section is a 15 section. You are told to cut a dissection animal along two planes so that the lungs are observable in both sections. The body plane that would *not* meet these criteria is 16.

- | | | |
|----------|-----------|-----------|
| 1. _____ | 6. _____ | 12. _____ |
| 2. _____ | 7. _____ | 13. _____ |
| 3. _____ | 8. _____ | 14. _____ |
| 4. _____ | 9. _____ | 15. _____ |
| _____ | 10. _____ | 16. _____ |
| 5. _____ | 11. _____ | |

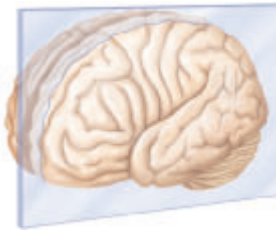
8 Review Sheet 1

3. A nurse informs you that she is about to give you a shot in the lateral femoral region. What portion of your body should you uncover?
-

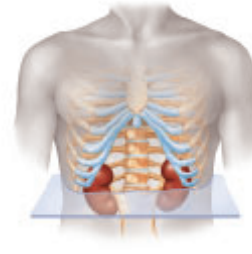
4. Correctly identify each of the body planes by inserting the appropriate term for each on the answer line below the drawing.



(a) _____



(b) _____



(c) _____

Body Cavities

5. Which body cavity would have to be opened for the following types of surgery? (Insert the key term in the same-numbered blank.)

Key: abdominopelvic cranial spinal thoracic

1. surgery to remove a cancerous lung lobe 1. _____
2. gastric bypass surgery to reduce the size of the stomach 2. _____
3. surgery to remove a ruptured spinal disk 3. _____
4. removal of a brain tumor 4. _____
6. **+** Name the body region that blood is usually drawn from. _____
7. **+** A patient has been diagnosed with appendicitis. Use anatomical terminology to describe the location of the person's pain. Assume that the pain is referred to the surface of the body above the organ.
- _____
- _____
8. **+** Which body cavity would be opened to perform a hysterectomy? _____
- _____

Organ Systems Overview

Materials

- Freshly killed or pre-dissected rat (if available)
- Probes
- Forceps
- Scissors
- Dissecting pins or twine
- Dissecting trays
- Disposable gloves
- Human torso model (dissectible)

Learning Outcomes

- Identify several organs of the various organ systems on a dissected rat.
- Identify several organs on a dissectible human torso model, and, given a list of organs, assign each to the correct organ system.

The building block of life is the **cell**. Cells fall into four different groups according to their structures and functions. These categories correspond to the four primary **tissue** types: epithelial, muscular, nervous, and connective. An **organ** is a structure composed of two or more tissue types that performs a specific function for the body.

An **organ system** is a group of organs that act together to perform a particular body function. For example, digestive system organs work together to break down foods moving through the digestive system and absorb the end products into the bloodstream to provide nutrients for all the body's cells.

An important concept in your study of anatomy and physiology is **homeostasis**, which can be defined as a state of body equilibrium or a stable internal environment of the body. Keep this concept in mind as you study the organ systems listed in **Table 2.1** and begin to think about how each of these important systems works to maintain homeostasis in the human body.

Activity 1

Studying the Organ Systems of the Body and Their Functions

In all, there are 11 organ systems (Table 2.1). Read through this summary before beginning the rat dissection.



DISSECTION

Rat Dissection and/or Observation

Many of the external and internal structures of the rat are quite similar in structure and function to those of the human, so a study of the gross anatomy of the rat should help you understand your own anatomy.

The following instructions complement and direct your dissection and observation of a rat. In addition, you can easily adapt the general instructions for observing external structures to observing a human cadaver, if cadavers are available.


Note that four organ systems—integumentary, skeletal, muscular, and nervous—will not be studied at this time, because they require microscopic study or more detailed dissection.

Table 2.1 Overview of Organ Systems of the Body		
Organ system	Major component organs	Function
Integumentary	Skin, nails, and hair; cutaneous sense organs and glands	<ul style="list-style-type: none"> • Protects deeper organs from injury due to bumps, chemicals, bacteria, and dehydration (drying out) • Excretes salts and urea • Helps regulate body temperature
Skeletal	Bones, cartilages, tendons, ligaments, and joints	<ul style="list-style-type: none"> • Supports and protects internal organs • Provides levers for muscular action • Stores minerals (calcium and others) • Cavities provide a site for blood cell formation
Muscular	Muscles attached to the skeleton	<ul style="list-style-type: none"> • Skeletal muscles contract, or shorten; in doing so, they move bones to allow motion (running, walking, etc.), grasping and manipulating the environment, and facial expression • Generates heat
Nervous	Brain, spinal cord, nerves, and sensory receptors	<ul style="list-style-type: none"> • Allows body to detect changes in its internal and external environment and to respond to such information by activating appropriate muscles or glands • Helps maintain short-term homeostasis of the body by rapidly transmitting electrical signals
Endocrine	Pituitary, thyroid, parathyroid, adrenal, and pineal glands; ovaries, testes, and pancreas	<ul style="list-style-type: none"> • Promotes growth and development; produces chemical “messengers” (hormones) that travel in the blood to exert their effect(s) on various target organs of the body • Plays a role in regulating long-term homeostasis
Cardiovascular	Heart and blood vessels	<ul style="list-style-type: none"> • Carries blood containing oxygen, carbon dioxide, nutrients, wastes, ions, hormones, and other substances to and from the cells where exchanges are made; pumping action of the heart propels blood through the blood vessels • Protects body with blood clots, antibodies, and other protein molecules in the blood
Lymphatic	Lymphatic vessels, lymph nodes, spleen, and thymus	<ul style="list-style-type: none"> • Picks up fluid leaked from the blood vessels and returns it to the blood • Cleanses blood of pathogens and other debris • Houses cells (lymphocytes and others) that act in the immune response to protect the body from foreign substances (antigens)
Respiratory	Nasal cavity, pharynx, larynx, trachea, bronchi, and lungs	<ul style="list-style-type: none"> • Keeps the blood continuously supplied with oxygen while removing carbon dioxide • Contributes to the acid-base balance of the blood via its carbonic acid/bicarbonate buffer system
Digestive	Oral cavity, pharynx, esophagus, stomach, small and large intestines, and accessory structures (teeth, salivary glands, liver, gallbladder, and pancreas)	<ul style="list-style-type: none"> • Breaks down ingested foods to tiny particles, which can be absorbed into the blood for delivery to the body’s cells • Undigested residue leaves the body as feces
Urinary	Kidneys, ureters, urinary bladder, and urethra	<ul style="list-style-type: none"> • Filters the blood and then rids the body of nitrogen-containing wastes (urea, uric acid, and ammonia) that result from the breakdown of proteins and nucleic acids by the body’s cells. • Maintains water, electrolyte, and acid-base balance of blood
Reproductive	<p>Male: testes, scrotum, penis, and duct system, which carries sperm to the body exterior</p> <p>Female: ovaries, uterine tubes, uterus, and vagina</p>	<ul style="list-style-type: none"> • Produces gametes called sperm for producing offspring • Produces gametes called eggs; the female uterus houses a developing fetus until birth

Activity 2

Observing External Structures

1. If your instructor has provided a pre-dissected rat, go to the demonstration area to make your observations. Alternatively, if you and/or members of your group will be dissecting the specimen, obtain a preserved or freshly killed rat (one for every two to four students), a dissecting tray, dissecting pins, scissors, forceps, and disposable gloves. Bring these items to your laboratory bench.

 2. Don the gloves before beginning your observations. This precaution is particularly important when you are handling freshly killed animals, which may harbor internal parasites.

3. Observe the major divisions of the animal's body—head, trunk, and extremities. Compare these divisions to those of humans.

Activity 3

Examining the Mouth (Oral Cavity)

Examine the structures of the mouth or oral cavity, the most superior part of the digestive system. Identify the teeth and tongue. Observe the hard palate (the part supported by bone) and the soft palate (immediately posterior to the hard palate and with no bony support). Notice that the posterior end of the oral cavity leads into the throat, or pharynx, a passageway used by both the digestive and respiratory systems.

Activity 4

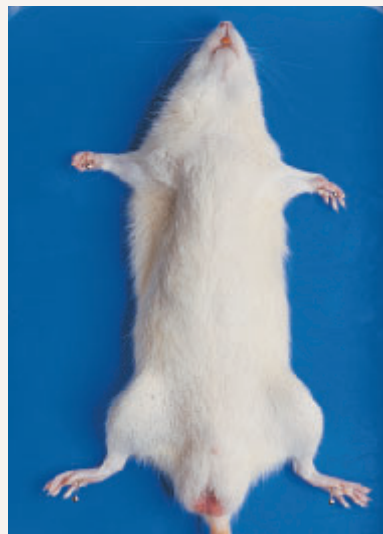Opening the Ventral Body Cavity

1. Pin the animal to the wax of the dissecting tray by placing its dorsal side down and securing its extremities to wax (**Figure 2.1a**).

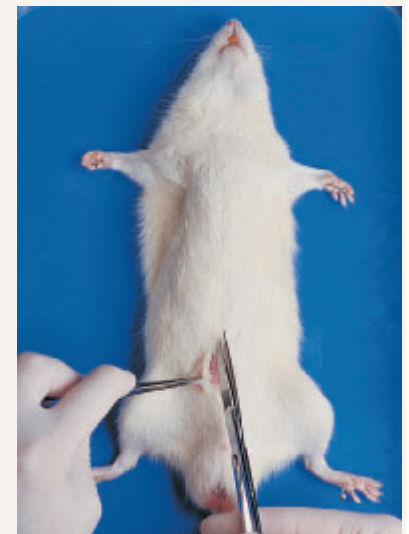
Text continues on next page. →

Figure 2.1 Rat dissection: Securing for dissection and the initial incision.

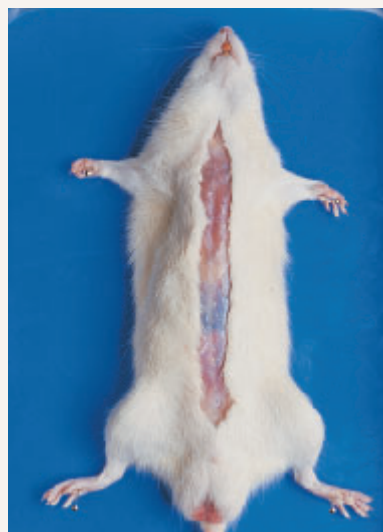(a) Securing the rat to the dissection tray with dissecting pins. (b) Using scissors to make the incision on the median line of the abdominal region. (c) Completed incision from the pelvic region to the lower jaw. (d) Reflecting (folding back) the skin to expose the underlying muscles.



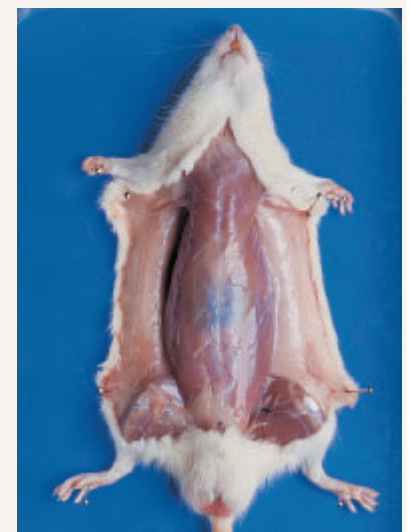
(a)



(b)



(c)



(d)

2. Lift the abdominal skin with a forceps, and cut through it with the scissors (Figure 2.1b). Close the scissor blades and insert them under the cut skin. Moving in a cephalad direction, open and close the blades to loosen the skin from the underlying connective tissue and muscle. Once you have completed this skin-freeing procedure, cut the skin along the body midline, from the pubic region to the lower jaw (Figure 2.1c). Make a lateral cut about halfway down the ventral surface of each limb. Complete the job of freeing the skin with the scissor tips, and pin the flaps to the tray (Figure 2.1d). The underlying tissue that is now exposed is the skeletal musculature of the body wall and limbs. It allows voluntary body movement. Notice that the muscles are packaged in sheets of pearly white connective tissue (fascia), which protect the muscles and bind them together.

3. Carefully cut through the muscles of the abdominal wall in the pubic region, avoiding the underlying organs. Remember, *to dissect* means “to separate.” Now, hold and lift the muscle layer with a forceps and cut through the muscle layer from the pubic region to the bottom of the rib cage. Make two lateral cuts through the rib cage (Figure 2.2). You should easily see a thin membrane attached to the inferior boundary of the rib cage: this is the **diaphragm**, which separates the thoracic and abdominal cavities. Cut the diaphragm away to loosen the rib cage. You can now carefully cut

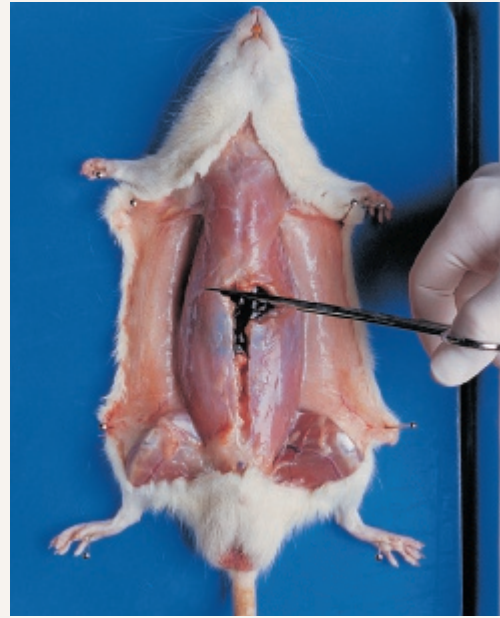

Figure 2.2 Rat dissection: Opening the ventral body cavity. Making lateral cuts at the base of the rib cage.

through the rib cage to view the contents of the thoracic cavity.

Activity 5

Examining the Ventral Body Cavity

1. Examine the structures of the thoracic cavity, starting with the most superficial structures and working deeper. As you work, refer to the figure that shows the superficial thoracic organs (Figure 2.3).

Thymus: An irregular mass of glandular tissue overlying the heart.

With a probe, push the thymus to the side to view the heart.

Heart: Medial oval structure that lies between the lungs.

Lungs: Lateral to the heart on either side.

Now observe the throat region to identify the trachea.

Trachea: Tubelike “windpipe” running medially down the throat; part of the respiratory system.

Follow the trachea into the thoracic cavity. Notice where it divides into two branches—these are the bronchi.

Bronchi: Two passageways that plunge laterally into the tissue of the two lungs.

To expose the esophagus, push the trachea to one side.

Esophagus: A food chute; the part of the digestive system that transports food from the pharynx (throat) to the stomach.

Diaphragm: A thin muscular membrane attached to the inferior boundary of the rib cage.

Follow the esophagus through the diaphragm to its junction with the stomach.

Stomach: A curved organ important in food digestion and temporary food storage.

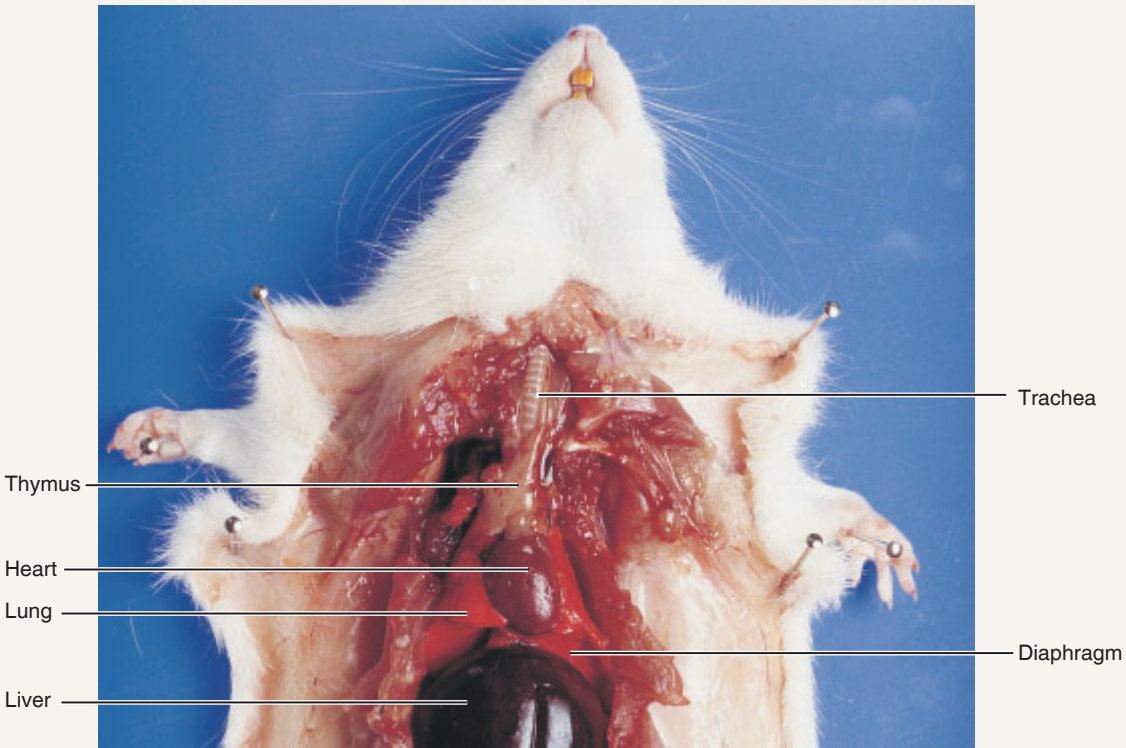2. Examine the superficial structures of the abdominopelvic cavity. Lift the *greater omentum*, an apronlike membrane fold that covers the abdominal organs. Continuing from the stomach, trace the rest of the digestive tract (Figure 2.3b).

Small intestine: A long coiled tube connected to the stomach and ending just before the saclike cecum.

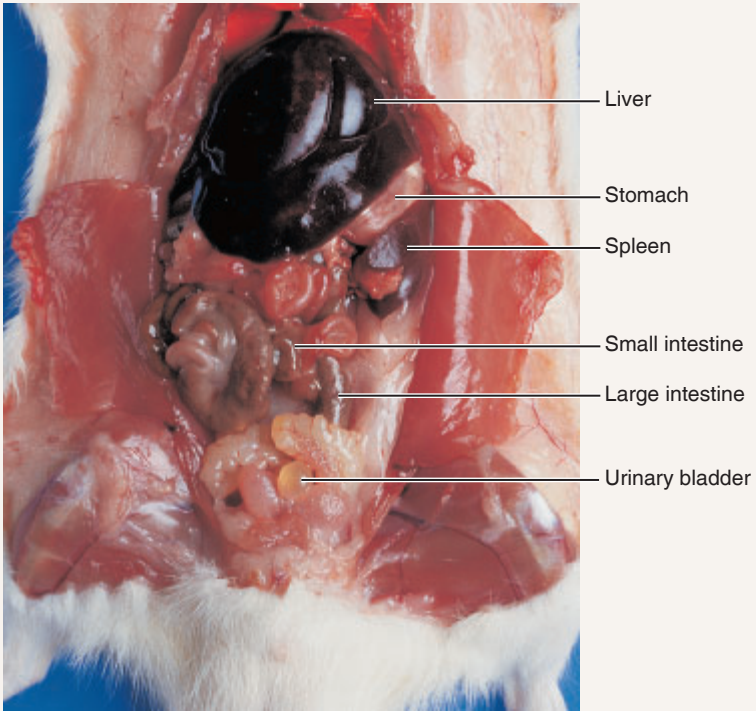
Large intestine: A large muscular tube coiled within the abdomen.

Follow the course of the large intestine, which begins at the saclike cecum, frames the small intestine, and ends at the rectum. Notice that it is partially covered by the urinary bladder.

Rectum: Terminal part of the large intestine; continuous with the anal canal.



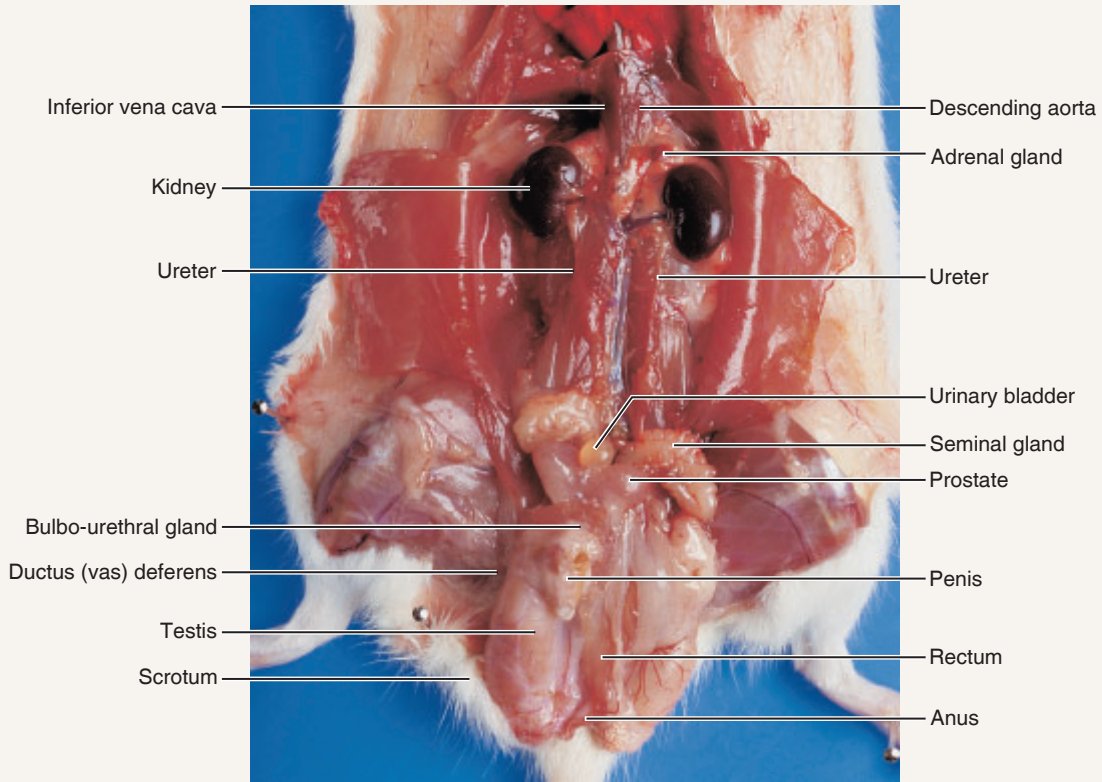
(a) Thoracic cavity



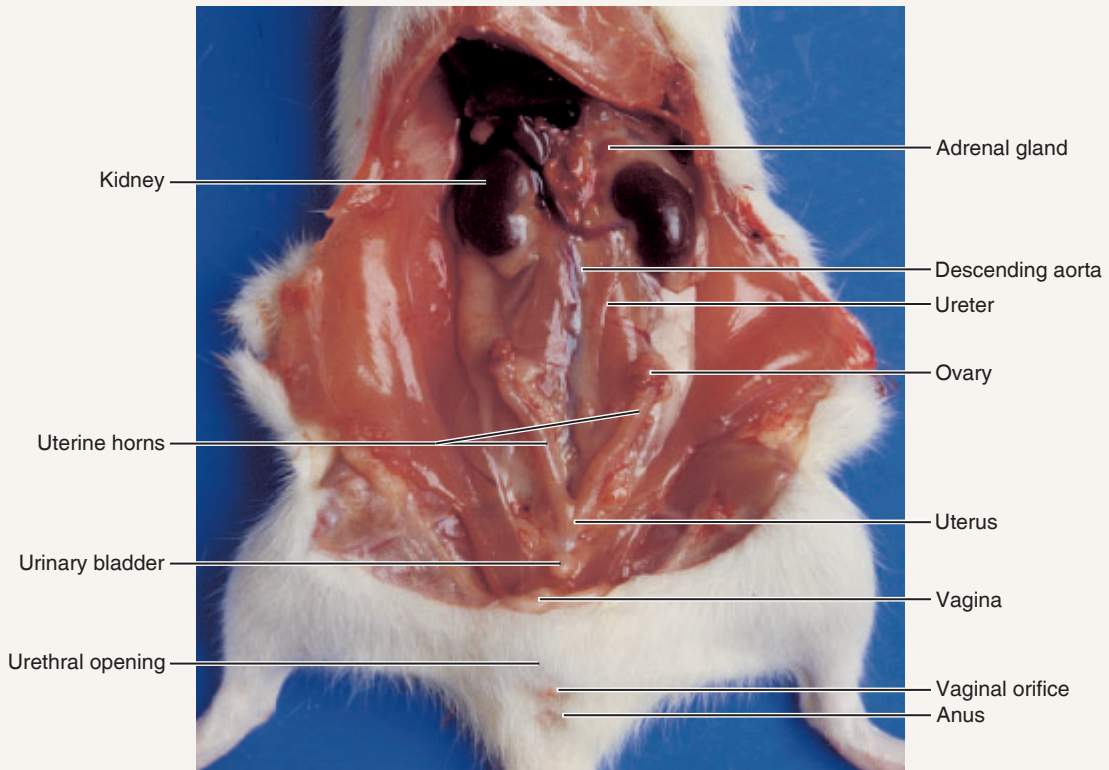(b) Abdominal cavity

Figure 2.3 Rat dissection: Superficial organs of the thoracic and abdominal cavities.

Text continues on next page. →



(a) Male



(b) Female

Figure 2.4 Rat dissection: Deeper organs of the abdominopelvic cavity.

Anus: The opening of the digestive tract (anal canal) to the exterior.

Now lift the small intestine with the forceps to view the mesentery.

Mesentery: A delicate membrane; suspends the small intestine in the abdominal cavity. Notice that it is heavily invested with blood vessels.

Locate the remaining abdominal structures.

Pancreas: A diffuse gland; rests posterior to and between the first portion of the small intestine and the stomach. You will need to lift the stomach to view the pancreas.

Spleen: A dark red organ curving around the left lateral side of the stomach; an organ of the lymphatic system.

Liver: Large and brownish red; the most superior organ in the abdominal cavity, directly inferior to the diaphragm.

3. To locate the deeper structures of the abdominopelvic cavity, move the stomach and the intestines to one side with the probe. Refer to **Figure 2.4** as you work.

Examine the posterior wall of the abdominal cavity to locate the two kidneys.

Kidneys: Bean-shaped organs; secured to the posterior wall of the body trunk.

Adrenal glands: Small glands that sit on the top of each kidney; considered part of the endocrine system.

Carefully strip away part of the membrane covering a kidney with forceps. Attempt to follow the course of one of the ureters to the bladder.

Ureter: Tube running from the indented region of a kidney to the urinary bladder (see also Figure 2.4b).

Urinary bladder: The sac in the pelvis that serves as a reservoir for urine.

4. In the midline of the body cavity lying between the kidneys are the two principal abdominal blood vessels.

Inferior vena cava: The large vein that returns blood to the heart from the lower regions of the body.

Descending aorta: Deep to the inferior vena cava; the largest artery of the body; carries blood away from the heart.

5. You will perform only a cursory examination of reproductive organs. First determine whether the animal is a male or female. Observe the ventral body surface beneath the tail. If a saclike scrotum and a single body opening are visible, the animal is a male. If three body openings are present, it is a female. (See Figure 2.4.)

Male Rat

Make a shallow incision into the **scrotum**. Loosen and lift out the oval **testis**. Pull very gently on the testis to identify the slender **ductus deferens**, or sperm duct, which carries sperm from the testis superiorly into the abdominal cavity and joins with the urethra. The urethra runs through the penis of the male and carries both urine and sperm out of the body. Identify the **penis**, extending from the bladder to the ventral body wall. You may see other glands of the male reproductive system (Figure 2.4a), but you don't need to identify them at this time.

Female Rat

Inspect the pelvic cavity to identify the Y-shaped **uterus** lying against the dorsal body wall and beneath the bladder (Figure 2.4b). Follow one of the uterine horns superiorly to identify an **ovary**, a small oval structure at the end of the uterine horn. (The rat uterus is quite different from the uterus of a human female, which is a single-chambered organ about the size and shape of a pear.) The inferior undivided part of the rat uterus is continuous with the vagina, which leads to the body exterior. Identify the **vaginal orifice** (external vaginal opening).

Activity 6

Examining the Human Torso Model

1. Examine a human torso model to identify the organs listed below. If a torso model is not available, refer to **Figure 2.5** for part of this exercise. You'll need to remove some organs on the model to see deeper organs.

Dorsal body cavity: Brain, spinal cord

Thoracic cavity: Heart, lungs, bronchi, trachea, esophagus, diaphragm, thyroid gland

Abdominopelvic cavity: Liver, gall bladder, stomach, pancreas, spleen, small intestine, large intestine, rectum, kidneys, ureters, bladder, adrenal gland, uterus, descending aorta, inferior vena cava

2. Before continuing, identify each organ with a leader line in Figure 2.5.

3. Assign all of the structures listed above to one of the following organ system categories.

Digestive: _____

Urinary: _____

Text continues on next page. →

Cardiovascular: _____

Endocrine: _____

Reproductive: _____

Respiratory: _____

Lymphatic: _____

Nervous: _____

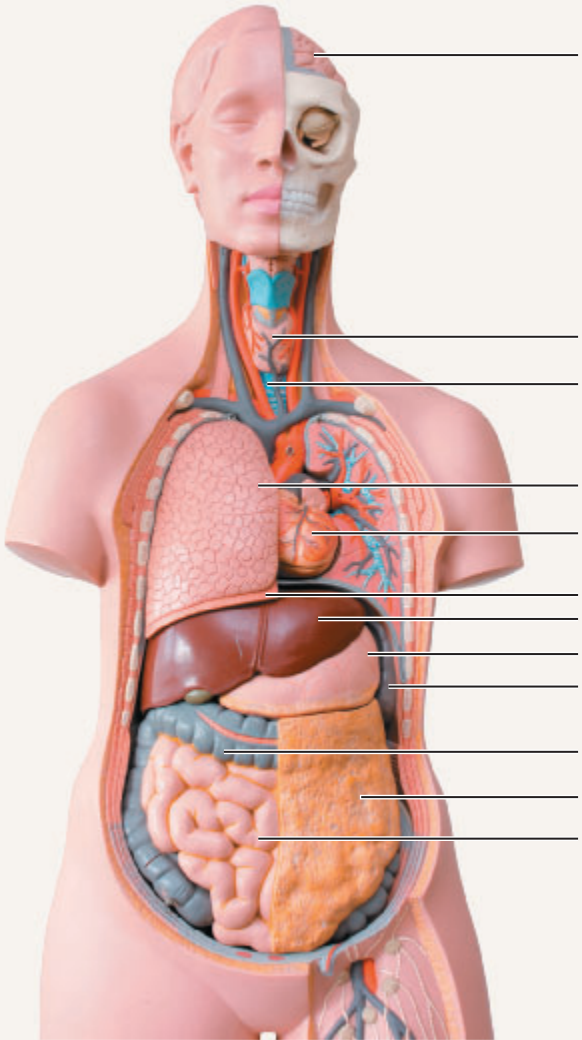


Figure 2.5 Human torso model.

EXERCISE
2

REVIEW SHEET

Organ Systems Overview

Name _____ Lab Time/Date _____

1. Using the key, indicate which body system matches each of the following descriptions.

Key:	cardiovascular	integumentary	nervous	skeletal
	digestive	lymphatic	reproductive	urinary
	endocrine	muscular	respiratory	

- _____ 1. rids the body of nitrogen-containing wastes
- _____ 2. is affected by removal of the adrenal gland
- _____ 3. protects and supports body organs; provides a framework for muscular action
- _____ 4. includes arteries and veins
- _____ 5. composed of glands that secrete hormones
- _____ 6. external body covering
- _____ 7. houses cells involved in the body's immune response
- _____ 8. breaks down ingested food into its absorbable units
- _____ 9. loads oxygen into the blood
- _____ 10. uses blood as a transport vehicle
- _____ 11. generates body heat and provides for movement of the body as a whole
- _____ 12. key organs include the brain and spinal cord
- _____ and _____ 13. necessary for conception and childbearing
- _____ 14. is damaged when you fall and scrape your knee

2. Using the above key, choose the *organ system* to which each of the following sets of organs or body structures belongs:

- | | |
|---|----------------------------------|
| _____ 1. lymph nodes, spleen, lymphatic vessels | _____ 4. trachea, bronchi, lungs |
| _____ 2. bones, cartilages, ligaments | _____ 5. uterus, ovaries, vagina |
| _____ 3. thyroid, pancreas, pituitary gland | _____ 6. arteries, veins, heart |

18 Review Sheet 2


3. Name the cells that are produced by the testes and ovaries. _____


4. List the four primary tissue types. _____


5. Explain why an artery is an organ. _____

6. Name the two main organ systems that communicate within the body to maintain homeostasis. Briefly explain their different control mechanisms. _____

7. Explain the role that the skeletal system plays in facilitating cardiovascular system function. _____

8.  Untreated diabetes mellitus can lead to a condition in which the blood is more acidic than normal. Name two organ systems that play the largest role in compensating for acid-base imbalances. _____

9.  The mother of a child scheduled to receive a thymectomy (removal of the thymus gland) asks you whether there will be any side effects from the removal of the gland. Which two organ systems would you mention in your explanation? _____

10.  Individuals with asplenia are missing their spleen or have a spleen that doesn't function well. It is recommended that these patients talk to their doctor about vaccines that are indicated for their health condition. Explain how this recommendation correlates to their chronic health condition. _____

The Cell—Anatomy and Division

Materials

- Three-dimensional model of the “composite” animal cell or chart of cell anatomy
- Chenille sticks (pipe cleaners) and chalk
- Three-dimensional models of mitotic stages
- Demonstration area:

Station 1: Compound microscopes set up and focused on slides of four tissue samples for student observation (simple squamous epithelium [AgNO₃ stain], teased smooth muscle, human blood cell smear, and sperm)

Station 2: Compound microscopes set up and focused with pointers on whitefish blastula cells exhibiting the major phases of mitosis (prophase, metaphase, anaphase, and telophase)

Learning Outcomes

- Name, identify, and list the major function(s) of the various cell structures.
- Compare and contrast specialized cells to the generalized cells.
- Define interphase, mitosis, and cytokinesis, and identify and describe the stages of mitosis.

The cell is the structural and functional unit of all living things. Differences in size, shape, and internal makeup of the cells of the human body reflect their specific roles in the body. Still, cells do have many common features and functions. For example, all cells maintain their boundaries, metabolize and digest nutrients, dispose of wastes, grow and reproduce, move, and respond to a stimulus. Most of these functions are considered in detail in later exercises. This exercise begins by describing the structural similarities typical of the “composite,” or “generalized,” cell and then considers the function of cell reproduction (cell division).

Anatomy of the Composite Cell

All cells have three major regions: **nucleus**, **plasma membrane**, and **cytoplasm**. The nucleus is typically a round or oval structure near the center of the cell. It is surrounded by cytoplasm, which in turn is enclosed by the plasma membrane. Within the cytoplasm, even smaller cell structures—organelles—have been identified. **Figure 3.1** is a diagram of the internal structure of the composite cell.

Nucleus

The nucleus is often described as the control center of the cell and is necessary for cell reproduction. The nucleus is the site of the genes, or genetic material—DNA—and when the cell is not dividing, that genetic material is in a threadlike form called **chromatin**. When a cell is dividing to form daughter cells, the chromatin coils and condenses to form rodlike bodies called **chromosomes**—much in the way a stretched spring becomes shorter and thicker when it is released.

The nucleus also contains one or more small round bodies, called **nucleoli**. The nucleoli are assembly sites for ribosomes that are particularly abundant in the cytoplasm.

The nucleus is bound by a double-layered porous membrane, the **nuclear envelope**. The nuclear envelope is similar to other cellular membranes, but is distinguished by its large *nuclear pores*, which permit large molecules like protein and RNA molecules to pass easily.

Activity 1

Identifying Parts of a Cell

Locate the nuclear envelope, chromatin, nucleoli, and nuclear pores in Figure 3.1.

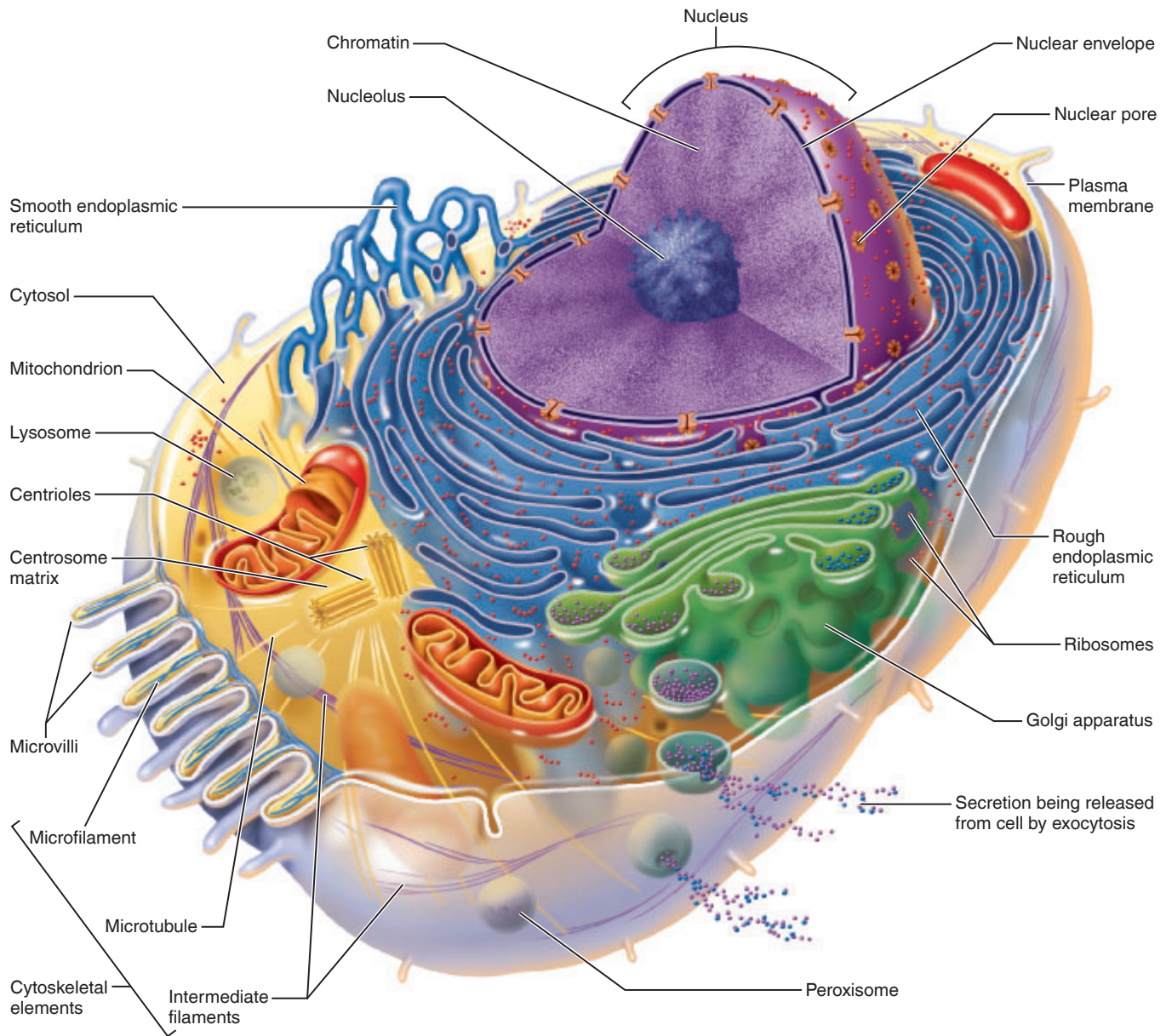


Figure 3.1 Structure of the generalized cell.

Plasma Membrane

The **plasma membrane** separates cell contents from the surrounding environment. Essentially, the membrane has a double-layered lipid structure that the protein molecules (some with attached carbohydrate groups) float in (**Figure 3.2**). Occasional cholesterol molecules dispersed in the fluid phospholipid bilayer help to stabilize it.

Besides protecting the cell, the plasma membrane determines which substances may enter or leave the cell and in what quantity. In some cells the membrane has **microvilli**, tiny fingerlike projections that greatly increase the surface area of the cell.

Activity 2

Identifying Components of a Plasma Membrane

Identify the phospholipid and protein portions of the plasma membrane in Figure 3.2. Also locate the carbohydrate side chains and cholesterol molecules. Identify the microvilli in the figure of the generalized cell (Figure 3.1).

Cytoplasm and Organelles

The cytoplasm is the cell contents outside the nucleus and is the major site of most activities carried out by the cell. Suspended

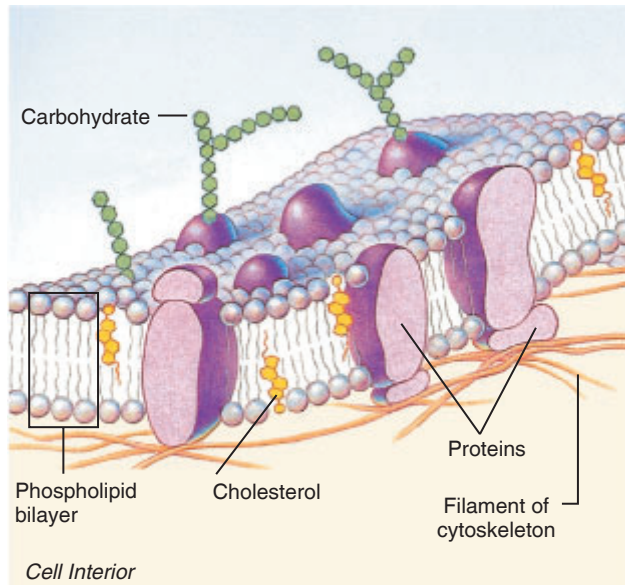


Figure 3.2 Structure of the plasma membrane.

in the **cytosol**, the fluid part of the cytoplasm, are tiny structures called **organelles** (literally, “small organs”). The organelles (**Table 3.1**) are the metabolic machinery of the cell, organized to carry out specific activities for the cell as a whole.

The cell cytoplasm contains various other substances and structures, including stored foods (glycogen granules and lipid droplets), pigment granules, crystals of various types, water vacuoles, and ingested foreign materials. But these are not part of the active metabolic machinery of the cell and are therefore called **inclusions**.

Activity 3

Locating Organelles

Read about the organelles and their structure and function in Table 3.1, and then be sure you can locate the organelles in the figure depicting the generalized cell (Figure 3.1).

Activity 4

Examining the Cell Model

Once you have located all of the structures in the figure of the generalized cell (Figure 3.1), examine the cell model (or cell chart) to repeat and reinforce your identifications. Try not to look at the figure as you make your identifications.

Table 3.1 Cytoplasmic Organelles


Organelle	Location and function
Ribosomes	Tiny spherical bodies consisting of RNA and protein; actual sites of protein synthesis; seen floating free or attached to a membranous structure (the rough ER) in the cytoplasm
Endoplasmic reticulum (ER)	Membranous system of tubules that extends throughout the cytoplasm; two varieties: (1) rough ER—studded with ribosomes (tubules of the rough ER provide an area for proteins made on the ribosomes to be transported to other cell areas) and (2) smooth ER—a site of steroid and lipid synthesis, lipid metabolism, and drug detoxification (no protein synthesis–related function)
Golgi apparatus	Stack of flattened sacs with swollen ends and associated small vesicles; found close to the nucleus; plays a role in packaging proteins or other substances that will be exported from the cell or incorporated into the plasma membrane and in packaging lysosomal enzymes
Lysosomes	Various-sized membranous sacs containing digestive enzymes including acid hydrolases; digest worn-out cell organelles and foreign substances that enter the cell; if ruptured, they have the capacity to totally destroy the cell and are for this reason referred to as “suicide sacs”
Peroxisomes	Small lysosome-like membranous sacs containing oxidase enzymes that detoxify alcohol, free radicals, and other harmful chemicals
Mitochondria	Generally rod-shaped bodies with a double-membrane wall; inner membrane is shaped into folds, or cristae; contain enzymes that oxidize foodstuffs to produce cellular energy (ATP); often referred to as “powerhouses of the cell”
Centrioles	Paired, cylindrical bodies that lie at right angles to each other close to the nucleus; direct the formation of the mitotic spindle during cell division; form the bases of cilia and flagella
Cytoskeletal elements: microtubules, intermediate filaments, and microfilaments	Form an internal scaffolding called the <i>cytoskeleton</i> ; provide cellular support; function in intracellular transport; microtubules form the internal structure of the centrioles and help determine cell shape; intermediate filaments, which are stable elements made up of a variety of proteins, resist mechanical forces acting on cells; microfilaments are formed largely of actin, a contractile protein, and are thus important in cell mobility, particularly in muscle cells

Activity 5


Observing Differences and Similarities in Cell Structure

1. Go to station 1 of the demonstration area, and examine the slides of simple squamous epithelium, sperm, human blood, and teased smooth muscle cells.
2. Observe each slide under the microscope carefully, noting similarities and differences in the four kinds of cells. Notice the cell shape and position of the nucleus in each case. When you look at the human blood smear, direct your attention to the red blood cells, the pink-stained cells that are most numerous. Sketch your observations in the circles below.
3. How do these four cell types differ in shape?


How might cell shape affect cell function?




Simple squamous epithelium



Sperm cells



Human red blood cells



Teased smooth muscle cells

Which cells have visible projections?

How do these projections relate to the function of these cells?

Do any of these cells lack a plasma membrane? _____

A nucleus? _____

Were you able to observe any of the organelles in these cells?

_____ Why or why not? _____

Cell Division: Mitosis and Cytokinesis

The cell cycle is the series of changes that a cell goes through from the time it is formed until it reproduces. It includes two stages—**interphase**, the longer period when the DNA and centrioles duplicate and the cell grows and carries out its usual activities (**Figure 3.3a**), and **cell division**, when the cell reproduces itself by dividing (**Figure 3.3b–f**).

Cell division in human cells consists of a series of events collectively called mitosis and cytokinesis. **Mitosis** is nuclear division; **cytokinesis** is the division of the cytoplasm, which begins after mitosis is nearly complete. Although mitosis is usually accompanied by cytokinesis, sometimes the cytoplasm does not divide. This results in cells that are binucleate or multinucleate. This is relatively common in the human liver and during embryonic development of skeletal muscle cells.

The products of **mitosis** are two daughter nuclei that are genetically identical to the mother nucleus. The function of *mitotic* cell division in the body is to increase the number of cells for growth and repair.

Prophase (**Figure 3.3b and c**): As nuclear division begins, the chromatin threads coil and shorten to form densely staining, short, barlike **chromosomes**. By the middle of prophase,

the chromosomes are obviously double-stranded structures (each strand is a **sister chromatid**) connected by a buttonlike body called a **centromere**. The centrioles separate from one another and direct the assembly of a system of microtubules called the **mitotic spindle**. The spindle acts as a scaffolding the chromosomes attach to and are moved along during later mitotic stages. Meanwhile, the nuclear envelope and the nucleolus break down and disappear.

Metaphase (**Figure 3.3d**): In this brief stage, the chromosomes align along the metaphase plate, or the equator of the spindle.

Anaphase (**Figure 3.3e**): During anaphase, the centromeres split, and the chromatids now become chromosomes in their own right. The chromosomes separate from one another and move slowly toward opposite ends of the cell with their “arms” dangling behind them. Anaphase is complete when poleward movement ceases.

Telophase (**Figure 3.3f**): Similar to prophase in reverse. The chromosomes uncoil and resume the chromatin form, the spindle breaks down and disappears, a nuclear envelope forms around each chromatin mass, and nucleoli appear in the daughter nuclei. Mitosis is now ended.

3

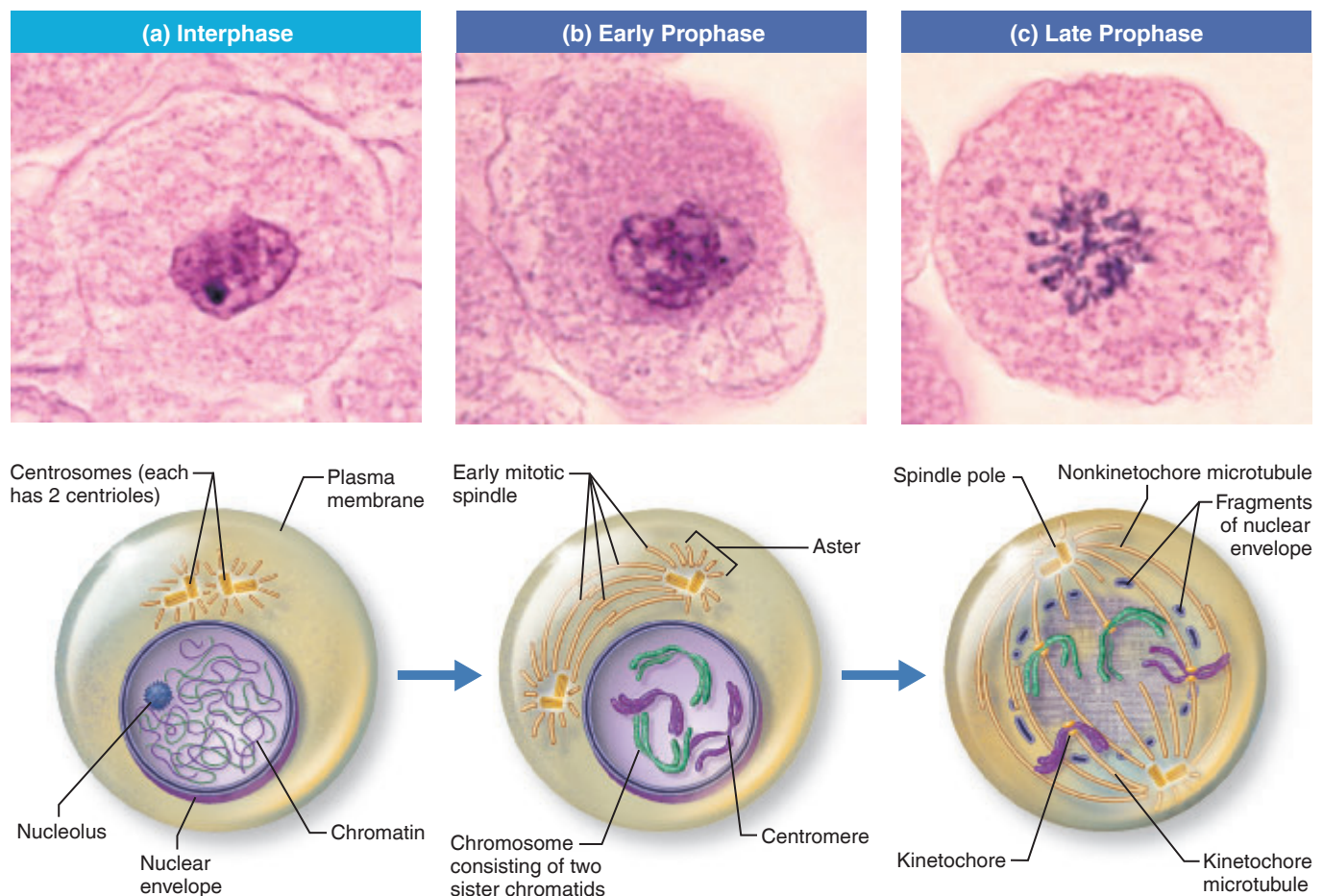


Figure 3.3 The interphase cell and the events of cell division. The cells shown are from an early embryo of a whitefish. Photomicrographs are above; corresponding diagrams are below. (*Figure continues on page 24.*)

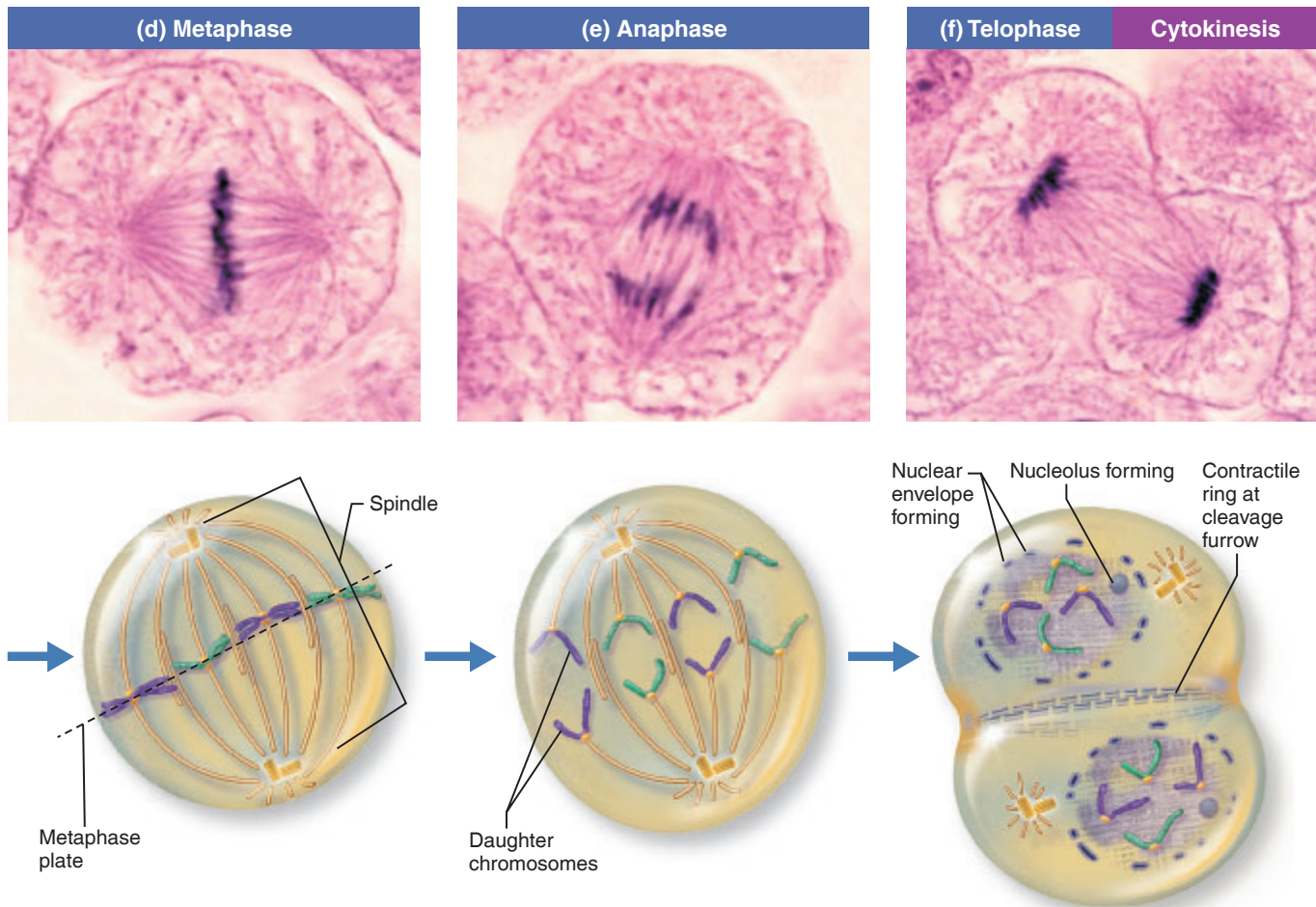


Figure 3.3 (continued) The events of cell division.

Cytokinesis typically begins during late anaphase and continues through and beyond telophase (Figure 3.3f). In animal cells, a *cleavage furrow* begins to form and eventually pinches the cells apart. Once formed, the daughter cells grow and carry out the normal spectrum of metabolic processes until it is their turn to divide.

Examine the slides carefully, identifying the four mitotic phases and the process of cytokinesis. Compare your observations with the figure that illustrates these processes (Figure 3.3).

Activity 6

Identifying the Mitotic Stages

1. Use the three-dimensional models of dividing cells to identify each of the mitotic phases illustrated in Figure 3.3.
2. Go to station 2 of the demonstration area, where slides of whitefish blastulas are set up for your microscopic study of mitosis. The cells of each blastula (a stage of embryonic development consisting of a hollow ball of cells) are at approximately the same mitotic stage, so it is necessary to observe more than one blastula to view all the mitotic stages. You can think of a blastula as a soccer ball in which each of the multisided leather pieces making up the ball's surface represents an embryonic cell.

Activity 7

Creating Mitotic Figures

1. Obtain a packet of chenille sticks and a piece of chalk from the supply area, and bring them to your bench.
2. Using the chalk, draw three representations of mitotic spindles on the bench top. Then bend the chenille sticks as necessary to create the typical appearance and location of chromosomes in (1) prophase, (2) metaphase, (3) anaphase, and (4) telophase by placing them on your spindle drawings.
3. Have your instructor check your mitotic figures before cleaning up your bench top.

EXERCISE
3

REVIEW SHEET

The Cell—Anatomy and Division

Name _____ Lab Time/Date _____

Anatomy of the Composite Cell

1. Define the following:

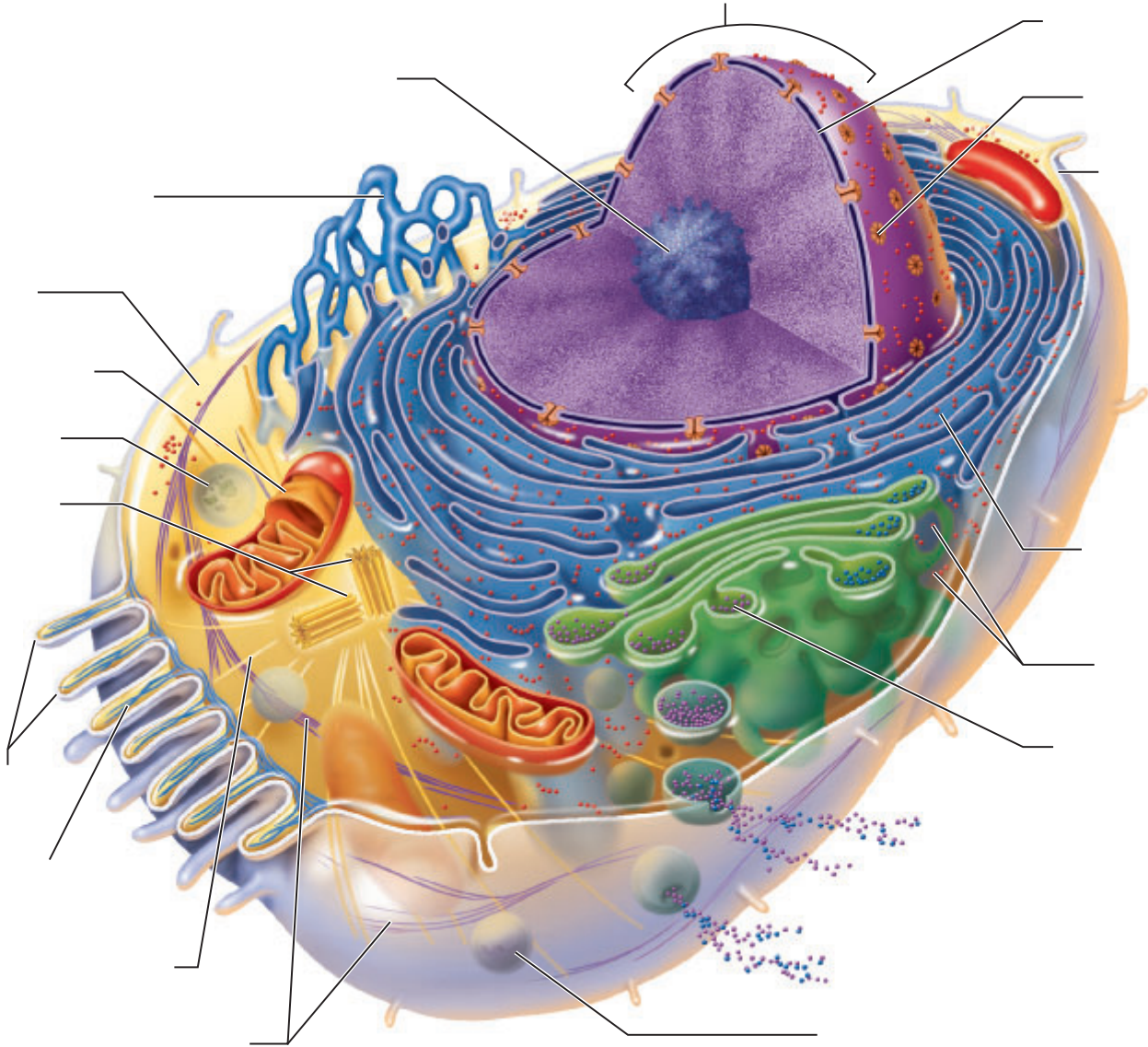
organelle: _____

cell: _____

2. Identify the following cell structures:

- _____ 1. external boundary of cell; regulates flow of materials into and out of the cell
- _____ 2. contains digestive enzymes of many varieties; "suicide sac" of the cell
- _____ 3. scattered throughout the cell; major site of ATP synthesis
- _____ 4. slender extensions of the plasma membrane that increase its surface area
- _____ 5. stored glycogen granules, crystals, pigments; present in some cell types
- _____ 6. membranous system consisting of flattened sacs and vesicles; packages proteins for export
- _____ 7. control center of the cell; necessary for cell division and cell life
- _____ 8. rod-shaped bodies that direct the formation of the mitotic spindle
- _____ 9. dense, darkly staining nuclear body; packaging site for ribosomes
- _____ 10. contractile elements of the cytoskeleton
- _____ 11. membranous system that has "rough" and "smooth" varieties
- _____ 12. attached to membrane systems or scattered in the cytoplasm; synthesize proteins
- _____ 13. threadlike structures in the nucleus; contain genetic material (DNA)
- _____ 14. site of free radical detoxification

3. Label the cell structures using the leader lines provided.



Differences and Similarities in Cell Structure

4. For each of the following cell types, list (a) *one* important *structural* characteristic you observed in the laboratory and (b) the *function* that the structure complements or ensures.

squamous epithelium a. _____

b. _____

sperm a. _____

b. _____

smooth muscle a. _____

b. _____

red blood cells a. _____

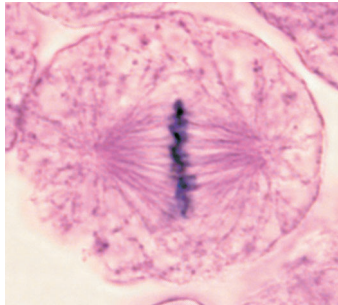
b. _____

Cell Division: Mitosis and Cytokinesis

5. Identify the four phases of mitosis shown in the following photomicrographs, and select the events from the key that correctly identify each phase. On the appropriate answer line, write the letters that correspond to these events.

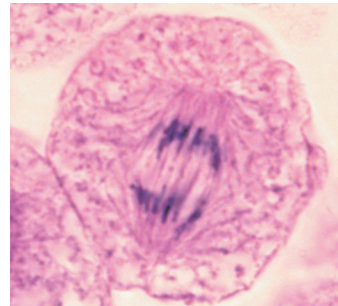
Key:

- Chromatin coils and condenses, forming chromosomes.
- The chromosomes (chromatids) are V-shaped.
- The nuclear envelope re-forms.
- Chromosomes stop moving toward the poles.
- Chromosomes line up in the center of the cell.
- The nuclear envelope fragments.
- The mitotic spindle begins to form.



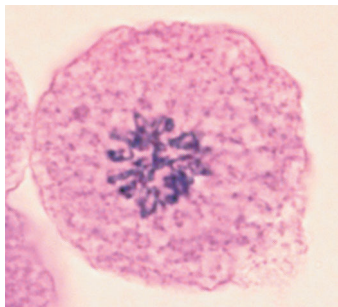
1. Phase: _____

Events: _____



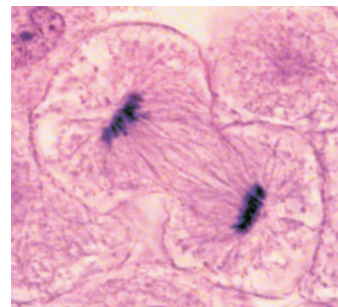
2. Phase: _____

Events: _____



3. Phase: _____

Events: _____



4. Phase: _____

Events: _____


6. What is the function of mitotic cell division? _____

7. Describe the events that occur during interphase.


8. Complete or respond to the following statements:


Division of the 1 is referred to as mitosis. Cytokinesis is division of the 2. The major structural difference between chromatin and chromosomes is that the latter are 3. Chromosomes attach to the spindle fibers by undivided structures called 4. If a cell undergoes mitosis but not cytokinesis, the product is 5. The structure that acts as a scaffolding for chromosomal attachment and movement is called the 6. 7 is the period of cell life when the cell is not involved in division. Three cell populations in the body that do not routinely undergo cell division are 8, 9, and 10.

- 1. _____
- 2. _____
- 3. _____
- 4. _____
- 5. _____
- 6. _____
- 7. _____
- 8. _____
- 9. _____
- 10. _____

9.  Plasma cells are key to the immune response because they secrete antibodies. Given that antibodies are made of protein, which membrane-enclosed cell organelle would you expect the plasma cells to have in abundance?

Why? _____

10.  Name which organelle you would expect to play the largest role in decomposition of the human body. Why?

11.  Some antifungal medications work by blocking DNA synthesis in the fungal cell. Describe where in the cell cycle such a medication would halt the fungal cell and the consequences of this early termination of the cycle.

Cell Membrane Transport Mechanisms

Materials

Diffusion Experiment 1:

- Forceps
- Petri dishes (2) containing 12 ml of 1.5% agar-agar
- 3.5% methylene blue solution (approximately 0.1 M)
- 1.6% potassium permanganate solution (approximately 0.1 M)
- Millimeter-ruled graph paper
- Medicine dropper

Diffusion Experiment 2:

- Four dialysis sacs
- 15-ml graduated cylinders
- Four beakers (250 ml)
- Distilled water
- 40% glucose solution
- Fine twine or dialysis tubing clamps
- 10% NaCl solution
- 40% sucrose solution
- Laboratory balance
- Hot plate and large beaker for water bath
- Benedict's solution in dropper bottle
- Four test tubes in racks, test tube holder
- Wax marker
- Small syringes (without needles)
- Silver nitrate (AgNO_3) in dropper bottle
- Lugol's iodine solution in dropper bottle
- Demonstration area: Three microscopes with blood cells suspended in:
 1. Physiological saline
 2. 1.5% saline
 3. Distilled water

Filtration:

- Flask
- Filter paper, funnel
- Solution containing a mixture of uncooked starch, powdered charcoal, and copper sulfate (CuSO_4)
- Lugol's iodine solution in dropper bottle

Learning Outcomes

- Describe processes that move substances across the plasma membrane and indicate the driving force for each.
- Determine which way substances will move passively through a selectively permeable membrane (given appropriate information on concentration differences).

The plasma membrane is selective about what passes through it. It allows nutrients to enter the cell but keeps out undesirable substances. At the same time, the plasma membrane keeps valuable cell proteins and other substances within the cell, and allows excreta, or wastes, to pass to the exterior. This property is known as **selective, or differential, permeability**. Transport through the plasma membrane occurs in two basic ways. In **active processes**, the cell provides energy (ATP) to power the transport process. In the other, **passive processes**, the transport process is driven by particle concentration or pressure differences. In this exercise, we will observe several examples of passive processes.

Passive Processes

The two important types of passive membrane transport are *diffusion* and *filtration*. Diffusion is an important means of transport for every cell in the body. By contrast, filtration usually occurs only across capillary walls. Here we will consider diffusion only.

Diffusion

Recall that all molecules possess *kinetic energy* and are in constant motion. As molecules move about randomly, they collide and ricochet off one another, changing direction with each collision. In general, the smaller the particle, the more kinetic energy it has and the faster it moves.

When a **concentration gradient** (difference in concentration) exists, the net effect of this random molecular movement is that the molecules eventually become evenly distributed throughout the environment, that is, the process called diffusion occurs. Hence, **diffusion** is the movement of molecules from a region of their higher concentration to a region of their lower concentration. Its driving force is the kinetic energy of the molecules themselves.

In general, molecules diffuse passively through the plasma membrane if they are small enough to pass through its pores or if they can dissolve in the lipid portion of the membrane as CO_2 and O_2 can. The unassisted diffusion of solutes (particles dissolved in water) through a semipermeable membrane is called **simple diffusion**. The diffusion of water through a semipermeable membrane is called **osmosis**.

In general, molecules in a warm environment diffuse more quickly than those that are cooler; light molecules move more quickly than heavy ones; and diffusion through a nondense medium (such as water) occurs faster than diffusion through a denser or more viscous substance (such as agar gel). The next activity examines these relationships in the diffusion of two dyes.

(Text continues on page 33.)

Activity 1

Observing Diffusion of Dye Through Agar Gel

1. Obtain a Petri dish containing agar gel, millimeter-ruled graph paper, dropper bottles of methylene blue (molecular weight = 320 g/mole) and potassium permanganate (molecular weight = 158 g/mole) stain, and a medicine dropper. Bring these items to your bench.
2. Place the Petri dish on the graph paper.
3. Create a well in the center of each section using the medicine dropper (**Figure 4.1a**). To do this, squeeze the bulb of the medicine dropper, and push the tip of the dropper down into the agar. Release the bulb as you slowly pull the dropper out of the agar. This should remove an agar plug, leaving a well in the agar that extends all the way down to the bottom of the Petri dish.
4. Carefully fill one well with the methylene blue solution and the other with potassium permanganate solution (Figure 4.1b).

Record the time: _____.

5. At 15-minute intervals, measure the distance the dye has diffused from *each* solution source by measuring the diameter of the dye using the graph paper. Continue these observations for 1 hour, and record the results in the **Activity 1 chart**.

Calculate the rate of diffusion of the potassium permanganate molecules in millimeters per minute (mm/min), and record.


_____ mm/min

Calculate the rate of diffusion of the methylene blue molecules in mm/min, and record.


_____ mm/min

Activity 1: Diffusion of Dye Through Agar Gel

Time (min)	Diameter of methylene blue (mm) at room temperature	Diameter of potassium permanganate (mm) at room temperature
15		
30		
45		
60		



(a)



(b)

Figure 4.1 Setup for comparing the diffusion rates of molecules of methylene blue and potassium permanganate through an agar gel.

Which dye diffused more rapidly? _____

What is the relationship between molecular weight and rate of molecular movement (diffusion)?

Why did the dye molecules move?

What would be the effect of heating on the rate of diffusion of the dyes? _____

In molecular terms, what is the basis of this effect?

Activity 2

Observing Diffusion Through Nonliving Membranes

This experiment provides information on the diffusion of water and solutes through semipermeable membranes, which may be applied to the study of membrane transport in living cells.

Dialysis sacs are selectively permeable membranes with pores of a particular size. The selectivity of living membranes depends on more than just pore size, but using the dialysis sacs will allow you to examine selectivity due to this factor.

1. Obtain four dialysis sacs, a small syringe, a graduated cylinder, a wax marker, fine twine or dialysis tubing clamps, and four beakers (250 ml). Number the beakers 1 to 4 with the wax marker, and fill beakers 1, 3, and 4 halfway with distilled water. To beaker 2, add 40% glucose solution (**Figure 4.2**).

2. Prepare the dialysis sacs one at a time. Using the syringe, half fill each with 10 ml of the specified liquid: 40% glucose solution for sacs 1 and 2; 10% NaCl for sac 3; and sucrose solution for sac 4 (see Figure 4.2). Press out the air, fold over the open end of the sac, and tie it securely with fine twine or clamp it (Figure 4.2). Before proceeding to the next sac, rinse it under the tap and quickly and carefully blot the sac dry by rolling it on a paper towel. Weigh it with a laboratory balance. Record the weight, and then drop the sac into the corresponding beaker. Be sure the sac is completely covered by the beaker solution, adding more solution if necessary.

- Sac 1: 40% glucose solution. Weight: _____ g
- Sac 2: 40% glucose solution. Weight: _____ g
- Sac 3: 10% NaCl solution. Weight: _____ g
- Sac 4: 40% sucrose solution. Weight: _____ g

Allow sacs to remain undisturbed in the beakers for 1 hour. (Use this time to continue with other experiments.)

3. After an hour, boil a beaker of water on the hot plate. Obtain the supplies you will need to determine your experimental results: dropper bottles of Benedict's solution, silver nitrate solution, and Lugol's iodine, a test tube rack, four test tubes, and a test tube holder.

4. Quickly and gently blot sac 1 dry and weigh it. (*Note:* Do not squeeze the sac during the blotting process.)

Weight of sac 1: _____ g

Has there been any change in weight? _____

Conclusions: _____

Place 5 drops of Benedict's solution in each of two test tubes. Put 2 ml of the fluid from beaker 1 into one test tube and 2 ml of the sac fluid into the other. Mark the tubes for identification, and then place them in the beaker containing boiling water. Boil test tubes for 2 minutes then cool them slowly. (See **Table 4.1** to interpret test results.)

Text continues on next page. →

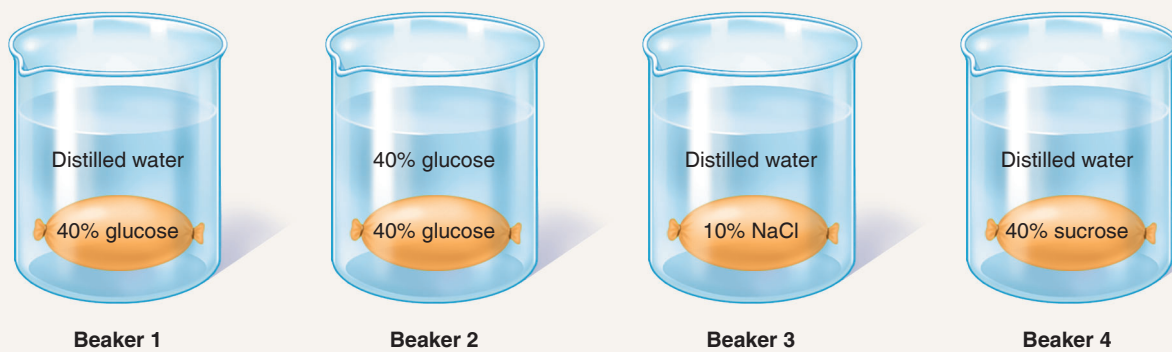


Figure 4.2 Setup for observing diffusion through nonliving membranes.

Table 4.1 Reagent Testing Solutions

Testing solution	Positive result
Benedict's solution	A green, yellow, or rusty red color indicates the presence of glucose
Silver nitrate	A white precipitate or cloudiness indicates the presence of salt
Lugol's iodine	A blue-black color indicates the presence of starch

Was glucose still present in the sac? _____

Was glucose present in the beaker? _____

Conclusions: _____

5. Blot gently and weigh sac 2: _____ g

Was there any change in weight? _____

With 40% glucose in the sac and 40% glucose in the beaker, would you expect to see any net movements of water (osmosis) or of glucose molecules (simple diffusion)?

_____ Why or why not? _____

6. Blot gently and weigh sac 3: _____ g

Was there any change in weight? _____

Conclusions: _____

Take a 3-ml sample of beaker 3 solution, and put it in a clean test tube. Add a drop of silver nitrate. (See Table 4.1 to interpret test results.)

Results: _____

Conclusions: _____

7. Blot gently and weigh sac 4: _____ g

Was there any change in weight? _____

Take a 1-ml sample of beaker 4 solution, and put the test tube in boiling water in a hot water bath. Add 5 drops of Benedict's solution to the tube, and boil for 5 minutes. Benedict's solution detects the presence of glucose, a hydrolysis product of sucrose. (See Table 4.1 to interpret test results.)

Did sucrose diffuse from the sac into the bath water?

_____ Explain your conclusion. _____

8. In which of the test situations did net osmosis occur?

In which of the test situations did net simple diffusion occur?

What conclusions can you make about the relative size of glucose, sucrose, NaCl, and water molecules?

With what cell structure can the dialysis sac be compared?

Activity 3

Investigating Diffusion Through Living Membranes

To examine permeability properties of cell membranes, conduct the following microscopic study.

Isotonic solution (physiological saline)—the solution surrounding the red blood cell has the *same* concentration of solutes as the fluid inside the red blood cell.

Hypertonic solution—the solution surrounding the red blood cell has a *higher* concentration of solutes than the fluid inside the red blood cell.

Hypotonic solution—the solution surrounding the red blood cell has a *lower* concentration of solutes than the fluid inside the red blood cell.

1. Go to the demonstration area, where three red blood cell suspensions have been prepared for microscopic observation. In slide 1, the red blood cells are suspended in physiological saline; in slide 2, they are bathed in 1.5 percent saline (NaCl); and in slide 3, the cells are suspended in distilled water. The following definitions will help you to draw some conclusions about variations in the shape of the red blood cells.

Normal shape of a red blood cell—a biconcave *disc*.

Crenation—occurs when a red blood cell loses water and shrinks.

Lysis—occurs when a red blood cell takes in so much additional fluid that it bursts.

2. View slide 1 to see whether any changes in the normal disc-like shape of the red blood cells have occurred.

Observation: _____

3. Observe slide 2. What has happened to the red blood cells in this preparation?

A solution of 1.5 percent saline is *hypertonic* to red blood cells. On the basis of what you know about the effect of such solutions on living cells, explain your observation.

4. Observe slide 3. What has happened to the cells in this preparation?

Explain. _____

Filtration

Filtration is a passive process by which water and solutes are forced through a membrane by hydrostatic (fluid) pressure. For example, fluids and solutes filter out of the capillaries in the kidneys and into the kidney tubules because the blood pressure in the capillaries is greater than the fluid pressure in the tubules. Filtration is not selective. The amount of filtrate (fluids and solutes) formed depends almost entirely on the pressure gradient (difference in pressure on the two sides of the membrane) and on the size of the membrane pores.

4

Activity 4

Observing the Process of Filtration

1. Obtain the following equipment: a funnel; a piece of filter paper; a flask; a solution containing uncooked starch, powdered charcoal, and copper sulfate; and a dropper bottle of Lugol's iodine.

2. Fold the filter paper in half twice, open it into a cone, and place it in a funnel (**Figure 4.3**). Set the funnel on the flask. Shake the starch solution, and fill the funnel with it to just below the top of the filter paper. When the steady stream of filtrate changes to countable filtrate drops, count the number of drops formed in 10 seconds, and record the count.

_____ drops

When the funnel is half empty, again count the number of drops formed in 10 seconds. Record the count.

_____ drops

3. After all the fluid has passed through the filter, check the filtrate and paper to see which materials were retained by the paper. *Note:* If the filtrate is blue, the copper sulfate passed. Check both the paper and filtrate for black particles to see whether the charcoal passed. Finally, add Lugol's iodine to a 2-ml filtrate sample in a test tube. (See Table 4.1 to interpret test results.)

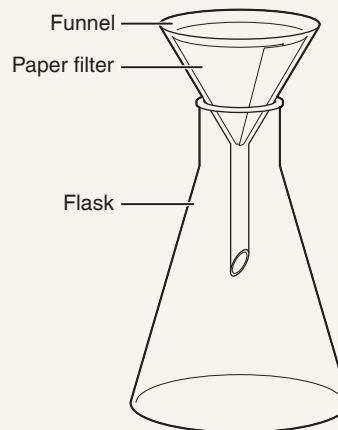


Figure 4.3 Setup for observing the process of filtration.

Text continues on next page. →

Passed: _____

Retained: _____

What does the filter paper represent? _____

What characteristic of the three solutes determined whether or not they passed through the filter paper?

During which counting interval was the filtration rate greatest?

Explain: _____

REVIEW SHEET

Cell Membrane Transport Mechanisms

Name _____ LabTime/Date _____

Choose all answers that apply to items 1 and 2, and place their letters on the response blanks.

- The movement of molecules _____.
 - reflects the kinetic energy of molecules
 - reflects the potential energy of molecules
 - is ordered and predictable
 - is random and erratic
- Speed of molecular movement _____.
 - is higher in larger molecules
 - is lower in larger molecules
 - increases with increasing temperature
 - decreases with increasing temperature
 - reflects kinetic energy
- Summarize below the results of Activity 2, Observing Diffusion Through Nonliving Membranes.

Sac 1: 40% glucose suspended in distilled water

Did glucose diffuse out of the sac? _____ Did the sac weight change? _____

Explanation: _____

Sac 2: 40% glucose suspended in 40% glucose

Was there net movement of glucose into or out of the sac? _____

Explanation: _____

Did the sac weight change? _____

Explanation: _____

Sac 3: 10% NaCl suspended in distilled water

Was there net movement of NaCl out of the sac? _____

Direction of net osmosis: _____

Sac 4: 40% sucrose suspended in distilled water

Was there net movement of sucrose out of the sac? _____

Explanation: _____

Direction of net osmosis: _____

4. What single characteristic of the semipermeable membranes used in the laboratory determines the substances that can pass through them? _____

In addition to this characteristic, what other factors influence the passage of substances through living membranes?

5. A semipermeable sac filled with a solution containing 4% NaCl, 9% glucose, and 10% albumin is suspended in a solution with the following composition: 10% NaCl, 10% glucose, and 40% albumin. Assume that the sac is permeable to all substances except albumin. State whether each of the following will (a) move into the sac, (b) move out of the sac, or (c) not move.

glucose _____

albumin _____

water _____

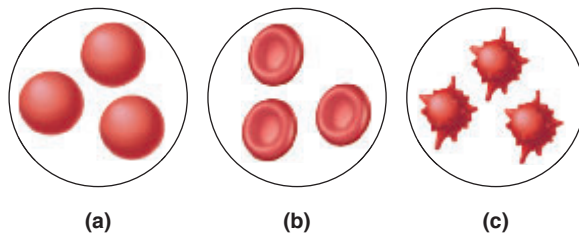
NaCl _____

6. The diagrams below represent three microscope fields containing red blood cells.

Which field contains a hypertonic solution? _____ The cells in this field are said to be _____.

Which field contains an isotonic bathing solution? _____ Which field contains a hypotonic solution? _____


What is happening to the cells in this field? _____




7. What is the driving force for filtration? _____

How does knowing this help you to explain why the filtration process examined in the lab slowed down with time?

8. Define *diffusion*: _____

9.  Drinking too much plain water in a short period of time can result in water intoxication. As a result, blood plasma will become hypotonic. What effect do you think this would have on cells, and why? _____

10.  Receptor-mediated endocytosis is used to remove low-density lipoproteins (LDLs) from circulating in the blood. Explain the effect that defective LDL receptors would have on a patient's cholesterol levels and overall risk for heart disease. (Hint: LDLs are the "bad cholesterol.")

Classification of Tissues

Materials

- Demonstration area with four microscope stations set up:
 - Station 1:* Prepared slides of simple squamous, simple cuboidal, simple columnar, stratified squamous (nonkeratinized), pseudostratified ciliated columnar, and transitional epithelia
 - Station 2:* Prepared slides of adipose, areolar, reticular, and dense regular (tendon) connective tissue; of hyaline cartilage; and of bone (cross section)
 - Station 3:* Prepared slides of skeletal, cardiac, and smooth muscle (longitudinal sections)
 - Station 4:* Prepared slide of nervous tissue (spinal cord smear)

Learning Outcomes

- Name the four primary tissue types in the human body, and state a general function of each.
- Name the major subcategories of the primary tissue types, and identify the tissues of each subcategory microscopically or in an appropriate image.
- State the locations of the various tissues in the body.
- List the general function and structural characteristics of each of the tissues studied.

Cells are the building blocks of life. In humans and other multicellular organisms, cells depend on one another and cooperate to maintain homeostasis in the body.

With a few exceptions, even the most complex animal starts out as a single cell, the fertilized egg, which divides almost endlessly. The resulting trillions of cells then specialize for a particular function. Some become supportive bone, others skin cells, and so on. Thus a division of labor exists, with certain groups of cells highly specialized to perform functions that benefit the organism as a whole.

Groups of cells that are similar in structure and function are called **tissues**. The four primary tissue types—epithelial, connective, muscle, and nervous—have distinct structures, patterns, and functions.

To perform specific body functions, the tissues are organized into **organs** such as the heart, kidneys, and lungs. Most organs contain several representatives of the primary tissues, and the arrangement of these tissues determines the organ's structure and function. The main objective of this exercise is to familiarize you with the major similarities and dissimilarities of the primary tissues. In this exercise, we will focus chiefly on epithelial tissues and some types of connective tissue. Muscle tissue, nervous tissue, and bone (a connective tissue), are covered in greater depth in other exercises.

Epithelial Tissue

Epithelial tissues, or **epithelia**, cover surfaces. For example, epithelia cover the external body surface (as the epidermis), line its cavities, and generally mark off our “insides” from our outsides. Because glands of the body almost always develop from epithelial membranes, glands too are classed as epithelia.

Epithelial functions include protection, absorption, filtration, excretion, secretion, and sometimes sensory reception. For example, the epithelium covering the body protects against bacterial invasion and chemical damage; that lining the respiratory tract is ciliated to sweep dust and other foreign particles away from the lungs. Secretion is a specialty of the glands, and taste receptors are epithelial cells.

Epithelia generally exhibit these characteristics:

- Specialized contacts.* Cells fit closely together to form membranes, or sheets of cells, and are bound together by specialized junctions.
- Polarity.* The membranes always have one exposed surface or free edge, called the *apical surface*. Typically, that surface is significantly different from the *basal surface*.

- *Supported by connective tissue.* The cells are attached to and supported by an adhesive **basement membrane**, a material secreted collectively by the epithelial cells and the connective tissue cells that lie next to each other.
- *Avascular but innervated.* Epithelial tissues have no blood supply of their own (are avascular), but depend on diffusion of nutrients from the underlying connective tissue. They are supplied by nerves.
- *Regeneration.* If well nourished, epithelial cells can easily regenerate themselves. This is an important characteristic because many epithelia are subjected to a good deal of abrasion and other types of trauma.

The covering and lining epithelia are classified according to two criteria—number of cell layers and cell shape (**Figure 5.1**).

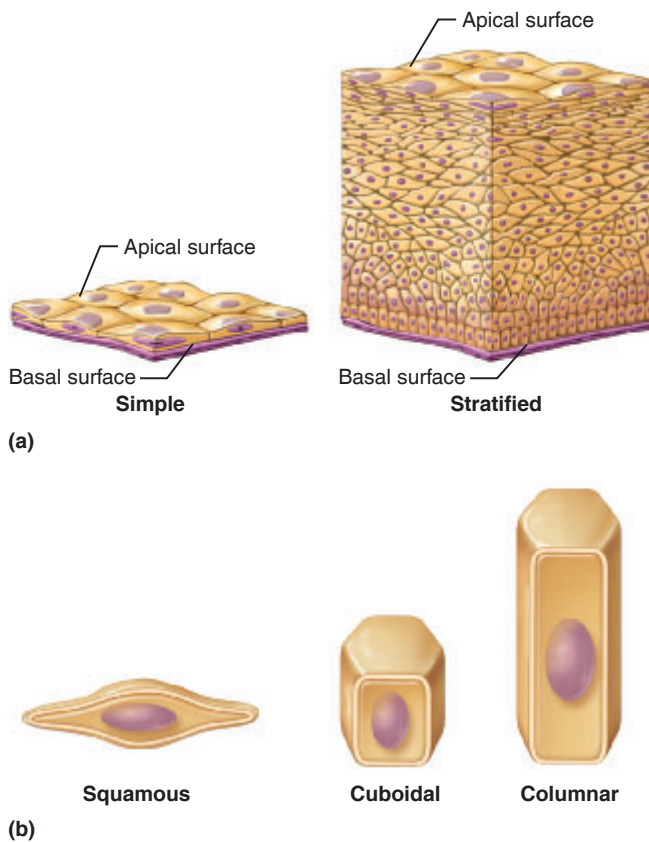


Figure 5.1 Classification of epithelia. (a) Classification based on number of cell layers. (b) Classification based on cell shape.

On the basis of layers, epithelia are classified as follows:

- **Simple** epithelia consist of one layer of cells attached to the basement membrane.
- **Stratified** epithelia consist of two or more layers of cells; only the deepest layer rests on the basement membrane.

Based on cell shape, epithelia are classified according to these categories:

- **Squamous** (scalelike)
- **Cuboidal** (cube-like)
- **Columnar** (column-shaped)

The terms denoting shape and arrangement of the epithelial cells are combined to describe the epithelium fully. *Stratified epithelia are named according to the cells at the apical surface of the epithelial sheet, not those resting on the basement membrane.*

There are also two less easily categorized types of epithelia:

- **Pseudostratified epithelium** is actually a simple columnar epithelium (one layer of cells with all cells attached to the basement membrane), but its cells extend varied distances from the basement membrane so it gives the false appearance of being stratified. This epithelium is often ciliated.
- **Transitional epithelium** is a rather peculiar stratified squamous epithelium formed of rounded, or “plump,” cells with the ability to slide over one another to allow the organ to be stretched. Transitional epithelium is found only in urinary system organs. The superficial cells are flattened (like true squamous cells) when the organ is full and rounded when the organ is empty.

The most common types of epithelia, their characteristic locations in the body, and their functions are described in **Figure 5.2**.

(Text continues on page 42.)

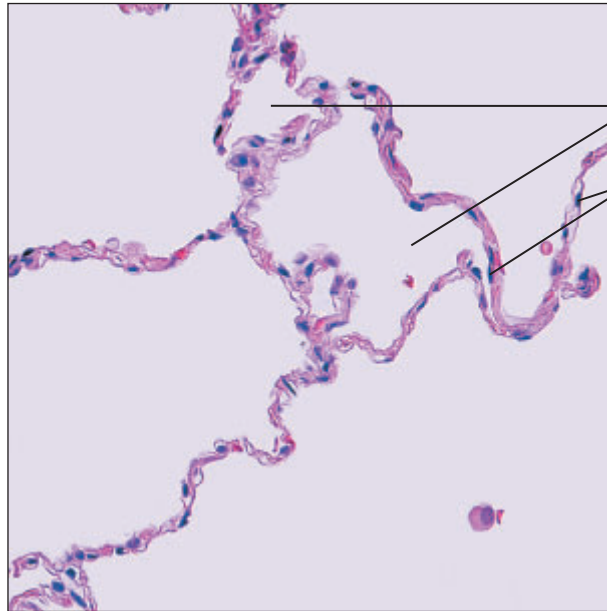
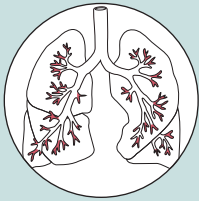
(a) Simple squamous epithelium

Description: Single layer of flattened cells with disc-shaped central nuclei and sparse cytoplasm; the simplest of the epithelia.



Function: Allows materials to pass by diffusion and filtration in sites where protection is not important; secretes lubricating substances in serosae.

Location: Kidney glomeruli; air sacs of lungs; lining of heart, blood vessels, and lymphatic vessels; lining of ventral body cavity (serosae).

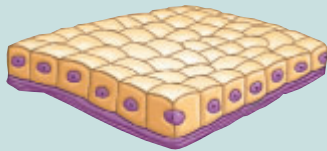


Air sacs of lung tissue
Nuclei of squamous epithelial cells

Photomicrograph: Simple squamous epithelium forming part of the alveolar (air sac) walls (140X).

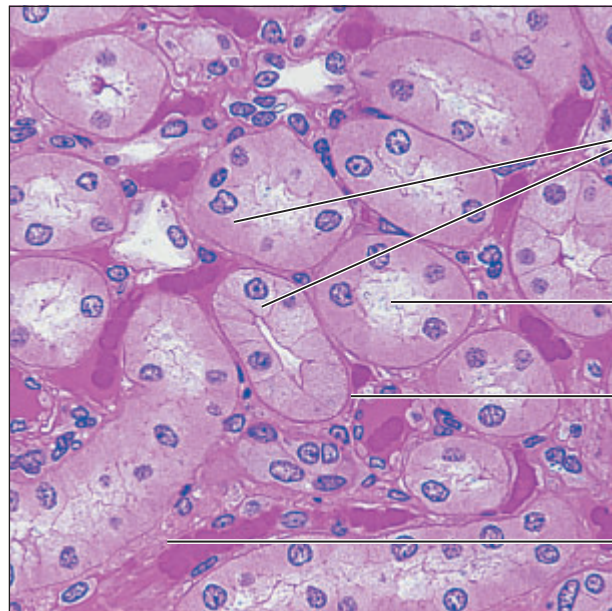
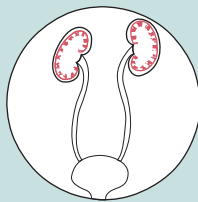
(b) Simple cuboidal epithelium

Description: Single layer of cubelike cells with large, spherical central nuclei.



Function: Secretion and absorption.

Location: Kidney tubules; ducts and secretory portions of small glands; ovary surface.



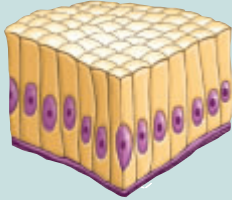
Simple cuboidal epithelial cells
Lumen
Basement membrane
Connective tissue

Photomicrograph: Simple cuboidal epithelium in kidney tubules (430X).

Figure 5.2 Epithelial tissues. Simple epithelia (a and b).
(Figure continues on page 40.)

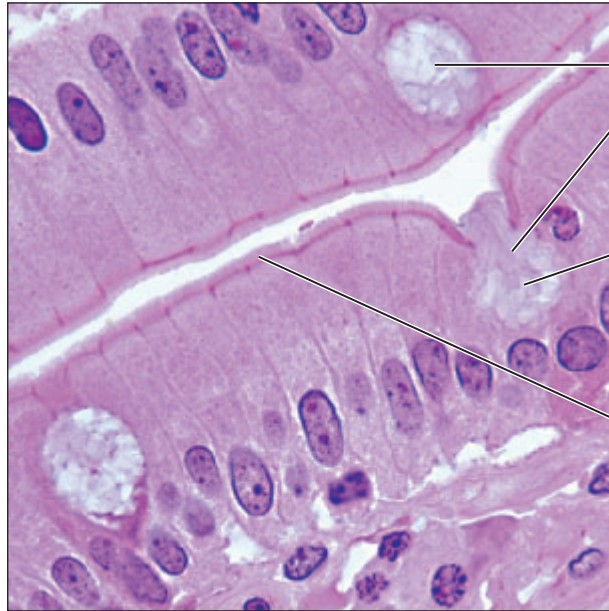
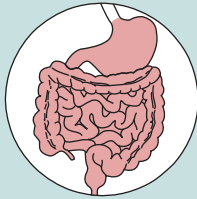
(c) Simple columnar epithelium

Description: Single layer of tall cells with *round to oval* nuclei; some cells bear cilia; layer may contain mucus-secreting unicellular glands (goblet cells).



Function: Absorption; secretion of mucus, enzymes, and other substances; ciliated type propels mucus (or reproductive cells) by ciliary action.

Location: Nonciliated type lines most of the digestive tract (stomach to rectum), gallbladder, and excretory ducts of some glands; ciliated variety lines small bronchi, uterine tubes, and some regions of the uterus.



Goblet cells

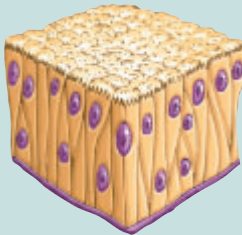
Mucus secretion

Microvilli (brush border)

Photomicrograph: Simple columnar epithelium containing goblet cells from the small intestine (640X).

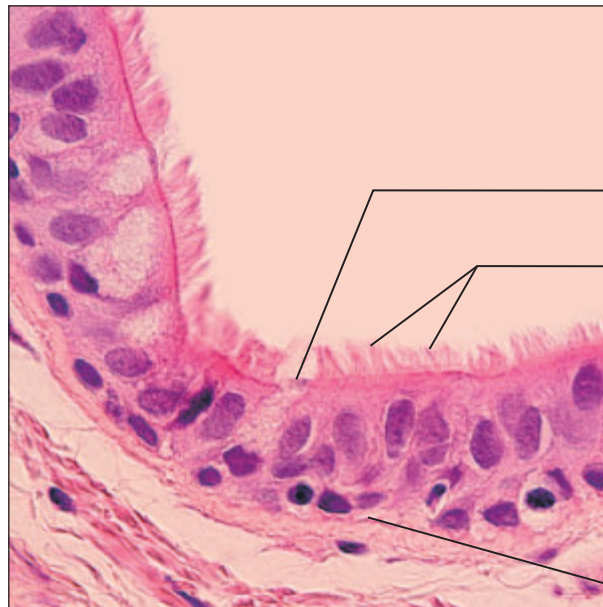
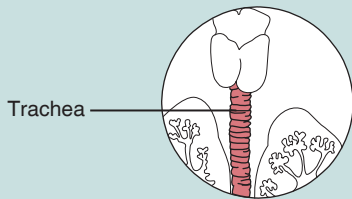
(d) Pseudostratified columnar epithelium

Description: Single layer of cells of differing heights, some not reaching the free surface, but all touching the basement membrane; nuclei seen at different levels; may contain mucus-secreting goblet cells and bear cilia.



Function: Secrete substances, particularly mucus; propulsion of mucus by ciliary action.

Location: Nonciliated type in male's sperm-carrying ducts and ducts of large glands; ciliated variety lines the trachea, most of the upper respiratory tract.



Mucus of goblet cell

Cilia

Pseudostratified epithelial layer


Basement membrane

Photomicrograph: Pseudostratified ciliated columnar epithelium lining the human trachea (530X).

Figure 5.2 (continued) Epithelial tissues. Simple epithelia (c and d). (See also Plate 1 of the Histology Atlas to view simple columnar epithelium.)

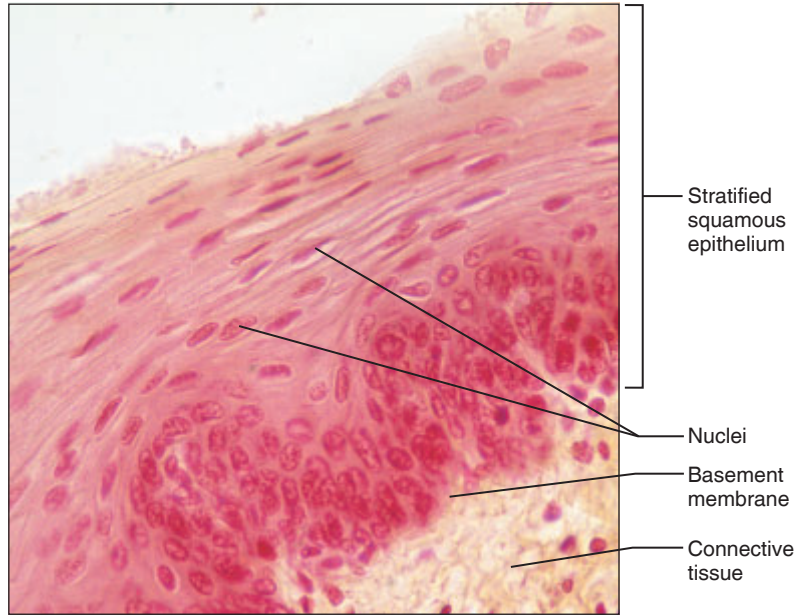
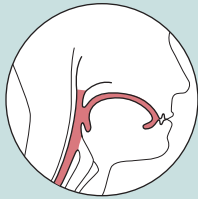
(e) Stratified squamous epithelium

Description: Thick membrane composed of several cell layers; basal cells are cuboidal or columnar and metabolically active; cells at the apical surface are flattened (squamous); in the keratinized type, the surface cells are full of keratin and dead; basal cells are active in mitosis and produce the cells of the more superficial layers.



Function: Protects underlying tissues in areas subjected to abrasion.

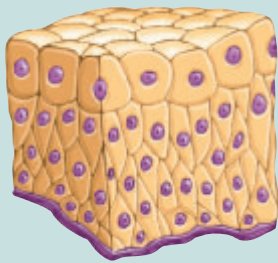
Location: Nonkeratinized type forms the moist linings of the esophagus, mouth, and vagina; keratinized variety forms the epidermis of the skin, a dry membrane.



Photomicrograph: Stratified squamous epithelium lining the esophagus (285 \times).

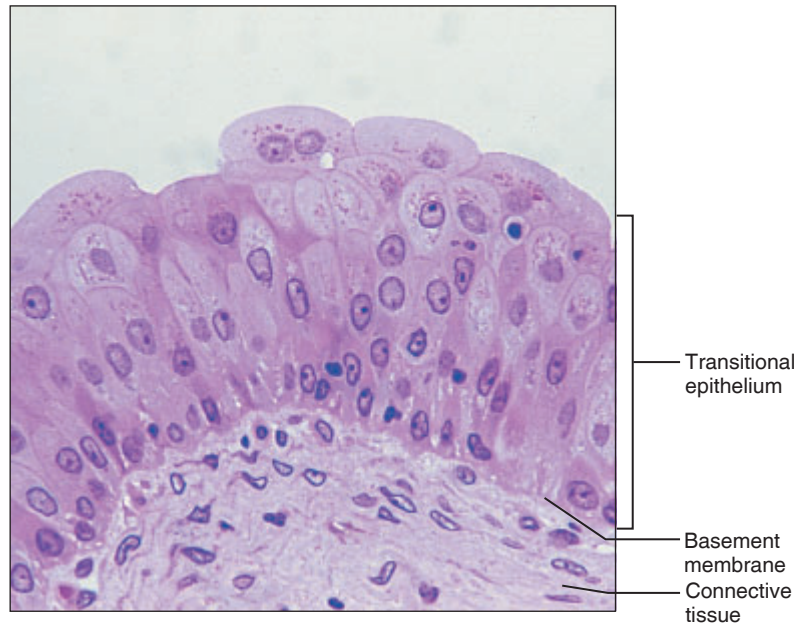
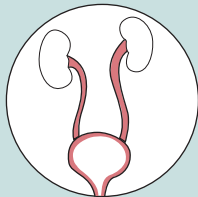
(f) Transitional epithelium

Description: Resembles both stratified squamous and stratified cuboidal; basal cells cuboidal or columnar; surface cells dome shaped or squamouslike, depending on degree of organ stretch.



Function: Stretches readily and permits stored urine to distend urinary organ.

Location: Lines the ureters, urinary bladder, and part of the urethra.



Photomicrograph: Transitional epithelium lining the urinary bladder, relaxed state (360 \times); note the bulbous, or rounded, appearance of the cells at the surface; these cells flatten and become elongated when the bladder is filled with urine.

5

Figure 5.2 (continued) Epithelial tissues. Stratified epithelia (e and f).

Activity 1

Examining Epithelial Tissue Under the Microscope

Go to station 1 of the demonstration area to examine slides of simple squamous, simple cuboidal, simple columnar, stratified squamous (nonkeratinized), pseudostratified ciliated columnar, and transitional epithelia. Observe each carefully, and notice how the epithelial cells fit closely together to form intact sheets of cells, a necessity for a tissue that forms linings or covering membranes. Scan each epithelial type for modifications for specific functions, such as cilia (motile cell projections that help to

move substances along the cell surface), microvilli (which increase the surface area for absorption), and goblet cells (which secrete lubricating mucus). Compare your observations with the photomicrographs (Figure 5.2).

While working, check the questions in the laboratory Review Sheet section for this exercise (beginning on page 51). A number of the questions there refer to some of the observations you are asked to make during your microscopic study.

Connective Tissue

5 **Connective tissue** is found in all parts of the body. It is the most abundant and widely distributed of the tissue types. There are four main types of connective tissue: **connective tissue proper, cartilage, bone, and blood**. All of these derive from an embryonic tissue called *mesenchyme*. Connective tissue proper has two subclasses: **loose connective tissues** (areolar, adipose, and reticular) and **dense connective tissues** (dense regular, dense irregular, and elastic).

The connective tissues perform a variety of functions, but primarily they protect, support, and bind together other tissues of the body. For example, bones are composed of connective tissue (bone or osseous tissue), and they protect and support other body tissues and organs. Ligaments and tendons (dense regular connective tissue) bind the bones together or bind skeletal muscles to bones. Connective tissue also serves a vital function in the repair of all body tissues: many wounds are repaired by connective tissue in the form of scar tissue.

Connective tissues are composed of many types of cells, and there is a great deal of nonliving material between the cells. The nonliving material between the cells—the **extracellular matrix**—distinguishes connective tissue from all other tissues. The matrix, secreted by the cells, is primarily responsible for the strength associated with connective tissue, but its firmness and relative amount vary.

The matrix has two components—ground substance and fibers. The **ground substance** is chiefly glycoproteins and large polysaccharide molecules. Depending on its makeup, the ground substance may be liquid, gel-like, or very hard. When the matrix is firm, as in cartilage and bone, the connective tissue cells reside in cavities in the matrix called *lacunae*. The fibers, which provide support, include **collagen (white) fibers, elastic (yellow) fibers, and reticular (fine collagen) fibers**.

Figure 5.3 lists the general characteristics, location, and function of some of the connective tissues found in the body. Blood, considered in detail in Exercise 19, is not covered here.

(Text continues on page 47.)

Activity 2

Examining Connective Tissue Under the Microscope

Go to station 2 at the demonstration area to examine prepared slides of adipose, areolar, reticular, and dense regular connective tissue; of fibrocartilage, hyaline cartilage, and elastic cartilage; and of osseous connective tissue (bone). Compare your observations with Figure 5.3.

Distinguish the living cells from the matrix, and pay particular attention to the appearance of the matrix. For example, notice how the matrix of the dense regular connective tissues making up tendons is packed with collagen fibers, and notice that the fibers are all running in the same direction.

While examining the areolar connective tissue, a soft “packing tissue,” notice how much empty space (*areol* = small empty space) there appears to be, and distinguish the collagen fibers from the thin, coiled elastic fibers.

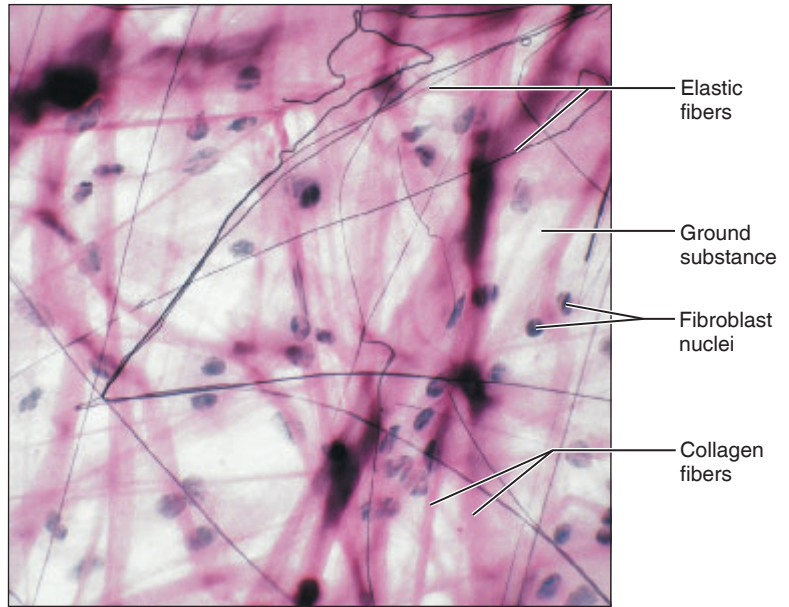
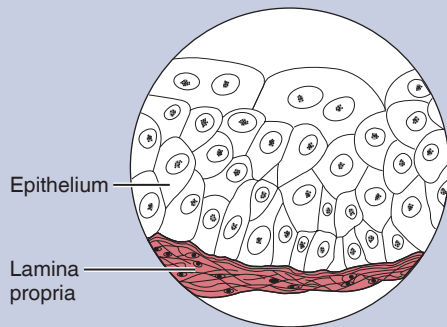
In adipose (fat) tissue, locate a hollow-appearing cell in which the nucleus is pushed to one side by the large, fat-filled vacuole that appears to be a large empty space. Also notice how little matrix there is in adipose tissue. Distinguish the living cells from the matrix in the dense connective tissues, bone, and hyaline cartilage preparations.

(a) Connective tissue proper: loose connective tissue, areolar

Description: Gel-like matrix with all three fiber types; cells: fibroblasts, macrophages, mast cells, and some white blood cells.

Function: Wraps and cushions organs; its macrophages phagocytize bacteria; plays important role in inflammation; holds and conveys tissue fluid.

Location: Widely distributed under epithelia of body, e.g., forms lamina propria of mucous membranes; packages organs; surrounds capillaries.



Photomicrograph: Areolar connective tissue from the lamina propria of a mucous membrane (340X).

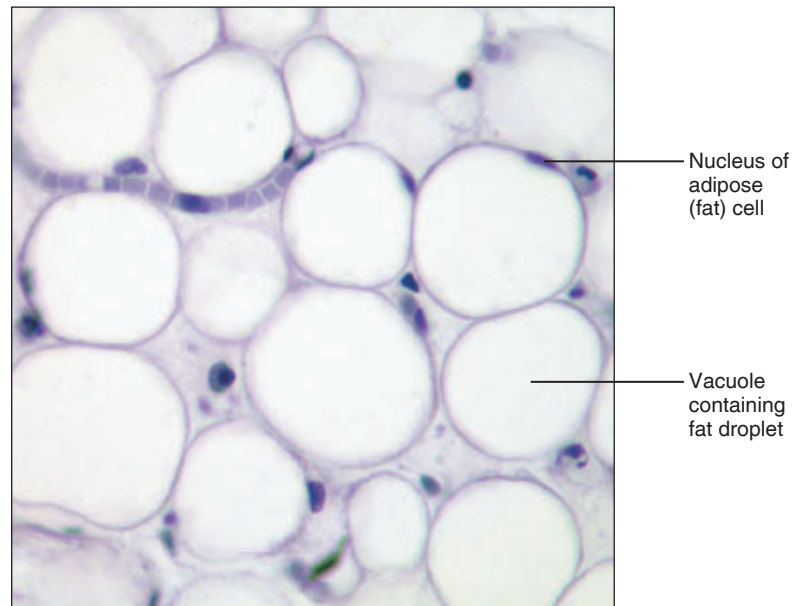
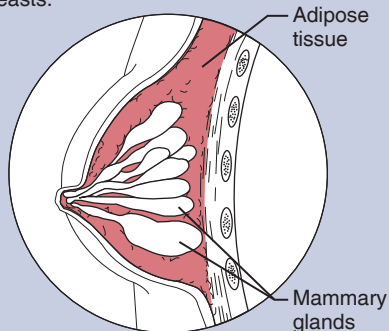
5

(b) Connective tissue proper: loose connective tissue, adipose

Description: Matrix as in areolar, but very sparse; closely packed adipocytes, or fat cells, have nucleus pushed to the side by large fat droplet.

Function: Provides reserve food fuel; insulates against heat loss; supports and protects organs.

Location: Under skin in subcutaneous tissue; around kidneys and eyeballs; within abdomen; in breasts.



Photomicrograph: Adipose tissue from the subcutaneous layer under the skin (350X).

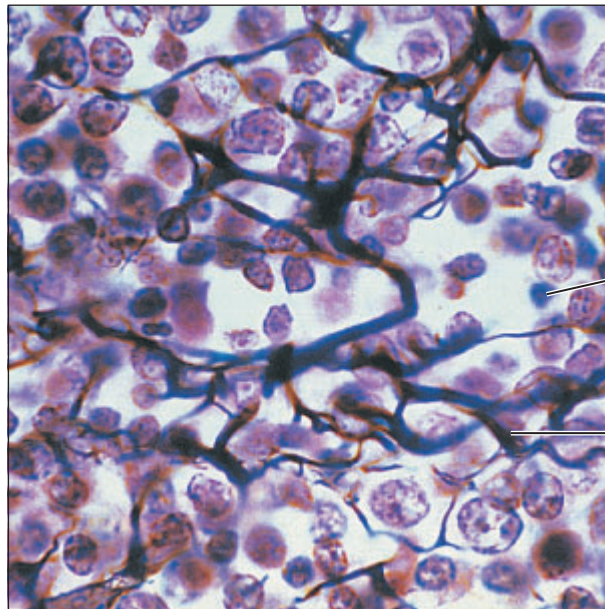
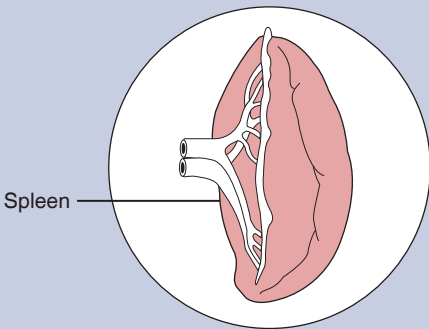
Figure 5.3 Connective tissues. Loose connective tissues: areolar (a) and adipose (b). (Figure continues on page 44.)

(c) Connective tissue proper: loose connective tissue, reticular

Description: Network of reticular fibers in a typical loose ground substance; reticular cells lie on the network.

Function: Fibers form a soft internal skeleton (stroma) that supports other cell types, including white blood cells, mast cells, and macrophages.

Location: Lymphoid organs (lymph nodes, bone marrow, and spleen).



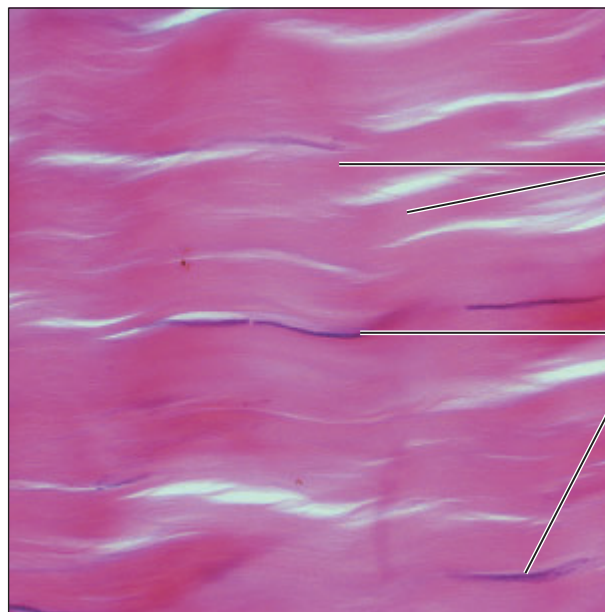
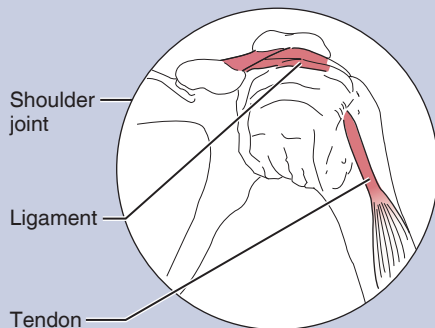
Photomicrograph: Dark-staining network of reticular connective tissue fibers forming the internal skeleton of the spleen (350X).

(d) Connective tissue proper: dense regular connective tissue

Description: Primarily parallel collagen fibers; a few elastic fibers; major cell type is the fibroblast.

Function: Attaches muscles to bones or to muscles; attaches bones to bones; withstands great tensile stress when pulling force is applied in one direction.

Location: Tendons, most ligaments, aponeuroses.



Photomicrograph: Dense regular connective tissue from a tendon (430X).

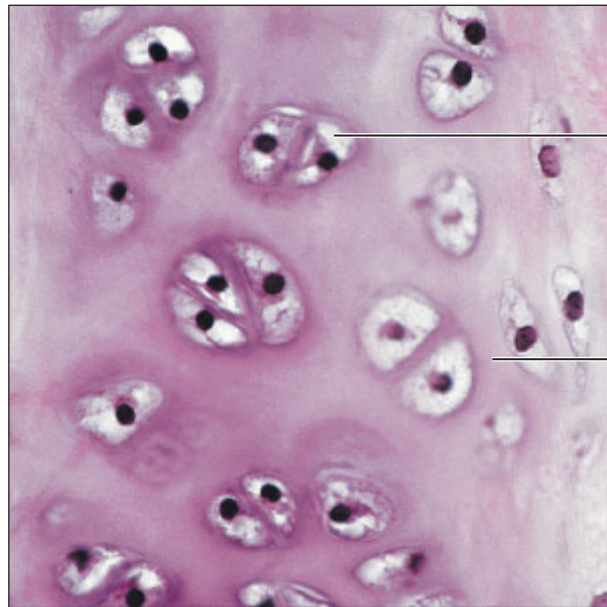
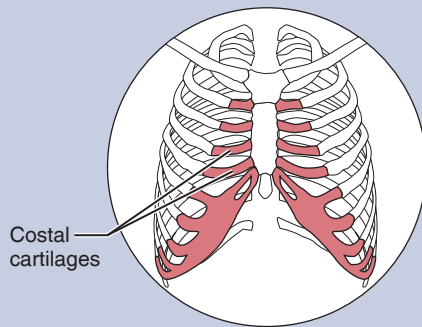
Figure 5.3 (continued) Connective tissues. Loose connective tissue: reticular (c). Dense regular connective tissue (d).

(e) Cartilage: hyaline

Description: Amorphous but firm matrix; collagen fibers form an imperceptible network; chondroblasts produce the matrix and when mature (chondrocytes) lie in lacunae.

Function: Supports and reinforces; serves as resilient cushion; resists compressive stress.

Location: Forms most of the embryonic skeleton; covers the ends of long bones in joint cavities; forms costal cartilages of the ribs; cartilages of the nose, trachea, and larynx.



Chondrocyte in lacuna

Matrix

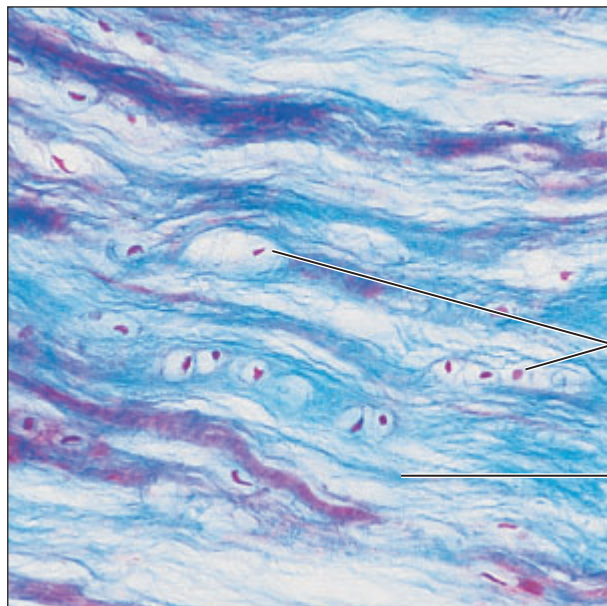
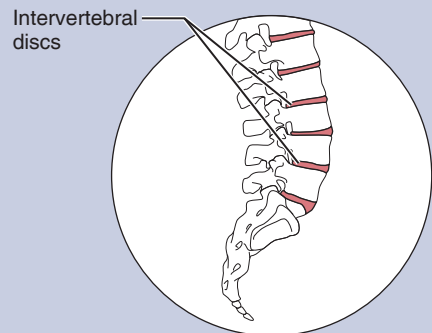
Photomicrograph: Hyaline cartilage from a costal cartilage of a rib (470X).

(f) Cartilage: fibrocartilage

Description: Matrix similar to but less firm than that in hyaline cartilage; thick collagen fibers predominate.

Function: Tensile strength with the ability to absorb compressive shock.

Location: Intervertebral discs; pubic symphysis; discs of knee joint.



Chondrocytes in lacunae

Collagen fiber

Photomicrograph: Fibrocartilage of an intervertebral disc (125X). Special staining produced the blue color.

5

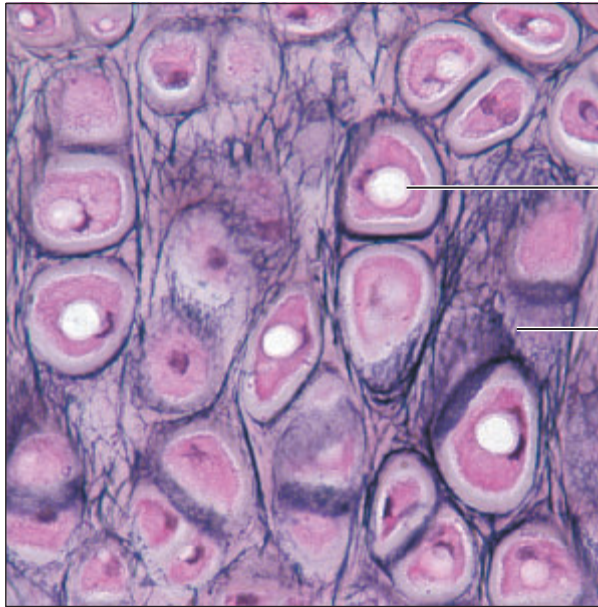
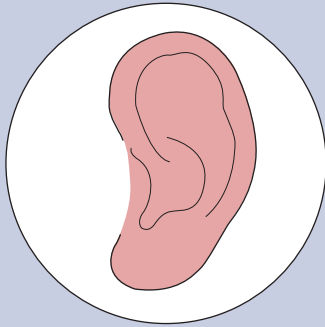
Figure 5.3 (continued) Hyaline cartilage (e) and fibrocartilage (f). (Figure continues on page 46.)

(g) Cartilage: elastic

Description: Similar to hyaline cartilage, but more elastic fibers in matrix.

Function: Maintains the shape of a structure while allowing great flexibility.

Location: Supports the external ear (auricle); epiglottis.



Chondrocyte in lacuna

Matrix

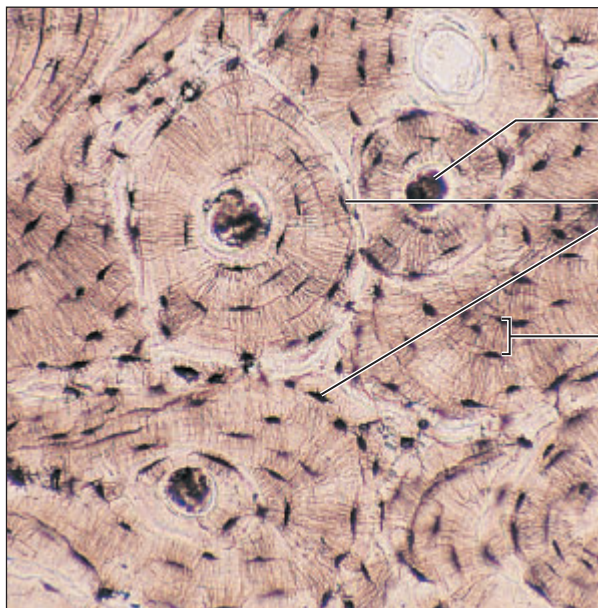
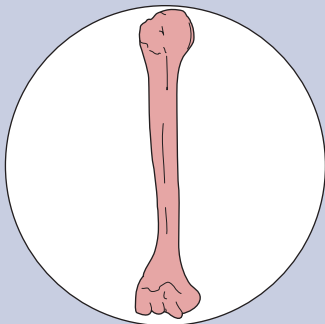
Photomicrograph: Elastic cartilage from the human ear auricle; forms the flexible skeleton of the ear (800X).

(h) Bone (osseous tissue)

Description: Hard, calcified matrix containing many collagen fibers; osteocytes lie in lacunae. Very well vascularized.

Function: Bone supports and protects (by enclosing); provides levers for the muscles to act on; stores calcium and other minerals and fat; marrow inside bones is the site for blood cell formation (hematopoiesis).

Location: Bones



Central canal

Osteocytes in the lacunae

Lamella

Photomicrograph: Cross-sectional view of bone (125X).

Figure 5.3 (continued) Connective tissues. Elastic cartilage (g) and bone (osseous tissue) (h).

Muscle Tissue

Muscle tissue is specialized to contract in order to produce movement of some body parts. As you might expect, muscle cells are elongated to provide a long axis for contraction. The three basic types of muscle tissue are described briefly here.

Skeletal muscle, the flesh of the body, is attached to the skeleton. It is under voluntary control (consciously controlled), and as it contracts it moves the limbs and other external body parts. The cells of skeletal muscles are long, cylindrical, nonbranching, and multinucleate (several nuclei per cell); they have obvious *striations* (stripes).

Cardiac muscle is found only in the heart. As it contracts, the heart acts as a pump, propelling the blood into the blood vessels. Like skeletal muscle, cardiac muscle has striations, but cardiac cells are branching cells with one nucleus (or occasionally two) that fit together at junctions called **intercalated discs**, which allow cardiac muscle to act as a unit. Cardiac muscle is under involuntary control, which means that we cannot voluntarily or consciously control the operation of the heart.

Smooth muscle is found mainly in the walls of hollow organs (digestive and urinary tract organs, uterus, blood vessels). Typically two layers run at right angles to each other, so the muscle can constrict or dilate the lumen (cavity) of an organ and also propel substances along existing pathways. No striations are visible, and the uninucleate smooth muscle cells are spindle-shaped.

Activity 3


Examining Muscle Tissue Under the Microscope

Go to station 3 of the demonstration area to examine prepared slides of skeletal, cardiac, and smooth muscle. Notice their similarities and dissimilarities in your observations and in the illustrations (**Figure 5.4**). (See also Plates 2 and 3 in the Histology Atlas.)

5

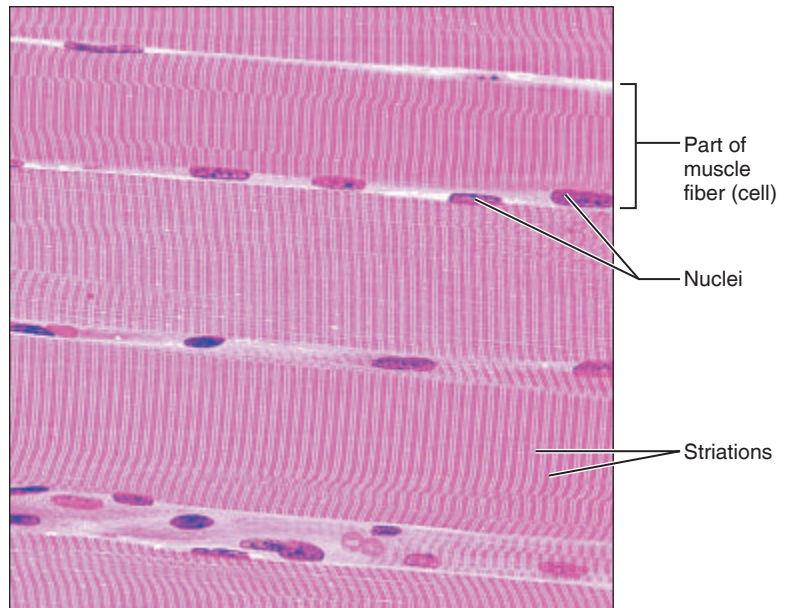
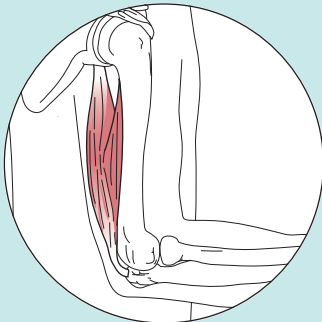
(a) Skeletal muscle

Description: Long, cylindrical, multinucleate cells; obvious striations.



Function: Voluntary movement; locomotion; manipulation of the environment; facial expression; voluntary control.

Location: In skeletal muscles attached to bones or occasionally to skin.




Photomicrograph: Skeletal muscle (approx. 440 \times). Notice the obvious banding pattern and the fact that these large cells are multinucleate.

Figure 5.4 Muscle tissues. Skeletal muscle (a) (Figure continues on page 48.)

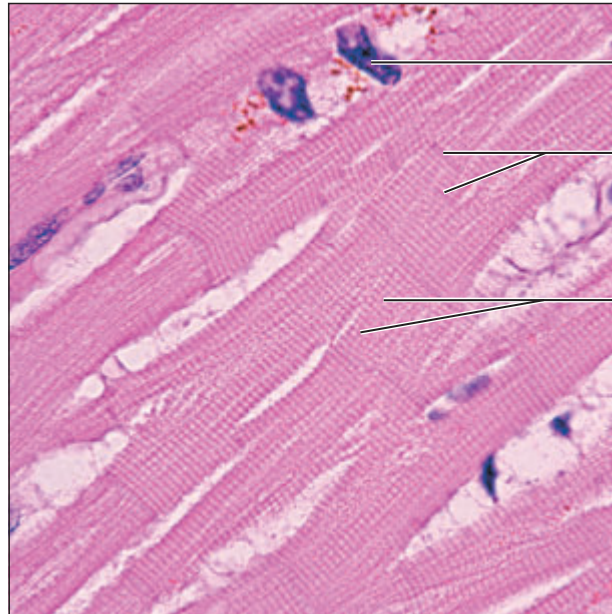
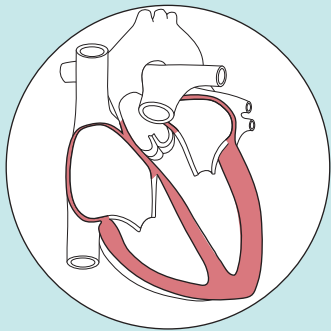
(b) Cardiac muscle

Description: Branching, striated, generally uninucleate cells that interdigitate at specialized junctions called intercalated discs.



Function: As it contracts, cardiac muscle propels blood into the circulation; involuntary control.

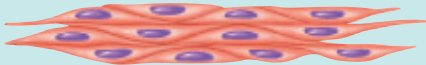
Location: The walls of the heart.



Photomicrograph: Cardiac muscle (775 \times); notice the striations, branching of cells, and the intercalated discs.

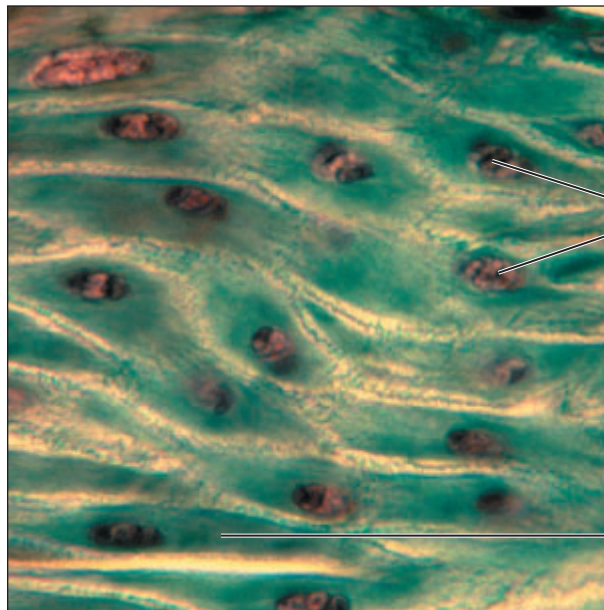
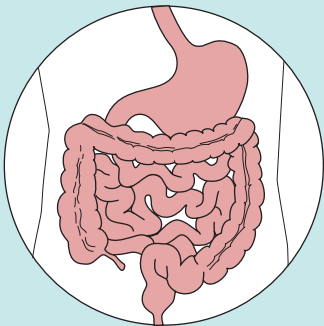
(c) Smooth muscle

Description: Spindle-shaped cells with central nuclei; no striations; cells arranged closely to form sheets.



Function: Propels substances (foodstuffs, urine) or a baby along internal passageways; involuntary control.

Location: Mostly in the walls of hollow organs.



Photomicrograph: Sheet of smooth muscle (720 \times).

Figure 5.4 (continued) Muscle tissues. Cardiac muscle (b) and smooth muscle (c).

Nervous Tissue

Nervous tissue is composed of two major cell populations. **Neuroglia** are special supporting cells that protect, support, and insulate the more delicate neurons. The **neurons** are highly specialized to receive stimuli and to conduct impulses to all parts of the body. They are the cells that are most often associated with nervous system functioning.

The structure of neurons is markedly different from that of all other body cells. They all have a nucleus-containing cell body, and their cytoplasm is drawn out into long extensions (cell processes)—sometimes as long as 3 feet (about 1 m). This allows a single neuron to conduct an impulse over relatively long distances. For more detail about the anatomy of the different classes of neurons and neuroglia, see Exercise 13.

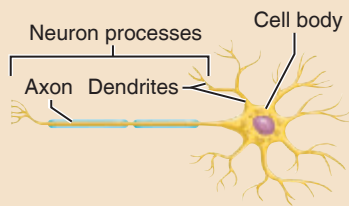
Activity 4

Examining Nervous Tissue Under the Microscope

Go to station 4 at the demonstration area, and examine a prepared slide of a spinal cord smear. Locate a neuron and compare it to **Figure 5.5** and Plate 5 of the Histology Atlas. Keep the light on the microscope dim—this will help you see the cellular extensions of the neurons.

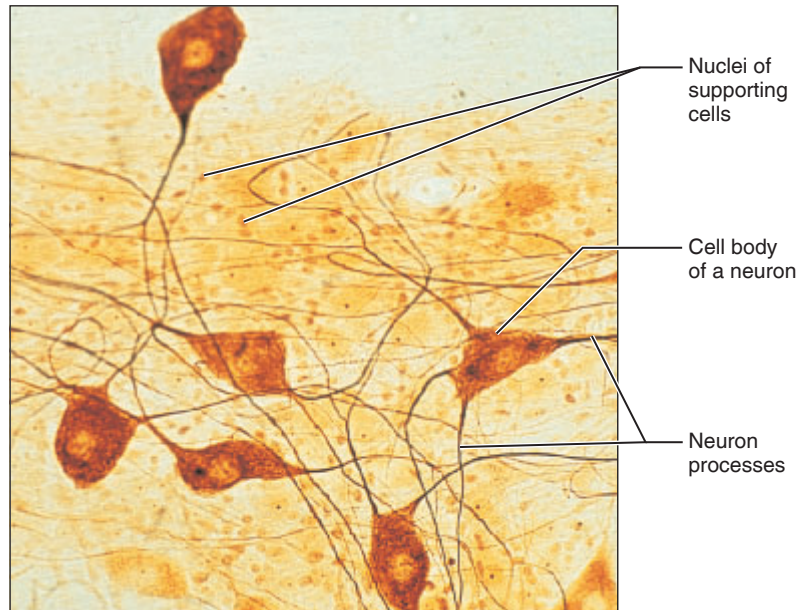
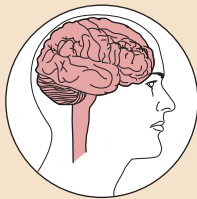Nervous tissue

Description: Neurons are branching cells; cell processes that may be quite long extend from the nucleus-containing cell body; also contributing to nervous tissue are nonexcitable supporting cells.



Function: Neurons transmit electrical signals from sensory receptors and to effectors (muscles and glands). Supporting cells support and protect neurons.

Location: Brain, spinal cord, and nerves.



Photomicrograph: Neurons (350 \times).

Figure 5.5 Nervous tissue.

Activity 5

Constructing a Concept Map of the Tissues

Using **Figure 5.6** as a guide and the following steps, prepare your own concept map that separates the tissues based on what you observe in the photomicrographs in this exercise (Figures 5.2, 5.3, 5.4, and 5.5). Your instructor will give you a list of the tissue types to include.

1. Read the sections on epithelial, connective, muscle, and nervous tissues. Carefully review the characteristics of the assigned tissues.

2. Prepare a series of questions based on features observed through the microscope that

a. will have only two possible answers, yes or no.

b. will separate the tissues in a logical manner. (Figure 5.6 provides an example of a concept map separating out simple squamous epithelium.)

3. A helpful first question is “Is there a free edge?” This question separates epithelial tissue from connective, muscle, and nervous tissue.

4. A branch of the concept map is complete when only a single tissue type is alone at the end of a branch.

5. When your concept map is complete, use it to help identify tissue types on prepared slides.

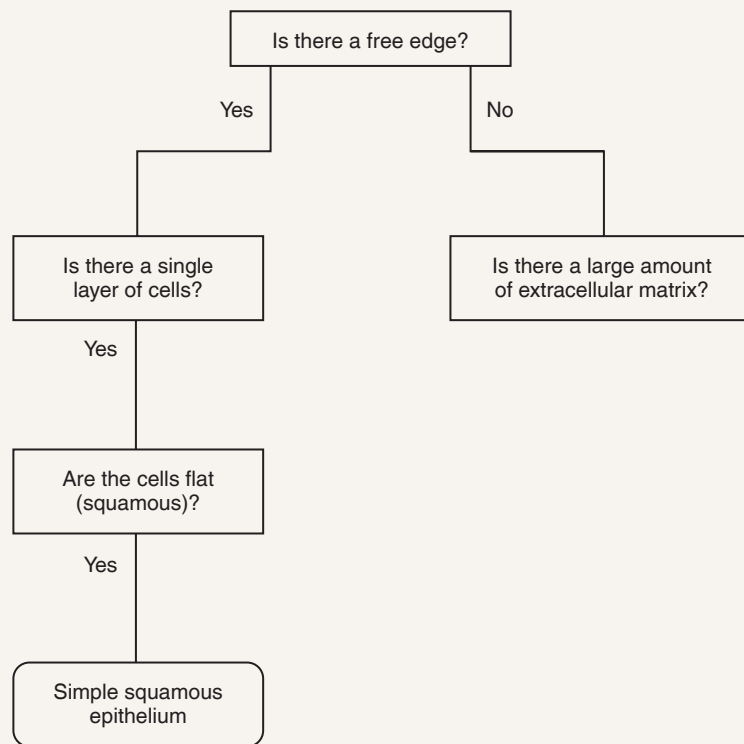


Figure 5.6 A concept map separating tissues based on observable characteristics. A map of simple squamous epithelium has been completed as an example. The map should continue until each tissue type is alone at the end of a branch.

EXERCISE
5

REVIEW SHEET

Classification of Tissues

Name _____ LabTime/Date _____

Tissue Structure and Function: General Review

1. Define *tissue*: _____

2. Use the key to identify the major tissue types described below.

Key: connective epithelial muscle nervous

- _____ 1. lines body cavities and covers the body's external surface
- _____ 2. pumps blood, flushes urine out of the body, allows one to swing a bat
- _____ 3. transmits electrical signals
- _____ 4. anchors and packages body organs
- _____ 5. cells may absorb, protect, or form a filtering membrane
- _____ 6. forms nerves and the brain
- _____ 7. major function is to contract
- _____ 8. the most widespread tissue in the body

Epithelial Tissue

3. How are epithelial tissues classified? _____

4. How is the function of an epithelium reflected in its arrangement? _____

5. Using the key, choose the type of epithelial tissue that best fits each description.

Key: pseudostratified ciliated columnar simple cuboidal stratified squamous
simple columnar simple squamous transitional

- _____ 1. best suited for areas subject to friction
- _____ 2. most suited for rapid diffusion
- _____ 3. tubules of the kidney
- _____ 4. lines much of the respiratory tract
- _____ 5. stretches
- _____ 6. lines the small and large intestines

Connective Tissue

6. How are the functions of connective tissue reflected in its structure? _____

7. Using the key, choose the best response to identify each connective tissue described below.

Key: adipose connective tissue dense regular connective tissue hyaline cartilage
 areolar connective tissue reticular connective tissue osseous tissue

- _____ 1. attaches bones to bones and muscles to bones
- _____ 2. provides levers for your muscles to act on
- _____ 3. composes basement membranes; a soft packaging tissue with a jellylike matrix
- _____ 4. forms the larynx and the costal cartilages of the ribs
- _____ 5. fibers form a network that supports other cells
- _____ 6. insulates against heat loss; provides reserve fuel

Muscle Tissue

8. The terms and phrases in the key relate to the muscle tissues. For each of the three muscle tissues, select the terms or phrases that characterize it, and write the corresponding letter of each term on the answer line.

Key: a. striated e. voluntary i. attached to bones
 b. branching cells f. involuntary j. intercalated discs
 c. spindle-shaped cells g. one nucleus k. in wall of bladder and stomach
 d. cylindrical cells h. many nuclei l. forms heart walls

Skeletal muscle: _____ Cardiac muscle: _____ Smooth muscle: _____

Nervous Tissue

9. In what ways are nerve cells similar to other cells? _____

How are they different? _____

How does the special structure of a neuron relate to its function? _____

10.  When cardiac muscle tissue dies in adults, it is replaced with scar tissue composed of dense connective tissue.

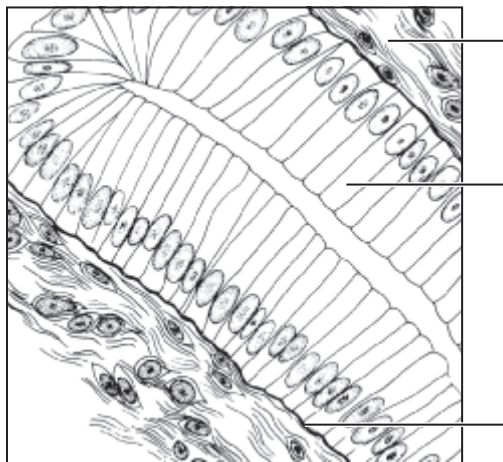
Explain how the function of the scar tissue would differ from the function the cardiac muscle tissue. _____

11.  Smoking impairs cilia because the toxins paralyze and can destroy the cilia. Based on this loss of function, explain

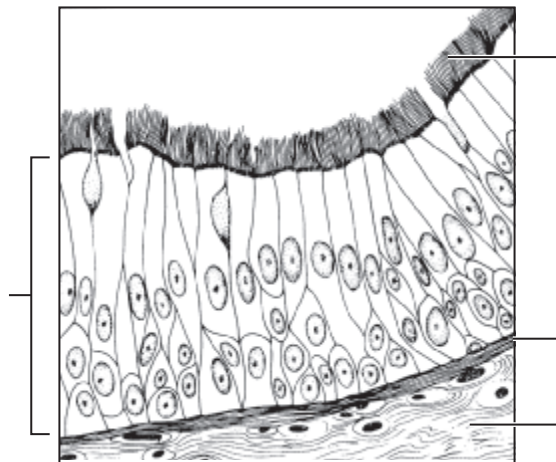
which types of infections smokers would be more susceptible to. _____

For Review

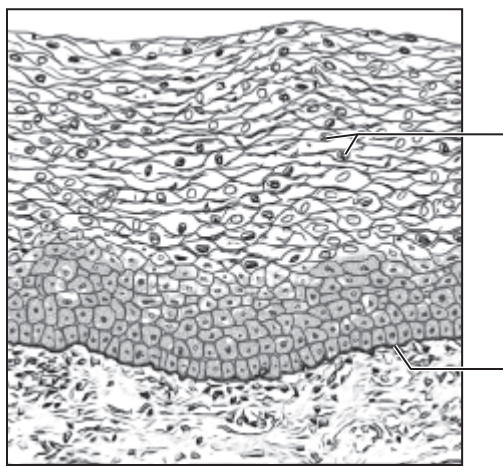
12. Write the name of each tissue type in illustrations (a) through (f), and identify all structures provided with leader lines.



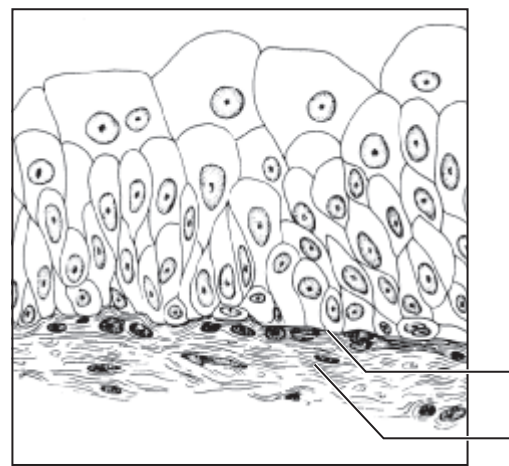
(a) _____



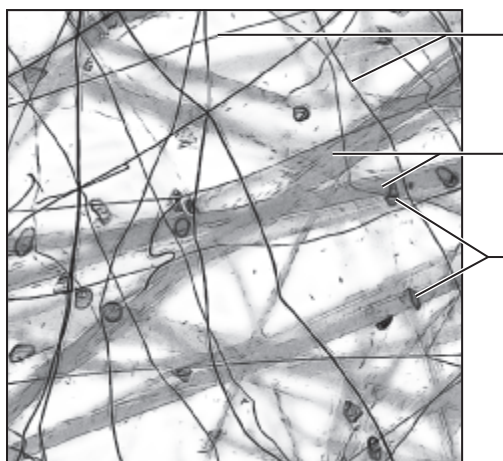
(b) _____




(c) _____




(d) _____



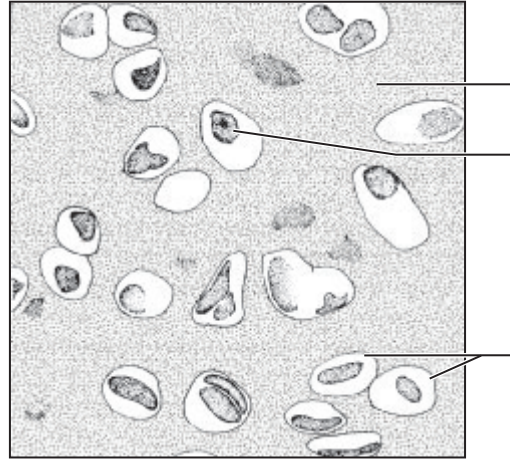
(e) _____



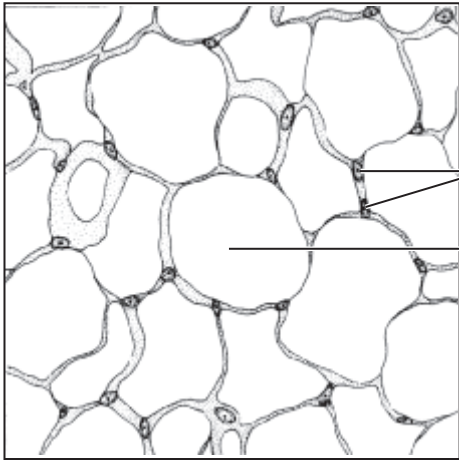
(f) _____



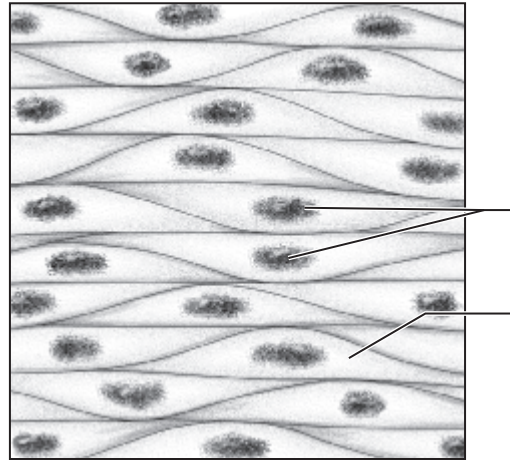
(g) _____



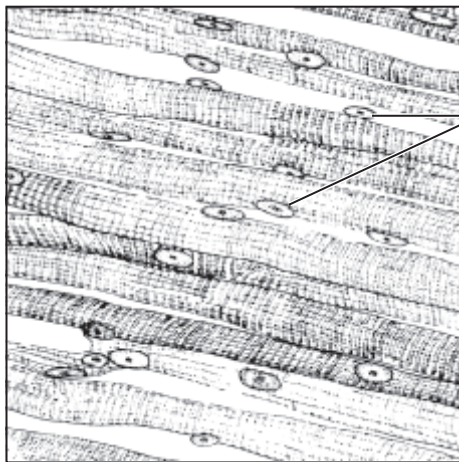
(h) _____



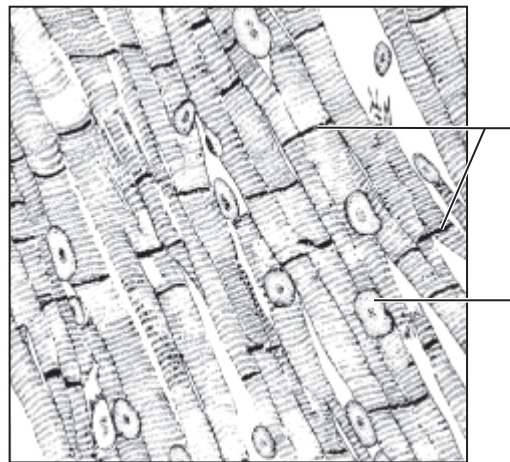
(i) _____



(j) _____



(k) _____



(l) _____

The Integumentary System

Materials

- Skin model (three-dimensional, if available)
- Small metric ruler
- Calipers or esthesiometer
- Four coins (nickels or quarters)
- Fine felt-tipped markers (2 different colors)
- Sheet of 20# bond paper ruled to mark off cm² areas
- Scissors
- Povidone-iodine swabs, or Lugol's iodine and cotton swabs
- Adhesive tape
- Small clear glass plates (5×5 inches or larger)
- Demonstration area:
 - Station 1:* Compound microscope set up to demonstrate human skin showing hair follicles (about 20×)
 - Station 2:* Prepared slide of skin; pointer on a tactile corpuscle
 - Station 3:* Prepared slide of skin; pointer on a lamellar corpuscle

Learning Outcomes

- List several important functions of the integumentary system.
- During observation of a model, diagram, or slide, recognize and name the following skin structures: epidermal and dermal layers, hair follicles and hairs, sebaceous and sweat glands.
- Describe the distribution and function of eccrine and apocrine sweat glands and sebaceous glands.
- Identify the major regions of a hair and hair follicle.
- Identify the major regions of nails.

The **integumentary system** includes the skin and its accessory organs. The skin does much more than just cover the body exterior. Architecturally, the skin is a wonder. It is tough yet pliable, a characteristic that enables it to withstand constant insult from outside agents.

The skin has several functions, most concerned with protection. It insulates and cushions the underlying body tissues and protects the entire body from mechanical damage, chemical damage, thermal damage, and bacterial invasion. The hardened uppermost layer of the skin prevents water loss from the body surface.

The skin has other functions, as well. The skin:

- Acts as a mini-excretory system; urea, salts, and water are lost when we sweat.
- Performs important metabolic duties, such as producing proteins important to our immunity.
- Is the site where vitamin D is synthesized for the body. Vitamin D plays a role in calcium absorption in the digestive system.
- Contains the cutaneous sense organs that allow us to sense and enjoy the external environment.
- Plays an important role in regulating heat loss from the body surface.

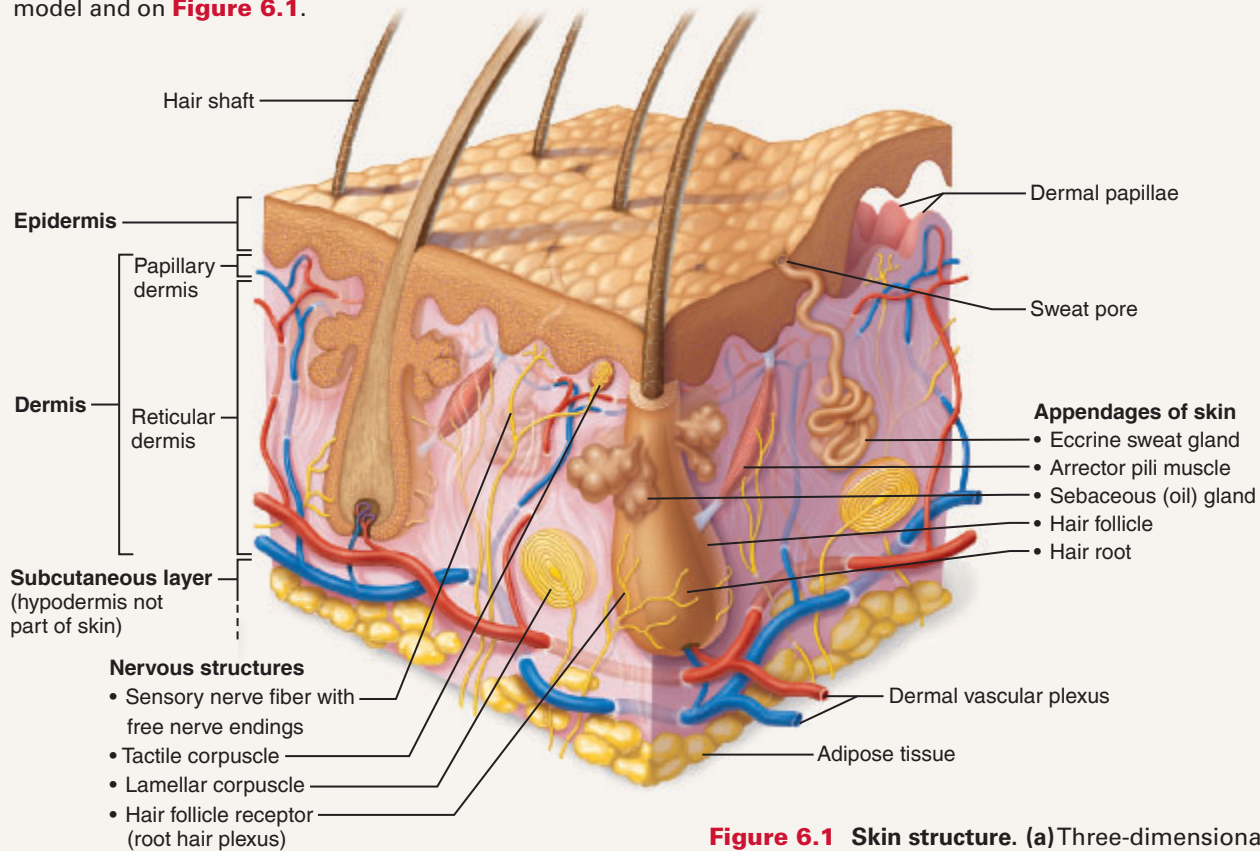
Basic Structure of the Skin

The skin has two distinct regions—the superficial *epidermis* composed of epithelium and an underlying connective tissue *dermis*. These layers are firmly “cemented” together along a wavy basement membrane. But friction, such as the rubbing of a poorly fitting shoe, may cause them to separate, resulting in a blister. Immediately deep to the dermis is the **subcutaneous layer**, or **hypodermis**, which is not considered part of the skin. A description of the main skin areas and structures follows.

Activity 1

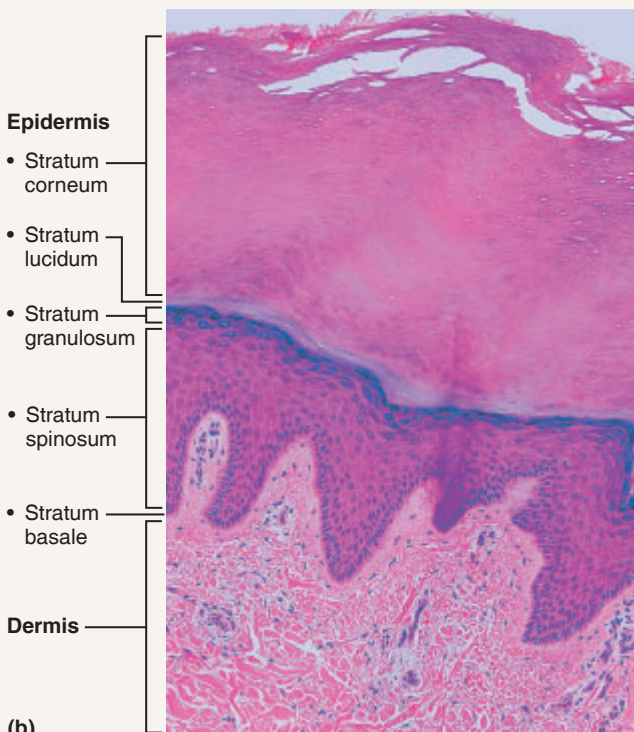
Locating Structures on a Skin Model

As you read, locate the following structures on a skin model and on **Figure 6.1**.



(a)

Figure 6.1 Skin structure. (a) Three-dimensional view of the skin and underlying tissue. Tactile corpuscles are not common in hairy skin but are included here for illustrative purposes. (b) Photomicrograph of thick skin (75 \times).



(b)

Epidermis

Structurally, the avascular epidermis is a keratinized stratified squamous epithelium consisting of four distinct cell types and four or five distinct layers.

Cells of the Epidermis

- **Keratinocytes** (literally, keratin cells): The most abundant epidermal cells. They function to produce **keratin**, a tough fibrous protein that gives the epidermis durability and protective capabilities.

Far less numerous are the following types of epidermal cells:

- **Melanocytes**: Spidery black cells that produce the reddish yellow to brownish black pigments collectively called **melanin**. Melanin provides a protective pigment umbrella that shields the nuclei of deeper epidermal layers from the damaging effects of ultraviolet radiation in sunlight.

- **Dendritic cells**: Also called *Langerhans cells*, these cells arise from the bone marrow and migrate to the epidermis. They ingest foreign substances and play a key role in activating the immune response.

- **Tactile epithelial cells:** When combined with sensory nerve endings, these cells form sensitive touch receptors located at the epidermal-dermal junction.

Layers of the Epidermis

From deep to superficial, the layers of the epidermis of thick skin are the stratum basale, stratum spinosum, stratum granulosum, stratum lucidum, and stratum corneum (Figure 6.1b). This order of the epidermal layers represents the progression that skin cells take as they age, from the young epidermal cells in the stratum basale to the dead cells in the stratum corneum. This represents a journey that takes approximately 25–45 days. The layers of the epidermis are summarized in **Table 6.1**.

Dermis

The connective tissue proper making up the bulk of the dermis has two principal regions—the papillary and reticular areas.

- **Papillary dermis:** composed of areolar connective tissue. It is very uneven and has fingerlike projections from its superior surface, called **dermal papillae**, which attach it to the epidermis above. In the palms of the hands and soles of the feet, the papillae produce the fingerprints, unique patterns of loops and ridges in the epidermis. Capillaries in the papillary layer furnish nutrients for the epidermis and allow heat to radiate to the skin surface. The pain and touch receptors (tactile corpuscles in hairless skin) are also found here.
- **Reticular dermis:** the deepest skin layer. It contains blood vessels, sweat and sebaceous glands, and pressure receptors (lamellar corpuscles).

Collagenic and elastic fibers are found throughout the dermis. The collagenic fibers make the dermis tough and attract and hold water, thus keeping the skin hydrated. The elastic fibers give skin its exceptional elasticity in youth. Fibroblasts, adipose cells, various types of phagocytes (which

are important in the body’s defense), and other cell types are found throughout the dermis.

Dermal Blood Supply

The rich dermal blood supply allows the skin to play a role in regulating body temperature. When body temperature is high, the capillary network of the dermis becomes engorged with the heated blood. Thus body heat is allowed to radiate from the skin surface. If the environment is cool and body heat must be conserved, the dermal blood vessels constrict so that blood bypasses the dermis temporarily.

Activity 2

Visualizing Changes in Skin Color Due to Continuous External Pressure

Go to the supply area, and obtain a small glass plate. Press the heel of your hand firmly against the plate for a few seconds, and then observe and record the color of your skin in the compressed area by looking through the glass.

Color of compressed skin: _____

What is the reason for this color change? _____

What would happen if the pressure were continued for an extended period in this area? _____

Dermal Cutaneous Receptors

The dermis also has a rich nerve supply. Many of the nerve endings bear specialized receptor organs that respond to pain, pressure, or temperature extremes, and transmit messages to

6

Table 6.1 Layers of the Epidermis (from superficial to deep)

Epidermal layer	Description
Stratum corneum (horny layer)	The outermost layer consisting of 20–30 layers of dead, scalelike keratinocytes. They are constantly being exfoliated and replaced by the division of the deeper cells.
Stratum lucidum (clear layer)	Present only in thick skin. A very thin transparent band of flattened, dead keratinocytes with indistinct boundaries.
Stratum granulosum (granular layer)	A thin layer named for the abundant granules its cells contain. These granules are (1) <i>lamellar granules</i> , which contain a waterproofing glycolipid that is secreted into the extracellular space; and (2) <i>keratohyaline granules</i> , which help to form keratin in the more superficial layers. At the upper border of this layer, the cells are beginning to die.
Stratum spinosum (spiny layer)	Several layers of cells that contain thick, weblike bundles of intermediate filaments made of a pre-keratin protein. The cells in this layer appear spiky because when the tissue is prepared, the cells shrink, but their desmosomes hold tight to adjacent cells. Cells in this layer and the basal layer are the only ones to receive adequate nourishment from diffusion of nutrients from the dermis.
Stratum basale (basal layer)	A single row of cells immediately above the dermis. Its cells are constantly undergoing mitosis to form new cells, hence its alternate name, <i>stratum germinativum</i> . Some 10–25% of the cells in this layer are melanocytes, which thread their processes through this and adjacent layers of keratinocytes. Occasional tactile epithelial cells are also present in this layer.

the central nervous system for interpretation. These receptors include free nerve endings (pain and temperature receptors), lamellar corpuscles, tactile corpuscles, and hair follicle receptors (Figure 6.1a; see also Plates 11–13 in the Histology Atlas).

Activity 3

Viewing Two Types of Pressure Receptors Microscopically

Go to the demonstration area where two types of dermal pressure receptors—tactile corpuscles and lamellar corpuscles—have been set up for viewing under the microscope. At station 2, examine the tactile corpuscle, which responds to touch or light pressure. Notice that its connective tissue capsule is located in a dermal papilla. (Compare your observations to Plate 11 in the Histology Atlas.)

Next, at station 3, view the much larger lamellar corpuscle, which responds to deep pressure as indicated by its location much deeper in the dermis. What vegetable does its structure remind you of? (Compare your observations to Plate 13 in the Histology Atlas.)

There are several simple experiments you can conduct to investigate the location and physiology of cutaneous receptors. In each of the following activities, work in pairs, with one person as the subject and the other as the experimenter. After you have completed an experiment, switch roles and go through the procedures again so that all class members obtain individual results. Keep an accurate account of each test that you perform.

Activity 4

Determining the Two-Point Threshold

The density of the touch receptors varies significantly in different areas of the body. In general, areas that have the greatest density of tactile receptors have a heightened ability to “feel.” These areas correspond to areas that receive the greatest motor innervation; thus, they are also typically areas of fine motor control. Let’s check it out.

- Using calipers or an esthesiometer and a metric ruler, test the ability of the subject to differentiate two distinct sensations when the skin is touched simultaneously at two points. Beginning with the face, start with the caliper arms completely together. Gradually increase the distance between the points, testing the subject’s skin after each adjustment. Continue with this testing procedure until the subject reports that *two points* of contact can be felt. This measurement, the smallest distance at which two points of contact can be felt, is the **two-point threshold**.
- Repeat this procedure on the back and palm of the hand, fingertips, lips, back of the neck, and anterior forearm. Record your results in the **Activity 4 chart**.
- Which area has the smallest two-point threshold?

Activity 4: Determining Two-Point Threshold

Body area tested	Two-point threshold (millimeters)
Face	
Back of hand	
Palm of hand	
Fingertips	
Lips	
Back of neck	
Anterior forearm	

Activity 5

Testing Tactile Localization

Tactile localization is the ability to determine which portion of the skin has been touched. The receptive field of the body periphery has a corresponding “touch” field in the brain. Some body areas are well represented with touch receptors, and tactile stimuli can be localized with great accuracy, but density of touch receptors in other body areas allows only crude discrimination.

- The subject keeps eyes closed during the testing. The experimenter touches the palm of the subject’s hand with a pointed black felt-tipped marker. The subject then tries to touch the exact point with his or her own marker, which should be a different color. Measure the error of localization in millimeters.
- Repeat the test in the same spot twice more, recording the error of localization for each test. Average the results of the three determinations and record it in the **Activity 5 chart**.

Activity 5: Testing Tactile Localization

Body area tested	Average error of localization (millimeters)
Palm of hand	
Fingertip	
Ventral forearm	
Back of hand	
Back of neck	

Does the ability to localize the stimulus improve the second time?

_____ The third time? _____ Explain.

3. Repeat the above procedure on a fingertip, the ventral forearm, the back of a hand, and the back of the neck. Record the averaged results in the chart above.

4. Which area has the smallest error of localization (is most sensitive to touch)?

5. Which body area tested has the smallest receptive field?

Activity 6

Demonstrating Adaptation of Touch Receptors

In many cases, when a stimulus is applied for a prolonged period, the rate of receptor response slows and conscious awareness of the stimulus declines or is lost until some type of stimulus change occurs. This phenomenon is referred to as **adaptation**. The touch receptors adapt particularly rapidly, which is highly desirable. Who, for instance, would want to be continually aware of the pressure of clothing on their skin? The simple experiment conducted next allows you to investigate the phenomenon of adaptation.

1. The subject keeps eyes closed. Place a coin on the anterior surface of the subject's forearm, and determine

how long the sensation persists for the subject. Duration of the sensation:

_____ sec

2. Repeat the test, placing the coin at a different forearm location. How long does the sensation persist at the second location?

_____ sec

3. After the awareness of the sensation has been lost at the second site, stack three more coins atop the first one.

Does the pressure sensation return? _____

If so, for how long is the subject aware of the pressure in this instance?

_____ sec

Are the same receptors being stimulated when the four coins, rather than the one coin, are used?

_____ Explain. _____

Accessory Organs of the Skin

The accessory organs of the skin—hair, nails, and cutaneous glands—all derive from the epidermis, but they reside in the dermis. They originate from the stratum basale and extend into the dermis.

Cutaneous Glands

The cutaneous glands fall primarily into two categories: the sebaceous glands and the sweat glands (Figure 6.1). The **sebaceous (oil) glands** are found nearly all over the skin, except for the palms of the hands and the soles of the feet. Their ducts usually empty into a hair follicle, but some open directly onto the skin surface.

The product of the sebaceous glands, called **sebum**, is a mixture of oily substances and fragmented cells that acts as a natural lubricant that keeps the skin soft and moist. *Blackheads* are accumulations of dried sebum and bacteria. *Acne* is due to active infection of the sebaceous glands.

Epithelial openings, called *pores*, are the outlets for the **sweat (sudoriferous) glands**. Sweat, or sudoriferous, glands are exocrine glands and are widely distributed in the skin. There are two types of sweat glands. The **eccrine sweat glands**, which are distributed all over the body, produce a clear secretion, consisting primarily of water, salts (mostly NaCl), and urea. The **apocrine sweat glands**, found chiefly in the axillary and genital areas, secrete the basic components of eccrine sweat glands plus proteins and fat-rich substances that is an excellent source of nutrients for the bacteria typically found on the skin.

The sweat glands are controlled by the nervous system and are an important part of the body's heat-regulating apparatus. They secrete perspiration when the external temperature or body temperature is high. When sweat evaporates, it carries excess body heat with it.

Activity 7

Plotting the Distribution of Sweat Glands

1. For this simple experiment you will need two squares of bond paper (each 1 cm × 1 cm), adhesive tape, and a povidone-iodine swab *or* Lugol's iodine and a cotton-tipped swab. (The bond paper has been preruled in cm²—just cut along the lines to obtain the required squares.)

2. Using the iodine solution, paint an area of the medial aspect of your left palm (avoid the crease lines) and a region of your left forearm. Allow the iodine solution to dry thoroughly. In each case, make sure that the painted area is slightly larger than the paper squares to be used.

3. Mark one piece of ruled bond paper with an "H" (for hand) and the other "A" (for arm). Have your lab partner *securely* tape the appropriate square of bond paper over each iodine-painted area, and leave them in place for

Text continues on next page. →

20 minutes. (If it is very warm in the laboratory, you can obtain good results within 5 minutes.) While waiting to determine the results, continue with the sections on hair and nails.

4. After 20 minutes, remove the paper squares, and count the number of blue-black dots on each square. The appearance of a blue-black dot on the paper indicates an active sweat gland. (The iodine in the pore dissolves in the sweat and reacts with the starch in the bond paper to produce the blue-black color.) Thus you have produced "sweat maps" for the two skin areas.

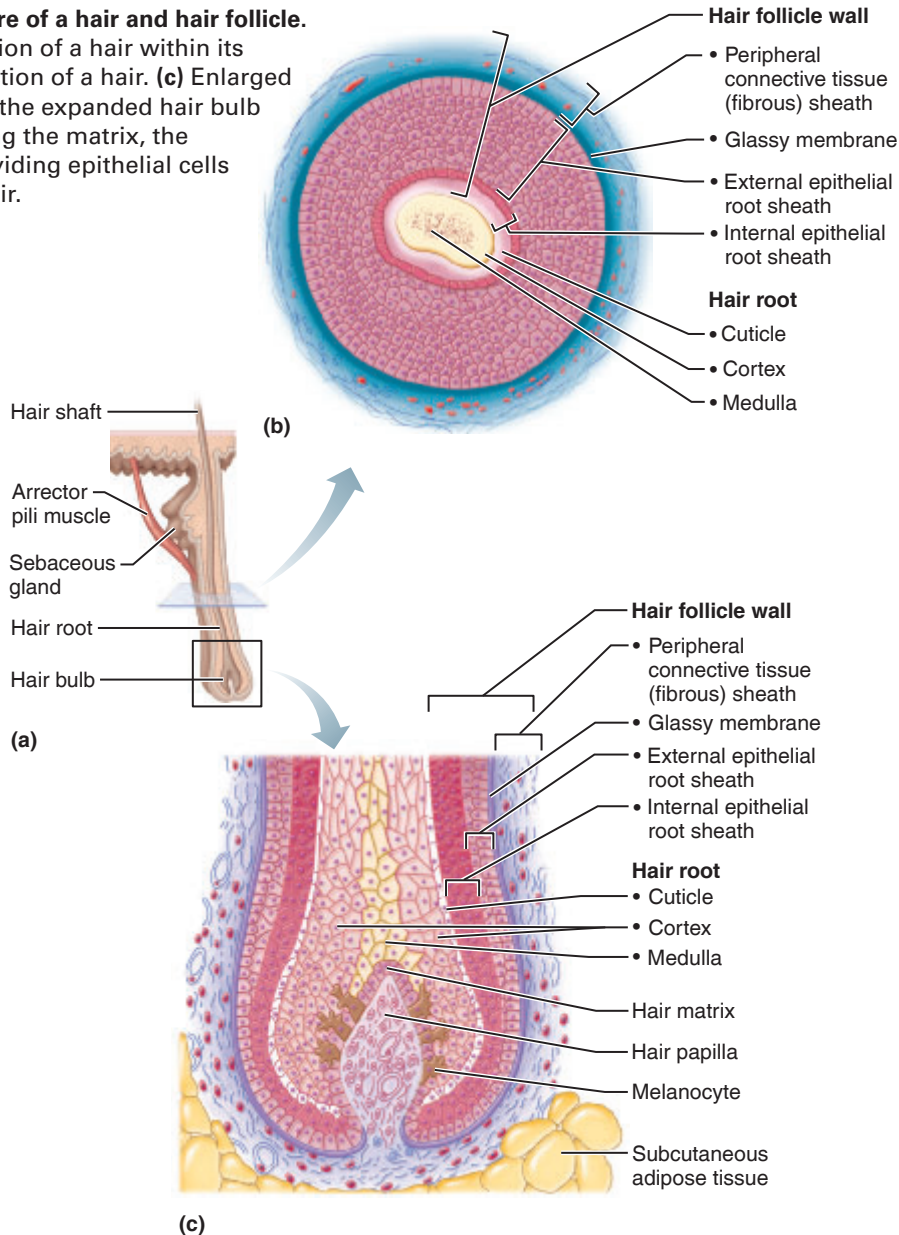
5. Which skin area tested has the most sweat glands?

Hair

Hairs are found over the entire body surface, except for the palms of the hands, the soles of the feet, parts of the external genitalia, the nipples, and the lips. A hair, enclosed in a hair follicle, is also an epithelial structure (**Figure 6.2**). The part of the hair enclosed within the follicle is called the **hair root**;

6 **Figure 6.2 Structure of a hair and hair follicle.**

(a) Longitudinal section of a hair within its follicle. (b) Cross section of a hair. (c) Enlarged longitudinal view of the expanded hair bulb in the follicle showing the matrix, the region of actively dividing epithelial cells that produces the hair.



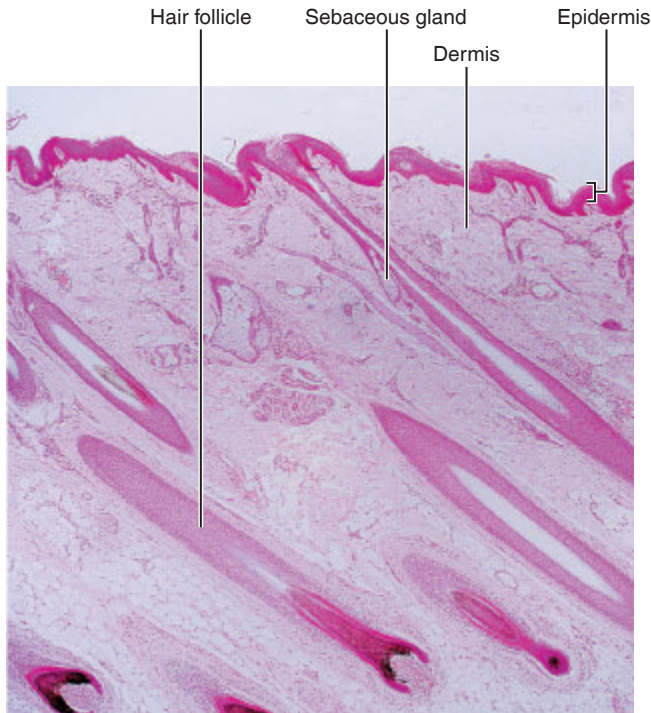


Figure 6.3 Photomicrograph of skin (40×).

the portion projecting from the skin is the **hair shaft**. The hair is formed by mitosis of the germinal epithelial cells at the base of the follicle, the **hair bulb**. As the daughter cells are pushed away from the growing region, they become keratinized and die; thus the bulk of the hair shaft, like the bulk of the epidermis, is dead material.

A hair (Figure 6.2b) consists of a central medulla surrounded first by the cortex and then by a protective cuticle.

The **hair follicle** is formed from both epidermal and dermal cells (Figure 6.2c). Its external and internal epithelial root sheaths are enclosed in a thickened basement membrane, the glassy membrane, and by a peripheral connective tissue (or fibrous) sheath, which is essentially dermal tissue. The **hair papilla** is a small nipple of dermal tissue that protrudes into the hair bulb and provides nutrition to the growing hair. A layer of actively dividing epithelial cells called the **hair matrix** is located on top of the hair papilla. If you look carefully at the structure of the hair follicle (Figure 6.3), you will see that it generally is in a slanted position. Small bands of smooth muscle cells—**arrector pili**—connect each hair follicle to the dermis. When these muscles contract (during cold or fright), the hair follicle is pulled upright, dimpling the skin surface with “goose bumps.”

Microscopic Structure of the Skin

Activity 8

Examining a Skin Slide

Go to station 1 of the demonstration area to view a prepared slide of human skin. Study it carefully under the microscope. Identify hair shafts, hair roots, and hair

follicles. Compare your tissue slide to the view shown in Figure 6.3, and identify as many of the other structures depicted in Figure 6.1 as you can.

How is this stratified squamous epithelium different from that found in the esophagus?

How does this difference relate to the functions of these two similar epithelia?

Nails

Nails, the hornlike derivatives of the epidermis, are transparent and nearly colorless, but they appear pink because of the blood supply in the underlying dermis. The exception to this is the proximal region of the thickened nail matrix, which appears as a white crescent called the **lunule** (Figure 6.4). When someone is cyanotic because of a lack of oxygen in the blood, the nail beds take on a blue cast.

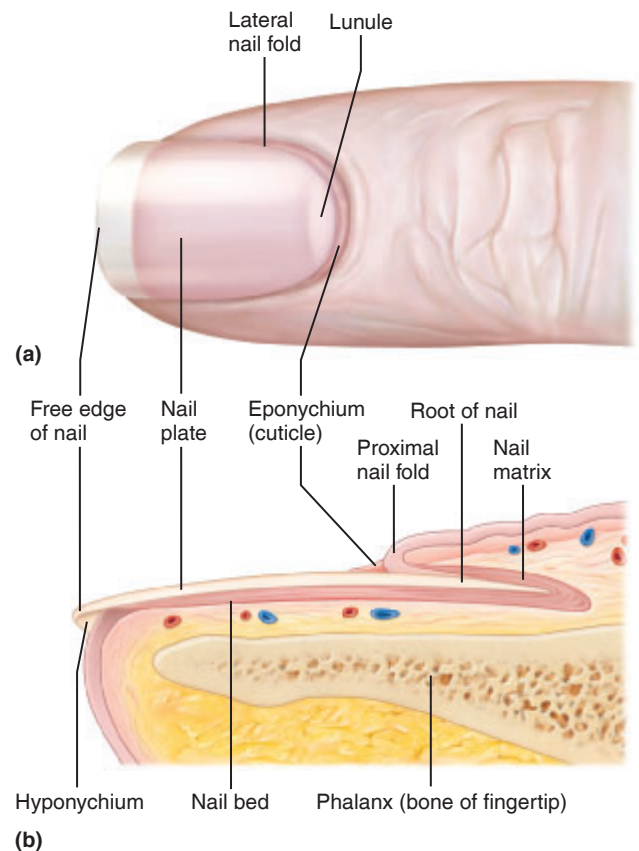


Figure 6.4 Structure of a nail. (a) Surface view of the distal part of a finger. (b) Sagittal section of the fingertip.

Nails consist of a *free edge*, a *nail plate* (visible attached portion), and a *nail root* (embedded in the skin and adhering to an epithelial **nail bed**). The borders of the nail are overlapped by skin folds called **nail folds**. The thick proximal nail fold is the **eponychium**, commonly called the *cuticle*. The region beneath the free edge of the nail is the **hyponychium**. The germinal cells in the **nail matrix**, the thickened proximal part of the nail bed, are responsible for nail growth. As new cells are produced by the matrix, they become heavily keratinized and die.

Activity 9

Identifying Nail Structures

Identify the nail structures shown in Figure 6.4 on yourself or your lab partner.

EXERCISE
6

REVIEW SHEET

The Integumentary System

Name _____ Lab Time/Date _____

Basic Structure of the Skin

1. Complete the following statements by writing the appropriate word or phrase on the blank line:

1. The superficial region of the skin is the _____, composed of _____
_____ (3 words) tissue.

2. The deeper region tissue is the _____, composed of connective tissue.

3. The most numerous cell of the epidermis is the _____.

4. The two primary layers of the dermis are the _____ dermis, composed of areolar connective
tissue, and the _____ dermis, composed of dense irregular connective tissue.

2. Four protective functions of the skin are:

a. _____ c. _____

b. _____ d. _____

3. Using the key, choose all responses that apply to the following descriptions.

Key: a. stratum basale d. stratum lucidum g. reticular dermis
b. stratum corneum e. stratum spinosum
c. stratum granulosum f. papillary dermis

_____ 1. layer of translucent cells in thick skin containing dead keratinocytes

_____ 2. two layers containing dead cells

_____ 3. dermal layer responsible for fingerprints

_____ 4. epidermal layer exhibiting the most rapid cell division

_____ 5. layer including scalelike dead cells, full of keratin, that constantly slough off

_____ 6. layer named for the numerous granules present

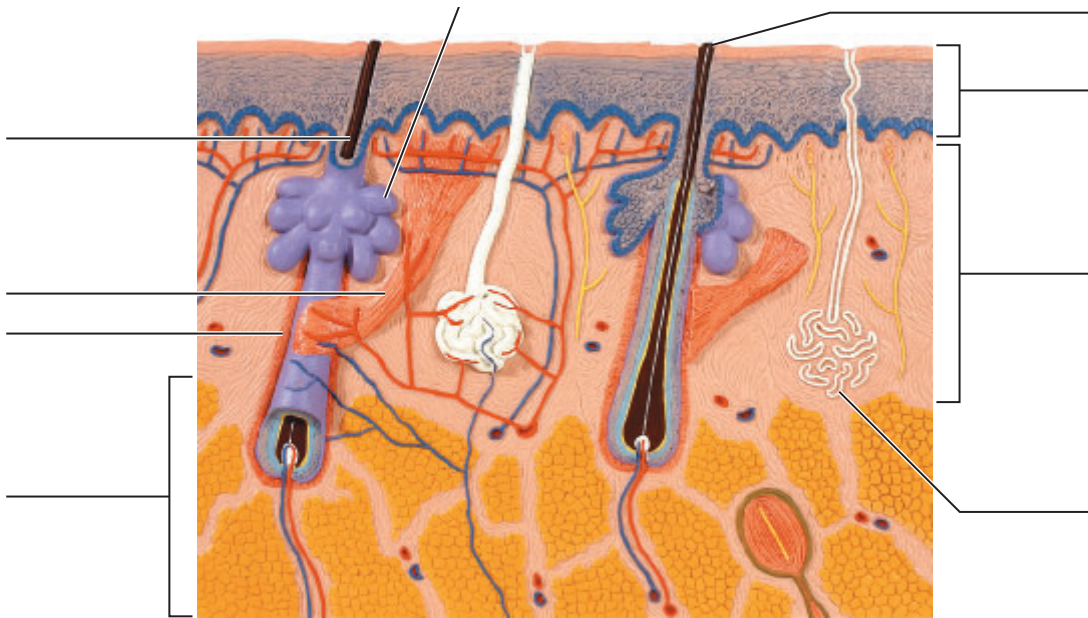
_____ 7. location of melanocytes and tactile epithelial cells

_____ 8. area where weblike pre-keratin filaments first appear

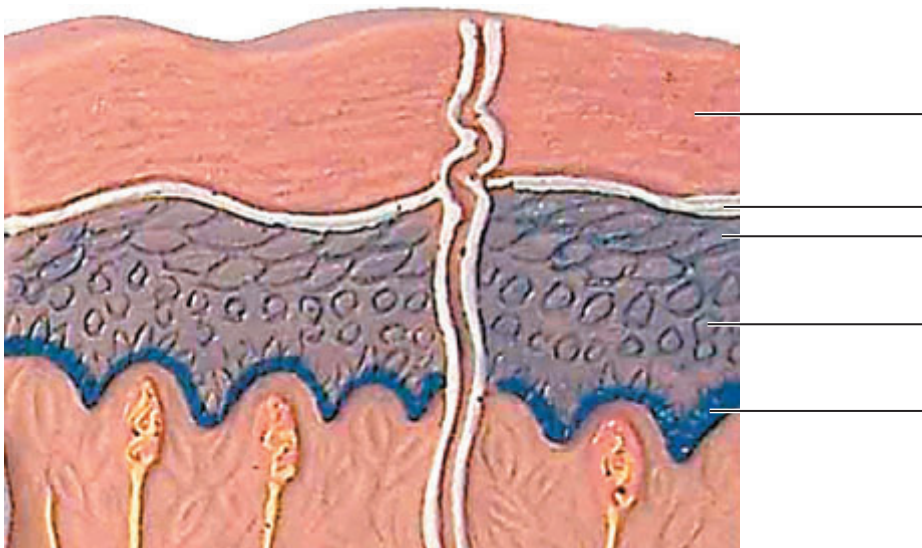
_____ 9. deep layer of the dermis

_____ 10. layer that secretes a glycolipid that prevents water loss from the skin

4. Label the integumentary structures and areas indicated in the diagram.



5. Label the layers of the epidermis in thick skin. Then, complete the statements that follow.



- a. Glands that respond to rising androgen levels are the _____ glands.
 - b. _____ are epidermal cells that play a role in the immune response.
 - c. Tactile corpuscles are located in the _____.
 - d. _____ corpuscles are located deep in the dermis.
6. What substance is manufactured in the skin and plays a role in calcium absorption elsewhere in the body?

7. What did the two-point discrimination test demonstrate? _____

8. Two questions regarding general sensation are posed below. Answer each by placing your response in the appropriately numbered blanks to the right.

1–2. Which two body areas tested were most sensitive to touch? 1–2. _____

3–4. Which two body areas tested were the least sensitive to touch? 3–4. _____

9. Define *adaptation of sensory receptors*: _____

10. Why is it advantageous to have pain receptors that are sensitive to all vigorous stimuli, whether heat, cold, or pressure?

Pain receptors do not adapt. Why is this important? _____

Accessory Organs of the Skin

11. Using the key, respond to the following descriptions. (Some responses may be used more than once.)

Key:	arrector pili	hair follicle	sweat gland—apocrine
	cutaneous receptor	nail	sweat gland—eccrine
	hair	sebaceous gland	

- _____ 1. acne is an infection of this structure
- _____ 2. structure that houses a hair
- _____ 3. more numerous variety of sweat gland that is activated by rise in temperature
- _____ 4. sheath formed of both epithelial and connective tissues
- _____ 5. type of sweat gland that produces a secretion containing proteins and fats in addition to water and salts
- _____ 6. smooth muscle connecting the hair follicle to the skin
- _____ 7. primarily dead/keratinized cells (two responses)
- _____ 8. specialized nerve ending that responds to environmental stimuli
- _____ 9. produces a secretion that contains cell fragments
- _____ 10. "sports" a lunule and a cuticle

12. How does the skin help to regulate body temperature? (Describe two different mechanisms.) _____


Plotting the Distribution of Sweat Glands


13. With what substance in the bond paper does the iodine painted on the skin react? _____

14. Which skin area—the forearm or palm of hand—has more sweat glands? _____

Which other body areas would, if tested, prove to have a high density of sweat glands? _____

15. Which organ system controls the activity of the eccrine sweat glands? _____

16.  Vitiligo is a disorder in which the pigmentation of the skin is uneven, resulting in white patches. Recent research suggests that vitiligo might be an autoimmune disorder. Which cell would you expect to be most affected, and why?

17.  Keratinase is an enzyme produced by dermatophytes. Which organs in the body would these pathogenic fungi tend to proliferate in, and why? _____

Overview of the Skeleton

Materials

- Disarticulated bones (identified by name or number) that demonstrate easily recognizable examples of the four bone classifications (long, short, flat, and irregular)
- Long bone sawed longitudinally (beef bone from a slaughterhouse, if possible, or prepared laboratory specimen)
- Disposable gloves
- Long bone soaked in 10% hydrochloric acid (or vinegar) until flexible
- Long bone baked at 250°F for more than 2 hours
- Three-dimensional model of microscopic structure of compact bone
- Articulated skeleton
- Leather belt or strap, china cups (old), several large reference-type books
- Demonstration area: Microscope set to view a cross section of ground bone at low power; pointer on central canal

Learning Outcomes

- List three functions of the skeletal system.
- Identify several surface bone markings and functions.
- Identify the four main groups of bones based on shape.
- Identify the major anatomical areas of a longitudinally cut long bone.
- Contrast the roles of inorganic salts and organic matrix in providing flexibility and hardness to bone.
- Identify the major parts of an osteon.

The **skeleton** is constructed of two of the most supportive tissues found in the human body—cartilage and bone. In embryos, the skeleton is composed mainly of hyaline cartilage, but in adults, most of the cartilage is replaced by more rigid bone.

Besides supporting the body as an internal framework and protecting many of its soft organs, the skeleton provides a system of levers the skeletal muscles use to move the body. In addition, the bones store lipids and many minerals (the most important is calcium). Finally, bones provide a site for blood cell formation in their red marrow.

The skeleton is made up of bones that are connected at joints, or articulations. The skeleton is subdivided into two divisions: the **axial skeleton** (those bones that form the body's longitudinal axis) and the **appendicular skeleton** (bones of the girdles and limbs) (**Figure 7.1**).

Before beginning your study of the skeleton, imagine for a moment that your bones have turned to putty. What if you were running when this transformation took place? Now imagine your bones forming a continuous metal framework inside your body. What problems could you foresee with this arrangement? These images should help you understand how well the skeletal system provides support and protection while making movement possible.

Bone Markings

Bone surfaces are not featureless and smooth. They have an array of bumps, holes, and ridges called **bone markings**. Bone markings fall into two main categories: projections, or processes that grow out from the bone and serve as sites of muscle attachment or help form joints; and depressions or cavities, indentations or openings in the bone that serve as passageways for nerves and blood vessels (**Table 7.1**).

Classification of Bones

The 206 bones of the adult skeleton are composed of two basic kinds of osseous tissue that differ in texture. **Compact bone** is dense and made up of organizational units called *osteons*. **Spongy bone** is composed of small *trabeculae* (columns) of bone and lots of open space.

Bones may be classified further on the basis of their gross anatomy into four main groups: long, short, flat, and irregular bones.

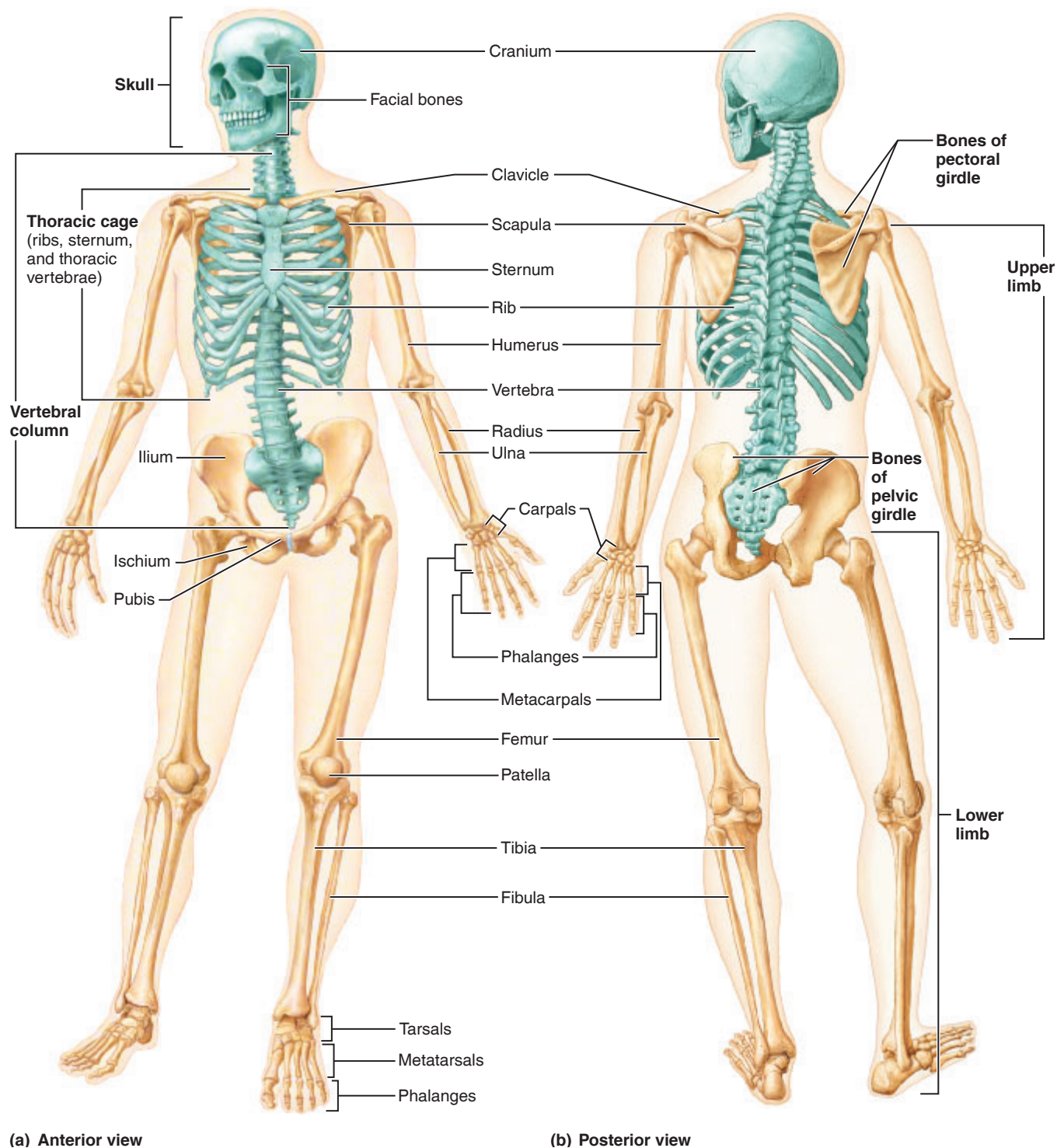


Figure 7.1 The human skeleton. The bones of the axial skeleton are colored green to distinguish them from the bones of the appendicular skeleton.

- **Long bones**, such as the femur (Figure 7.1), and bones of the fingers are much longer than they are wide and generally consist of a shaft with heads at either end. Long bones are mostly compact bone.
- **Short bones** are typically cube-shaped, and they contain more spongy bone than compact bone. For example, the tarsals and carpals are short bones (Figure 7.1).

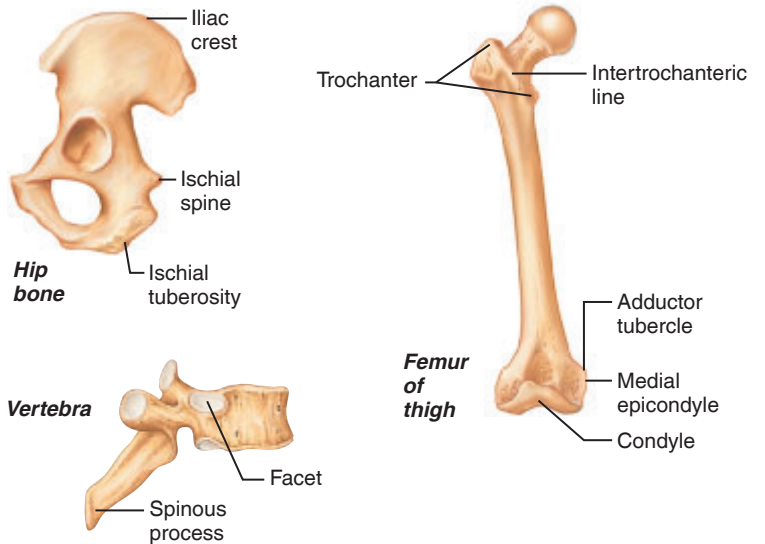
- **Flat bones** are generally thin, with a layer of spongy bone sandwiched between two waferlike layers of compact bone. Bones of the cranium are flat bones.
- **Irregular bones**, such as the vertebrae, are bones that do not fall into one of the preceding categories (see Figure 7.1 and Table 7.1).

Table 7.1 Bone Markings

Name of Bone Marking	Description	Illustrations
----------------------	-------------	---------------

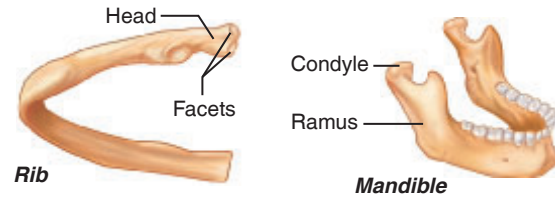
Projections That Are Sites of Muscle and Ligament Attachment

Tuberosity	Large rounded projection; may be roughened
Crest	Narrow ridge of bone; usually prominent
Trochanter	Very large, blunt, irregularly shaped process (the only examples are on the femur)
Line	Narrow ridge of bone; less prominent than a crest
Tubercle	Small rounded projection or process
Epicondyle	Raised area on or above a condyle
Spine	Sharp, slender, often pointed projection
Process	Any bony prominence



Projections That Help to Form Joints

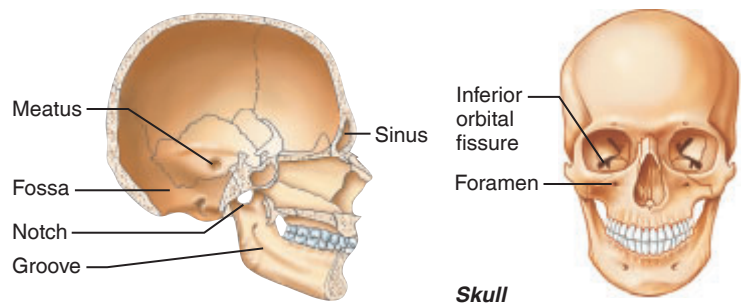
Head	Bony expansion carried on a narrow neck
Facet	Smooth, nearly flat articular surface
Condyle	Rounded articular projection
Ramus	Armlike bar of bone



Depressions and Openings

For Passage of Blood Vessels and Nerves

Groove	Furrow
Fissure	Narrow, slitlike opening
Foramen	Round or oval opening through a bone
Notch	Indentation at the edge of a structure



Others

Meatus	Canal-like passageway
Sinus	Cavity within a bone, filled with air and lined with mucous membrane
Fossa	Shallow, basinlike depression in a bone, often serving as an articular surface

Activity 1

Examining and Classifying Bones

Examine the isolated bones on display. See if you can find specific examples of the bone markings described in Table 7.1. Then classify each of the bones into one of the four anatomical groups by recording its name or number in the **Activity 1 chart**. Verify your identifications with your instructor before leaving the laboratory.

Activity 1: Classifying Bones			
Long	Short	Flat	Irregular

Gross Anatomy of the Typical Long Bone

Activity 2

Examining a Long Bone

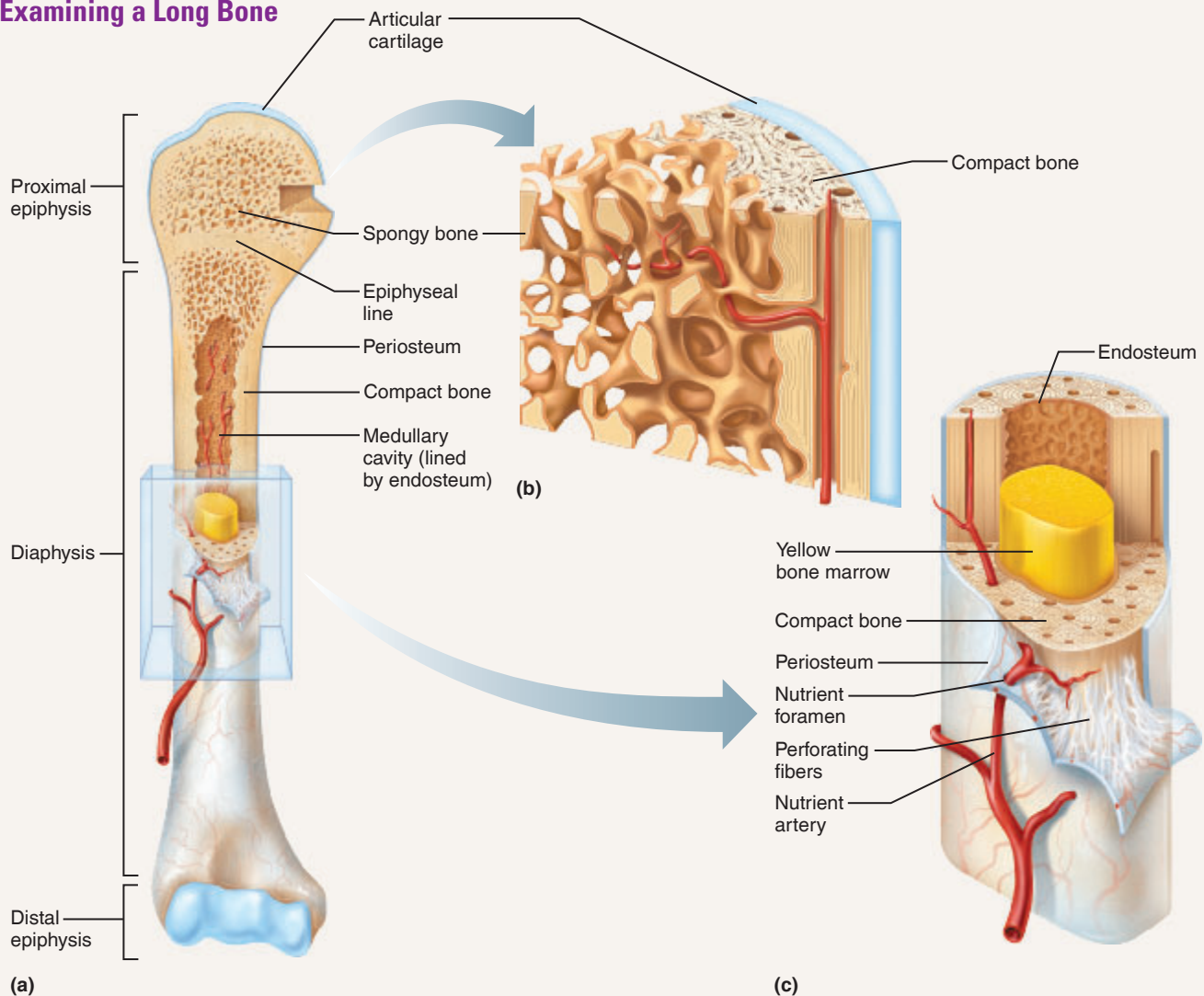


Figure 7.2 The structure of a long bone (humerus of the arm). **(a)** Anterior view with longitudinal section cut away at the proximal end. **(b)** Pie-shaped, three-dimensional view of spongy bone and compact bone of the epiphysis. **(c)** Cross section of the diaphysis. Note that the external surface of the diaphysis is covered by a periosteum, but the articular surface of the epiphysis is covered with hyaline cartilage.

1. Obtain a long bone that has been sawed lengthwise.



Note: If the bone supplied is a fresh beef bone, put on disposable gloves before beginning your observations. If a cleaned dry bone is provided, you do not need to take any special precautions.

Identify the shaft, or **diaphysis** (Figure 7.2). Observe its smooth surface composed of compact bone. If you are using a fresh specimen, look for its **periosteum**, a fibrous membrane composed of dense irregular connective tissue that covers the bone surface. Notice that many fibers of the periosteum penetrate into the bone. These fibers are called **perforating fibers**.

2. Now inspect the **epiphysis**, the end of the long bone. Notice that it is composed of a thin layer of compact bone enclosing spongy bone.

3. Identify the **articular cartilage**, which covers the epiphyseal surface in place of the periosteum. Because it is composed of glassy hyaline cartilage, it provides a smooth surface to prevent friction at joint surfaces.

4. If the animal was still young and growing, you will be able to see the **epiphyseal plate**, a thin area of hyaline cartilage that provides for growth in bone length. When long bone growth ends, these areas are replaced with bone. Their barely discernible remnants are called **epiphyseal lines**.

5. In an adult animal, the **medullary cavity**, the central cavity of the shaft, is essentially a storage region for adipose tissue, or **yellow bone marrow**. In the infant, **red bone marrow**, involved in forming blood cells, is found in these central marrow cavities. In adult bones, red bone marrow is seen in the spaces of the spongy bone at the epiphyses and the spongy bone within flat bones.

6. If you are examining a fresh bone, look carefully to see whether you can distinguish the delicate **endosteum** lining the medullary cavity.



7. If you have been working with a fresh bone specimen, return it to the appropriate area and properly dispose of your gloves, as designated by your instructor. Wash your hands before continuing to the microscope study.

Chemical Composition of Bone

Although it is relatively light, bone is one of the hardest materials in the body, and it has a remarkable ability to resist tension and shear forces that continually act on it. The intracellular material in bone is typically called the *bony matrix* and is composed of both organic and inorganic com-

ponents. The organic portion of the matrix is made up largely of collagen fibers, whereas the inorganic part is primarily calcium salts. Thus, nature has given us an extremely strong, exceptionally simple (almost crude), and flexible supporting system without sacrificing mobility.

Activity 3

Comparing the Relative Contributions of Bone Salts and Collagen Fibers in Bone Matrix

Go to the supply area and obtain a china cup, a leather belt or strap, and two or three large reference books. Carefully stack the books on the china cup to determine whether such a fragile-looking object can support the heavy books.

What happens? _____

Next, yank and pull on the leather belt (strap) a few times to see if you can break it.

What happens? _____

Which article—the cup or the belt—demonstrates the *compression strength* provided by bone salts?

Which item better illustrates the *tensile strength* (ability to resist stretch) provided by collagen fibers in bone?

Activity 4

Examining the Effects of Heat and Nitric Acid on Bones

Now, let's use another experimental approach to examine a bone's functional makeup. Obtain a bone sample that has been soaked in hydrochloric acid (or vinegar) and one that has been baked. Heating removes the organic part of bone,

whereas acid dissolves the minerals. Do the treated bones still have the shape of untreated specimens?

Text continues on next page. →

Gently apply pressure to each bone sample. What happens to the heated bone?

The bone treated with acid?

Microscopic Structure of Compact Bone

As you have seen, spongy bone has a spiky, open-work appearance due to the arrangement of the **trabeculae** that compose it, and compact bone appears dense and homogeneous on the

surface. However, compact bone is riddled with passageways carrying blood vessels and nerves that provide the living bone cells with needed substances and a way to eliminate wastes.

Activity 5

Examining the Microscopic Structure of Compact Bone

1. Go to the demonstration area to examine a prepared slide of ground bone under low power. Focus on a **central (Haversian) canal** (one is indicated by the microscope pointer). Use **Figure 7.3** as a guide. The central canal runs parallel to the long axis of the bone and carries blood vessels and nerves through the bony matrix. Identify the **lacunae** (chambers) where the **osteocytes** (mature bone cells) are found in living bone. These are arranged in concentric circles (**lamellae**) around the central canal. A central canal and all the lamellae surrounding it are referred to as an **osteon** or *Haversian system*. Also identify **canaliculi**, tiny canals running from a central canal to the lacunae of the first lamella and then from lamella to lamella. The canaliculi connect all the living cells of the osteon to the nutrient supply.

2. The superficial lamellae that run parallel to the bone's surface and do not comprise osteons are called **circumferential lamellae**. *Note:* These structures may not be visible on your individual slide. Refer to Figure 7.2a for an accurate representation.

3. Also notice the **perforating (Volkmann's) canals** (Figure 7.3). These canals run at right angles to the shaft and connect the blood and nerve supply of the medullary cavity to the central canals.

4. If a model of bone histology is available, identify the same structures on the model.

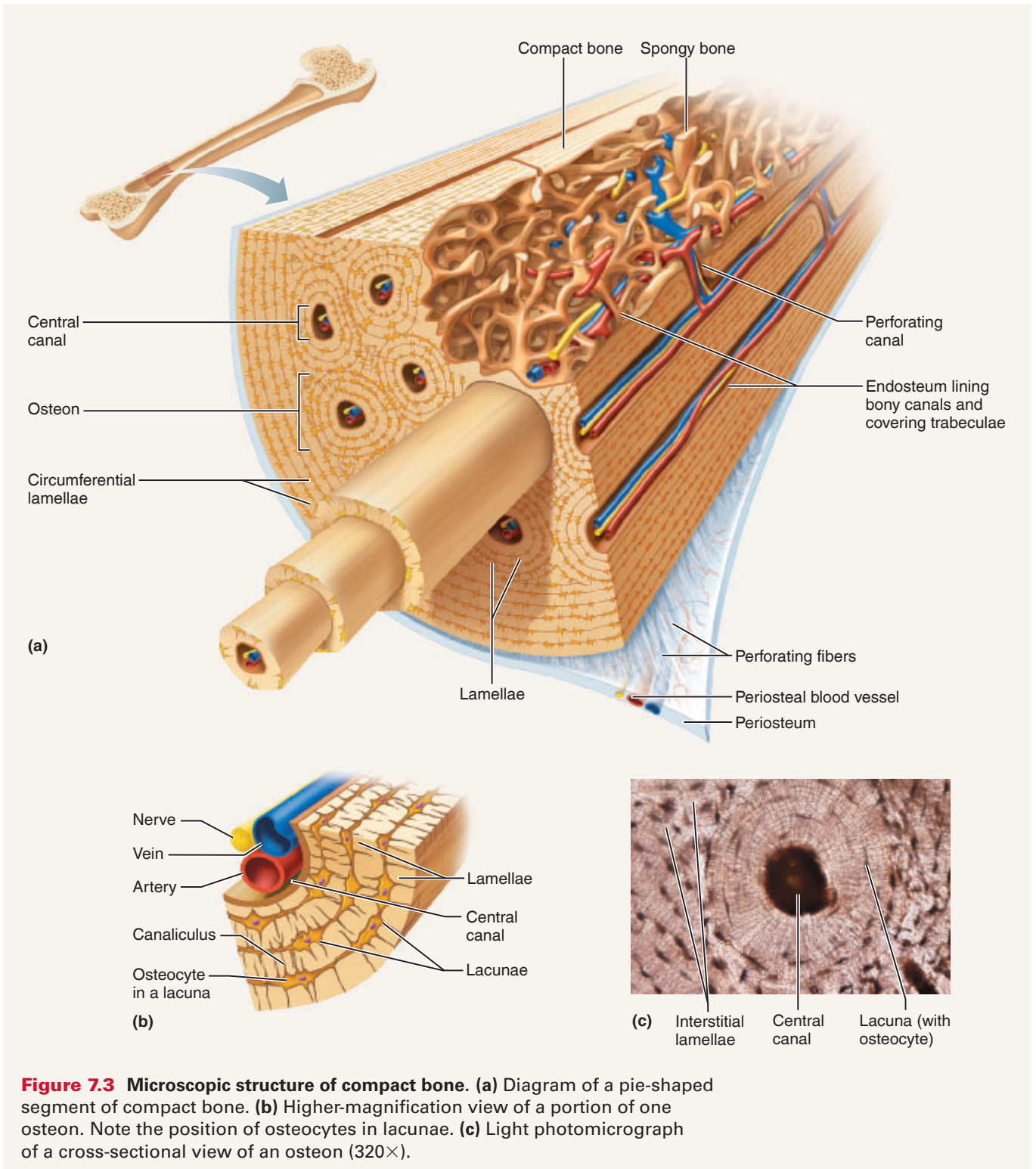


Figure 7.3 Microscopic structure of compact bone. **(a)** Diagram of a pie-shaped segment of compact bone. **(b)** Higher-magnification view of a portion of one osteon. Note the position of osteocytes in lacunae. **(c)** Light photomicrograph of a cross-sectional view of an osteon (320 \times).

This page intentionally left blank

EXERCISE
7

REVIEW SHEET

Overview of the Skeleton

Name _____ Lab Time/Date _____

Bone Markings

1. Match the terms in column B with the appropriate description in column A:

Column A	Column B
_____ 1. sharp, slender process	condyle
_____ 2. small rounded projection	foramen
_____ 3. large rounded projection	fossa
_____ 4. structure supported on neck	head
_____ 5. armlike projection	meatus
_____ 6. rounded, convex projection	ramus
_____ 7. canal-like structure	sinus
_____ 8. opening through a bone	spine
_____ 9. shallow depression	trochanter
_____ 10. air-filled cavity	tubercle
_____ 11. large, irregularly shaped projection	tuberosity

Classification of Bones

2. The four major anatomical classifications of bones are long, short, flat, and irregular. Which category has the least amount of spongy bone relative to its total volume? _____

3. Classify each of the bones in the chart below as either long, short, flat, or irregular by placing a check mark in the appropriate column. Also use a check mark to indicate whether the bone is a part of the axial or the appendicular skeleton. Use Figure 7.1 as a guide.

	Long	Short	Flat	Irregular	Axial skeleton	Appendicular skeleton
Sternum						
Radius						
Calcaneus (tarsal bone)						
Parietal bone (cranial bone)						
Phalanx (single bone of a digit)						
Vertebra						

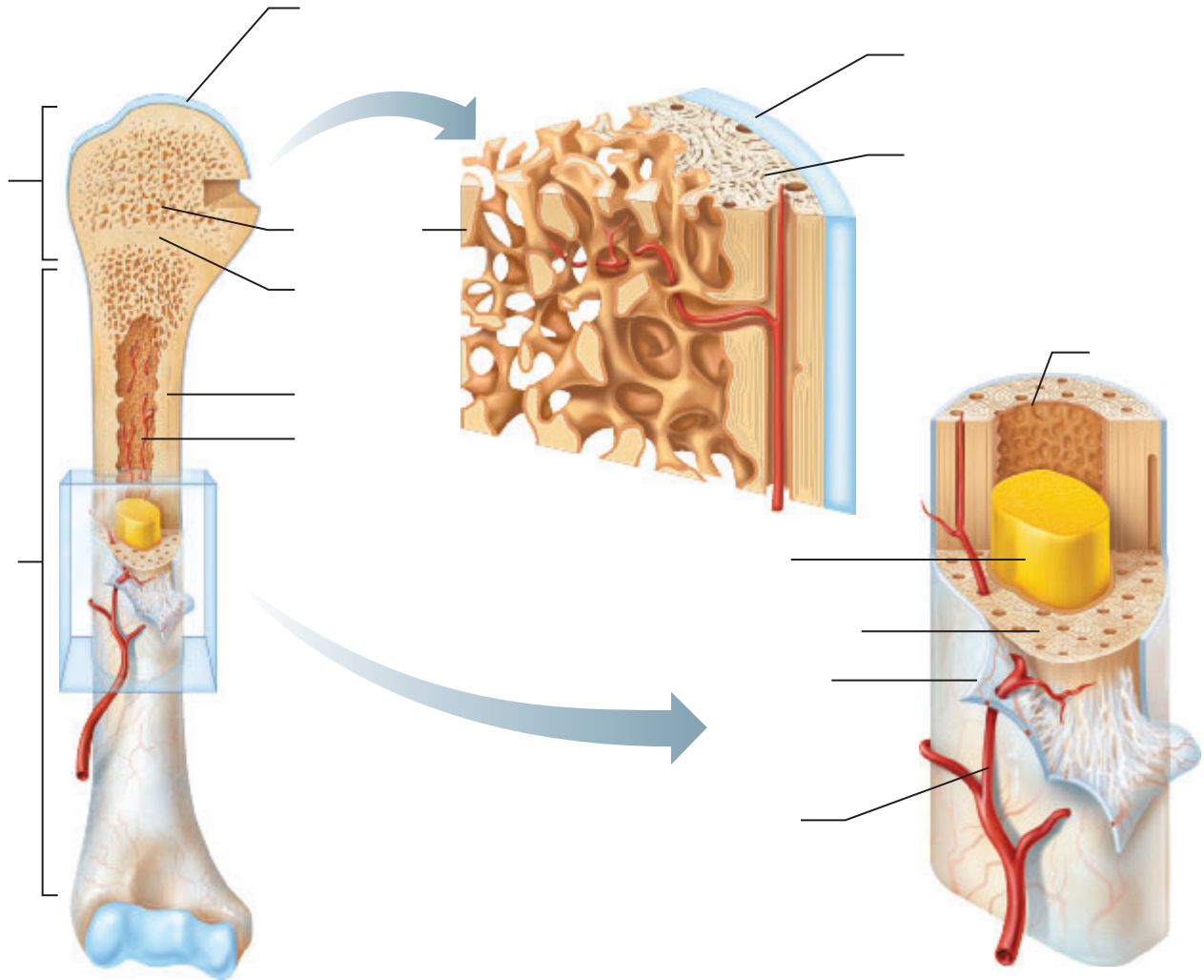
Gross Anatomy of the Typical Long Bone

4. Use the terms below to identify the structures marked by leader lines and brackets in the diagrams (some terms are used more than once). After labeling the diagrams, use the listed terms to characterize the statements following the diagrams.

Key: articular cartilage
compact bone
diaphysis
endosteum

epiphyseal line
epiphysis
medullary cavity
nutrient artery

periosteum
spongy bone
yellow bone marrow



- _____ 1. made almost entirely of compact bone
- _____ 2. site of blood cell formation
- _____ 3. fibrous membrane that covers the bone

- _____ 4. end portion of a long bone
- _____ 5. contains yellow bone marrow in adult bones
- _____ 6. growth plate remnant

5. What differences between compact and spongy bone can be seen with the naked eye? _____

Chemical Composition of Bone

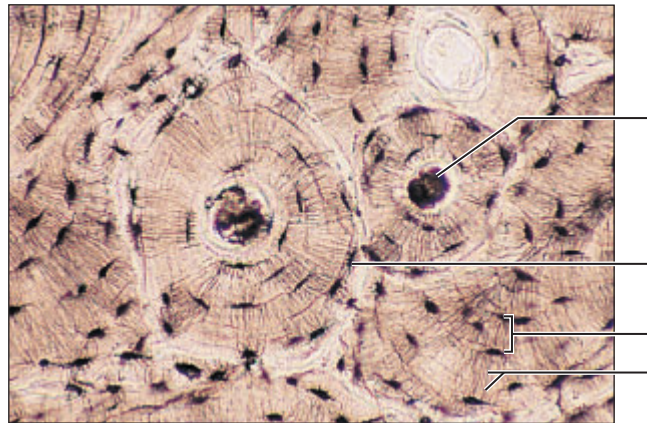6. What is the function of the organic matrix in bone? _____
7. Name the important organic bone components. _____
8. Calcium salts form the bulk of the inorganic material in bone. What is the function of the calcium salts?

9. Which is responsible for bone structure? (circle the appropriate response)
inorganic portion (bone salts) organic portion both contribute

Microscopic Structure of Compact Bone

10. On the photomicrograph of bone below, identify all structures listed in the key to the left.

Key: canaliculi
central canal
lacuna
lamella



11. **+** The pain in the leg that is referred to as “shin splints” is often caused by microtears in the periosteum and perforating fibers. These tears lead to inflammation of the periosteum. Considering the type of tissue found in the periosteum, which cells do you think would be most involved in the repair process?

12. **+** In a child with rickets, the bones are not properly calcified. Which treated bone in Activity 4 most closely resembles the bones of a child with rickets? Why? _____

This page intentionally left blank

The Axial Skeleton

Materials

- Intact skull and Beauchene skull
- X-ray images of individuals with scoliosis, lordosis, and kyphosis (if available)
- Articulated skeleton, articulated vertebral column
- Isolated cervical, thoracic, and lumbar vertebrae; sacrum; and coccyx

Learning Outcomes

- Identify the bones of the axial skeleton either by examining disarticulated bones or by pointing them out on an articulated skeleton, and name the important markings on each.
- Discuss the importance of the intervertebral discs and spinal curvatures.
- Distinguish the different types of vertebrae.

The **axial skeleton** (the green portion of Figure 7.1 on page 68) can be divided into three parts: the skull, the vertebral column, and the thoracic cage.

The Skull

The **skull** is composed of two sets of bones—the **cranial bones** and the **facial bones**. All but one of the bones of the skull are joined by interlocking joints called *sutures*. Only the mandible, or lower jawbone, is attached to the rest of the skull by a freely movable joint. Be sure to observe how many cranial and facial bones contribute to the orbit (eye socket).

Activity 1

Identifying the Bones of the Adult Skull

The bones of the skull (**Figures 8.1, 8.2, 8.3, and 8.4**) are described in **Tables 8.1 and 8.2** on pages 80–82. As you read through this material, identify each bone on a skull.

Note: *Important bone markings are listed in the tables for the bones on which they appear, and each bone name is colored to correspond to the bone color in the figures.*

The Cranium

Eight large flat bones construct the cranium, which encloses and protects the brain. *With the exception of two paired bones (the parietals and the temporals), all are single bones.*

Major Sutures

- **Sagittal suture:** Occurs where the left and right parietal bones meet superiorly.
- **Coronal suture:** Located where the parietal bones articulate with the frontal bone anteriorly.
- **Squamous suture:** Occurs where a parietal bone and temporal bone meet on the lateral aspect of the skull.
- **Lambdoid suture:** Occurs where the parietal bones meet the occipital bone posteriorly.

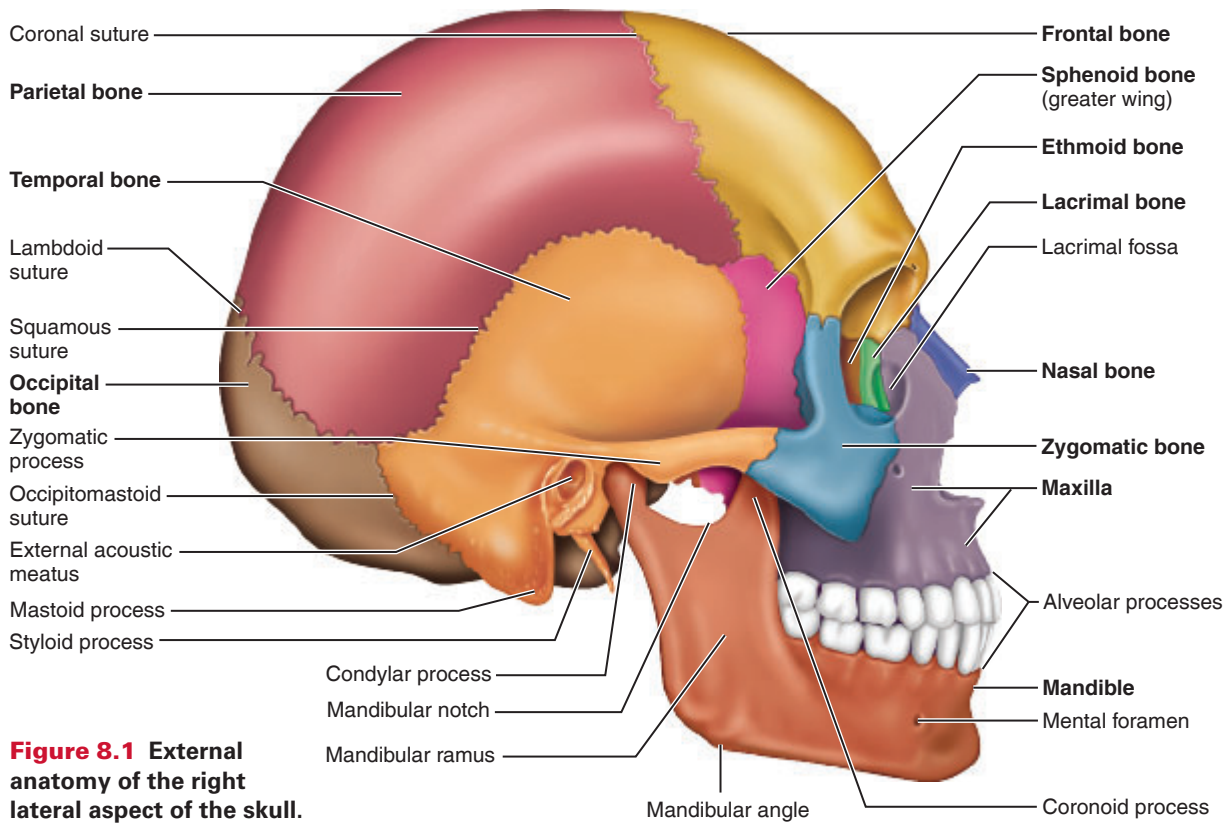


Figure 8.1 External anatomy of the right lateral aspect of the skull.

Table 8.1A The Axial Skeleton: Cranial Bones and Important Bone Markings

Cranial bone	Important markings	Description
Frontal (1) Figures 8.1, 8.2, and 8.4	N/A	Forms the forehead, superior part of the orbit, and the floor of the anterior cranial fossa.
	Supraorbital foramen (notch)	Opening above each orbit allowing blood vessels and nerves to pass.
Parietal (2) Figures 8.1 and 8.2	N/A	Form the superior and lateral aspects of the skull.
Temporal (2) Figures 8.1, 8.2, and 8.3	N/A	Form the inferolateral aspects of the skull and contribute to the middle cranial fossa; each has squamous, tympanic, and petrous parts.
	Zygomatic process	A bridgelike projection that articulates with the zygomatic bone to form the zygomatic arch.
	Mandibular fossa	Located on the inferior surface of the zygomatic process; receives the condylar process of the mandible to form the temporomandibular joint.
	External acoustic meatus	Canal leading to the middle ear and eardrum.
	Styloid process	Needlelike projection that serves as an attachment point for ligaments and muscles of the neck.
	Jugular foramen	Located where the petrous part of the temporal bone joins the occipital bone. Forms an opening through which the internal jugular vein and cranial nerves IX, X, and XI pass.
	Carotid canal	Opening through which the internal carotid artery passes into the cranial cavity.
	Mastoid process	Located posterior to the external acoustic meatus; serves as an attachment point for neck muscles.
Occipital (1) Figures 8.1, 8.2, and 8.3	N/A	Forms the posterior aspect and most of the base of the skull.
	Foramen magnum	Large opening in the base of the bone, which allows the spinal cord to join with the brain stem.
	Occipital condyles	Rounded projections lateral to the foramen magnum that articulate with the first cervical vertebra (atlas).

The number in parentheses () following the bone name indicates the total number of such bones in the body.

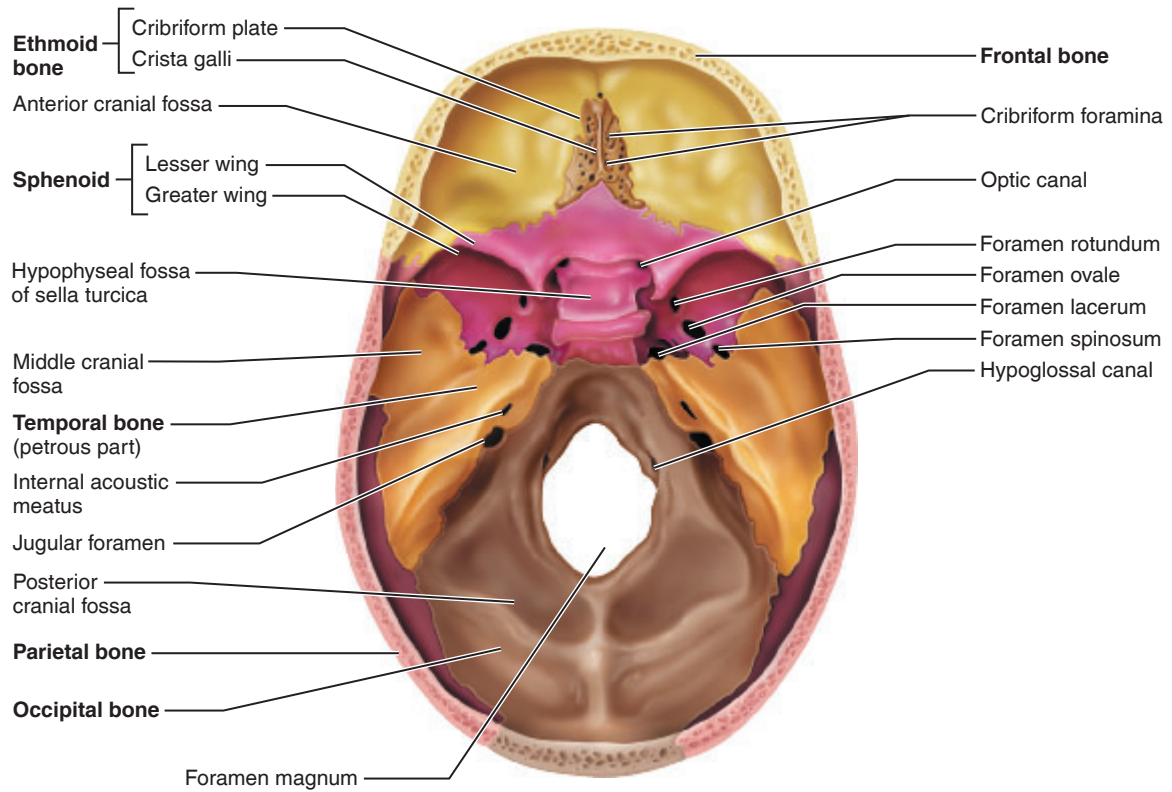


Figure 8.2 Internal anatomy of the inferior portion of the skull, calvaria removed.

Table 8.1B The Axial Skeleton: Cranial Bones and Important Bone Markings		
Cranial bone	Important markings	Description
Sphenoid bone (1) Figures 8.1, 8.2, 8.3, and 8.4	N/A	Bat-shaped bone that is described as the keystone bone of the cranium because it articulates with all other cranial bones.
	Greater wings	Project laterally from the sphenoid body, forming parts of the middle cranial fossa and the orbits.
	Pterygoid processes	Project inferiorly from the greater wings; attachment site for chewing muscles (pterygoid muscles).
	Superior orbital fissures	Slits in the orbits providing passage of cranial nerves that control eye movements (III, IV, VI, and the ophthalmic division of V).
	Sella turcica	“Turkish saddle” located on the superior surface of the body; the seat of the saddle, called the <i>hypophyseal fossa</i> , holds the pituitary gland.
	Lesser wings	Form part of the floor of the anterior cranial fossa and part of the orbit.
	Optic canals	Openings in the base of the lesser wings; cranial nerve II (optic nerve) passes through to serve the eye.
	Foramen ovale	Openings located posterior to the sella turcica; a branch of cranial nerve V (mandibular division) passes through.
Ethmoid (1) Figures 8.1, 8.2, and 8.4	N/A	Contributes to the anterior cranial fossa; forms part of the nasal septum and the nasal cavity; contributes to the medial wall of the orbit.
	Crista galli	“Rooster’s comb”; a superior projection that attaches to the dura mater, helping to secure the brain within the skull.
	Cribriform foramina	Tiny holes in the cribriform plates that allow for the passage of filaments of cranial nerve I (olfactory nerve).
	Perpendicular plate	Inferior projection that forms the superior portion of the nasal septum.
	Superior and middle nasal conchae	Act as turbinates to improve airflow through the nasal cavity.

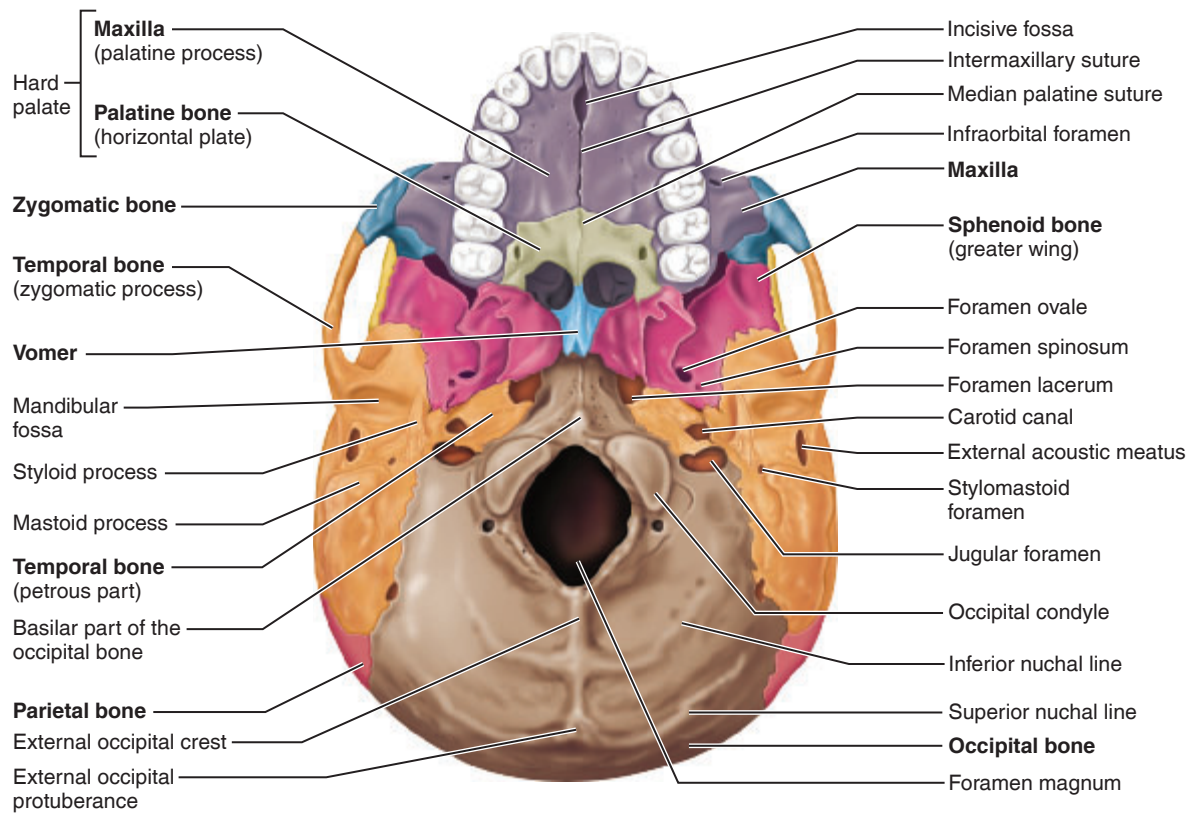


Figure 8.3 Inferior view of the skull, mandible removed.

Table 8.2 The Axial Skeleton: Facial Bones and Important Bone Markings (Figures 8.1, 8.3, and 8.4)

Facial bone	Important markings	Description
Nasal (2)	N/A	Small rectangular bones forming the bridge of the nose.
Lacrimal (2)	N/A	Each forms part of the medial orbit in between the maxilla and ethmoid bone.
	Lacrimal fossa	Houses the lacrimal sac, which helps to drain tears from the nasal cavity.
Zygomatic (2)	N/A	Commonly called the cheekbones; each forms part of the lateral orbit.
Inferior nasal concha (2)	N/A	Inferior turbinate; each forms part of the lateral walls of the nasal cavities; improves the airflow through the nasal cavity.
Palatine (2)	N/A	Forms the posterior hard palate, part of the nasal cavity, and part of the orbit.
Vomer (1)	N/A	Thin, blade-shaped bone that forms the inferior nasal septum.
Maxilla (2)	N/A	Keystone bones because they articulate with all facial bones except the mandible; form the upper jaw and parts of the palate, orbits, and nasal cavity.
	Palatine process	Forms the anterior hard palate; meet anteriorly in the intermaxillary suture.
	Alveolar process	Inferior margin of the maxilla; contains sockets in which the teeth lie.
Mandible (1)	N/A	The lower jawbone, which articulates with the temporal bone to form the only freely movable joints in the skull (the temporomandibular joint).
	Condylar processes	Articulate with the mandibular fossae of the temporal bones.
	Coronoid processes	“Crown-shaped” portion of the ramus for muscle attachment.
	Mandibular notches	Separate the condylar process and the coronoid process.
	Body	Horizontal portion that forms the chin.
	Ramus	Vertical extension of the body.
	Alveolar process	Superior margin of the mandible; contains sockets in which the teeth lie.

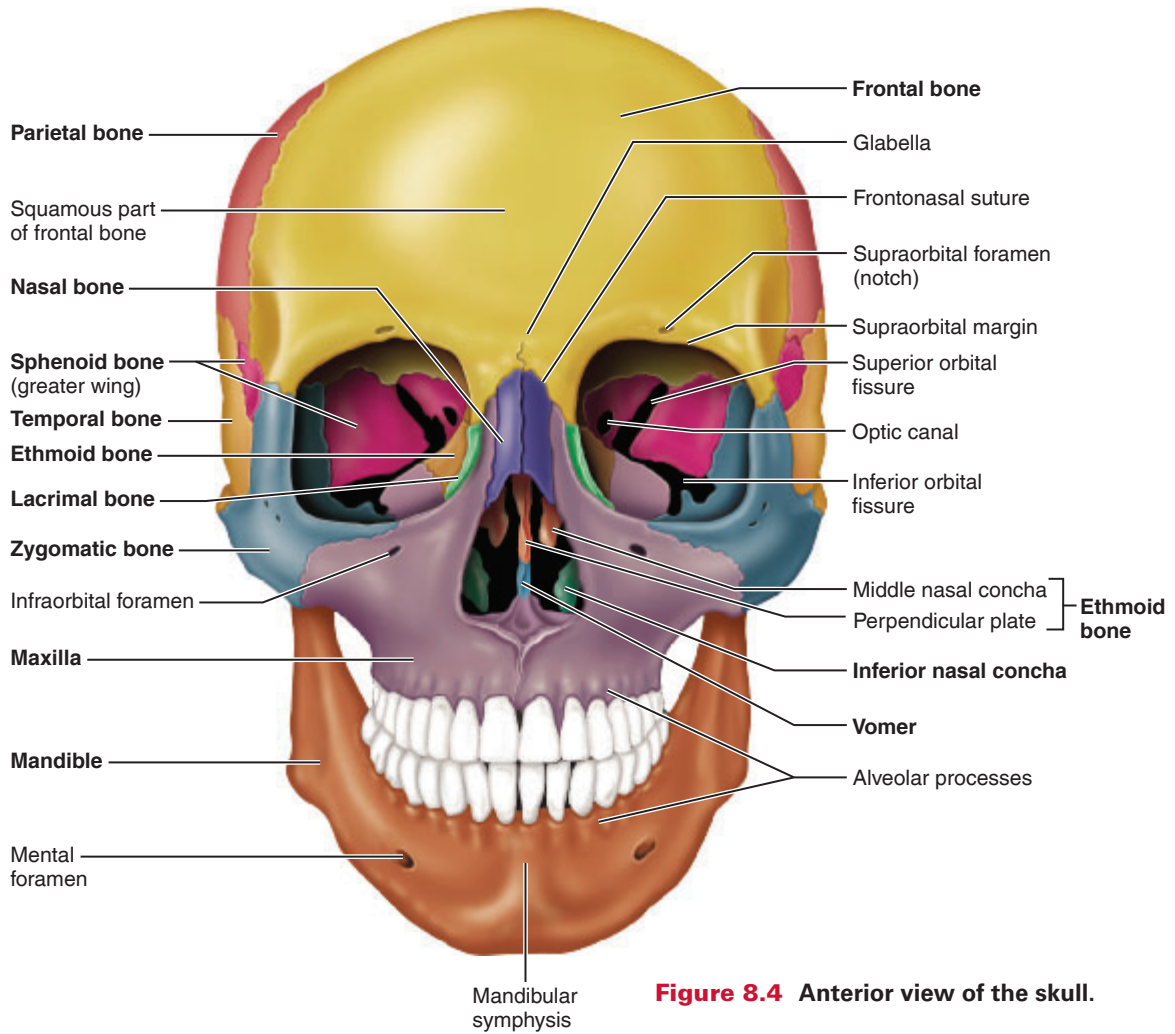


Figure 8.4 Anterior view of the skull.

8

Facial Bones

The facial bones form the base for the muscles of the face, which allow us to show our feelings to the world and to chew our food. Of the 14 bones composing the face, 12 are paired. *Only the mandible and vomer are single bones.*

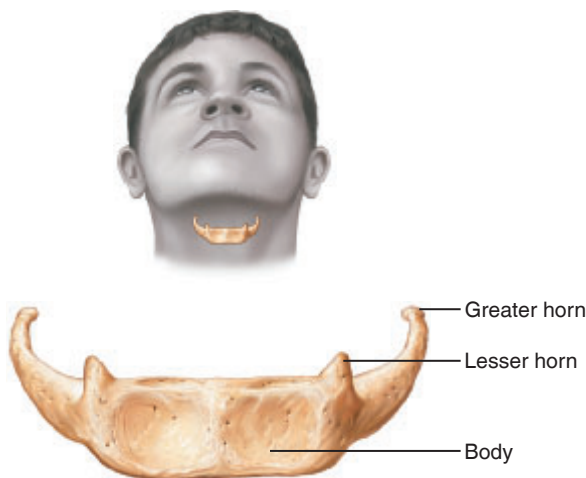


Figure 8.5 Hyoid bone.

Hyoid Bone

The hyoid bone is not really considered or counted as a skull bone. Located in the throat above the larynx (Figure 8.5), it is the point of attachment for many tongue and neck muscles. The hyoid bone is horseshoe-shaped with a body and two pairs of horns, or **cornua**.

Paranasal Sinuses

Five skull bones—the frontal, sphenoid, ethmoid, and paired maxillary bones—contain mucus-lined, air-filled cavities called **paranasal sinuses** (Figure 8.6). These paranasal sinuses lighten facial bones and may act as resonance chambers for speech. The maxillary sinus is the largest of the sinuses found in the skull.

Activity 2

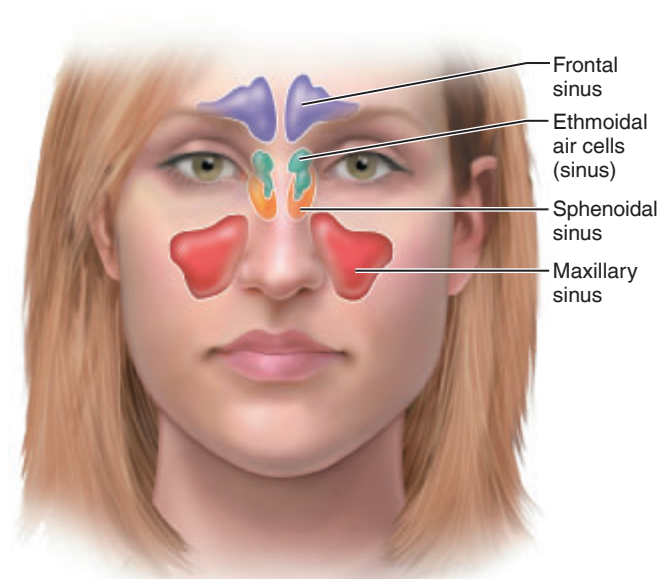
Palpating Skull Markings

Palpate the following areas on yourself. Place a check mark in the boxes as you locate the skull markings.

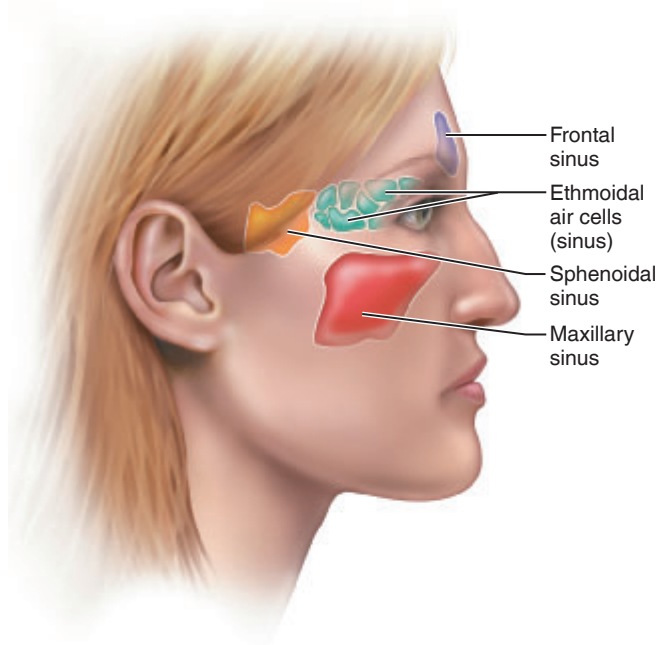
- Zygomatic bone and arch. Run your hand anteriorly from your ear toward your eye and feel the zygomatic arch at the high point of your cheek.
- Mastoid process (the rough area behind your ear).

Text continues on next page. →

- Temporomandibular joint. Place your finger directly in front of the external auditory meatus, and open and close your jaws to feel this joint in action.
- Greater wing of sphenoid. Find the indented area posterior to the orbit and superior to the zygomatic arch.
- Mandibular angle (most inferior and posterior aspect of your lower jaw).
- Nasal bones. Run your index finger and thumb along opposite sides of the bridge of your nose until they “slip” medially at the inferior end of the nasal bones.



(a)



(b)

Figure 8.6 Paranasal sinuses. (a) Anterior “see-through” view. (b) As seen in a medial view of the head.

The Vertebral Column

The **vertebral column**, also called the *spine*, extends from the skull to the pelvis. It forms the body’s major axial support, and it surrounds and protects the delicate spinal cord.

The vertebral column consists of 24 single bones called **vertebrae** and two bones that are formed of fused vertebrae (the sacrum and coccyx) that are connected in such a way as to provide a flexible curved structure (**Figure 8.7**). Of the 24 single vertebrae, the 7 bones of the neck are called *cervical vertebrae*; the next 12 are *thoracic vertebrae*; and the 5 supporting the lower back are *lumbar vertebrae*. Remembering

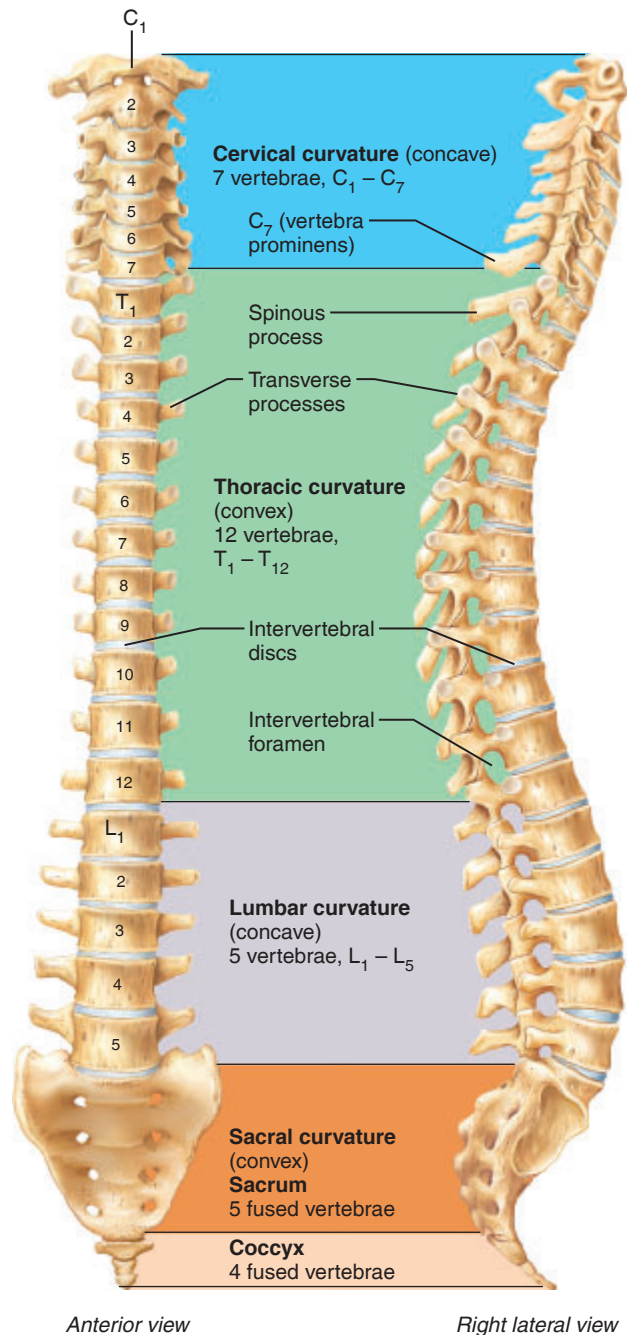


Figure 8.7 The vertebral column. Notice the curvatures in the lateral view. (Convex and concave refer to the curvature of the posterior aspect of the vertebral column.)

common mealtimes for breakfast, lunch, and dinner (7 A.M., 12 noon, and 5 P.M.) may help you to remember the number of bones in each region.

The individual vertebrae are separated by pads of fibrocartilage, **intervertebral discs**, that absorb shocks while providing the spine flexibility. Each disc has two major regions: a central gelatinous region that behaves like a rubber ball and an outer ring of tough collagen fibers that stabilizes the disc. As a person ages, the water content of the discs decreases and the discs become thinner and less compressible.

The discs and the S-shaped or springlike construction of the vertebral column help prevent shock to the head during walking and running and make the body trunk flexible.

Activity 3

Examining Spinal Curvatures

1. Observe the normal curves of the vertebral column in your laboratory specimen, and compare it to the figure of the vertebral column (Figure 8.7). Then examine the figure depicting three abnormal spinal curvatures—*scoliosis*, *kyphosis*, and *lordosis* (Figure 8.8). These abnormalities may result from disease or poor posture. Also examine X-ray images showing these same conditions in a living person, if they are available.

2. Next, using an articulated vertebral column (or an articulated skeleton), examine the freedom of movement between two lumbar vertebrae separated by an intervertebral disc.

When the disc is properly positioned, are the spinal cord or peripheral nerves impaired in any way?

Remove the disc, and put the two vertebrae back together. What happens to the nerve?

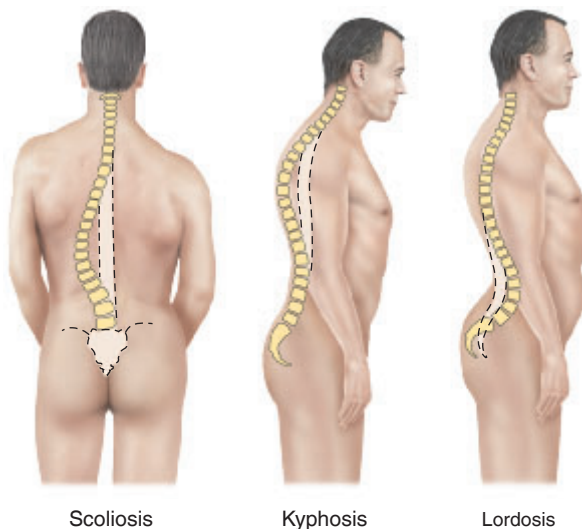


Figure 8.8 Abnormal spinal curvatures.

What might happen to the spinal nerves in areas of malpositioned, or “slipped,” discs?

Structure of a Typical Vertebra

Although they differ in size and specific features, all vertebrae have some common features (Figure 8.9).

Body: Rounded central weight-bearing portion of the vertebra; faces anteriorly in the human vertebral column.

Vertebral arch: Composed of two pedicles and two laminae.

Vertebral foramen: Opening enclosed by the body and vertebral arch through which the spinal cord passes.

Transverse processes: Two lateral projections from the vertebral arch.

Spinous process: Single posterior projection formed at the junction of the two laminae.

Superior and inferior articular processes: Paired projections lateral to the vertebral foramen that enable adjacent vertebrae to articulate with one another.

Figures 8.10 and 8.11 show how specific vertebrae differ; refer to them as you read the following sections.

Cervical Vertebrae

The seven cervical vertebrae (C_1 through C_7) form the neck portion of the vertebral column (Figure 8.10a). The first two cervical vertebrae (atlas and axis) are modified to perform special functions. The **atlas** (C_1) lacks a body, and its lateral processes contain large depressions on their superior surfaces that receive the occipital condyles of the skull. This joint enables you to nod “yes.” The **axis** (C_2) acts as a pivot for rotation of the atlas (and skull) above. Its large vertical process, the **dens** acts as the pivot point. The joint between C_1 and C_2 allows you to rotate your head from side to side to indicate “no.”

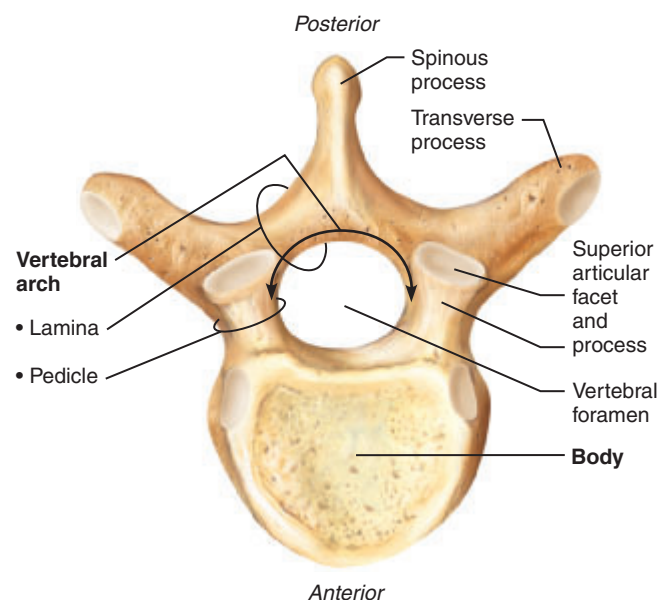


Figure 8.9 A typical vertebra, superior view. Inferior articulating surfaces not shown.

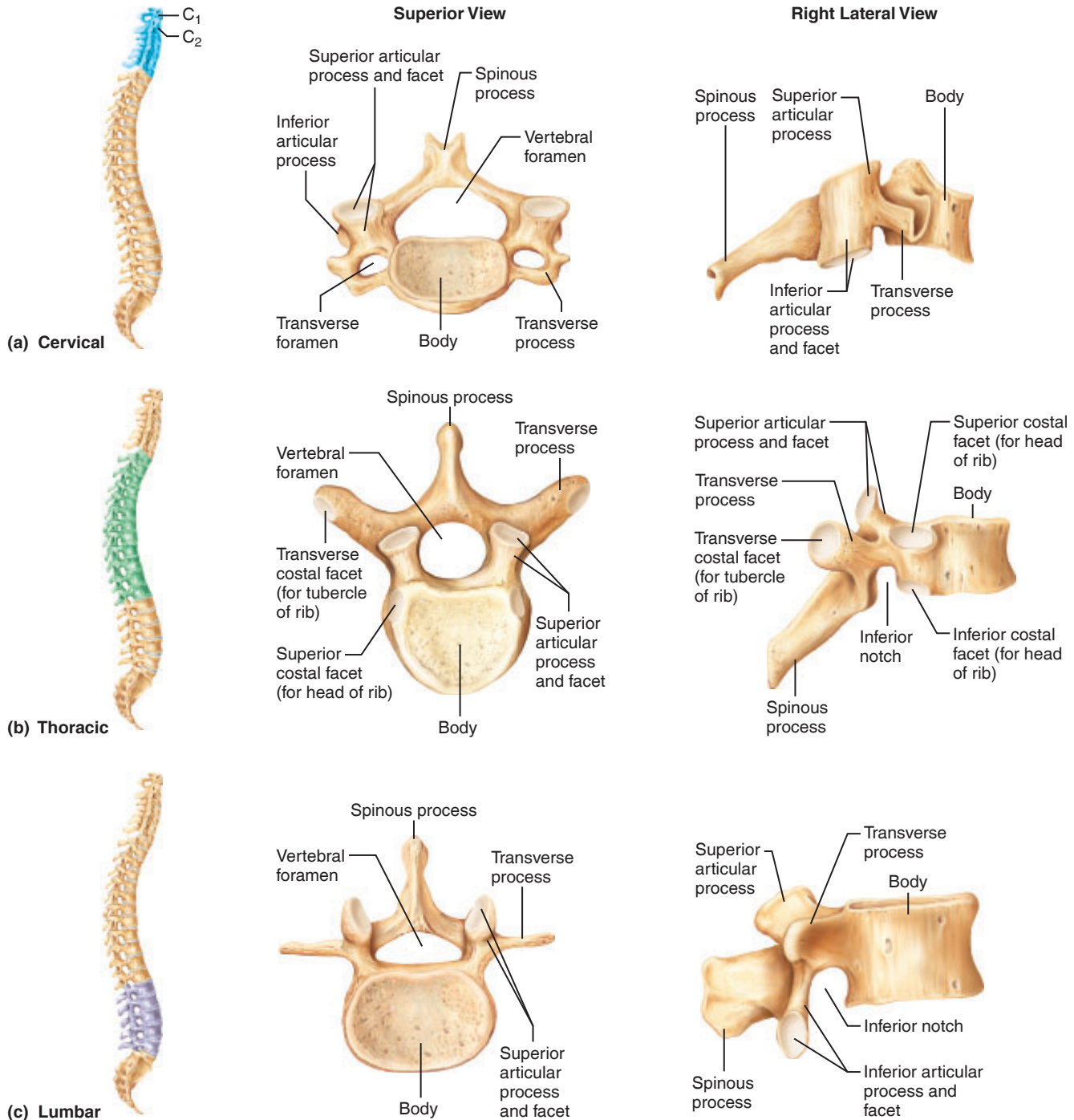


Figure 8.10 Regional characteristics of vertebrae.

The more typical cervical vertebrae (C_3 through C_7) are the smallest, lightest vertebrae. The vertebral foramen is triangular and the spinous process is short and often bifid, or split, into two branches. Transverse processes of the cervical vertebrae contain foramina through which the vertebral arteries pass superiorly to the brain. Any time you see these foramina in a vertebra, you can be sure that it is a cervical vertebra.

Activity 4

Palpating the Spinous Processes

Run your fingers inferiorly along the midline of the back of your neck to feel the *spinous processes* of the cervical vertebrae. The spine of C_7 is especially prominent, which is why this vertebra is sometimes called the *vertebra prominens*.

Thoracic Vertebrae

The 12 thoracic vertebrae (T_1 through T_{12}) have a larger body than the cervical vertebrae (Figure 8.10b). The body is somewhat heart shaped, with two small articulating surfaces, or *costal facets*, on each side (one superior, the other inferior) that articulate with the heads of the corresponding ribs. The vertebral foramen is oval or round, and the spinous process is long, with a sharp downward hook. These vertebrae form the thoracic part of the spine and the posterior aspect of the thoracic cage. They are the only vertebrae that articulate with the ribs.

Lumbar Vertebrae

The five lumbar vertebrae (L_1 through L_5) have massive blocklike bodies and short, thick, hatchet-shaped spinous processes extending directly backward (Figure 8.10c). Because the lumbar region is subjected to the most stress, these are also the sturdiest of the vertebrae.

Activity 5

Examining Vertebral Structure

Obtain examples of each type of vertebra and examine them carefully, comparing them to the figures (Figures 8.10 and 8.11) and to each other.

The Sacrum

The **sacrum** (Figure 8.11), formed from the fusion of five vertebrae, is the posterior border of the pelvis. Superiorly it articulates with L_5 , and inferiorly it connects with the coccyx. The **median sacral crest** is a remnant of the spinous processes of the fused vertebrae. The winglike **alae** articulate laterally with the hip bones, forming the sacroiliac joints (see the auricular surface in Figure 8.11). The **anterior** and **posterior sacral foramina** are additional evidence that the sacrum is formed of separate fused vertebrae and serve as passageways for blood vessels and nerves. The vertebral canal continues inside the sacrum as the **sacral canal** and terminates near the coccyx in the **sacral hiatus**. The **sacral promontory** is an important anatomical landmark for obstetricians.

The Coccyx

The **coccyx** (see Figure 8.11) results from the fusion of three to five small, irregularly shaped vertebrae. Literally the human tailbone, it is a remnant of the tail that other vertebrates have.

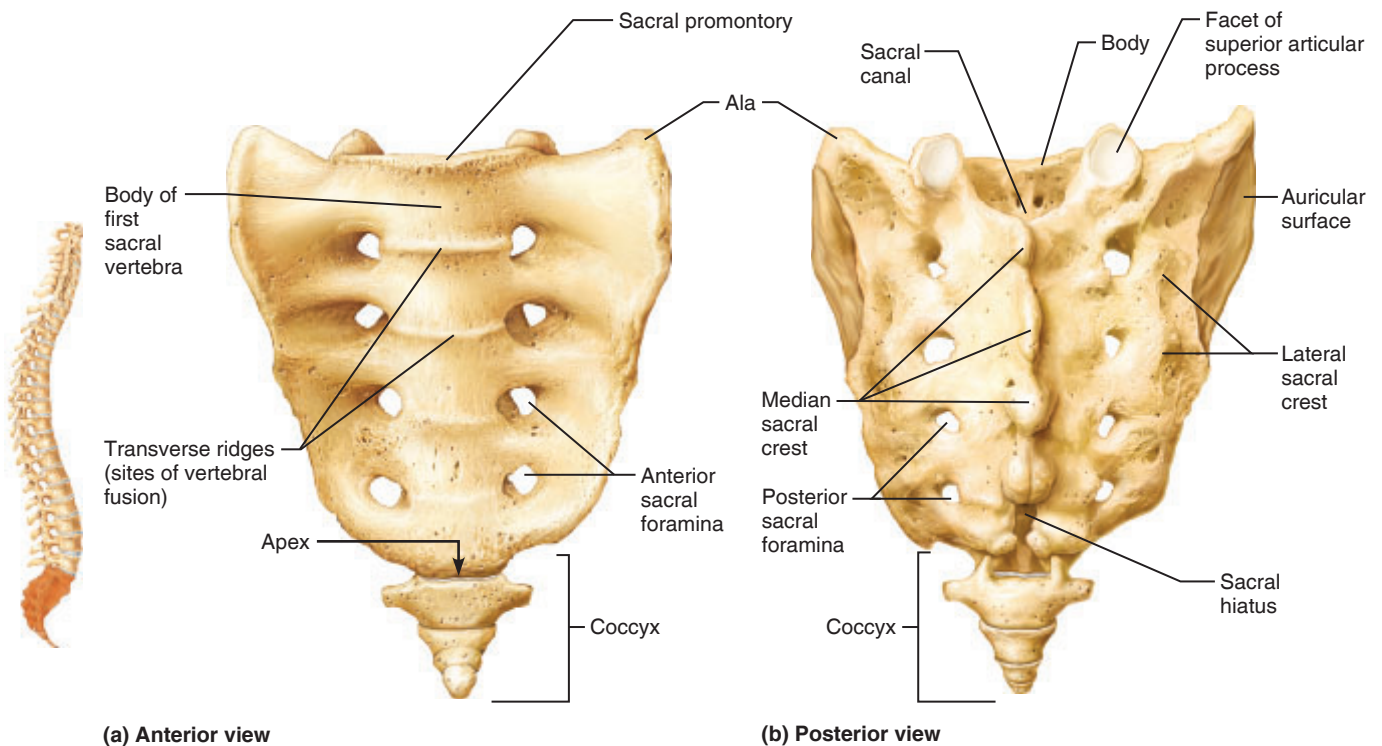


Figure 8.11 Sacrum and coccyx.

The Thoracic Cage

The **thoracic cage** is composed of the sternum, ribs, and thoracic vertebrae (**Figure 8.12**). It forms a protective cone-shaped enclosure around the organs of the thoracic cavity, including the heart and lungs.

The Sternum

The **sternum** (breastbone), a typical flat bone, is a result of the fusion of three bones. From superior to inferior, these are the manubrium, body, and xiphoid process. The sternum is attached to the first seven pairs of ribs. The **manubrium** looks like the knot of a tie; it articulates with the clavicle (collarbone) laterally. The **body** forms most of the sternum. The **xiphoid process**, at the inferior end of the sternum, lies at the level of the fifth intercostal space.

The Ribs

Twelve pairs of **ribs** form the walls of the thoracic cage (see **Figure 8.12**). All ribs articulate posteriorly with the vertebral column at two locations, the body and transverse processes

of the thoracic vertebrae. They then curve downward and toward the anterior body surface. The first seven pairs, called the *true ribs*, attach directly to the sternum by their “own” costal cartilages. The next five pairs are called *false ribs*. Of these, rib pairs 8–10 have *indirect* cartilage attachments to the sternum. The last two pairs, also called *floating ribs*, have *no* sternal attachment.

Activity 6

Examining the Relationship Between Ribs and Vertebrae

First, take a deep breath to expand your chest. Notice how your ribs seem to move outward and how your sternum rises. Then examine an articulated skeleton to observe the relationship between the ribs and the vertebrae.

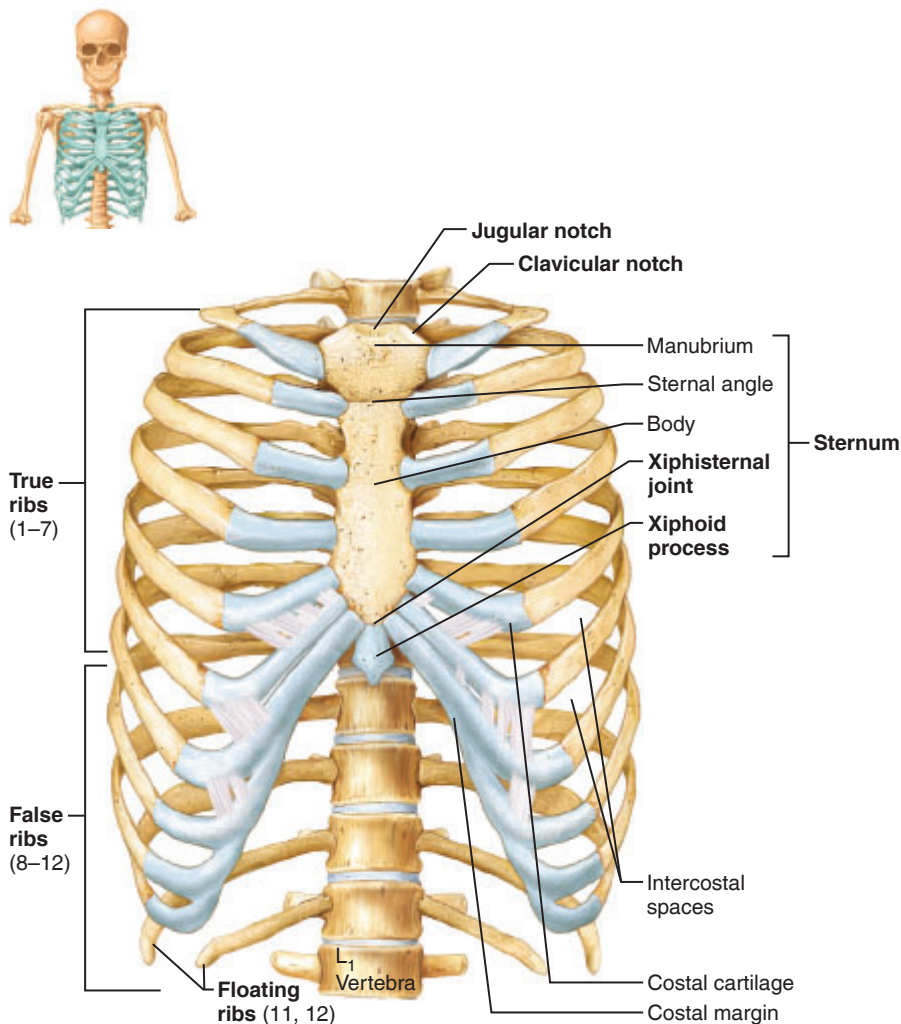
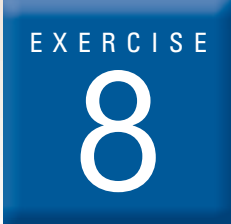

Figure 8.12 The thoracic cage, anterior view. (Costal cartilages are shown in light blue.)



REVIEW SHEET

The Axial Skeleton

Name _____ LabTime/Date _____

The Skull

1. The skull is one of the major components of the axial skeleton. Name the other two.

_____ and _____

What structures does each of these component areas protect? _____

2. Define *suture*: _____

3. With one exception, the skull bones are joined by sutures. Name the exception. _____

4. What are the four major sutures of the skull, and what bones do they connect?

5. Name the eight bones that form the cranium. (Remember to include left and right.)

6. Give two possible functions of the sinuses. _____

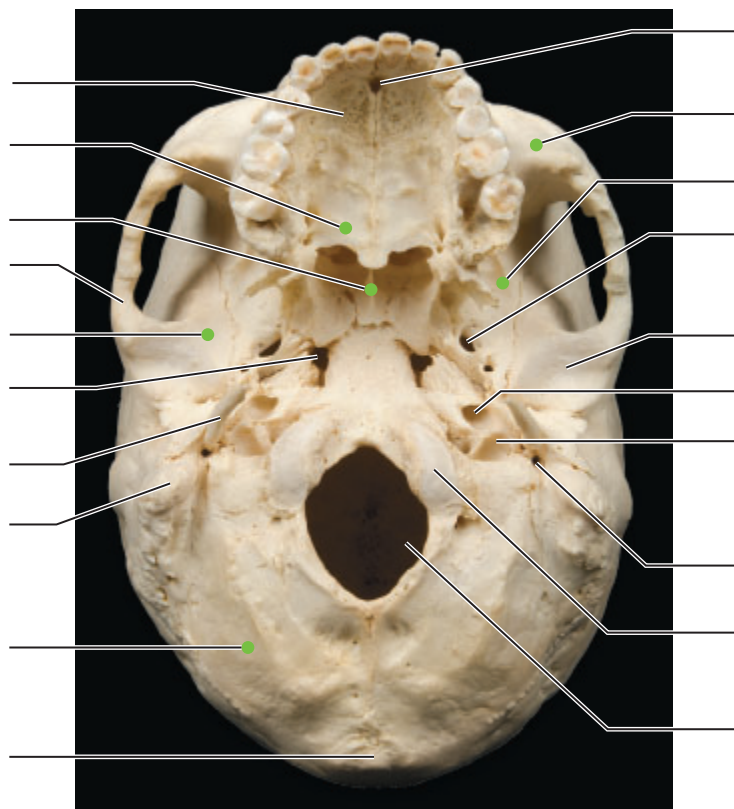
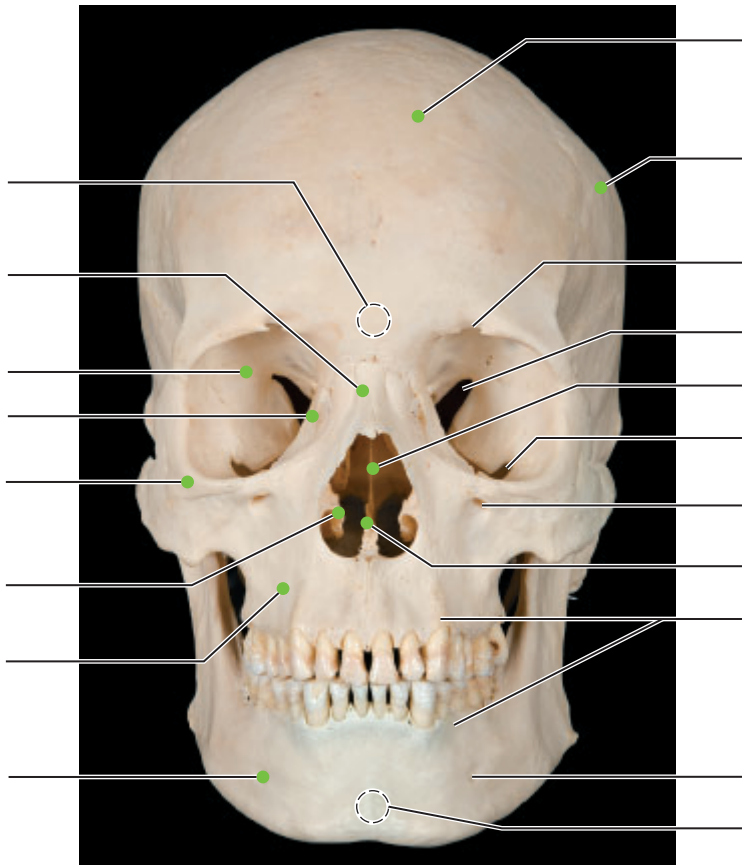
7. What is the bony orbit? _____

8. Why can the sphenoid bone be called the keystone bone of the cranium? _____

9. Match the bone names in column B with the descriptions in column A. (Some responses may be used more than once.)

Column A	Column B
_____ 1. bone forming anterior cranium	ethmoid
_____ 2. cheekbone	frontal
_____ 3. form the superior and lateral cranium	hyoid
_____ 4. bony skeleton of nose	lacrimal
_____ 5. posterior hard palate	mandible
_____ 6. bone pair united by the sagittal suture	maxilla
_____ 7. site of jugular foramen and carotid canal	nasal
_____ 8. contains a "saddle" that houses the pituitary gland	occipital
_____ 9. allows tears to drain	palatine
_____ 10. forms most of hard palate	parietal
_____ 11. superior and middle nasal conchae are part of this bone	sphenoid
_____ 12. site of external acoustic meatus	temporal
_____ 13. has greater and lesser wings	vomer
_____ 14. its "holey" plate allows olfactory fibers to pass	zygomatic
_____ 15. facial bone that contains a paranasal sinus	
_____, _____, and _____ 16. three cranial bones containing paranasal sinuses	
_____ 17. its oval-shaped protrusions articulate with the atlas	
_____ 18. forms the chin	
_____ 19. not really a skull bone	
_____ 20. spinal cord passes through a large foramen in this bone	
_____ 21. inferior part of nasal septum	
_____, _____ 22. contain sockets bearing teeth	

10. Using choices from the numbered key to the right, identify all bones and bone markings provided with various leader lines in the two following photographs. A colored dot at the end of a leader line indicates a bone. Leader lines without a colored dot indicate bone markings. Note that vomer, sphenoid bone, and zygomatic bone will each be labeled twice.



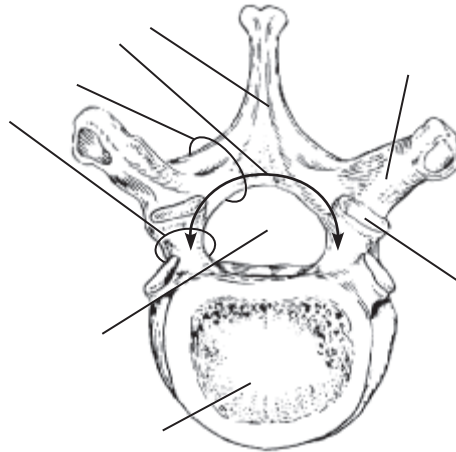
- Key:
1. alveolar processes
 2. carotid canal
 3. ethmoid bone (perpendicular plate)
 4. external occipital protuberance
 5. foramen lacerum
 6. foramen magnum
 7. foramen ovale
 8. frontal bone
 9. glabella
 10. incisive fossa
 11. inferior nasal concha
 12. inferior orbital fissure
 13. infraorbital foramen
 14. jugular foramen
 15. lacrimal bone
 16. mandible
 17. mandibular fossa
 18. mandibular symphysis
 19. mastoid process
 20. maxilla
 21. mental foramen
 22. nasal bone
 23. occipital bone
 24. occipital condyle
 25. palatine bone
 26. palatine process of maxilla
 27. parietal bone
 28. sphenoid bone
 29. styloid process
 30. stylomastoid foramen
 31. superior orbital fissure
 32. supraorbital foramen
 33. temporal bone
 34. vomer
 35. zygomatic bone
 36. zygomatic process

The Vertebral Column

11. Using the key terms, correctly identify the vertebral areas in the diagram.

Key:

- body
- lamina
- pedicle
- spinous process
- superior articular facet
- transverse process
- vertebral arch
- vertebral foramen

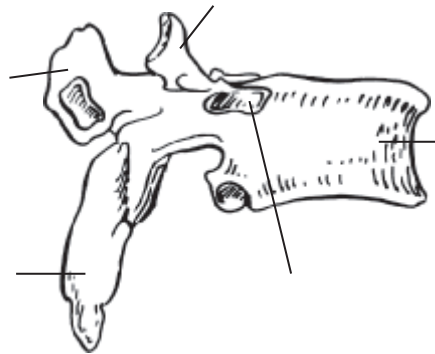


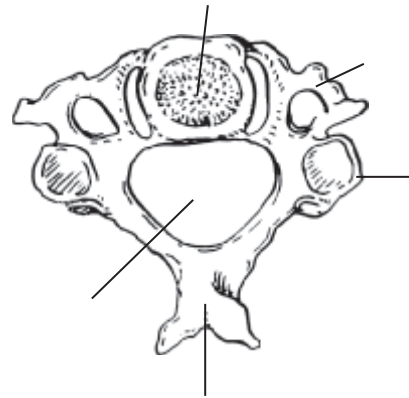
12. The distinguishing characteristics of the vertebrae that make up the vertebral column are noted below. Correctly identify each described structure or region by choosing a response from the key.

- | | | | |
|------|---------------------------|-----------------|-------------------|
| Key: | atlas | coccyx | sacrum |
| | axis | lumbar vertebra | thoracic vertebra |
| | cervical vertebra—typical | | |

- _____ 1. vertebra type with bifid (forked) spinous process
- _____ 2. its dens acts as a pivot point
- _____ 3. bears facets for articulation with ribs; forms part of thoracic cage
- _____ 4. forms a joint with the hip bone
- _____ 5. massive vertebra; weight supporting
- _____ 6. "tail bone"; fused vertebrae
- _____ 7. articulates with the occipital condyles
- _____ 8. five components; unfused
- _____ 9. twelve components; unfused
- _____ 10. type of vertebra where each transverse process has a foramen

13. Identify as specifically as possible each of the vertebrae types shown in the diagrams below. Also identify and label the following markings as required for each type of vertebra: transverse processes, spinous process, body, superior articular processes, vertebral foramen, and superior costal facet.





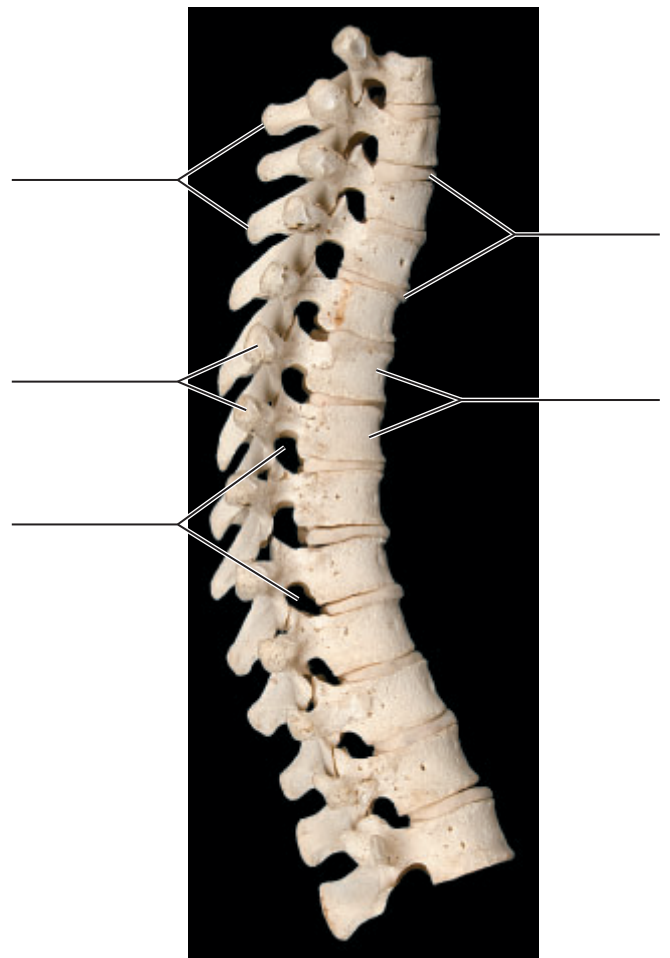
14. What kind of tissue makes up the intervertebral discs? _____

15. What is a herniated disc? _____

What problems might it cause? _____

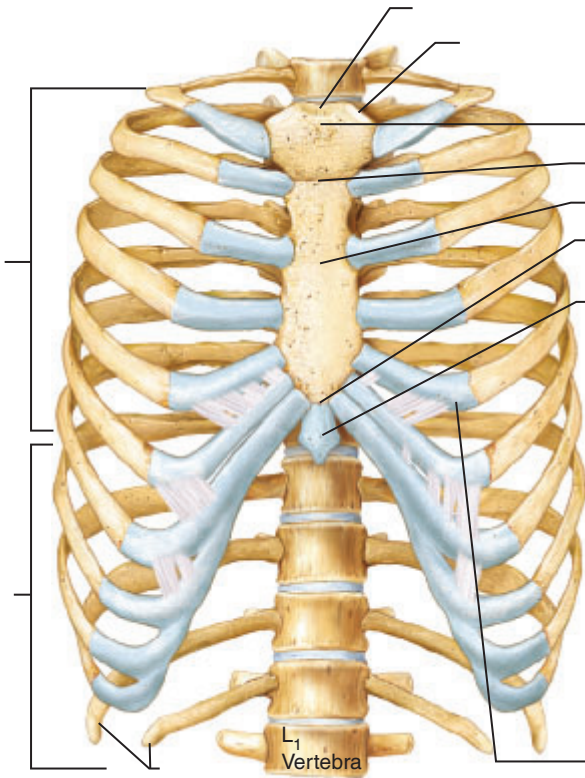
16. Use the key to label the structures on the thoracic region of the vertebral column.

- Key:
- a. intervertebral discs
 - b. intervertebral foramina
 - c. spinous processes
 - d. thoracic vertebrae
 - e. transverse processes



The Thoracic Cage

17. The major components of the thorax (excluding the vertebral column) are the _____ and the _____.
18. What is the general shape of the thoracic cage? _____
19. Using the letters of the terms at the right, identify the regions and landmarks of the thoracic cage.



- a. body
- b. clavicular notch
- c. costal cartilage
- d. false ribs
- e. floating ribs
- f. jugular notch
- g. manubrium
- h. sternal angle
- i. sternum
- j. true ribs
- k. xiphisternal joint
- l. xiphoid process

20. **+** As we age, we often become shorter. Explain why this might occur. _____
- _____
- _____
21. **+** The xiphoid process is often missing from the sternum in bone collections. Hypothesize why it might be missing. _____
- _____

The Appendicular Skeleton

Materials

- Articulated skeletons
- Disarticulated skeletons (complete)
- Articulated pelvis (male and female for comparative study)
- X-ray images of bones of the appendicular skeleton

Learning Outcomes

- Identify the bones of the pectoral and pelvic girdles and their attached limbs.
- Compare and contrast the relative functions and stability of the two girdles.
- Differentiate between a male and a female pelvis.
- Arrange unmarked, disarticulated bones in proper relative position to form a skeleton.

The appendicular skeleton (see Figure 7.1 on page 68) is composed of the 126 bones of the appendages and the pectoral and pelvic girdles, which attach the limbs to the axial skeleton. Although, the upper and lower limbs differ in their functions and mobility, they have the same basic plan. Each limb is composed of three major segments connected by freely movable joints.

Activity 1

Examining and Identifying Bones of the Appendicular Skeleton

Examine each of the bones described in this exercise, and identify characteristic bone markings of each (see Tables 9.1–9.5). The markings help you to determine whether a bone is the right or left member of its pair. *This is very important because before completing this laboratory exercise, you will be constructing your own skeleton.* When corresponding X-ray images are available, compare the actual bone specimen to its X-ray image.

Bones of the Pectoral Girdle and Upper Limb

The Pectoral (Shoulder) Girdle

The paired **pectoral**, or **shoulder**, **girdles** (**Figures 9.1** and **9.2** and **Table 9.1**) each consist of two bones—a clavicle and a scapula. The shoulder girdles anchor the upper limbs to the axial skeleton and provide attachment points for many trunk and neck muscles.

The shoulder girdle is exceptionally light and allows the upper limb a degree of mobility that is not present elsewhere in the body. This flexibility comes at a price. The humerus is very susceptible to dislocation, and fracture of the clavicle affects mobility of the entire upper limb. This is because the clavicle acts as a brace to hold the scapula and humerus away from the thoracic cage.

The Arm

The arm (**Figure 9.3**, page 98, and **Table 9.2**) consists of a single bone—the **humerus**, a typical long bone. Immediately inferior to the head is a slight constriction, the **anatomical neck**. Further down the humerus is the **surgical neck**, so named because it is the most frequently fractured part of the humerus. Proximally its *head* fits into the shallow glenoid cavity of the scapula.

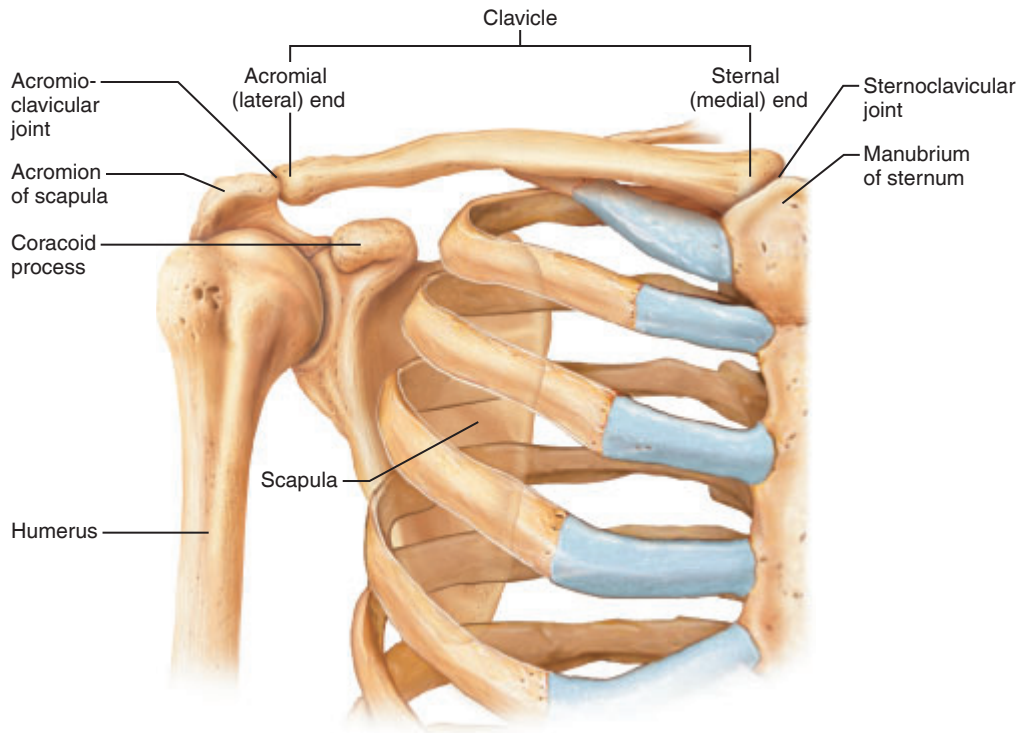


Figure 9.1 Bones of the right pectoral (shoulder) girdle. Pectoral girdle is articulated to show the relationship of the girdle to the bones of the thorax and arm; the scapula is darker.

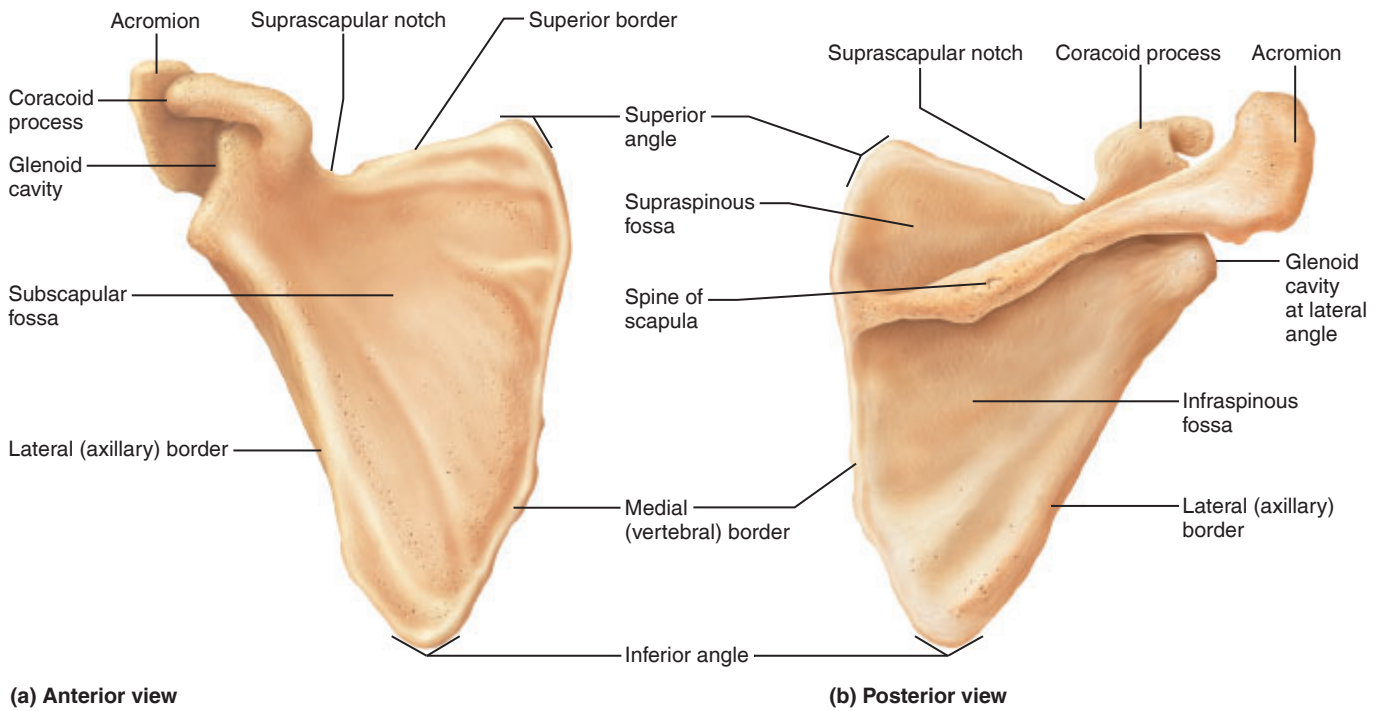


Figure 9.2 Right scapula.

Table 9.1 The Appendicular Skeleton: The Pectoral (Shoulder) Girdle (Figures 9.1 and 9.2)

Bone	Important markings	Description
Clavicle (“collarbone”)	Acromial (lateral) end	Flattened lateral end that articulates with the acromion of the scapula to form the acromioclavicular (AC) joint
	Sternal (medial) end	Oval or triangular medial end that articulates with the sternum to form the lateral walls of the jugular notch (see Figure 8.12, p. 88)
Scapula (“shoulder blade”)	Superior border	Short, sharp border located superiorly
	Medial (vertebral) border	Thin, long border that runs roughly parallel to the vertebral column
	Lateral (axillary) border	Thick border that is closest to the armpit and ends superiorly with the glenoid cavity
	Glenoid cavity	A shallow socket that articulates with the head of the humerus
	Spine	A ridge of bone on the posterior surface that is easily felt through the skin
	Acromion	The lateral end of the spine of the scapula that articulates with the clavicle to form the AC joint
	Coracoid process	Projects above the glenoid cavity as a hooklike process; helps attach the biceps brachii muscle
	Suprascapular notch	Small notch located medial to the coracoid process that allows for the passage of blood vessels and a nerve
	Subscapular fossa	A large shallow depression that forms the anterior surface of the scapula
	Infraspinous fossa	A broad depression located inferior to the spine of the scapula

Table 9.2 The Appendicular Skeleton: The Upper Limb (Figure 9.3)

Bone	Important markings	Description
Humerus (only bone of the arm)	Greater tubercle	Large lateral prominence; site of the attachment of rotator cuff muscles
	Lesser tubercle	Small medial prominence; site of attachment of rotator cuff muscles
	Intertubercular sulcus	A groove separating the greater and lesser tubercles; the tendon of the biceps brachii lies in this groove
	Deltoid tuberosity	A roughened area about midway down the shaft of the lateral humerus; site of attachment of the deltoid muscle
	Radial fossa	Small lateral depression; receives the head of the radius when the forearm is flexed
	Coronoid fossa	Small medial anterior depression; receives the coronoid process of the ulna when the forearm is flexed
	Capitulum	A rounded lateral condyle that articulates with the radius
	Trochlea	A flared medial condyle that articulates with the ulna
	Lateral epicondyle	Small condyle proximal to the capitulum
	Medial epicondyle	Rough condyle proximal to the trochlea
Radius (lateral bone of the forearm in the anatomical position)	Head	Proximal end of the radius that forms part of the proximal radioulnar joint and articulates with the capitulum of the humerus
	Radial tuberosity	Medial prominence just below the head of the radius; site of attachment of the biceps brachii
	Radial styloid process	Distal prominence; site of attachment for ligaments that travel to the wrist
Ulna (medial bone of the forearm in the anatomical position)	Olecranon	Prominent process on the posterior proximal ulna; articulates with the olecranon fossa of the humerus when the forearm is extended
	Trochlear notch	Deep notch that separates the olecranon and the coronoid process; articulates with the trochlea of the humerus
	Coronoid process	Shaped like a point on a crown; articulates with the trochlea of the humerus
	Head	Slim distal end of the ulna; forms part of the distal radioulnar joint
	Ulnar styloid process	Distal pointed projection; located medial to the head of the ulna

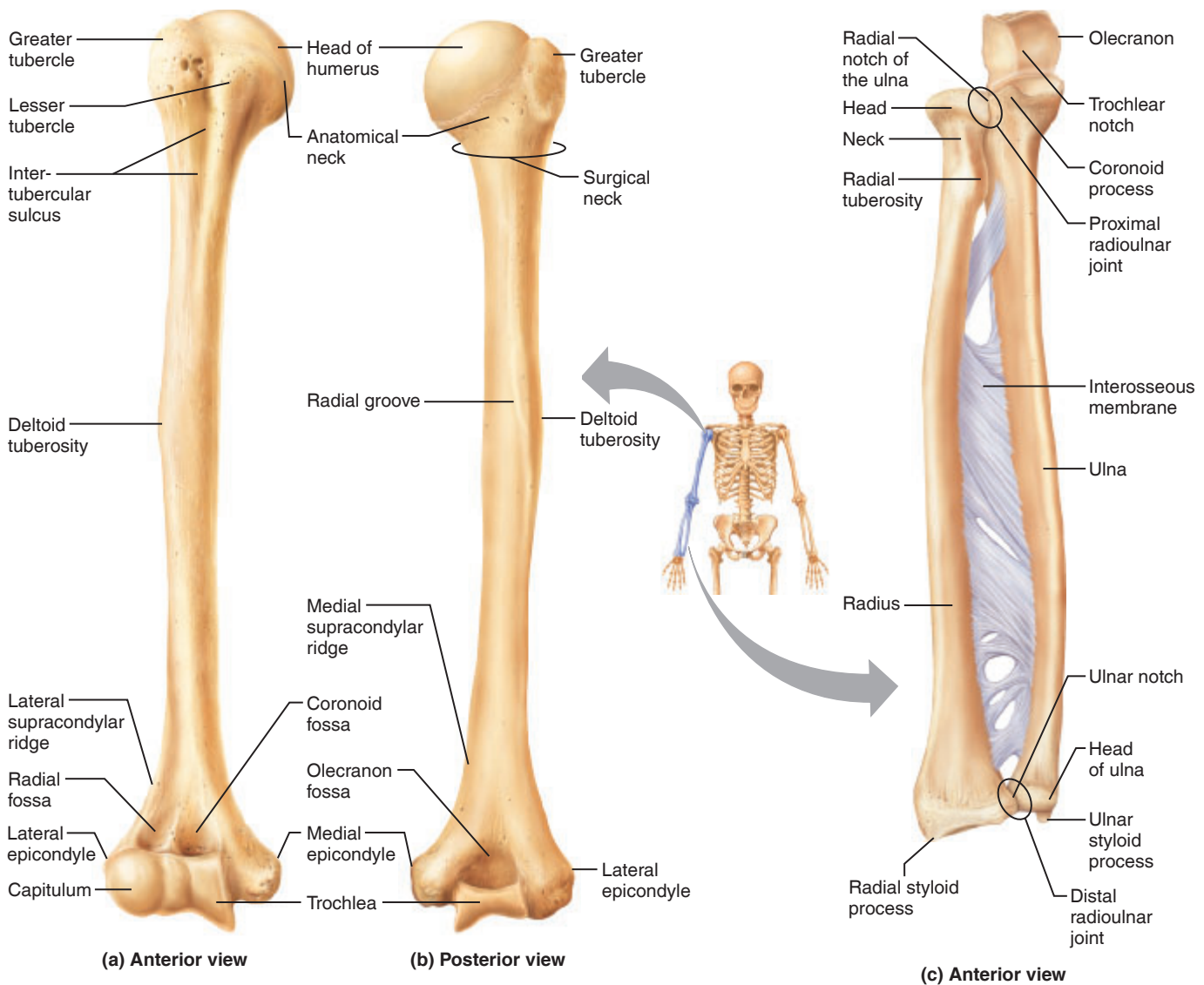


Figure 9.3 Bones of the right arm and forearm. (a) Humerus, anterior view. (b) Humerus, posterior view. (c) Anterior view of bones of the forearm, the radius and the ulna.

The Forearm

Two bones, the radius and the ulna, form the skeleton of the forearm (see Figure 9.3c and Table 9.2). When the body is in the anatomical position, the **radius** is lateral, the ulna is medial, and the radius and ulna are parallel.

The Hand

The skeleton of the hand (**Figure 9.4**) includes three groups of bones: the carpals (wrist bones), metacarpals (bones of the palm), and phalanges (bones of the fingers).

The **carpus**, or wrist, is the proximal portion of the hand. The eight bones composing the carpus, the **carpals**, are arranged in two irregular rows of four bones each. These bones are illustrated in Figure 9.4. In the proximal row (lateral to medial) are the *scaphoid*, *lunate*, *triquetrum*, and *pisiform*. In the distal row (lateral to medial) are the *trapezium*, *trapezoid*, *capitate*, and *hamate*.

The **metacarpals**, numbered I to V from the thumb side of the hand, radiate out from the wrist like spokes to form the palm of the hand. The *bases* of the metacarpals articulate

with the carpals of the wrist; their *heads* articulate with the phalanges of the fingers distally.

Like the bones of the palm, the fingers are numbered from I to V, beginning from the thumb side of the hand. The 14 bones of the fingers, or digits of each hand, are miniature long bones, called **phalanges** (singular: **phalanx**) as noted above. Each finger has three phalanges (proximal, middle, and distal) except the thumb, which has only two (proximal and distal).

Activity 2

Palpating the Surface Anatomy of the Pectoral Girdle and the Upper Limb

Identify the following bone markings on the skin surface of the upper limb. You will probably want to observe and palpate these bone markings on your lab partner, particularly because many can be seen only from the

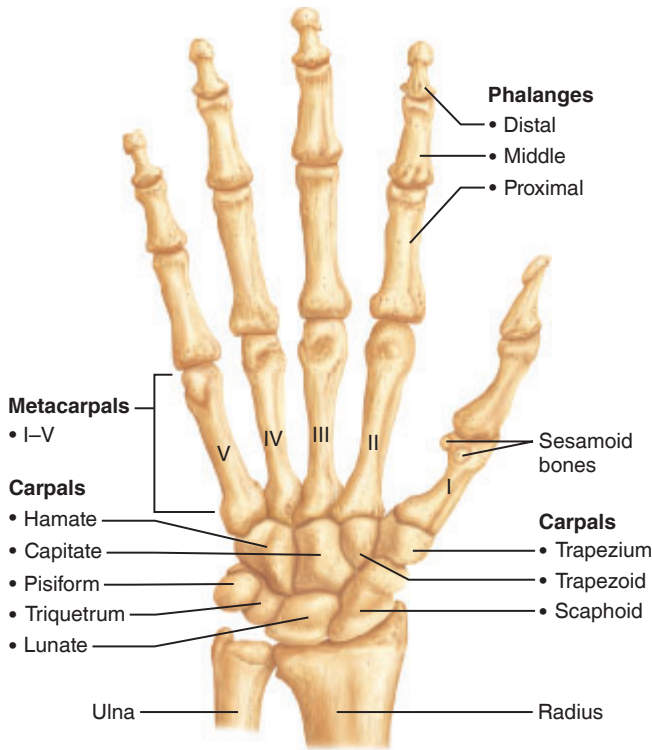


Figure 9.4 Bones of the right hand, anterior view.

posterior aspect. Place a check mark in the boxes as you locate the bone markings.

- Clavicle: Palpate the clavicle along its entire length from sternum to shoulder. Where the clavicle joins the sternum, identify the rigid sternoclavicular joint.
- Acromioclavicular (AC) joint: At the high point of the shoulder, find the junction point between the clavicle and the acromion of the scapula.
- Spine of the scapula: Extend your arm at the shoulder so that your scapula moves posteriorly. As you do this, the spine of your scapula will be seen as a winglike protrusion on your posterior thorax.
- Medial and lateral epicondyles of the humerus: Feel the medial projection (epicondyle) at the distal end of the humerus. The ulnar nerve, which runs behind the medial epicondyle, is responsible for the tingling, painful sensation felt when you hit your “funny bone.” Now run your hand to the lateral side of the humerus at the same level. This is the lateral epicondyle of the humerus.
- Olecranon of the ulna: Work your elbow—flexing and extending—as you palpate its posterior aspect to feel the olecranon of the ulna moving in and out of the olecranon fossa on the backside of the humerus.
- Ulnar styloid process: With the hand in the anatomical position, feel out this small projection on the medial aspect at the distal end of the ulna.

- Radial styloid process: Find this projection at the distal end of the radius (lateral aspect). It is most easily located by moving the hand medially at the wrist. Next, move your fingers just medially onto the anterior wrist. Press firmly, and then let up slightly on the pressure.
- Metacarpophalangeal joints (knuckles): Clench your fist, and find the first set of flexed-joint protrusions beyond the wrist—these are your metacarpophalangeal joints, which form the knuckles.

Bones of the Pelvic Girdle and Lower Limb

The Pelvic (Hip) Girdle

As with the bones of the pectoral girdle and upper limb, pay particular attention to bone markings needed to identify right and left bones.

The **pelvic girdle**, or **hip girdle** (Figures 9.5 and 9.6 and Table 9.3), is formed by the two **hip bones** (also called the **ossa coxae**, or coxal bones). The two hip bones together with the sacrum and coccyx form the **pelvis**, or *bony pelvis*. Unlike the bones of the shoulder girdle, those of the pelvic girdle are heavy and massive, and they attach securely to the axial skeleton. The sockets for the heads of the femurs (thigh bones) are deep and heavily reinforced by ligaments, ensuring a stable, strong limb attachment. Here, security and the ability to bear weight are more important than mobility and flexibility.

Each hip bone is a result of the fusion of three bones—the ilium, ischium, and pubis.

The **rami** of the pubic bone anteriorly and the ischium posteriorly forms a bar of bone enclosing the **obturator foramen**, through which blood vessels and nerves run from the pelvic cavity into the thigh. The two pubic bones meet anteriorly at a joint called the **pubic symphysis**.

The ilium, ischium, and pubis unite at the deep hemispherical socket called the **acetabulum** (literally, “vinegar cup”), which receives the head of the thigh bone.

Activity 3

Palpating the Surface Anatomy of the Pelvic Girdle

Locate and palpate the following bone markings on yourself and/or your lab partner. Place a check mark in the boxes as you locate the bone markings.

- Iliac crest: Rest your hands on your hips—they will be overlying the iliac crests.
- Anterior superior iliac spine: Trace the crest anteriorly to the anterior superior iliac spine. This bone marking is easily felt in almost everyone and is clearly visible through the skin of very slim people.



Hip bone
(coxal bone
or os coxae)

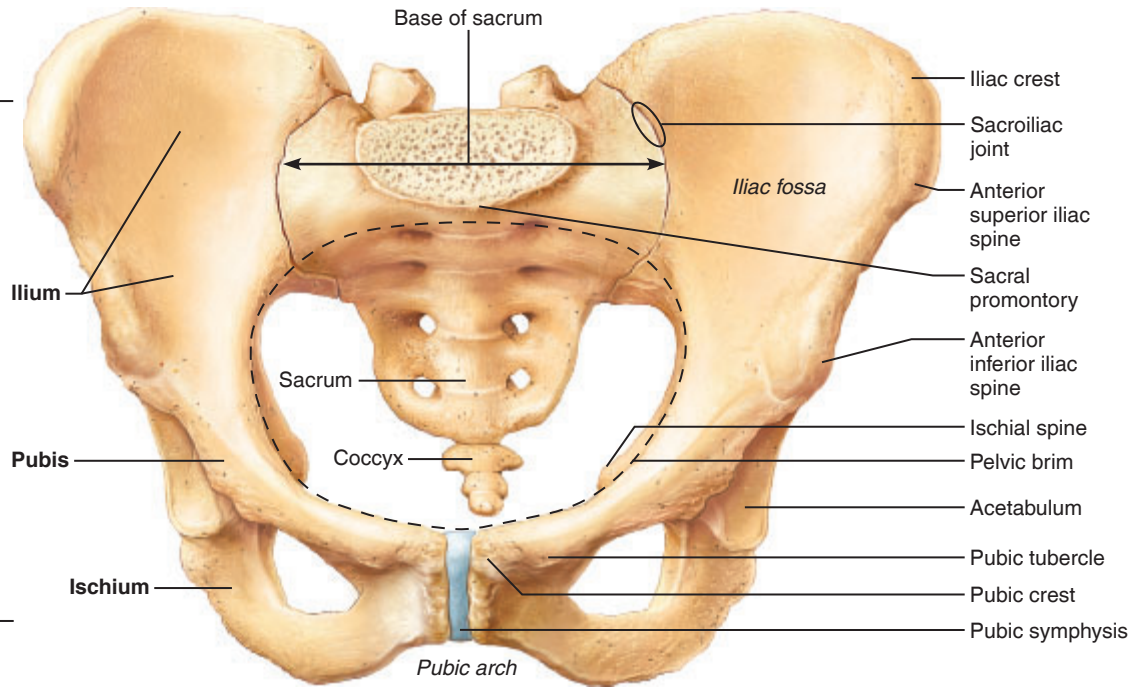


Figure 9.5 Bones of the pelvic girdle.

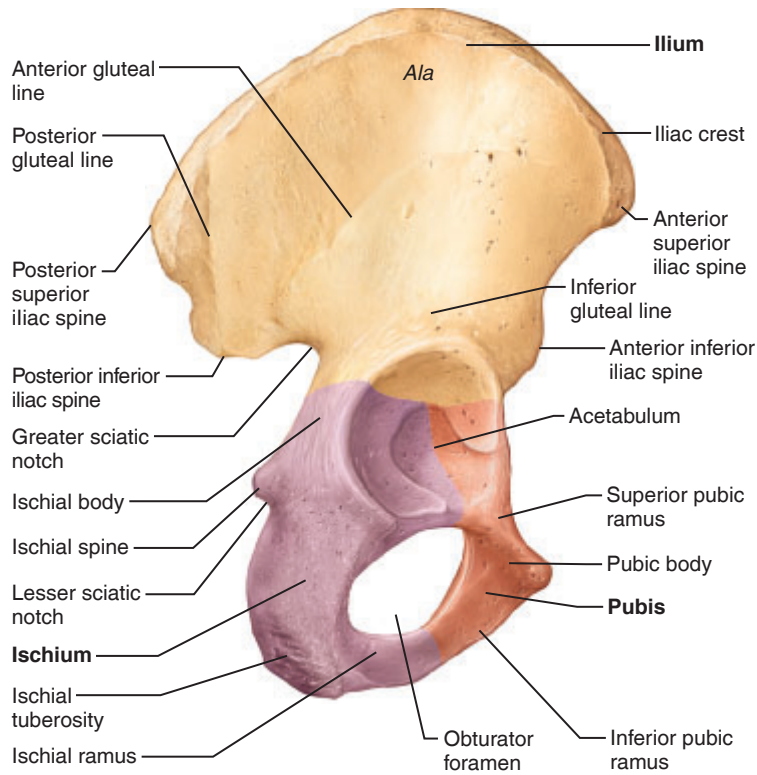


Figure 9.6 Right hip bone.

Table 9.3 The Appendicular Skeleton: The Pelvic (Hip) Girdle (Figures 9.5 and 9.6)

Bone	Important markings	Description
Ilium	Iliac crest	Thick superior margin of bone
	Anterior superior iliac spine	The blunt anterior end of the iliac crest
	Posterior superior iliac spine	The sharp posterior end of the iliac crest
	Greater sciatic notch	Deep notch located inferior to the posterior inferior iliac spine; allows the sciatic nerve to enter the thigh
	Auricular surface	Rough medial surface that articulates with the auricular surface of the sacrum, forming the sacroiliac joint
Ischium (“sit-down” bone)	Ischial tuberosity	Rough projection that receives the weight of our body when we are sitting
	Ischial spine	Located superior to the ischial tuberosity and projects medially into the pelvic cavity
	Lesser sciatic notch	A small notch located inferior to the ischial spine
Pubis	Superior pubic ramus	Superior extension of the body of the pubis
	Inferior pubic ramus	Inferior extension of the body of the pubis; articulates with the ischium

Comparison of the Male and Female Pelves

Although bones of males are usually larger and heavier, the male and female skeletons are very similar. The outstanding exception to this generalization is pelvic structure. The female pelvis is modified for childbearing. Generally speaking, the female pelvis is wider, shallower, lighter, and rounder than that of the male. The major differences between the male and female pelves are summarized in **Table 9.4**.

The **pelvic brim** is a continuous oval ridge of bone that runs along the pubic symphysis, pubic crests, arcuate lines, sacral alae, and sacral promontory. The **false pelvis** is that portion superior to the pelvic brim; it is bounded by the ilia laterally and the sacrum and lumbar vertebrae posteriorly (Figure 9.5). The false pelvis supports the abdominal viscera, but it does not restrict childbirth in any way. The **true pelvis** is the region inferior to the pelvic brim that is almost entirely surrounded by bone. Its posterior boundary is the sacrum. The ilia, ischia, and pubic bones define the limits of the true pelvis laterally and anteriorly.

The dimensions of the true pelvis, particularly its inlet and outlet, are critical if delivery of a baby is to be uncomplicated, and they are carefully measured by the obstetrician. The **pelvic inlet** is the opening delineated by the pelvic brim. The **pelvic outlet** is the inferior margin of the true pelvis. It is bounded anteriorly by the pubic bones, laterally by the ischia, and posteriorly by the sacrum and coccyx. Because both the coccyx and the ischial spines protrude into the outlet opening, a sharply angled coccyx or large, sharp ischial spines can dramatically narrow the outlet. The largest dimension of the outlet is the anterior-posterior diameter.

Activity 4

Comparing Male and Female Pelves

Examine Table 9.4 and, if possible, both a male and a female pelvis. Pay particular attention to differences in the relative size and shape of the inlet, ischial spines, and sacrum, and to the angle of the pubic arch.

The Thigh

The **femur**, or thigh bone (**Figure 9.7a** and **b** and **Table 9.5A**), is the only bone of the thigh. It is the heaviest, strongest bone in the body. Its ball-like head articulates with the hip bone via the deep, secure socket of the acetabulum.

The **patella**, or kneecap, is a triangular sesamoid bone enclosed in the quadriceps tendon that secures the anterior thigh to the tibia.

The Leg

Two bones, the tibia and the fibula, form the skeleton of the leg (Figure 9.7c and **Table 9.5B**, page 104). The **tibia**, or *shinbone*, is the larger, medial, weight-bearing bone of the leg.

The **fibula**, which lies parallel to the tibia, takes no part in forming the knee joint. Its proximal head articulates with the lateral condyle of the tibia.

The Foot

The bones of the foot include the 7 **tarsal** bones forming the ankle; 5 **metatarsals**, which form the instep; and 14 **phalanges**, which form the toes (**Figure 9.8**, page 104). Body weight is concentrated on the two largest tarsals—the *calcaneus* (heel bone) and the *talus*, which lies between the tibia and the calcaneus. The metatarsals are numbered I through V, medial to lateral. Like the fingers of the hand, each toe has three phalanges except the great toe, which has two.

Table 9.4 Comparison of the Male and Female Pelves

Characteristic	Female	Male
General structure and functional modifications	Tilted forward; adapted for childbearing; true pelvis defines the birth canal; cavity of the true pelvis is broad, shallow, and has a greater capacity	Tilted less far forward; adapted for support of a male's heavier build and stronger muscles; cavity of the true pelvis is narrow and deep
Bone thickness	Bones lighter, thinner, and smoother	Bones heavier and thicker, and markings are more prominent
Acetabula	Smaller; farther apart	Larger; closer together
Pubic arch	Broader (80° to 90°); more rounded	Angle is more acute (50° to 60°)
Anterior view		
Sacrum	Wider; shorter; sacral curvature is accentuated	Narrow; longer; sacral promontory projects anteriorly
Coccyx	More movable; projects inferiorly	Less movable; projects anteriorly
Greater sciatic notch	Wide and shallow	Narrow and deep
Left lateral view		
Pelvic inlet	Wider; oval from side to side	Narrow; basically heart shaped
Pelvic outlet	Wider; ischial spines shorter, farther apart and everted	Narrower; ischial spines longer, sharper, and point more medially
Posteroinferior view		

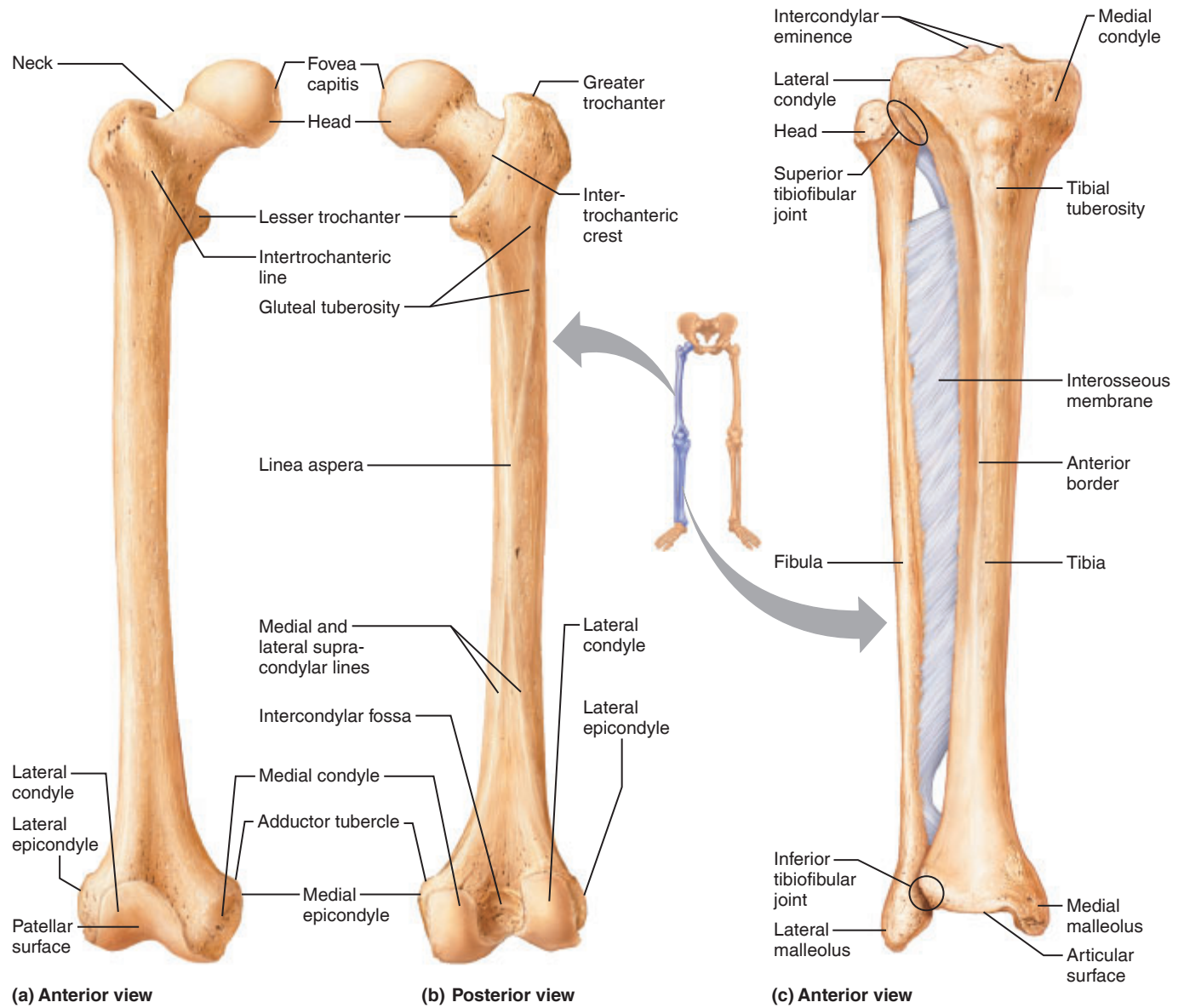
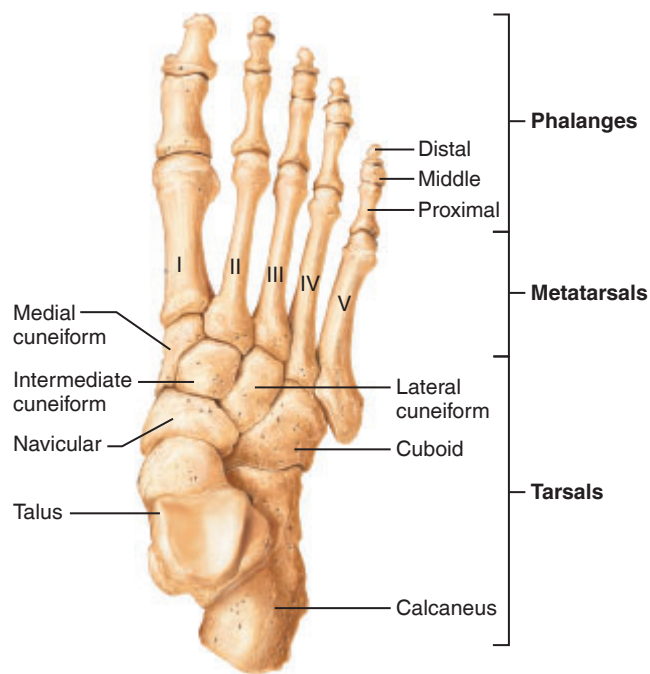


Figure 9.7 Bones of the right thigh and leg. (a) Femur (thigh bone), anterior view. (b) Femur, posterior view. (c) Tibia and fibula of the leg, anterior view.

Table 9.5A The Appendicular Skeleton: The Lower Limb (Figure 9.7)		
Bone	Important markings	Description
Femur (thigh bone)	Neck	Weakest part of the femur, the usual fracture site of a “broken hip”
	Greater trochanter	Large lateral projection; serves as a site for muscle attachment on the proximal femur
	Lesser trochanter	Large posteromedial projection; serves as a site for muscle attachment
	Intertrochanteric crest	Prominent ridge of bone that connects the two trochanters posteriorly
	Gluteal tuberosity	Thin ridge of bone located posteriorly; serves as a site for muscle attachment on the proximal femur
	Medial and lateral condyles	Distal “wheel shaped” projections that articulate with the tibia; each condyle has a corresponding epicondyle
	Intercondylar fossa	Deep depression located between the condyles

Table 9.5B The Appendicular Skeleton: The Lower Limb (Figure 9.7)

Bone	Important markings	Description
Tibia (shin bone, medial bone of the leg)	Lateral condyle	Slightly concave surface that articulates with the lateral condyle of the femur; the inferior region of this condyle articulates with the fibula to form the superior tibiofibular joint
	Medial condyle	Slightly concave surface that articulates with the medial condyle of the femur
	Intercondylar eminence	Irregular projection located between the two condyles
	Tibial tuberosity	Roughened anterior surface; site of patellar ligament attachment
	Anterior border	Sharp ridge of bone easily palpated because it is close to the surface
	Medial malleolus	Forms the medial bulge of the ankle
Fibula (lateral bone of the leg)	Head	Proximal end of the fibula that articulates with the tibia to form the superior tibiofibular joint
	Lateral malleolus	Forms the lateral bulge of the ankle and articulates with the talus

**Figure 9.8** Bones of the right foot, superior view.

Activity 5

Palpating the Surface Anatomy of the Lower Limb

Locate and palpate the following bone markings on yourself and/or your lab partner. Place a check mark in the boxes as you locate the bone markings.

- Greater trochanter of the femur: It is the most lateral point of the proximal femur, and it typically lies 6–8 inches below the iliac crest.

- Patella and tibial tuberosity: Feel your kneecap (patella), and palpate the ligaments attached to its borders. Follow the inferior ligament to the tibial tuberosity where it attaches.

- Medial and lateral condyles of the femur and tibia: As you move from the patella inferiorly on the medial (and then the lateral) knee surface, you will feel first the femoral and then the tibial condyle.

- Medial malleolus: Feel the medial protrusion of your ankle, the medial malleolus of the distal tibia.

- Lateral malleolus: Feel the bulge of the lateral aspect of your ankle, the lateral malleolus of the fibula.

- Calcaneus: Attempt to follow the extent of your calcaneus, or heel bone.

Activity 6

Constructing a Skeleton

- When you finish examining yourself and the disarticulated bones of the appendicular skeleton, work with your lab partner to arrange the disarticulated bones on the laboratory bench in their proper relative positions to form an entire skeleton.

- When you believe that you have accomplished this task correctly, ask the instructor to check your arrangement. If it is not correct, go to the articulated skeleton and check your bone arrangements. Also review the tables to help you make the necessary changes.

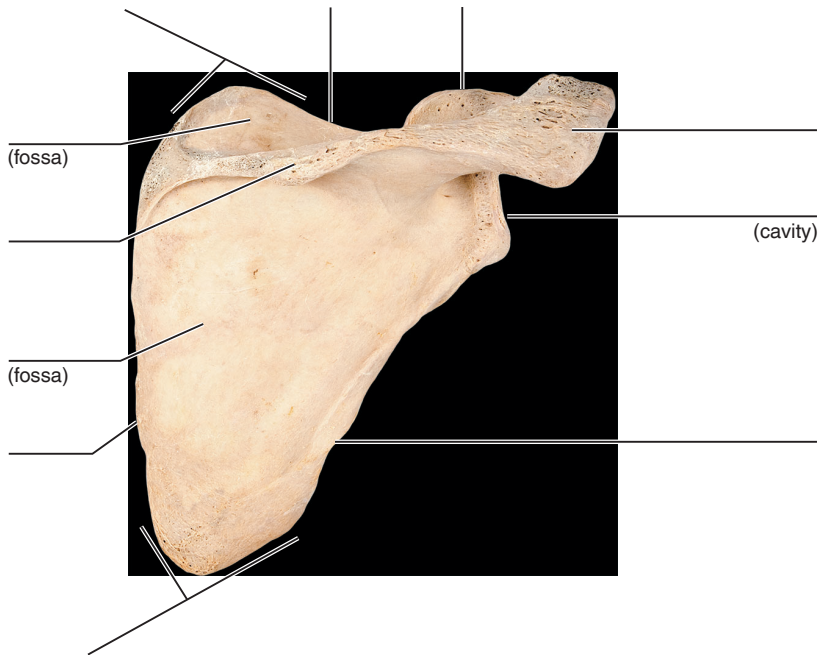
REVIEW SHEET

The Appendicular Skeleton

Name _____ LabTime/Date _____

Bones of the Pectoral Girdle and Upper Limb

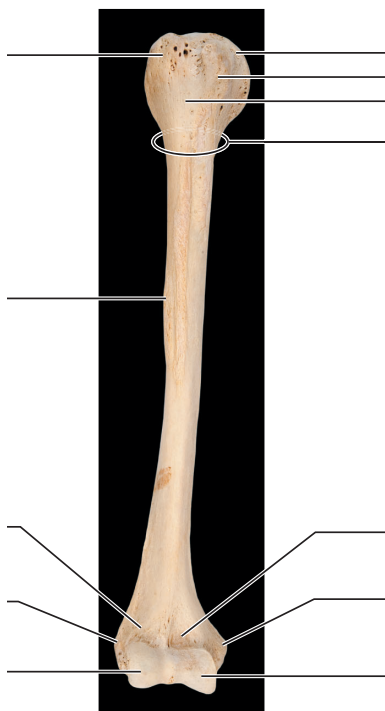
1. Using items from the list at the right, identify the anatomical landmarks and regions of the scapula.



Key:

- acromion
- coracoid process
- glenoid cavity
- inferior angle
- infraspinous fossa
- lateral border
- medial border
- spine
- superior angle
- superior border
- supraspinous fossa

2. Match the terms in the key with the appropriate leader lines on the photograph of the humerus.



Key:

- capitulum
- coronoid fossa
- deltoid tuberosity
- greater tubercle
- head
- intertubercular sulcus
- lateral epicondyle
- lesser tubercle
- medial epicondyle
- radial fossa
- surgical neck
- trochlea

3. Match the terms in the key with the appropriate leader lines on the photographs of the posterior view of the radius on the left and the lateral view of the ulna on the right.



Key:

- a. coronoid process
- b. head of the radius
- c. head of the ulna
- d. neck of the radius
- e. olecranon
- f. radial notch of the ulna
- g. radial styloid process
- h. radial tuberosity
- i. trochlear notch
- j. ulnar notch of the radius
- k. ulnar styloid process

4. What is the total number of phalanges in the hand? _____

5. What is the total number of carpals in the wrist? _____

Bones of the Pelvic Girdle and Lower Limb

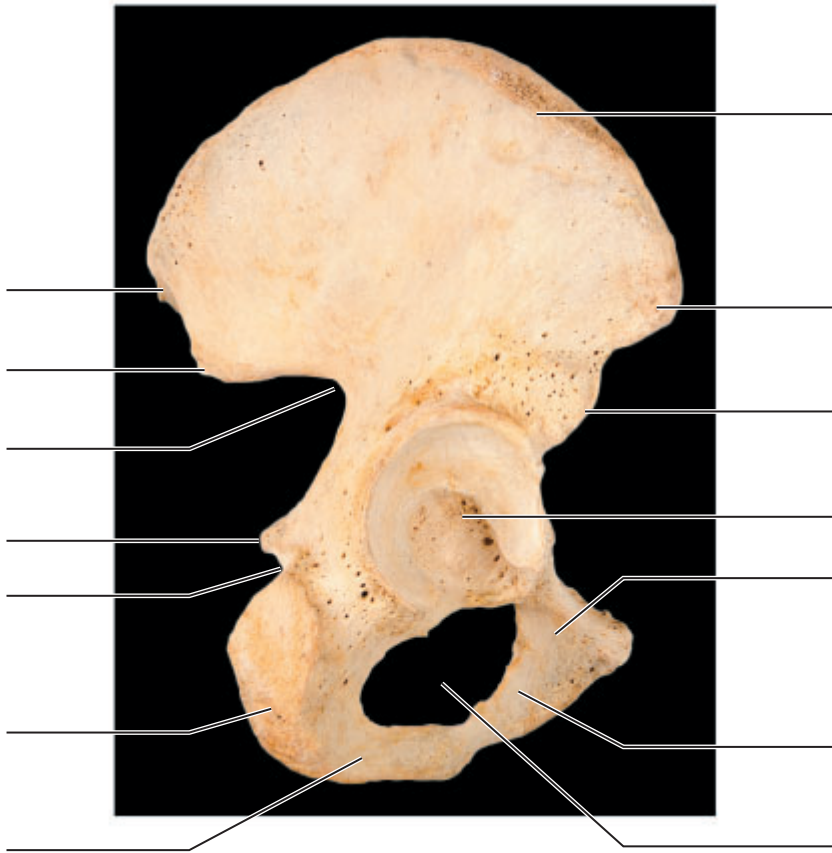6. Compare the pectoral and pelvic girdles by choosing appropriate descriptive terms from the key.

- Key:
- | | |
|-------------------------------|--|
| a. flexibility most important | d. insecure axial and limb attachments |
| b. massive | e. secure axial and limb attachments |
| c. lightweight | f. weight-bearing most important |

Pectoral: _____, _____, _____ Pelvic: _____, _____, _____

7. Distinguish between the true pelvis and the false pelvis. _____

8. Match the terms in the key with the appropriate leader lines on the photograph of the lateral view of the hip bone.



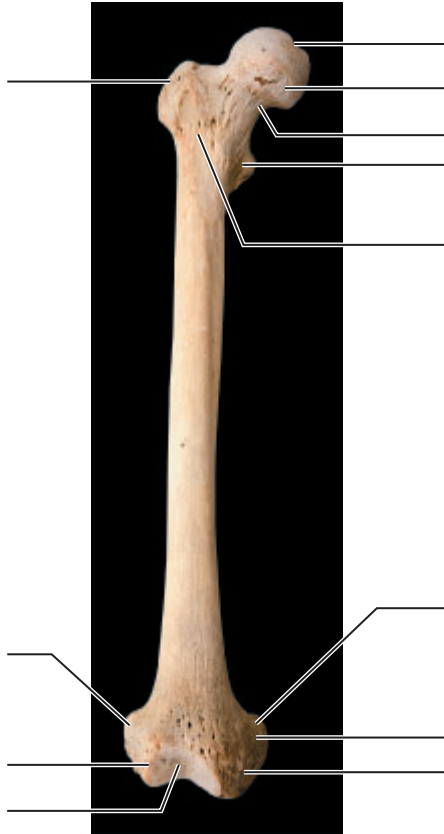
Key:

- a. acetabulum
- b. anterior inferior iliac spine
- c. anterior superior iliac spine
- d. greater sciatic notch
- e. iliac crest
- f. inferior pubic ramus
- g. ischial ramus
- h. ischial spine
- i. ischial tuberosity
- j. lesser sciatic notch
- k. obturator foramen
- l. posterior inferior iliac spine
- m. posterior superior iliac spine
- n. superior pubic ramus

9. **+** FOOSH is an acronym that stands for **F**all on **O**utstretched **H**and. Discuss possible fractures and dislocations that might occur with an injury of this type.

10. **+** Describe some of the features of the female pelvis that provide for compatibility with vaginal birth. _____

11. Match the terms in the key with the appropriate leader lines on the photograph of the anterior view of the femur.



Key:

- a. adductor tubercle
- b. fovea capitis
- c. greater trochanter
- d. head
- e. intertrochanteric line
- f. lateral condyle
- g. lateral epicondyle
- h. lesser trochanter
- i. medial condyle
- j. medial epicondyle
- k. neck
- l. patellar surface

12. Match the terms in the key with the appropriate leader lines on the photograph of the anterior view of the tibia.



Key:

- a. anterior border
- b. lateral condyle
- c. medial condyle
- d. medial malleolus
- e. tibial tuberosity

Joints and Body Movements

Materials

- Articulated skeleton
- Skull
- Diarthrotic beef joint (fresh or preserved), preferably a knee joint sectioned sagittally
- Disposable gloves
- Water balloons and clamps
- Anatomical chart of joint types (if available)
- X-ray images of normal and arthritic joints (if available)

Learning Outcomes

- Name the three structural categories of joints, and compare their structure and mobility.
- Identify the types of synovial joints.
- Define origin and insertion of muscles.
- Demonstrate or identify the various body movements.

Nearly every bone in the body is connected to, or forms a joint with, at least one other bone. **Joints**, or **articulations**, perform two functions for the body. They (1) hold bones together and (2) allow the rigid skeleton some flexibility so that gross body movements can occur.

Classification of Joints

Joints are classified by structure or by function. The *structural classification* is based on what separates the articulating bones—fibers, cartilage, or a joint cavity. Structurally, there are *fibrous*, *cartilaginous*, and *synovial joints*.

The *functional classification* focuses on the amount of movement the joint allows. On this basis, there are **synarthroses**, or immovable joints; **amphiarthroses**, or slightly movable joints; and **diarthroses**, or freely movable joints. Freely movable joints predominate in the limbs, whereas immovable and slightly movable joints are largely restricted to the axial skeleton.

The structural and functional classifications of joints are summarized in **Table 10.1**. A sample of the types of joints appears in **Figure 10.1**.

Activity 1

Identifying Fibrous Joints

Examine a human skull. Notice that adjacent bone surfaces do not actually touch but are separated by a wavy seam of fibrous connective tissue. Also examine a skeleton, an anatomical chart of joint types, and Table 10.1 for examples of fibrous joints.

Activity 2

Identifying Cartilaginous Joints

Identify the cartilaginous joints on a human skeleton and on an anatomical chart of joint types.

Table 10.1 Summary of Joint Classification (Figure 10.1)

Structural class	Structural characteristics	Structural types	Examples	Functional classification
Fibrous	Adjoining bones connected by dense fibrous connective tissue; no joint cavity	Suture (short fibers)	Squamous suture between the parietal and temporal bones	Synarthrosis (immovable)
		Syndesmosis (longer fibers)	Between the tibia and fibula	Amphiarthrosis (slightly movable)
		Gomphosis (periodontal ligament)	Tooth in a bony socket (Figure 25.9, page 319)	Synarthrosis (immovable)
Cartilaginous	Adjoining bones united by cartilage; no joint cavity	Synchondrosis (hyaline cartilage)	Between the costal cartilage of rib 1 and the sternum and the epiphyseal plate in growing long bones	Synarthrosis (immovable)
		Symphysis (fibrocartilage)	Intervertebral discs between adjacent vertebrae and the anterior connection between the pubic bones	Amphiarthrosis (slightly movable and immovable)
Synovial	Adjoining bones covered in articular cartilage; separated by a joint cavity and enclosed in an articular capsule lined with a synovial membrane	Plane joint	Between the carpals of the wrist	Diarthrosis (freely movable)
		Hinge joint	Elbow joint	
		Pivot joint	Proximal radioulnar joint	
		Condylar joint	Between the metacarpals and the proximal phalanx	
		Saddle joint	Between the trapezium (carpal) and metatarsal I	
		Ball-and-socket joint	Shoulder joint	

Synovial Joints

In **synovial joints**, the articulating bone ends are separated by a joint cavity containing synovial fluid (see Figure 10.1f–h). All synovial joints are diarthroses, or freely movable joints. Their mobility varies, however; some can move in only one plane, and others can move in several directions (multiaxial movement). Most joints in the body are synovial joints.

All synovial joints have the following structural characteristics (**Figure 10.2**):

- **Joint (articular) cavity:** A space between the articulating bones that contains a small amount of synovial fluid.
- **Articular cartilage:** Hyaline cartilage that covers the surfaces of the bones forming the joint.
- **Articular capsule:** Two layers that enclose the joint cavity. The tough external layer is the *fibrous layer* composed of dense irregular connective tissue. The inner layer is the *synovial membrane* composed of loose connective tissue.

- **Synovial fluid:** A viscous fluid, the consistency of egg whites, located in the joint cavity and articular cartilage. This fluid acts as a lubricant, reducing friction.

Synovial joints may also be reinforced with ligaments and may contain bursae or tendon sheaths that reduce the friction where muscles, tendons, or ligaments cross the bone.

Activity 3

Examining Synovial Joint Structure

Examine a beef joint to identify the general structural features of diarthrotic joints.

If the joint is freshly obtained from the slaughterhouse, put on disposable gloves before beginning your observations.

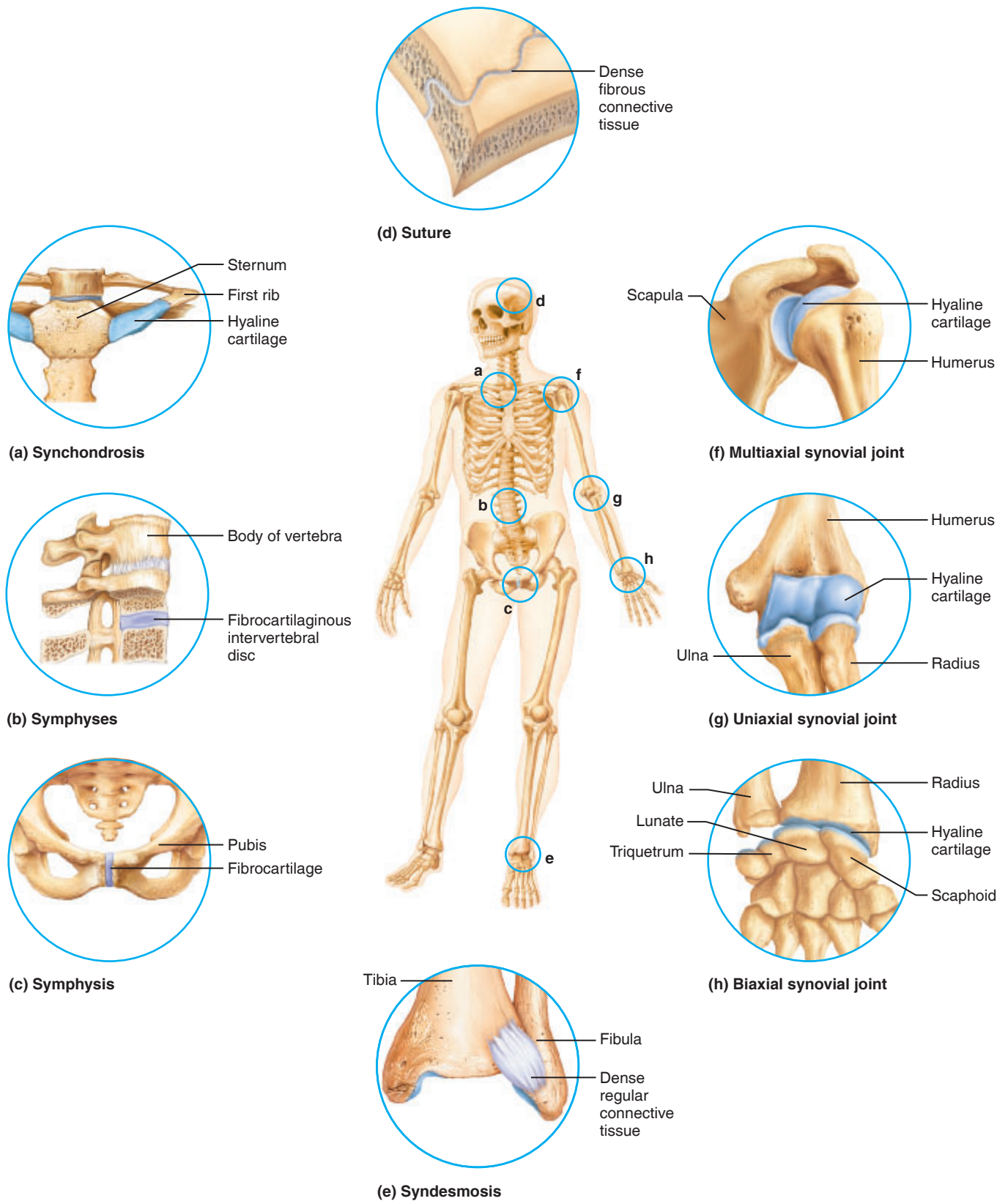


Figure 10.1 Types of joints. Joints to the left of the skeleton are cartilaginous joints; joints above and below the skeleton are fibrous joints; joints to the right of the skeleton are synovial joints. **(a)** Joint between costal cartilage of rib 1 and the sternum. **(b)** Intervertebral discs of fibrocartilage connecting adjacent vertebrae. **(c)** Fibrocartilaginous pubic symphysis connecting the pubic bones anteriorly. **(d)** Dense fibrous connective tissue connecting interlocking skull bones. **(e)** Ligament of dense regular connective tissue connecting the inferior ends of the tibia and fibula. **(f)** Shoulder joint. **(g)** Elbow joint. **(h)** Wrist joint.

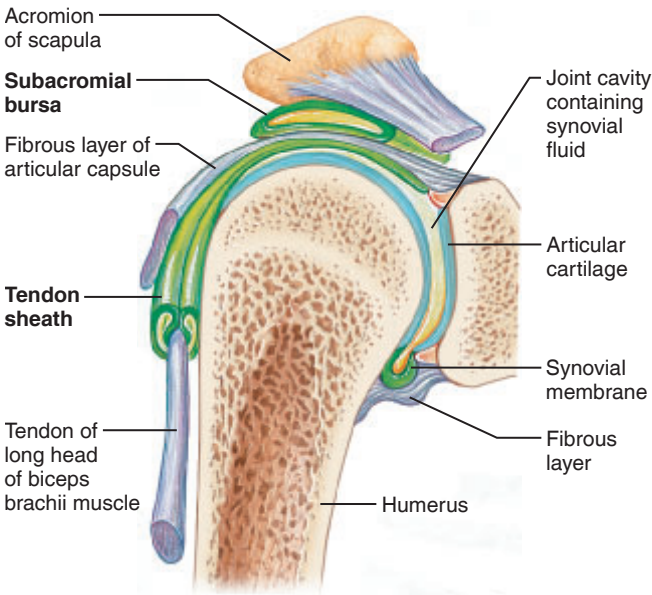


Figure 10.2 Major structural features of the shoulder joint, a synovial joint.

back and forth over one another. Assess the amount of friction generated.

3. Unclamp the balloon, and add more water. The goal is to get just enough water in the balloon so that your fists cannot come into contact with one another but remain separated by a thin water layer when pressure is applied to the balloon.

4. Once again, perform the same movements to assess the amount of friction generated.

How does the presence of a cavity containing fluid

influence the amount of friction generated? _____

What anatomical structure(s) does the water-containing balloon mimic?

What anatomical structures might be represented by your fists?

Activity 4

Demonstrating the Importance of Friction-Reducing Structures

1. Obtain a small water balloon and clamp. Partially fill the balloon with water (it should still be flaccid), and clamp it closed.
2. Position the balloon atop one of your fists and press down on its top surface with the other fist. Push on the balloon until your two fists touch, and move your fists

Activity 5

Identifying Types of Synovial Joints

Synovial joints are divided into the following subcategories on the basis of the movements they allow. As you read through the description of each joint type in **Table 10.2**, manipulate the joints identified as examples on yourself and on an articulated skeleton to observe its possible movements. Range of motion allowed by synovial joints varies from **uniaxial movement** (movement in one plane) to **biaxial movement** (movement in two planes) to **multiaxial movement** (movement in or around all three planes of space and axes).

Table 10.2 Types of Synovial Joints			
Synovial joint	Description of articulating surfaces	Movement	Examples
Plane	Flat or slightly curved bones	Nonaxial: gliding	Intertarsal, intercarpal joints
Hinge	A rounded or cylindrical bone fits into a concave surface on the other bone	Uniaxial: flexion and extension	Elbow, interphalangeal joints
Pivot	A rounded bone fits into a sleeve (a concave bone plus a ligament)	Uniaxial: rotation	Proximal radioulnar, atlantoaxial joints
Condylar	An oval condyle fits into an oval depression on the other bone	Biaxial: flexion, extension, adduction, and abduction	Metacarpophalangeal (knuckle) and radiocarpal joints
Saddle	Articulating surfaces are saddle shaped; one surface is concave, the other surface is convex	Biaxial: flexion, extension, adduction, and abduction	Carpometacarpal joint of the thumb
Ball-and-socket	The ball-shaped head of one bone fits into the cuplike depression of the other bone	Multiaxial: flexion, extension, adduction, abduction, and rotation	Shoulder, hip joints

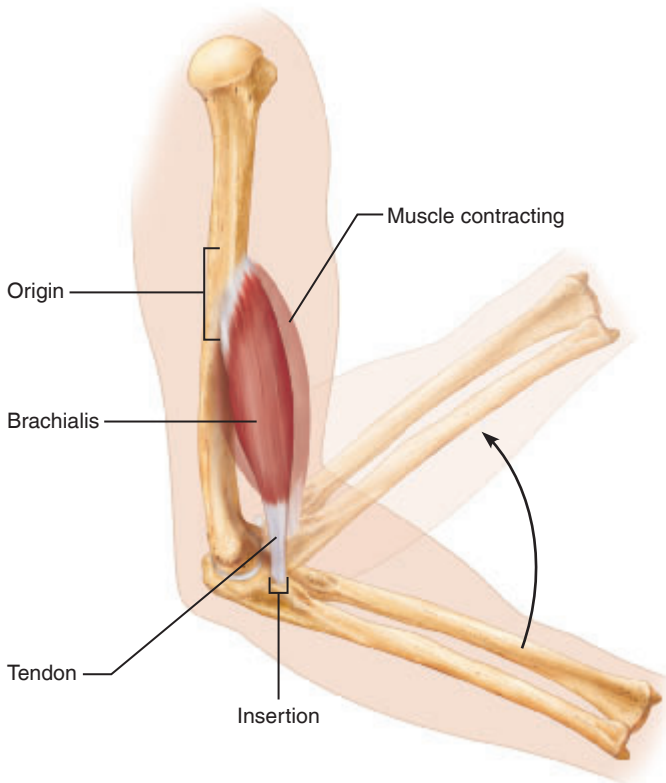


Figure 10.3 Muscle attachments (origin and insertion). When a skeletal muscle contracts, its insertion is pulled toward its origin.

Movements Allowed by Synovial Joints

Every muscle of the body is attached to bone (or other connective tissue structures) by at least two points—the **origin** is the stationary, immovable, or less movable bone, and the **insertion** is the movable bone. Body movement occurs when muscles contract across diarthrotic synovial joints (**Figure 10.3**). When the muscle contracts and its fibers shorten, the insertion moves toward the origin. The type of movement depends on the construction of the joint (uniaxial, biaxial, or multiaxial) and on the position of the muscle relative to the joint. The most common types of body movements are described in the following activity and illustrated in **Figure 10.4**.

Activity 6

Demonstrating Movements of Synovial Joints

Attempt to demonstrate each movement on a skeleton or on yourself as you read through the following material:

Flexion (Figure 10.4a–c): A movement, generally in the sagittal plane, that decreases the angle of the joint and

reduces the distance between the two bones. Flexion is typical of hinge joints (bending the knee or elbow), but it is also common at ball-and-socket joints (bending forward at the hip).

Extension (Figure 10.4a–c): A movement that increases the angle of a joint and the distance between two bones. Extension is the opposite of flexion. If extension is greater than 180 degrees (for example, bending the trunk or head backward), it is termed *hyperextension* (Figure 10.4a).

Abduction (Figure 10.4d): Movement of a limb away from the midline of the body, along the frontal plane, or the fanning movement of fingers or toes when they are spread apart.

Adduction (Figure 10.4d): Movement of a limb toward the midline of the body. Adduction is the opposite of abduction.

Rotation (Figure 10.4e): Movement of a bone around its longitudinal axis. Rotation, a common movement of ball-and-socket joints, also describes the movement of the atlas around the dens of the axis.

Circumduction (Figure 10.4d): A combination of flexion, extension, abduction, and adduction commonly observed in ball-and-socket joints like the shoulder. The limb as a whole outlines a cone.

Pronation (Figure 10.4f): Movement of the palm of the hand from an anterior or upward-facing position to a posterior or downward-facing position. The distal end of the radius rotates over the ulna so that the two bones form an X.

Supination (Figure 10.4f): Movement of the palm from a posterior position to an anterior position (the anatomical position). Supination is the opposite of pronation. During supination, the radius and ulna are parallel.

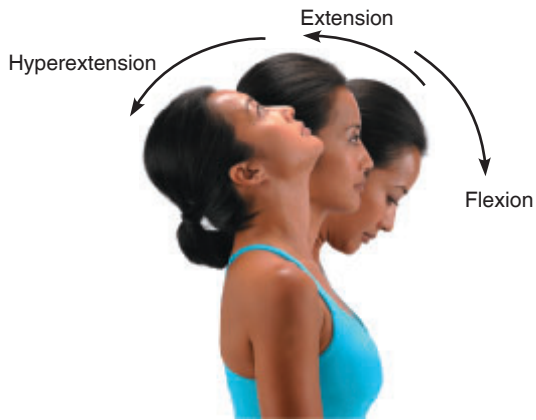
The last four terms refer to movements of the foot:

Dorsiflexion (Figure 10.4g): A movement of the ankle joint in a dorsal direction (standing on one's heels).

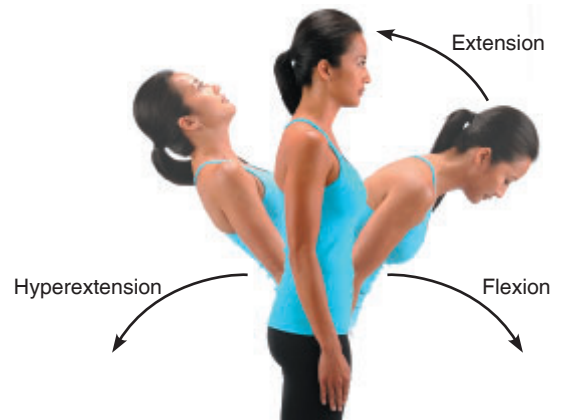
Plantar flexion (Figure 10.4g): A movement of the ankle joint in which the foot is flexed downward (standing on one's toes or pointing the toes).

Inversion (Figure 10.4h): A movement that results in the medial turning of the sole of the foot.

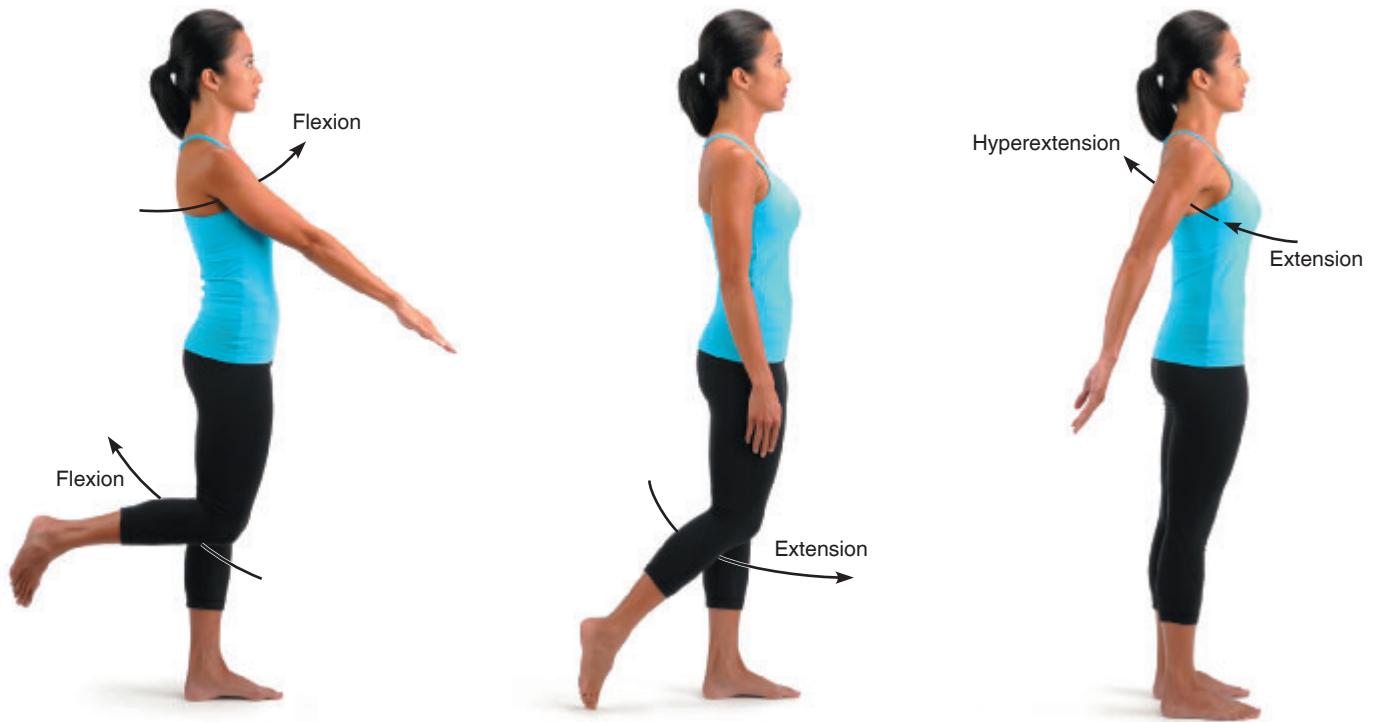
Eversion (Figure 10.4h): A movement that results in the lateral turning of the sole of the foot; the opposite of inversion.



(a) Flexion, extension, and hyperextension of the neck

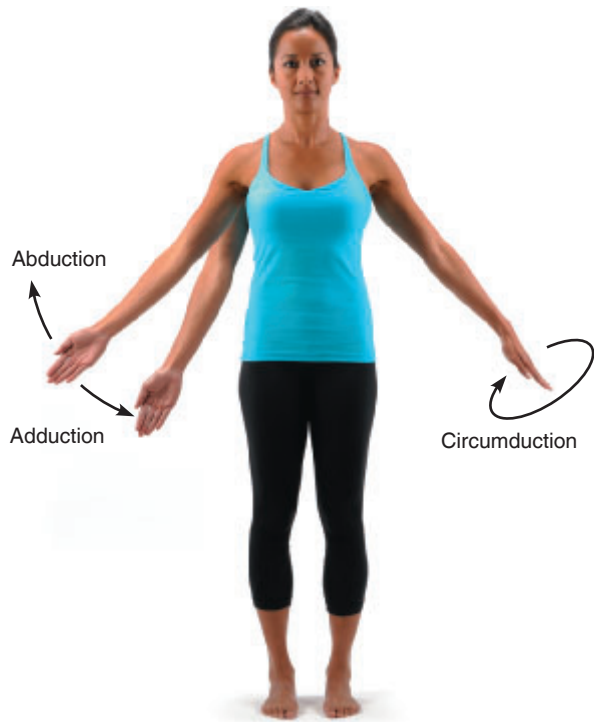

(b) Flexion, extension, and hyperextension of the vertebral column

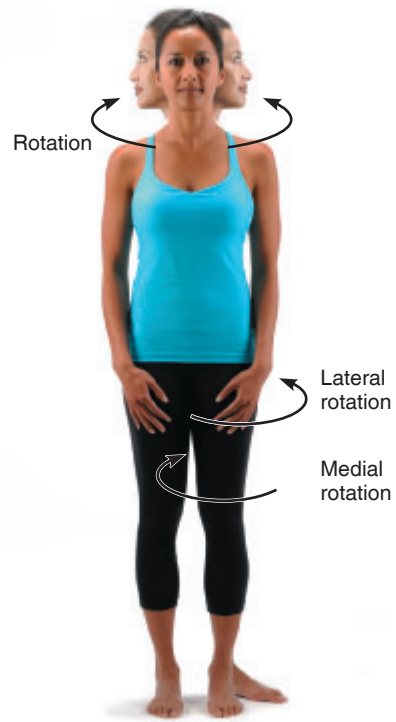


(c) Flexion and extension at the shoulder and knee, and hyperextension of the shoulder

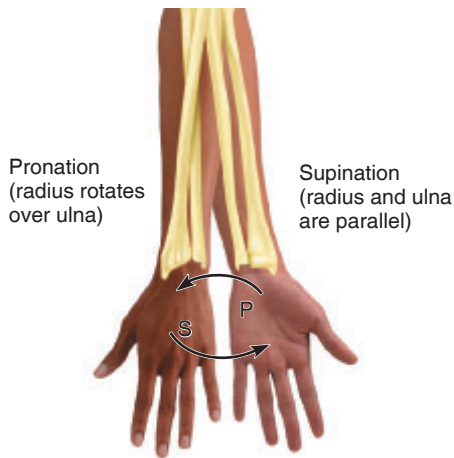
Figure 10.4 Movements occurring at synovial joints of the body.



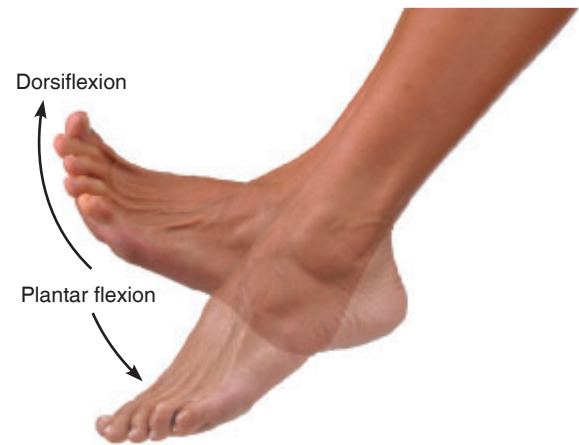(d) Abduction, adduction, and circumduction of the upper limb at the shoulder



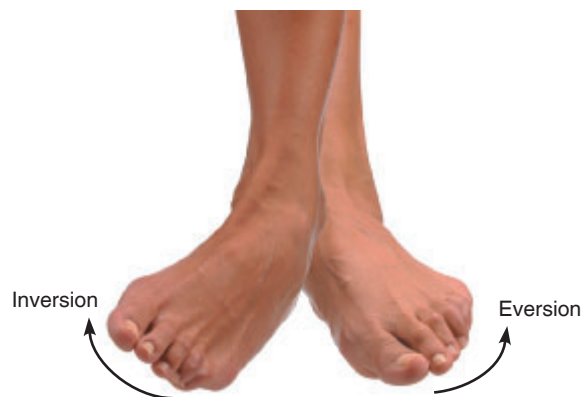(e) Rotation of the head and lower limb



(f) Supination (S) and pronation (P) of the forearm



(g) Dorsiflexion and plantar flexion of the foot



(h) Inversion and eversion of the foot

Figure 10.4 (continued)

Activity 7

Demonstrating Uniaxial, Biaxial, and Multiaxial Movements

Using the information in the previous activity, perform the following demonstrations and complete the **Activity 7 charts**.

1. Demonstrate movement at two joints that are uniaxial.

Activity 7: Uniaxial Joints	
Name of joint	Movement allowed

2. Demonstrate movement at two joints that are biaxial.

Activity 7: Biaxial Joints		
Name of Joint	Movement allowed	Movement allowed

3. Demonstrate movement at two joints that are multiaxial.

Activity 7: Multiaxial Joints			
Name of joint	Movement allowed	Movement allowed	Movement allowed

Joint Disorders

Most of us don't think about our joints until something goes wrong with them. Joint pains and malfunctions have a variety of causes. For example, a hard blow to the knee can cause a painful bursitis, known as "water on the knee," due to damage to the patellar bursa. Tearing a ligament may result in a painful condition that persists over a long period because these poorly vascularized structures heal so slowly. Similarly, the fibrocartilage of the knee joint that forms the meniscus can tear and require surgical repair.

Advancing years also take their toll on joints. Weight-bearing joints in particular eventually begin to degenerate. *Adhesions* (fibrous bands) may form between the surfaces where bones join, and excess bone tissue (*spurs*) may grow along the joint edges.

- If possible, compare an X-ray image of an arthritic joint to one of a normal joint.

EXERCISE
10

REVIEW SHEET

Joints and Body Movements

Name _____ Lab Time/Date _____

Types of Joints

1. Use the key terms to identify the joint types described below.

Key: cartilaginous fibrous synovial

- _____ 1. include shoulder, elbow, and wrist joints
- _____ 2. includes joints between the vertebral bodies and the pubic symphysis
- _____ 3. sutures are memorable examples
- _____ 4. found in the epiphyseal plate
- _____ 5. found in a gomphosis
- _____ 6. have a fibrous articular capsule lined with a synovial membrane surrounding a joint cavity
- _____ 7. all are freely movable or diarthrotic
- _____ 8. bone regions are united by dense regular connective tissue

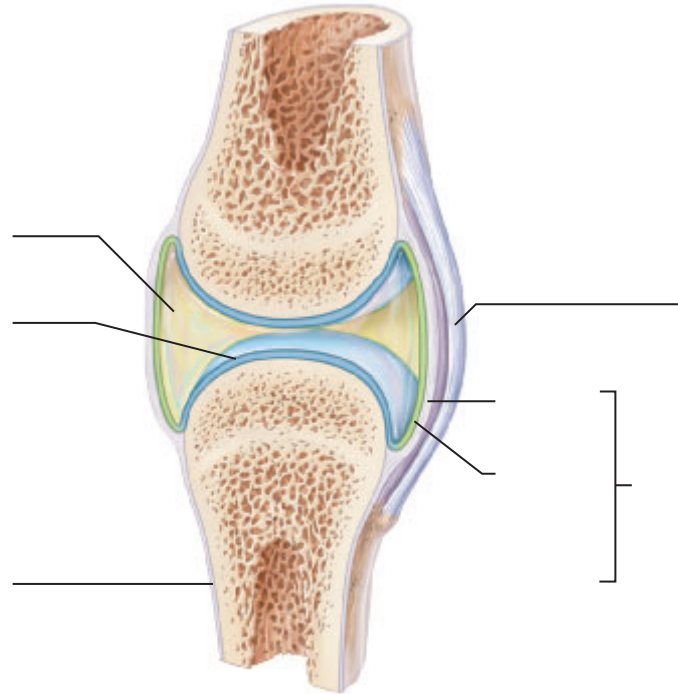
2. Match the joint subcategories in column B with their descriptions in column A, and place an asterisk (*) beside all choices that are examples of synovial joints.

Column A	Column B
_____ 1. joint between most skull bones	ball-and-socket
_____ 2. joint between the axis and atlas	condyloid
_____ 3. hip joint	gliding
_____ 4. joint between forearm bones and wrist	hinge
_____ 5. elbow	pivot
_____ 6. interphalangeal joints	saddle
_____ 7. intercarpal joints	suture
_____ 8. joint between the skull and vertebral column	symphysis
_____ 9. joints between proximal phalanges and metacarpal bones	syndesmosis

3. What characteristics do all joints have in common? _____

4. Label the diagram of a typical synovial joint using the terms provided in the key and the appropriate leader lines.

- Key:
- a. articular capsule
 - b. articular cartilage
 - c. fibrous layer
 - d. joint cavity
 - e. ligament
 - f. periosteum
 - g. synovial membrane



5. Which joint, the hip or the knee, is more stable? _____

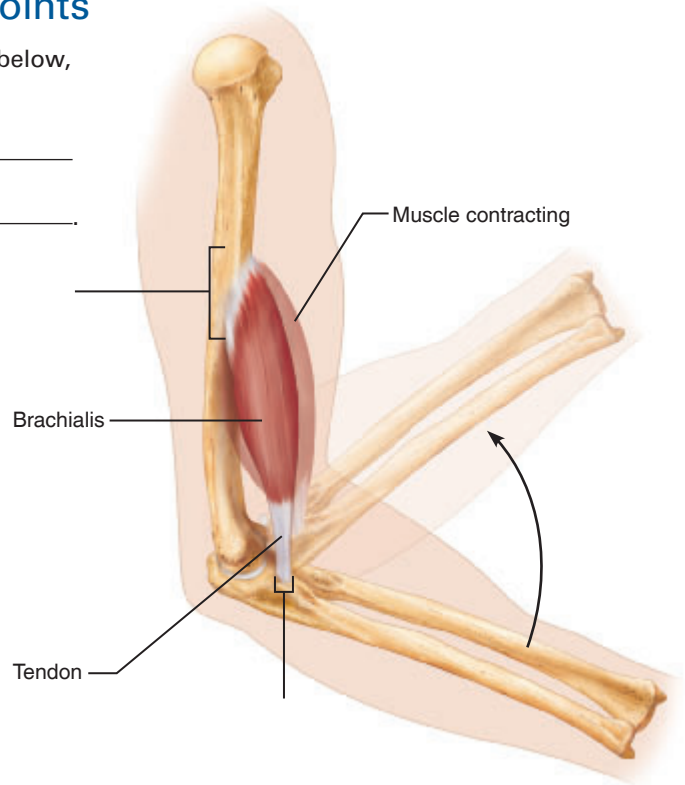
Name two important factors that contribute to the stability of the hip joint.

_____ and _____


Movements Allowed by Synovial Joints

6. Label the *origin* and *insertion* points on the diagram below, and complete the following statement:

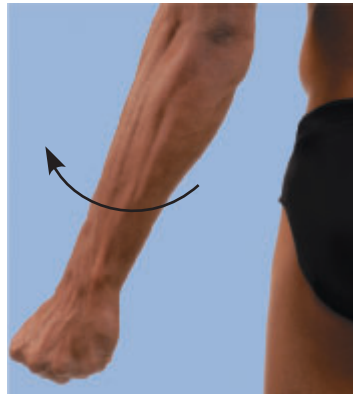
During muscle contraction, the _____
 moves toward the _____.



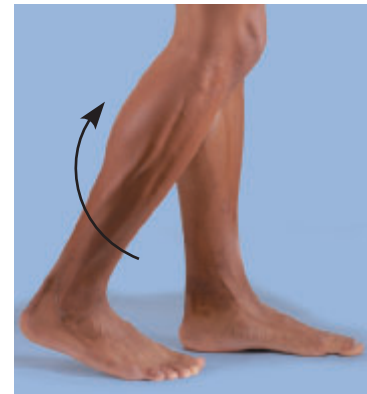7. Complete the descriptions below the diagrams by inserting the type of movement in each answer blank.



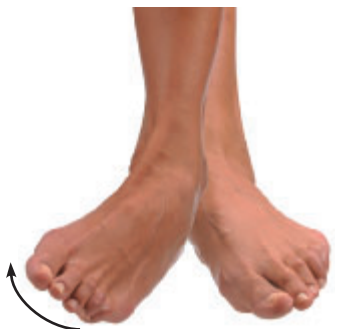(a) _____ at the elbow



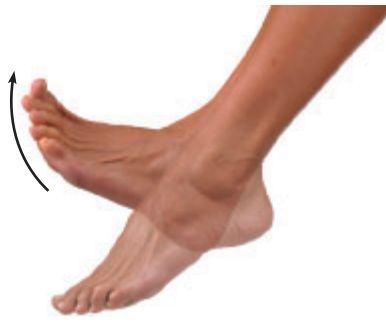(b) _____ of the upper limb



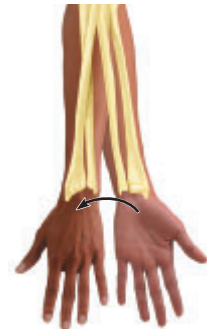(c) _____ at the knee



(d) _____ of the foot




(e) _____ of the foot




(f) _____ of the forearm

Joint Disorders

8. What structural joint changes are common in older people? _____

9.  A physician diagnoses you with "olecranon bursitis." Predict the location and cause of the swelling that you are experiencing. _____

10.  The menisci in the knee joint can be torn for a variety of reasons. Considering the structure of the menisci, would you expect these tears to heal on their own? _____

Why or why not? _____

Microscopic Anatomy and Organization of Skeletal Muscle

Materials

- Three-dimensional model of skeletal muscle fibers (if available)
- Glass teasing needles or forceps
- Glass microscope slides
- Petri dishes
- ATP muscle kits (glycerinated rabbit psoas muscle;* ATP and salt solutions obtainable from Carolina Biological Supply)
- Millimeter ruler
- Dissecting microscope
- Three-dimensional model of skeletal muscle showing neuromuscular junction (if available)
- Demonstration area: Histologic slides of skeletal muscle (longitudinal and cross-sectional views) and skeletal muscle showing neuromuscular junctions set up for student viewing

* Note to the Instructor: At the beginning of the lab, the muscle bundle should be removed from the test tube and cut into ~ 5-cm lengths. Both the cut muscle segments and the entubed glycerol should be put into a petri dish. One muscle *segment* is sufficient for each group of four students making observations.

Learning Outcomes

- Describe the microscopic structure of skeletal muscle, and explain the role of myofibrils and myofilaments.
- Describe gross muscle structure, and indicate the names of its connective tissue coverings.
- Describe the structure and function of the neuromuscular junction.
- List the criteria used in naming muscles.
- Define terms used to describe muscle actions in the body.

The bulk of the body's muscle is called **skeletal muscle** because it is attached to the skeleton. Skeletal muscle influences body shape, and it allows you to smile and frown, move around, and manipulate the environment. The remaining muscle tissue of the body consists of smooth muscle, which forms the walls of hollow organs, and cardiac muscle, which forms the walls of the heart.

Each of the three muscle types has a structure and function uniquely suited to its function in the body. However, the term *muscular system* applies specifically to skeletal muscle, and our objective here is to investigate the structure and function of skeletal muscle.

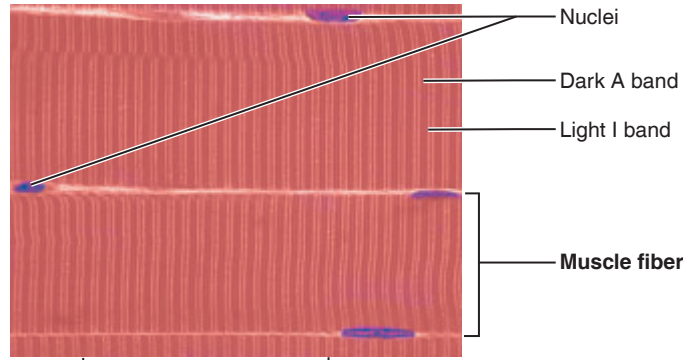
The Cells of Skeletal Muscle

Skeletal muscle is composed of relatively large cylindrical cells called **muscle fibers**. Some range up to 25 or 30 cm (10–12 in.) in length and can be seen with the naked eye.

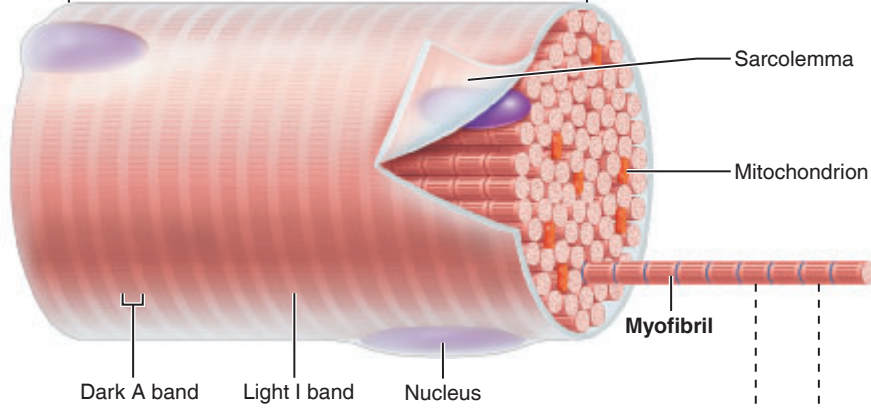
Skeletal muscle cells (**Figure 11.1a** and **b**) are multinucleate. The multiple oval nuclei can be seen just beneath the plasma membrane (called the *sarcolemma* in these cells). The nuclei are pushed aside by longitudinally arranged **myofibrils**, which nearly fill the cell interior (Figure 11.1c). Alternating light (I) and dark (A) bands along the length of the perfectly aligned myofibrils give the muscle fiber as a whole its striped appearance.

The myofibrils are made up of even smaller threadlike structures called **myofilaments** (Figure 11.1c–e). The myofilaments are composed largely of two varieties of contractile proteins—**actin** and **myosin**—which slide past each other during muscle activity to bring about shortening or contraction. The precise arrangement of the myofilaments within the myofibrils is responsible for the banding pattern in skeletal muscle. The actual contractile units of muscle, called **sarcomeres**, extend from the middle of one I band (its Z disc, or Z line) to the middle of the next, along the length of the myofibrils. (See Figure 11.1c–e.)

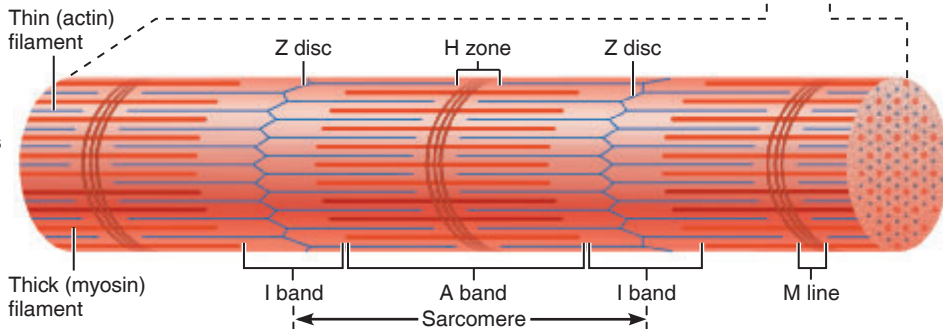
(a) Photomicrograph of portions of two isolated muscle fibers (700×). Notice the obvious striations (alternating dark and light bands).



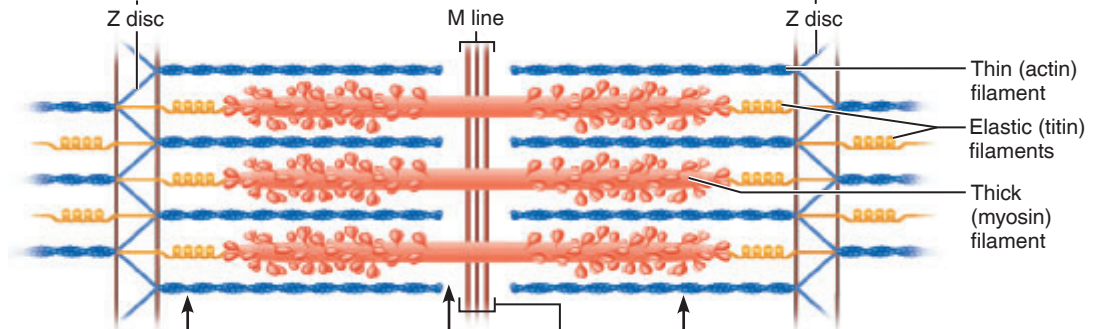
(b) Diagram of part of a muscle fiber showing the myofibrils. One myofibril extends from the cut end of the fiber.



(c) Small part of one myofibril enlarged to show the myofilaments responsible for the banding pattern. Each sarcomere (contractile unit) extends from one Z disc to the next.



(d) Enlargement of one sarcomere (sectioned lengthwise). Notice the myosin heads on the thick filaments.



(e) Cross-sectional view of a sarcomere cut through in different locations.

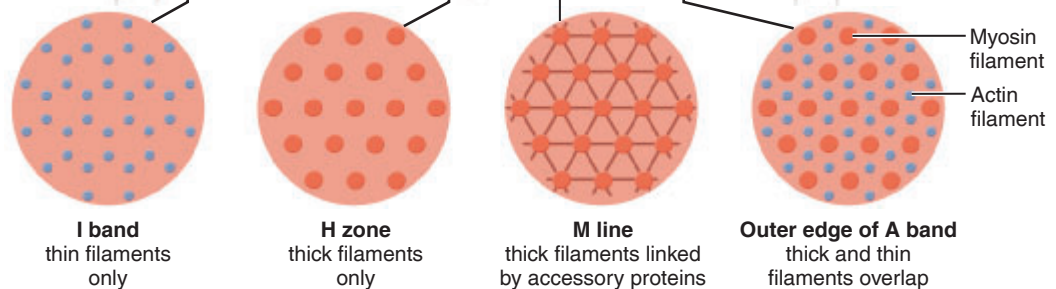


Figure 11.1 Microscopic anatomy of a skeletal muscle fiber.

Activity 1

Examining Skeletal Muscle Cell Anatomy

1. Look at the three-dimensional model of skeletal muscle cells, paying attention to the relative shape and size of the cells. Identify the nuclei, myofibrils, and light and dark bands.
2. Now go to the demonstration area and view professionally prepared skeletal muscle (longitudinal section) under the microscope. Identify nuclei and A and I bands. Compare your observations with **Figure 11.2** and Plate 2 in the Histology Atlas.

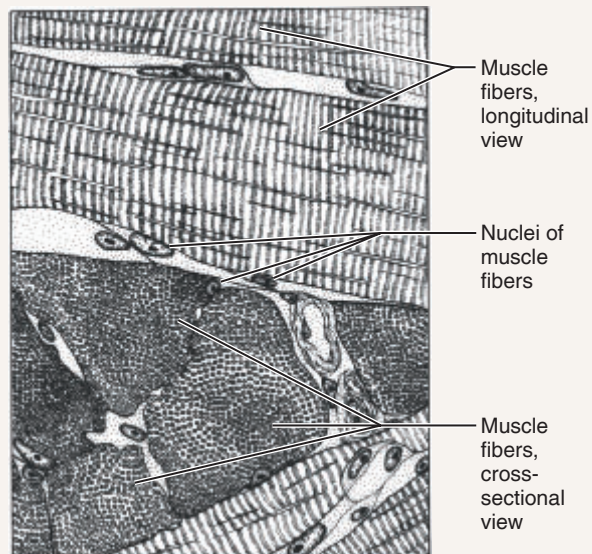


Figure 11.2 Muscle fibers, longitudinal and transverse views. (See also Plate 2 in the Histology Atlas.)

Muscle Fiber Activity

The contraction of skeletal muscle fibers can be considered in terms of three important events—excitation of the fibers by an action potential traveling along their length, release of calcium ions from the sarcoplasmic reticulum into the sarcoplasm (in response to the action potential), and shortening of

the muscle cell due to sliding of the myofilaments inside it. However, this is not the end of the story—for contraction to occur, the proper ions must be present, and cellular energy (ATP) must be readily available. Let's take a look.

Activity 2

Observing Muscle Fiber Contraction

In this simple observational experiment, you will have the opportunity to reinforce your understanding of muscle fiber anatomy and to watch fibers contracting (or not contracting) in response to the presence of certain chemicals (ATP, and potassium and magnesium ions).

1. Obtain the following materials from the supply area: two glass teasing needles or forceps, three glass microscope slides, millimeter ruler, dropper vials containing the following solutions: (a) 0.25% ATP in triply distilled water; (b) 0.25% ATP plus 0.05 M KCl plus 0.001 M $MgCl_2$ in distilled water; and (c) 0.05 M KCl plus 0.001 M $MgCl_2$ in distilled water; a petri dish; and a small portion of a previously cut muscle bundle segment. While you are at the supply area, place the muscle fibers in the petri dish, and pour a small amount of glycerol (the fluid in the supply petri dish) over your muscle fibers. Also obtain a dissection microscope and bring it to your laboratory bench.

2. Using the fine glass needles or forceps, tease the muscle segment to separate its fibers. The objective is to isolate *single* muscle cells or fibers for observation. Be patient and work carefully so that you don't tear the fibers.

3. Transfer three or four fibers (the thinnest strands you have obtained) to a second clean microscope slide with a glass needle. Using the needle or forceps as a prod, position the fibers so that they are parallel to one another and as straight as possible. Place this slide under a dissecting microscope, and measure the length of each fiber by holding a millimeter ruler next to it or by resting the microscope slide *on* the millimeter ruler. Record the fiber lengths on the **Activity 2 chart**.

4. Flood the fibers (still situated under the dissecting microscope) with several drops of the solution containing ATP, potassium ions, and magnesium ions. Watch how the fibers react to the solution. After 30 seconds (or slightly

Text continues on next page. →

longer), remeasure each fiber and record the observed lengths on the chart. Also, check the fibers to see whether any width changes have occurred. Calculate the percentage of contraction by using the following simple formula, and record this information on the Activity 2 chart.

$$\frac{\text{initial length (mm)} - \text{ending length (mm)}}{\text{initial length (mm)}} = \text{net change (mm)}$$

then:

$$\frac{\text{net change (mm)}}{\text{initial length (mm)}} \times 100 = \text{_____ \% contraction}$$

Activity 2: Muscle Fiber Contraction

	Salts and ATP muscle fiber 1	ATP only muscle fiber 2	Salts only muscle fiber 3
Initial length (mm)			
Ending length (mm)			
% contraction			

5. Repeat steps 3 and 4 twice more, using clean slides and fresh muscle fibers. First use the solution of ATP in distilled water (no salts). Then, use the solution containing only salts (no ATP) for the third series.

What percentage of contraction did you observe when ATP was applied in the absence of potassium and magnesium ions?

What percentage of contraction did you observe when the muscle fibers were flooded with a solution containing K^+ and Mg^{2+} but lacking ATP?

What conclusions can you draw about the importance of ATP and of potassium and magnesium ions to the ability of muscle fibers to contract?

Organization of Skeletal Muscle Cells into Muscles

Muscle fibers, which are soft and fragile, are bundled together with connective tissue to form skeletal muscles (**Figure 11.3**). Each muscle fiber is enclosed in a delicate connective tissue sheath called **endomysium**. Several sheathed muscle fibers are wrapped by a collagenic membrane called **perimysium**, forming a muscle fiber bundle called a **fascicle**. A large number of fascicles are bound together by a substantially coarser “overcoat” of dense irregular connective tissue called an **epimysium**, which encloses the entire muscle. All three sheaths blend into strong cordlike **tendons** or sheetlike **aponeuroses**, which attach muscles to each other or indirectly to bones. A muscle’s more movable attachment is called its *insertion*, whereas its fixed (or immovable) attachment is the *origin* (see Exercise 10).

In addition to supporting and binding the muscle fibers, and providing strength to the muscle as a whole, the connective tissue wrappings provide a route for the entry and exit of nerves and blood vessels that serve the muscle fibers.

Activity 3

Observing the Structure of a Skeletal Muscle

Go to the appropriate microscope at the demonstration area and examine a slide showing a cross section of a skeletal muscle. Identify the muscle fibers, endomysium, perimysium, and epimysium, if visible (refer to Figure 11.3).

The Neuromuscular Junction

Skeletal muscle cells are always stimulated by motor neurons via nerve impulses. The junction between a nerve fiber (axon) and a muscle fiber is called a **neuromuscular junction** (**Figure 11.4**).

Each motor axon breaks up into many branches called *axon terminals* as it nears the muscle, and each branch forms a neuromuscular junction with a single muscle fiber.

Thus a single neuron may stimulate many muscle fibers. Together, a neuron and all the muscle fibers it stimulates make up the functional structure called the **motor unit** (**Figure 11.5**).

The neuron and muscle fiber membranes, close as they are, do not actually touch. They are separated by a small fluid-filled gap called the **synaptic cleft** (see Figure 11.4).

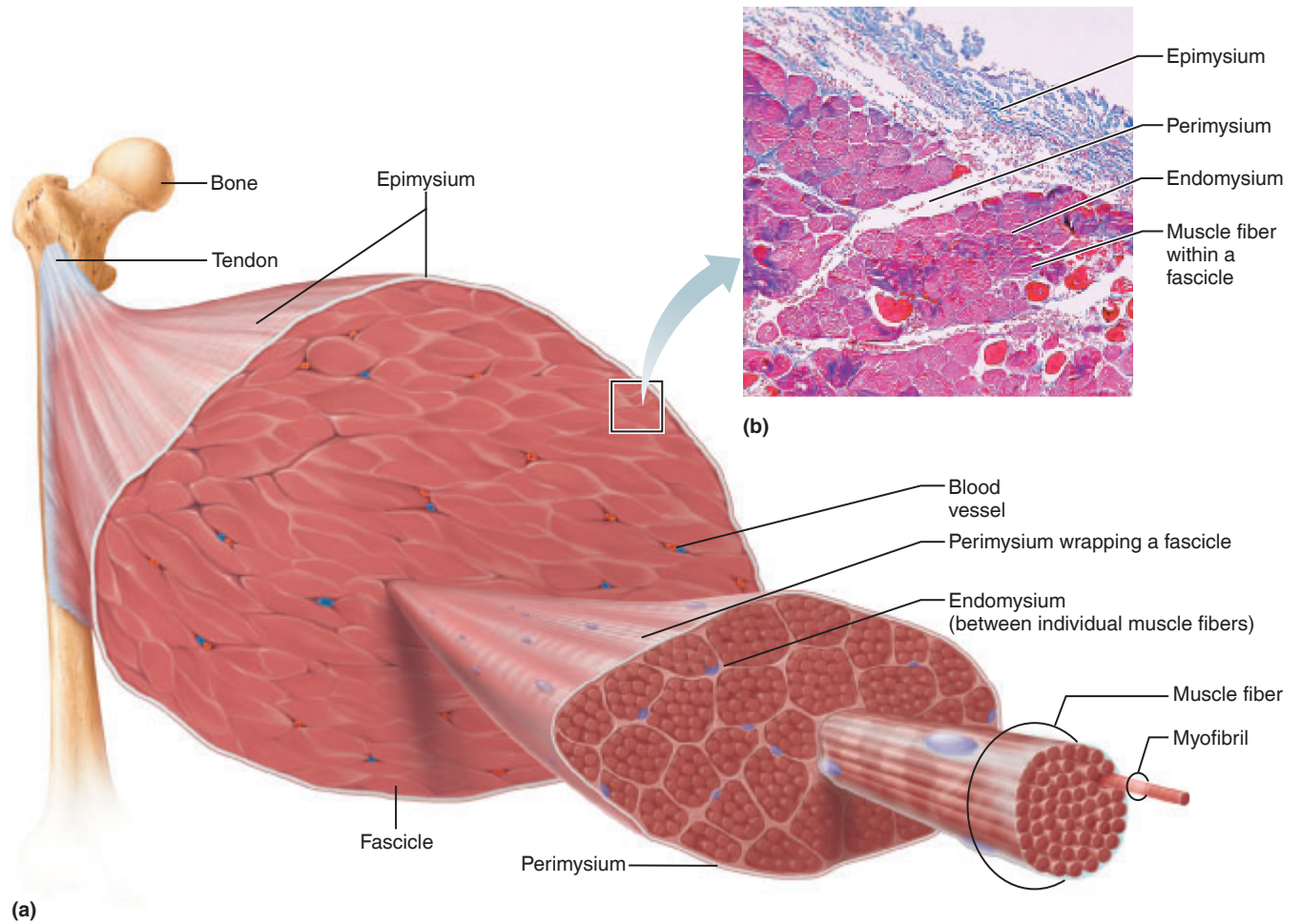


Figure 11.3 Connective tissue coverings of skeletal muscle.

Within the axon terminals are mitochondria and vesicles containing a neurotransmitter chemical called *acetylcholine* (*ACh*). When an action potential reaches the axon terminal, voltage-gated Ca^{2+} channels open. Ca^{2+} enters the axon terminal and causes *ACh* to be released by exocytosis. The

ACh rapidly diffuses across the synaptic cleft and combines with the receptors on the sarcolemma. When receptors bind *ACh*, the permeability of the sarcolemma changes briefly. Ion channels open for a short time, depolarizing the sarcolemma, and subsequent contraction of the muscle fiber occurs.

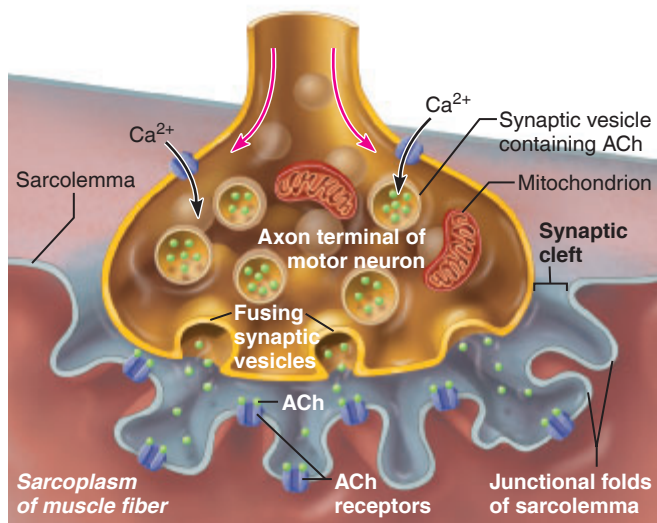


Figure 11.4 The neuromuscular junction.

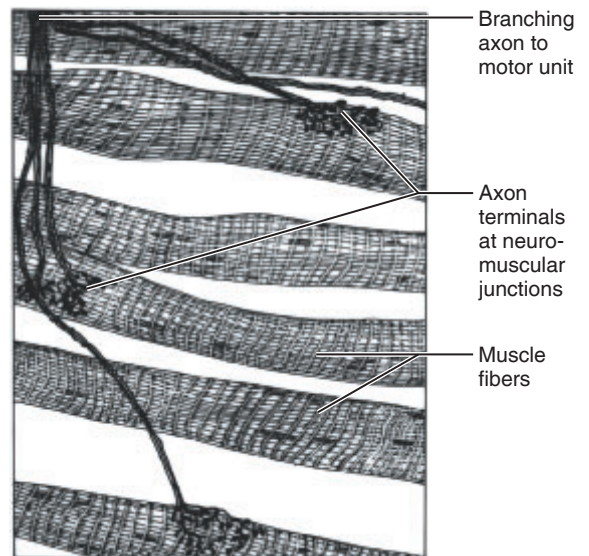


Figure 11.5 A portion of a motor unit.

Activity 4

Studying the Structure of a Neuromuscular Junction

1. If possible, examine a three-dimensional model of skeletal muscle fibers that illustrates the neuromuscular junction. Identify the structures just described.
2. Go to the demonstration area to examine a slide of skeletal muscle stained to show a portion of a motor unit.

Identify the axon branches extending like a leash to the muscle fibers. Follow one of the axons to its terminal branch to identify the oval-shaped axon terminal. Compare your observations to Figure 11.5 and Plate 4 in the Histology Atlas).

Classification of Skeletal Muscles

Naming Skeletal Muscles

Remembering the names of the skeletal muscles is a monumental task, but certain clues help. Muscles are named on the basis of the following criteria:

- **Direction of muscle fibers:** Some muscles are named relative to some imaginary line, usually the midline of the body or the longitudinal axis of a limb bone. For example, the rectus abdominis is the straight muscle of the abdomen. The terms *rectus*, *transverse*, and *oblique* indicate that the muscle fibers run with, at right angles, or obliquely (respectively) to the imaginary line.
- **Muscle size:** When size is the criterion, terms such as *maximus* (largest), *minimus* (smallest), *longus* (long), and *brevis* (short) are often used—as in gluteus maximus and gluteus minimus.
- **Muscle location:** Some muscles are named for the bone with which they are associated. For example, the temporalis muscle overlies the temporal bone.
- **Number of origins:** When the term *biceps*, *triceps*, or *quadriceps* forms part of a muscle name, you can assume that the muscle has two, three, or four origins (respectively). For example, the biceps muscle of the arm has two origins.
- **Location of attachments:** For example, the sternocleidomastoid muscle has its origin on the sternum (*sterno*)

and clavicle (*cleido*), and it inserts on the mastoid process of the temporal bone.

- **Muscle shape:** For example, the deltoid muscle is roughly triangular (*deltoid* = triangle), and the trapezius muscle resembles a trapezoid.
- **Muscle action:** For example, all the adductor muscles of the anterior thigh bring about its adduction.

Types of Muscles

Most often, body movements involve the coordinated action of several muscles acting together. Muscles that are primarily responsible for producing a particular movement are called **prime movers**, or **agonists**.

Muscles that oppose or reverse a movement are called **antagonists**. When a prime mover is active, the fibers of the antagonist are stretched and relaxed.

Synergists aid the action of prime movers by reducing undesirable or unnecessary movement. For example, you can make a fist without bending at the wrist only because synergist muscles stabilize the wrist joint.

Fixators, or fixation muscles, are specialized synergists. They immobilize the origin of a prime mover so that all the tension is exerted at the insertion. Muscles that help maintain posture and those that “fix” the scapula during arm movements are fixators.

EXERCISE
11

REVIEW SHEET

Microscopic Anatomy and Organization of Skeletal Muscle

Name _____ Lab Time/Date _____

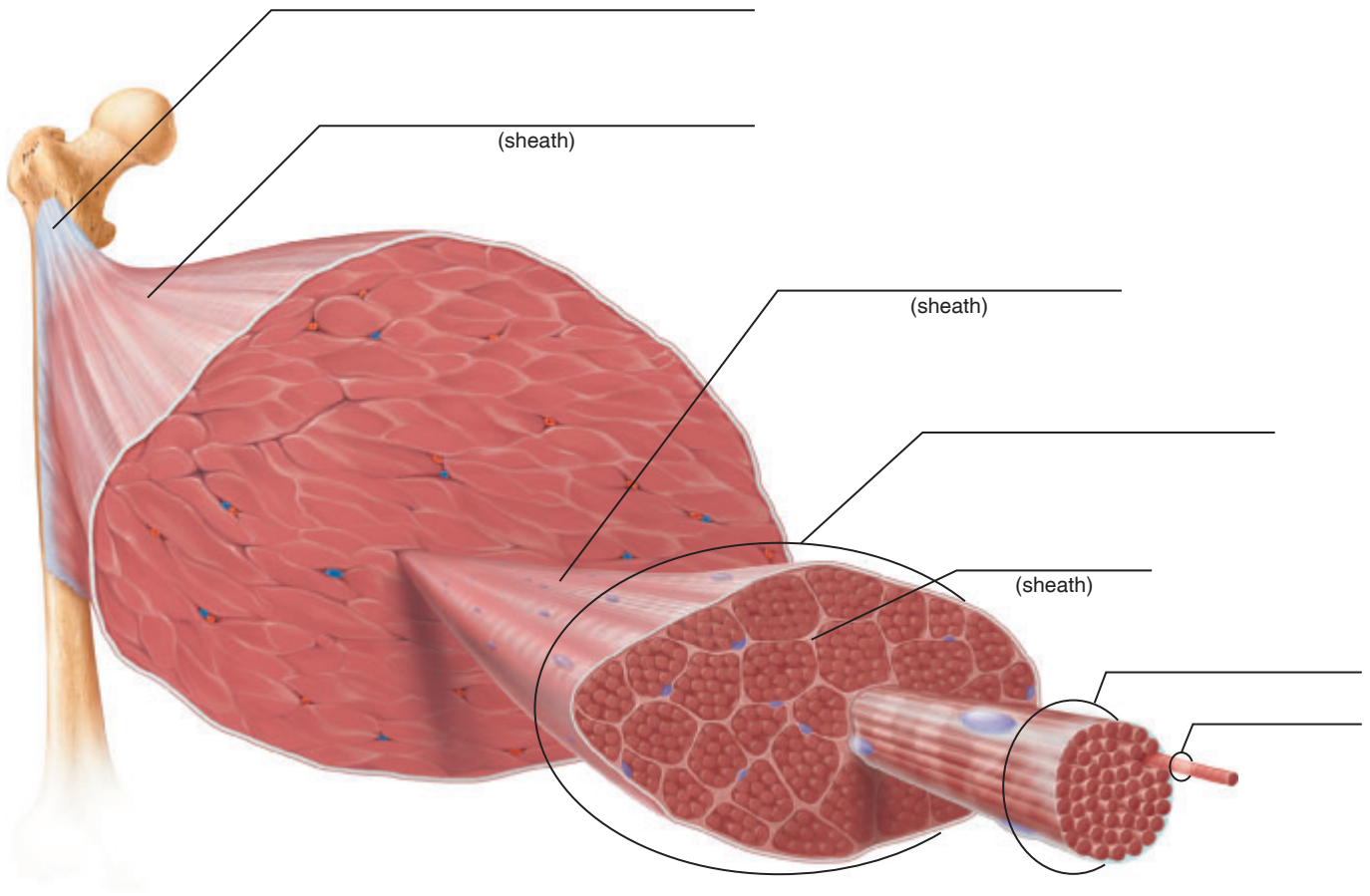
Skeletal Muscle Cells and Their Packaging into Muscles

1. From deep to superficial, name the three types of connective tissue sheaths of a skeletal muscle.

a. _____ b. _____ c. _____

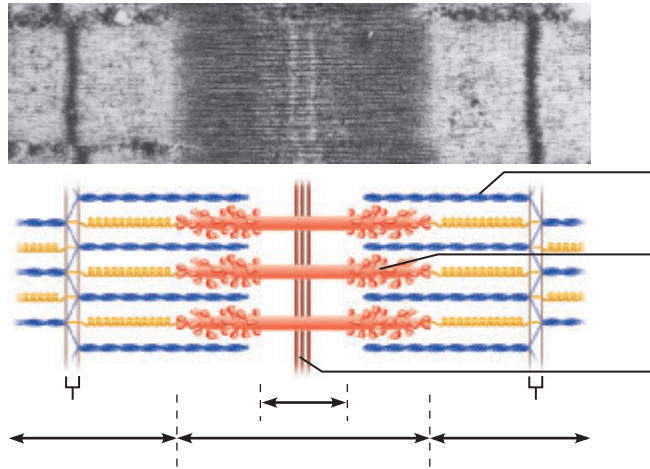
Why are the connective tissue wrappings of skeletal muscle important? (Give at least three reasons.)

2. On the following figure, label the endomysium, epimysium, a fascicle, a muscle fiber, a myofibril, perimysium, and the tendon.



3. The drawing and photomicrograph below show a relaxed sarcomere. Using the terms from the key, identify each structure indicated by a leader line or bracket. The number 2 in parentheses indicates that the structure will be labeled twice.

- Key:
- a. actin filament
 - b. A band
 - c. H zone
 - d. I band (2)
 - e. M line
 - f. myosin filament
 - g. Z disc (2)



4. Relative to your observations of muscle fiber contraction pages 123–124:
- a. What percentage of contraction did you observe with the solution containing ATP, K^+ , and Mg^{2+} ? _____ %
 With *just* ATP? _____ % With *just* Mg^{2+} and K^+ ? _____ %
 - b. *Explain* your observations. _____

The Neuromuscular Junction

5. For skeletal muscle fibers to contract, they must be excited by motor neurons. However, the electrical impulse cannot pass directly from a neuron to the skeletal muscle fibers to excite them. Just what *does pass* from the neuron to the muscle fibers, and what effect does it produce?

6. Why is it that the electrical impulse cannot pass from neuron to muscle fiber? _____

Classification of Skeletal Muscles

7. For each of the criteria below, list at least two muscles that are named for the given criterion.

1. Muscle location: _____

2. Muscle shape: _____

3. Muscle size: _____

4. Direction of muscle fibers: _____

5. Number of origins: _____

6. Location of attachments: _____

7. Muscle action: _____


8. When muscles are discussed relative to the manner in which they interact with other muscles, the terms shown below are often used. Define each term.


Antagonist: _____

Fixator: _____

Prime mover (agonist): _____

Synergist: _____

9.  Necrotizing fasciitis is a serious bacterial infection. Necrosis is death of tissues in the body. Considering the organization of the connective tissue sheaths of skeletal muscle, explain how this infection could spread rapidly throughout the body. _____

10.  The bacterium *Clostridium botulinum* secretes botulinum toxin, a neurotoxin. The toxin blocks the release of acetylcholine from the axon terminal of a motor neuron. Explain how the toxin binding would change the normal sequence of events at the neuromuscular junction. _____

This page intentionally left blank

Gross Anatomy of the Muscular System

Materials

- Human torso model or large anatomical chart showing human musculature
- Tubes of body (or face) paint
- 1-inch wide artist's bristle brushes

Learning Outcomes

- Name and locate the major muscles of the head and neck, and state their actions.
- Name and locate the major muscles of the trunk.
- Name and locate the major muscles of the upper limb.
- Name and locate the major muscles of the hip and lower limb.

Identification of Human Muscles

Muscles of the Head and Neck

The muscles of the head serve many functions. For instance, the muscles of facial expression differ from most skeletal muscles because they insert into the skin or other muscles rather than into bone. As a result, they move the facial skin, allowing the face to show a wide range of emotions. Other head muscles are the muscles of mastication, which are active during chewing, and the six extrinsic eye muscles located within the orbit, which aim the eye. Orbital muscles are studied in Exercise 17.

Neck muscles primarily move the head and shoulder girdle.

Activity 1

Identifying Head and Neck Muscles

On the next several pages you'll find summary figures illustrating the superficial muscles of the body (**Figures 12.1** and **12.2**) and a table and figure describing the head and neck muscles (**Table 12.1** on page 134 and **Figure 12.3** on page 135).

While reading the table and identifying the head and neck muscles in the figures, try to visualize what happens when the muscle contracts. Then, use a torso model or an anatomical chart to again identify as many of these muscles as possible. Also carry out the following palpation on yourself:

- To demonstrate the temporalis, clench your teeth. The masseter can also be palpated now at the angle of the jaw.

Muscles of the Trunk

The trunk musculature includes muscles that move the vertebral column; anterior thorax muscles that move the ribs, head, and arms; and abdominal muscles that help move the vertebral column and, even more important, form the “natural girdle,” or the major portion of the abdominal body wall.

(Text continues on page 136.)

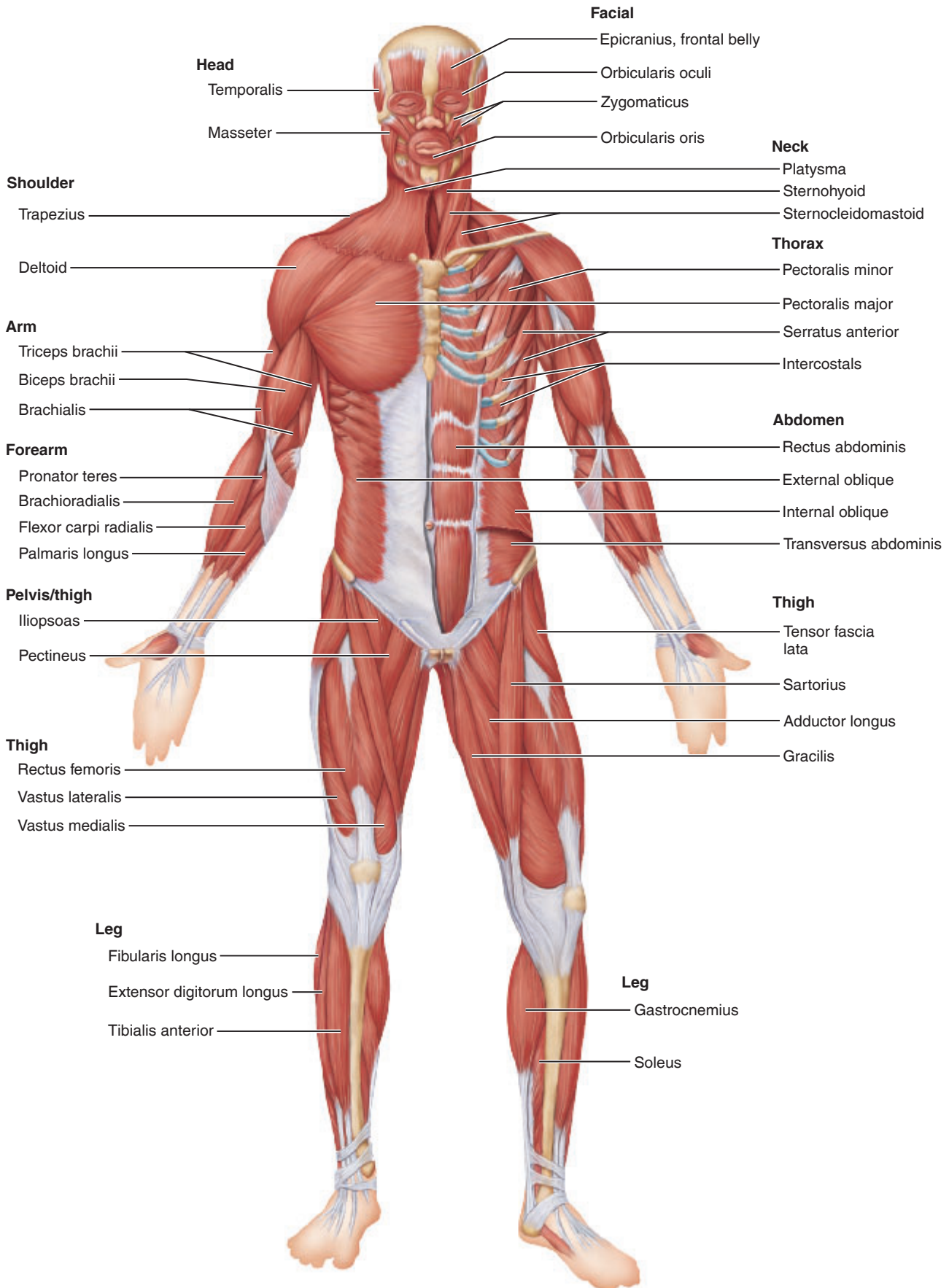


Figure 12.1 Anterior view of superficial muscles of the body. The abdominal surface has been partially dissected on the left side of the body to show somewhat deeper muscles.

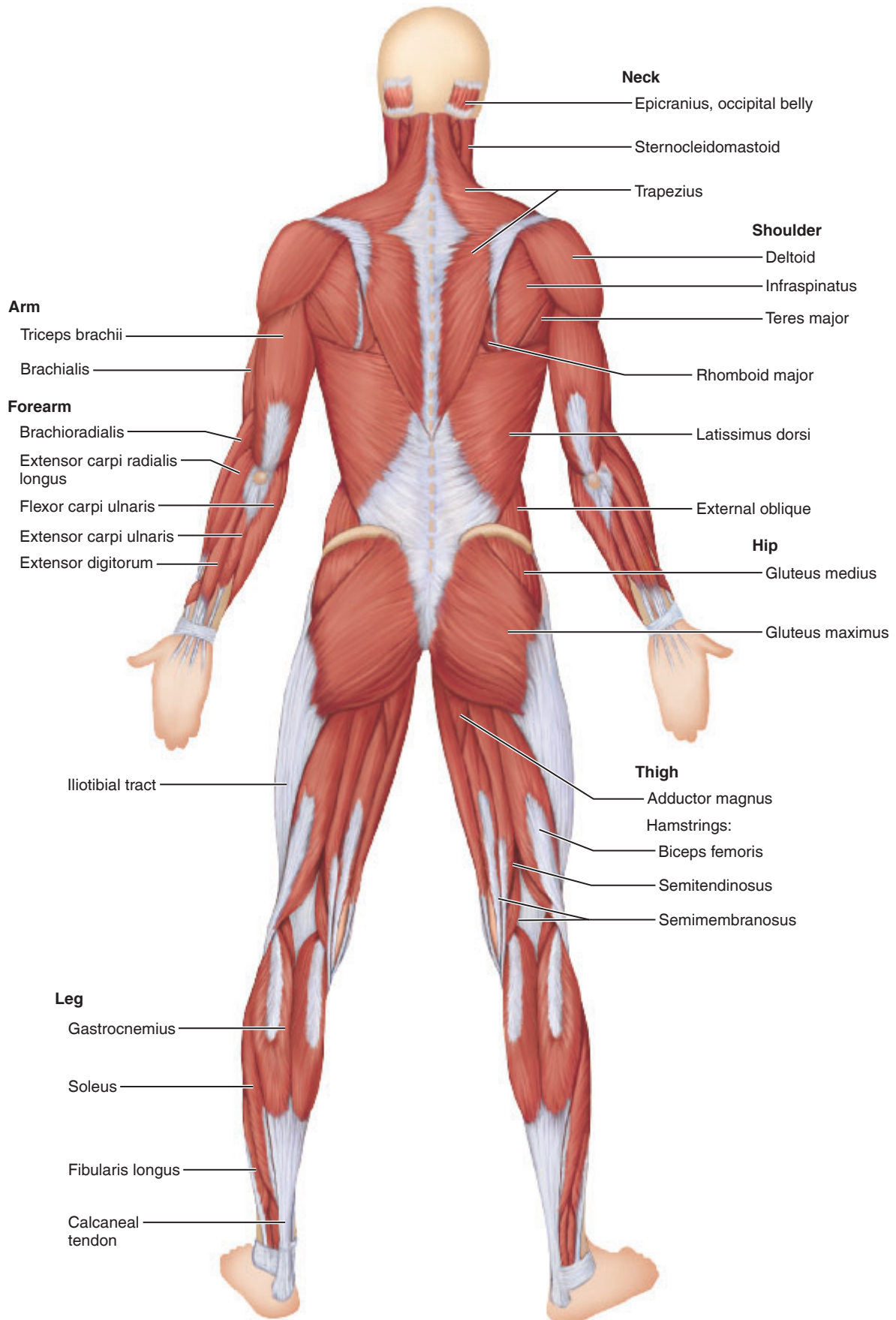


Figure 12.2 Posterior view of superficial muscles of the body.

Table 12.1 Major Muscles of Human Head and Neck (see Figure 12.3)

Muscle	Comments	Origin	Insertion	Action
Muscles of Facial Expression				
Epicranium—frontal and occipital bellies	Two-part muscle consisting of frontal and occipital bellies that cover dome of skull	Frontal belly: epicranial aponeurosis Occipital belly: occipital and temporal bones	Frontal belly: skin of eyebrows and root of nose Occipital belly: epicranial aponeurosis	With aponeurosis fixed, frontal belly raises eyebrows; occipital belly pulls scalp posteriorly
Orbicularis oculi	Sphincter muscle of eyelids	Frontal and maxillary bones	Tissue of eyelids	Closes eye, produces blinking and squinting
Zygomaticus	Extends diagonally from corner of mouth to cheekbone	Zygomatic bone	Skin and muscle at corner of mouth	Raises lateral corners of mouth upward (smiling muscle)
Orbicularis oris	Encircles mouth; sphincter muscle of lips with fibers that run in many different directions	Maxilla and mandible; fibers blended with fibers of other muscles associated with lips	Muscle and skin at angles of mouth	Closes mouth; purses and protrudes lips (kissing muscle)
Muscles of Mastication				
Masseter	Extends across jawbone	Zygomatic process and arch	Mandible	Closes jaw and elevates mandible
Temporalis	Fan-shaped muscle over temporal bone	Temporal bone	Mandible	Closes jaw and elevates mandible
Buccinator	Principal muscle of cheek; runs horizontally, deep to the masseter	Maxilla and mandible near molars	Orbicularis oris	Compresses cheek (as in whistling); holds food between teeth during chewing
Neck				
Platysma	Thin, sheetlike superficial neck muscle, plays role in facial expression	Fascia of chest (over pectoral muscles) and deltoid	Lower margin of mandible and muscle at corner of mouth	Tenses skin of neck; depresses mandible; pulls lower lip back and down (produces downward sag of the mouth)
Sternocleidomastoid	Two-headed muscle located deep to platysma on anterolateral surface of neck	Sternum and clavicle	Mastoid process of temporal bone	Simultaneous contraction of both muscles of pair causes flexion of neck forward; acting independently, rotate head toward opposite shoulder

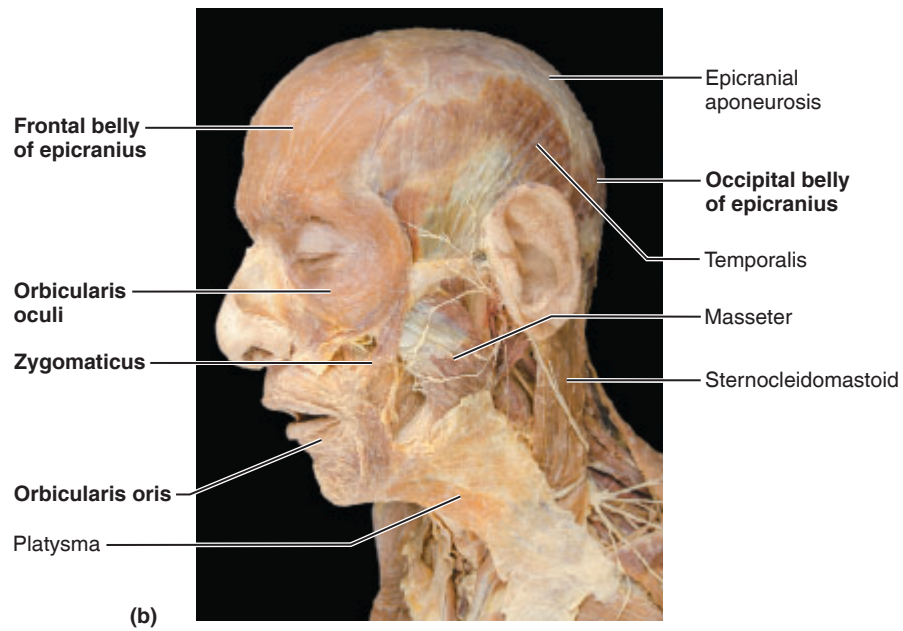
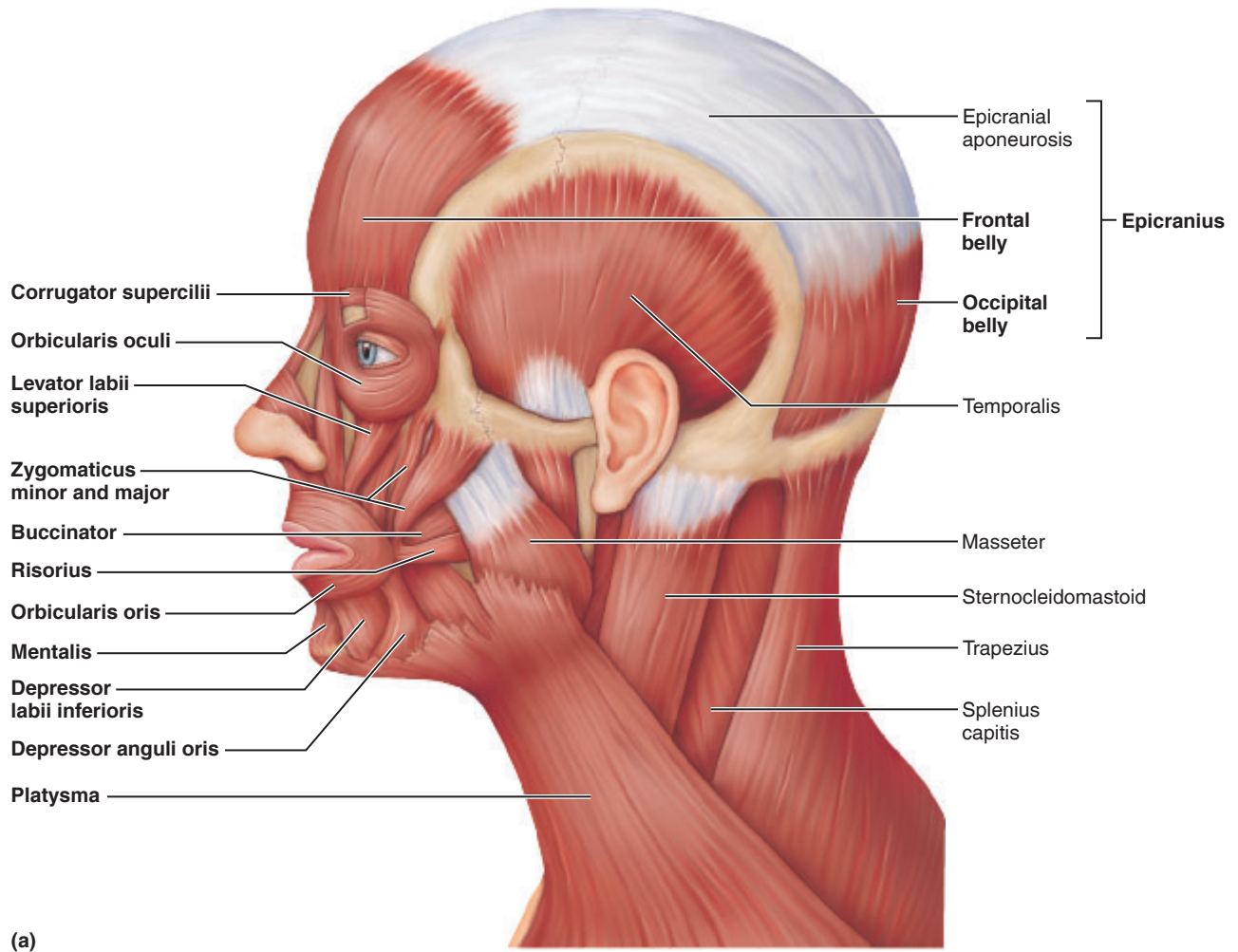


Figure 12.3 Muscles of the scalp, face, and neck; left lateral view. (a) Superficial muscles. (b) Photo of superficial structures of head and neck.

Table 12.2 Anterior Muscles of Trunk and Upper Limb (see Figure 12.4)

Muscle	Comments	Origin	Insertion	Action
Thorax and Shoulder, Superficial				
Pectoralis major	Large fan-shaped muscle covering upper portion of chest	Clavicle, sternum, and cartilage of first 6 ribs	Fibers insert by short tendon into greater tubercle of humerus	Prime mover of arm flexion; adducts, medially rotates arm
Deltoid	Fleshy triangular muscle forming shoulder muscle mass	Lateral third of clavicle; acromion and spine of scapula	Deltoid tuberosity of humerus	Acting as a whole, prime mover of arm abduction; when only specific fibers are active, can act as a synergist in flexion, extension, and rotation of arm
Abdominal Wall				
Rectus abdominis	Medial superficial muscle, extends from pubis to rib cage; segmented	Pubis	Xiphoid process and costal cartilages of ribs 5–7	Flexes vertebral column; increases abdominal pressure
External oblique	Most superficial lateral muscle; fibers run downward and medially	Anterior surface of lower eight ribs	Iliac crest	See rectus abdominis, above; also aids muscles of back to rotate and laterally flex the trunk
Internal oblique	Fibers run at right angles to those of external oblique, which it underlies	Iliac crest	Costal cartilages of lower three ribs	As for external oblique
Transversus abdominis	Deepest muscle of abdominal wall; fibers run horizontally	Iliac crest and cartilages of lower five or six ribs	Pubis	Compresses abdominal contents
Arm/Forearm				
Biceps brachii	Two-headed muscle of anterior arm	Coracoid process of scapula	Radial tuberosity	Flexes and supinates forearm
Brachialis (see Figure 12.1)	Immediately deep to the biceps brachii	Anterior surface of distal humerus	Coronoid process of ulna	Flexor of forearm
Brachioradialis (see Figure 12.1)	Superficial muscle of lateral forearm	Distal humerus	Base of radial styloid process	Synergist in forearm flexion
Pronator teres (see Figure 12.1)	Anterior forearm	Medial epicondyle of humerus and coronoid process of ulna	Midshaft of radius	Pronates forearm
Flexor carpi radialis (see Figure 12.1)	Superficial; runs diagonally across forearm	Medial epicondyle of humerus	Second and third metacarpals	Powerful flexor and abductor of the hand
Flexor carpi ulnaris (see Figure 12.2)	Superficial; medial to flexor carpi radialis	Medial epicondyle of humerus and posterior ulna	Fifth metacarpal and carpals	Flexes and adducts hand
Flexor digitorum superficialis (not illustrated)	Deeper muscle; overlain by muscles named above; visible at distal end of forearm	Medial epicondyle of humerus, ulna, and radius	Middle phalanges of second through fifth fingers	Flexes hand and middle phalanges of second through fifth fingers

Activity 2

Identifying Muscles of the Trunk

Identify the trunk muscles (described in **Tables 12.2** and **12.3** and shown in **Figures 12.4** and **12.5**). Identify the muscles in the figures as you read the tabular descriptions, and then identify them on the torso or laboratory chart.

Activity 3

Demonstrating Operation of Trunk Muscles

Now work with a partner to demonstrate the operation of the following muscles. One of you can demonstrate the movement (the following steps are addressed to this partner). The other can supply resistance and palpate the muscle being tested.

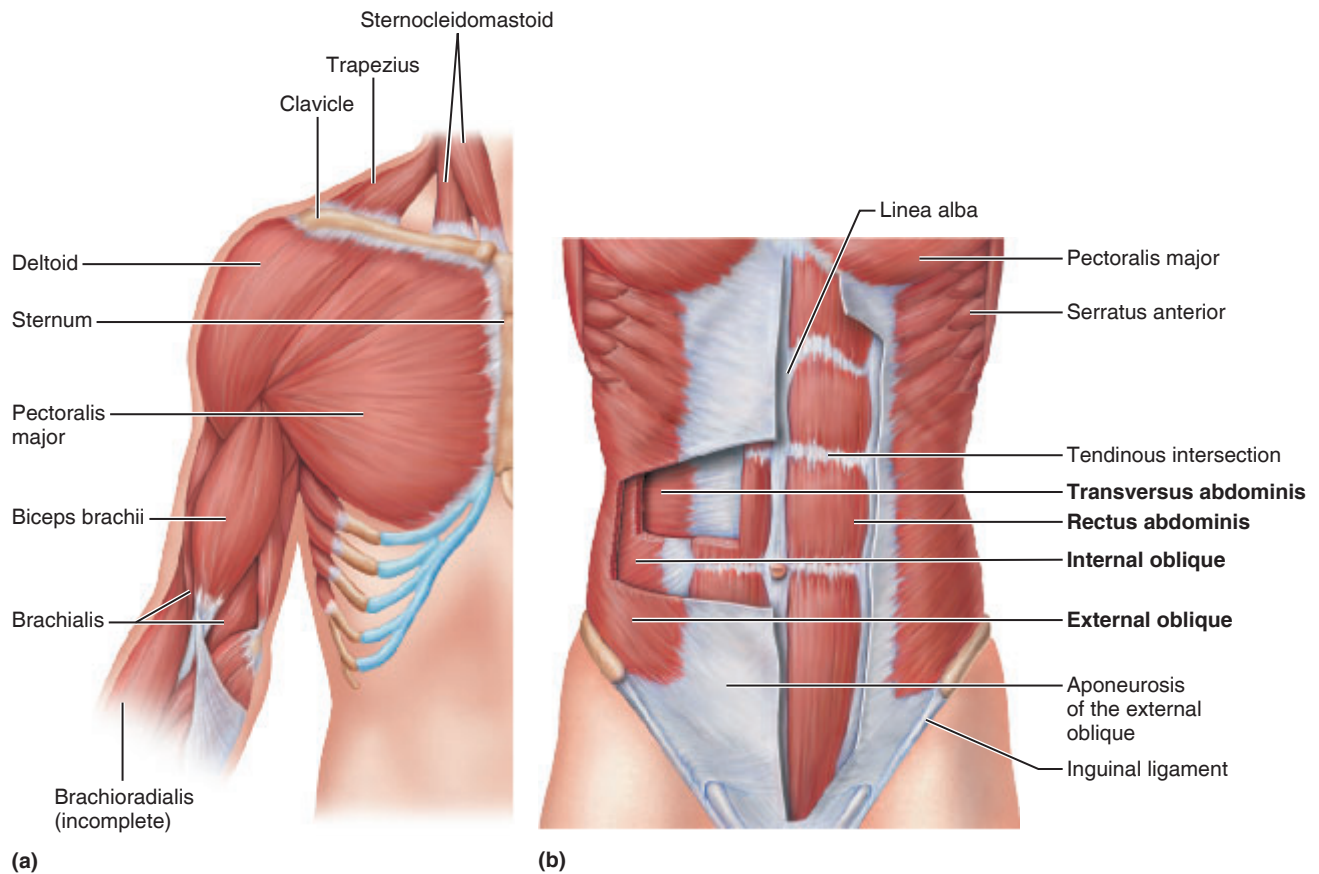


Figure 12.4 Muscles of the anterior neck, shoulder, trunk, and arm. (a) Muscles of the right thorax and arm. (b) Muscles of the abdomen. Portions of the superficial muscles of the right side of the abdomen are cut away to reveal the deeper muscles.

1. Fully abduct the arm and extend at the elbow. Now adduct the arm against resistance. You are using the *latissimus dorsi* and *pectoralis major* muscles.
2. To observe the action of the *deltoid*, abduct your arm against resistance. Now attempt to elevate your shoulder against resistance; you are contracting the upper portion of the *trapezius*.
3. The *pectoralis major* is used when you press your hands together at chest level.

Muscles of the Upper Limb

The muscles that move the upper limb fall into three groups: those that move the arm, those causing movement of the forearm, and those moving the hand and fingers.

The muscles that cross the shoulder joint to insert on the humerus and move the arm are primarily trunk muscles that originate on the axial skeleton or shoulder girdle. These muscles are included with the trunk muscles.

The second group of muscles forms the musculature of the humerus and crosses the elbow joint. They flex and extend the forearm.

The third group forms the musculature of the forearm. Most of these muscles cross the wrist to insert on the digits and produce movements of the hand and fingers. The origins, insertions, and actions of these last two groups of muscles are summarized in Tables 12.2 and 12.3 and are shown in Figures 12.1, 12.2, 12.4, and 12.5.

Table 12.3 Posterior Muscles of Human Neck, Trunk, and Upper Limb (see Figure 12.5)

Muscle	Comments	Origin	Insertion	Action
Muscles of the Neck, Shoulder, and Thorax				
Trapezius	Most superficial muscle of posterior neck and thorax; broad origin and insertion	Occipital bone and all cervical and thoracic vertebrae	Acromion and spinous process of scapula; clavicle	Extends head; retracts (adducts) scapula and stabilizes it
Latissimus dorsi	Broad flat muscle of lower back (lumbar region); extensive superficial origins	Lower three to four ribs, inferior spine, and iliac crest	Proximal humerus	Prime mover of arm extension; adducts and medially rotates arm; brings arm down in power stroke, as in striking a blow
Erector spinae	A long three-part muscle composed of iliocostalis (lateral), longissimus, and spinalis (medial) muscle columns; extends from pelvis to head	Iliac crest; lumbar, thoracic, and cervical vertebrae; and/or ribs, depending on specific part	Ribs and thoracic and cervical vertebrae	All act to extend the vertebral column; longissimus also extends the head
Deltoid	(see Table 12.2)			
Arm/Forearm Muscles				
Triceps brachii (see Figures 12.1 and 12.2)	Large fleshy muscle of posterior humerus; three-headed origin	Glenoid cavity of scapula, posterior humerus	Olecranon of ulna	Powerful forearm extensor; antagonist of biceps brachii
Extensor carpi radialis longus (see Figure 12.2)	Superficial; parallels brachioradialis on lateral forearm	Lateral humerus	Second metacarpal	Extends and abducts hand
Extensor digitorum (see Figure 12.2)	Superficial; between extensor carpi ulnaris and extensor carpi radialis	Lateral epicondyle of humerus	Distal phalanges of second through fifth fingers	Prime mover of finger extension; extends hand; can flare (adduct) fingers
Extensor carpi ulnaris (see Figure 12.2)	Superficial; medial posterior forearm	Lateral epicondyle of humerus	Fifth metacarpal	Extends and adducts hand

Activity 4

Identifying Muscles of the Upper Limb

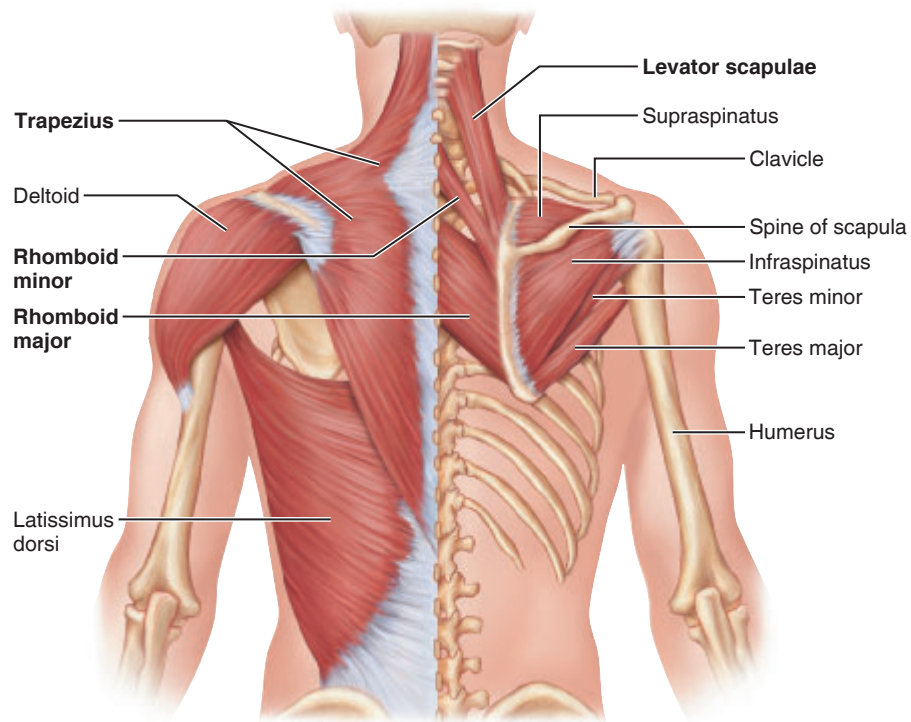
First study the tables and figures, and then see whether you can identify these muscles on a torso model or anatomical chart. Complete this portion of the exercise by palpating upper limb muscles, as outlined next. As you palpate each muscle, place a check mark in the box.

To observe the *biceps brachii* in action, attempt to flex your forearm (hand supinated) against resistance.

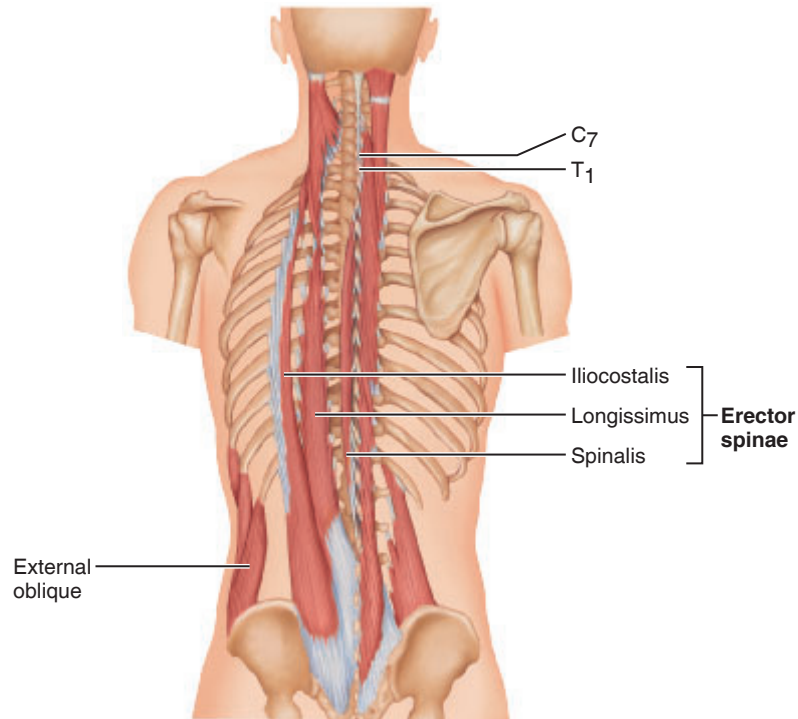
Acutely flex at the elbow and then try to extend it against resistance to demonstrate the action of your *triceps brachii*.

Strongly flex at the wrist and make a fist. Palpate your contracting wrist flexor muscles (which originate from the medial epicondyle of the humerus) and their insertion tendons, which can be easily felt at the anterior aspect of the wrist.

Flare your fingers to identify the tendons of the *extensor digitorum* muscle on the back of your hand.



(a)



(b)

Figure 12.5 Muscles of the posterior neck, trunk, and arm. (a) Superficial muscles. (b) The erector spinae muscles, deep muscles of the back.

Table 12.4 Anteromedial Muscles of the Hip and Lower Limb (see Figure 12.6)

Muscle	Comments	Origin	Insertion	Action
Origin on the Pelvis				
Iliopsoas—iliacus and psoas major	Two closely related muscles; fibers pass under inguinal ligament to insert into femur via a common tendon	Iliacus: iliac fossa; psoas major: transverse processes, bodies, and discs of T ₁₂ and lumbar vertebrae	Lesser trochanter of femur	Flex trunk at hip joint; major flexor of hip (or thigh on pelvis when pelvis is fixed)
Sartorius	Straplike superficial muscle running obliquely across anterior surface of thigh to knee	Anterior superior iliac spine	By an aponeurosis into medial aspect of proximal tibia	Flexes and laterally rotates thigh; flexes leg; known as “tailor’s muscle” because it helps bring about cross-legged position in which tailors are often depicted
Thigh				
Adductors (magnus, longus, and brevis)	Large muscle mass forming medial aspect of thigh; arise from front of pelvis and insert at various levels on femur	Magnus: ischial and pubic rami; longus: pubis near pubic symphysis; brevis: body and inferior ramus of pubis	Magnus: linea aspera and adductor tubercle of femur; longus and brevis: linea aspera	Adduct and laterally rotate and flex thigh; posterior part of magnus is also a synergist of the hamstrings in thigh extension
Quadriceps				
• Rectus femoris	Superficial muscle of thigh; runs straight down thigh; only muscle of group to cross hip joint	Pelvis	Tibial tuberosity via patellar ligament	Extends leg and flexes thigh
• Vastus lateralis	Forms lateral aspect of thigh	Greater trochanter of femur	Tibial tuberosity	Extends leg
• Vastus medialis	Forms medial aspect of thigh	Femur	Tibial tuberosity	Extends leg
• Vastus intermedius	Obscured by rectus femoris; lies between vastus lateralis and vastus medialis	Femur (not shown in figure)	Tibial tuberosity	Extends leg
Leg				
Tibialis anterior	Superficial muscle of anterior leg; parallels sharp anterior margin of tibia	Lateral condyle and upper two-thirds of tibia; interosseous membrane	By tendon into inferior surface of first cuneiform and metatarsal I	Prime mover of dorsiflexion; inverts foot
Extensor digitorum longus	Lateral to tibialis anterior	Lateral condyle of tibia; proximal fibula; interosseous membrane	By tendons (4) into middle and distal phalanges of toes II–V	Prime mover of toe extension; dorsiflexes foot
Fibularis (peroneus) longus	Superficial lateral muscle; overlies fibula	Upper portion of fibula	By long tendon under foot to first metatarsal	Plantar flexes and everts foot; helps keep foot flat on ground

Muscles of the Hip and Lower Limb

Muscles that move the lower limb cause movement at the hip, knee, and ankle joints. Muscles acting on the thigh (femur) cause various movements at the multiaxial hip joint (flexion, extension, rotation, abduction, and adduction). These include the iliopsoas, the adductors, and various other muscles.

Muscles acting on the leg form the musculature of the thigh. (Anatomically the term *leg* refers only to that portion between the knee and the ankle.) The thigh muscles cross the knee to allow flexion and extension of the leg. They include the hamstrings and the quadriceps. Some of these muscles also attach on the pelvic girdle, so they can cause movement at the hip joint.

Muscles originating on the leg act on the foot and toes. These lower limb muscles are described in **Table 12.4** and **Table 12.5** and are shown in **Figure 12.6** and **Figure 12.7**.

Activity 5

Identifying Muscles of the Hip and Lower Limb

Identify the muscles that move the thigh, leg, foot, and toes as instructed previously.

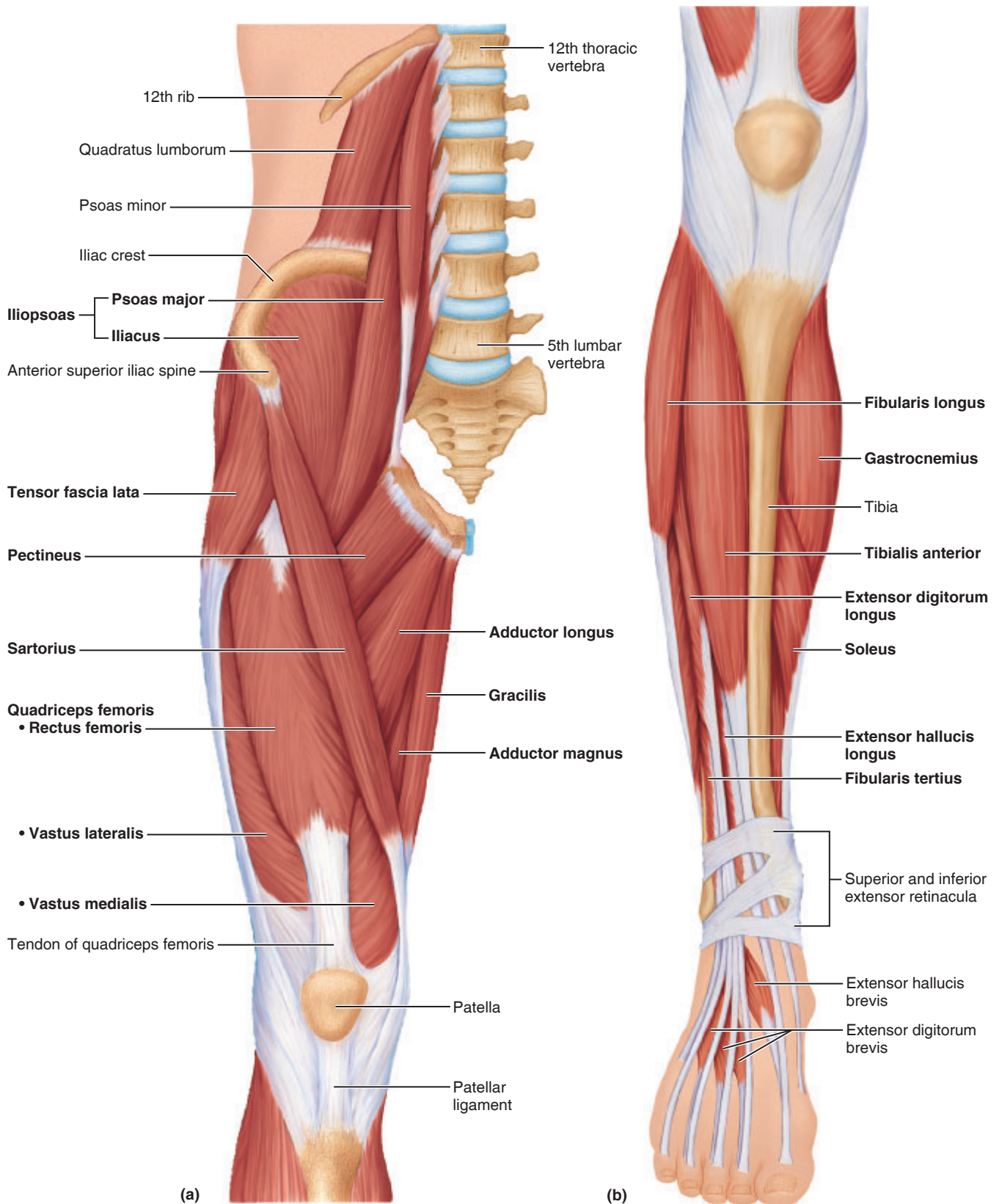


Figure 12.6 Pelvic, thigh, and leg muscles of the right side of the body, anterior view. (a) Pelvic and thigh muscles. (b) Leg muscles.

Table 12.5 Muscles of the Hip and Lower Limb, Posterior Aspect (see Figure 12.7)

Muscle	Comments	Origin	Insertion	Action
Origin on the Pelvis				
Gluteus maximus	Largest and most superficial of gluteal muscles (which form buttock mass)	Ilium, sacrum, and coccyx	Gluteal tuberosity of femur; iliotibial tract	Powerful hip extensor (most effective when thigh is flexed, as in climbing stairs—but not as in walking)
Gluteus medius	Partially covered by gluteus maximus	Lateral surface of ilium	Greater trochanter of femur	Abducts and medially rotates thigh; steadies pelvis during walking
Thigh				
Hamstrings*				
• Biceps femoris	Most lateral muscle of group; arises from two heads	Ischial tuberosity and distal femur	Tendon passes laterally to insert into head of fibula	Extends thigh; laterally flexes leg
• Semitendinosus	Medial to biceps femoris	Ischial tuberosity	Proximal tibia	Extends thigh; flexes leg; medially rotates leg
• Semimembranosus	Deep to semitendinosus	Ischial tuberosity	Proximal tibia	Extends thigh; flexes leg; medially rotates leg
Leg				
Gastrocnemius	Superficial muscle with two prominent bellies	By two heads from medial and lateral condyles of the femur	Calcaneus via calcaneal tendon	Plantar flexes foot; crosses knee joint; flexes knee when foot is dorsiflexed
Soleus	Deep to gastrocnemius	Proximal tibia and fibula	Calcaneus via calcaneal tendon	Plantar flexes foot

*The hamstrings are the fleshy muscles of the posterior thigh. As a group, they are strong extensors of the thigh; they counteract the powerful quadriceps by stabilizing the knee joint when standing.

Activity 6

Palpating Muscles of the Hip and Lower Limb

Complete this exercise by performing the following palpation demonstrations with your lab partner. As you complete each demonstration, place a check mark in the appropriate box.

- Go into a deep knee bend, and palpate your own *gluteus maximus* muscle as you extend at the hip to return to the upright posture.
- Demonstrate the contraction of the anterior *quadriceps femoris* by trying to extend your leg against resistance. Do this while seated, and notice how the patellar ligament reacts. The hamstrings of the posterior thigh come into play when you flex your leg against resistance.
- Now stand on your toes. Have your partner palpate the lateral and medial heads of the *gastrocnemius* and follow it to its insertion in the calcaneal tendon.
- Dorsiflex and invert your foot while palpating your *tibialis anterior* muscle (which parallels the sharp anterior crest of the tibia laterally).

Activity 7

Making a Muscle Painting

1. Choose a male student to be “muscle painted.”
2. Obtain brushes and water-based paints from the supply area while the “volunteer” removes his shirt and rolls up his pant legs (if necessary).
3. Using paints of different colors, identify the muscles listed below by painting his skin. If a muscle covers a large body area, you can opt to paint only its borders.
 - Biceps brachii
 - Deltoid
 - Erector spinae
 - Pectoralis major
 - Rectus femoris
 - Tibialis anterior
 - Triceps brachii
 - Vastus lateralis
 - Biceps femoris
 - Extensor carpi radialis longus
 - Latissimus dorsi
 - Rectus abdominis
 - Sternocleidomastoid
 - Trapezius
 - Gastrocnemius
 - Vastus medialis
4. Check your “human painting” with your instructor before cleaning your bench and leaving the laboratory.

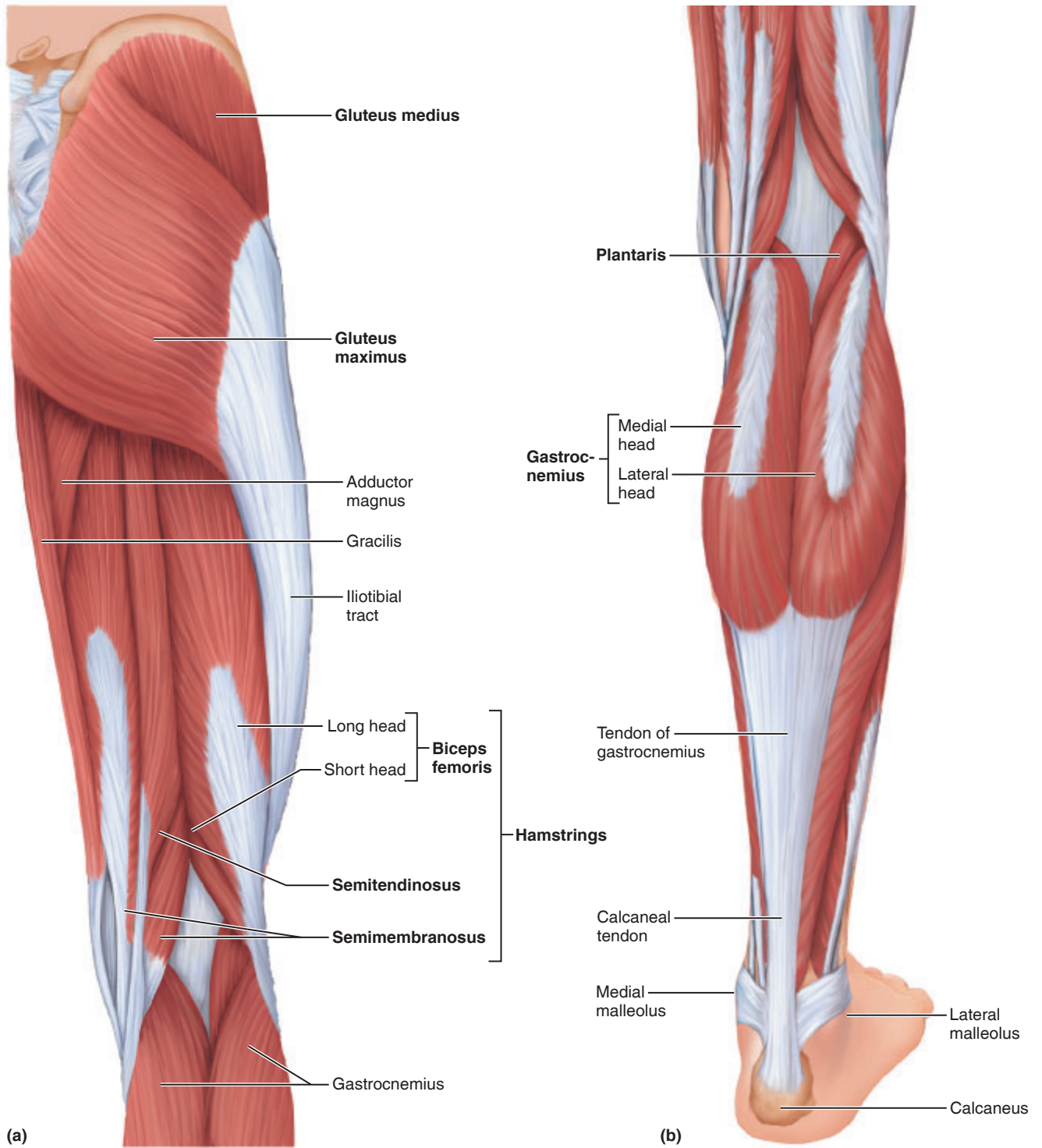


Figure 12.7 Muscles of the (a) hip and thigh, and (b) leg, posterior aspect.

This page intentionally left blank

REVIEW SHEET

Gross Anatomy of the Muscular System

Name _____ Lab Time/Date _____

Muscles of the Head and Neck

1. Using choices from the list at the left, correctly identify the muscles provided with leader lines on the diagram.

buccinator

frontal belly of epicranii

masseter

occipital belly of epicranii

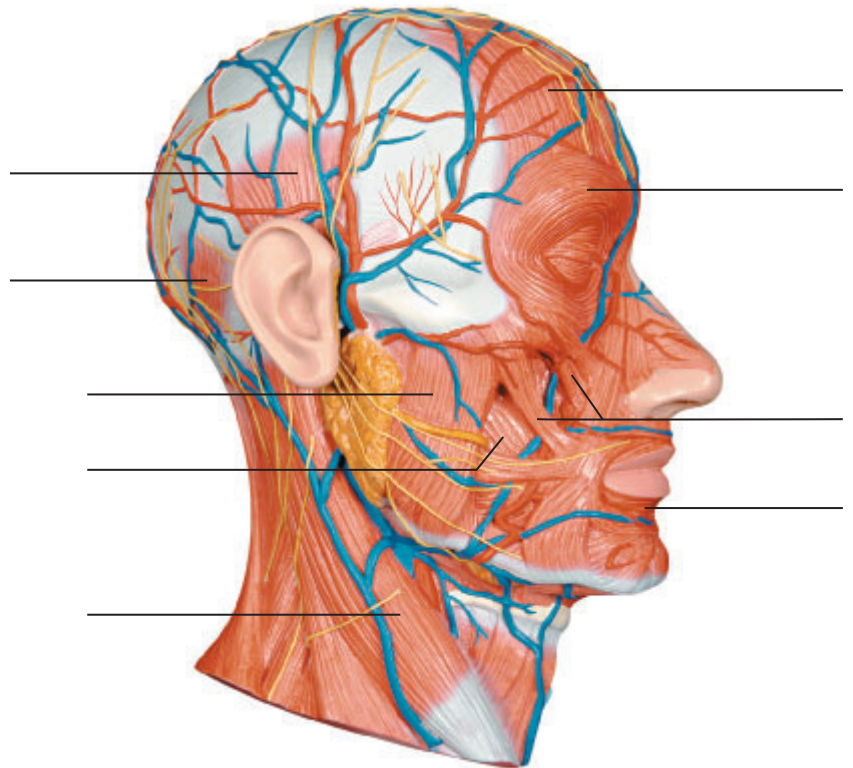
orbicularis oculi

orbicularis oris

sternocleidomastoid

temporalis

zygomaticus



2. Using the terms provided above, identify the muscles described next.

_____ 1. used to smile

_____ 2. used to suck in your cheeks

_____ 3. used in blinking and squinting

_____ 4. pulls the scalp posteriorly

_____ 5. raises your eyebrows for a questioning expression

_____ 6. your kissing muscle

_____ 7. allows you to "bite" that carrot stick

_____ 8. used to turn and tilt the head toward the shoulder

Muscles of the Trunk and Upper Limb

3. Using choices from the key, identify the major muscles described next. Some choices may be used more than once.

Key: a. biceps brachii f. flexor digitorum superficialis k. internal oblique
 b. deltoid g. external intercostals l. latissimus dorsi
 c. erector spinae h. external oblique m. pectoralis major
 d. extensor carpi ulnaris i. flexor carpi radialis n. rectus abdominis
 e. transversus abdominis j. trapezius o. triceps brachii

- _____ 1. a major spine flexor
- _____ 2. prime mover for pulling the arm posteriorly
- _____ 3. forearm extender
- _____, _____ 4. help form the abdominal girdle (four pairs of muscles)
- _____ 5. flexes and abducts hand
- _____ 6. prime mover of arm abduction
- _____, _____ 7. adductors of the arm (two muscles)
- _____ 8. flexes and supinates the forearm
- _____ 9. small muscles between the ribs; elevate the ribs during breathing
- _____ 10. extends the head
- _____ 11. extends the spine
- _____ 12. extends and adducts the wrist
- _____ 13. flexes the hand and middle phalanges

Muscles of the Lower Limb

4. Use the key terms to respond to the descriptions below.

Key: a. adductor group d. fibularis longus g. semitendinosus
 b. gastrocnemius e. rectus femoris h. tibialis anterior
 c. gluteus maximus f. semimembranosus

- _____ 1. lateral compartment muscle that plantar flexes and everts the foot
- _____ 2. forms the buttock
- _____ 3. posterior muscle that performs plantar flexion
- _____ 4. a prime mover of dorsiflexion
- _____ 5. allow you to grip a horse's back with your thighs
- _____, _____ 6. muscles that originate on the ischial tuberosity (two muscles)
- _____ 7. muscle that extends leg and flexes thigh

General Review: Muscle Description

5. Identify the muscles described below by completing the statements:

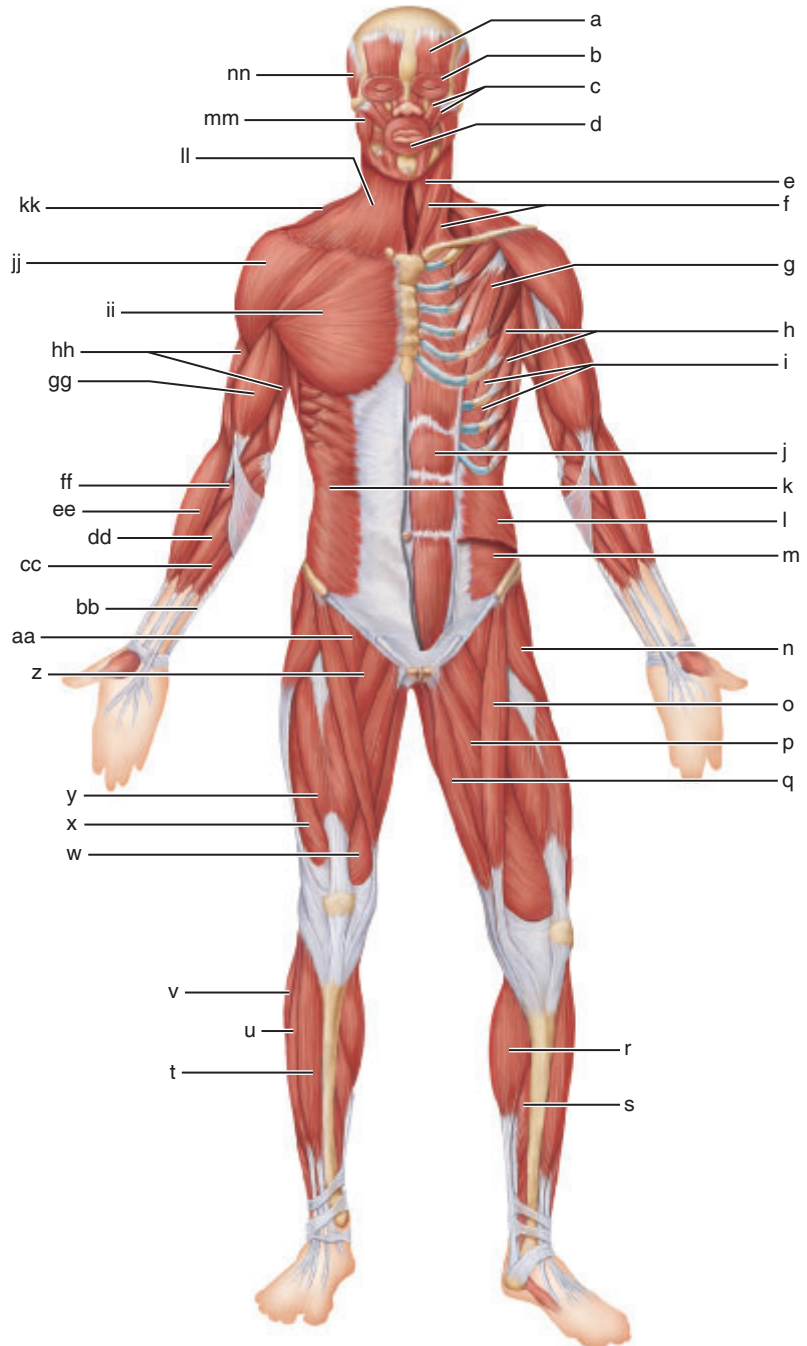
1. _____, _____, _____, and _____
 are commonly used for intramuscular injections (four muscles).
2. The insertion of the _____ group contains a large sesamoid bone, the patella.
3. The gastrocnemius and soleus insert in common into the _____ tendon.
4. The bulk of the tissue of a muscle tends to lie _____ to the part of the body it causes to move.
5. The extrinsic muscles of the hand originate on the _____.
6. Most flexor muscles are on the _____ aspect of the body;
 most extensors are located _____. An exception to this generalization is the
 extensor-flexor musculature of the _____.

General Review: Muscle Recognition

6. Identify each lettered muscle in the illustration of the human anterior superficial musculature by matching its letter with one of the following muscle names:

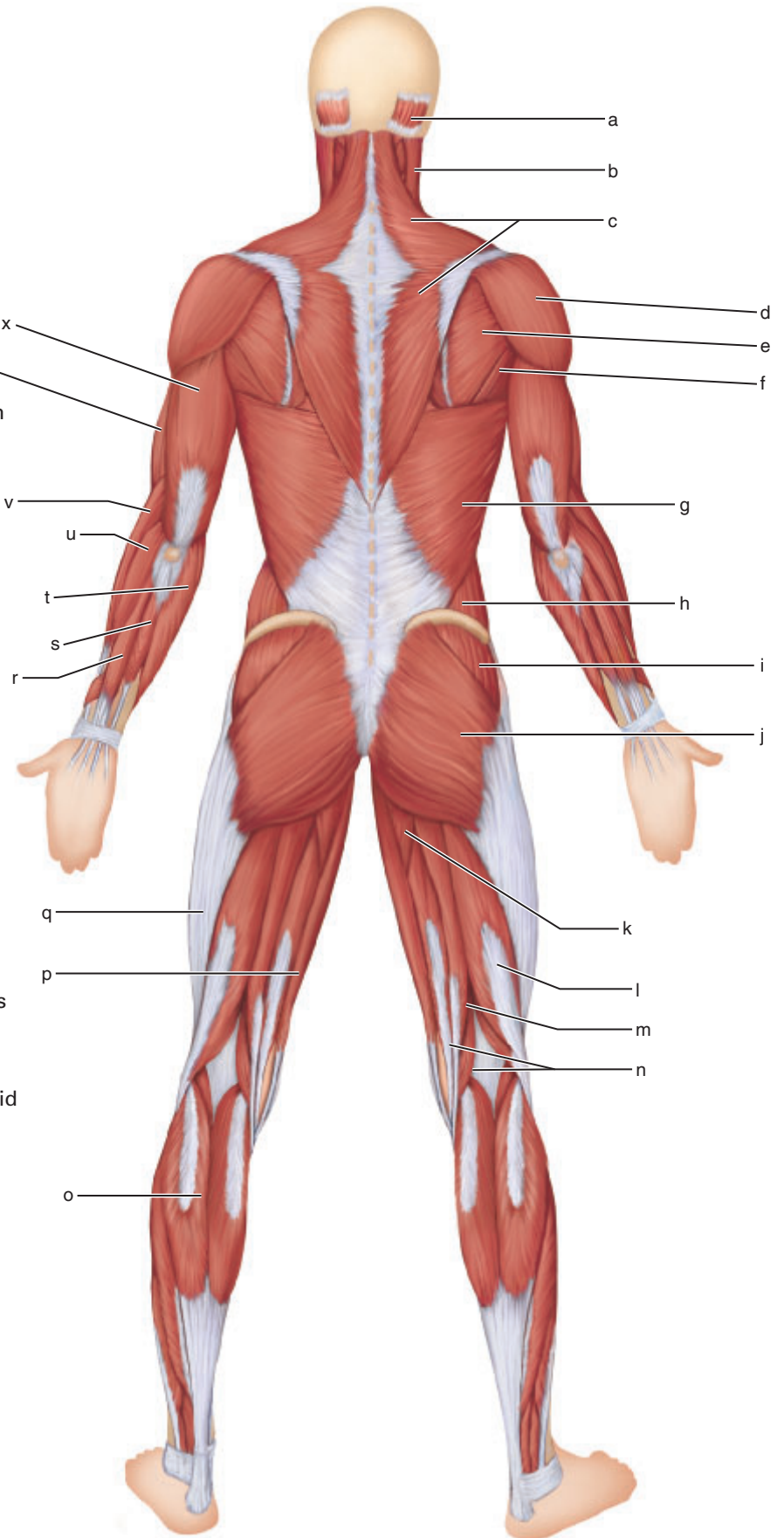
- _____ 1. adductor longus
- _____ 2. biceps brachii
- _____ 3. brachioradialis
- _____ 4. deltoid
- _____ 5. extensor digitorum longus
- _____ 6. external oblique
- _____ 7. fibularis longus
- _____ 8. flexor carpi radialis
- _____ 9. flexor carpi ulnaris
- _____ 10. frontal belly of epicranius
- _____ 11. gastrocnemius
- _____ 12. gracilis
- _____ 13. iliopsoas
- _____ 14. intercostals
- _____ 15. internal oblique
- _____ 16. masseter
- _____ 17. orbicularis oculi
- _____ 18. orbicularis oris
- _____ 19. palmaris longus
- _____ 20. pectineus
- _____ 21. pectoralis major
- _____ 22. pectoralis minor
- _____ 23. platysma
- _____ 24. pronator teres
- _____ 25. rectus abdominis
- _____ 26. rectus femoris
- _____ 27. sartorius
- _____ 28. serratus anterior
- _____ 29. soleus
- _____ 30. sternocleidomastoid
- _____ 31. sternohyoid
- _____ 32. temporalis
- _____ 33. tensor fascia lata
- _____ 34. tibialis anterior


- _____ 35. transversus abdominis
- _____ 36. trapezius
- _____ 37. triceps brachii
- _____ 38. vastus lateralis
- _____ 39. vastus medialis
- _____ 40. zygomaticus




7. Identify each lettered muscle in this illustration of the human posterior superficial musculature by matching its letter with one of the following muscle names:

- _____ 1. adductor magnus
- _____ 2. biceps femoris
- _____ 3. brachialis
- _____ 4. brachioradialis
- _____ 5. deltoid
- _____ 6. extensor carpi radialis longus
- _____ 7. extensor carpi ulnaris
- _____ 8. extensor digitorum
- _____ 9. external oblique
- _____ 10. flexor carpi ulnaris
- _____ 11. gastrocnemius
- _____ 12. gluteus maximus
- _____ 13. gluteus medius
- _____ 14. gracilis
- _____ 15. iliotibial tract (tendon)
- _____ 16. infraspinatus
- _____ 17. latissimus dorsi
- _____ 18. occipital belly of epicranii
- _____ 19. semimembranosus
- _____ 20. semitendinosus
- _____ 21. sternocleidomastoid
- _____ 22. teres major
- _____ 23. trapezius
- _____ 24. triceps brachii



8.  Bruxism is a condition in which individuals clench and/or grind their teeth. It often occurs as they sleep, leading to jaw pain and damaged teeth. Which muscles contract during this nocturnal event? _____

9.  Repetitive extension of the hand at the wrist and abduction of the hand can lead to lateral epicondylitis. Although sometimes called "tennis elbow," it more often affects individuals who don't play tennis. Based on the name *lateral epicondylitis* and the action described above, which muscle would most likely have microscopic tears in the tendon? _____

Neuron Anatomy and Physiology

Materials

- Model of a “typical” neuron (if available)
- Demonstration area: Microscopes set up with the following prepared slides for student examination:
 - Station 1:* Ox spinal cord smear (under oil)
 - Station 2:* Teased myelinated nerve fibers
 - Station 3:* Nerve (cross section)

Learning Outcomes

- Discuss the functional differences between neurons and neuroglia.
- Identify the important anatomical characteristics of a neuron.
- Explain how a nerve impulse is transmitted from one neuron to another.
- Describe the functional importance of myelin sheaths, and explain how those sheaths are formed by Schwann cells.
- Classify neurons according to structure and function.
- Describe briefly how a nerve impulse is generated.
- Describe the structure of a nerve, identifying the connective tissue coverings.

The nervous system is the master integrating and coordinating system of the body. Every thought, action, and sensation is a reflection of its activity.

Despite its complexity, nervous tissue is made up of just two principal cell populations: **neurons** and supporting cells called **neuroglia** or **glial cells**. The neuroglia in the central nervous system (CNS: brain and spinal cord) include several cell types that serve the needs of the neurons by acting as phagocytes and by protecting and myelinating the delicate neurons. In addition, CNS neuroglia act as a selective barrier between the capillary blood supply and the neurons. The most important neuroglia in the peripheral nervous system (PNS: the neural structures outside the CNS) are *Schwann cells*, which insulate nerve fibers, and **satellite cells**, which surround neuron cell bodies. In this exercise, we focus on neurons, which are highly excitable.

Neuron Anatomy

Neurons are specialized to transmit messages (nerve impulses) from one part of the body to another. Neurons differ structurally, but they have many features in common (**Figure 13.1a**). All have a **cell body** from which slender processes, or fibers, extend. Neuron cell bodies found in the CNS in clusters are called **nuclei**. In the PNS, clusters of neuron cell bodies are called **ganglia**. Nuclei and ganglia make up the gray matter of the nervous system. Neuron processes running through the CNS form tracts of white matter. In the PNS, they form the peripheral nerves.

The neuron cell body contains a large round nucleus surrounded by cytoplasm. The cytoplasm is filled with *neurofibrils*, cytoskeletal elements of the neuron, which have a support and intracellular transport function, and an elaborate rough endoplasmic reticulum called the **chromatophilic substance** or *Nissl bodies*.

Generally speaking, neuron processes that conduct electrical currents *toward* the cell body are called **dendrites**, and those that carry impulses *away from* the nerve cell body are called **axons** or **nerve fibers**. Neurons have only one axon but may have many dendrites, depending on the neuron type. The axon may branch, forming one or more processes called **axon collaterals**.

A neuron is excited by other neurons when their axons release neurotransmitters close to its dendrites or cell body, and an electrical current produced travels down its axon. The axon ends in many small structures called **axon terminals**,

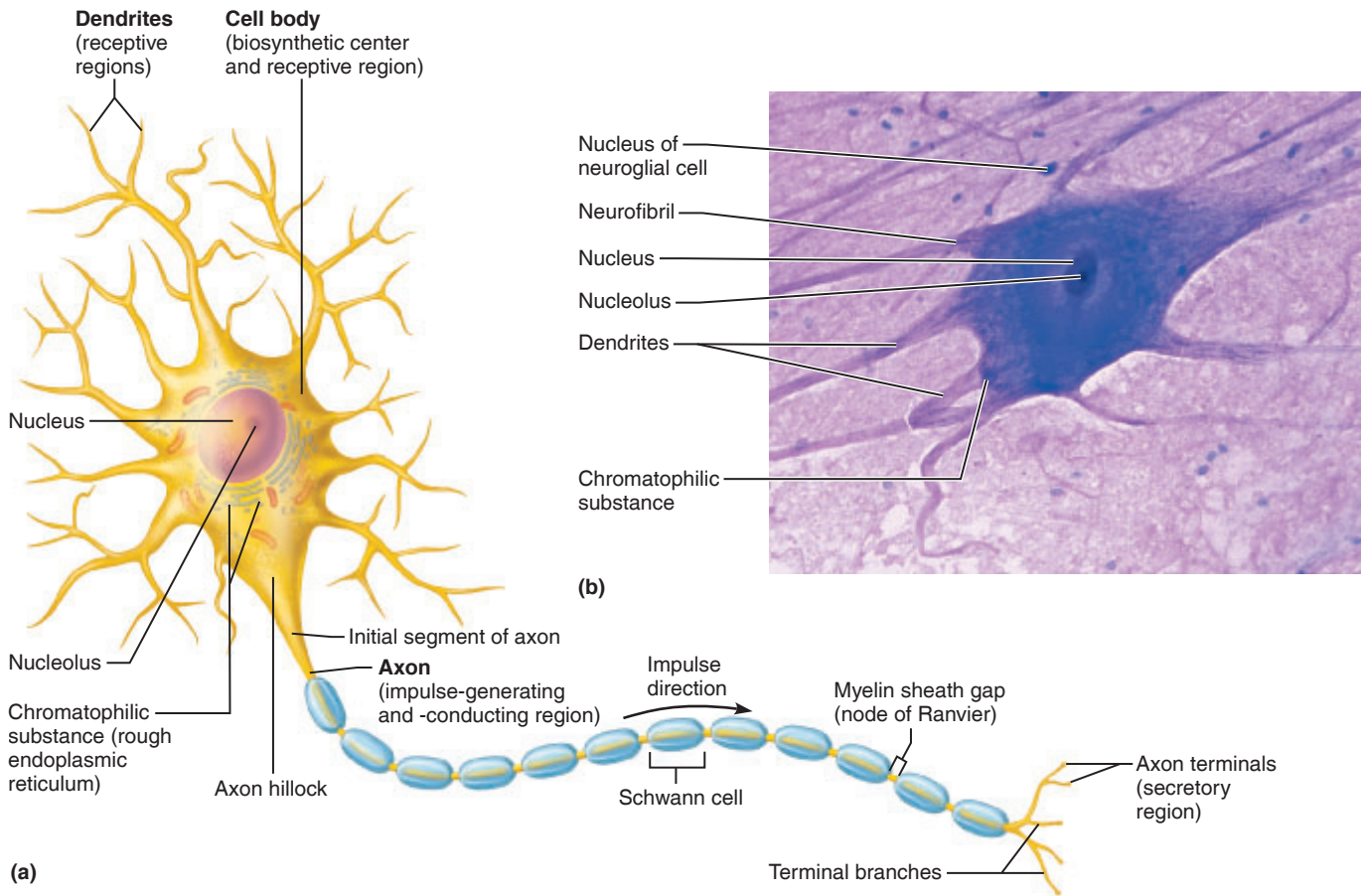


Figure 13.1 Structure of a typical motor neuron. (a) Diagram. (b) Photomicrograph (450 \times). (See also Plate 5 in the Histology Atlas.)

which store the neurotransmitter chemical in tiny vesicles (see Figure 13.1a). Each axon terminal is separated from the cell body or dendrites of the next neuron by a tiny gap called the **synaptic cleft**. Thus, although they are close, there is no actual physical contact between neurons. When an impulse reaches the axon terminals, some of the synaptic vesicles fuse with the plasma membrane and then rupture and release neurotransmitter into the synaptic cleft. The neurotransmitter then diffuses across the synaptic cleft to bind to membrane receptors on the next neuron, initiating the action potential.

Most long nerve fibers are covered with a fatty material called **myelin**, and such fibers are referred to as **myelinated fibers**. Nerve fibers in the peripheral nervous system are myelinated by special neuroglia called **Schwann cells**, which

wrap themselves tightly around the axon in jelly-roll fashion so that when the process is completed a tight core of plasma membrane material called the **myelin sheath** encompasses the axon (Figure 13.2). The Schwann cell nucleus and the bulk of its cytoplasm end up just beneath the outermost portion of its plasma membrane. This part of the Schwann cell external to the myelin sheath is referred to as the **outer collar of the perinuclear cytoplasm**. Because the myelin sheath is formed by many individual Schwann cells, it has gaps or indentations called **myelin sheath gaps**, or **nodes of Ranvier** (see Figure 13.1a). Within the CNS, myelination is accomplished by neuroglia called **oligodendrocytes**. Myelin insulates the fibers and greatly increases the speed of neurotransmission by neuron fibers.

Activity 1

Identifying Parts of a Neuron


1. Study the illustration of a motor neuron shown in Figure 13.1, noting the structural details described, and then identify these structures on a neuron model.

2. Go to station 1 of the demonstration area where the microscopes are set up, and view a prepared slide of the ox spinal cord smear, which has large, easily identifiable neurons. Study one representative neuron and identify the cell body, the nucleus and the large, prominent nucleolus. If possible, distinguish the axon from the many dendrites. Sketch the neuron in the space that follows, and label the important anatomical details you observe. Compare your sketch to Figure 13.1b and Plate 5 in the Histology Atlas. Also, as you study the photomicrograph of the neuron (Plate 5 in the Histology Atlas) reexamine the diagram (Figure 13.1a), which differentiates the neuronal processes more clearly.

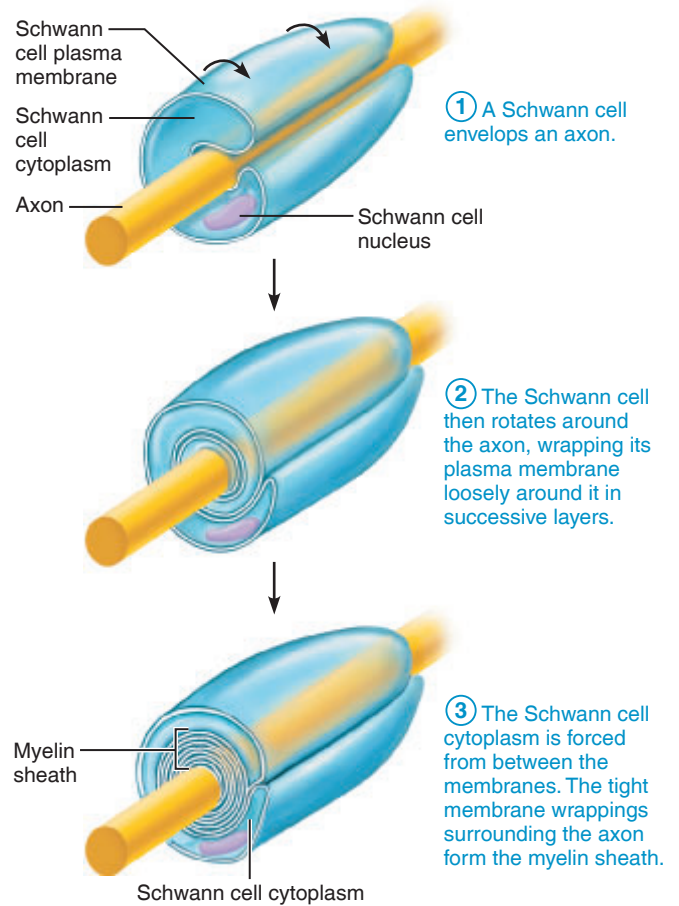


3. At station 2, view a prepared slide of teased myelinated nerve fibers. Identify the following: myelin sheath gaps, outer collar of perinuclear cytoplasm, the axon, Schwann cell nuclei, and myelin sheath (use Figures 13.1 and 13.2 and Plate 8 in the Histology Atlas as guides).

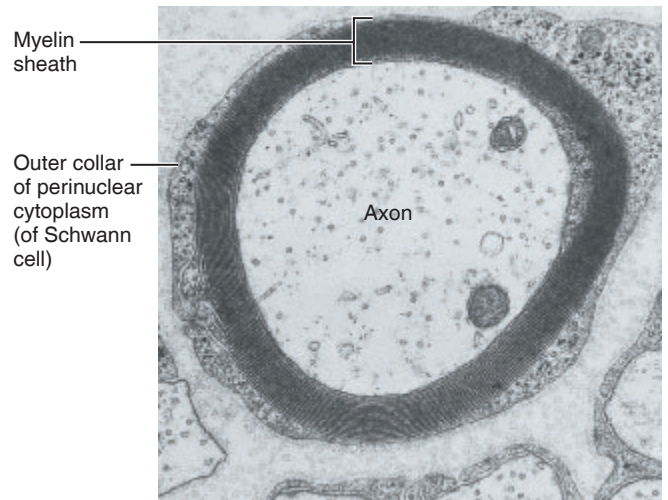
Sketch a portion of a myelinated nerve fiber in the space below, illustrating two or three myelin sheath gaps. Label the axon, myelin sheath, myelin sheath gap, and Schwann cell nucleus.



Do the gaps seem to occur at consistent intervals, or are they distributed irregularly?



(a) Myelination of a nerve fiber (axon)



(b) Cross-sectional view of a myelinated axon (electron micrograph 24,000x)

Figure 13.2 Myelination of a nerve fiber (axon) by Schwann cells.

Neuron Classification

Neurons may be classified on the basis of structure or of function.

Classification by Structure

The number of processes attached to the cell body determines the structural class of a neuron (**Figure 13.3**). In **unipolar neurons**, one very short process, which divides into *peripheral* and *central processes*, extends from the cell body. Functionally, only the most distal portions of the peripheral process act as receptive regions; the rest acts as an axon along with the central process. Unipolar neurons are more accurately called **pseudounipolar neurons** because they are derived from bipolar neurons. Nearly all neurons that conduct impulses toward the CNS are unipolar.

Bipolar neurons have two processes—one axon and one dendrite—attached to the cell body. This neuron type is quite rare; typically bipolar neurons serve as sensory receptor cells in some special sense organs (e.g., eye, ear).

Many processes issue from the cell body of **multipolar neurons**, and all are dendrites except for a single axon.

Most neurons in the brain and spinal cord and those whose axons carry impulses away from the CNS fall into this last category.

Classification by Function

Neurons carrying impulses from the sensory receptors in the internal organs or in the skin are called **sensory**, or **afferent, neurons** (**Figure 13.4**). The dendritic endings of sensory neurons often bear specialized receptors that are stimulated by specific changes in their immediate environment. The cell bodies of sensory neurons are always found in a ganglion outside the CNS, and these neurons are typically unipolar.

Neurons carrying impulses from the CNS to the viscera and/or body muscles and glands are **motor**, or **efferent, neurons**. Motor neurons are most often multipolar, and their cell bodies are almost always located in the CNS.

The third functional category of neurons is the **interneurons**, which are situated in pathways that connect sensory and motor neurons. Their cell bodies are always located within the CNS, and they are multipolar.

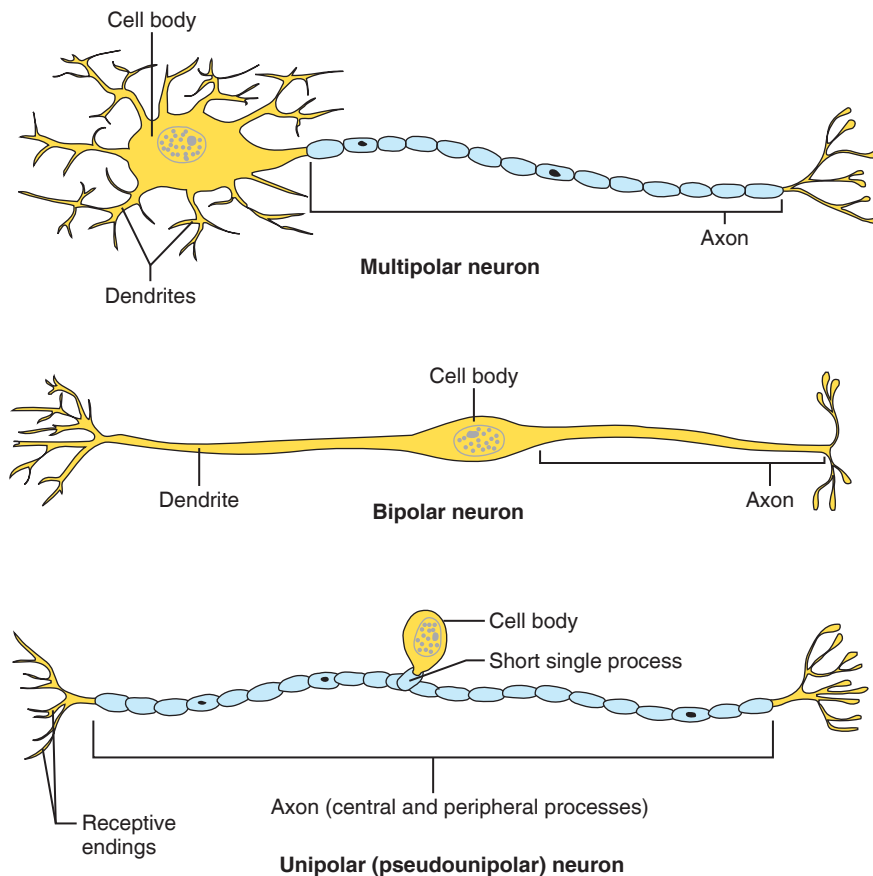


Figure 13.3 Classification of neurons based on structure (number of processes extending from the cell body). (See also Plates 6 and 7 in the Histology Atlas.)

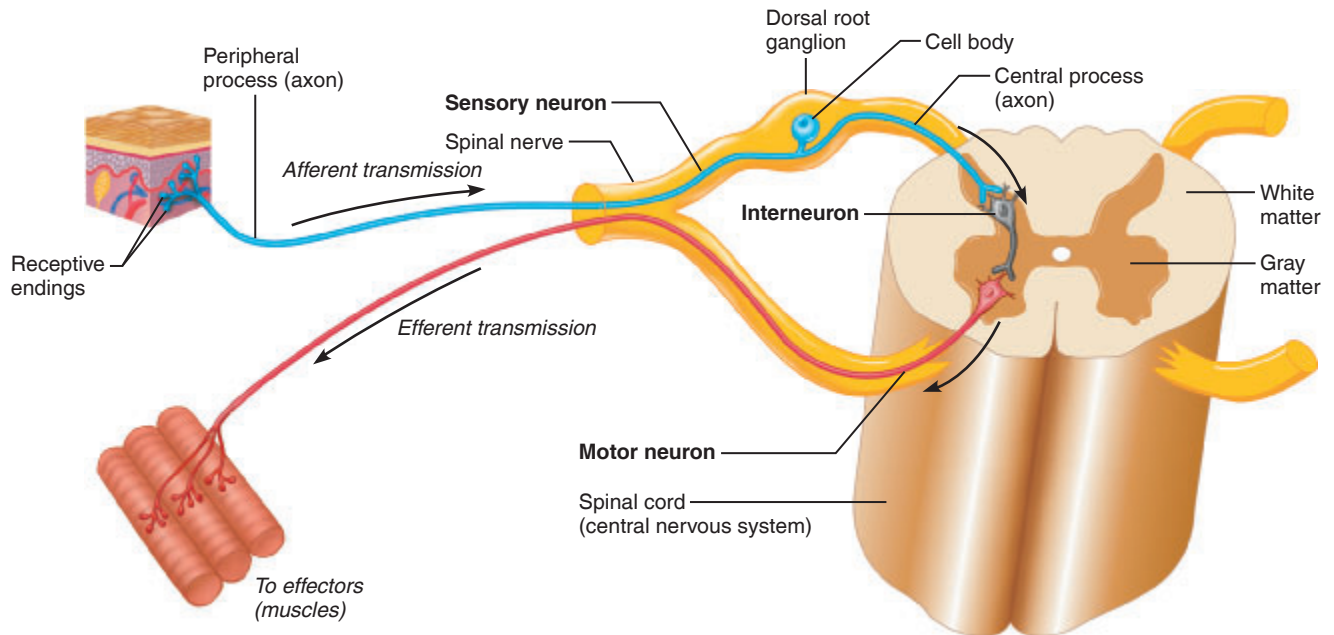


Figure 13.4 Classification of neurons on the basis of function. Sensory (afferent) neurons conduct impulses from the body's sensory receptors to the central nervous system; most are unipolar neurons with their cell bodies in ganglia in the peripheral nervous system (PNS). Motor (efferent) neurons transmit impulses from the CNS to effectors such as muscles and glands. Interneurons complete the communication line between sensory and motor neurons. They are typically multipolar, and their cell bodies reside in the CNS.

Neuron Physiology: The Action Potential

Neurons have two major physiological properties: (1) the ability to respond to stimuli and convert them into nerve impulses, and (2) the ability to transmit the impulses to other neurons, muscles, or glands. In a resting neuron, the outside surface of the membrane is slightly more positively charged than the inside surface (**Figure 13.5a**). This difference in electrical charge on the two sides of the membrane is called the **resting membrane potential**, and a neuron in this state is said to be **polarized**. In a resting neuron, the main intracellular cation is potassium (K^+); sodium ions (Na^+) are found in greater concentration in the extracellular fluids. The resting potential is maintained by the sodium-potassium pump, which transports Na^+ out of the cell and K^+ into the cell.

When the neuron is activated by a threshold stimulus, the membrane briefly becomes more permeable to sodium (sodium gates are opened), and sodium ions rush into the cell (**Figure 13.5b**). Thus the inside of the membrane becomes less negative, an event called **depolarization**. If the stimulus is great enough to depolarize the axon to **threshold**, an **action potential** is generated. (**Figure 13.5c**).

Within a millisecond after the inward rush of sodium, the membrane permeability again changes. As a result,

Na^+ permeability decreases, K^+ permeability increases, and K^+ rushes out of the cell. Since K^+ ions are positively charged, their movement out of the cell reverses the membrane potential again, so that the external membrane surface is again positive relative to the internal membrane face (**Figure 13.5d**). This event is called **repolarization**. The action potential is a brief reversal of the neuron's membrane potential.

Once generated, the action potential propagates along the entire length of the axon. It is never partially transmitted; that is, it is an all-or-none response. When the action potential reaches the axon terminals, they release a neurotransmitter that acts either to stimulate or to inhibit the next neuron in the transmission chain. This action potential begins in the axon hillock region (see **Figure 13.1**) and travels sequentially down the axon.

Because only tiny amounts of sodium and potassium ions change places, once repolarization has been completed the neuron can quickly respond again to a stimulus. Eventually, however, the original ionic concentrations must be restored on the two sides of the membrane. This is accomplished by enhanced activity of the Na^+-K^+ pump (**Figure 13.5e**).

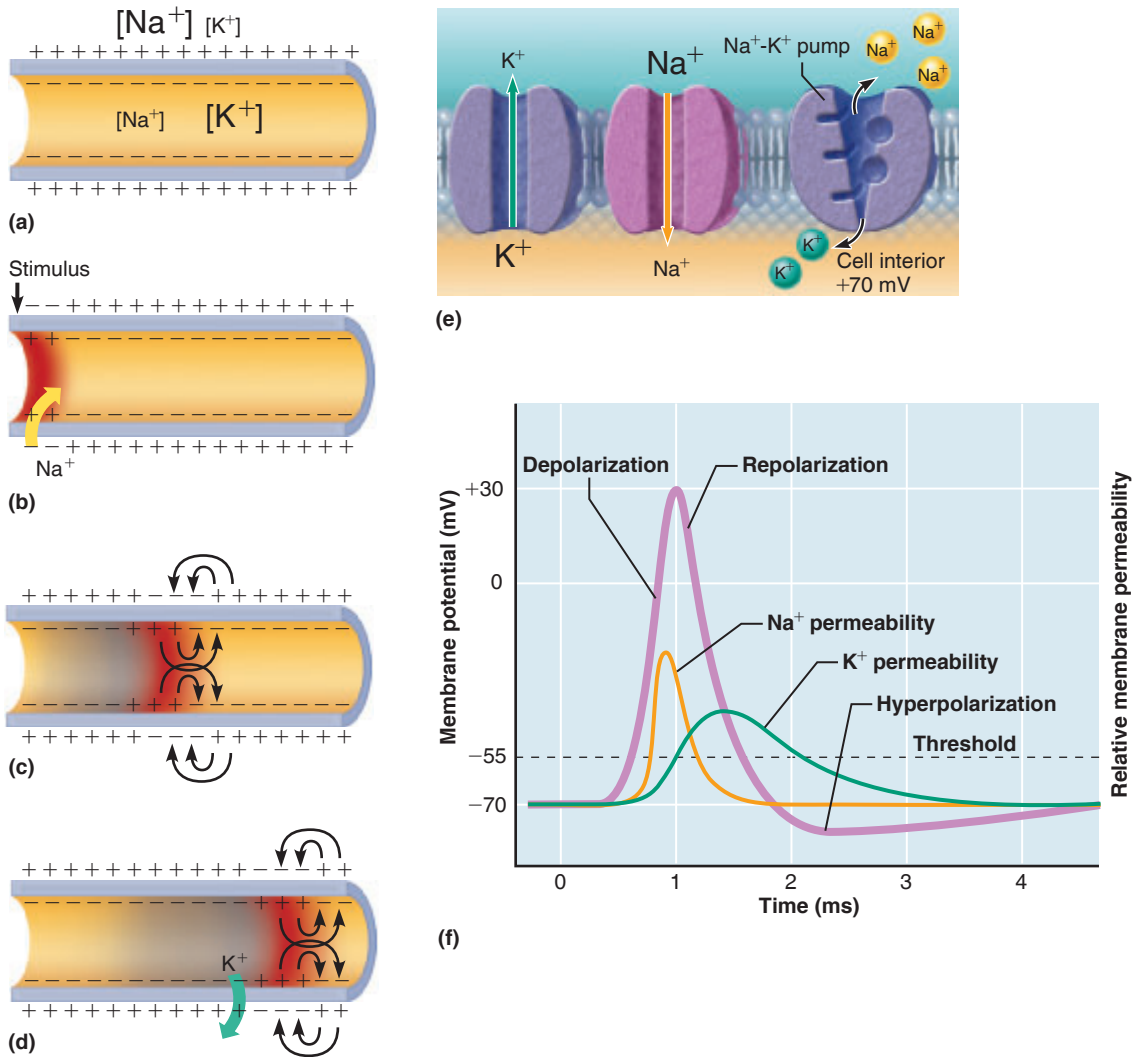


Figure 13.5 The action potential. (a) Resting membrane potential (RMP). There is an excess of positive ions outside the cell, with Na^+ as the main extracellular fluid ion and K^+ as the predominant intracellular ion. The plasma membrane has a low permeability to Na^+ . (b) Depolarization—reversal of the RMP. Application of a stimulus changes the membrane permeability, and Na^+ ions are allowed to diffuse rapidly into the cell. The interior face of the membrane becomes less negative (moves toward positive). (c) Generation of the action potential. If the stimulus is strong enough, the depolarization wave spreads rapidly along the entire length of the membrane. (d) Repolarization—reestablishment of the RMP. The negative charge on the internal plasma membrane surface and the positive charge on its external surface are reestablished by diffusion of K^+ ions out of the cell, proceeding in the same direction as in depolarization. (e) The original ionic concentrations of the resting state are restored by the Na^+-K^+ pump. (f) A tracing of an action potential. The purple line shows the changes to the membrane potential over time. The yellow and green lines show the changes to the permeability of Na^+ and K^+ , respectively, over time.

Structure of a Nerve

In the CNS, bundles of axons are called **tracts**. In the PNS, bundles of axons are called **nerves**. Nerves extend to and/or from the CNS and visceral organs or structures of the body periphery, such as skeletal muscles, glands, and skin (**Figure 13.6**).

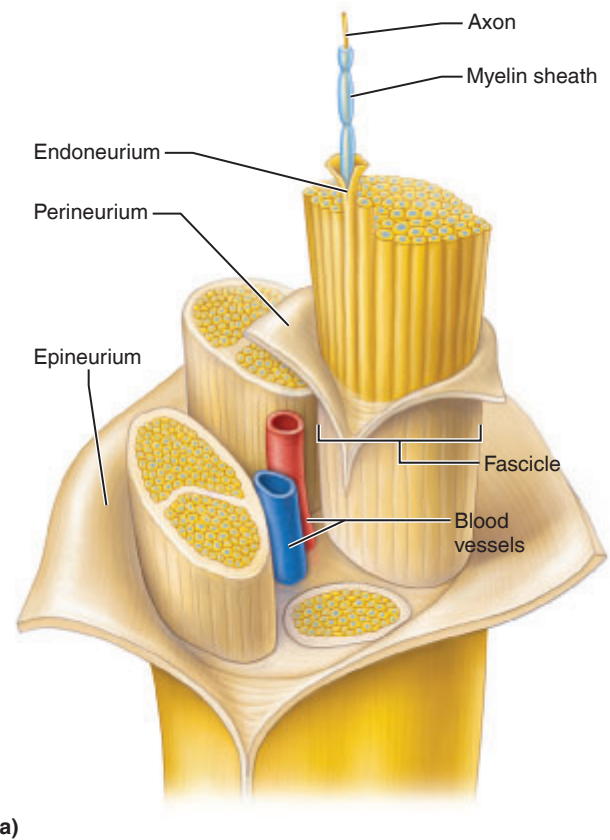

Within a nerve, each fiber is surrounded by a delicate connective tissue sheath called an **endoneurium**, which insulates it from the other neuron processes adjacent to it. Groups of fibers are bound by a coarser connective tissue, called the **perineurium**, to form bundles of fibers called **fascicles**. Finally, all the fascicles are bound together by a tough, white, fibrous connective tissue sheath called the **epineurium**, forming the cordlike nerve (**Figure 13.6**).

Like neurons, nerves are classified according to the direction in which they transmit impulses. Nerves carrying both sensory (afferent) and motor (efferent) fibers are **mixed nerves**; all spinal nerves are mixed nerves. Nerves that carry only sensory processes and conduct impulses only toward the CNS are **sensory**, or **afferent**, nerves. A few of the cranial nerves are pure sensory nerves, but the majority are mixed nerves. The ventral roots of the spinal cord, which carry only motor fibers, are **motor**, or **efferent**, nerves.

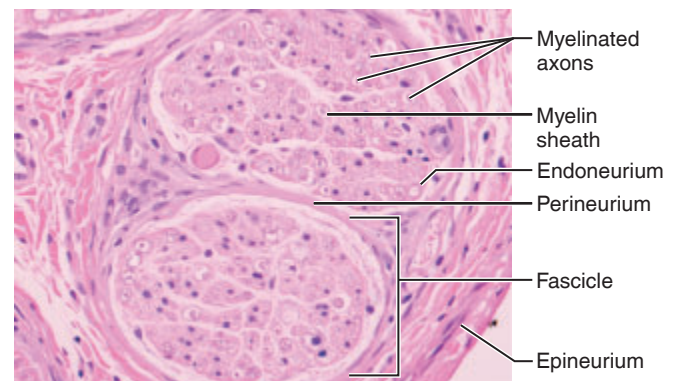
Activity 2

Examining the Microscopic Structure of a Nerve

Go to station 3 of the demonstration area, and examine under the compound microscope a prepared cross section of a peripheral nerve. Identify axons, myelin sheaths, fascicles, and endoneurium, perineurium, and epineurium sheaths. If desired, sketch the nerve in the space below. Compare your sketch to **Figure 13.6b** and **Plate 10** in the *Histology Atlas*.



(a)



(b)

Figure 13.6 Structure of a nerve showing connective tissue wrappings. (a) Three-dimensional view of a portion of a nerve. (b) Photomicrograph of a cross section of a portion of a nerve (200 \times).

This page intentionally left blank

EXERCISE
13

REVIEW SHEET

Neuron Anatomy and Physiology

Name _____ Lab Time/Date _____

1. The cellular unit of the nervous system is the neuron. What is the major function of this cell type?

2. Neuroglia have numerous functions. Name three.

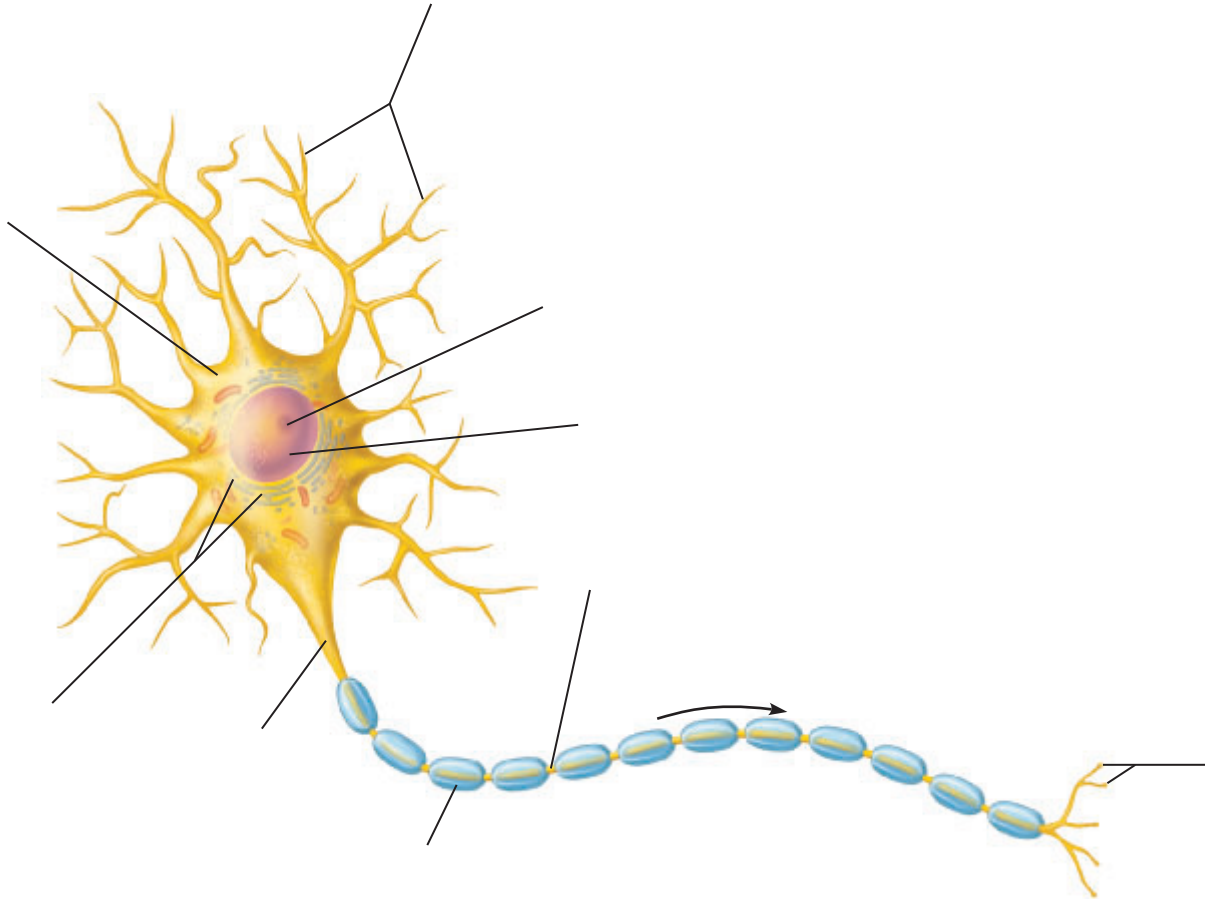
3. Match each statement with a response chosen from the key.

Key: afferent neuron	interneuron	nuclei
central nervous system	neuroglia	peripheral nervous system
efferent neuron	neurotransmitters	synaptic cleft
ganglion	nerve	tract

- _____ 1. the brain and spinal cord collectively
- _____ 2. tiny gap that separates two neurons
- _____ 3. a bundle of axons outside the CNS
- _____ 4. neuron connecting sensory and motor neurons
- _____ 5. a bundle of axons within the CNS
- _____ 6. collections of neuron cell bodies inside the CNS
- _____ 7. neuron that conducts impulses away from the CNS to muscles and glands
- _____ 8. neuron that conducts impulses toward the CNS from the body periphery
- _____ 9. chemicals released by axon terminals
- _____ 10. specialized supporting cells in the nervous system
- _____ 11. collection of neuron cell bodies found in the PNS
- _____ 12. neural structures found outside of the central nervous system

Neuron Anatomy

4. Label the following structures on the diagram of a multipolar neuron shown below: cell body, nucleus, nucleolus, chromatophilic substance, dendrites, initial segment of axon, myelin sheath, myelin sheath gaps, and axon terminals.



5. Describe what happens when an action potential reaches the axon terminal. _____

6. What anatomical characteristic determines whether a particular neuron is classified as unipolar, bipolar, or multipolar? _____

Make a simple line drawing of each type here.

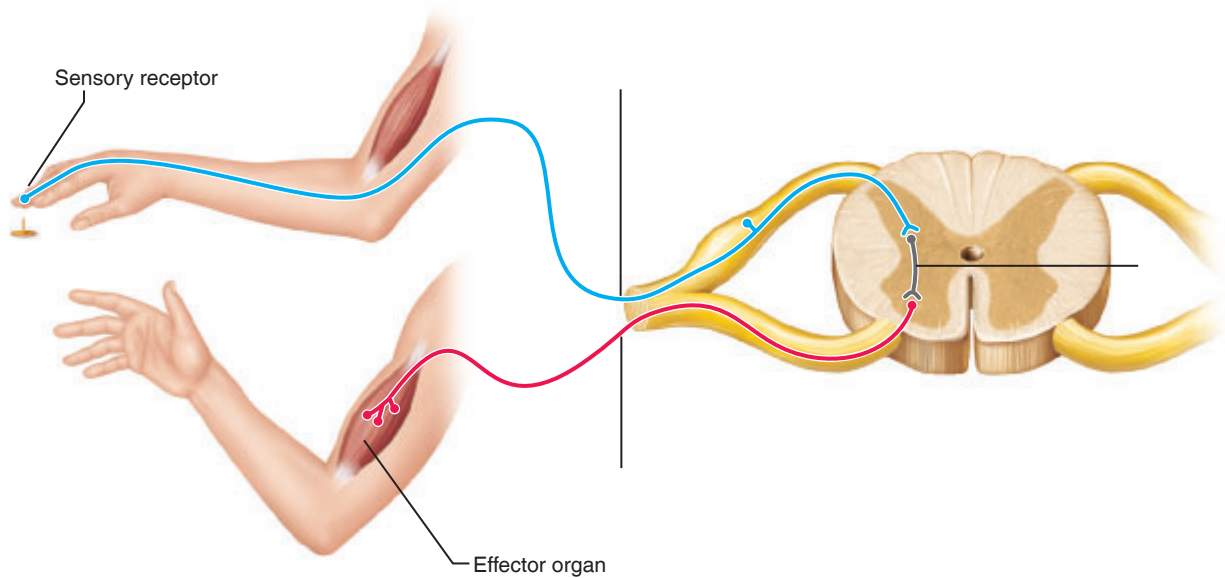
Unipolar neuron

Bipolar neuron

Multipolar neuron

7. Describe how the Schwann cells form the myelin sheath encasing the nerve fibers. _____

8. Correctly identify the sensory (afferent) neuron, interneuron, and motor (efferent) neuron in the figure below.
 Which of these neuron types is/are unipolar? _____
 Which is/are most likely multipolar? _____



The Action Potential

9. Match each of the terms in column B to the appropriate definition in column A.

_____	Column A	Column B
_____	1. reversal of the resting potential due to an influx of sodium ions	action potential
_____	2. period during which potassium ions are diffusing out of the neuron because of a change in membrane permeability	depolarization
_____	3. a brief reversal of membrane potential that travels along the axon	repolarization
_____	4. mechanism that restores the resting membrane voltage and intracellular ionic concentrations	sodium-potassium pump

10. How does an action potential differ from simple depolarization? _____

Structure of a Nerve

11. What is a nerve? _____

12. State the location of each of the following connective tissue coverings:


endoneurium _____


perineurium _____

epineurium _____

13. What is the value of the connective tissue wrappings found in a nerve? _____

14. Define *mixed nerve*: _____

15.  Peripheral neuropathy has a variety of causes. Worldwide, the most common cause is leprosy, also known as Hansen's disease. Would you expect peripheral neuropathy to cause damage to tracts or to nerves? _____
why? _____

16.  Some local anesthetics that are used to block nerve pain work by decreasing the permeability of sodium in the plasma membrane of the neuron. Explain the effect that this change in permeability would have on the generation of action potentials and why. _____

Gross Anatomy of the Brain and Cranial Nerves

Materials

- Human brain model (dissectible)
- Three-dimensional model of ventricles
- Preserved human brain (if available)
- Frontally sectioned human brain slice (if available)
- Materials as needed for cranial nerve testing (see Table 14.2)
- Preserved sheep brain (meninges and cranial nerves intact)
- Dissecting tray and instruments
- Disposable gloves

Learning Outcomes

- Identify externally visible regions of the cerebral hemispheres, diencephalon, brain stem, and cerebellum, and locate the functional areas of the cerebral hemispheres.
- Identify important internal areas of the cerebral hemispheres, diencephalon, brain stem, and cerebellum.
- Identify the three meningeal layers, and state the function of each.
- Discuss the formation, circulation, and drainage of cerebrospinal fluid.
- Identify the cranial nerves by number and name on an appropriate model or diagram, stating the function of each.

For convenience, the nervous system is considered in terms of two principal divisions: the **central nervous system (CNS)** and the **peripheral nervous system (PNS)**. The central nervous system consists of the brain and spinal cord, which interpret incoming sensory information and issue instructions based on past experience. The peripheral nervous system consists of the cranial and spinal nerves, ganglia, and sensory receptors.

In this exercise, we will study both CNS (brain) and PNS (cranial nerves) structures together because of their close anatomical relationship.

The Human Brain

Activity 1

Identifying External Brain Structures

Generally, the brain is studied in terms of four major regions: the cerebral hemispheres, diencephalon, brain stem, and cerebellum. Identify external brain structures using a model of the human brain and the figures cited in the following sections.

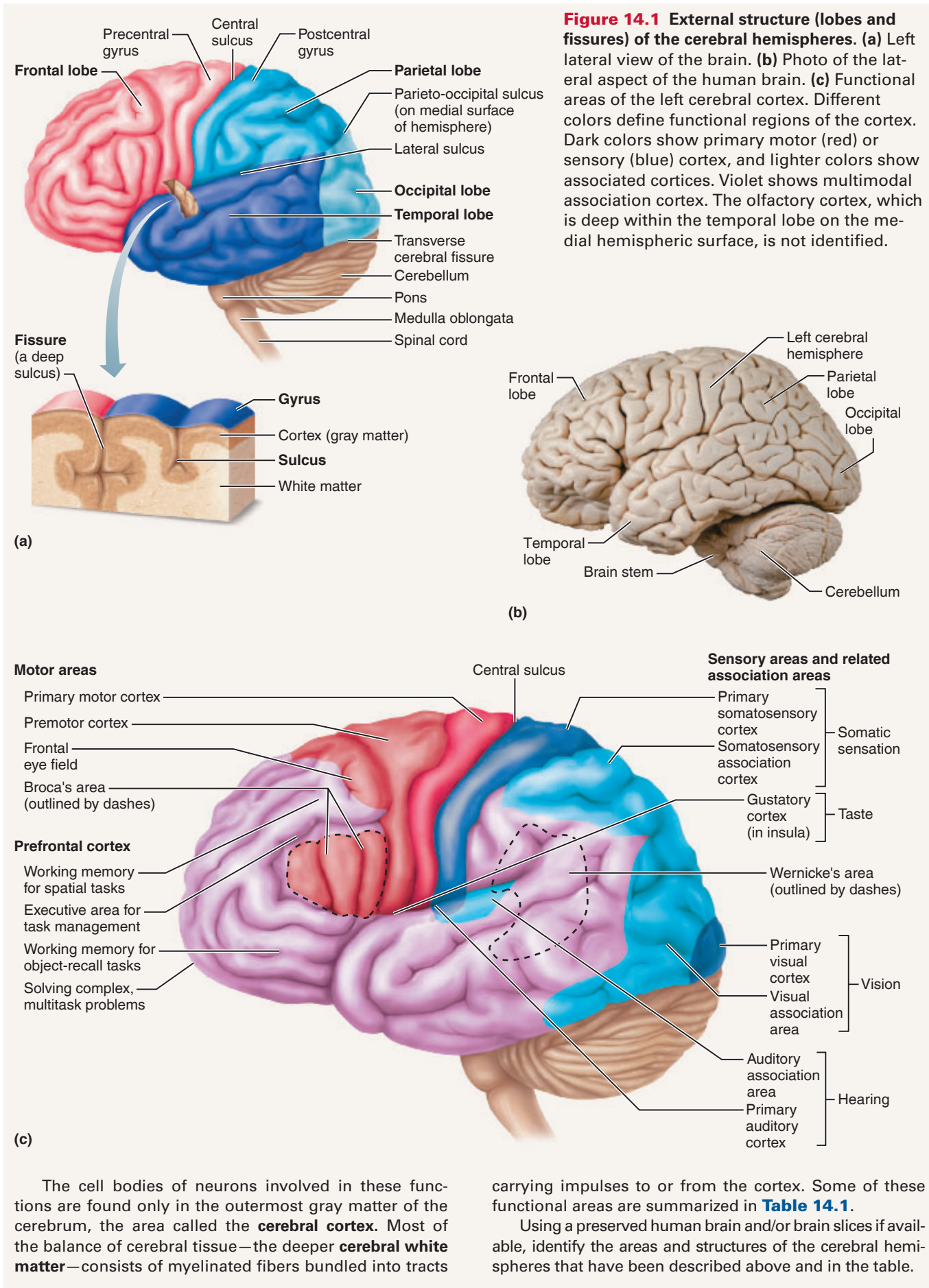
Cerebral Hemispheres

The **cerebral hemispheres** are the most superior part of the brain (**Figure 14.1**). Their entire surface is thrown into elevated ridges called **gyri** that are separated by depressed areas called **fissures** or **sulci**. Many of the fissures and gyri are important anatomical landmarks.

The cerebral hemispheres are divided by the deep **longitudinal fissure**. The **central sulcus** divides the **frontal lobe** from the **parietal lobe**, and the **lateral sulcus** separates the **temporal lobe** from the parietal lobe. The **parieto-occipital sulcus**, which divides the **occipital lobe** from the parietal lobe, is not visible externally. Notice that the cerebral hemisphere lobes are named for the cranial bones that lie over them.

Some important functional areas of the cerebral hemispheres have also been located (Figure 14.1c).

Text continues on next page. →



The cell bodies of neurons involved in these functions are found only in the outermost gray matter of the cerebrum, the area called the **cerebral cortex**. Most of the balance of cerebral tissue—the deeper **cerebral white matter**—consists of myelinated fibers bundled into tracts

carrying impulses to or from the cortex. Some of these functional areas are summarized in **Table 14.1**.

Using a preserved human brain and/or brain slices if available, identify the areas and structures of the cerebral hemispheres that have been described above and in the table.

Table 14.1 Important Functional Areas of the Cerebral Cortex

Functional sensory areas	Location	Functions
Primary somatosensory cortex	Postcentral gyrus of the parietal lobe	Receives information from the body's sensory receptors in the skin and from proprioceptors in the skeletal muscles, joints, and tendons
Primary visual cortex	Occipital lobe	Receives visual information that originates in the retina of the eye
Primary auditory cortex	Temporal lobe in the gyrus bordering the lateral sulcus	Receives sound information from the receptors for hearing in the internal ear
Primary olfactory cortex	Medial surface of the temporal lobe, in a region called the uncus	Receives information from olfactory (smell) receptors in the superior nasal cavity
Functional motor areas	Location	Functions
Primary motor cortex	Precentral gyrus of the frontal lobe	Conscious control of voluntary movement of skeletal muscles
Broca's area	Anterior to the inferior region of the premotor area in the frontal lobe, in only one hemisphere	Controls the muscles involved in speech production and also plays a role in the planning of nonspeech motor functions

Then continue using the preserved brain along with the model and figures as you read about other structures.

Diencephalon

The **diencephalon** consists largely of three paired structures—the thalamus, hypothalamus, and epithalamus.

Turn the brain model to view the ventral surface of the brain. Identify the visible external structures that mark the position of the floor of the diencephalon. These are the **olfactory bulbs and tracts, optic nerves, optic chiasma, optic tracts, pituitary gland, and mammillary bodies (Figure 14.2)**.

Brain Stem

Continue to identify **brain stem** structures—the **cerebral peduncles** (fiber tracts in the **midbrain** connecting the pons below with cerebrum above), the pons, and the medulla oblongata. *Pons* means “bridge,” and the **pons** consists primarily of motor and sensory fiber tracts connecting the brain with lower CNS centers. The lowest brain stem region, the **medulla oblongata**, is also composed primarily of fiber tracts. The medulla also houses many vital autonomic centers involved in the control of visceral activities, such as heart rate, respiratory rhythm, and blood pressure.

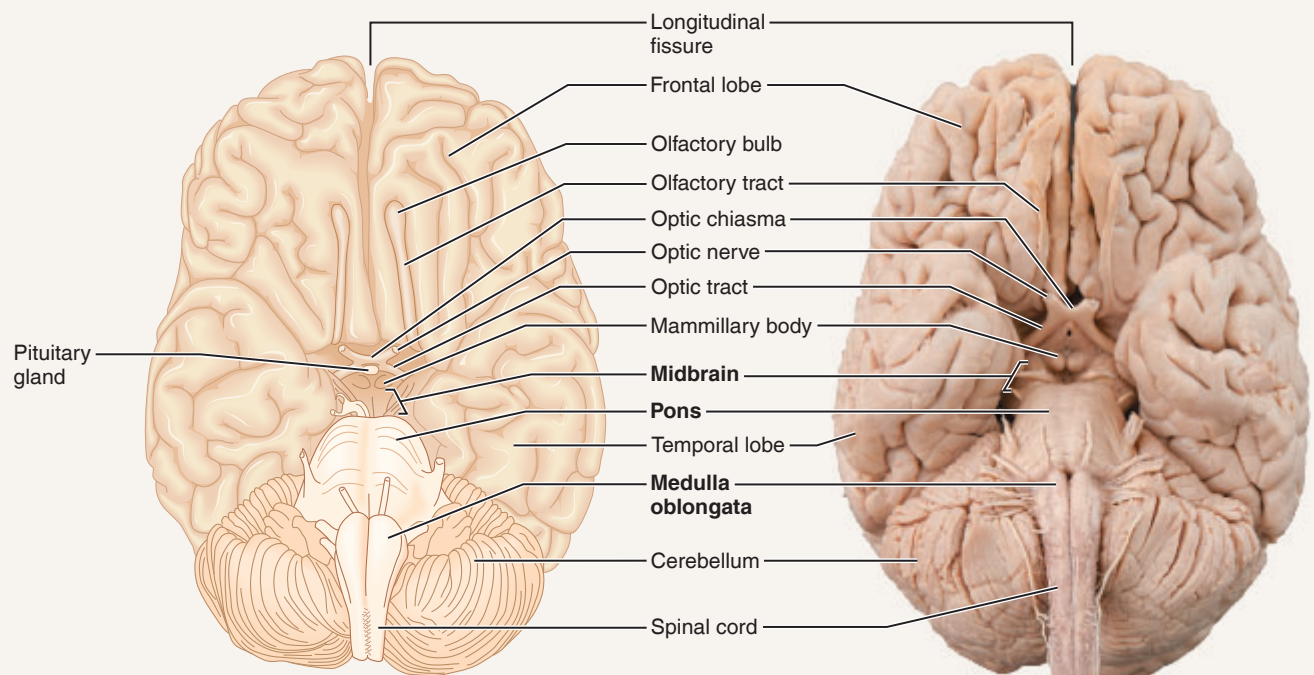


Figure 14.2 Ventral aspect of the human brain, showing the three regions of the brain stem. Only a small portion of the midbrain can be seen; the rest is surrounded by other brain regions.

Text continues on next page. →

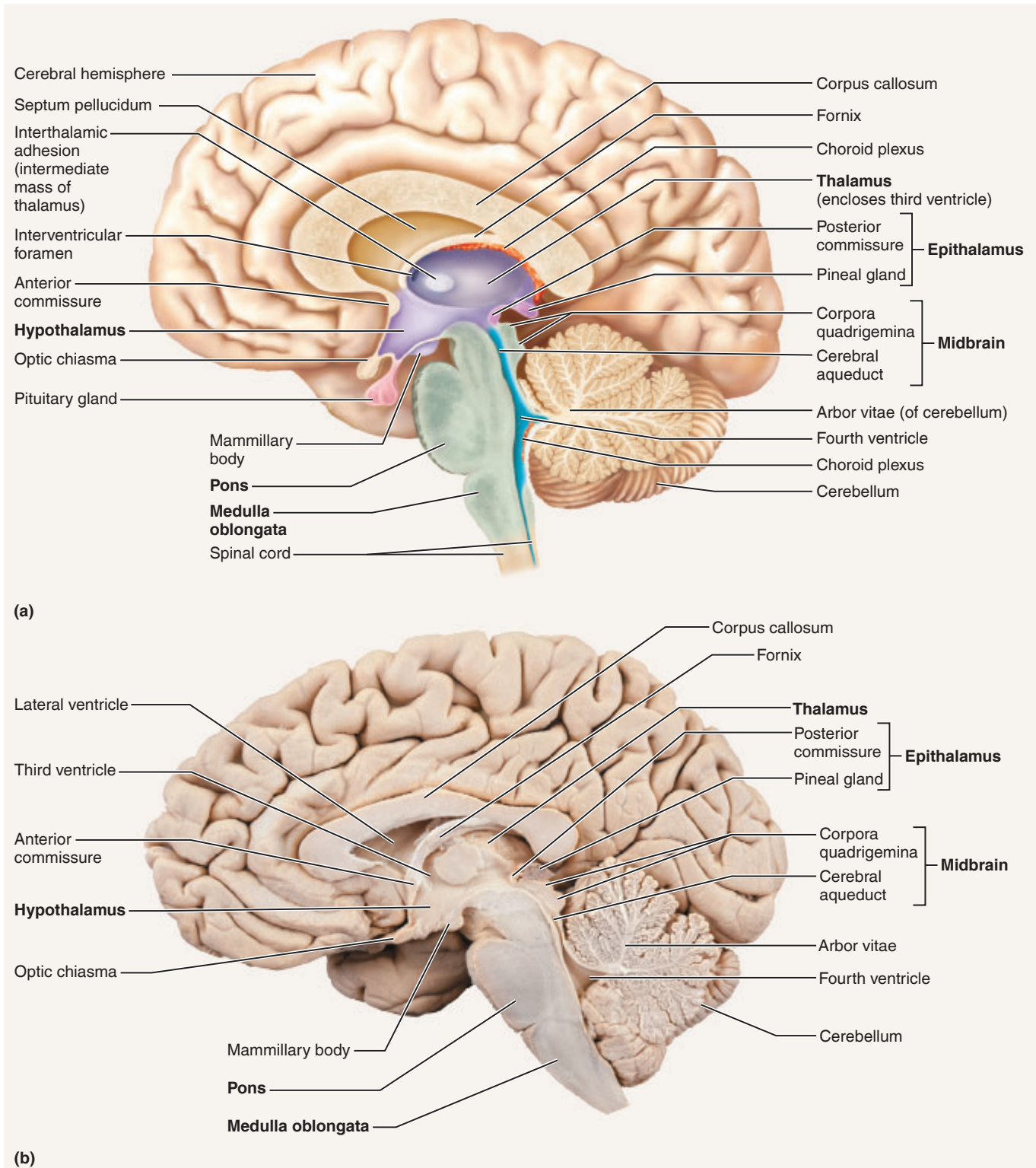


Figure 14.3 Diencephalon and brain stem structures as seen in a median section of the brain. (a) Diagram. (b) Photograph.

Cerebellum

1. Turn the brain model so you can see the dorsal aspect. Identify the large cauliflower-shaped **cerebellum**, which projects dorsally from under the occipital lobe of the cerebrum. Notice that, like the cerebrum, the cerebellum has two major hemispheres and a convoluted surface.

2. Remove the cerebellum to examine the **corpora quadrigemina**, located on the posterior aspect of the midbrain. The two superior prominences are the **superior colliculi** (visual reflex centers). The two smaller **inferior colliculi** are auditory reflex centers (**Figure 14.3**).

Activity 2

Identifying Internal Brain Structures

The deeper structures of the brain have also been well mapped. As the internal brain areas are described, identify them on the figures cited. Also use the brain model, and preserved human brains if available, to help you in this study.

Cerebral Hemispheres

1. Take the brain model apart to see a median view of the internal brain structures (Figure 14.3). Examine the model closely to see the extent of the outer cortex (gray matter), which contains the cell bodies of cerebral neurons.
2. Observe the deeper area of white matter, which is composed of fiber tracts. The fiber tracts are called *association tracts* if they connect two portions of the same hemisphere, *projection tracts* if they run between the cerebral cortex and lower brain structures or spinal cord, and *commissures* if they run from one hemisphere to another. Identify the large **corpus callosum**, the major commissure connecting the cerebral hemispheres. The corpus callosum arches above the structures of the diencephalon.
3. Buried deep within the white matter of the cerebral hemispheres are several “islands” of gray matter (clusters of neuron cell bodies) called **nuclei**. One important group of cerebral nuclei, called the **basal nuclei**, flank the lateral and third ventricles. The basal nuclei help regulate voluntary motor activities. If you have an appropriate dissectible model or a coronally or cross-sectioned human brain slice, identify the basal nuclei.

Diencephalon

1. The major internal structures of the diencephalon are the thalamus, hypothalamus, and epithalamus (Figure 14.3). The **thalamus** consists of two large lobes of gray matter that laterally enclose the narrow third ventricle of the brain. A slender stalk of thalamic tissue, the **interthalamic adhesion** or **intermediate mass**, connects the two lobes and spans the ventricle. The thalamus is a major relay station for sensory impulses passing upward to the cortical sensory areas.
2. The **hypothalamus** makes up the floor of the third ventricle. It is a crucially important autonomic center involved in regulation of body temperature and water

balance, as well as in many other activities and drives. Locate the **pituitary gland**, which hangs from the floor of the hypothalamus by a slender stalk called the **infundibulum**. The pituitary gland is usually not present in preserved brain specimens (and is not illustrated in Figure 14.3a). In life, the pituitary rests in the sella turcica of the sphenoid bone.

Anterior to the pituitary, identify the optic chiasma portion of the optic pathway to the brain. The **mammillary bodies**, relay stations for olfaction, bulge exteriorly from the floor of the hypothalamus just posterior to the pituitary gland.

3. The **epithalamus** forms the roof of the third ventricle. Important structures in the epithalamus are the **pineal gland** (part of the endocrine system) and the **choroid plexus** of the third ventricle. The choroid plexuses, capillary knots within each ventricle, form cerebrospinal fluid.

Brain Stem

1. Now trace the short midbrain from the mammillary bodies to the rounded pons below. (Continue to refer to Figure 14.3.) The **cerebral aqueduct** is a slender canal traveling through the midbrain; it connects the third ventricle to the fourth ventricle. The cerebral peduncles and the rounded corpora quadrigemina lie anterior and posterior (respectively) to the cerebral aqueduct.
2. Trace the rounded pons to the medulla oblongata below, and identify the fourth ventricle posterior to these structures. Attempt to identify the three orifices in the walls of the fourth ventricle, which allow cerebrospinal fluid to circulate into the subarachnoid space from the fourth ventricle.

Cerebellum

Examine the internal structure of the cerebellum. The cerebellum has an outer cortical area of gray matter and an inner area of branching white matter. The treelike branching of the cerebellar white matter is referred to as the **arbor vitae**, or “tree of life.” The cerebellum controls the unconscious coordination of skeletal muscle activity along with balance and equilibrium.

Meninges of the Brain

The brain and spinal cord are covered and protected by three connective tissue membranes called **meninges** (singular: **meninx**). The outermost membrane is the double-layered **dura mater** (Figure 14.4a). One of its layers (the *periosteal layer*) is attached to the inner surface of the skull, forming the periosteum. The other (the *meningeal layer*) forms the outermost brain covering and continues as the dura mater of the spinal cord.

The dural layers are fused together, except in three places where the inner membrane extends inward to form a fold that secures the brain in the cranial cavity. One such extension, the **falx cerebri** (Figure 14.4b), dips into the longitudinal fissure to attach to the crista galli of the ethmoid bone of the skull. The cavity created at this point is the large

superior sagittal sinus, which collects blood draining from the brain tissue.

The middle layer, the weblike **arachnoid mater**, underlies the dura mater and is partially separated from it by the **subdural space**. Threadlike projections bridge the **subarachnoid space** and attach to the innermost membrane, the **pia mater**. The delicate pia mater is highly vascular and clings to the surface of the brain.

In life, the subarachnoid space is filled with cerebrospinal fluid. Specialized projections of the arachnoid tissue called **arachnoid granulations** protrude through the dura mater to allow the cerebrospinal fluid to drain back into the venous blood via the superior sagittal sinus and other dural venous sinuses.

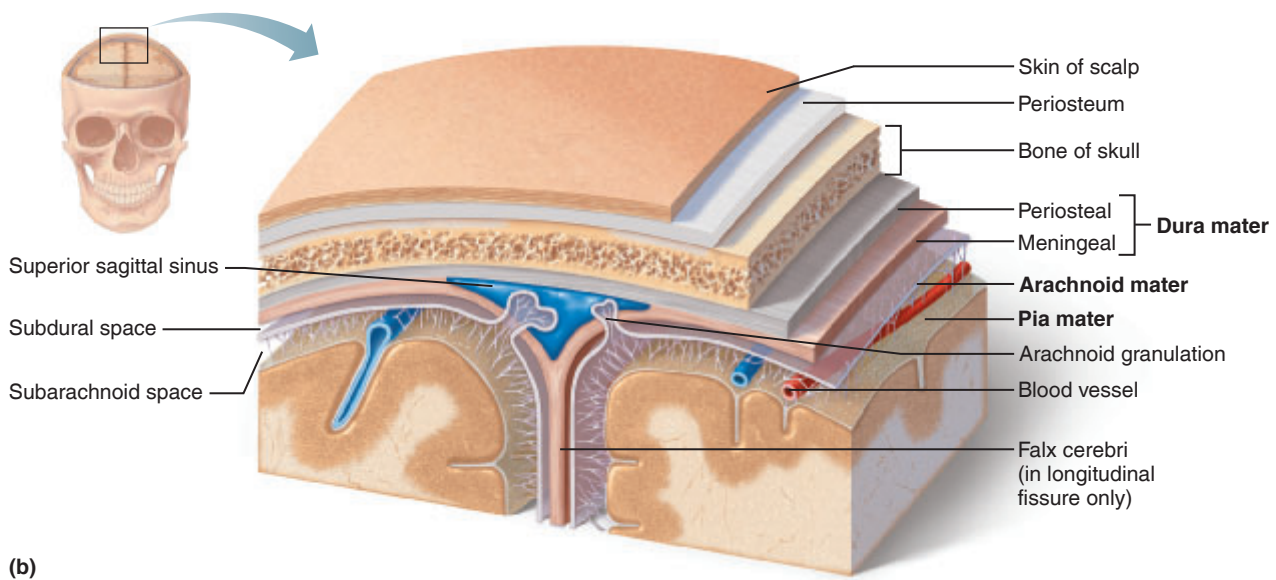
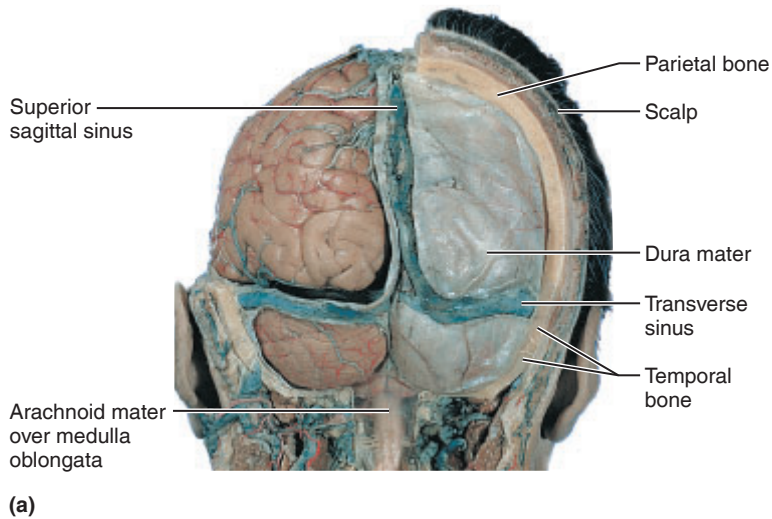


Figure 14.4 Meninges of the brain. (a) Posterior view of the brain in place, surrounded by the dura mater. (b) Three-dimensional frontal section showing the relationship of the dura mater, arachnoid mater, and pia mater. The meningeal dura forms the falx cerebri fold, which extends into the longitudinal fissure and attaches the brain to the ethmoid bone of the skull. A dural venous sinus, the superior sagittal sinus, is enclosed by the dural membranes superiorly. Arachnoid granulations, which return cerebrospinal fluid to the dural venous sinus, are also shown.

Cerebrospinal Fluid

The cerebrospinal fluid is continually formed by the **choroid plexuses**, small capillary knots hanging from the roof of the ventricles of the brain. Cerebrospinal fluid forms a watery cushion that protects the delicate brain tissue against blows to the head.

Within the brain, the cerebrospinal fluid circulates from the two lateral ventricles (in the cerebral hemispheres) into the third ventricle and then through the cerebral aqueduct of the midbrain into the fourth ventricle (**Figure 14.5**). From the fourth ventricle, cerebrospinal fluid circulates into the subarachnoid space via three apertures (openings) in the walls of the fourth ventricle. The fluid returns to the blood in the dural venous sinuses via the arachnoid granulations.

Activity 3

Tracing the Pathway of Cerebrospinal Fluid in the Brain

Obtain a three-dimensional model of the ventricles, and trace the path of cerebrospinal fluid circulation through the internal brain cavities from the lateral ventricles to the subarachnoid space.

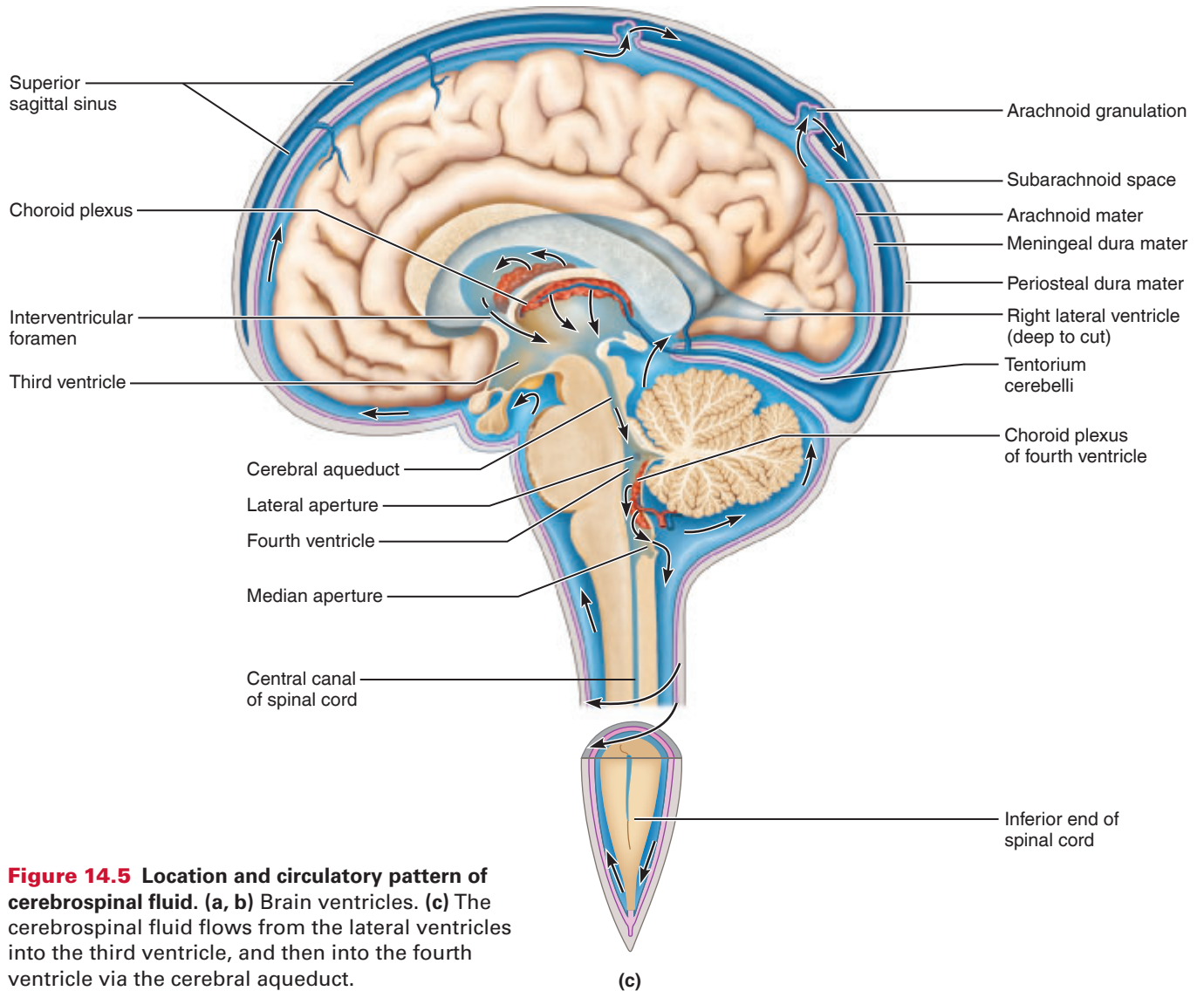
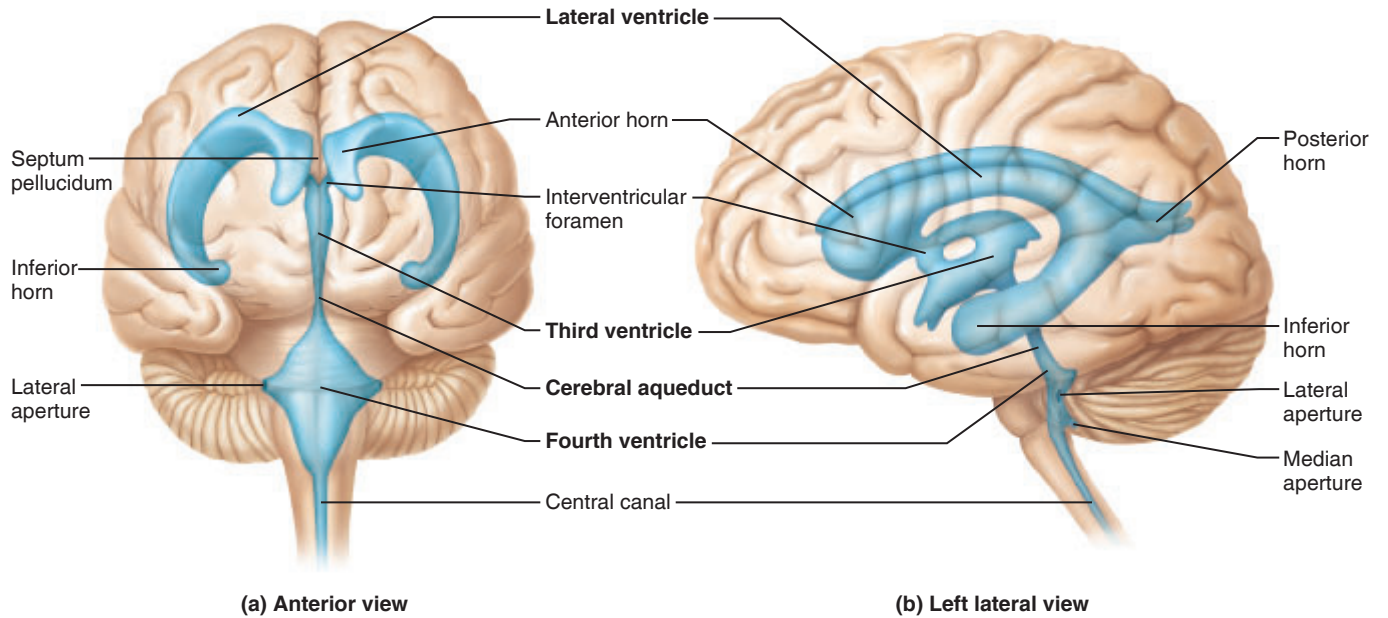


Figure 14.5 Location and circulatory pattern of cerebrospinal fluid. (a, b) Brain ventricles. (c) The cerebrospinal fluid flows from the lateral ventricles into the third ventricle, and then into the fourth ventricle via the cerebral aqueduct.

Cranial Nerves

The **cranial nerves** are part of the peripheral nervous system, but they are best identified while studying the brain. The 12 pairs of cranial nerves primarily serve the head and neck. Only one pair, the vagus nerves, extends into the thoracic and abdominal cavities.

The cranial nerves are numbered in order, and in most cases their names reflect the major structures they control.

Table 14.2 describes the cranial nerves by number (Roman

numeral), name, function, and testing method. You should memorize this information. A catchy saying that might help you to remember the cranial nerves in order is “*On occasion our trusty truck acts funny—very good vehicle anyhow.*” The first letter of each word and the “a” and “h” of the final word, “anyhow,” will remind you of the first letter of the cranial nerve name.

Table 14.2 The Cranial Nerves (see Figure 14.6)

Number and name	Function*	Testing
I. Olfactory	Purely sensory—carries afferent impulses for sense of smell	Person is asked to sniff and identify aromatic substances, such as oil of cloves and vanilla.
II. Optic	Purely sensory—carries afferent impulses for vision	Vision and visual field are determined with eye chart and by testing the point at which the person first sees an object (finger) moving into the visual field. Eye interior viewed with ophthalmoscope to detect swelling of optic disc (point at which optic nerve leaves the eye) and to observe blood vessels.
III. Oculomotor	Primarily motor—motor fibers to inferior oblique and superior, inferior, and medial rectus muscles, which direct eyeball; to levator palpebrae muscles of eyelid; to iris and smooth muscle controlling lens shape and pupil size	Pupils are examined for size, shape, and equality. Pupillary reflex is tested with penlight (pupils should constrict when illuminated). Convergence for near vision is tested, as is subject’s ability to follow objects up, down, side to side, and diagonally with eyes.
IV. Trochlear	Primarily motor—provides motor fibers to superior oblique muscle (an extrinsic eye muscle)	Tested with cranial nerve III
V. Trigeminal	Mixed—conducts sensory impulses from skin of face and anterior scalp, from mucosae of mouth and nose; also contains motor fibers that activate the chewing muscles	Sensations of pain, touch, and temperature are tested with safety pin and hot and cold objects. Corneal reflex tested with wisp of cotton. Motor branch assessed by asking person to clench his teeth, open mouth against resistance, and move jaw side to side.
VI. Abducens	Primarily motor—carries motor fibers to lateral rectus muscle of eye	Tested with cranial nerve III
VII. Facial	Mixed—supplies motor fibers to muscles of facial expression and to lacrimal and salivary glands; carries sensory fibers from taste receptors of anterior tongue	Anterior two-thirds of tongue is tested for ability to taste sweet (sugar), salty, sour (vinegar), and bitter (quinine) substances. Symmetry of face is checked. Subject is asked to close eyes, smile, whistle, and so on. Tearing is assessed with ammonia fumes.
VIII. Vestibulocochlear	Mostly sensory—transmits impulses for senses of equilibrium and hearing; small motor component adjusts the sensitivity of sensory receptors	Hearing is checked by air and bone conduction using tuning fork.
IX. Glossopharyngeal	Mixed—motor fibers serve pharyngeal muscles and salivary glands; sensory fibers carry impulses from pharynx, posterior tongue (taste buds), and pressure receptors of carotid artery	Gag and swallowing reflexes are checked. Subject is asked to speak and cough. Posterior third of tongue may be tested for taste.
X. Vagus	Mixed—motor fibers to pharynx and larynx and sensory fibers from same structures; a very large portion is composed of parasympathetic motor fibers, which supply heart and smooth muscles of abdominal visceral organs; transmits sensory impulses from viscera	As for cranial nerve IX (IX and X are tested, together, since they both serve muscles of throat and mouth)
XI. Accessory	Mixed (but primarily motor in function)—provides motor fibers to sternocleidomastoid and trapezius muscles	Sternocleidomastoid and trapezius muscles are checked for strength by asking person to rotate head and elevate shoulders against resistance.
XII. Hypoglossal	Mixed (but primarily motor in function)—motor fibers serve muscles of tongue, and sensory fibers carry impulses from tongue	Person is asked to protrude and retract tongue. Any deviations in position are noted.

*Does not include sensory impulses from proprioceptors.

Most cranial nerves are mixed nerves (containing both motor and sensory fibers), but two pairs—optic and olfactory—are purely sensory. Neuron cell bodies of the sen-

sory cranial nerves are located in ganglia. Those of the mixed cranial nerves are found both in the brain and in peripheral ganglia.

Activity 4

Identifying and Testing the Cranial Nerves

1. Identify the cranial nerves on the anterior surface of the brain model (use **Figure 14.6** as a guide). Notice that the first (olfactory) cranial nerves are not visible on the model because they consist only of short axons that run from the nasal mucosa through the cribriform foramina of the ethmoid bone. However, the synapse points of the

first cranial nerves, the *olfactory bulbs*, are visible on the model, so identify these.

2. Testing cranial nerves is an important part of any neurological examination (see the last column of Table 14.2). Conduct tests of cranial nerve function following these directions.

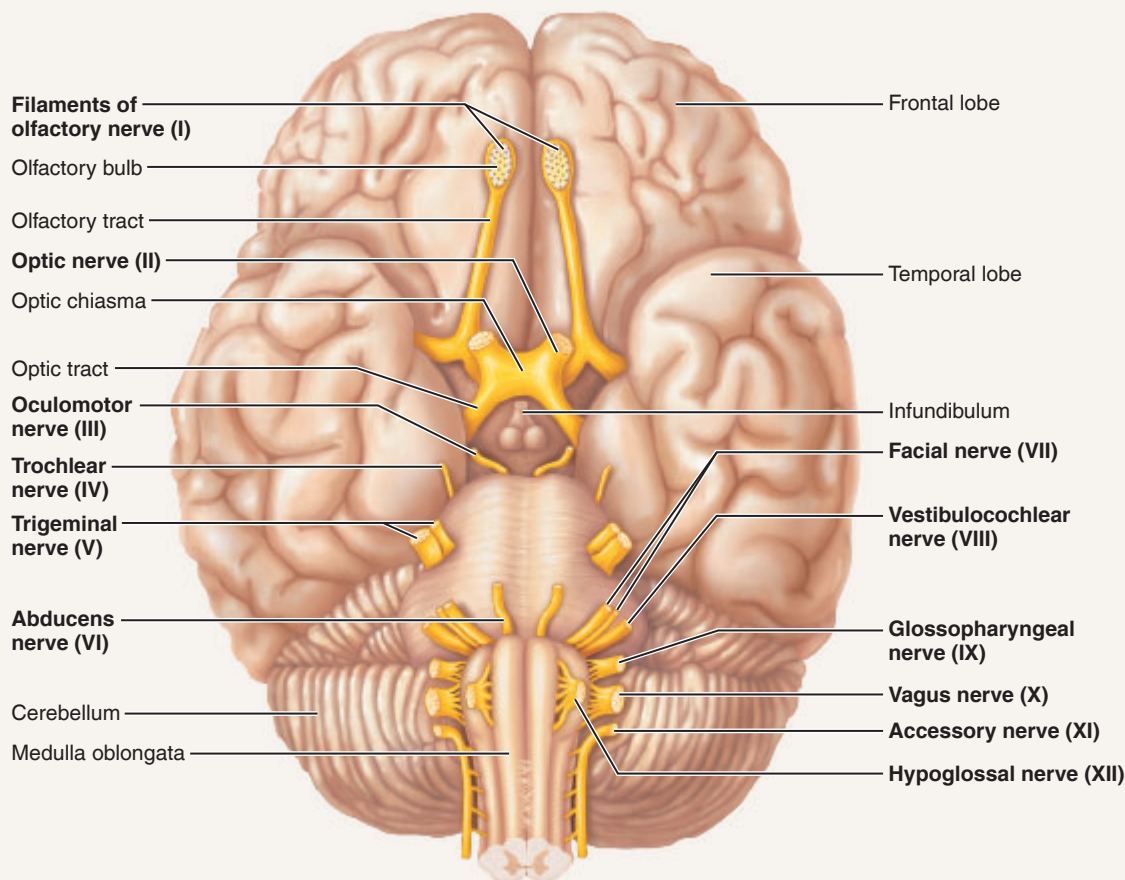


Figure 14.6 Ventral aspect of the human brain, showing the cranial nerves.



DISSECTION

The Sheep Brain

Obtain a sheep brain, disposable gloves, dissecting tray, and instruments, and bring them to your laboratory bench.

1. Turn your sheep brain so that you are viewing its left lateral aspect. Compare the various areas of the sheep brain (cerebrum, brain stem, cerebellum) to the photo of the human brain (Figure 14.1b). Relatively speaking, which of these structures is obviously much larger in humans?

2. Place the ventral surface of the sheep brain down on the dissecting tray, and observe the fragments of the dura mater. Feel its consistency and notice its toughness. Cut through the dura mater along the line of the longitudinal fissure. Gently force the cerebral hemispheres apart laterally to expose the corpus callosum, the huge fiber tract deep to the longitudinal fissure.

Text continues on next page. →

3. Examine the superior surface of the brain. Notice that like the human brain, its surface is thrown into convolutions (fissures and gyri). Identify the arachnoid mater, which appears on the brain surface as a delicate “cottony” material spanning the fissures.

Ventral Structures

Note the important features of the ventral surface of the sheep brain (**Figure 14.7a** and **b**). Turn the brain over so that its ventral surface is up.

1. Look for the clublike olfactory bulbs on the inferior surface of the frontal lobes of the cerebral hemispheres.

How does the size of these olfactory bulbs compare with those of humans?

Is the sense of smell more important as a protective and a foraging sense in sheep *or* in humans?

2. The optic nerve (II) carries sensory impulses concerned with vision from the retina of the eye. Identify the optic nerves, the optic chiasma, and the optic tracts.

3. Posterior to the optic chiasma, identify the stalk, or infundibulum, of the pituitary gland and then the mammillary body. Notice that the sheep’s mammillary body is a single rounded eminence. In humans, it is a double structure.

4. Identify the cerebral peduncles on the ventral aspect of the midbrain, just posterior to the mammillary body. Also identify the large oculomotor nerves (III), which arise from the ventral midbrain surface, and the tiny trochlear nerves (IV), seen at the midbrain-pons junction. These cranial nerves provide motor fibers to extrinsic muscles of the eyeball.

5. Moving posteriorly from the midbrain, identify first the pons and then the medulla oblongata.

6. Return to the junction of the pons and midbrain, and proceed posteriorly to identify the following cranial nerves, all arising from the pons:

- Trigeminal nerves (V), which are involved in chewing and sensations of the head and face
 - Abducens nerves (VI), which abduct the eye (and thus work in conjunction with cranial nerves III and IV)
 - Facial nerves (VII), large nerves involved in taste sensation, gland function (salivary and lacrimal glands), and facial expressions
7. Continue posteriorly to identify the following:
- Vestibulocochlear nerves (VIII), mostly sensory nerves that are involved with hearing and equilibrium
 - Glossopharyngeal nerves (IX), which contain motor fibers innervating throat structures and sensory fibers transmitting taste stimuli (in conjunction with cranial nerve VII)
 - Vagus nerves (X), often called “wanderers,” which serve many organs of the head, thorax, and abdominal cavity

- Accessory nerves (XI), which serve muscles of the neck, larynx, and shoulder; notice that the accessory nerves arise from the spinal cord

- Hypoglossal nerves (XII), which stimulate tongue and neck muscles

Dorsal Structures

Identify the following structures (refer to Figure 14.7b as a guide).

1. Reidentify the now exposed cerebral hemispheres. How does the depth of the fissures in the sheep’s cerebral hemispheres compare to that in the human brain?

2. Examine the cerebellum. Notice that, in contrast to the human cerebellum, it is not divided longitudinally and that its fissures are oriented differently.

3. To expose the dorsal surface of the midbrain, gently force the cerebrum and cerebellum apart (**Figure 14.8**). Identify the corpora quadrigemina, four rounded prominences on the dorsal midbrain surface. What is the function of the corpora quadrigemina?

Also locate the pineal gland, which appears as a small oval protrusion in the midline just anterior to the corpora quadrigemina.

Internal Structures

1. The internal structure of the brain can only be examined after further dissection. Position the brain ventral side down, and make a cut completely through it in a superior to inferior direction. Cut through the longitudinal fissure, corpus callosum, and midline of the cerebellum. (Refer to **Figure 14.9** as you work.)

2. A thin nervous tissue membrane immediately ventral to the corpus callosum that separates the lateral ventricles is the septum pellucidum. Pierce this membrane, and probe the cavity of the lateral ventricle.

3. Identify the thalamus, which forms the walls of the third ventricle. The interthalamic adhesion spanning the ventricular cavity appears as a round protrusion of the thalamus wall.

4. The hypothalamus forms the floor of the third ventricle. Identify the optic chiasma, infundibulum, and mammillary body on its exterior surface. The pineal gland is at the posterior end of the third ventricle.

5. Locate the midbrain by identifying the corpora quadrigemina that form its dorsal roof. Follow the cerebral aqueduct through the midbrain tissue to the fourth ventricle. Identify the cerebral peduncles, which form its anterior walls.

6. Identify the pons and medulla, which lie anterior to the fourth ventricle. The medulla continues into the spinal cord without any obvious anatomical change, but the

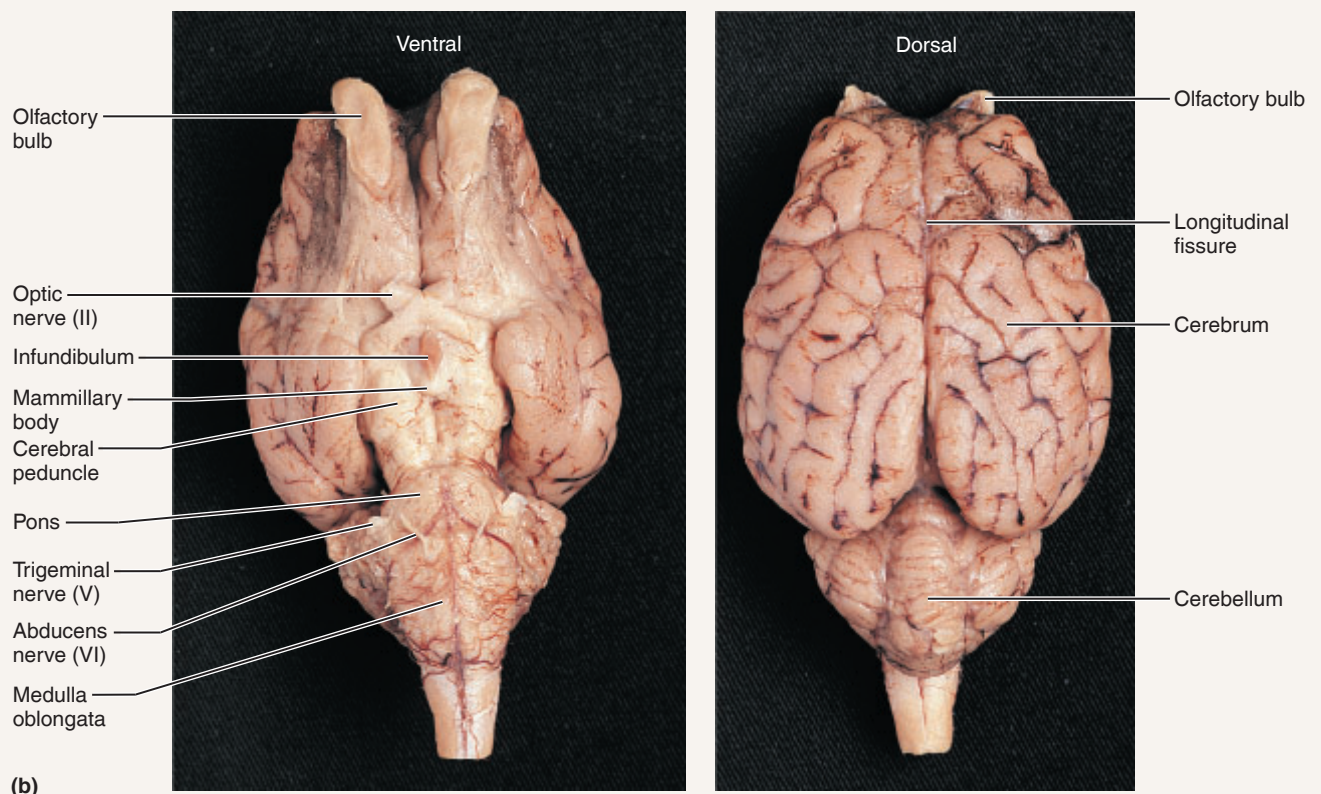
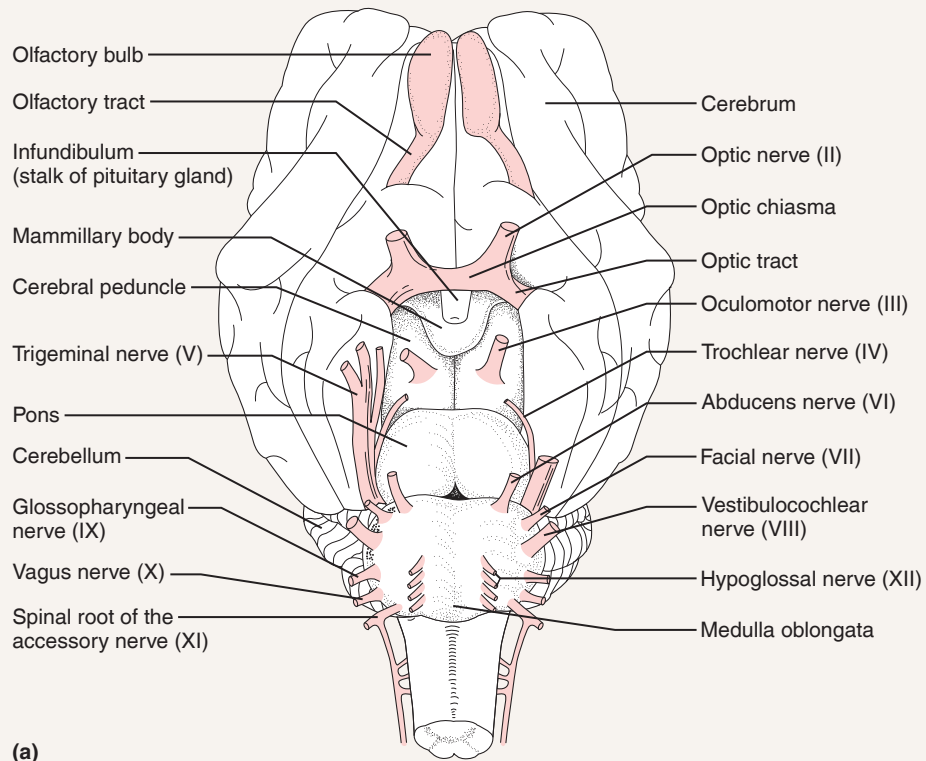


Figure 14.7 Intact sheep brain. (a) Diagram, ventral view. (b) Photographs showing ventral and dorsal views.

Text continues on next page. →

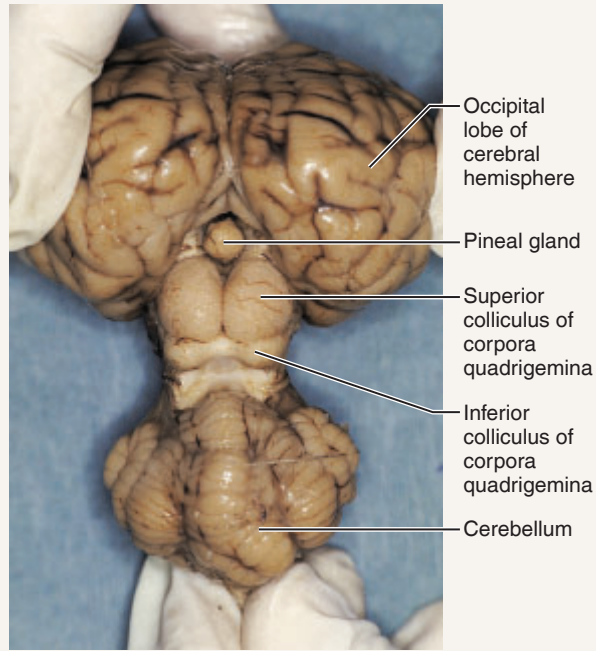


Figure 14.8 Means of exposing the dorsal midbrain structures of the sheep brain.

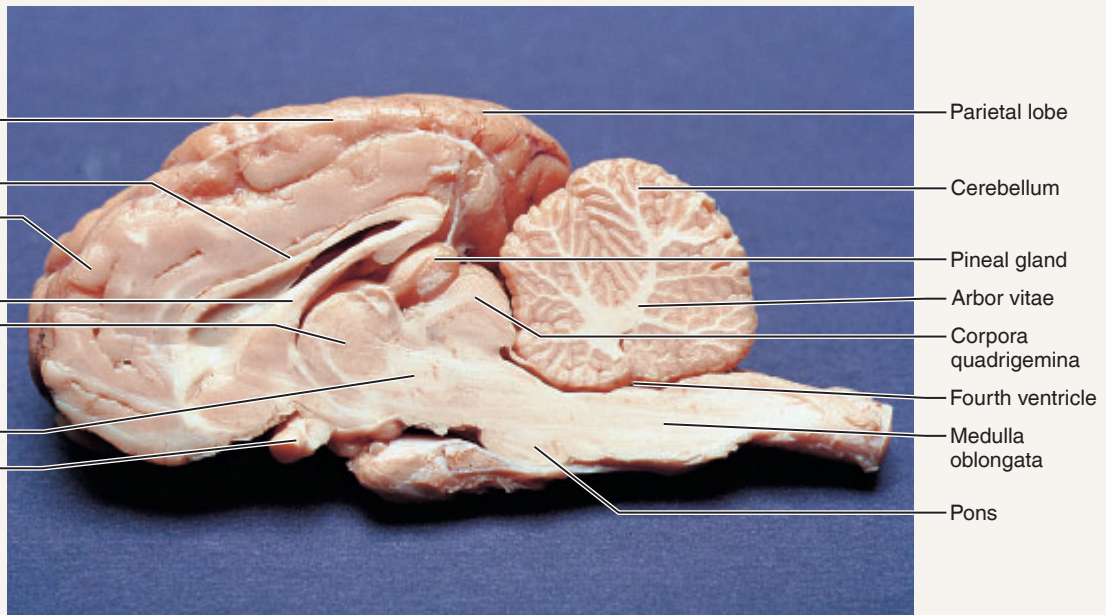


Figure 14.9 Sagittal section of the sheep brain, showing internal structures.

point at which the fourth ventricle narrows to a small canal is generally accepted as the beginning of the spinal cord.

7. Identify the cerebellum posterior to the fourth ventricle and notice the internal treelike arrangement of its white matter called the arbor vitae.

8. Check with your instructor to determine whether cow spinal cord sections (preserved) are available for the spinal

cord studies (Exercise 15). If not, save the small portion of the spinal cord from your brain specimen. Otherwise, dispose of all organic debris in the appropriate laboratory containers, and clean the dissecting instruments and tray before leaving the laboratory.

EXERCISE
14

REVIEW SHEET

Gross Anatomy of the Brain and Cranial Nerves

Name _____ Lab Time/Date _____

The Human Brain

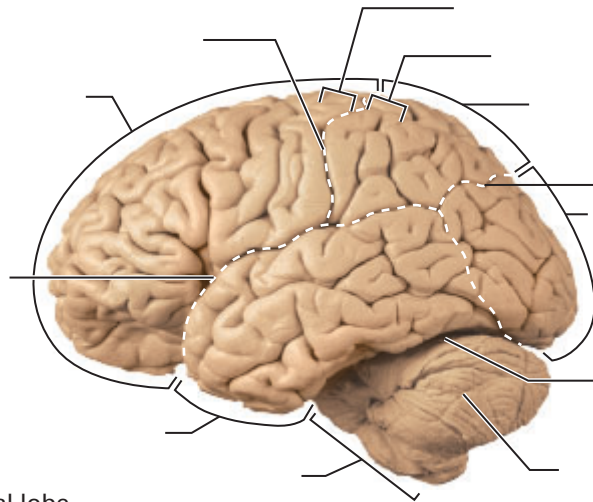
1. In which of the cerebral lobes (frontal, parietal, occipital, or temporal) would the following functional areas be found?

primary auditory cortex _____ primary olfactory cortex _____
 primary motor cortex _____ primary visual cortex _____
 primary somatosensory cortex _____ Broca's area _____

2. Using the terms from the key, identify the structures of the brain.

Key:

- a. brain stem
- b. central sulcus
- c. cerebellum
- d. frontal lobe
- e. lateral sulcus
- f. occipital lobe
- g. parietal lobe
- h. parieto-occipital sulcus
- i. postcentral gyrus
- j. precentral gyrus
- k. temporal lobe
- l. transverse cerebral fissure



3. Which of the following structures are *not* part of the brain stem? (Circle the appropriate response or responses.)

cerebral hemispheres pons midbrain cerebellum medulla

4. Complete the following statements by writing the proper word or phrase in the corresponding blank at left.

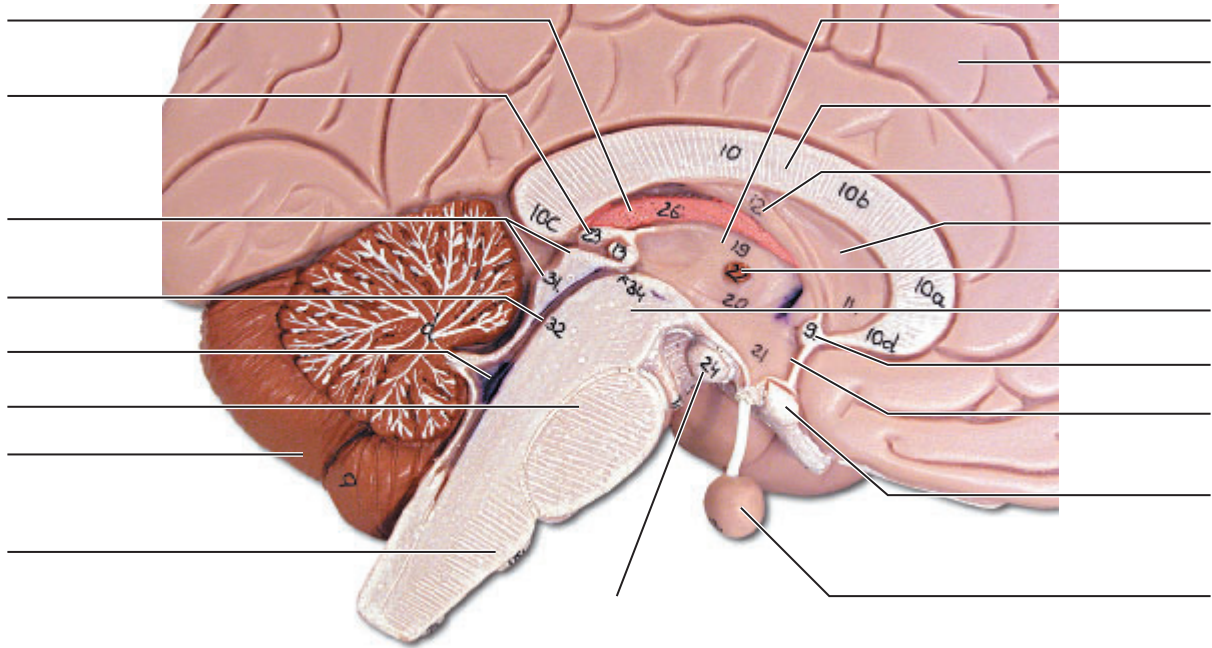
- 1. _____
- 2. _____
- 3. _____
- 4. _____
- 5. _____
- 6. _____

A(n) 1 is an elevated ridge of cerebral tissue. Inward folds of cerebral tissue are called 2 or 3. Gray matter is composed of 4. White matter is composed of 5. A fiber tract that provides for communication between different parts of the same cerebral hemisphere is called a(n) 6, whereas one that carries impulses from one cerebral hemisphere to another is called a(n) 7. Nuclei deep within the cerebral hemisphere white matter are collectively called the 8.

- 7. _____
- 8. _____

5. Using the terms from the key, identify the structures on the following midsagittal view of the human brain.

- Key:
- | | | |
|-------------------------|---------------------------|----------------------|
| a. anterior commissure | h. fornix | o. optic chiasma |
| b. cerebellum | i. fourth ventricle | p. pineal gland |
| c. cerebral aqueduct | j. hypothalamus | q. pituitary gland |
| d. cerebral hemisphere | k. interthalamic adhesion | r. pons |
| e. choroid plexus | l. mammillary body | s. septum pellucidum |
| f. corpora quadrigemina | m. medulla oblongata | t. thalamus |
| g. corpus callosum | n. midbrain | |



6. Using the key from question 5, match the appropriate structures with the following descriptions:

- | | |
|-------|---|
| _____ | 1. important autonomic center of brain involved in the regulation of body temperature |
| _____ | 2. located in the midbrain; contains reflex centers for vision and hearing |
| _____ | 3. coordinates complex muscular movements |
| _____ | 4. contains autonomic centers regulating heart rate, respiration, and other visceral activities |
| _____ | 5. large fiber tract connecting the cerebral hemispheres |
| _____ | 6. the infundibulum connects this gland to the hypothalamus |
| _____ | 7. canal that connects the third and fourth ventricles |
| _____ | 8. the interthalamic adhesion connects its two lobes |

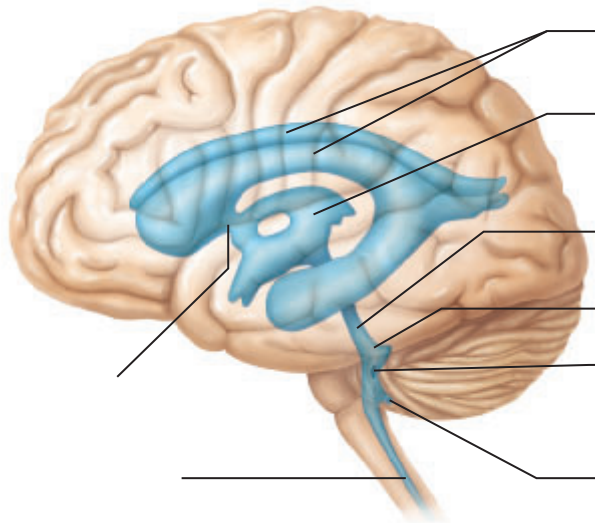
Meninges of the Brain

7. Identify the meningeal (or associated) structures described below:

- _____ 1. outermost meninx; composed of tough fibrous connective tissue
- _____ 2. innermost meninx covering the brain; follows every convolution
- _____ 3. returns cerebrospinal fluid to the venous blood in the dural venous sinuses
- _____ 4. structure that produces the cerebrospinal fluid
- _____ 5. middle meninx delicate with cottony fibers
- _____ 6. a dural fold that attaches the cerebrum to the crista galli of the skull

Cerebrospinal Fluid

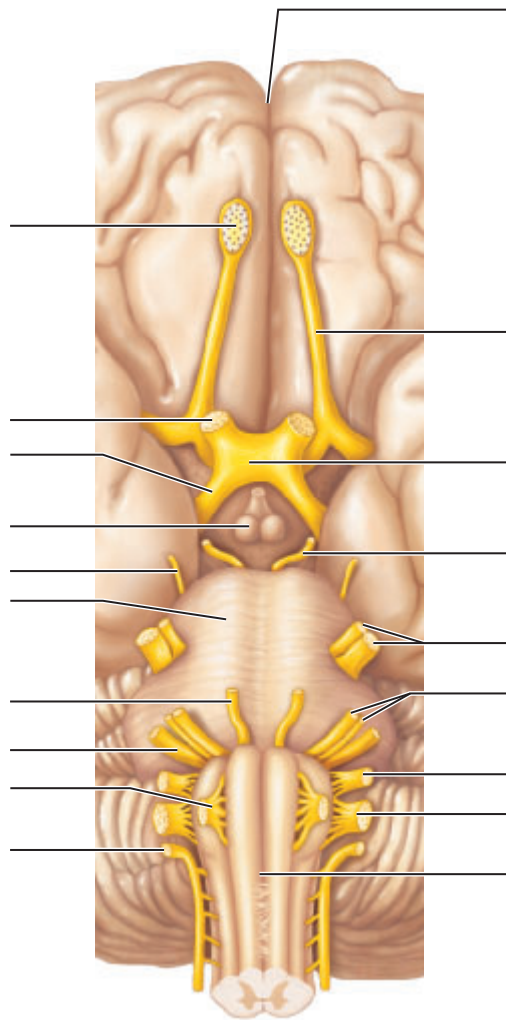
8. Label the structures involved with circulation of cerebrospinal fluid on the accompanying diagram.



Cranial Nerves

9. Using the terms below, correctly identify all structures indicated by leader lines on the diagram.

- | | | |
|--------------------------------|---------------------------|-----------------------------------|
| a. abducens nerve (VI) | h. medulla oblongata | o. pons |
| b. accessory nerve (XI) | i. oculomotor nerve (III) | p. trigeminal nerve (V) |
| c. facial nerve (VII) | j. olfactory bulb | q. trochlear nerve (IV) |
| d. glossopharyngeal nerve (IX) | k. olfactory tract | r. vagus nerve (X) |
| e. hypoglossal nerve (XII) | l. optic chiasma | s. vestibulocochlear nerve (VIII) |
| f. longitudinal fissure | m. optic nerve (II) | |
| g. mammillary body | n. optic tract | |



Dissection of Sheep Brain


10. In your own words, describe the relative hardness of the sheep brain tissue as noticed when you were cutting into it.


Formalin hardens all tissue. What conclusions might you draw about the firmness and texture of living brain tissue?

11. How does the relative size of the cerebral hemispheres compare in sheep and human brains? _____

What is the significance of this difference? _____

12. What is the significance of the fact that the olfactory bulbs are much larger in the sheep brain than in the human brain?

13.  Explain why trauma to the brain stem is often much more dangerous than trauma to the frontal lobes.

14.  Patients with unresponsive wakefulness syndrome (UWS) have lost awareness of self and their environment. In many cases, there is no damage to the cerebral cortex or the brain stem. If signal transmission to the cerebral cortex is affected, what part of the brain is most likely to have been damaged? _____

This page intentionally left blank

Spinal Cord and Spinal Nerves

Materials

- Spinal cord model (cross section)
- Three-dimensional models or laboratory charts of the spinal cord and spinal nerves
- Colored pencils
- Preserved cow spinal cord sections with meninges and nerve roots intact, or spinal cord segment saved from the brain dissection (Exercise 14)
- Petri dishes
- Dissecting tray and single-edge razor blades
- Dissecting microscope or magnifying glass
- Disposable gloves

Learning Outcomes

- Identify important anatomical areas on a model or appropriate diagram of the spinal cord.
- Describe the origin, fiber composition, and distribution of the spinal nerves, differentiating roots, the spinal nerve proper, and rami.
- Identify the four major nerve plexuses, the major nerves of each, and their distribution.

Anatomy of the Spinal Cord

The cylindrical **spinal cord** plays a major role in spinal reflex activity and provides neural pathways to and from the brain. Enclosed within the vertebral column, the spinal cord extends from the foramen magnum of the skull to the first or second lumbar vertebra where it terminates in the cone-shaped **conus medullaris** (**Figure 15.1**).

Like the brain, the spinal cord is cushioned and protected by meninges. The dura mater and arachnoid meningeal coverings extend beyond L₂, approximately to the level of S₂. The **filum terminale**, a fibrous extension of the pia mater, extends even farther to attach to the posterior coccyx.

In humans, 31 pairs of spinal nerves arise from the spinal cord and serve the body area at their approximate level of emergence. The cord is about the diameter of a thumb for most of its length, but it is obviously enlarged in the cervical and lumbar areas where the nerves serving the upper and lower limbs leave the cord.

Because the spinal cord does not extend to the end of the vertebral column, lumbar and sacral spinal nerves must travel through the vertebral canal for some distance before exiting. This collection of spinal nerves at the inferior end of the vertebral canal is called the **cauda equina** (literally translated as “a horse’s tail”).

Activity 1

Identifying Structures of the Spinal Cord

Obtain a model of a cross section of a spinal cord, and identify its structures as they are described next.

Gray Matter

In cross section, the **gray matter** of the spinal cord looks like a butterfly or the letter H (**Figure 15.2**). The two posterior projections are called the **dorsal (posterior) horns**. The two broader anterior projections are the **ventral (anterior) horns**. In the thoracic and lumbar regions of the cord, there is also a lateral out-pocketing of gray matter on each side referred to as the **lateral horn**. The central area of gray matter surrounds the **central canal** of the spinal cord.

The posterior horns contain interneurons and sensory fibers that enter the cord via the **dorsal root**. The cell bodies of these sensory neurons are found in an enlarged area of the dorsal root called the **dorsal root ganglion**. The ventral horns contain cell bodies of motor neurons of the somatic nervous system, which

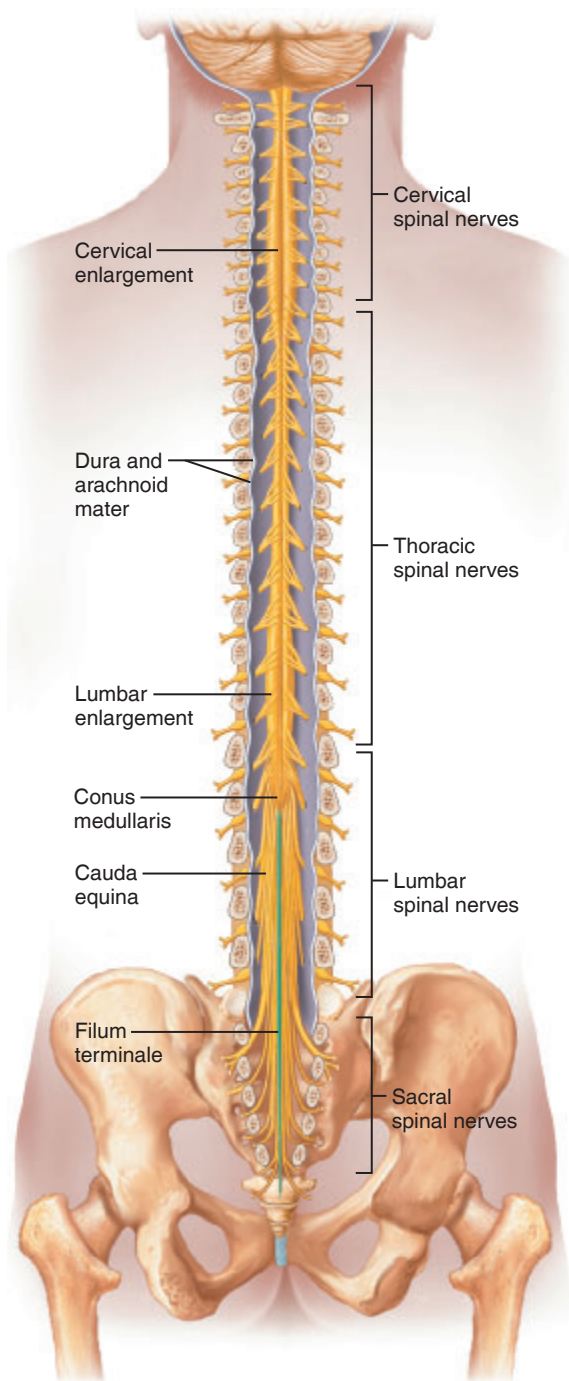


Figure 15.1 Gross structure of the spinal cord, posterior view. The bony vertebral arches have been removed to reveal the spinal cord and its nerve roots. The dura and arachnoid mater are cut open and reflected laterally.

send their axons out via the **ventral root** of the cord to enter the adjacent spinal nerve. The dorsal and ventral roots fuse to form the **spinal nerves**. The lateral horns, where present, contain nerve cell bodies of motor neurons of the autonomic nervous system (sympathetic division).

White Matter

The **white matter** of the spinal cord is composed of myelinated fibers—most running to or from higher centers. Because of the shape of the gray matter, the white matter on each side

of the cord is divided into three regions: the **dorsal (posterior) lateral**, and **ventral (anterior) columns**, or **funiculi** (singular: **funiculus**). Each white column contains a number of fiber **tracts** composed of axons with the same origin, destination, and function. Tracts conducting sensory impulses to the brain are *ascending*, or *sensory, tracts*. Those carrying impulses from the brain to the skeletal muscles are *descending*, or *motor, tracts*.



DISSECTION

Spinal Cord

1. Obtain a dissecting tray and razor blade, a petri dish, and disposable gloves. Place a segment of preserved spinal cord from a cow or saved from the brain specimen (used in Exercise 14) on the petri dish, and bring it to your laboratory bench. Identify the tough outer dura mater and the weblike arachnoid mater.

What name is given to the third meningeal layer, and where is it found?

Peel back the dura mater, and observe the fibers making up the dorsal and ventral roots. If possible, identify a dorsal root ganglion.

2. Using the razor blade, cut a thin cross section of the cord and identify the ventral and dorsal horns of the gray matter with the naked eye or with the aid of a dissecting microscope or magnifying glass.

How can you be certain that you are correctly identifying the ventral and dorsal horns?

Also identify the central canal and the general location of the posterior, anterior, and lateral funiculi of white matter.

3. Refer to **Figure 15.3** and to Plate 9 of the Histology Atlas as you examine the section carefully. Using colored pencils, color Figure 15.3 to match the spinal cord tissue you are viewing.

Observe the shape of the central canal. Is it basically

circular or oval? _____

Can you see any neuron cell bodies? _____

What type of neurons would you expect to find in the ventral horns—motor, interneurons, or sensory?

In the dorsal root ganglion? _____

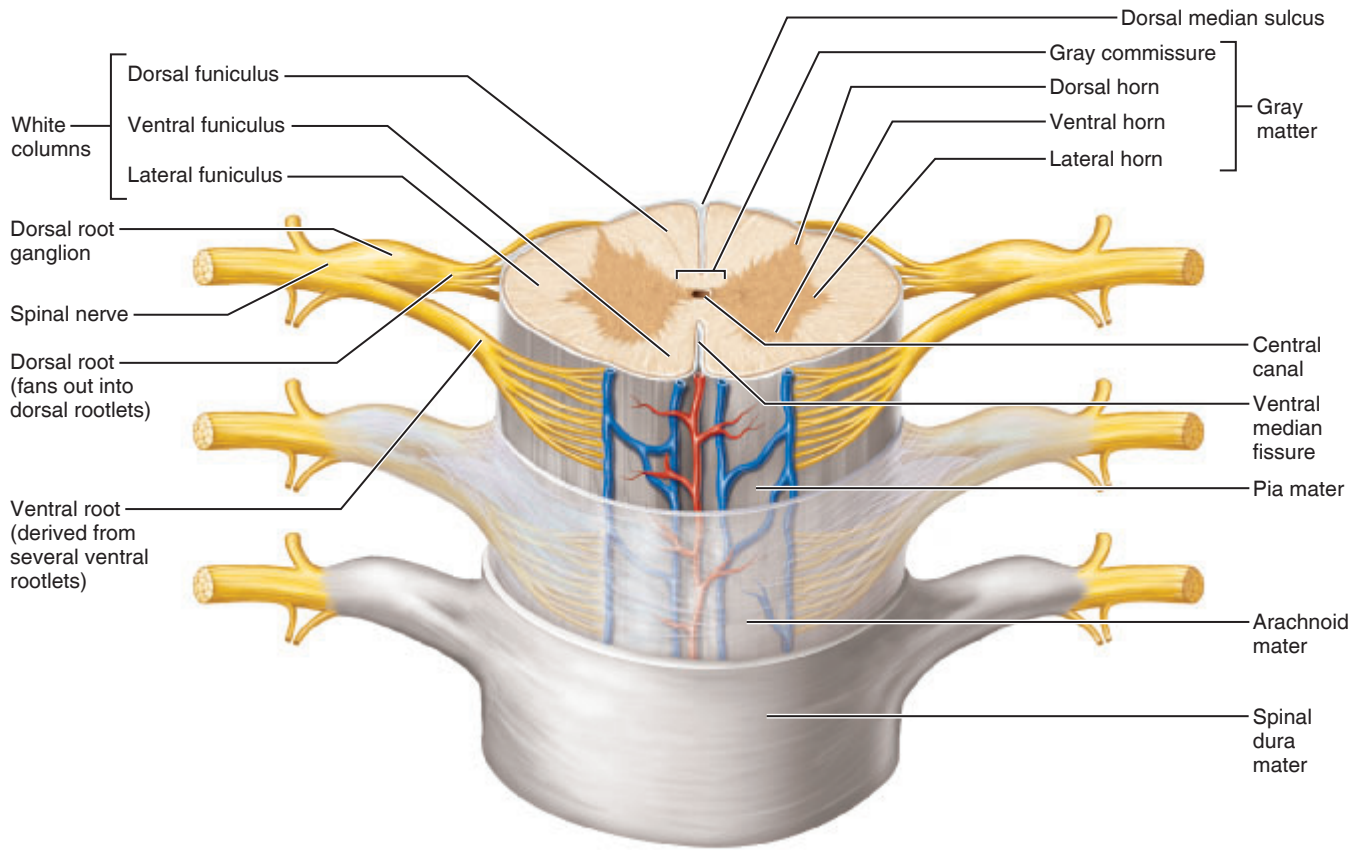


Figure 15.2 Anatomy of the human spinal cord (three-dimensional view).

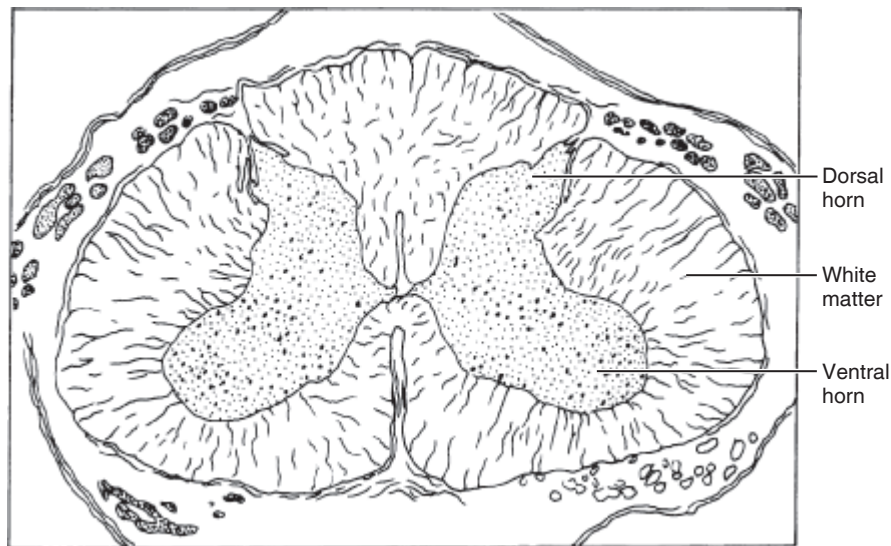
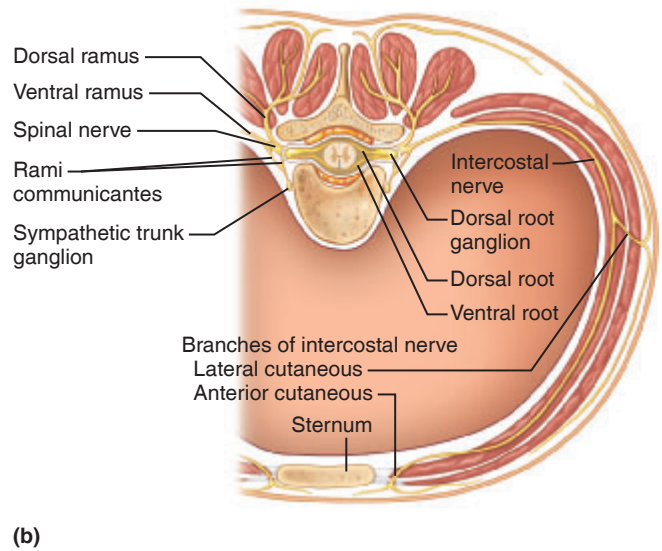
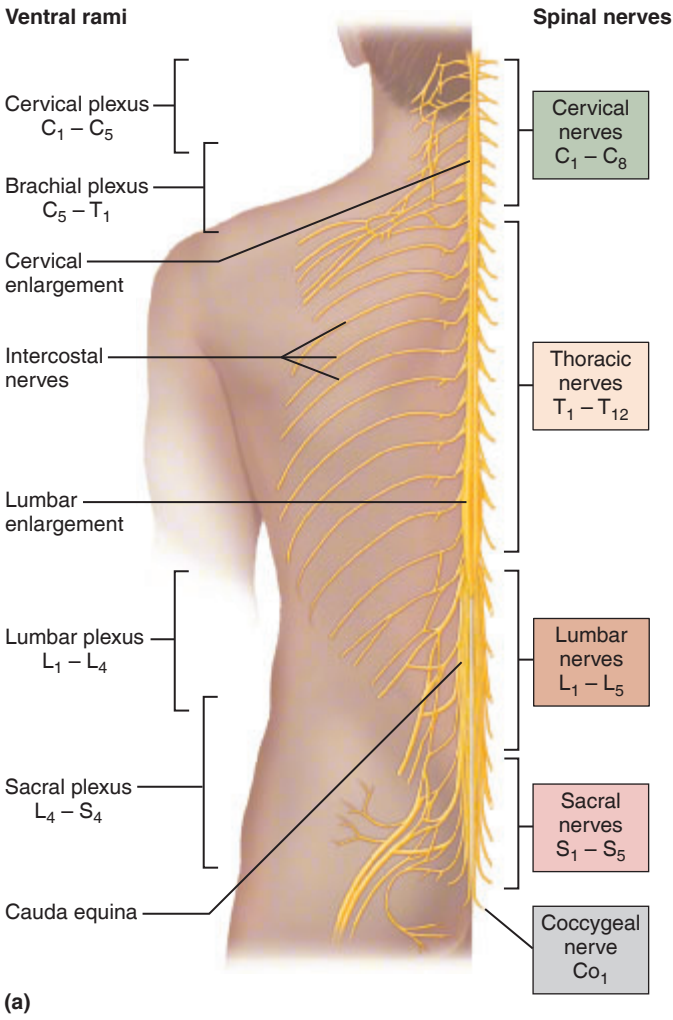


Figure 15.3 Cross section of the spinal cord. (See also Plate 9 in the Histology Atlas.)

Spinal Nerves and Nerve Plexuses

The nerves are named according to their point of issue (**Figure 15.4**). The first pair of spinal nerves leaves the vertebral canal between the base of the occipital bone and the atlas; the rest exit via the intervertebral foramina. The first through seventh pairs of cervical nerves emerge *above* the

vertebra for which they are named. C₈ emerges between C₇ and T₁. (Notice that there are 7 cervical vertebrae, but 8 pairs of cervical nerves.) The remaining spinal nerve pairs emerge from the spinal cord *below* the same-numbered vertebra.



(b)

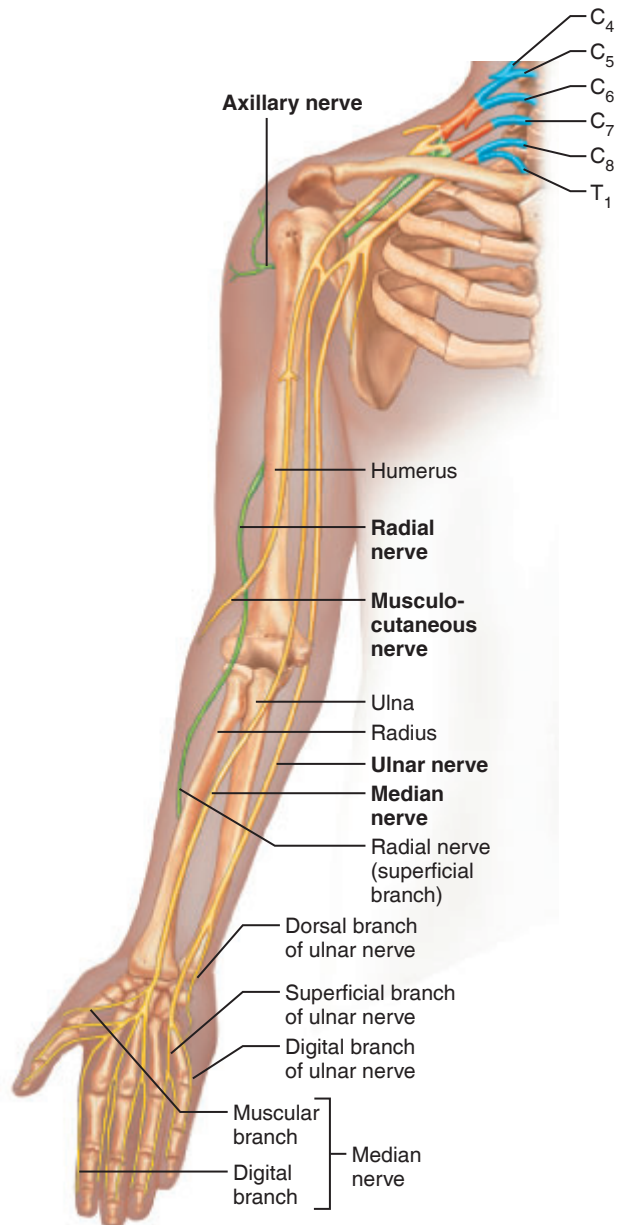


Figure 15.4 Human spinal nerves. (a) Spinal nerves are shown at right; ventral rami and the major nerve plexuses are shown at left. (b) Distribution of the ventral and dorsal rami of a spinal nerve (cross section of thorax).

Almost immediately after emerging, each nerve divides into **dorsal** and **ventral rami**. Thus, each spinal nerve is only about 1 cm (1/2 in.) long. The rami, like the spinal nerves, contain both motor and sensory fibers. The smaller dorsal rami serve the skin and muscles of the posterior body trunk. The ventral rami of spinal nerves T₂–T₁₂ pass anteriorly as the **intercostal nerves** to supply the muscles of intercostal spaces, and the skin and muscles of the anterior and lateral trunk. The ventral rami of all other spinal nerves form complex nerve networks called **plexuses**, which serve the motor and sensory needs of the limbs. From the plexuses the fibers diverge again to form peripheral nerves. The four major nerve plexuses and their chief peripheral nerves are described next (see also **Table 15.1**).

Figure 15.5 Distribution of the major peripheral nerves arising from the brachial plexus.

Table 15.1 Spinal Nerve Plexuses

Plexus	Ventral rami	Important nerves	Body areas served	Result of damage to plexus or its nerves
Cervical	C ₁ –C ₅	Phrenic	Diaphragm	Respiratory paralysis (and death if not treated promptly)
Brachial	C ₅ –C ₈ and T ₁	Axillary	Deltoid muscle of shoulder	Paralysis and atrophy of deltoid muscle
		Radial	Triceps and extensor muscles of the forearm	Wristdrop—inability to extend hand at wrist
		Median	Flexor muscles of forearm and some muscles of hand	Decreased ability to flex and abduct hand and flex and abduct thumb and index finger—therefore, inability to pick up small objects
		Musculocutaneous	Flexor muscles of arm	Decreased ability to flex forearm or arm
		Ulnar	Wrist and many hand muscles	Clawhand—inability to spread fingers apart
Lumbar	L ₁ –L ₄	Femoral (including lateral and anterior cutaneous branches)	Lower abdomen, buttocks, anterior thighs, and skin of anteromedial leg and thigh	Inability to extend leg and flex at the hip; loss of cutaneous sensation
		Obturator	Adductor muscles of medial thigh and small hip muscles; skin of medial thigh and hip joint	Inability to adduct thigh
Sacral	L ₄ –L ₅ and S ₁ –S ₄	Sciatic (largest nerve in body; splits to common fibular (peroneal) and tibial nerves)	Lower trunk and posterior surface of thigh (and leg)	Inability to extend at the hip and flex at the knee; sciatica
		• Common fibular (peroneal) (superficial and deep branches)	Lateral aspect of leg and foot	Footdrop—inability to dorsiflex foot
		• Tibial (including sural and plantar branches)	Posterior aspect of leg and foot	Inability to plantar flex and invert foot; shuffling gait
		Superior and inferior gluteal	Gluteus muscles of hip	Inability to extend at the hip (maximus) or abduct and medially rotate thigh (medius)

Cervical Plexus and the Neck

The **cervical plexus** (see Figure 15.4 and Table 15.1) arises from the ventral rami of C₁ through C₅ and supplies muscles of the shoulder and neck. The major motor branch of this plexus is the **phrenic nerve**, which arises from C₃–C₅ and passes into the thoracic cavity in front of the first rib to innervate the diaphragm. The primary danger of a broken neck is that the phrenic nerve may be severed, leading to paralysis of the diaphragm and cessation of breathing. A jingle to help you remember the rami (roots) forming the phrenic nerves is “C₃, C₄, C₅ keep the diaphragm alive.”

Brachial Plexus and the Upper Limb

The **brachial plexus**, arising from the ventral rami of C₅ through C₈, and T₁ (Figure 15.5 and Table 15.1), is subdivided into five major *peripheral nerves*.

The **axillary nerve**, serving the muscles and skin of the shoulder, has the most limited distribution. The large **radial nerve** passes down the posterolateral surface of the limb, supplying all the extensor muscles of the arm, forearm, and hand and the skin along its course. The **median nerve** passes down the anterior surface of the arm to supply most of the flexor muscles in the forearm and several muscles in the lateral part of the hand.

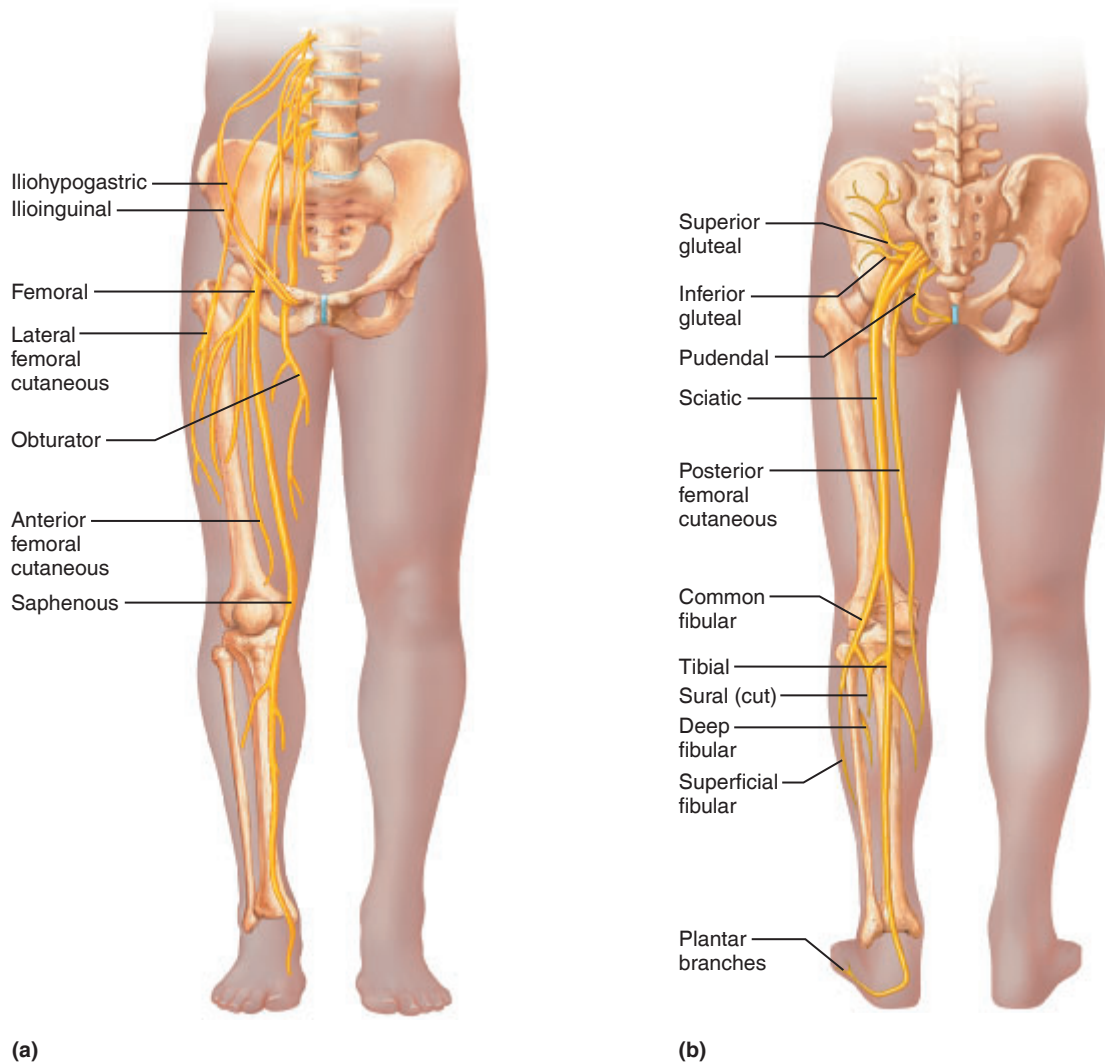


Figure 15.6 Distribution of the major peripheral nerves of the lower limb. (a) Lumbar plexus. (b) Sacral plexus.

□ Hyperextend at the wrist to identify the long, obvious tendon of your palmaris longus muscle, which crosses the exact midline of the anterior wrist. Your median nerve lies immediately deep to that tendon, and the radial nerve lies just *lateral* to it.

The **musculocutaneous nerve** supplies the arm muscles that flex the forearm and the skin of the lateral surface of the forearm. The **ulnar nerve**, which travels down the posteromedial surface of the arm, supplies the flexor carpi ulnaris and all intrinsic muscles of the hand not served by the median nerve.

Lumbar Plexus and the Lower Limb

The **lumbar plexus** arises from ventral rami of L₁ through L₄ (**Figure 15.6a**). Its nerves serve the lower abdominal region and the anteromedial thigh (Table 15.1). The largest nerve of this plexus is the **femoral nerve**, which innervates the anterior thigh muscles.

Sacral Plexus and the Lower Limb

Arising from L₄ through S₄, the nerves of the **sacral plexus** (**Figure 15.6b**) supply the buttock, the posterior thigh, and virtually all of the leg and foot (Table 15.1). The major peripheral nerve of this plexus is the **sciatic nerve**, the largest nerve in the body. The sciatic nerve travels through the greater sciatic notch and down the posterior thigh, serving its flexor muscles and skin. In the popliteal region, the sciatic nerve divides into the **common fibular nerve** and the **tibial nerve**, which together supply the balance of the leg and foot, both directly and via several branches.

Activity 2

Identifying the Major Nerve Plexuses and Peripheral Nerves

Identify each of the four major nerve plexuses and their major nerves on a large laboratory chart or model. Trace the courses of the nerves and relate those observations to the information provided in Table 15.1.

EXERCISE
15

REVIEW SHEET

Spinal Cord and Spinal Nerves

Name _____ Lab Time/Date _____

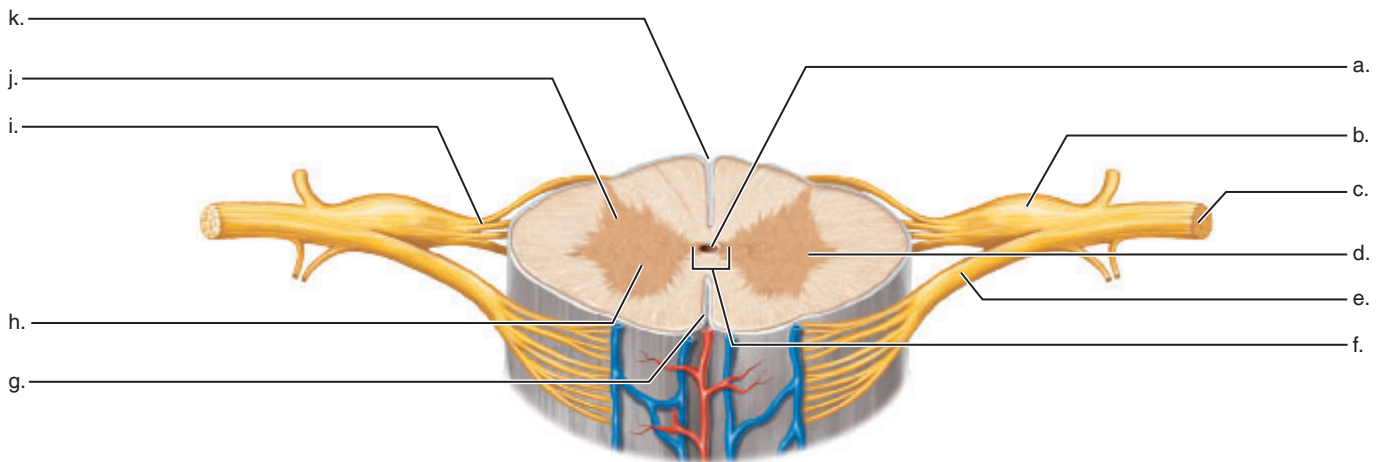
Anatomy of the Spinal Cord

1. Complete the following statements by inserting the proper anatomical terms in the answer blanks.

The superior boundary of the spinal cord is at the level of the _____, and its inferior boundary is at the level of vertebra _____. The collection of spinal nerves traveling in the vertebral canal below the terminus of the spinal cord is called the _____.

2. Match the key letters on the diagram with the following terms.

- | | |
|--------------------------------------|--|
| _____ 1. central canal | _____ 7. lateral horn |
| _____ 2. dorsal horn | _____ 8. spinal nerve |
| _____ 3. dorsal median sulcus | _____ 9. ventral horn |
| _____ 4. dorsal root ganglion | _____ 10. ventral median fissure |
| _____ 5. dorsal root of spinal nerve | _____ 11. ventral root of spinal nerve |
| _____ 6. gray commissure | |



3. The spinal cord is enlarged in two regions, the _____ and the _____ regions.

What is the significance of these enlargements? _____

Spinal Nerves and Nerve Plexuses

4. In the human, there are 31 pairs of spinal nerves named according to the region of the vertebral column from which they issue. The spinal nerves are named below. Note, by number, the vertebral level at which they emerge:

cervical nerves _____ sacral nerves _____

lumbar nerves _____ thoracic nerves _____

5. The ventral rami of spinal nerves C₁ through T₁ and T₁₂ through S₄ form _____, which serve the _____ of the body. The ventral rami of T₂ through T₁₂ run between the ribs to serve the _____.

6. What would happen (i.e., loss of sensory or motor function or both) if the following structures were damaged or transected?

1. dorsal root of a spinal nerve _____

2. ventral root of a spinal nerve _____

3. ventral ramus of a spinal nerve _____

7. Name the major nerves that serve the following body areas:

_____ 1. deltoid muscle

_____ 2. diaphragm

_____ 3. posterior thigh

_____ 4. lateral leg and foot


_____ 5. flexor muscles of forearm and some hand muscles


_____ 6. flexor muscles of arm

_____ 7. lower abdomen and anterior thigh

_____ 8. triceps muscle

_____ 9. posterior leg and foot

8.  After a person recovers from the chickenpox, the virus can lie dormant in the dorsal root ganglion in multiple levels of the spinal cord and cranial nerves. Later in life, the virus can be reactivated and travel within a sensory neuron to cause shingles. Do you think it is possible to get shingles more than once? _____ Why or why not?

9.  Wrist drop results in an inability to extend the hand at the wrist. Which nerve would most likely be affected in this injury, and why? _____

Human Reflex Physiology

Materials

- Reflex hammer
- Cot (if available)
- Absorbent cotton (sterile)
- Tongue depressor
- Metric ruler
- Flashlight
- Disposable autoclave bag
- Wash bottle containing 10% bleach solution

Learning Outcomes

- Define *reflex* and *reflex arc*.
- Identify and describe the function of each element of a reflex arc.
- Describe several types of reflex activity observed in the laboratory.

The Reflex Arc

Reflexes are rapid, predictable, involuntary motor responses to stimuli and they occur over neural pathways called **reflex arcs**.

Reflexes can be classed as either autonomic or somatic reflexes. **Autonomic** (visceral) **reflexes** are mediated through the autonomic nervous system. These reflexes activate smooth muscles, cardiac muscle, and glands. They regulate body functions such as digestion and blood pressure. **Somatic reflexes** include reflexes that stimulate skeletal muscles. An example of a somatic reflex is the rapid withdrawal of your foot from a piece of glass you have just stepped on.

Components of a Reflex Arc

Reflex arcs have a minimum of five functional elements (**Figure 16.1**):

1. The *receptor* is the site of the stimulus action.
2. The *sensory neuron* conducts afferent impulses to the CNS.
3. The *integration center* consists of one or more synapses in the CNS.
4. The *motor neuron* conducts efferent impulses from the integration center to an effector.

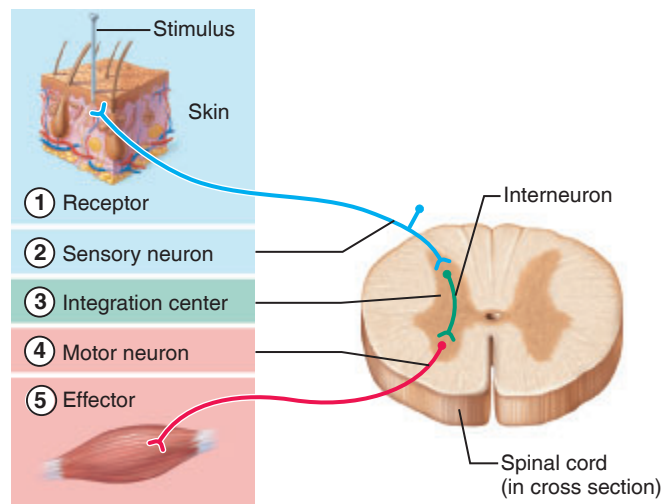


Figure 16.1 The five basic components of reflex arcs.

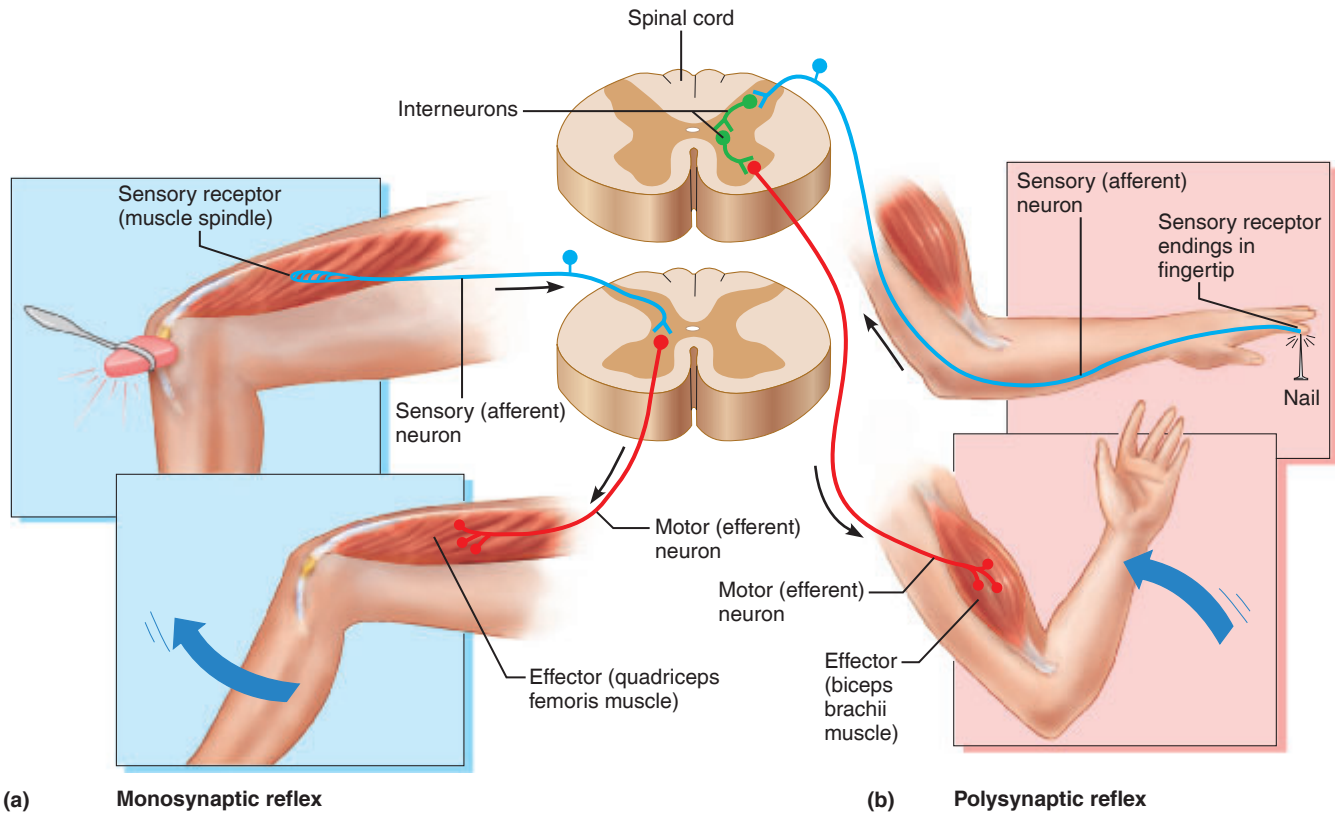


Figure 16.2 Monosynaptic and polysynaptic reflex arcs. The integration center is in the spinal cord, and in each example the receptor and effector are in the same limb. **(a)** The patellar reflex, a two-neuron monosynaptic reflex. **(b)** A flexor reflex, an example of a polysynaptic reflex.

5. The *effector*, a muscle fiber or a gland cell, responds to the efferent impulses by contracting or secreting a product, respectively.

The simple patellar, or knee-jerk, reflex is an example of a simple, two-neuron, *monosynaptic* (literally, “one syn-

apse”) reflex arc (**Figure 16.2a**). It will be demonstrated in the laboratory. However, most reflexes are more complex and are *polysynaptic*, involving one or more interneurons in the reflex arc pathway. For example, the flexor reflex is a three-neuron reflex arc (**Figure 16.2b**).

Somatic Reflexes

There are many types of somatic reflexes, including several that you will be observing during this laboratory session—the stretch, superficial, corneal, and gag reflexes. Some require only spinal cord activity; others involve the brain as well. Some somatic reflexes are mediated by cranial nerves.

Spinal Reflexes

Spinal reflexes are somatic reflexes that are mediated by the spinal cord.

Stretch Reflexes

Stretch reflexes are important for maintaining and adjusting muscle tone for posture, balance, and locomotion. Stretch reflexes are produced by tapping a tendon, which stretches the attached muscle. This stimulates muscle spindles (specialized sensory receptors in the muscle) and causes reflex contraction of the stretched muscle. As the stretch reflex is occurring, impulses are relayed to higher brain centers to advise of muscle length and speed of shortening—information needed to maintain muscle tone and posture.

Activity 1

Initiating Stretch Reflexes

1. To test the **patellar**, or knee-jerk, **reflex**, seat the person on the laboratory bench with legs hanging free (or with knees crossed). Tap the patellar ligament sharply with the broad side of the reflex hammer just below the knee to elicit the response. The knee-jerk reflex assesses the L₂–L₄ level of the spinal cord (**Figure 16.3**). Test both knees, and record your observations.

Which muscles contracted? _____

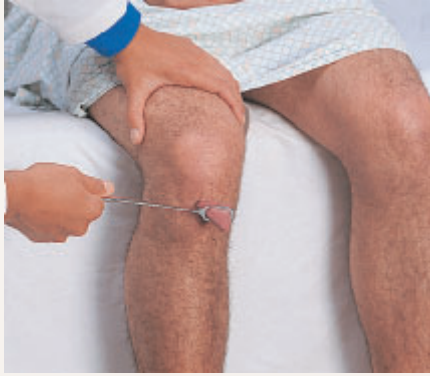

Figure 16.3 Testing the patellar reflex. The examiner supports the subject's knee so that the subject's muscles are relaxed, and then strikes the patellar ligament with the reflex hammer. The proper location may be ascertained by palpation of the patella.

What nerve is carrying the afferent and efferent impulses?

2. Fatigue influences the stretch reflex response. To demonstrate its effect, your partner should jog in position until the lower limbs are fatigued (*really fatigued*—no slackers). Test the patellar reflex again, and record whether it is more *or less* vigorous than the first response.

Would you say that nervous system activity or muscle function is responsible for the changes you have just observed?

3. The **calcaneal tendon**, or **ankle-jerk**, **reflex** assesses the first two sacral segments of the spinal cord. With your partner's shoe removed, use one hand to dorsiflex the foot to increase the tension of the gastrocnemius (calf) muscle, and sharply tap the calcaneal tendon with the broad side of the reflex hammer (**Figure 16.4**).

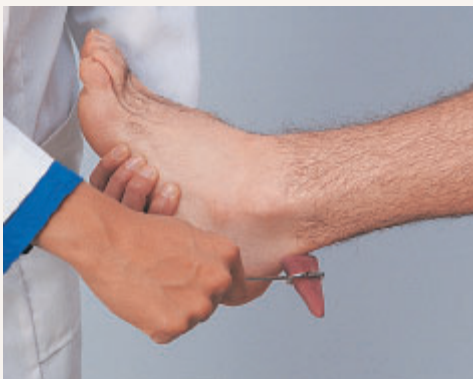

Figure 16.4 Testing the calcaneal tendon reflex. The examiner slightly dorsiflexes the subject's ankle by supporting the foot lightly in the hand, and then taps the calcaneal tendon just above the ankle.

What is the result? _____

During walking, what is the action of the gastrocnemius?

In the stretch reflexes that have been demonstrated so far, the reflex pathway is initiated and completed at the spinal cord level.

Superficial Reflexes

The **superficial reflexes** (abdominal and plantar reflexes) are initiated by stimulating receptors in the skin and mucosae. The superficial reflexes depend *both* on brain participation and on the spinal cord-level reflex arc. We will use the plantar reflex as our example.

The **plantar reflex**, an important neurological test, is elicited by stimulating the cutaneous receptors in the sole of the foot. In adults, stimulating these receptors causes the toes to flex and move closer together. Damage to the primary motor cortex or the corticospinal tract, however, produces *Babinski's sign*, an abnormal response in which the great toe moves upward and the smaller toes fan outward. In a newborn, Babinski's sign is normal because the nervous system is still incompletely myelinated.

Activity 2

Initiating the Plantar Reflex

Have your partner remove a shoe and lie on the cot or laboratory bench with knees slightly bent and thighs rotated so that the lateral side of the foot rests on the cot. Alternatively, the person may sit up and rest the lateral surface of the foot on a chair. Draw the handle of the reflex hammer firmly down the lateral side of the exposed sole from the heel to the base of the great toe (**Figure 16.5**).

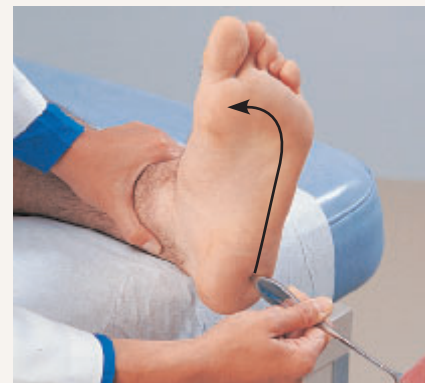

Figure 16.5 Testing the plantar reflex. Using a moderately sharp object, the examiner strokes the lateral border of the subject's sole, starting at the heel and continuing toward the big toe across the ball of the foot.

Text continues on next page. →

What is the response? _____

Is this a normal plantar reflex or Babinski's sign?

Cranial Nerve Reflexes

In these experiments, you will be working with your lab partner to illustrate two somatic reflexes mediated by cranial nerves. The first of these, the **corneal reflex**, is mediated through the trigeminal nerve (cranial nerve V). The absence of this reflex is an ominous sign because it often indicates damage to the brain stem. The second cranial nerve reflex you will test, the **gag reflex**, tests the motor responses of cranial nerves IX and X (glossopharyngeal and vagus nerves). When the oral mucosa on the side of the uvula is stroked, each side of the mucosa should rise to the same extent.

Activity 3

Initiating the Corneal Reflex

Stand to one side of the subject; your partner should look away from you toward the opposite wall. Wait a few seconds and then quickly, *but gently*, touch the person's

cornea (on the side toward you) with a wisp of absorbent cotton. What is the reaction?


What is the function of this reflex? _____

Was the sensation that of touch or of pain? _____

Activity 4

Initiating the Gag Reflex

For this experiment, select a subject who does not have a queasy stomach, because regurgitation is a possibility. Stroke the oral mucosa on each side of the subject's uvula (the fleshy tab hanging from the roof of the mouth) with a tongue depressor. What happens?

 Discard the used tongue depressor in the disposable autoclave bag before continuing. Do *not* lay it on the laboratory bench at any time.

16

Autonomic Reflexes

The autonomic reflexes include the pupillary reflexes as well as many others.

Pupillary Reflexes

There are several types of pupillary reflexes. We'll examine the **pupillary light reflex** and the **consensual reflex** here. In both of these reflexes, the retina of the eye is the receptor, the optic nerve contains the afferent fibers, the oculomotor nerve contains the efferent fibers, and the smooth muscle of the iris is the effector. Absence of the normal pupillary reflexes is generally a late indication of severe trauma or deterioration of the vital brain stem tissue.

Activity 5

Initiating Pupillary Reflexes

1. Conduct the reflex testing in an area where the lighting is relatively dim. Before beginning, obtain a flashlight and a metric ruler.
2. Measure and record the size of your partner's pupils as best you can. Note that it may be easier to measure the size of the pupil in an individual with light-colored eyes.

Right pupil: _____ mm

Left pupil: _____ mm

3. Stand to the left of the subject to conduct the testing. The person should shield the right eye by holding a hand vertically between the eye and the right side of the nose.
4. Using a quick right-to-left motion, shine a flashlight into the person's left eye. What is the pupillary response?

Measure the size of the left pupil: _____ mm

5. Observe the right pupil. Has the same type of change (called a *consensual reflex*) occurred in the right eye?

Measure the size of the right pupil: _____ mm

The consensual reflex, or any reflex observed on one side of the body when the *other* side has been stimulated, is called a **contralateral response**. The pupillary light reflex, or any reflex occurring on the same side stimulated, is referred to as an **ipsilateral response**.

What is the function of these pupillary reflexes?

EXERCISE
16

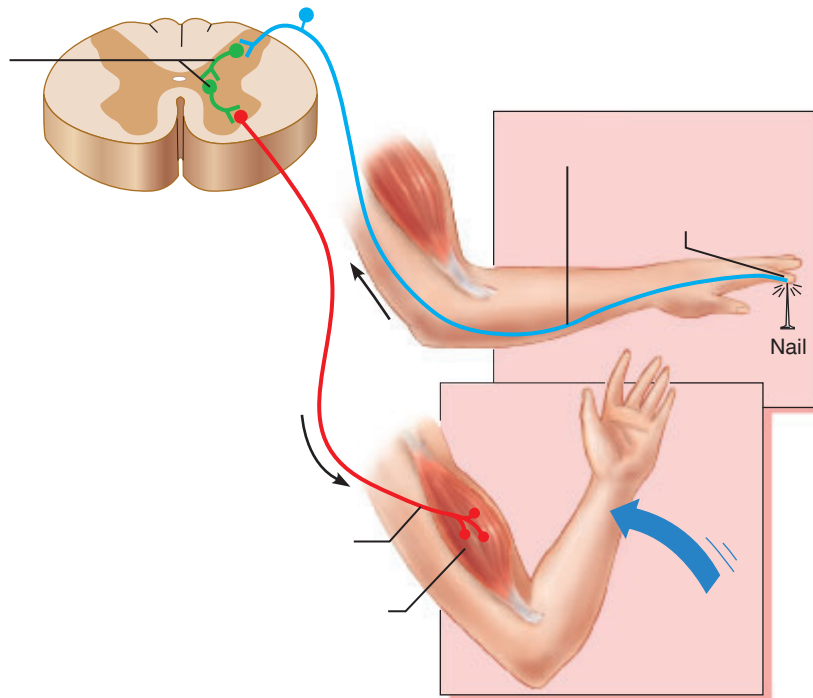
REVIEW SHEET

Human Reflex Physiology

Name _____ Lab Time/Date _____

The Reflex Arc

- Label the five components of a reflex arc using the leader lines in the figure below.



- In general, what is the importance of reflex testing in a routine physical examination? _____

Somatic and Autonomic Reflexes

- Use the key terms to complete the statements given below.

Key: calcaneal tendon reflex gag reflex plantar reflex
 corneal reflex patellar reflex pupillary light reflex

Reflexes classified as somatic reflexes include _____, _____, _____,
 and _____.

Of these, the simple stretch reflexes are _____ and _____, and the superficial reflex is _____.

A reflex classified as an autonomic reflex is the _____.

4. Name three spinal cord-mediated reflexes: _____, _____, and _____

Name two somatic reflexes that are mediated by cranial nerves: _____ and _____

5. Trace the reflex arc, naming efferent and afferent nerves, receptors, effectors, and integration centers, for the following reflexes:

patellar reflex _____

calcaneal tendon reflex _____


6. What was the effect of muscle fatigue on your ability to produce the patellar reflex?

7. The pupillary light reflex and the corneal reflex illustrate the purposeful nature of reflex activity. Describe the protective aspect of each:

pupillary light reflex _____
corneal reflex _____

8. Was the pupillary consensual reflex a contralateral or ipsilateral response? _____
Why would such a response be of significant value in this particular reflex? _____

9. Differentiate between the types of effectors and activities accomplished by somatic and by autonomic reflexes. _____

10.  Hyporeflexia occurs when normal reflexes are weak but not absent. Explain how this condition could be due to damage to skeletal muscle, a sensory neuron, or a motor neuron. _____

The Special Senses

Materials

For Vision

- Dissectible eye model
- Chart of eye anatomy
- Preserved cow or sheep eye
- Dissecting tray and instruments
- Disposable gloves
- Metric ruler
- Common straight pins
- Snellen eye chart (floor marked to indicate 20-ft distance from posted Snellen chart)
- Ishihara's color-blindness plates

For Hearing and Equilibrium

- Three-dimensional dissectible ear model and/or chart of ear anatomy
- Otoscope (if available)
- Alcohol swabs
- Prepared microscope slide of cochlea
- Absorbent cotton
- Pocket watch or clock that ticks
- 12-inch ruler
- Tuning forks (range of frequencies)
- Rubber mallet
- Demonstration area:
Cochlea slide set up under a compound microscope for student observation

For Smell and Taste

- Small mirror
- Paper towels
- Granulated sugar
- Cotton-tipped swabs
- Disposable autoclave bag
- Paper cups; paper plates
- Beaker containing 10% bleach solution
- Prepared dropper bottles of oil of cloves, oil of peppermint, and oil of wintergreen or corresponding flavorings found in the condiment section of a supermarket
- Equal-sized cubes of foods, such as cheese, apple, dried prunes, banana, and hard-cooked egg white (in an opaque container, such as a foil-lined egg carton)
- Chipped ice
- Absorbent cotton

Learning Outcomes

- Describe the structure and function of the accessory visual structures.
- Identify the internal structures of the eye when provided with a model, diagram, or preserved animal eye, and list the functions of each.
- Define *blind spot*, *refraction*, *hyperopia*, *myopia*, and *astigmatism*, and discuss image formation on the retina.
- Discuss the importance of the accommodation and convergence reflexes.
- Identify the structures of the external, middle, and internal ear by correctly labeling a diagram.
- Describe the anatomy of the spiral organ and explain its role in hearing.
- Describe how one is able to localize sounds and to differentiate sensorineural from conduction deafness.
- Describe the anatomy of the equilibrium organs of the internal ear, and explain their relative roles in maintaining equilibrium.
- State the purpose of the Romberg test, and describe the role of vision in maintaining equilibrium.
- Describe the location, structure, and function of the olfactory and taste receptors.
- List several factors that influence taste.

In contrast to the small and widely distributed general receptors (touch, temperature, pressure, and pain), the **special sense receptors** are large, complex sensory organs (eyes and ears) or localized clusters of receptors (taste buds and olfactory epithelium). This chapter focuses on the functional anatomy of each of the special sense organs individually, but keep in mind that sensory inputs are overlapping.

Anatomy of the Eye

Accessory Structures

The adult human eye is a sphere some 2.5 cm (1 inch) in diameter. Only about one-sixth of the eye's anterior surface is observable (**Figure 17.1**); the remainder is protected by a cushion of fat and the walls of the bony orbit. The accessory structures of the eye include the eyebrows, eyelids, conjunctivae, lacrimal apparatus, and extrinsic eye muscles (**Table 17.1**, **Figure 17.1** and **Figure 17.2**).

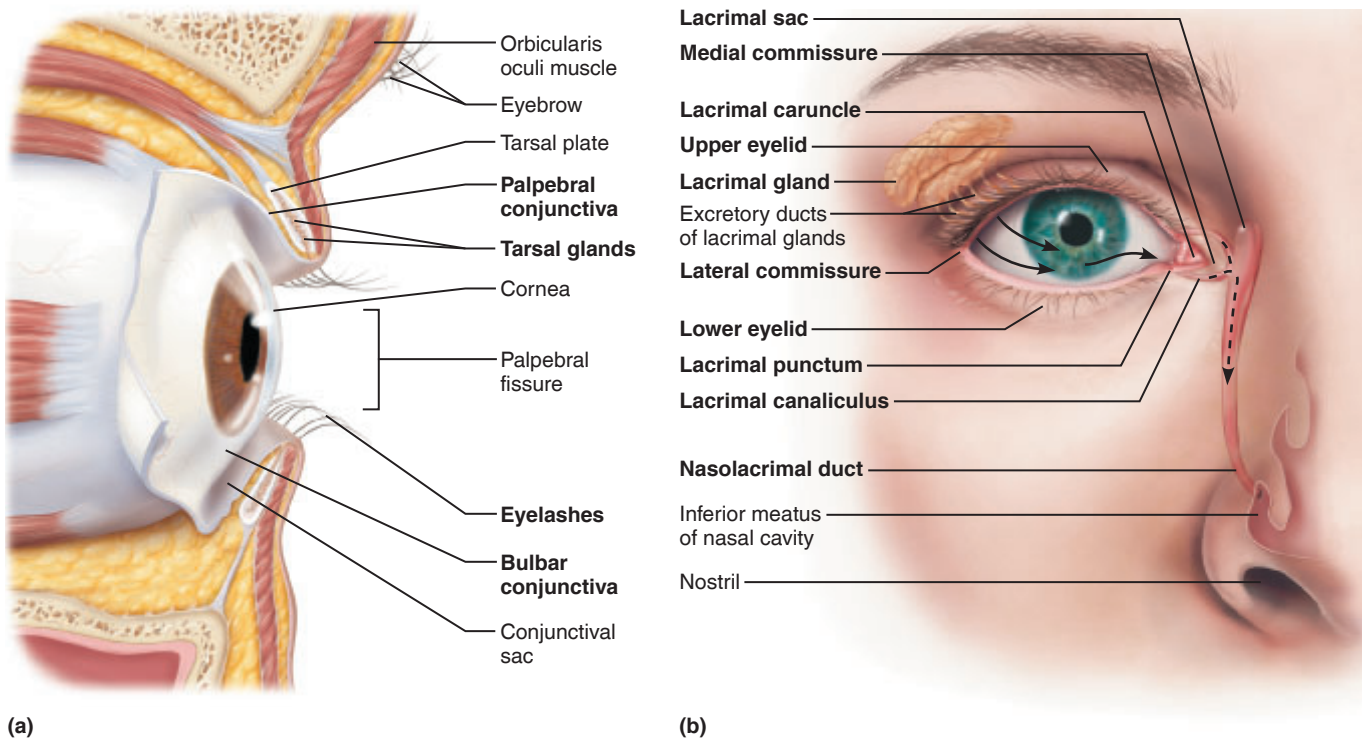
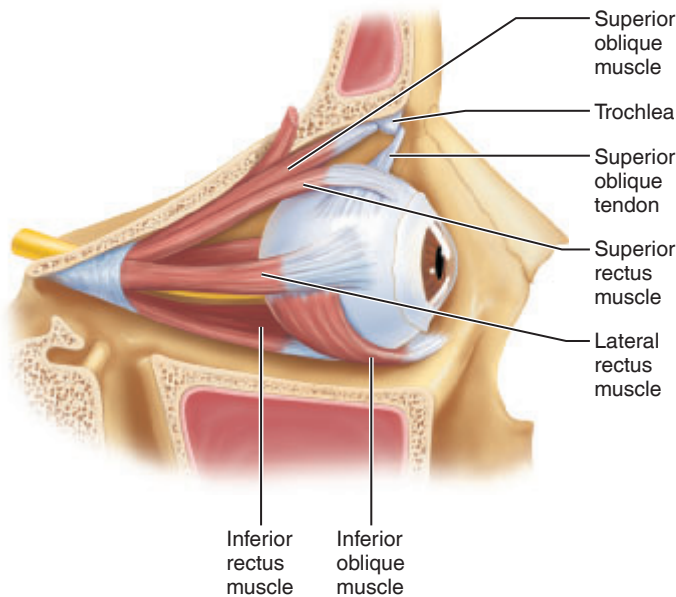


Figure 17.1 The eye and accessory structures. (a) Lateral view. (b) Anterior view with lacrimal apparatus. Arrows indicate the flow of lacrimal fluid.

Table 17.1 Accessory Structures of the Eye (Figures 17.1 and 17.2)

Structure	Description	Function
Eyebrows	Short hairs located on the supraorbital margins	Shade and prevent sweat from entering the eyes.
Eyelids (palpebrae)	Skin-covered upper and lower lids, with eyelashes projecting from their free margin	Protect the eyes and spread lacrimal fluid (tears) with blinking.
Tarsal glands	Modified sebaceous glands embedded in the tarsal plate of the eyelid	Secrete an oily secretion that lubricates the surface of the eye.
Ciliary glands	Typical sebaceous and modified sweat glands that lie between the eyelash follicles	Secrete an oily secretion that lubricates the surface of the eye and the eyelashes. An infection of a ciliary gland is called a sty.
Conjunctivae	A clear mucous membrane that lines the eyelids (palpebral conjunctivae) and lines the anterior white of the eye (bulbar conjunctiva)	Secrete mucus to lubricate the eye. Inflammation of the conjunctiva results in conjunctivitis, (commonly called “pinkeye”).
Medial and lateral commissures	Junctions where the eyelids meet medially and laterally	Form the corners of the eyes. The medial commissure contains the lacrimal caruncle.
Lacrimal caruncle	Fleshy reddish elevation that contains sebaceous and sweat glands	Secretes a whitish oily secretion for lubrication of the eye (can dry and form “eye sand”).
Lacrimal apparatus	Includes the lacrimal gland and a series of ducts that drain the lacrimal fluid into the nasal cavity	Protects the eye by keeping it moist. Blinking spreads the lacrimal fluid.
Lacrimal gland	Located in the superior and lateral aspect of the orbit of the eye	Secretes lacrimal fluid, which contains mucus, antibodies, and lysozyme.
Lacrimal puncta	Two tiny openings on the medial margin of each eyelid	Allow lacrimal fluid to drain into the superior and inferiorly located lacrimal canaliculi.
Lacrimal canaliculi	Two tiny canals that are located in the eyelids	Allow lacrimal fluid to drain into the lacrimal sac.
Lacrimal sac	A single pouch located in the medial orbital wall	Allows lacrimal fluid to drain into the nasolacrimal duct.
Nasolacrimal duct	A single tube that empties into the nasal cavity	Allows lacrimal fluid to flow into the nasal cavity.
Extrinsic eye muscles	Six muscles for each eye; four recti and two oblique muscles (see Figure 17.2)	Control the movement of each eyeball and hold the eyes in the orbits.



(a)

Muscle	Action
Lateral rectus	Moves eye laterally
Medial rectus	Moves eye medially
Superior rectus	Elevates eye and turns it medially
Inferior rectus	Depresses eye and turns it medially
Inferior oblique	Elevates eye and turns it laterally
Superior oblique	Depresses eye and turns it laterally

(b)

Figure 17.2 Extrinsic muscles of the eye. (a) Lateral view of the right eye. (b) Summary of actions of the extrinsic eye muscles.

Activity 1

Identifying Accessory Eye Structures

Observe the eyes of another student, and identify as many accessory structures as possible. Ask the student to look to the left. Which extrinsic eye muscles produce this action?

Right eye _____

Left eye _____

Internal Anatomy of the Eye

Anatomically, the wall of the eye is constructed of three layers: the **fibrous layer**, the **vascular layer**, and the **inner layer (retina)**.

Distribution of Photoreceptors

The retina consists of two layers; an outer **pigmented layer** and an inner **neural layer**. The inner neural layer is composed of three major populations of neurons. There are, from outer to inner aspect, the **photoreceptors** (rods and cones), the **bipolar cells**, and the **ganglion cells** (Figure 17.3). The **rods** are the specialized photoreceptors for dim light. The **cones** are color photoreceptors that permit high levels of visual acuity, but they only function under conditions of high light intensity. The photoreceptor cells are distributed over most of the neural retina, except where the optic nerve (the bundled axons of the ganglion cells) leaves the eyeball. This site is called the **optic disc**, or **blind spot** (see Figure 17.4). Lateral to each blind spot is the **macula lutea** (yellow spot), an area of high cone density. In its center is the **fovea centralis**, a tiny pit that contains only cones and is the area of greatest visual acuity. Focusing for detailed color vision occurs in the fovea centralis.

Internal Chambers and Fluids

The lens divides the eye into two segments: the **anterior segment** anterior to the lens, which contains a clear, watery fluid called the **aqueous humor** and the **posterior segment** behind the lens, filled with the gel-like **vitreous humor**. The aqueous humor is continually formed by the capillaries of the **ciliary process**. It helps to maintain the intraocular pressure of the eye and provides nutrients for the avascular lens and cornea. Aqueous humor is drained into the **scleral venous sinus**, a drainage duct located at the junction of the sclera and cornea. The vitreous humor reinforces the posterior part of the eyeball, and helps to keep the retina pressed firmly against the wall of the eyeball.

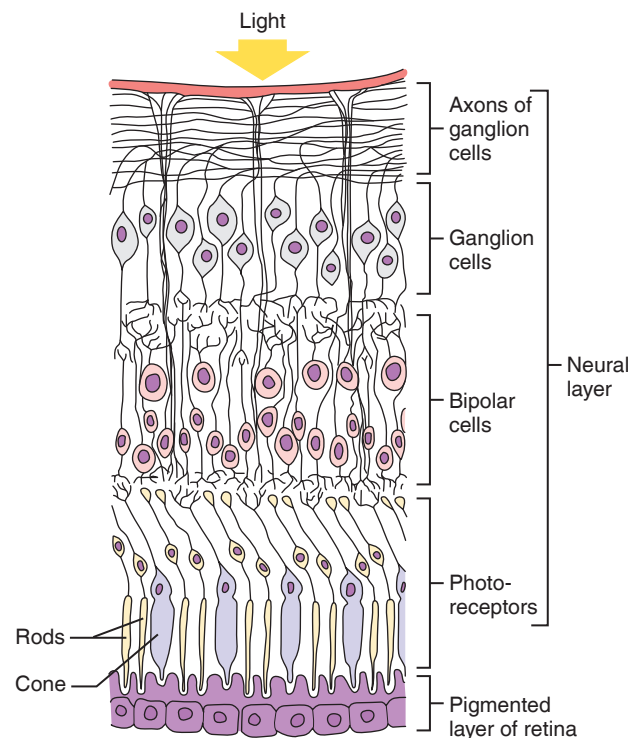
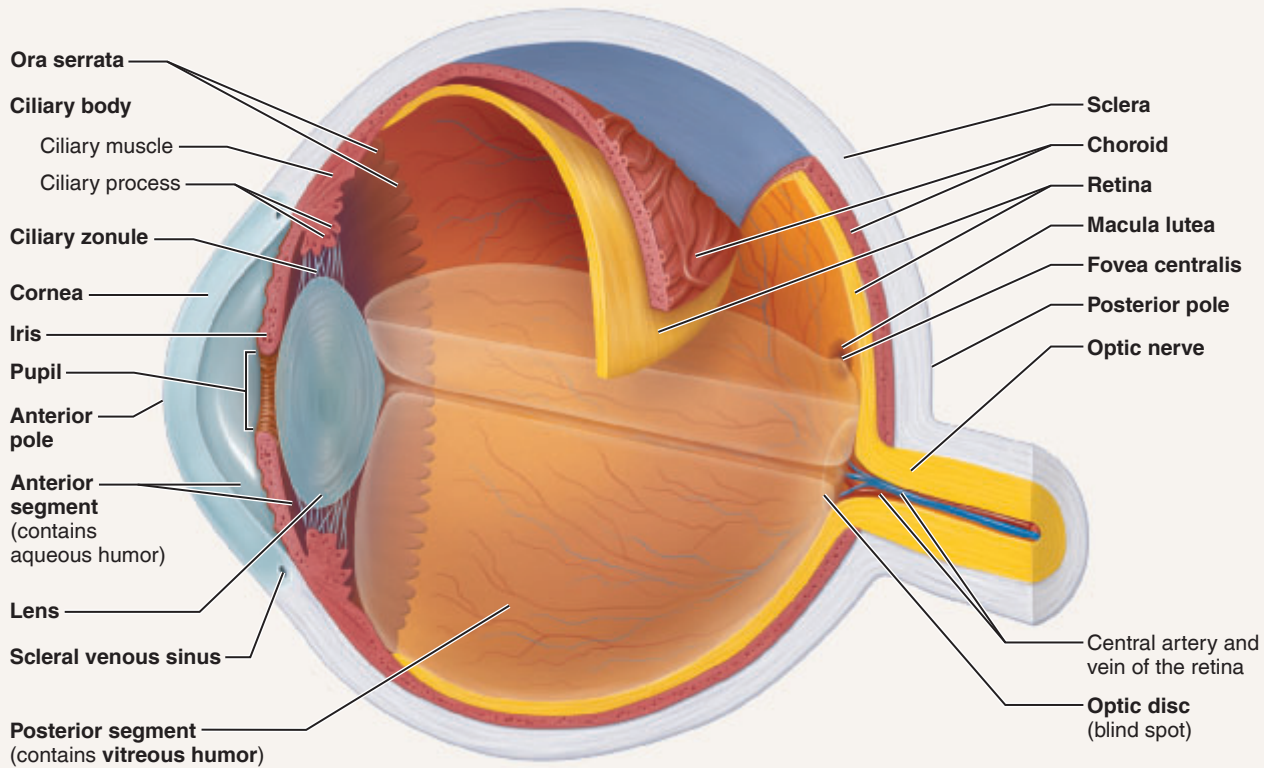


Figure 17.3 Microscopic anatomy of the retina. (See also Plate 15 in the Histology Atlas.)

Activity 2

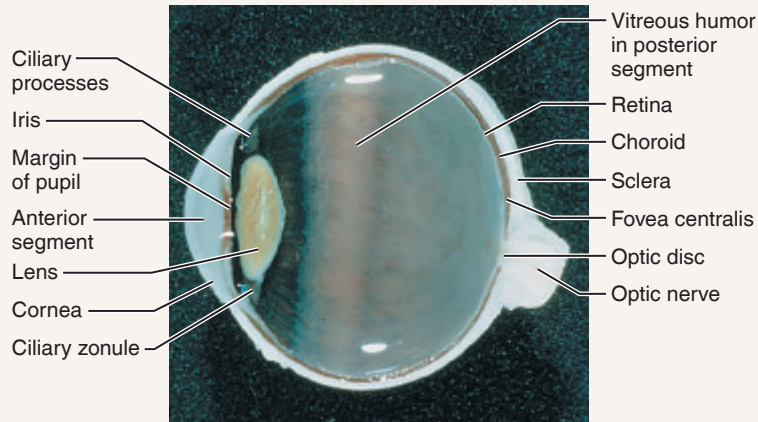
Identifying Internal Structures of the Eye

Obtain a dissectible eye model or observe a chart of eye anatomy to identify the structures described below. As you work, refer to **Figure 17.4** and **Table 17.2.**)

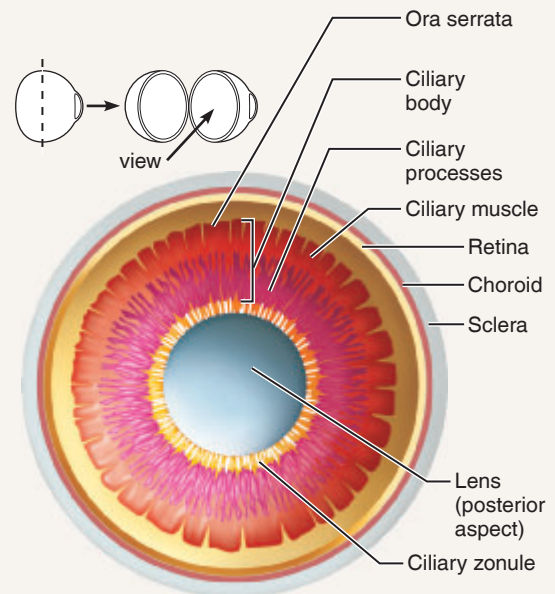


(a) Diagram of sagittal section of the eye. The vitreous humor is illustrated only in the bottom half of the eyeball.

17



(b) Photograph of the human eye.



(c) Posterior view of anterior half of the eye.

Figure 17.4 Internal anatomy of the right eye.

Table 17.2 Layers of the Eye (Figure 17.4)

Structure	Description	Function
Fibrous Layer (External Layer)		
Sclera	Opaque white connective tissue that forms the “white of the eye.”	Helps to maintain the shape of the eyeball and provides an attachment point for the extrinsic eye muscles.
Cornea	Structurally continuous with the sclera; modified to form a transparent layer that bulges anteriorly; contains no blood vessels.	Forms a clear window that is the major light bending (refracting) medium of the eye.
Vascular Layer (Middle Layer)		
Choroid	A blood vessel–rich, dark membrane.	The blood vessels nourish the other layers of the eye, and the melanin helps to absorb excess light.
Ciliary body	Modification of the choroid that encircles the lens.	Contains the ciliary muscle and the ciliary process.
Ciliary muscle	Smooth muscle found within the ciliary body.	Alters the shape of the lens with contraction and relaxation.
Ciliary process	Radiating folds of the ciliary muscle.	Capillaries of the ciliary process form the aqueous humor by filtering plasma.
Ciliary zonule (Suspensory ligament)	A halo of fine fibers that extends from the ciliary process around the lens.	Attaches the lens to the ciliary process.
Iris	The anterior portion of the vascular layer that is pigmented. It contains two layers of smooth muscle (sphincter pupillae and dilator pupillae).	Controls the amount of light entering the eye by changing the size of the pupil diameter.
Pupil	The round central opening of the iris.	Allows light to enter the eye.
Inner Layer (Retina)		
Pigmented layer of the retina	The outer layer that is composed of only a single layer of pigment cells (melanocytes).	Absorbs light and prevents it from scattering in the eye. Pigment cells act as phagocytes for cleaning up cell debris.
Neural layer of the retina	The thicker inner layer composed of three main types of neurons: photoreceptors (rods and cones), bipolar cells, and ganglion cells.	Photoreceptors respond to light and convert the light energy into action potentials that travel to the primary visual cortex of the brain.



DISSECTION

The Cow (Sheep) Eye

1. Obtain a preserved cow or sheep eye, dissecting instruments, and a dissecting tray. Put on disposable gloves.
2. Examine the external surface of the eye, noticing the thick cushion of adipose tissue. Identify the optic nerve as it leaves the eyeball, the cut remnants of the extrinsic eye muscles, the conjunctiva, the sclera, and the cornea. Refer to **Figure 17.5** as you work.
3. Trim away most of the fat and connective tissue, but leave the optic nerve intact. Holding the eye with the cornea facing downward, carefully make an incision with a sharp scalpel into the sclera, about $\frac{1}{4}$ inch above the cornea. Using scissors, cut around the circumference of the eyeball, paralleling the corneal edge.
4. Carefully lift the anterior part of the eyeball away from the posterior portion. Move some of the vitreous humor aside to view the following:

Pigmented choroid coat: Appears iridescent in the cow or sheep eye because of a modification, the **tapetum lucidum**. This specialized surface reflects the light within the eye and is found in the eyes of animals that live under conditions of dim light. It is not found in humans.

5. Examine the anterior part of the eye, and identify the following structures:

Ciliary body: Black, pigmented body that appears in a halo encircling the lens.

Lens: Biconvex structure that is opaque in preserved specimens.

Ciliary zonule: A halo of delicate fibers attaching the lens to the ciliary body.

Carefully remove the lens and identify the adjacent structures:

Iris: Anterior continuation of the ciliary body penetrated by the pupil.

Cornea: More convex anteriormost portion of the sclera; normally transparent but cloudy in preserved specimens.

6. Examine the posterior portion of the eyeball. Remove the vitreous humor, and identify the following structure:

Retina: Appears as a delicate tan membrane that separates easily from the choroid.

Notice its posterior point of attachment. What is this point called?

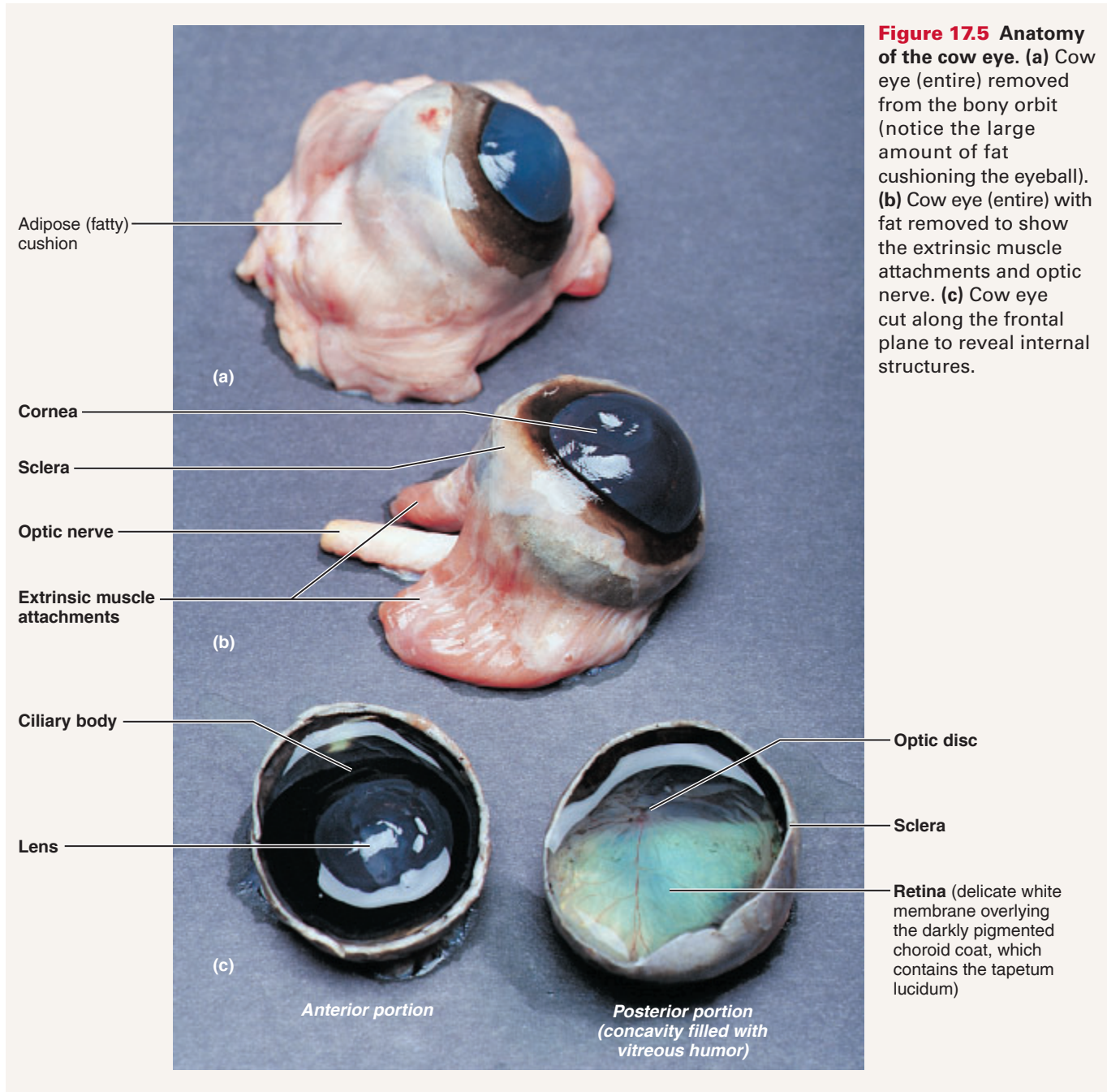


Figure 17.5 Anatomy of the cow eye. (a) Cow eye (entire) removed from the bony orbit (notice the large amount of fat cushioning the eyeball). (b) Cow eye (entire) with fat removed to show the extrinsic muscle attachments and optic nerve. (c) Cow eye cut along the frontal plane to reveal internal structures.

Visual Tests and Experiments

Activity 3

Demonstrating the Blind Spot

1. Hold the blind spot test figure (**Figure 17.6**) about 18 inches (46 cm) from your eyes. Close your left eye, and focus your right eye on the X, which should be positioned so that it is directly in line with your right eye. Move the figure slowly toward your face, keeping your right eye focused on the X. When the dot focuses on the blind spot, which lacks photoreceptors, it will disappear.

2. Have your laboratory partner record in centimeters the distance at which this occurs. The dot will reappear as the figure is moved closer. Distance at which the dot disappears:

Right eye _____

Repeat the test for the left eye. This time, close the right eye and focus the left eye, on the dot. Record the distance at which the X disappears:

Left eye _____



Figure 17.6 Blind spot test figure.

Refraction, Visual Acuity, and Astigmatism

When light rays pass from one substance to another, their speed changes, and the rays are bent, or **refracted**. Thus, the light rays are refracted as they encounter the cornea, aqueous humor, lens, and vitreous humor of the eye.

The bending power of the cornea, aqueous humor, and vitreous humor is constant. But the lens's refractive strength can be varied by changing its shape. The greater the lens convexity, or bulge, the more the light will be bent.

In general, light from a distant source (over 20 feet) approaches the eye as parallel rays, and no change in lens shape is necessary for it to focus properly on the retina. However, light from a close source tends to diverge, and the convexity of the lens must increase to make close vision possible. To achieve this, the ciliary muscle contracts, decreasing the tension of the ciliary zonule attached to the lens and allowing the elastic lens to “round up.” The ability of the eye to focus differentially for close objects (less than 20 feet) is called **accommodation**. The image formed on the retina as a result of the light-bending activity of the lens (**Figure 17.7**) is a **real image** (reversed from left to right, inverted, and smaller than the object).

The normal, **emmetropic**, eye is able to accommodate properly. However, visual problems may result from (1) lenses that are too strong or too “lazy” (overconverging and underconverging, respectively); (2) structural problems, such as an eyeball that is too long or too short; or (3) a cornea or lens with improper curvatures.

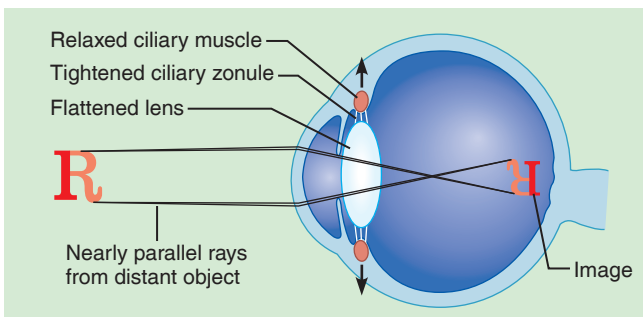


Figure 17.7 Refraction of light in the eye, resulting in the production of a real image on the retina.

Individuals in whom the image normally focuses in front of the retina have **myopia**, or “nearsightedness”; they can see close objects without difficulty, but distant objects are blurred or indistinct. Correction requires a concave lens, which causes the light reaching the eye to diverge.

If the image focuses behind the retina, the individual has **hyperopia**, or farsightedness. Such persons have no problems with distant vision but need glasses with convex lenses to boost the converging power of the lens for close vision.

Irregularities in the curvatures of the lens and/or the cornea lead to a blurred vision problem called **astigmatism**. Cylindrically ground lenses are prescribed to correct the condition.

The elasticity of the lens decreases dramatically with age, resulting in difficulty in focusing for near or close vision, especially when the person is reading. This condition is called **presbyopia**—literally, “old vision.” Lens elasticity can be tested by measuring the **near point of vision**.

Activity 4

Determining Near Point of Vision

To determine your near point of vision, hold a common straight pin (or other object) at arm’s length in front of one eye. Slowly move the pin toward that eye until the pin image becomes distorted. Have your lab partner use the metric ruler to measure the distance from your eye to the pin at this point, and record the distance. Repeat the procedure for the other eye.

Near point for right eye _____

Near point for left eye _____

Visual acuity, or sharpness of vision, is generally tested with a Snellen eye chart. The distance at which the normal eye can read a line of letters is printed at the end of that line.

Activity 5

Testing Visual Acuity

1. Have your partner stand 20 feet from the posted Snellen eye chart and cover one eye with a card or hand. As your partner reads each consecutive line aloud, check for accuracy. If this individual wears glasses, give the test twice—first with glasses off and then with glasses on. *Do not remove contact lenses, but note that they were in place during the test.*

2. Record the number of the line with the smallest-sized letters read. If it is 20/20, the person’s vision for that eye is normal. If it is 20/40, or any ratio with a value less than one, he or she has less than the normal visual acuity. (Such an individual is myopic, so a person with 20/40 vision is seeing objects clearly at 20 feet that a person with normal vision sees clearly at 40 feet.) If the visual acuity ratio is greater than 1, vision is better than normal. Give your partner the number of the line corresponding to the smallest letters read, to record in step 4.

3. Repeat the process for the other eye.

Text continues on next page. →

4. Have your partner test and record your visual acuity. If you wear glasses, the test results *without* glasses should be recorded first.

Visual acuity, right eye _____

Visual acuity, left eye _____

Activity 6

Testing for Astigmatism

The astigmatism chart (**Figure 17.8**) tests for defects in the refracting surface of the lens and/or cornea.

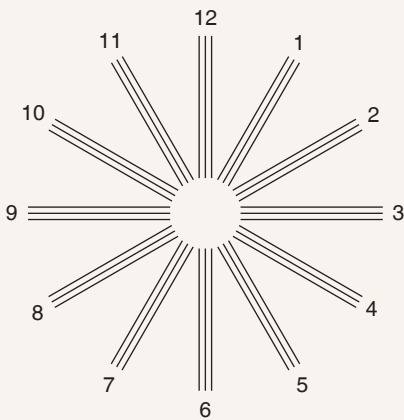


Figure 17.8 Astigmatism testing chart.

View the chart first with one eye and then with the other, focusing on the center of the chart. If all the radiating lines appear equally dark and distinct, your refracting surfaces are not distorted. If some of the lines are blurred or appear less dark than others, you have at least some degree of astigmatism.

Is astigmatism present in your left eye? _____

Right eye? _____

Color Blindness

Ishihara's color-blindness plates are designed to test for deficiencies in the color photoreceptor cells, the cones. There are three cone types—one type primarily absorbs the red wavelengths of visible light, another the blue wavelengths, and a third the green wavelengths. Nerve impulses reaching the brain from these different photoreceptor types are then interpreted (seen) as red, blue, and green, respectively. The intermediate colors of the visible light spectrum are interpreted as a result of simultaneous input from more than one cone type.

Activity 7

Testing for Color Blindness

1. View the color plates in bright light or sunlight while holding them about 30 inches (0.8 m) away and at right angles to your line of vision. Report to your laboratory partner what you see in each plate. Take no more than 3 seconds for each decision.

2. Your partner is to write down your responses and then check their accuracy with the correct answers provided in the color plate book. Is there any indication that you have some degree of color blindness?

_____ If so, what type? _____

Repeat the procedure to test your partner's color vision.

Eye Reflexes

Both intrinsic (internal) and extrinsic (external) muscles are necessary for proper eye function. The intrinsic muscles, controlled by the autonomic nervous system, are those of the ciliary body (which alters the lens curvature) and the sphincter pupillae and dilator pupillae muscles of the iris (which control pupil size and thus regulate the amount of light entering the eye). The extrinsic muscles are the rectus and oblique muscles, which are attached to the outside of the eyeball (see Figure 17.2). These muscles control eye movement and make it possible to keep moving objects focused on the fovea centralis. They are also responsible for **convergence**, or medial eye movements, which is essential for near vision. When convergence occurs, both eyes are aimed at the near object viewed. The extrinsic eye muscles are controlled by the somatic nervous system.

Activity 8

Demonstrating Reflex Activity of Intrinsic and Extrinsic Eye Muscles

Activity of both the intrinsic and extrinsic muscle types is brought about by reflex actions that can be observed with simple experiments. The *convergence reflex* mediated by the extrinsic eye muscles and the *accommodation reflex* mediated by the intrinsic eye muscles are described here.

Accommodation Pupillary Reflex

Have your partner gaze for approximately 1 minute at a distant object in the lab—*not* toward the windows or another light source. Observe your partner's pupils. Then hold some printed material 6 to 10 inches from his or her face, and ask your partner to focus on it.

How does pupil size change as your partner focuses on the printed material?

Convergence Reflex

Repeat the previous experiment, this time noting the position of your partner's eyeballs both while he or she is gazing at the distant object and then at the close object

(a pen or pencil). Do they change position as the object of focus is changed?

In what way? _____

The Ear and Hearing and Balance

Gross Anatomy of the Ear

The ear, which contains sensory receptors for hearing and equilibrium, is divided into three major areas: the *external ear*, the *middle ear*, and the *internal ear* (Figure 17.9). The external and middle ear structures serve the needs of the sense of hearing *only*, whereas internal ear structures function both in equilibrium and hearing.

Activity 9

Identifying Structures of the Ear

Obtain a dissectible ear model, and identify the structures summarized in Table 17.3.

Text continues on next page. →

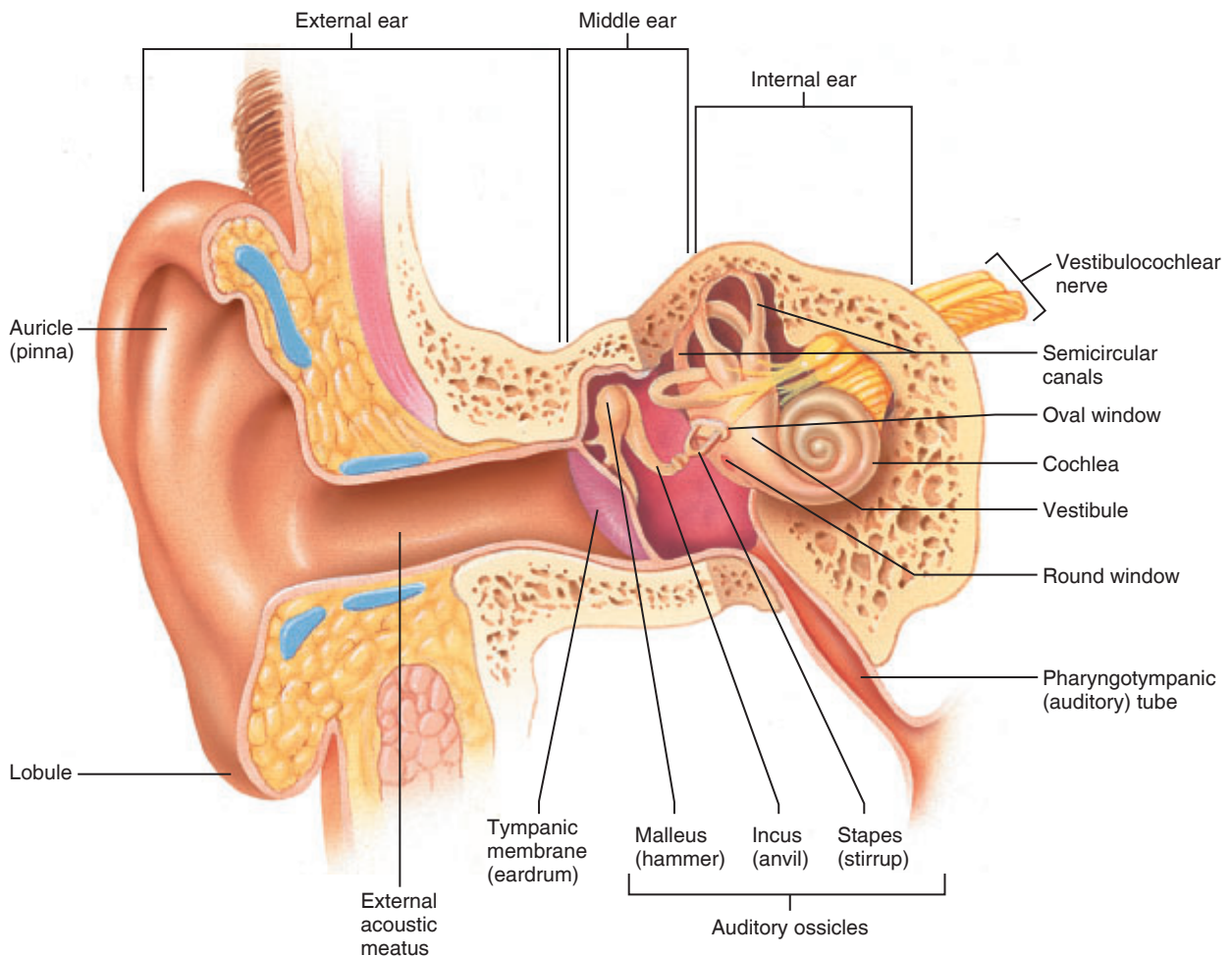



Figure 17.9 Anatomy of the ear.

Table 17.3 Structures of the External, Middle, and Internal Ear (Figure 17.9)

External Ear			
Structure	Description	Function	
Auricle (pinna)	Elastic cartilage covered with skin	Collects and directs sound waves into the external acoustic meatus	
Lobule (“earlobe”)	Portion of the auricle that is inferior to the external acoustic meatus	Completes the formation of the auricle	
External acoustic meatus	Short, narrow canal carved into the temporal bone; lined with ceruminous glands	Transmits sound waves from the auricle to the tympanic membrane	
Tympanic membrane (eardrum)	Thin membrane that separates the external ear from the middle ear	Vibrates at exactly the same frequency as the sound wave(s) hitting it and transmits vibrations to the auditory ossicles	
Middle Ear			
	A small air-filled chamber—the tympanic cavity	Contains the auditory ossicles (malleus, incus, and stapes)	
Structure	Description	Function	
Malleus (hammer)	Tiny bone shaped like a hammer; its “handle” is attached to the eardrum	Transmits and amplifies vibrations from the tympanic membrane to the incus	
Incus (anvil)	Tiny bone shaped like an anvil that articulates with the malleus and the stapes	Transmits and amplifies vibrations from the malleus to the stapes	
Stapes (stirrup)	Tiny bone shaped like a stirrup; its “base” fits into the oval window	Transmits and amplifies vibrations from the incus to the oval window	
Oval window	Oval-shaped membrane located deep to the stapes	Transmits vibrations from the stapes to the perilymph of the scala vestibuli	
Pharyngotympanic (auditory) tube	A tube that connects the middle ear to the superior portion of the pharynx (throat)	Equalizes the pressure in the middle ear cavity with the external air pressure so that the tympanic membrane can vibrate properly	
Internal Ear			
Bony labyrinth	Membranous labyrinth (within the bony labyrinth)	Structure that contains the receptors	Function of the receptors
Cochlea	Cochlea duct	Spiral organ	Hearing
Vestibule	Utricule and saccule	Maculae	Equilibrium: static equilibrium and linear acceleration of the head
Semicircular canals	Semicircular ducts	Ampullae	Equilibrium: rotational acceleration of the head

Activity 10**Examining the Ear with an Otoscope (Optional)**

1. Obtain an otoscope and two alcohol swabs. Inspect your partner’s ear canal, and then select the speculum with the largest diameter that will fit comfortably into the ear and permit good visibility. Clean the speculum thoroughly with an alcohol swab, and then attach it to the battery-containing otoscope handle. Before beginning, check that the otoscope light beam is strong. If not, obtain another otoscope or new batteries.

 2. When you are ready to begin the examination, hold the lighted otoscope securely between your thumb and forefinger (like a pencil), and rest the little finger of your otoscope-holding hand against your partner’s head. This maneuver forms a brace that allows the speculum to move as your partner moves and

prevents it from penetrating too deeply into the ear canal during the unexpected movements.

3. Grasp the ear auricle firmly, and pull it up, back, and slightly laterally. If this causes your partner pain or discomfort, the external ear may be inflamed or infected. If this occurs, do not attempt to examine the ear canal.

4. Carefully insert the speculum of the otoscope into the external acoustic meatus in a downward and forward direction just far enough to permit examination of the tympanic membrane. Note its shape, color, and vascular network. The healthy tympanic membrane is pearly white. During the examination, notice whether there is any discharge or redness in the canal, and identify earwax.

5. After the examination, thoroughly clean the speculum with the second alcohol swab before returning the otoscope to the supply area.

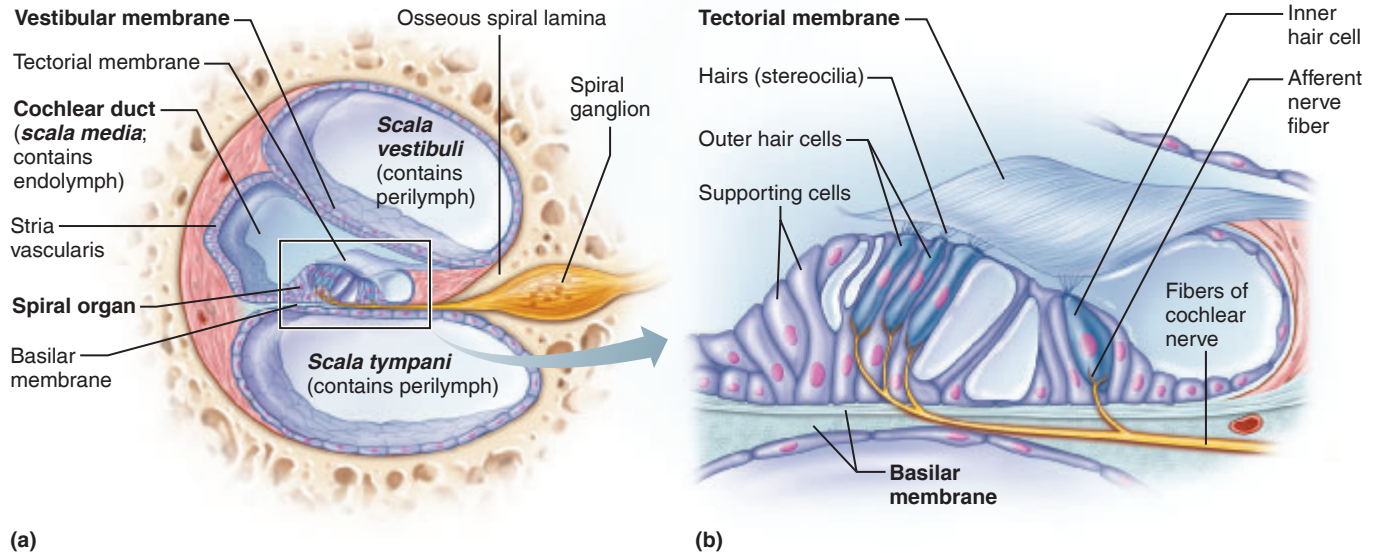


Figure 17.10 Anatomy of the cochlea. (a) Magnified cross section of one turn of the cochlea, showing the relationship of the three scalae. (b) Detailed structure of the spiral organ.

Microscopic Anatomy of the Spiral Organ

The snail-like cochlea (Figure 17.9 and **Figure 17.10**) contains the receptors for hearing. The cochlear membranous labyrinth, the cochlear duct, is a soft wormlike tube about 1.5 inches long that winds through the turns of the cochlea and separates the perilymph-containing cochlear cavity into upper and lower chambers. The upper chamber abuts the oval window, which “seats” the foot plate of the stapes located laterally in the tympanic cavity. The lower chamber is bounded by a membranous area called the round window. The cochlear duct, itself filled with endolymph, supports the spiral organ, which contains the receptors for hearing and nerve endings of the cochlear division of the vestibulocochlear nerve (VIII).

In the spiral organ, the auditory receptors are hair cells that rest on the **basilar membrane**, which forms the floor of the cochlear duct, and their hairs are stereocilia that project into the gel-like **tectorial membrane**, overlying them (Figure 17.10b). The roof of the cochlear duct is called the **vestibular membrane**.

Activity 11

Examining the Microscopic Structure of the Cochlea

Go to the demonstration area, and view the prepared microscope slide of the cochlea. Identify the areas described above and shown in Figure 17.10. Compare your observations to the view shown in Plate 16 in the Histology Atlas.

The Mechanism of Hearing

The mechanism of hearing begins as sound waves pass through the external acoustic meatus and through the middle ear into the internal ear, where the vibration eventually reaches the spiral organ, which contains the receptors for hearing.

Traveling sound waves stimulate hair cells of the spiral organ, where they peak. High-frequency waves (high-pitched sounds) peak close to the oval window, and low-frequency waves (low-pitched sounds) peak farther up the basilar membrane near the apex of the cochlea. Once stimulated, the hair cells depolarize and begin the chain of nerve impulses to the auditory centers of the temporal lobe cortex. This series of events results in the phenomenon we call hearing.

Activity 12

Conducting Laboratory Tests of Hearing

Perform the following hearing tests in a quiet area.

Acuity Test

Have your lab partner pack one ear with cotton and sit quietly with eyes closed. Obtain a ticking clock or pocket watch, and hold it very close to the *unpacked* ear. Then slowly move the clock or watch away from the ear until your partner signals that the ticking is no longer audible. Record the distance in inches at which ticking is inaudible.

Right ear _____ Left ear _____

Is the threshold of audibility sharp or indefinite?

Sound Localization

Ask your partner to close both eyes. Hold the pocket watch at an audible distance (about 6 inches) from the ear, and move it to various locations (front, back, sides, and above the head). Have your partner locate the position by pointing in each instance. Can the sound be localized equally well at all positions?

Text continues on next page. →

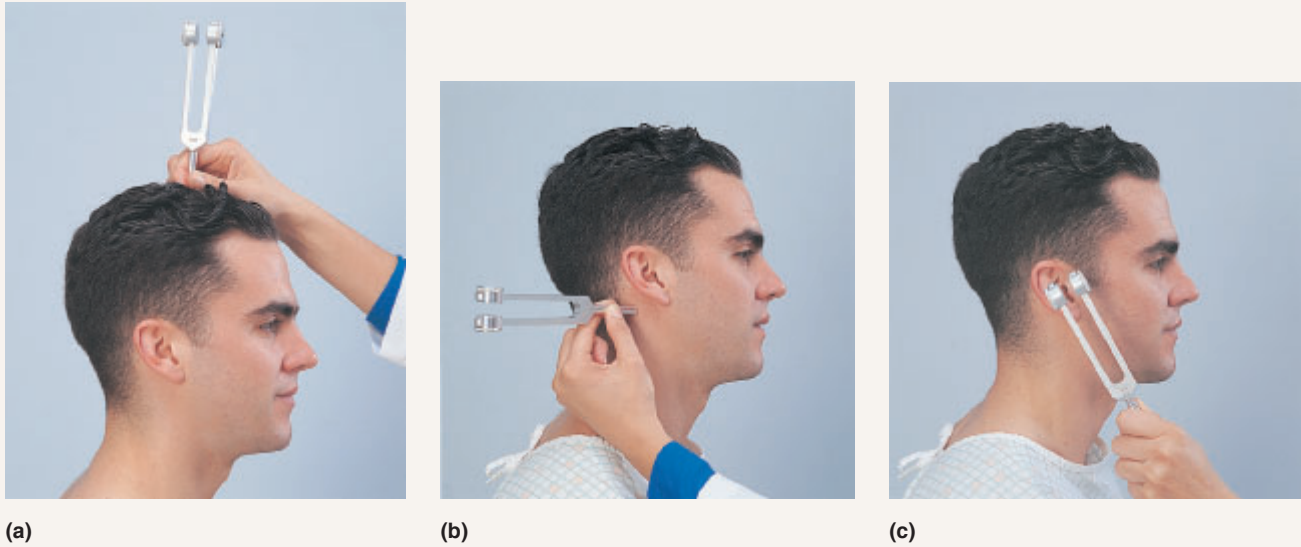


Figure 17.11 The Weber and Rinne tuning fork tests. (a) The Weber test to evaluate whether the sound remains centralized (normal) or lateralizes to one side or the other (indicative of some degree of conduction or sensorineural deafness). (b) and (c) The Rinne test to compare bone conduction and air conduction.

If not, at what position(s) was the sound *less* easily located?

The ability to localize the source of a sound depends on two factors—the difference in the loudness of the sound reaching each ear and the time of arrival of the sound at each ear. How does this information help to explain your findings?

Weber Test to Determine Conductive and Sensorineural Deafness

Obtain a tuning fork and a rubber mallet. Strike the tuning fork with the rubber mallet, and place the handle of the tuning fork medially on your partner’s head (**Figure 17.11a**). Is the tone equally loud in both ears, or is it louder in one ear?

If it is equally loud in both ears, your partner has equal hearing or equal loss of hearing in both ears. If sensorineural deafness is present in one ear, the tone will be heard in the unaffected ear, but not in the ear with sensorineural deafness. If conduction deafness is present,

the sound will be heard more strongly in the ear in which there is a hearing loss. Conduction deafness can be simulated by plugging one ear with cotton to interfere with the conduction of sound to the internal ear.

Rinne Test for Comparing Bone- and Air-Conduction Hearing

1. Strike the tuning fork, and place its handle on your partner’s mastoid process (Figure 17.11b).
2. When your partner indicates that he or she can no longer hear the sound, hold the still-vibrating prongs close to the acoustic meatus (Figure 17.11c). If your partner hears the fork again (by air conduction) when it is moved to that position, hearing is not impaired. Record the test result as positive (+). (Record below step 4.)
3. Repeat the test, but this time test air-conduction hearing first. After the tone is no longer heard by air conduction, hold the handle of the tuning fork on the bony mastoid process. If your partner hears the tone again by bone conduction after hearing by air conduction is lost, there is some conduction deafness, and the result is recorded as negative (-).
4. Repeat the sequence for the opposite ear.

Right ear _____ Left ear _____

Does the subject hear better by bone or by air conduction?

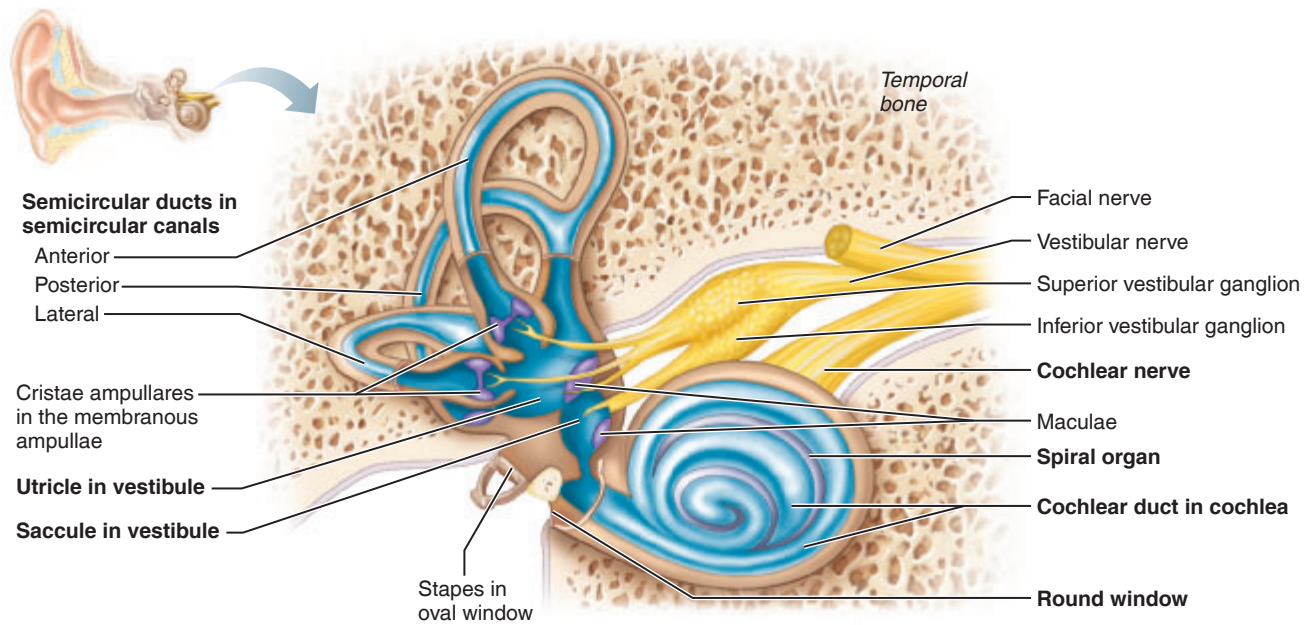


Figure 17.12 Internal ear. Right membranous labyrinth (blue) shown within the bony labyrinth (tan). The locations of sensory organs for hearing and equilibrium are shown in purple.

Anatomy of the Equilibrium Apparatus and Mechanisms of Equilibrium

The equilibrium receptors of the internal ear are collectively called the **vestibular apparatus** and are found in the vestibule and semicircular canal portions of the bony labyrinth (**Figure 17.12**). The vestibule contains the saclike **utricle** and **sacculle**, and the semicircular chambers contain membranous **semicircular ducts**. Like the cochlear duct, these membranes (1) are suspended in perilymph within the bony chambers, (2) are filled with endolymph, and (3) contain receptor cells that are activated by the disturbance of the hairs on their hair cells.

The semicircular canals house dynamic equilibrium receptors. The canals are about ½ inch in circumference and are oriented in the three planes of space. At the base of each

semicircular duct is an enlarged region, the **ampulla**, which contains a receptor region called a **crista ampullaris**. This receptor consists of a tuft of hair cells covered with a gelatinous cap, or **ampullary cupula** (**Figure 17.13**). These dynamic equilibrium receptors react to changes in angular motion rather than to motion itself (**Figure 17.13b** and **c**).

The membranous utricle and sacculle within the vestibule contain **maculae**, *static equilibrium* receptors that respond to gravitational pull and to linear or straightforward changes in speed. The **otolith membrane**, a gelatinous material containing small grains of calcium carbonate (**otoliths**), overrides the hair cells in each macula. As the head moves, the otoliths roll in response to changes in gravitational pull (**Figure 17.14**). As they bend different hair cells, they modify the rate of impulse transmission along the vestibular nerve.

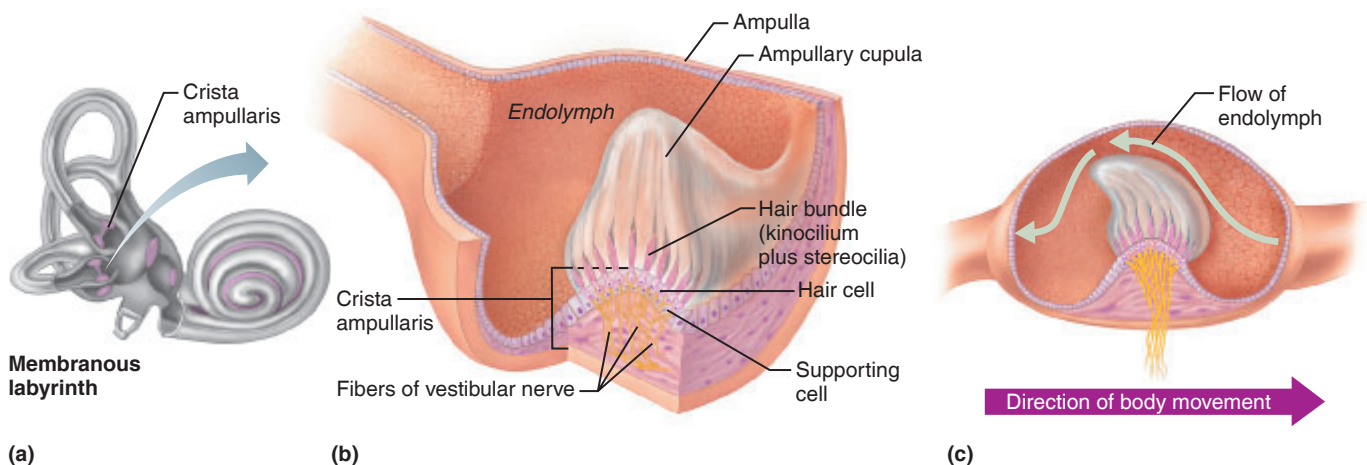


Figure 17.13 Structure and function of the crista ampullaris. (a) The semicircular ducts in the semicircular canals each have a swelling called an ampulla at their base. (b) Each ampulla contains a crista ampullaris. (c) Movement of the ampullary cupula during rotational acceleration of the head.

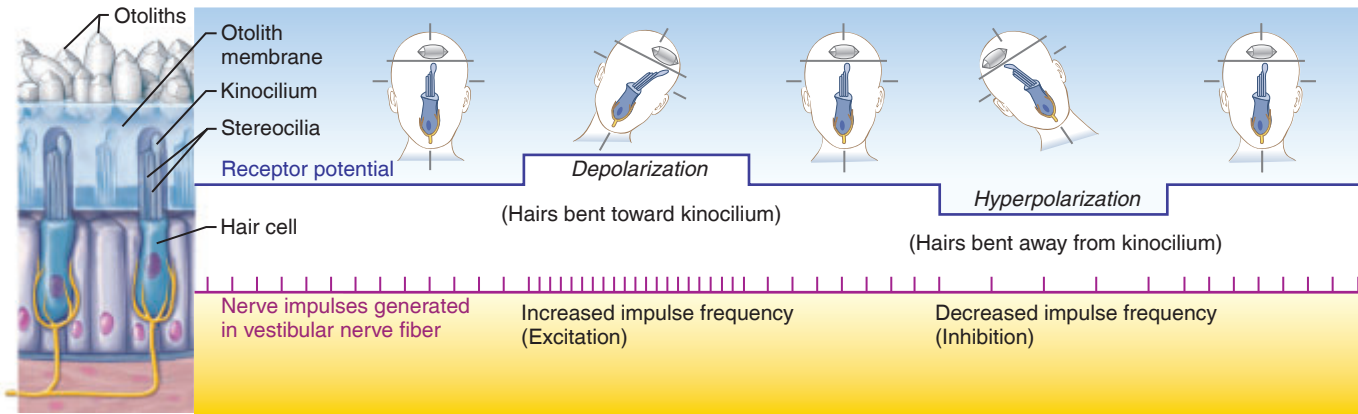


Figure 17.14 The effect of gravitational pull on a macula receptor in the utricle. When movement of the otolith membrane bends the hair cells in the direction of the kinocilium, the hair cells depolarize, exciting the nerve fibers, which generates action potentials more frequently. When the hair cells are bent in the direction away from the kinocilium, the hair cells become hyperpolarized, inhibiting the nerve fibers and decreasing the action potential frequency.

Activity 13

Conducting Laboratory Tests on Equilibrium

The functions of the semicircular canals and vestibule are not routinely tested in the laboratory, but the following simple tests should serve to illustrate normal equilibrium apparatus functioning.

Balance Test

Have your partner walk a straight line, placing one foot directly in front of the other.

Is he or she able to walk without noticeable wobbling from side to side?

Did he or she experience any dizziness? _____

The ability to walk with balance and without dizziness, unless subject to rotational forces, indicates normal function of the equilibrium apparatus.

Was nystagmus* present? _____

Romberg Test

The Romberg test determines the soundness of the dorsal white column of the spinal cord, which transmits impulses to the brain from the proprioceptors involved with posture.

1. Have your partner stand with the back to the blackboard or whiteboard.

* **Nystagmus** is the involuntary rolling of the eyes in any direction or the trailing of the eyes slowly in one direction, followed by their rapid movement in the opposite direction. It is normal after rotation; abnormal otherwise. The direction of nystagmus is that of its quick phase on acceleration.

2. Draw one line parallel to each side of your partner's body. He or she should stand erect, with feet together, eyes open and staring straight ahead for 2 minutes while you observe any movements. Did you see any gross swaying movements?

3. Repeat the test. This time the person's eyes should be closed. Note and record the degree of side-to-side movement.

4. Repeat the test with the person's eyes first open and then closed. This time, however, your partner should be positioned with the left shoulder toward, but not touching, the board so that you may observe and record the degree of front-to-back swaying.

Do you think the equilibrium apparatus of the internal ear was operating equally well in all these tests? _____

The proprioceptors? _____

Why was the observed degree of swaying greater when the eyes were closed?

What conclusions can you draw regarding the factors necessary for maintaining body equilibrium and balance?

Record the observations: _____

Rest for 1 or 2 minutes; then repeat the experiment with the same foot raised, but with your eyes closed.

Record the observations: _____

Role of Vision in Maintaining Equilibrium

To further demonstrate the role of vision in maintaining equilibrium, perform the following experiment. (Ask your lab partner to record observations and act as a “spotter.”) Stand erect, with your eyes open. Raise your left foot approximately 1 foot off the floor, and hold it there for 1 minute.

The Chemical Senses: Smell and Taste

The receptors for smell (olfaction) and taste (gustation) are classified as **chemoreceptors** because they respond to chemicals in solution.

Localization and Anatomy of the Olfactory and Taste Receptors

A pseudostratified epithelium called the **olfactory epithelium** is the organ of smell. It occupies an area lining the roof of each nasal cavity (Figure 17.15 and Plate 18 in the Histology Atlas).

Three cell types are found within the olfactory epithelium:

- **Olfactory sensory neurons:** Specialized receptor cells that are bipolar neurons with nonmotile olfactory cilia.
- **Supporting cells:** Columnar cells that surround and support the olfactory sensory neurons. They form the bulk of the olfactory epithelium.
- **Olfactory stem cells:** Located near the basal surface of the epithelium, they divide to form new olfactory sensory neurons.

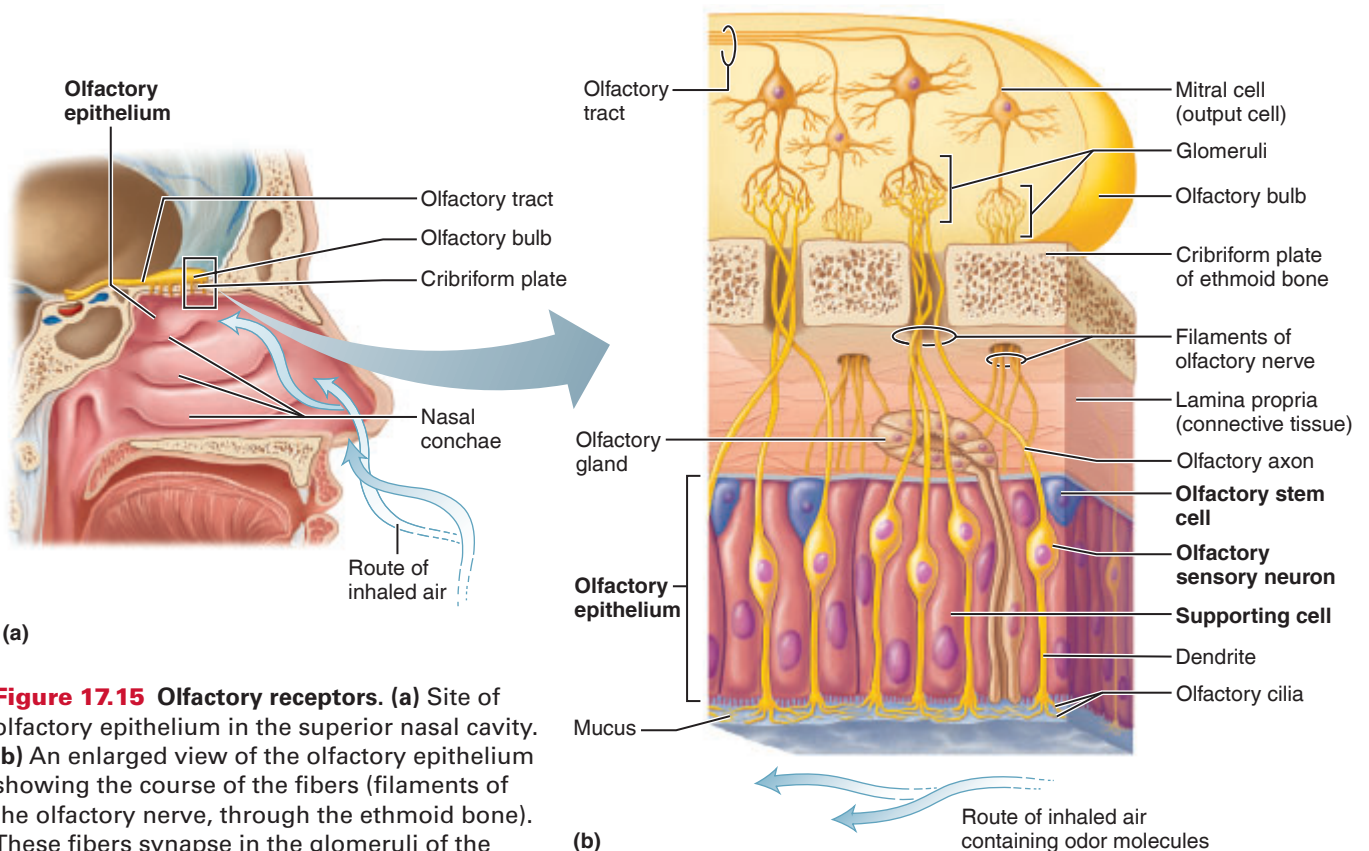
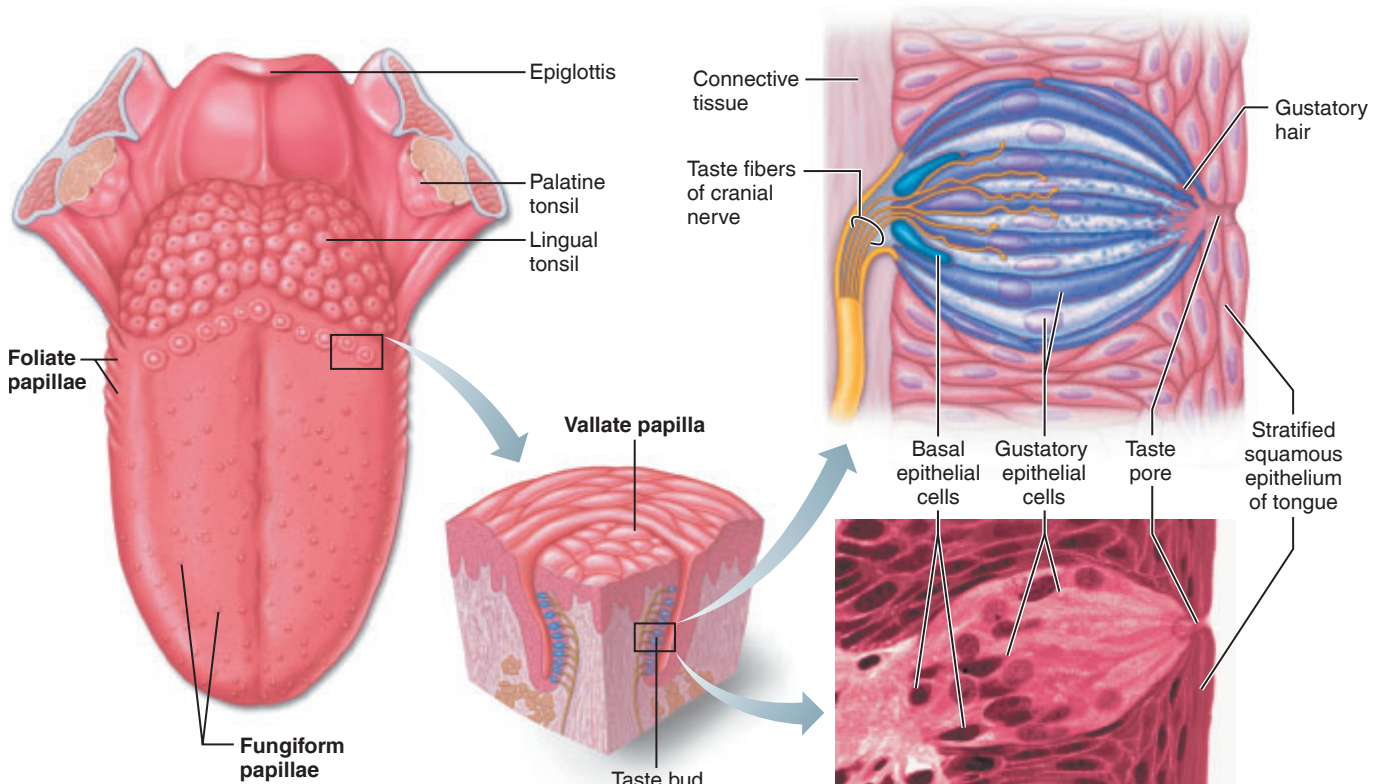


Figure 17.15 Olfactory receptors. (a) Site of olfactory epithelium in the superior nasal cavity. (b) An enlarged view of the olfactory epithelium showing the course of the fibers (filaments of the olfactory nerve, through the ethmoid bone). These fibers synapse in the glomeruli of the overlying olfactory bulb. The mitral cells are the output cells of the olfactory bulb.



(a) Taste buds are associated with fungiform, foliate, and vallate papillae.

(b) Enlarged section of a vallate papilla

(c) Enlarged view of a taste bud (445×)

Figure 17.16 Location and structure of taste buds on the tongue. (See also Plate 17 in the Histology Atlas.)

The axons of the olfactory sensory neurons form small fascicles called the *filaments of the olfactory nerve* (cranial nerve I), which penetrate the cribriform foramina and synapse in the olfactory bulbs.

The **taste buds**, containing specific receptors for the sense of taste, are widely distributed in the oral cavity. Most are located on the tongue (as described next). A few are found on the soft palate, pharynx, epiglottis, and inner surface of the cheeks.

The superior tongue surface is covered with small projections, or **papillae**, of three major types: *foliate*, *fungiform*, and *vallate papillae*. The taste buds are located primarily on the sides of the vallate papillae (arranged in a V-formation on the posterior surface of the tongue) and on the more numerous fungiform papillae. The latter look rather like small mushrooms and are widely distributed on the tongue (**Figure 17.16**).

Each taste bud consists largely of an arrangement of two types of modified epithelial cells:

- **Gustatory epithelial cells:** The receptors for taste; they have long microvilli called **gustatory hairs** that project through the epithelial surface through a **taste pore**.
- **Basal epithelial cells:** Precursor cells that divide to replace the gustatory epithelial cells.

Several nerve fibers enter each taste bud and supply sensory nerve endings to each of the taste cells. The long gustatory hairs of the receptor cells penetrate the taste pore. When the gustatory hairs are stimulated by specific chemicals in the solution, the taste cells depolarize. The afferent fibers from the taste buds to the gustatory cortex of the brain are carried in three cranial nerves: the *facial (VII)*, *glossopharyngeal (IX)*, and *vagus (X) nerves*.

When taste is tested with pure chemical compounds, most taste sensations can be grouped into one of five basic qualities—sweet, salty, sour, bitter, and umami (u-mam'e; “delicious”). Umami is responsible for the “meaty” taste of steak and of foods seasoned with monosodium glutamate.

Activity 14

Identification of Papillae on the Tongue

Use a mirror to examine your tongue. Can you pick out the various types of papillae? If so, which?

Laboratory Experiments

Activity 15

Stimulating Taste Buds

1. Obtain several paper towels and a disposable autoclave bag, and bring them to your bench.
2. With a paper towel, dry the superior surface of your tongue.



Immediately dispose of the paper towel in the autoclave bag.

3. Place a few sugar crystals on your dried tongue. Do *not* close your mouth. How long does it takes to taste the sugar?

_____ sec

Why couldn't you taste the sugar immediately?

Activity 16

Examining the Combined Effects of Smell, Texture, and Temperature on Taste

Effects of Smell and Texture

1. Ask your partner to sit with eyes closed and to pinch the nostrils shut.
2. Using a paper plate, obtain samples of the food items listed in the chart. Do *not* let the person see the foods being tested.
3. Use an out-of-sequence order of food testing. For each test, place a cube of food in your partner's mouth, and ask him or her to identify the food by using the following sequence of activities:
 - First, move the food around in the mouth with the tongue.
 - Second, chew the food.
 - Third, if the person cannot make a positive identification with the first two techniques and the taste sense, ask him or her to release the pinched nostrils and to continue chewing with the nostrils open. This may help the subject make a positive identification.

Record the results on the **Activity 16 chart** by checking the appropriate column.

Was the sense of smell equally important in all cases?

Where did it seem to be important and why?

Effect of Olfactory Stimulation

There is no question that what is commonly called taste depends heavily on the sense of smell, particularly in the case of strongly scented substances. The following experiments should illustrate this fact.

1. Obtain paper cups; vials of oil of wintergreen, peppermint, and cloves; and some fresh cotton-tipped swabs. Ask your partner to sit so that he or she cannot see which vial is being used. Then ask the subject to dry the tongue and pinch the nostrils shut.
2. Apply a drop of one of the oils to the subject's tongue. Can he or she distinguish the flavor?

3. Have your partner open the nostrils. Record the change in sensation he or she reports.

Activity 16: Method of Identification

Food	Texture only	Chewing with nostrils pinched	Chewing with nostrils open	Identification not made

Text continues on next page. →

- 4. Have your partner rinse the mouth well with water and dry the tongue.
- 5. Prepare two swabs, each with one of the two remaining oils.
- 6. Hold one swab under your partner's open nostrils while touching the second swab to the tongue.

Record the reported sensations. _____



Dispose of the used swabs and paper towels in the autoclave bag before continuing.

Which sense, taste or smell, appears to be more important in properly identifying a strongly flavored volatile substance?

Effect of Temperature

Olfaction and food texture are not the only influences on our taste sensation. Temperature also helps us determine whether we appreciate or even taste the foods we eat. To illustrate this, have your partner hold some chipped ice on the tongue for approximately 1 minute and then close the eyes. Immediately place any of the foods previously identified in the mouth, and ask for an identification.

Results? _____

EXERCISE
17

REVIEW SHEET

The Special Senses

Name _____ Lab Time/Date _____

The Eye and Vision: Anatomy

1. Several accessory eye structures contribute to the formation of tears and/or help lubricate the eyeball. Match the accessory structures with their secretion by choosing letters from the key.

Key: a. conjunctivae b. lacrimal glands c. tarsal glands

_____ 1. mucus

_____ 2. oil

_____ 3. lysozyme

2. The eyeball is wrapped in adipose tissue within the orbit. What is the function of the adipose tissue?

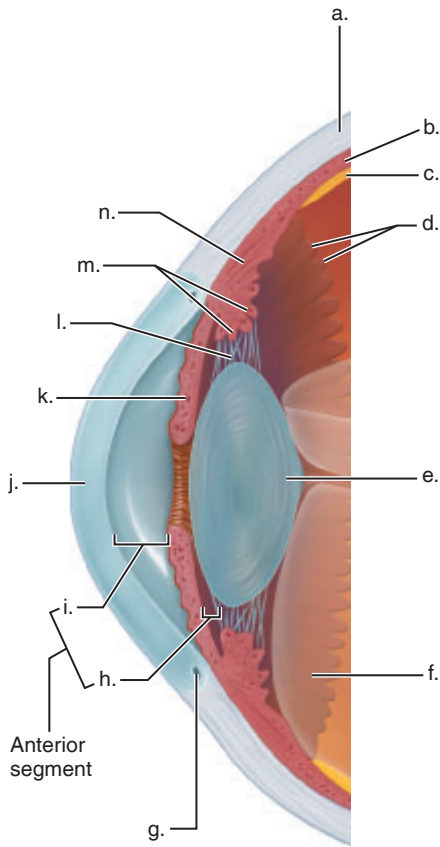
3. Why may it be necessary to blow your nose after having a good cry? _____

4. What is a sty? _____

Conjunctivitis? _____

5. What seven bones form the bony orbit? (Think! If you can't remember, check a skull or your textbook.)

6. Correctly identify each lettered structure in the diagram by writing the letter next to its name in the numbered list. Use an appropriate reference if necessary.



- _____ 1. anterior chamber
- _____ 2. choroid
- _____ 3. ciliary muscle
- _____ 4. ciliary process
- _____ 5. ciliary zonule
- _____ 6. cornea
- _____ 7. iris
- _____ 8. lens
- _____ 9. ora serrata
- _____ 10. posterior chamber
- _____ 11. posterior segment
- _____ 12. retina
- _____ 13. sclera
- _____ 14. scleral venous sinus

7. Match the key responses with the descriptive statements that follow.

- | | | | | |
|------|----------------|-----------------|------------|----------------------|
| Key: | aqueous humor | cornea | lens | sclera |
| | choroid | fovea centralis | optic disc | scleral venous sinus |
| | ciliary zonule | iris | retina | vitreous humor |

- _____ 1. attaches the lens to the ciliary body
- _____ 2. fluid filling the anterior segment of the eye
- _____ 3. the blind spot
- _____ 4. contains muscle that controls the size of the pupil
- _____ 5. drains the aqueous humor from the eye
- _____ 6. layer containing the rods and cones
- _____ 7. substance occupying the posterior segment of the eyeball
- _____ 8. forms most of the pigmented vascular tunic
- _____ 9. tiny pit in the macula lutea; contains only cones
- _____ 10. important light-bending structure of the eye; shape can be modified
- _____ 11. anterior transparent part of the fibrous tunic
- _____ 12. composed of tough, white, opaque, fibrous connective tissue

8. The intrinsic eye muscles are under the control of which of the following? (Circle the correct response.)

autonomic nervous system

somatic nervous system

Dissection of the Cow (Sheep) Eye

9. What modification of the choroid that is *not* present in humans is found in the cow eye? _____

What is its function? _____

10. Describe the appearance of the retina. _____

At what point is it attached to the posterior aspect of the eyeball? _____

Visual Tests and Experiments

11. Use terms from the key to complete the statements concerning near and distance vision. (Some terms may be used more than once.)

Key: contracted decreased increased loose relaxed taut

During distance vision: The ciliary muscle is _____, the ciliary zonule is _____, the convexity of the lens is _____, and light refraction is _____. During close vision: The ciliary muscle is _____, the ciliary zonule is _____, lens convexity is _____, and light refraction is _____.

12. Explain why the part of the image hitting the blind spot is not seen. _____

13. Match the terms in column B with the descriptions in column A:

Column A	Column B
_____ 1. light bending	accommodation
_____ 2. ability to focus for close (under 20 ft) vision	astigmatism
_____ 3. normal vision	convergence
_____ 4. inability to focus well on close objects (farsightedness)	emmetropia
_____ 5. nearsightedness	hyperopia
_____ 6. blurred vision due to unequal curvatures of the lens or cornea	myopia
_____ 7. medial movement of the eyes during focusing on close objects	refraction

14. Record your Snellen eye test results below:

Left eye (without glasses) _____ (with glasses) _____

Right eye (without glasses) _____ (with glasses) _____

Is your visual acuity normal, less than normal, or better than normal? _____

Explain. _____

Explain why the examiner tests each eye separately when using the Snellen eye chart. _____

15. Define *astigmatism*: _____

16. Record the distance of your near point of accommodation as tested in the laboratory:

right eye _____ left eye _____

Is your near point within the normal range for your age? _____

17. How can you explain the fact that we see a great range of colors even though only three cone types exist?

18. In the experiment on the convergence reflex, what happened to the position of the eyeballs as the object was moved

closer to the subject's eyes? _____

Which extrinsic eye muscles control the movement of the eyes during this reflex? _____

What is the value of this reflex? _____

If these muscles were unable to function, what would be the visual result? _____

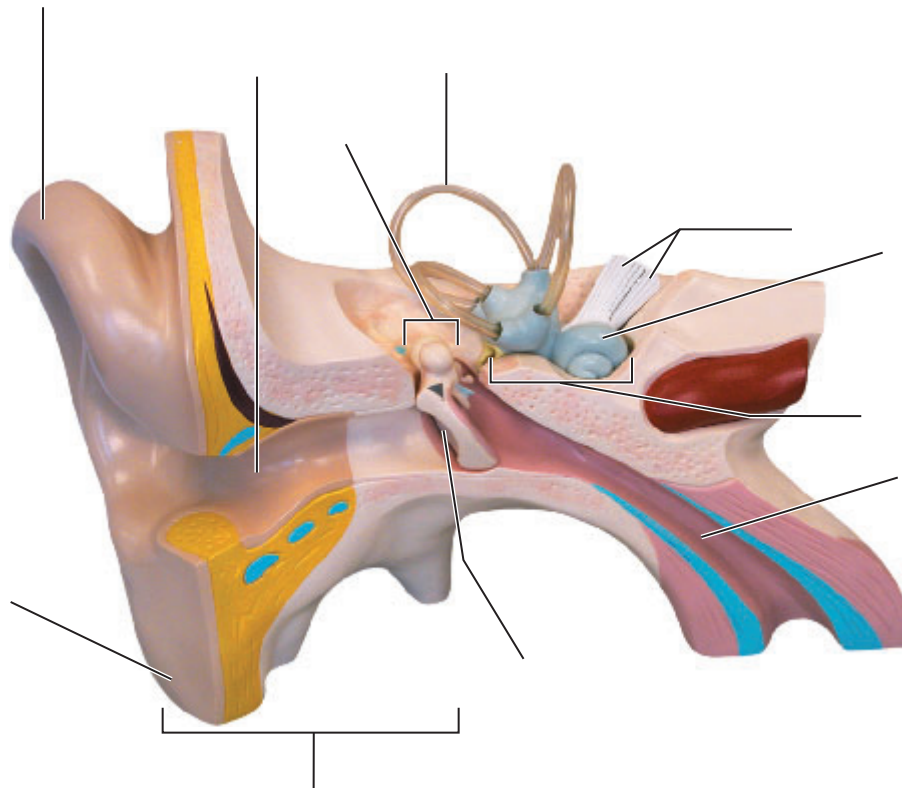
19. Many college students struggling through mountainous reading assignments are told that they need glasses for "eyestrain." Why is looking at close objects more of a strain on the extrinsic and intrinsic eye muscles than looking at far objects?

The Ear and Hearing and Balance: Anatomy

20. Select the terms from column B that apply to the column A descriptions.

Column A	Column B
_____	endolymph
_____ 1. collectively called the auditory ossicles	incus
_____ 2. ear structures involved with balance	malleus
_____ 3. transmits sound vibrations to the auditory ossicles	oval window
_____ 4. fluid contained within the bony labyrinth	perilymph
_____ 5. transmits the vibratory motion of the stapes to the fluid in the ear	pharyngotympanic (auditory) tube
_____ 6. passage between the throat and the tympanic cavity	semicircular canals
_____ 7. fluid contained within the membranous labyrinth	stapes
	tympanic membrane
	vestibule

21. Identify all indicated structures and ear regions in the following photograph.



22. Match the membranous labyrinth structures listed in column B with the descriptive statements in column A.

Column A	Column B
_____ 1. contains the spiral organ	ampulla
_____, _____ 2. sites of the maculae	ampullary cupula
_____ 3. hair cells of the spiral organ rest on this membrane	basilar membrane
_____ 4. gel-like membrane overlying the hair cells of the spiral organ	cochlear duct
_____ 5. contains the cristae ampullaris	cochlear nerve
_____ 6. carries equilibrium information to the brain	otoliths
_____ 7. three internal ear structures oriented in the three planes of space	sacculle
_____ 8. carries auditory information to the brain	semicircular ducts
_____ 9. gelatinous cap overlying hair cells of the crista ampullaris	tectorial membrane
_____ 10. grains of calcium carbonate in the maculae	utricle
	vestibular nerve

23. Describe how sounds of different frequency (pitch) are differentiated in the cochlea. _____

24. Explain the role of the endolymph of the semicircular canals in activating the receptors during angular motion.

25. Explain the role of the otoliths in perception of static equilibrium (head position). _____

Hearing and Balance Tests

26. Was the hearing acuity measurement made during the experiment (page 205) the same or different for both ears?

_____ What factors might account for a difference in the acuity of the two ears?

27. During the sound localization experiment (page 205), in which position(s) was the sound least easily located?

How can you explain this observation? _____

28. When the tuning fork handle was pressed to your forehead during the Weber test, where did the sound seem to originate?

Where did it seem to originate when one ear was plugged with cotton? _____

How do sound waves reach the cochlea when conduction deafness is present? _____

29. The Rinne test evaluates an individual's ability to hear sounds conducted by air or bone. Which is typical of normal hearing? _____

30. Define *nystagmus*: _____

31. What is the usual reason for conducting the Romberg test? (Use your textbook if necessary.)

Was the degree of sway greater with the eyes open or closed? _____

Why? _____

32. Normal balance, or equilibrium, depends on input from a number of sensory receptors. Name them.

Chemical Senses: Localization and Anatomy of Olfactory and Taste Receptors

33. Describe the cellular makeup and the location of the olfactory epithelium. _____

34. Name five sites where receptors for taste are found, and circle the predominant site:

_____, _____, _____, _____ and

35. Describe the cellular makeup and arrangement of a taste bud. (Use a diagram, if helpful.)

Taste and Smell Experiments

36. Taste and smell receptors are both classified as _____ because they both respond to

37. Why is it impossible to taste substances if your tongue is dry? _____

38. Explain why a cold, greasy hamburger is unappetizing to most people.

39. How palatable is food when you have a cold? _____

Explain. _____

40. **+** A cornea transplant involves the grafting of a donor cornea into a recipient's anterior eye. The sutures to hold the graft in place must stay in place for a long period of time because the cornea is slow to heal. Explain why the healing process is so slow and also why graft rejection is unlikely with a cornea transplant. _____

41. **+** Macular degeneration is an eye disease in which the macula lutea deteriorates. Explain why this would have a more profound effect on vision than deterioration of other parts of the retina. _____

42. **+** Acute labyrinthitis is sudden onset of inflammation of the structures that form the membranous labyrinth. List the structures that could be inflamed with this condition. _____

43. **+** One symptom of the common cold is loss of appetite. Explain why this occurs.

Functional Anatomy of the Endocrine Glands

Materials

- Demonstration area with two microscope stations set up:
 - Station 1:* Thyroid gland with pointer on colloid-filled follicle
 - Station 2:* Differentially stained pancreas tissue, allowing alpha and beta cells to be distinguished
- 20% glucose solution
- Commercial insulin solution (400 IU per 100 ml H₂O)
- Finger bowls
- Small (1½–2 in.) freshwater fish (guppy, bluegill, or sunfish—listed in order of preference)
- Small fish net
- Wax marking pencils
- Human torso model
- Anatomical chart of the human endocrine system

Learning Outcomes

- List the hormones produced by the major endocrine organs, and discuss the general function of each. Additionally, describe the major pathology resulting from hyper- or hyposecretion of each.
- Describe and explain the effects of hyperinsulinism.
- Identify and name the major endocrine glands on an appropriate diagram.

The **endocrine system** is the second major controlling system of the body. Acting with the nervous system, it helps coordinate and integrate the activity of the body's cells. However, the nervous system uses nerve impulses to bring about rapid control, whereas the more slowly acting endocrine system employs chemical messengers, or **hormones**, which are released into the blood to be transported throughout the body.

The body's hormones are steroids or amino acid-based molecules. Although hormones travel through the blood, a given hormone affects only a specific organ or organs. Cells within an organ that respond to a particular hormone are referred to as the **target cells** (also **target**) of that hormone. The ability of the target to respond depends on the ability of the hormone to bind with specific cellular receptors.

Although the function of most hormone-producing glands is purely endocrine, the function of others (the pancreas and gonads) is mixed—both endocrine and exocrine. In addition, there are varied numbers of hormone-producing cells within the intestine, stomach, kidney, and placenta, organs whose functions are primarily nonendocrine. Here we will consider only the major endocrine organs.

Gross Anatomy and Basic Function of the Endocrine Glands

Pituitary Gland

The *pituitary gland* is located in the sella turcica of the sphenoid bone. It has two functional areas, the **anterior pituitary**, which is glandular tissue, and the **posterior pituitary** (nervous tissue).

Anterior Pituitary Hormones

The anterior pituitary, or adenohypophysis, secretes a number of hormones, four of which are **tropic** hormones. The target organ of a tropic hormone is another endocrine gland. Target organ hormones then produce their effects on other body organs and tissues.

The anterior pituitary controls the activity of so many other endocrine glands that it has often been called the *master endocrine gland*. However, the anterior pituitary is not all-powerful, because release of its hormones is controlled by *releasing or inhibiting hormones* produced by the hypothalamus. These hypothalamic hormones are liberated into the blood of the *portal circulation*, which connects the blood supplies of the hypothalamus and anterior pituitary (**Figure 18.1**).

Table 18.1 summarizes the hormones released by the anterior pituitary and categorizes each as tropic or not tropic.

Posterior Pituitary Hormones

The posterior pituitary is not an endocrine gland, because it does not synthesize the hormones it releases. Instead it acts as a storage area for hormones produced

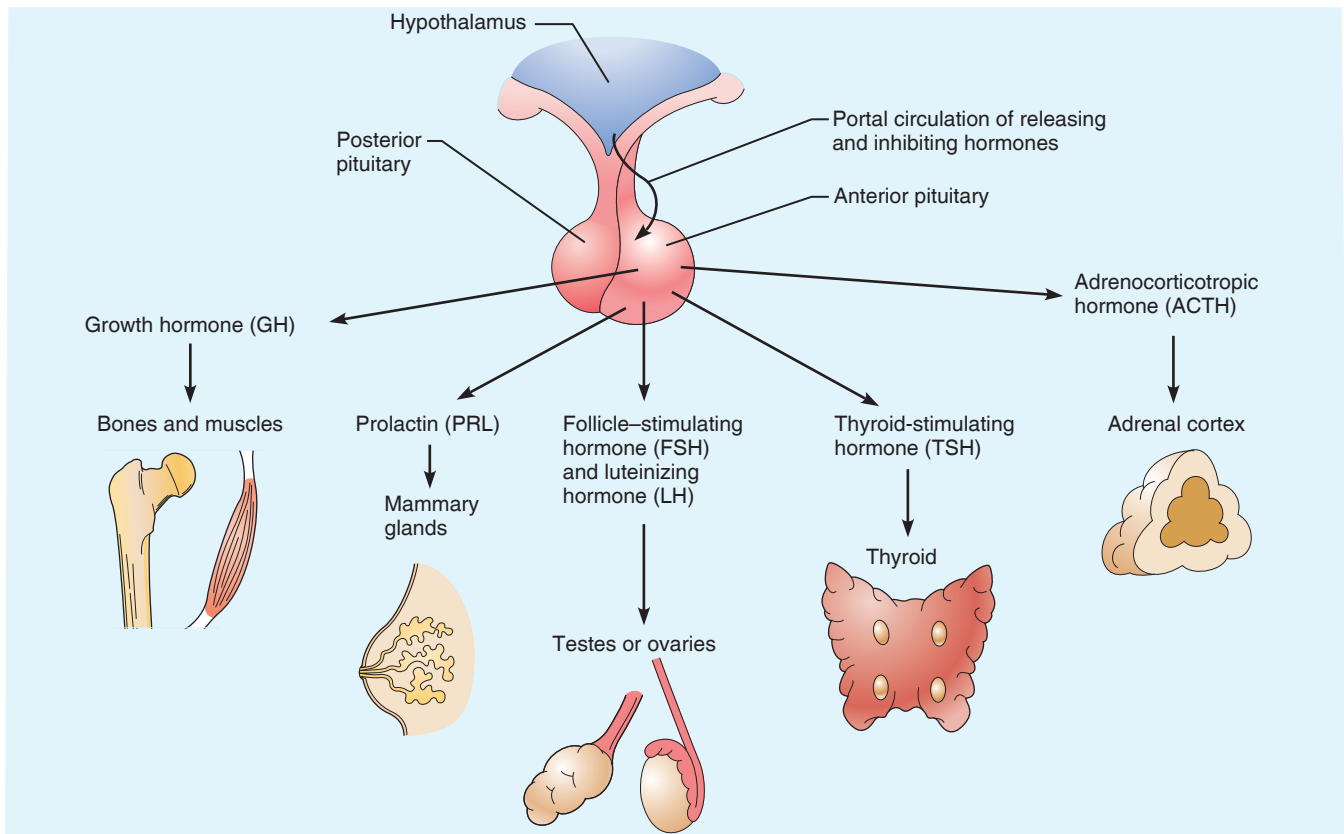


Figure 18.1 Hormones of the anterior pituitary and their major target organs. Hypothalamic neurons secrete releasing hormones, which stimulate the secretion of hormones from the anterior pituitary. The releasing and inhibiting hormones are secreted into a capillary network that connects via portal veins to a second capillary bed in the anterior pituitary gland.

Table 18.1 Anterior Pituitary Gland Hormones (Figure 18.1)

Hormone	Stimulus for release	Target	Effects
Anterior Pituitary Gland: Tropic Hormones			
Thyroid-stimulating hormone (TSH)	Thyrotropin-releasing hormone (TRH)*	Thyroid gland	Stimulates the secretion of thyroid hormones (T_3 and T_4)
Follicle-stimulating hormone (FSH)	Gonadotropin-releasing hormone (GnRH)*	Ovaries and testes (gonads)	Females—stimulates ovarian follicle maturation and estrogen production Males—stimulates sperm production
Luteinizing hormone (LH)	Gonadotropin-releasing hormone (GnRH)*	Ovaries and testes (gonads)	Females—triggers ovulation and stimulates ovarian production of estrogen and progesterone Males—stimulates testosterone production
Adrenocorticotropic hormone (ACTH)	Corticotropin-releasing hormone (CRH)*	Adrenal cortex	Stimulates the release of glucocorticoids and androgens (mineralocorticoids to a lesser extent)
Anterior Pituitary Gland: Other Hormones (Not Tropic)			
Growth hormone (GH)	Growth hormone-releasing hormone (GHRH)*	Liver, muscle, bone, and cartilage, mostly	Stimulates body growth and protein synthesis, mobilizes fat and conserves glucose
Prolactin (PRL)	A decrease in the amount of prolactin-inhibiting hormone (PIH)*	Mammary glands in the breasts	Stimulates milk production (lactation)

*Indicates hormones produced by the hypothalamus.

Table 18.2 Posterior Pituitary Gland Hormones

Hormone	Stimulus for release	Target	Effects
Posterior Pituitary Gland (Hormones That Are Synthesized by the Hypothalamus and Stored in the Posterior Pituitary)			
Oxytocin*	Nerve impulses from hypothalamic neurons in response to cervical/uterine stretch or suckling of an infant	Uterus and mammary glands	Stimulates powerful uterine contractions during birth and stimulates milk ejection (let-down) in lactating mothers
Antidiuretic hormone (ADH)*	Nerve impulses from hypothalamic neurons in response to increased blood solute concentration or decreased blood volume	Kidneys	Stimulates the kidneys to reabsorb more water, reducing urine output and conserving body water

*Indicates hormones produced by the hypothalamus.

by the hypothalamus. **Table 18.2** summarizes the hormones stored in the posterior pituitary gland.

Thyroid Gland

The *thyroid gland* is composed of two lobes joined by a central mass, or isthmus. It is located in the anterior neck, just inferior to the larynx. It produces two major hormones, thyroid hormone and calcitonin.

Activity 1

Examining the Microscopic Structure of the Thyroid Gland

Go to station 1 at the demonstration area, and scan the thyroid under low power, noting the **follicles**, spherical sacs containing a pink-stained material (*colloid*). Stored T_3 and T_4 are attached to the protein colloidal material stored in the follicles as **thyroglobulin** and are released gradually to the blood. The **parafollicular**, or **C, cells** you see between the follicles are responsible for calcitonin production.

When the thyroid gland is actively secreting, the follicles appear small, and the colloidal material has a ruffled border. When the thyroid is hypoactive or inactive, the

follicles are large and plump, and the follicular epithelium appears to be squamouslike. What is the physiological state of the tissue you have been viewing?

Activity 2

Palpating the Thyroid Gland

Try to palpate your thyroid gland by placing your fingers against your trachea. As you swallow, the thyroid gland will move up and down on the sides and front of the trachea.

Table 18.3 summarizes the hormones secreted by the thyroid and parathyroid glands (discussed next).

Parathyroid Glands

The *parathyroid glands* are embedded in the posterior surface of the thyroid gland. Typically, there are two small oval glands on each lobe, but there may be more and some may be

Table 18.3 Thyroid and Parathyroid Gland Hormones

Hormone(s)	Stimulus for release	Target	Effects
Thyroid Gland			
Thyroxine (T_4) and Triiodothyronine (T_3), collectively referred to as thyroid hormone (TH)	Thyroid-stimulating hormone (TSH)	Most cells of the body	Increases basal metabolic rate (BMR); regulates tissue growth and development.
Calcitonin	High levels of calcium in the blood	Bones	No known physiological role in humans. When the hormone is supplemented at doses higher than normally found in humans, it does have some pharmaceutical applications.
Parathyroid Gland (Located on the Posterior Aspect of the Thyroid Gland)			
Parathyroid hormone (PTH)	Low levels of calcium in the blood	Bones and kidneys	Increases blood calcium by stimulating osteoclasts and by stimulating the kidneys to reabsorb more calcium. PTH also stimulates the kidneys to convert vitamin D to calcitriol, which is required for the absorption of calcium in the intestines.

Table 18.4 Adrenal Gland Hormones

Cortical area	Hormone(s)	Stimulus for release	Target	Effects
Adrenal Cortex				
Zona glomerulosa	Mineralcorticoids: mostly aldosterone	Angiotensin II release and increased potassium in the blood (ACTH only in times of severe stress)	Kidneys	Increases the reabsorption of sodium and water by the kidney tubules. Increases the secretion of potassium in the urine.
Zona fasciculata	Glucocorticoids: mostly cortisol	ACTH	Most body cells	Promotes the breakdown of fat and protein, promotes stress resistance, and inhibits the immune response.
Zona reticularis	Gonadocorticoids: androgens (most are converted to testosterone and some to estrogen)	ACTH	Bone, muscle, integument, and other tissues	In females, androgens contribute to body growth, contribute to the development of pubic and axillary hair, and enhance sex drive. They have insignificant effects in males.
Cells	Hormone(s)	Stimulus for release	Target	Effects
Adrenal Medulla				
Chromaffin cells	Catecholamines: epinephrine and norepinephrine	Nerve impulses from preganglionic sympathetic fibers	Most body cells	Mimics sympathetic nervous system activation, “fight-or-flight” response.

located in other regions of the neck. They secrete **parathyroid hormone (PTH)** (see Table 18.3).

Adrenal Glands

The two *adrenal*, or *suprarenal*, glands are located atop the kidneys. Anatomically, the **adrenal medulla** develops from neural tissue and is directly controlled by sympathetic nervous system. The medullary cells respond to this stimulation by releasing **epinephrine** (adrenaline) (80%) or **norepinephrine** (noradrenaline) (20%), which act with the sympathetic nervous system to produce the “fight-or-flight” response to stressors.

Table 18.4 summarizes the hormones secreted by the adrenal glands.

Pancreas

The *pancreas*, located posterior to the stomach in the abdomen, acts both as an exocrine and an endocrine gland. It produces digestive enzymes as well as insulin and glucagon, important hormones concerned with regulating blood sugar levels.

Table 18.5 summarizes two of the hormones secreted by the pancreas and by the gonads (discussed next).

Table 18.5 Pancreas and Gonad Hormones

Hormone	Stimulus for release	Target(s)	Effects
Pancreas			
Insulin	Increased blood glucose levels, parasympathetic nervous system stimulation	Most cells of the body	Accelerates the transport of glucose into body cells; promotes glycogen, fat, and protein synthesis
Glucagon	Decreased blood glucose levels, sympathetic nervous system stimulation	Primarily the liver and adipose	Accelerates the breakdown of glycogen to glucose, stimulates the conversion of lactic acid into glucose, releases glucose into the blood from the liver
Ovaries (Female Gonads)			
Estrogens	Luteinizing hormone (LH) and follicle-stimulating hormone (FSH)	Most cells of the body	Promote the maturation of the female reproductive organs and the development of secondary sex characteristics
Estrogens and progesterone (together)	LH and FSH	Uterus and mammary glands	Regulate the menstrual cycle and promote breast development
Testes (Male Gonads)			
Testosterone	LH and FSH	Most cells of the body	Promotes the maturation of the male reproductive organs, the development of secondary sex characteristics, sperm production, and sex drive

Activity 3

Examining the Microscopic Structure of the Pancreas to Identify Alpha and Beta Cells

1. At station 2 in the demonstration area, observe pancreas tissue under low power to identify the roughly circular **pancreatic islets** (*islets of Langerhans*), the endocrine portions of the pancreas. The islets are scattered amid the more numerous acinar cells and stain differently (usually lighter), which makes it possible to identify them. (See Plate 38 in the Histology Atlas.)

2. Examine the cells of an islet under high power. Notice that the islet cells are densely packed and have no definite arrangement. In contrast, the cuboidal acinar cells are arranged around secretory ducts. The pancreas tissue you are viewing has been treated with special stains so that it is possible to distinguish the **alpha cells**, which tend to cluster at the periphery of the islets and produce glucagon, from the **beta cells**, which synthesize insulin. With these specific stains, the beta cells are larger and stain gray-blue, and the alpha cells are smaller and appear bright pink. What is the product of the

Alpha cells? _____

Of the beta cells? _____

What types of activity did you observe in the fish before it became comatose?

3. When the fish is comatose, carefully transfer it to finger bowl B, and observe its actions. What happens to the fish after it is transferred?

Approximately how long did it take for this recovery?

4. After you have made and recorded all your observations, carefully return the fish to the aquarium.

Activity 4

Observing the Effects of Hyperinsulinism

Many people with diabetes mellitus need injections of insulin to maintain blood glucose levels. Adequate levels of blood glucose are essential for proper functioning of the nervous system; thus, insulin administration must be carefully controlled. If blood glucose levels fall sharply, the patient will go into insulin shock.

A small fish will be used to demonstrate the effects of hyperinsulinism. The action of insulin on the fish parallels that in the human, so this experiment should provide valid information concerning its effect in humans.

1. Prepare two finger bowls. Using a wax marker, mark one A and the other B. To finger bowl A, add 100 ml of the commercial insulin solution. To finger bowl B, add 200 ml of 20% glucose solution.

2. Place a small fish in finger bowl A, and observe its actions carefully as the insulin diffuses into its bloodstream through the capillary circulation of its gills.

Approximately how long did it take for the fish to become comatose?

The Gonads

The female *gonads*, or *ovaries*, are paired, almond-sized organs located in the pelvic cavity. In addition to producing the female sex cells (ova), the ovaries produce two groups of steroid hormones, **estrogens** and **progesterone**. The endocrine and exocrine functions of the ovaries do not begin until puberty, when the anterior pituitary gonadotropic hormones prod the ovary into action. The result is rhythmic ovarian cycles in which ova develop and hormone levels rise and fall.

The paired oval *testes* of the male are suspended in a pouchlike sac, the scrotum, outside the pelvic cavity. Besides the male sex cells (sperm), the testes produce the male sex hormone, **testosterone**. Table 18.5 summarizes the hormones produced by the gonads.

Two organs not mentioned earlier as major endocrine organs are also briefly considered here, the thymus and the pineal gland.

Thymus

The *thymus* is situated in the superior thorax, posterior to the sternum and overlying the heart. It is large in the infant, begins to atrophy at puberty, and by old age it is relatively inconspicuous. The thymus produces several hormones, including **thymosin**, **thymulin**, and **thymopoietins**. These hormones are thought to be involved in the development of T lymphocytes and the immune response. They appear to act locally as paracrines.

Table 18.6 Summary of Select Endocrine Homeostatic Imbalances

Hormone	Effects of hyposecretion	Effects of hypersecretion
Growth hormone	<i>In children:</i> pituitary dwarfism , which results in short stature with normal proportions	<i>In children:</i> gigantism , abnormally tall <i>In adults:</i> acromegaly , abnormally large bones of the face, feet, and hands
Antidiuretic hormone	Diabetes insipidus , a condition characterized by thirst and excessive urine output	Syndrome of inappropriate ADH secretion , a condition characterized by fluid retention, headache, and disorientation
Thyroid hormone	<i>In children:</i> cretinism , mental retardation with a disproportionately short-sized body <i>In adults:</i> myxedema , low metabolic rate, edema, physical and mental sluggishness	Graves' disease , elevated metabolic rate, sweating, irregular heart rate, weight loss, protrusion of the eyeballs, and nervousness
Parathyroid hormone	Hypoparathyroidism , neural excitability with tetany (muscle spasms) and convulsions	Hyperparathyroidism , loss of calcium from bones, causing deformation, and spontaneous fractures
Insulin	Diabetes mellitus , which results in an inability of cells to take up and utilize glucose and in loss of glucose in the urine (may be due to hyposecretion or hypoactivity of insulin)	Hypoglycemia , which results in low blood sugar and is characterized by anxiety, nervousness, tremors, and weakness

Pineal Gland

The small, pinecone-shaped *pineal gland* hangs from the roof of the third ventricle of the brain. Its major endocrine product is **melatonin**, which appears to be involved in the sleep-wake

cycle. Melatonin levels peak at night, making us drowsy, and are lowest around noon. Recent evidence suggests that melatonin has anti-aging properties. Melatonin appears to play a role in the production of antioxidants.

Endocrine Disorders

Many endocrine disorders are a result of either hyposecretion (underproduction) or hypersecretion (overproduction) of a given hormone. The characteristics of select endocrine disorders are summarized in **Table 18.6**. As you read through the table, recall the targets for the hormones and the effects of normal secretion levels.

Activity 5

Identifying the Endocrine Organs

Locate the endocrine organs on **Figure 18.2**, and complete the labeling of that figure. Also locate these organs on the anatomical charts or torso.

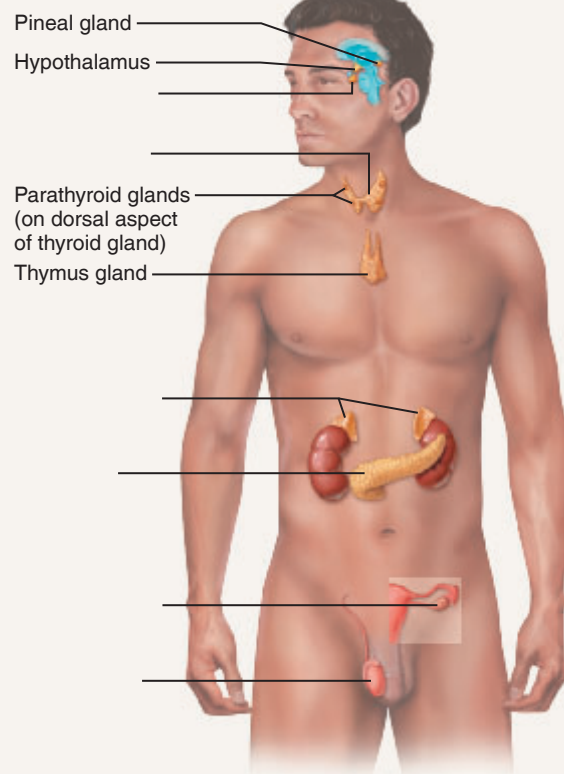


Figure 18.2 Human endocrine organs.

EXERCISE
18

REVIEW SHEET

Functional Anatomy of the Endocrine Glands

Name _____ Lab Time/Date _____

Gross Anatomy and Basic Function of the Endocrine Glands

1. The endocrine and nervous systems are major regulating systems of the body. However, the nervous system has been compared to a text message and the endocrine system to mailing a letter. Briefly explain this comparison.

2. Define *hormone*: _____

3. Chemically, hormones belong chiefly to two molecular groups, the _____

and the _____

4. Identify the endocrine organ described by the following statements:

- _____ 1. located in the anterior neck; bilobed gland connected by an isthmus
- _____ 2. produces the hormones that are stored in the posterior pituitary
- _____ 3. a mixed gland, located posterior to the stomach and close to the small intestine
- _____ 4. paired glands suspended in the scrotum
- _____ 5. bilobed gland located in the sella turcica
- _____ 6. found in the pelvic cavity of the female, responsible for ova and female hormone production
- _____ 7. found in the upper thorax overlying the heart; large during youth
- _____ 8. found in the roof of the third ventricle of the brain

5. Although the pituitary gland is sometimes referred to as the "master gland" of the body, the hypothalamus exerts some control over the pituitary gland. How does the hypothalamus control functioning of both the anterior and the posterior pituitary?

6. For each statement describing hormonal effects, identify the hormone(s) involved by choosing a number from key A, and note the hormone's site of production with a letter from key B.

Key A:

- | | |
|----------------|-------------------------------------|
| 1. ACTH | 11. melatonin |
| 2. ADH | 12. oxytocin |
| 3. aldosterone | 13. progesterone |
| 4. epinephrine | 14. prolactin |
| 5. estrogens | 15. PTH |
| 6. FSH | 16. testosterone |
| 7. glucagon | 17. thymosin |
| 8. GH | 18. T ₄ / T ₃ |
| 9. insulin | 19. TSH |
| 10. LH | |

Key B:

- a. adrenal cortex
- b. adrenal medulla
- c. anterior pituitary
- d. hypothalamus
- e. ovaries
- f. pancreas
- g. parathyroid glands
- h. pineal gland
- i. testes
- j. thymus gland
- k. thyroid gland

- _____, _____ **1.** basal metabolism hormone
- _____, _____ **2.** helps program the immune system
- _____, _____ **3.** regulates blood calcium levels
- _____, _____ **4.** released in response to stressors
- _____, _____ and _____, _____ **5.** drives development of secondary sexual characteristics
- _____, _____; _____, _____; _____, _____; and _____, _____ **6.** regulate the function of another endocrine gland
- _____, _____ **7.** mimics the sympathetic nervous system
- _____, _____ and _____, _____ **8.** regulate blood glucose levels; produced by the same "mixed" gland
- _____, _____ and _____, _____ **9.** directly responsible for regulating the menstrual cycle
- _____, _____ and _____, _____ **10.** help maintain salt and water balance in the body fluids
- _____, _____ **11.** involved in milk ejection

7. Name the hormone(s) produced in *inadequate* amounts that directly result in the following conditions.

- _____ **1.** diabetes insipidus
- _____ **2.** tetany
- _____ **3.** diabetes mellitus
- _____ **4.** abnormally small stature, normal proportions
- _____ **5.** myxedema (a lower-than-normal metabolic rate)

8. Name the hormone(s) produced in *excessive* amounts that directly result in the following conditions.

- _____ **1.** in the adult: large bones of the hands, feet, and face
- _____ **2.** nervousness, irregular pulse rate, sweating
- _____ **3.** demineralization of bones, spontaneous fractures

Observing the Effects of Hyperinsulinism


9. Briefly explain what was happening within the fish's system when the fish was immersed in the insulin solution.


10. What is the mechanism of the recovery process you observed? _____

11. What would you do to help a friend who had inadvertently taken an overdose of insulin? _____

_____ Why? _____

12. What is a glucose tolerance test? (Use an appropriate reference, as necessary, to answer this question.)

13.  Pituitary gland tumors can secrete excess amounts of growth hormone. Describe the signs and symptoms that these tumors cause in an adult experiencing hypersecretion of the growth hormone. _____

14.  Tumors of the adrenal medulla, called pheochromocytomas, cause hypersecretion of catecholamines. Describe the expected signs and symptoms of this tumor. _____

This page intentionally left blank

Materials

- Models and charts of blood cells
- Safety glasses (provided by students)
- Demonstration area: Five stations of microscopes set up under oil of human blood smears with a pointer to each of the formed elements, in order:

Station 1: Neutrophil pointed out; surrounded by erythrocytes

Station 2: Eosinophil

Station 3: Basophil

Station 4: Lymphocyte

Station 5: Monocyte

General Supply Area

- Plasma (obtained from an animal hospital or prepared by centrifuging animal [e.g., cattle or sheep] blood obtained from a biological supply house)
- Wide-range pH paper
- Test tubes and test tube racks
- Heparinized animal blood (if desired by the instructor) obtained from a biological supply house or animal hospital (e.g., dog blood) or EDTA-treated red cells (reference cells) with blood-type labels obscured (available from Immunocor, Inc.)
- Clean microscope slides
- Sterile lancets
- Alcohol swabs (wipes)
- Absorbent cotton balls
- Disposable gloves
- Bucket or large beaker containing 10% household bleach solution for slide and glassware disposal
- Spray bottles containing 10% bleach solution
- Disposable autoclave bag: Because many blood tests are to be conducted in this exercise, it is advisable to set up a number of appropriately labeled supply areas for the various tests, as designated next.

Hematocrit Supply Area

- Heparinized capillary tubes
- Microhematocrit centrifuge and reading gauge (if the reading gauge is not available, millimeter ruler may be used)

Text continues on next page. →

Learning Outcomes

- State the average percentage of plasma and formed elements in whole blood.
- Describe the composition and functions of plasma.
- Identify each of the formed elements when presented with a microscopic preparation or a photo, and cite their relative percentages and functions.
- Conduct the following blood tests in the laboratory, and state the norms and importance of each: hematocrit, hemoglobin determination, clotting time, and ABO and Rh blood typing.
- Discuss the reason for transfusion reactions resulting from administration of mismatched blood.

In this exercise, you will study plasma and formed elements of blood and conduct various hematologic tests. These tests are useful diagnostic tools for the physician because blood composition reflects the status of many body functions and malfunctions.



Alert: Special precautions when handling blood. Your instructor will decide whether to use animal blood for testing or to have students test their own blood in accordance with the educational goals of the student group. For example, for students in the nursing or laboratory technician curricula, learning how to safely handle human blood or other human wastes is essential. If human blood is being tested—whether your blood or blood obtained from a clinical agency—gloves and safety glasses must be worn, and precautions provided in the text for disposal of human waste *must be observed*. All soiled glassware is to be immersed in household bleach solution immediately after use, and disposable items (lancets, cotton balls, alcohol swabs, etc.) are to be placed in designated disposal containers so that they can be sterilized before disposal.

Composition of Blood

Circulating blood is a rather viscous substance that varies from bright red to a dull brick-red, depending on the amount of oxygen it is carrying. Oxygen-rich blood is bright red. The circulatory system of the average adult contains about 5.5 liters of blood. More than 100 different substances are dissolved or suspended in plasma (**Figure 19.1**), which is over 90% water. The composition of the blood varies continuously as cells remove or add substances to the blood.

Blood is classified as a type of connective tissue because it consists of cells within a matrix. The nonliving fluid matrix is the **plasma**, and the cells and cell fragments are the **formed elements**. The fibers typical of a connective tissue matrix become visible in blood only when clotting occurs. They then appear as fibrin threads, which form the framework for clot formation.

Three main types of formed elements are present in blood. The most numerous are the **erythrocytes**, or **red blood cells (RBCs)**, which are literally sacs of hemoglobin molecules that transport oxygen (and a small amount of carbon dioxide). **Leukocytes**, or **white blood cells (WBCs)**, are part of the body's non-specific defenses and the immune system, and **platelets** function in hemostasis (blood clot formation). Formed elements normally account for about 45% of whole blood, plasma for the remaining 55%.

(Materials list continued)

- Capillary tube sealer or modeling clay

Hemoglobin Determination Supply Area

- Tallquist hemoglobin scales and test paper or a hemoglobinometer, hemolysis applicator, and lens paper

Coagulation Time Supply Area

- Capillary tubes (nonheparinized)
- Fine triangular file

Blood Typing Supply Area

- Blood-typing sera (anti-A, anti-B, and anti-Rh [anti-D])

- Rh typing box
- Wax marker
- Toothpicks
- Blood test cards or clean microscope slides
- Medicine dropper

Activity 1

Determining the Physical Characteristics of Plasma

Go to the general supply area, and carefully pour a few milliliters of plasma into a test tube. Also obtain some wide-range pH paper, and then return to your laboratory bench to make the following simple observations.

pH of Plasma

Test the pH of the plasma with wide-range pH paper. Record the pH observed.

Color and Clarity of Plasma

Hold the test tube up to a source of natural light. Note and record its color and degree of transparency. Is it clear, translucent, or opaque?

Color _____

Degree of transparency _____

Consistency

While wearing gloves, dip your finger and thumb into the plasma, and then press them firmly together for a few seconds. Gently pull them apart. How would you describe the consistency of plasma? Slippery, watery, sticky, or granular? Record your observations.

Activity 2

Examining the Formed Elements of Blood Microscopically

In this section, you observe blood cells on already prepared (purchased) blood slides. Go to the demonstration area where several formed elements are pointed out, and examine each slide in order as you read the following descriptions of cell types and find each one on Figure 19.1 and in the photomicrographs (Plates 50–55 in the Histology Atlas).

Erythrocytes

At station 1, observe the erythrocytes, the cells that are the most numerous on this slide. (See Plate 50 in the Histology Atlas.) Erythrocytes average 7.5 μm in diameter and vary in color from an orange-pink to pale pink,

depending on the effectiveness of the stain. Notice their biconcave disc shape and that they appear paler in the center than at the edge.

Red blood cells differ from the other blood cells because they are anucleate when mature. As a result, they are unable to reproduce and have a limited life span of 100 to 120 days, after which they begin to fragment.

Leukocytes

Leukocytes, or white blood cells, are more typical cells than the erythrocytes because they contain a nucleus. Much less numerous than the red blood cells, white blood cells are protective, pathogen-destroying cells that are transported to all parts of the body in the blood or lymph. They are classified into two major groups, depending on whether or not they contain conspicuous granules in their cytoplasm.

Granulocytes make up the first group. The granules in their cytoplasm stain differentially with Wright's stain, and they have peculiar nuclei, which often consist of lobes of nuclear material connected by thin strands of nucleoplasm. There are three types of granulocytes:

- **Neutrophil:** Still at the first microscope, turn your attention to the cell at the end of the pointer, a neutrophil. Neutrophils represent 50% to 70% of the leukocyte population. Typically, their nucleus consists of three to seven lobes. Their pale lilac cytoplasm contains very fine cytoplasmic granules, which take up both the acidic (red) and basic (blue) dyes (*neutrophil* = neutral loving). Neutrophils function as active phagocytes, and their number increases explosively during acute infections. Compare to views in Plate 51 in the Histology Atlas.
- **Eosinophil:** Go to station 2 to study the eosinophil, which represents 2% to 4% of the leukocytes. Observe its nucleus, which is generally figure 8 or bilobed in shape, and its large cytoplasmic granules, that stain red-orange with Wright's stain. Eosinophils increase in number during allergies and parasite infections. Compare to Plate 54 in the Histology Atlas.
- **Basophil:** At station 3, view the rarest of the WBCs, a basophil, which represents 0.5% to 1% of the population. Notice its large U- or S-shaped nucleus and its coarse, sparse granules that stain deep purple with Wright's stain. The granules contain several chemicals, including histamine, a vasodilator that helps mediate the inflammatory response. Compare to Plate 55 in the Histology Atlas.

Agranulocytes, the second group, contain no observable cytoplasmic granules. Although found in the bloodstream, these WBCs are much more abundant in lymphoid

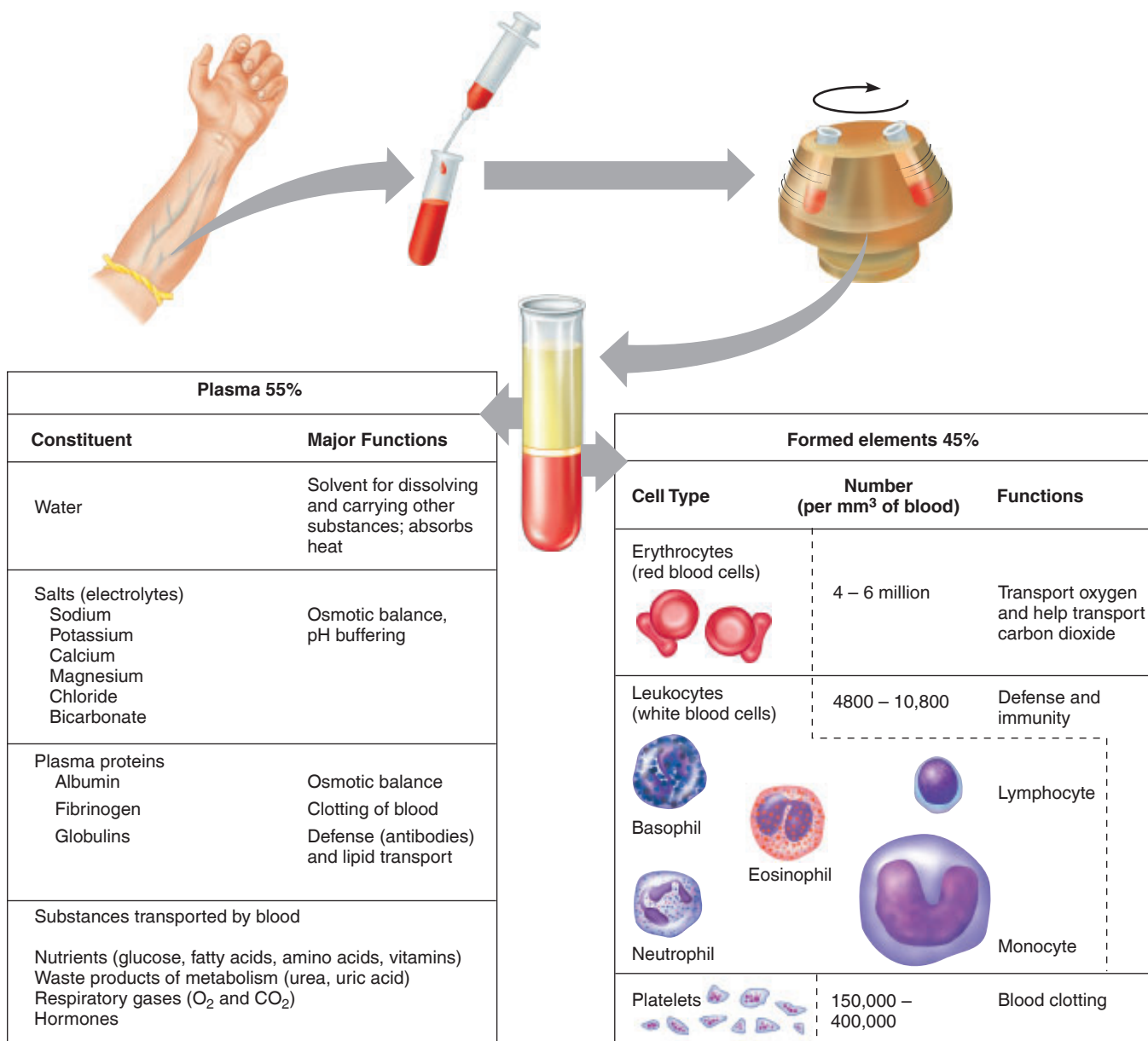


Figure 19.1 The composition of blood.

tissues. Their nuclei tend to be closer to the norm, that is, spherical, oval, or kidney-shaped. There are two types:

- Lymphocyte:** At station 4, observe the smallest of the leukocytes, which is approximately the size of a red blood cell. Notice the large dark blue to purple, generally spherical or slightly indented nucleus. Sparse cytoplasm appears as a thin blue rim around the nucleus. Lymphocytes, which function as “warriors” of the immune system, represent 25% to 45% of the WBC population. Compare to Plate 52 in the Histology Atlas.
- Monocyte:** At station 5, view a monocyte, the largest of the leukocytes, which is approximately twice the size of red blood cells. Monocytes represent 3% to 8% of leukocytes. The dark blue nucleus is generally U- or kidney-shaped, and its abundant cytoplasm stains gray-blue. In tissues, it develops into a macrophage that phagocytizes pathogens or debris, increasing

dramatically in number during chronic infections such as tuberculosis. See also Plate 53 in the Histology Atlas.


Students are often asked to list the leukocytes in order from the most abundant to the least abundant. The following silly phrase may help you with this task: *Never let monkeys eat bananas* (neutrophils, lymphocytes, monocytes, eosinophils, basophils).

Platelets

Also at station 5, notice the small clusters of dark-staining, irregularly shaped bodies that appear much smaller than the other formed elements; these are platelets. Platelets are cell fragments of large multinucleate cells called **megakaryocytes**. The normal platelet count in blood ranges from 150,000 to 400,000 per cubic millimeter. Platelets are needed for the clotting process that occurs in plasma when blood vessels are ruptured.

Hematologic Tests

When someone enters a hospital as a patient, several hematologic (blood) tests are routinely done to determine general level of health as well as the presence of pathological conditions. You will be conducting a few of these tests in this exercise.

 Materials such as cotton balls, lancets, and alcohol swabs are used in nearly all of the following diagnostic tests. These supplies are at the general supply area and should be properly disposed of (glassware to the “bleach bucket,” disposable items to the autoclave bag, and lancets in a designated sharps disposal container) immediately after use.

Other necessary supplies and equipment are at specific supply areas marked according to the test with which they are used. Since nearly all of the tests require a finger stick, if you will be using your own blood it might be wise to quickly read through the tests to determine when more than one test can be done from the same finger stick. A little planning will save you the discomfort of multiple finger sticks.

An alternative to using your own blood is using heparinized blood samples supplied by your instructor. The purpose of using heparinized tubes is to prevent the blood from clotting. Thus blood collected and stored in such tubes will be suitable for all tests *except* coagulation-time testing.

Total White and Red Blood Cell Counts

The hand-counting technique for determining total white and red blood cell counts, typically done in student labs, is rather outdated because most clinical agencies now have computerized equipment for performing blood counts. Hence these will not be among the tests done during this lab session. It is important, however, to know the typical blood count values of healthy individuals and to understand what abnormal counts might indicate.

Averaging 4800 to 10,800 cells per μl , white blood cells are an important part of the body’s defense system, so it is essential to note any abnormalities in them. Leukocytosis, an abnormally high WBC count, may indicate bacterial or viral infection, hemorrhage, or poisoning by drugs or chemicals. An abnormally low white blood cell count (leukopenia) may indicate measles, infectious hepatitis or cirrhosis, tuberculosis, or excessive antibiotic or X-ray therapy. A person with leukopenia lacks the usual protective mechanisms. Leukemia, a malignant disorder of the lymphoid tissues characterized by uncontrolled cell division of abnormal WBCs and a reduction in the number of RBCs and platelets, is detectable not only by a total WBC count but also by a differential WBC count (a count of the relative number of each WBC seen on the slide).

The red blood cell count, like the white blood cell count, determines the total number of this cell type per unit volume of blood. Normally the RBC count averages 4.2 to 5.4 million/ μl for women and 4.7 to 6.1 million/ μl for men. Since RBCs are absolutely necessary for oxygen transport, a doctor typically investigates any excessive change in their number immediately.

An increase in the number of RBCs (**polycythemia**) may result from bone marrow cancer or from living at high altitudes where less oxygen is available. A decrease in the number of RBCs results in anemia. The term **anemia** simply indicates a decreased oxygen-carrying capacity of blood that may result from a decrease in RBC number or size or a decreased hemoglobin content of the RBCs.

Hematocrit

The **hematocrit** is routinely done when anemia is suspected. Centrifuging whole blood spins the formed elements to the bottom of the tube, with plasma forming the top layer (see Figure 19.1). Since the blood cell population is mostly RBCs, the hematocrit is generally considered equal to the RBC volume, and this is the only value reported. However, the relative percentage of WBCs can be differentiated, and both WBC and plasma volume will be reported here. Normal hematocrit values for the male and female, respectively, are 42–52% and 37–47%.

Activity 3

Determining the Hematocrit

The hematocrit is determined by the micromethod, so only a drop of blood is needed. If possible (and if the centrifuge allows), all members of the class should prepare their capillary tubes at the same time so the centrifuge can be properly balanced and run only once.

1. Obtain two heparinized capillary tubes, capillary tube sealer or modeling clay, a lancet, alcohol swabs, and some cotton balls.

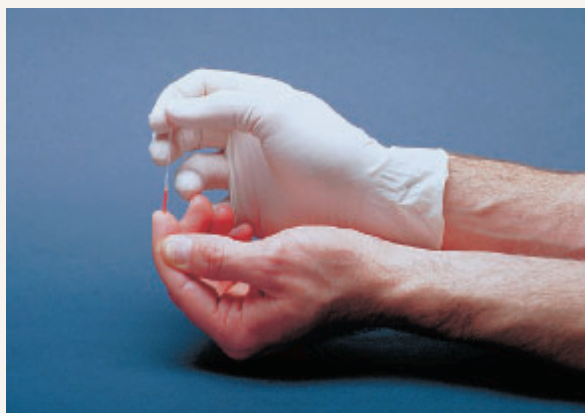2. If you are using your own blood, open the alcohol packet, and scrub your third or fourth finger with the swab. Swing (circumduct) your arm for 10 to 15 seconds. This will dry the alcohol and cause your fingers to become engorged with blood. Then open the lancet packet, and grasp the lancet by its blunt end. Quickly jab the pointed end into the prepared finger to produce a free flow of blood. Wipe away the first few drops with a cotton ball, and, holding the red-line-marked end of the capillary tube to the blood drop, allow the tube to fill at least three-fourths full by capillary action (**Figure 19.2a**). If the blood is not flowing freely, the end of the capillary tube will not be completely submerged in the blood during filling, air will enter, and you will have to prepare another sample.

If you are using instructor-provided blood, simply immerse the red-marked end of the capillary tube in the blood sample, and fill it three-quarters full as just described.

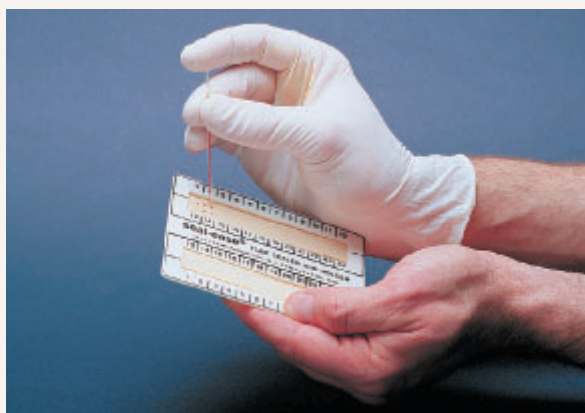3. Plug the blood-containing end by pressing it into the capillary tube sealer or clay (Figure 19.2b). Prepare a second tube in the same manner.

4. Place the prepared tubes opposite one another in the radial grooves of the microhematocrit centrifuge with the sealed ends abutting the rubber gasket at the centrifuge periphery (Figure 19.2c). This loading procedure balances the centrifuge and prevents blood from spraying everywhere by centrifugal force. *Make a note of the numbers of the grooves your tubes are in.* When all the tubes have been loaded, make sure the centrifuge is properly balanced, and secure the centrifuge cover. Turn the centrifuge on, and set the timer for 4 or 5 minutes.

5. Determine the percentage of RBCs, WBCs, and plasma by using the microhematocrit reader. The RBCs are the bottom layer, the plasma is the top layer, and the WBCs are the buff-colored layer between the two.



(a)



(b)



(c)

Figure 19.2 Steps in a hematocrit determination. (a) Fill a heparinized capillary tube with blood. (b) Plug the blood-containing end of the tube with clay. (c) Place the tube in a microhematocrit centrifuge. (Centrifuge must be balanced.)

If the reader is not available, use a millimeter ruler to measure the length of the filled capillary tube occupied by each element, and compute its percentage by using the following formula:

$$\frac{\text{Length of the column composed of the element (mm)}}{\text{Length of the original column of whole blood (mm)}} \times 100$$

Record your calculations below.

% RBC _____ % WBC _____ % plasma _____

Usually WBCs constitute 1% of the total blood volume. How do your blood values compare to this figure and to the normal percentages for RBCs and plasma?

As a rule, a hematocrit is considered a more accurate test for determining the RBC composition of the blood than the total RBC count. A hematocrit within the normal range generally indicates a normal RBC number, whereas an abnormally high or low hematocrit is cause for concern.

Hemoglobin Concentration

A person can be anemic even with a normal RBC count. Because hemoglobin is the RBC protein responsible for oxygen transport, perhaps the most accurate way of measuring the oxygen-carrying capacity of the blood is to determine its hemoglobin content. Oxygen, which combines with the heme (iron-containing portion) of the hemoglobin molecule, is picked up by the blood cells in the lungs and unloaded in the tissues. Thus, the more hemoglobin molecules the RBCs contain, the more oxygen they will be able to transport. Normal hemoglobin content in men is slightly higher (13 to 18 g) than in women (12 to 16 g).

Activity 4

Determining Hemoglobin Concentration

Several techniques have been developed to estimate the hemoglobin content of blood, ranging from the old, rather inaccurate Tallquist method to expensive hemoglobinometers that are precisely calibrated and yield highly accurate results. Directions for both the Tallquist method and a hemoglobinometer are provided here. Your instructor will indicate which technique you will be using.

Using the Tallquist Method

1. Obtain a Tallquist hemoglobin scale, lancets, alcohol swabs, and cotton balls.
2. Use instructor-provided animal blood, or prepare the finger as previously described. (For best results, make sure the alcohol evaporates before puncturing your finger.) Place one good-sized drop of blood on the special absorbent paper provided with the color chart. The blood stain should be larger than the holes on the color chart.

Text continues on next page. →

3. As soon as the blood has dried and loses its glossy appearance, match its color, under natural light, with the color standards by moving the specimen under the comparison chart so that the blood stain appears at all the various openings. (Do not allow the blood to dry to a brown color, as this will result in an inaccurate reading.) If the color of your blood sample is intermediate between two color standards, it may be necessary to estimate the percentage of hemoglobin.

4. Record your results as the percentage of hemoglobin concentration and as grams per 100 ml of blood, below.

_____ g/100 ml blood _____ %

5. Dispose of the blood-stained paper in the autoclave bag.

Using a Hemoglobinometer

1. Obtain a hemoglobinometer, hemolysis applicator stick, alcohol swab, and lens paper, and bring them to your bench. Test the hemoglobinometer light source to

make sure it is working; if not, obtain new batteries before proceeding and test it again.

2. Remove the blood chamber from the slot in the side of the hemoglobinometer. Disassemble the chamber by separating the glass plates from the metal clip. Notice as you do this that the larger glass plate has an H-shaped depression cut into it that acts as a moat to hold the blood, whereas the smaller glass piece is flat and serves as a coverslip.

3. Clean the glass plates with an alcohol swab, and then wipe dry with lens paper. Hold the plates by their sides to prevent smearing during the wiping process.

4. Reassemble the blood chamber (remember: larger glass piece on the bottom with the moat up), and leave the moat plate about halfway out to provide adequate exposed surface to charge it with blood.

5. Obtain a drop of blood (from the provided animal blood sample or from your fingertip as before), and place it on the depressed area of the moat plate that is closest to you (**Figure 19.3a**).



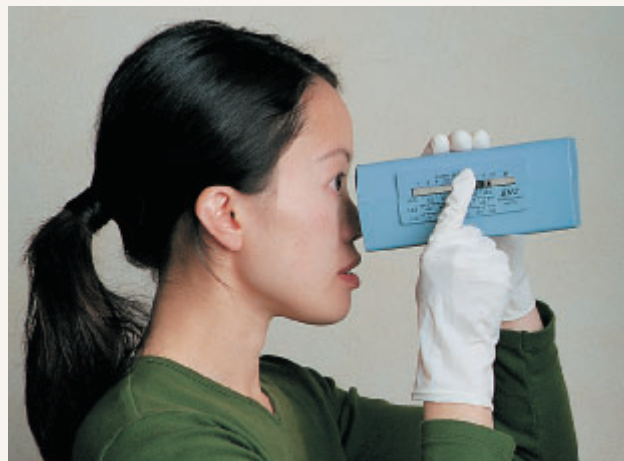(a) A drop of blood is added to the moat plate of the blood chamber. The blood must flow freely.



(b) The blood sample is hemolyzed with a wooden hemolysis applicator. Complete hemolysis requires 35 to 45 seconds.



(c) The charged blood chamber is inserted into the slot on the side of the hemoglobinometer.



(d) The colors of the green split screen are found by moving the slide with the right index finger. When the two colors match in density, the grams/100 ml and % Hb are read on the scale.

Figure 19.3 Hemoglobin determination using a hemoglobinometer.

6. Using the wooden hemolysis applicator, stir the blood to rupture (lyse) the RBCs (Figure 19.3b). This usually takes 35 to 45 seconds. Hemolysis is complete when the blood appears transparent rather than cloudy.
7. Push the blood-containing glass plate all the way into the metal clip, and then firmly insert the charged blood chamber back into the slot on the side of the instrument (Figure 19.3c).
8. Hold the hemoglobinometer in your left hand with your left thumb resting on the light switch located on the underside of the instrument. Look into the eyepiece, and notice that there is a green area divided into two halves (a split field).
9. With the index finger of your right hand, slowly move the slide on the right side of the hemoglobinometer back and forth until the two halves of the green field match (Figure 19.3d).

10. Record below the grams Hb (hemoglobin)/100 ml blood indicated on the uppermost scale by the index mark on the slide. Also record % Hb, indicated by one of the lower scales.

Hemoglobinometer type:

_____ g/100 ml blood _____ %

11. Disassemble the blood chamber once again, and carefully place its parts (glass plates and clip) into a bleach-containing beaker.

Generally speaking, the relationship between the hematocrit and grams of hemoglobin per 100 ml of blood is 3:1. How do your values compare?

Coagulation Time

Hemostasis is a protective mechanism that is set into motion when a blood vessel breaks. Hemostasis responds rapidly to stop bleeding. During hemostasis, three events occur in the following order: vascular spasm, platelet plug formation, and coagulation (blood clotting). Platelet plug formation and coagulation are illustrated in **Figure 19.4**.

Blood clotting, or **coagulation**, is a process that requires the interaction of many substances normally present in the plasma, as well as some released by platelets and injured tissues. The injured tissues and platelets release **tissue factor (TF)** and **phosphatidylserine** (formerly known as **platelet factor 3**), respectively, which trigger the clotting mechanism, or cascade. Tissue factor and phosphatidylserine interact with other blood clotting factors and calcium ions to form **prothrombin activator**, which in turn converts **prothrombin** (present in plasma) to **thrombin**. Thrombin then acts enzymatically to polymerize (combine) the soluble **fibrinogen** proteins (present in plasma) into insoluble **fibrin**, which forms a meshwork of strands that traps the RBCs and forms the basis of the clot. Normally, blood removed from the body clots within 2 to 6 minutes.

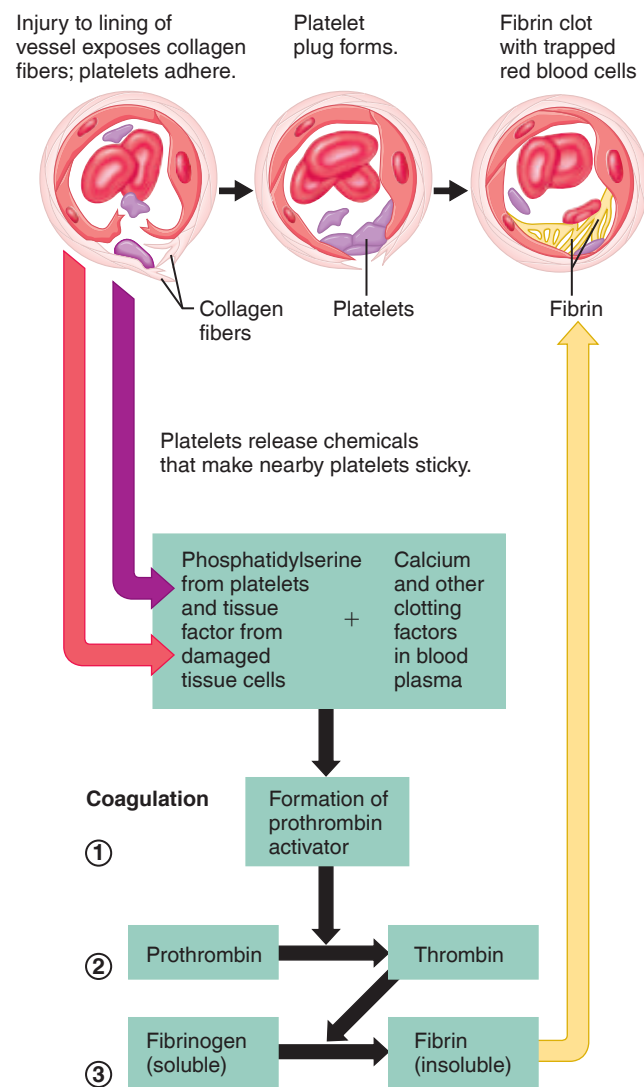


Figure 19.4 Events of platelet plug formation and coagulation. The color of the arrows indicates their source or destination: red from tissue, purple from platelets, and yellow to fibrin. Steps 1–3 are the major phases of coagulation.

Activity 5

Determining Coagulation Time

1. Obtain a *nonheparinized* capillary tube, a lancet, cotton balls, a triangular file, and alcohol swabs.
2. Clean and prick a finger to produce a free flow of blood. Discard the lancet in the disposal container.
3. Place one end of the capillary tube in the blood drop, and hold the opposite end at a lower level to collect the sample.
4. Lay the capillary tube on a paper towel after collecting the sample.

Record the time. _____

Text continues on next page. →

Table 19.1 ABO Blood Groups

ABO blood type	Antigens present on RBC membranes	Antibodies present in plasma	% of U.S. population		
			White	Black	Asian
A	A	Anti-B	40	27	28
B	B	Anti-A	11	20	27
AB	A and B	None	4	4	5
O	Neither	Anti-A and anti-B	45	49	40

5. At 30-second intervals, make a small nick on the tube close to one end with the triangular file, and then carefully break the tube. Slowly separate the ends to see whether a gel-like thread of fibrin spans the gap. When this occurs, record below and on the data sheet the time it took for coagulation to occur. Are your results within the normal time range?

6. Dispose of the capillary tube and used supplies in the disposable autoclave bag.

Blood Typing

Blood typing is a system for classifying blood based on specific glycoproteins present on the outer surface of the RBC plasma membrane. Such proteins are called **antigens** or **agglutinogens** and they are genetically determined. For ABO blood groups, these antigens are accompanied by plasma proteins, which are **antibodies** or **agglutinins**. These antibodies act against RBCs carrying antigens that are not present on the person's own RBCs. If the donor blood type doesn't match, the recipient's antibodies react with the donor's blood antigens, causing the RBCs to clump, agglutinate, and eventually hemolyze. It is because of this phenomenon, which occurs in a transfusion reaction, that a person's blood must be carefully typed before a blood transfusion.

Several blood typing systems exist, but the factors routinely typed for are antigens of the ABO and Rh blood groups, which are most commonly involved in transfusion reactions. The basis of the ABO typing is shown in **Table 19.1**.

Individuals whose red blood cells carry the Rh antigen are Rh positive (approximately 85% of the U.S. population); those lacking the antigen are Rh negative. Unlike ABO blood groups, neither Rh-positive (Rh⁺) nor Rh-negative (Rh⁻) blood carries preformed anti-Rh antibodies. This is understandable in the case of the Rh-positive individual. However, Rh-negative persons who receive transfusions of Rh-positive blood become sensitized by the Rh antigens of the donor RBCs, and their systems begin to produce anti-Rh antibodies. On later exposures to Rh-positive blood, typical transfusion reactions occur, resulting in the clumping and hemolysis of the donor blood cells.

Activity 6

Typing for ABO and Rh Blood Groups

1. Obtain two clean microscope slides, a wax pencil, anti-A, anti-B, and anti-Rh typing sera, toothpicks, lancets, alcohol swabs, medicine dropper, and the Rh typing box.

2. Divide slide 1 into two equal halves with the wax marking pencil. Label the lower left-hand corner "anti-A" and the lower right-hand corner "anti-B." Mark the bottom of slide 2 "anti-Rh."

3. Place one drop of anti-A serum on the left side of slide 1. Place one drop of anti-B serum on the right side of slide 1. Place one drop of anti-Rh serum in the center of slide 2.

4. If you are using your own blood, cleanse your finger with an alcohol swab, pierce the finger with a lancet, and wipe away the first drop of blood. Obtain 3 drops of freely flowing blood, placing one drop on each side of slide 1 and a drop on slide 2.

If using instructor-provided animal, EDTA-treated blood, or samples from a simulated blood testing kit, use a medicine dropper to place one drop of blood on each side of slide 1 and a drop of blood on slide 2.



5. Quickly mix each blood-antiserum sample with a *fresh* toothpick. Then dispose of the toothpicks, lancet, and used alcohol swab in the autoclave bag.

6. Place slide 2 on the Rh typing box, and rock gently back and forth. (A slightly higher temperature is required for precise Rh typing than for ABO typing.)

7. After 2 minutes, observe all three blood samples for evidence of clumping. The agglutination that occurs in the positive test for the Rh factor is fine and difficult to interpret. Record your observations in the **Activity 6 chart**.

8. Interpret your ABO results in light of the information in **Figure 19.5**. If you observed clumping on slide 2, you are Rh positive. If not, you are Rh negative.

9. Record your blood type at the top of the chart.

10. Put used slides in the bleach-containing bucket at the general supply area; put disposable supplies in the autoclave bag.

Before leaving the laboratory, obtain a spray bottle containing bleach solution. Spray your laboratory bench with the bleach solution, and wipe dry with a paper towel.

Activity 6: Blood Typing Result		Type _____
Result	Observed (+)	Not observed (-)
Presence of clumping with anti-A		
Presence of clumping with anti-B		
Presence of clumping with anti-Rh		

Blood being tested

Serum

Anti-A

Anti-B

Type AB (contains antigens A and B)



Type B (contains antigen B)



Type A (contains antigen A)



Type O (contains no antigen)

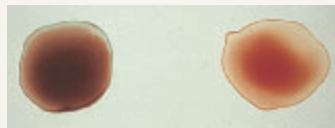

Figure 19.5 Blood typing of ABO blood types. When serum containing anti-A or anti-B antibodies is added to a blood sample, agglutination will occur between the antibody and the corresponding antigen—A or B. As illustrated, agglutination occurs with both sera in blood group AB, with anti-B serum in blood group B, with anti-A serum in blood group A, and with neither serum in blood group O.

This page intentionally left blank

EXERCISE
19

REVIEW SHEET

Blood

Name _____ Lab Time/Date _____

Composition of Blood

1. What is the blood volume of an average-sized adult? _____ liters
2. What determines whether blood is bright red or a dull brick-red? _____

3. Use the key to identify the cell type(s) or blood elements that fit the following descriptive statements. (Some terms may be used more than once.)

Key: basophil	platelets	monocyte
eosinophil	lymphocyte	neutrophil
erythrocyte	megakaryocyte	plasma

- _____ 1. its name means "neutral-loving," a phagocyte
- _____, _____, and _____ 2. granulocytes
- _____ 3. also called a red blood cell
- _____, _____ 4. agranulocytes
- _____ 5. precursor cell of platelets
- _____ 6. cell fragments
- _____ 7. number rises during parasite infections
- _____ 8. releases a vasodilator; the least abundant WBC
- _____ 9. transports oxygen
- _____ 10. primarily water, noncellular; the fluid matrix of blood
- _____ 11. develops into a macrophage
- _____, _____, _____,
- _____, _____ 12. the five types of white blood cells

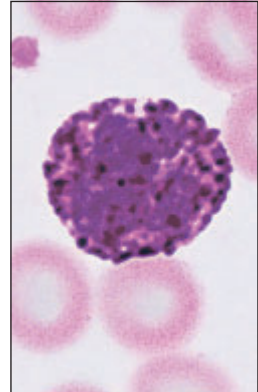
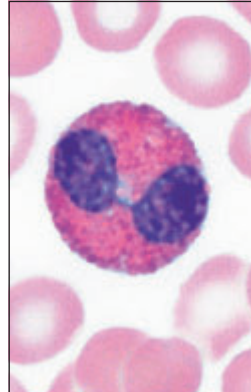
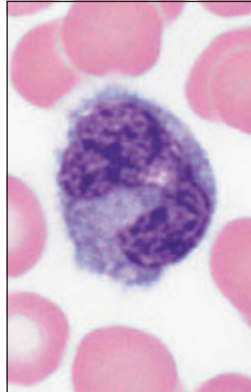
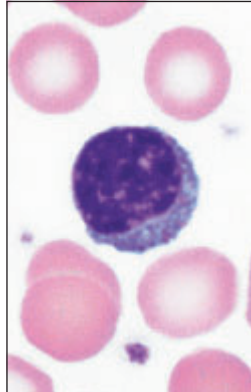
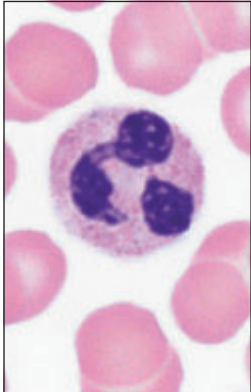
4. Define *formed elements*: _____

List the formed elements present in the blood. _____

5. Describe the consistency and color of the plasma you observed in the laboratory. _____

6. What is the average life span of a red blood cell? How does its anucleate condition affect this life span?

7. Identify the leukocytes shown in the photomicrographs below.



8. Correctly identify the blood pathologies described in column A by matching them with selections from column B:

Column A

Column B

_____ 1. abnormal increase in the number of WBCs

anemia

_____ 2. abnormal increase in the number of RBCs

leukocytosis

_____ 3. condition of too few RBCs or of RBCs with hemoglobin deficiencies

leukopenia

_____ 4. abnormal decrease in the number of WBCs

polycythemia

Hematologic Tests

9. Broadly speaking, why are hematologic studies of blood so important in diagnosing disease?

10. In the chart that follows, record information from the blood tests you conducted. Complete the chart by recording values for healthy male adults and indicating the significance of high or low values for each test.

Hematologic Tests				
Test	Student test results	Normal values (healthy male adults)	Significance	
			High values	Low values
Total WBC count	No data			
Total RBC count	No data			
Hematocrit				
Hemoglobin determination				
Coagulation time				

11. Define *hematocrit*: _____
12. If you had a high hematocrit, would you expect your hemoglobin determination to be high or low?
 _____ Why? _____

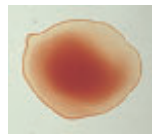
13. If your blood agglutinates with both anti-A and anti-B sera, your ABO blood type would be _____. To what ABO blood groups could you give blood? _____. From which ABO donor types could you receive blood? _____
 Which ABO blood type is most common? _____ Least common? _____ (If necessary, consult your textbook or another reference source.)

14. Explain why an Rh-negative person does not have a transfusion reaction on the first exposure to Rh-positive blood but does have a reaction on the second exposure. _____

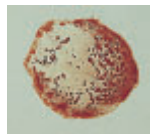
What happens when an ABO blood type is mismatched for the first time? _____

15. Assume the blood of two patients has been typed for ABO blood type.

Typing results
Mr. Adams:

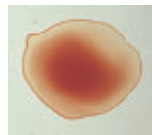


Blood drop and anti-A serum

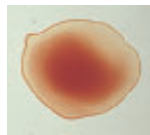


Blood drop and anti-B serum

Typing results
Mr. Calhoon:



Blood drop and anti-A serum



Blood drop and anti-B serum

On the basis of these results, Mr. Adams has type _____ blood, and Mr. Calhoon has type _____ blood.

16. **+** Plasmapheresis is a procedure in which blood is removed, its plasma is separated from the formed elements, and the formed elements are returned to the patient or donor. Kidney transplants usually require that the donor and recipient have the same blood type. If plasmapheresis is administered to the patient before and after the transplant surgery, rejection of the kidney is unlikely to occur. Explain why.

17. **+** Bleeding disorders are usually a result of thrombocytopenia, a deficiency of platelets. Considering the mechanism of hemostasis, explain why thrombocytopenia could lead to abnormal bleeding.

Anatomy of the Heart

Materials

- Torso model or laboratory chart showing heart anatomy
- Heart model (three-dimensional)
- Red and blue pencils
- Three-dimensional models of cardiac and skeletal muscle
- Demonstration area: Compound microscope set up with a longitudinal section cardiac muscle; pointer on an intercalated disc
- Preserved or fresh sheep hearts, pericardial sacs intact (if possible)
- Dissecting tray and instruments
- Pointed glass rods for probes
- Disposable gloves

Learning Outcomes

- Describe the location of the heart.
- Identify the major anatomical areas and structures of the heart on a heart model, diagram, or dissected sheep heart.
- Trace the pathway of blood through the heart, and compare the pulmonary and systemic circuits.
- Trace the functional blood supply of the heart, and name the associated blood vessels.
- Describe the microscopic structure of cardiac muscle, and indicate the importance of intercalated discs.
- Explain the operation of the heart valves.

The major function of the **cardiovascular system** is transportation. Using blood as the transport vehicle, the system carries oxygen, nutrients, cell wastes, electrolytes, and many other substances vital to the body's homeostasis to and from the body cells. The propulsive force is the beating heart, which is essentially a muscular pump equipped with one-way valves. As the heart contracts, it forces blood into a closed system of large and small plumbing tubes (blood vessels) within which the blood circulates.

Gross Anatomy of the Human Heart

The **heart**, a cone-shaped organ approximately the size of a fist, is located within the **mediastinum**. It is flanked laterally by the lungs, posteriorly by the vertebral column, and anteriorly by the sternum (**Figure 20.1**). Its more pointed **apex** extends slightly to the left and rests on the diaphragm, approximately at the level of the fifth intercostal space. Its broader **base**, from which the great vessels emerge, lies beneath the second rib and points toward the right shoulder. In the body, the right ventricle of the heart forms most of its anterior surface.

If you press just below the left nipple, you can feel the apical impulse of your beating heart. Verify the relationships described above on an X-ray image or on **Figure 20.1**.

The heart is enclosed within a double-walled sac called the pericardium. The loose-fitting superficial part of the sac is called the **fibrous pericardium**. Deep to it is the *serous pericardium*, which lines the fibrous pericardium as the **parietal layer**. At the base of the heart, the parietal layer reflects back to cover the external heart as the **visceral layer**, or **epicardium**. Serous fluid produced by these layers allows the heart to beat in a relatively frictionless environment.

The walls of the heart are composed of three layers:

- **Epicardium:** The outer layer, which is also the visceral pericardium.
- **Myocardium:** The middle layer and thickest layer, which is composed mainly of cardiac muscle. It is reinforced with dense fibrous connective tissue, the *cardiac skeleton*, which is thicker around the heart valves and at the base of the great vessels leaving the heart.
- **Endocardium:** The inner lining of the heart, which covers the heart valves and is continuous with the inner lining of the great vessels. It is composed of simple squamous epithelium resting on areolar connective tissue.

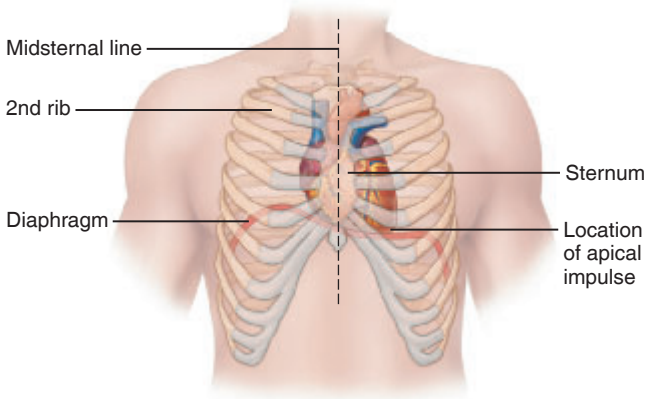


Figure 20.1 Location of the heart in the thorax.

Heart Chambers

The heart has four chambers: two superior **atria** and two inferior **ventricles** (**Figure 20.2**). The septum that divides the heart longitudinally is referred to as the **interatrial septum** where it separates the atria, and the **interventricular septum**, where it separates the ventricles. Functionally, the atria are receiving chambers and are relatively ineffective as pumps.

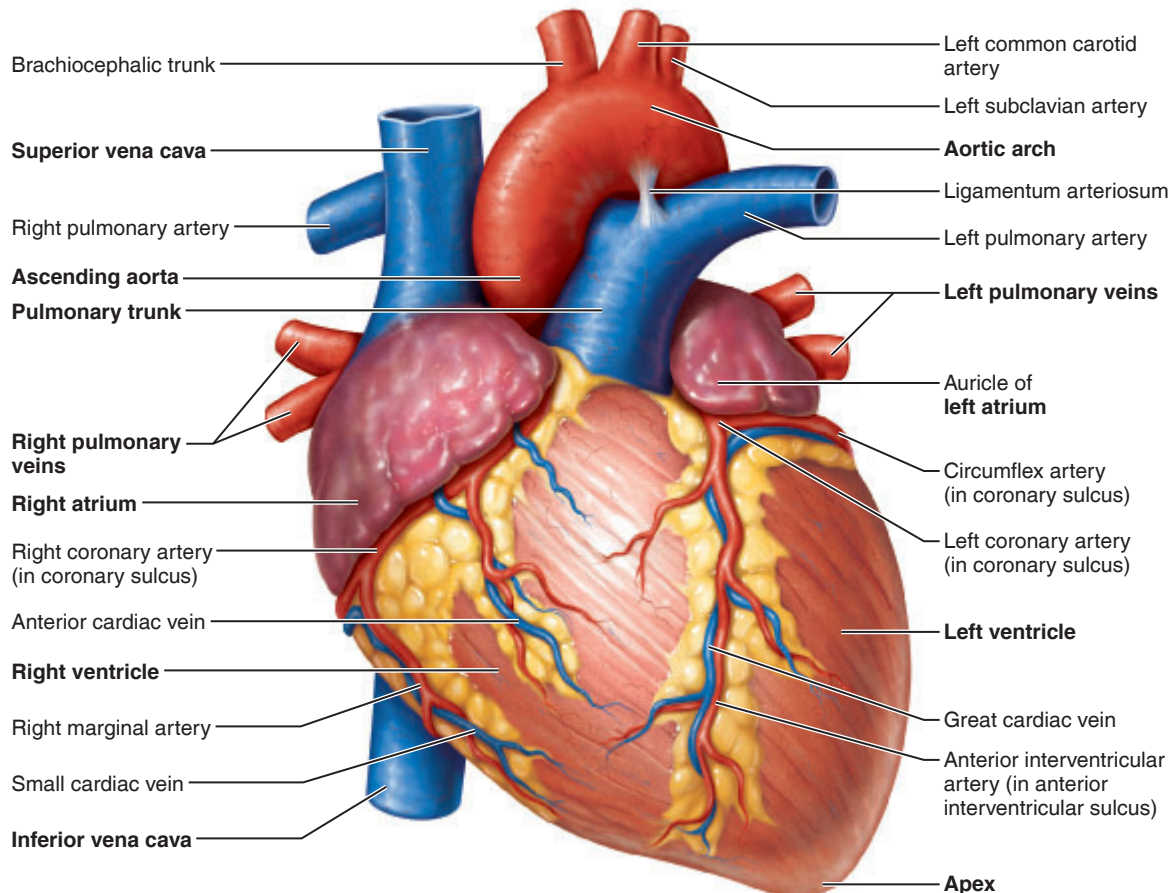
The inferior ventricles, which form the bulk of the heart, are the discharging chambers. They force blood out of the heart into the large arteries that emerge from its base.

Heart Valves

Four valves enforce a one-way blood flow through the heart chambers. The **atrioventricular (AV) valves** are located between the atrium and the ventricle on the left and right side of the heart. The **semilunar (SL) valves** are located between a ventricle and a great vessel.

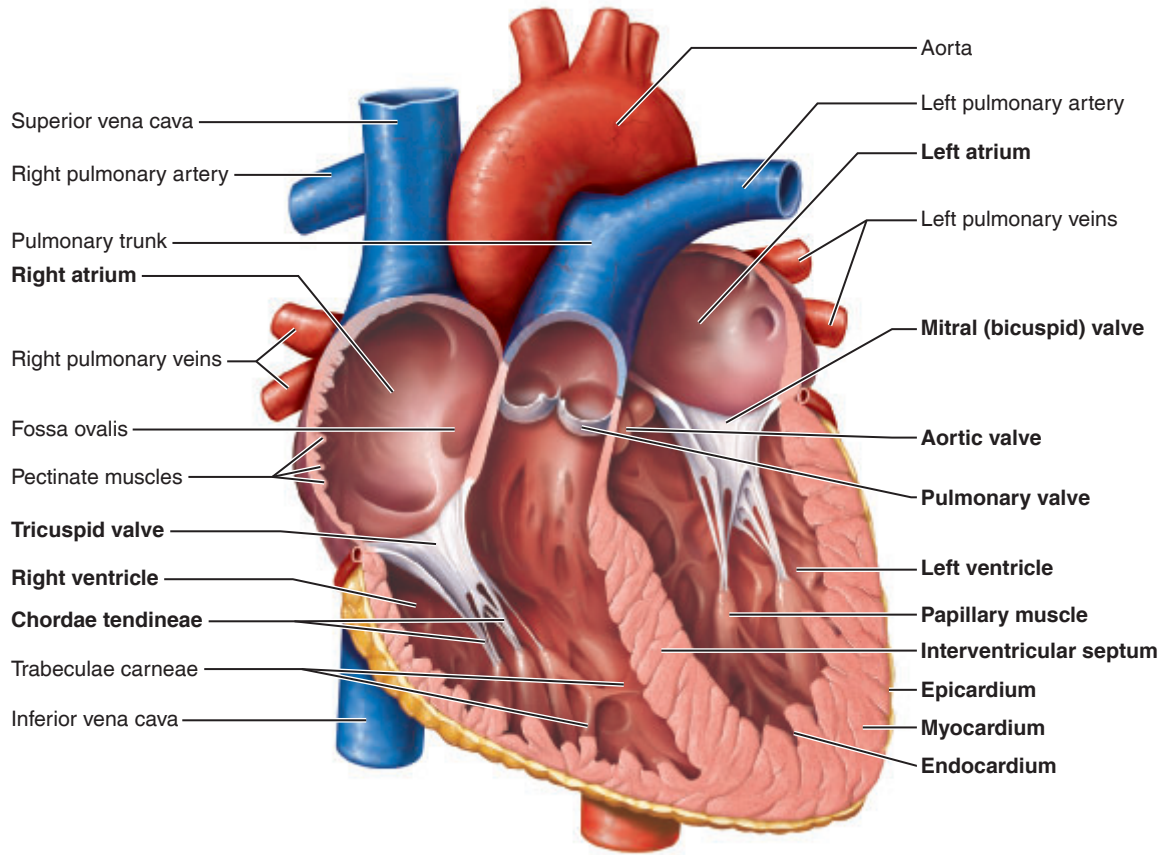
- **Tricuspid valve:** The right AV valve has three flaplike cusps (**Figure 20.2b**) anchored to the **papillary muscles** of the ventricular wall by tiny white collagenic cords called **chordae tendineae** (literally, heart strings)
- **Mitral valve (bicuspid valve):** The left AV valve has two flaplike cusps anchored to the papillary muscles by chordae tendineae.

The AV valves are open and hang into the ventricles when blood is flowing into the atria and the ventricles are relaxed. When the ventricles contract, the blood in the ventricles is compressed, causing the AV valves to move superiorly and close the opening between the atrium and the ventricle. The chordae tendineae, pulled tight by the contracting papillary muscles, anchor the cusps in the closed position and prevent

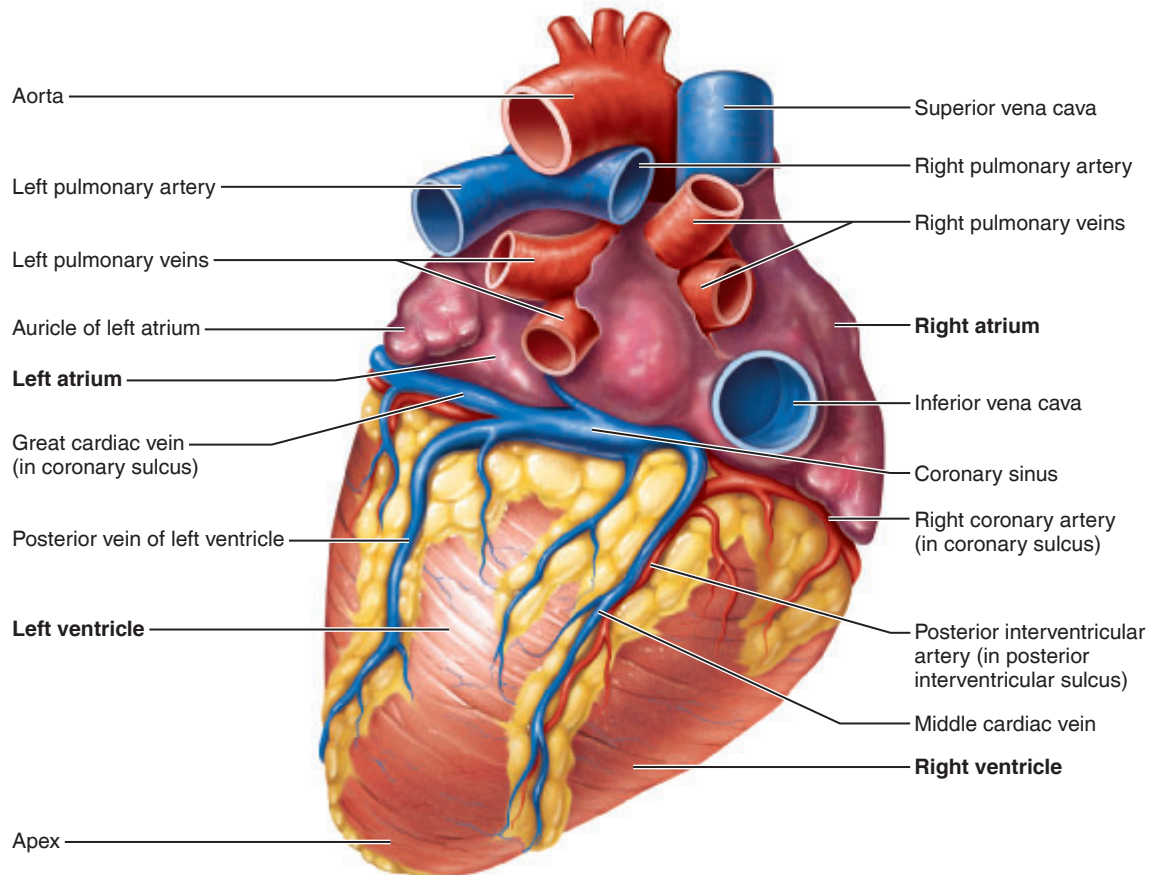


(a)

Figure 20.2 Anatomy of the human heart. (a) Anterior view.



(b)



(c)

Figure 20.2 (continued) (b) Frontal section. (c) External posterior view.

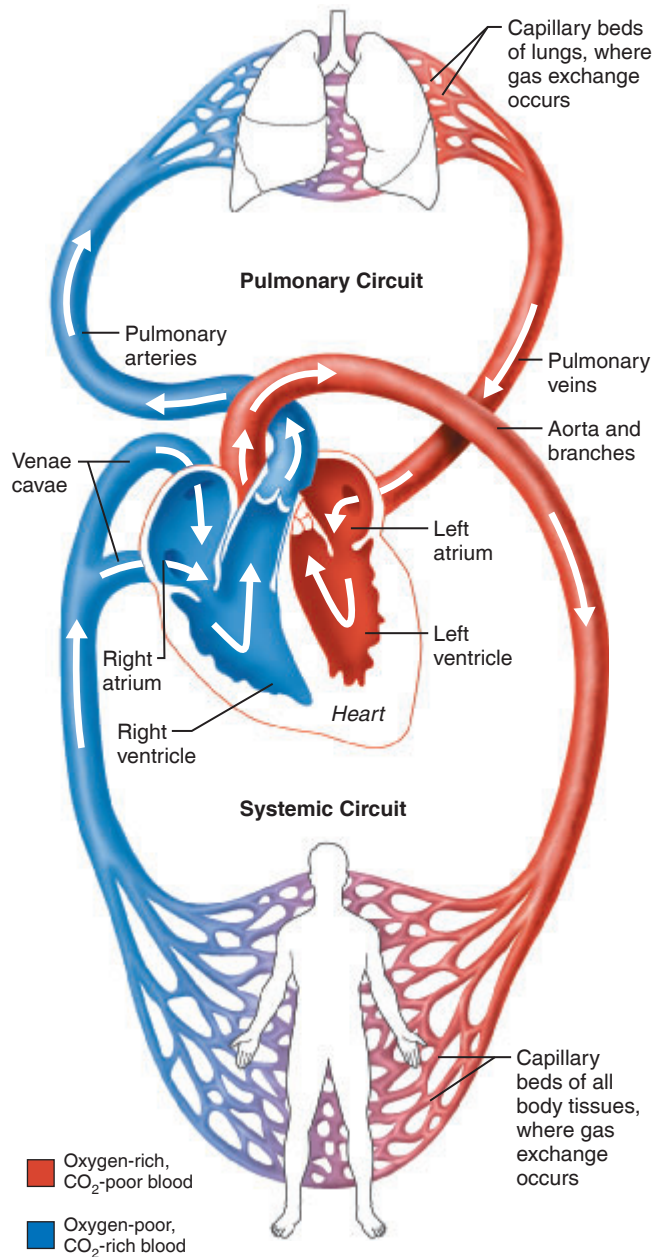


Figure 20.3 The systemic and pulmonary circulations. For simplicity, the actual number of two pulmonary arteries and four pulmonary veins has been reduced to one each in this diagram.

the backflow of blood from the ventricles into the atria. If unanchored, the cusps would move upward into the atria like an umbrella being turned inside out by a strong wind.

- **Pulmonary (SL) valve:** Has three pocketlike cusps located between the right ventricle and the pulmonary trunk.
- **Aortic (SL) valve:** Has three pocketlike cusps located between the left ventricle and the aorta.

The SL valves are open and flattened against the wall of the vessel when the contraction of the ventricles pushes blood into the great vessels. When the ventricles relax, blood flows backward toward the ventricle and the cusps fill with blood, closing the SL valves. This prevents the backflow of blood from the great vessels into the ventricles.

Activity 1

Using the Heart Model to Study Heart Anatomy

Locate in Figure 20.2 all the structures described so far, observe the human heart model, and re-identify the same structures without referring to the figure. Notice how much thicker the myocardium of the left ventricle is than that of the right ventricle. Compare the *shape* of the left ventricular cavity to the shape of the right ventricular cavity. Record your observations on the lines below.

Pulmonary, Systemic, and Coronary Circulations

Pulmonary and Systemic Circuits

The heart functions as a double pump:

- The right side of the heart pumps oxygen-poor blood entering its chambers to the lungs to unload carbon dioxide and to pick up oxygen. The blood vessels that carry blood to and from the lungs form the **pulmonary circuit**. The function of the pulmonary circuit is strictly to provide for gas exchange.
- The left side of the heart pumps oxygenated blood returning from the lungs to the body tissues. The blood vessels that

carry blood to and from all body tissues form the systemic circuit (**Figure 20.3**).

The following steps describe the blood flow through the right side of the heart (pulmonary circuit):

1. The right atrium receives oxygen-poor blood from the body via the **venae cavae** (**superior vena cava** and **inferior vena cava**) and the coronary sinus.
2. From the right atrium, blood flows through the tricuspid valve to the right ventricle.

Table 20.1 Coronary Circulation (Figure 20.2)

Arteries	Description	Areas supplied/branches
Right coronary artery (RCA)	Branches from the ascending aorta just above the aortic valve and encircles the heart in the coronary sulcus.	Its branches include the right marginal artery and the posterior interventricular artery.
Right marginal artery	Branches off the RCA and is located in the lateral portion of the right ventricle.	Supplies the lateral right side of the heart.
Posterior interventricular artery	Branches off the RCA and is located in the posterior interventricular sulcus.	Supplies the posterior walls of the ventricles and the posterior portion of the interventricular septum. Near the apex of the heart it merges (anastomoses) with the anterior interventricular artery.
Left coronary artery (LCA)	Branches from the ascending aorta and passes posterior to the pulmonary trunk.	Its branches include the anterior interventricular artery and the circumflex artery.
Anterior interventricular artery	Branches off the LCA and is located in the anterior interventricular sulcus. This artery is referred to clinically as the left anterior descending artery (LAD).	Supplies the anterior portion of the interventricular septum and the anterior walls of both ventricles.
Circumflex artery	Branches off the LCA: located in the coronary sulcus.	Supplies the left atrium and the posterior portion of the left ventricle.
Veins	Description	Areas drained
Great cardiac vein	Located in the anterior interventricular sulcus, parallel to the anterior interventricular artery.	Anterior portions of the right and left ventricles.
Middle cardiac vein	Located in the posterior interventricular sulcus, parallel to the posterior interventricular artery.	Posterior portions of the right and left ventricles.
Small cardiac vein	Located on the lateral right ventricle, parallel to the right marginal artery.	Lateral right ventricle.
Coronary sinus	Located in the coronary sulcus on the posterior surface of the heart; drains into the right atrium.	The entire heart; the great, middle and small cardiac veins all drain into the coronary sinus.
Anterior cardiac veins	Located on the anterior surface of the right atrium.	They drain directly into the right atrium.

- From the right ventricle, blood flows through the pulmonary valve into the **pulmonary trunk**.
- The pulmonary trunk branches into left and right **pulmonary arteries**, which carry blood to the lungs, where the blood unloads carbon dioxide and picks up oxygen.
- Oxygen-rich blood returns to the heart via four pulmonary veins.

The remaining steps describe the blood flow through the left side of the heart (systemic circuit):

- Oxygen-rich blood enters the left atrium via four pulmonary veins.
- From the left atrium, blood flows through the mitral valve to the left ventricle.
- From the left ventricle, blood flows through the aortic valve to the **aorta**.
- Oxygen-rich blood is delivered to the body tissues by the systemic arteries.

Activity 2

Tracing the Path of Blood Through the Heart

Trace the pathway of blood through the heart by adding arrows to Figure 20.2b. Use red arrows for the oxygen-rich blood and blue arrows for the less oxygen-rich blood.

Coronary Circulation

Even though the heart chambers are bathed with blood almost continually, this blood does not nourish the myocardium. The blood supply that nourishes the heart is provided by the right and left coronary arteries (see Figure 20.2a). **Table 20.1** summarizes the arteries that supply blood to the heart and the veins that drain the blood.

Microscopic Anatomy of Cardiac Muscle

Cardiac muscle is found in only one place—the heart. Because the heart acts as a blood pump, propelling blood to all tissues of the body, cardiac muscle is very important to life. Cardiac muscle is involuntary, ensuring a constant blood supply.

The cardiac cells are arranged in spiral or figure-8-shaped bundles (**Figure 20.4**). When the heart contracts, its internal chambers become smaller (or are temporarily obliterated), forcing the blood upward into the large arteries leaving the heart.

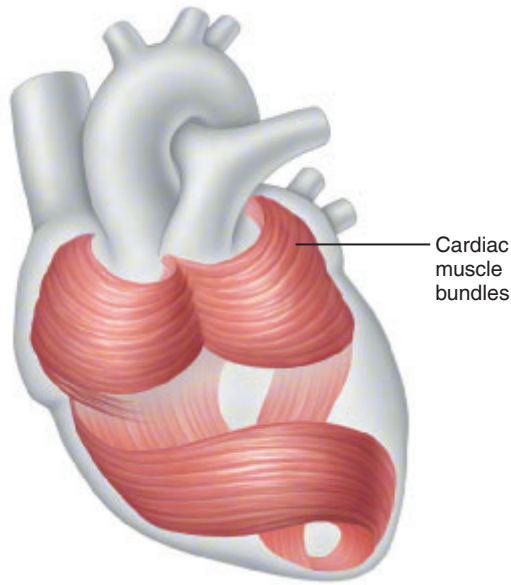


Figure 20.4 Longitudinal view of the heart chambers showing the spiral arrangement of the cardiac muscle fibers.

Activity 3

Examining Cardiac Muscle Cells

1. Observe the three-dimensional model of cardiac muscle, examining its branching cells and the areas where the cells interlock, the **intercalated discs**.

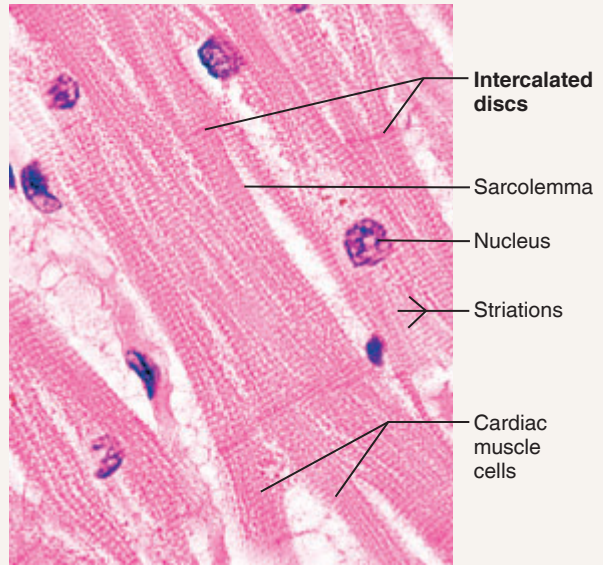


Figure 20.5 Photomicrograph of cardiac muscle (665x).

2. Compare the model of cardiac muscle to the model of skeletal muscle. Note the similarities and differences between the two kinds of muscle tissue.
3. Go to the microscope at the demonstration area, and observe a longitudinal section of cardiac muscle under high power. Identify the nucleus, striations, intercalated discs, and sarcolemma of the individual cells, and then compare your observations to **Figure 20.5**.

DISSECTION

The Sheep Heart

Dissecting a sheep heart is a valuable exercise because the sheep heart is similar in size and structure to the human heart. Refer to **Figure 20.6** as you proceed with the dissection.

1. Obtain a preserved sheep heart, a dissecting tray, dissecting instruments, glass probe, and gloves.
2. Observe the texture of the fibrous pericardium. Also, find its point of attachment to the heart. Where is it attached?

3. If the fibrous pericardial sac is still intact, slit it open and cut it from its attachments. Observe the epicardium. Using a sharp scalpel, carefully pull a little of this serous membrane away from the myocardium. How do its position, thickness, and apposition to the heart differ from those of the parietal pericardium?

4. Examine the external surface of the heart. Notice the accumulation of adipose tissue, which in many cases marks the separation of the chambers and the location of the coronary arteries. Carefully scrape away some of the fat with a scalpel to expose the coronary blood vessels.

5. Identify the base and apex of the heart, and then identify the two wrinkled **auricles**, earlike flaps of tissue projecting from the atria. The balance of the heart muscle is ventricular tissue. To identify the left ventricle, compress the ventricles on each side of the longitudinal fissures carrying the coronary blood vessels. The side that feels thicker and more solid is the left ventricle. The right ventricle is much thinner and feels somewhat flabby when compressed. This difference reflects the greater demand placed on the left ventricle, which must pump blood through the much longer systemic circuit. Hold the heart in its anatomical position (Figure 20.6a), with the anterior surface uppermost. In this position the left ventricle composes the entire apex and the left side of the heart.

6. Identify the pulmonary trunk and the aorta leaving the superior aspect of the heart. The pulmonary trunk is more anterior, and you may see its division into the right and left pulmonary arteries if it has not been cut too close to

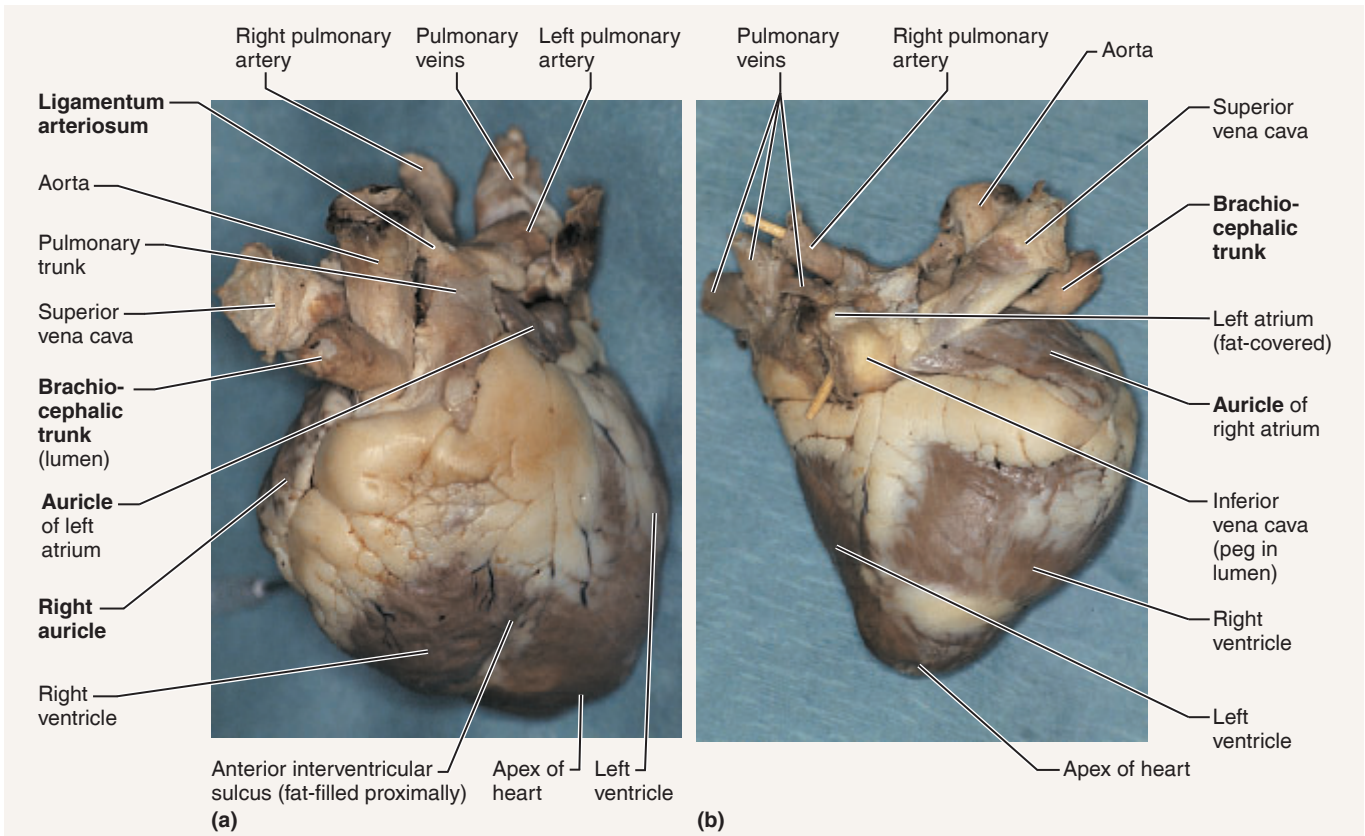


Figure 20.6 Anatomy of the sheep heart. (a) Anterior view. (b) Posterior view.

the heart. The thicker-walled aorta, which branches almost immediately, is located just beneath the pulmonary trunk. The first branch of the sheep aorta, the **brachiocephalic trunk**, can be identified unless the aorta has been cut immediately as it leaves the heart.

Carefully clear away the fat between the pulmonary trunk and the aorta to expose the **ligamentum arteriosum**, a remnant of the **ductus arteriosus**. (In the fetus, the ductus arteriosus allows blood to pass directly from the pulmonary trunk to the aorta, thus bypassing the nonfunctional fetal lungs.)

7. Cut through the wall of the aorta until you see the aortic valve. Identify the two openings into the coronary arteries just above the valve. Insert a probe into one of these holes to see whether you can follow the course of a coronary artery across the heart.

8. Turn the heart to view its posterior surface. (The heart will appear as shown in Figure 20.6b.) Notice that the right and left ventricles appear equal-sized in this view. Try to identify the four thin-walled pulmonary veins entering the left atrium. (It may or may not be possible to locate the pulmonary veins from this vantage point, depending on how they were cut as the heart was removed.) Identify the superior and inferior venae cavae entering the right atrium. Compare the approximate diameter of the superior vena cava with that of the aorta.

Which is larger? _____

Which has thicker walls? _____

Why do you suppose these differences exist?

9. Insert a probe into the superior vena cava, and use scissors to cut through its wall so that you can see the interior of the right atrium. Do not extend your cut entirely through the right atrium or into the ventricle. Observe the right atrioventricular valve.

How many cusps does it have? _____

10. Return to the pulmonary trunk, and cut through its anterior wall until you can see the pulmonary valve. How does its action differ from that of the atrioventricular valve?

Text continues on next page. →

11. Return to the superior vena cava, and continue the cut made in its wall through the right atrium and right atrioventricular valve into the right ventricle.

12. Next, make a longitudinal incision through the aorta, and continue it into the left ventricle. Again notice how much thicker the myocardium of the left ventricle is than that of the right ventricle. Compare the *shape* of the left ventricular cavity to the shape of the right ventricular cavity.

Are the chordae tendineae observed in the right ventricle also present in the left ventricle? _____

Count the number of cusps in the left atrioventricular valve. How does this compare with the number seen in the right atrioventricular valve?

How do the sheep valves compare with their human counterparts?

13. Continue your incision from the left ventricle superiorly into the left atrium. Reflect the cut edges of the atrial wall, and try to locate the entry points of the pulmonary veins into the left atrium. Follow the pulmonary veins to the heart exterior with a probe. Notice how thin-walled these vessels are.

14. Properly dispose of the organic debris in the designated container, and clean the dissecting tray and instruments before leaving the laboratory.

EXERCISE
20

REVIEW SHEET

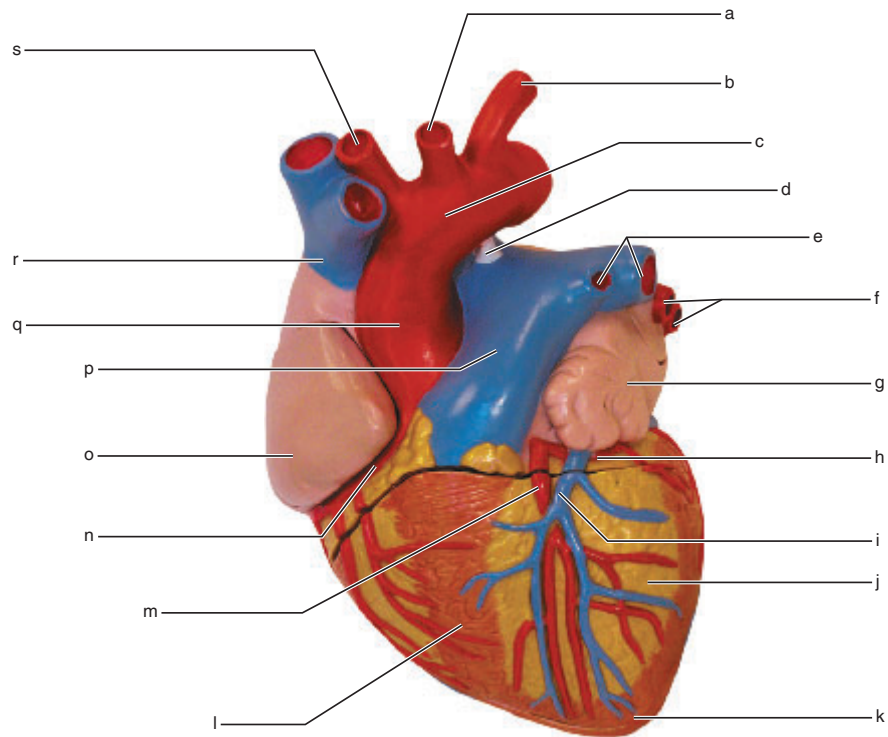
Anatomy of the Heart

Name _____ Lab Time/Date _____

Gross Anatomy of the Human Heart

1. An anterior view of the heart is shown here. Match each structure listed with the correct letter in the figure.

- | | | |
|-----------------------------|-------------------------------------|--|
| _____ 1. right atrium | _____ 8. brachiocephalic trunk | _____ 14. left pulmonary veins |
| _____ 2. right ventricle | _____ 9. left common carotid artery | _____ 15. right coronary artery |
| _____ 3. left atrium | _____ 10. left subclavian artery | _____ 16. circumflex artery |
| _____ 4. left ventricle | _____ 11. pulmonary trunk | _____ 17. anterior interventricular artery |
| _____ 5. superior vena cava | _____ 12. left pulmonary arteries | _____ 18. apex of heart |
| _____ 6. ascending aorta | _____ 13. ligamentum arteriosum | _____ 19. great cardiac vein |
| _____ 7. aortic arch | | |



2. What is the function of the fluid that fills the pericardial sac? _____

3. Match the terms in the key to the descriptions provided below.

Key:

- atria
- atrioventricular valves
- coronary arteries
- coronary sinus
- endocardium
- epicardium
- myocardium
- semilunar valves
- ventricles

- _____ 1. drains blood into the right atrium
- _____ 2. tricuspid and mitral valves
- _____ 3. discharging chambers of the heart
- _____ 4. innermost layer of the pericardium
- _____ 5. receiving chambers of the heart
- _____ 6. layer composed of cardiac muscle
- _____ 7. provide nutrient blood to the heart muscle
- _____ 8. visceral pericardium
- _____ 9. pulmonary and aortic valves

4. Which valves are anchored by chordae tendineae? _____

5. Which valves close when the cusps fill with blood? _____

Pulmonary, Systemic, and Coronary Circulations

6. Describe the role of the pulmonary circuit. _____

7. Describe the role of the systemic circuit.

8. Name the three vessels that deliver oxygen-poor blood to the right atrium.

9. Starting with the right atrium, trace a drop of blood through the heart and lungs, naming the following structures: aorta, aortic valve, left atrium, left ventricle, mitral valve, pulmonary arteries, pulmonary capillaries, pulmonary valve, pulmonary trunk, pulmonary veins, right atrium, right ventricle, and tricuspid valve.

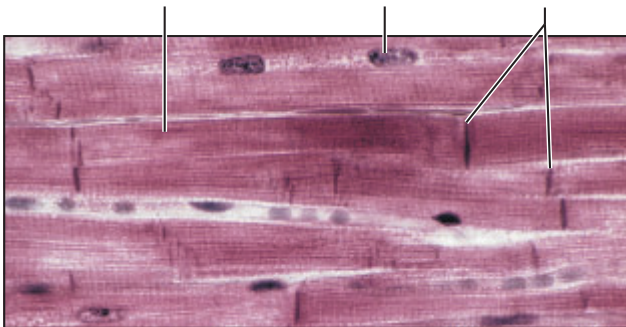
- | | |
|----------|-----------|
| 1. _____ | 8. _____ |
| 2. _____ | 9. _____ |
| 3. _____ | 10. _____ |
| 4. _____ | 11. _____ |
| 5. _____ | 12. _____ |
| 6. _____ | 13. _____ |
| 7. _____ | |

Microscopic Anatomy of Cardiac Muscle

10. How would you distinguish the structure of cardiac muscle from that of skeletal muscle? _____

11. Add the following terms to the photograph of cardiac muscle below.

- a. intercalated discs b. nucleus c. cardiac muscle cell



Describe the unique anatomical features of cardiac muscle. What role does the unique structure of cardiac muscle play in its function?

Dissection of the Sheep Heart

12. During the sheep heart dissection, you were asked initially to identify the right and left ventricles without cutting into the heart. During this procedure, what differences did you observe between the two chambers?

13. Semilunar valves prevent backflow into the _____; AV valves prevent backflow into the _____. Using your own observations, explain how the operation of the semilunar valves differs from that of the AV valves. _____

14. The remnant of a fetal structure is observable in the heart—the ligamentum arteriosum. What was it called in the fetal heart, where was it located, and what purpose did it serve?

15. **+** A proximal LAD lesion is a blockage in the left anterior descending artery, also known as the anterior interventricular artery. Explain why a heart attack caused by an obstruction of this artery is sometimes referred to as the “widow maker” heart attack. _____

16. **+** Congestive heart failure (CHF) is an inability of the heart to pump sufficient blood to the body. One sign of CHF is excess fluid in the tissue spaces, known as edema. Describe the location of the edema if the left side of the heart fails, compared to the location of edema if the right side of the heart fails. _____

Anatomy of Blood Vessels

Materials

- Anatomical charts of human arteries and veins (or a three-dimensional model of the human circulatory system)
- Anatomical charts of the following specialized circulations: pulmonary circulation, fetal circulation, hepatic portal circulation, arterial supply and cerebral arterial circle (circle of Willis) (or a brain model showing this circulation)
- Demonstration area: Microscope slides showing cross sections of an artery and vein, set up for student viewing

Learning Outcomes

- Describe the tunics of blood vessel walls. State the function of each layer, and discuss how it is/may be modified to serve the differing functional requirements of arteries, veins, and capillaries.
- Recognize a cross-sectional view of an artery and a vein.
- Identify the major arteries arising from the aorta, and name the body region supplied by each.
- Identify the major veins draining into the venae cavae, and indicate the body areas drained.
- Discuss the unique features of the special circulations studied.

Arteries, which carry blood away from the heart, and veins, which return blood to the heart, are simply conducting vessels. Only the tiny capillaries that branch throughout the tissues directly serve the needs of the body's cells. It is through the capillary walls that exchanges are made between tissue cells and blood.

In this exercise, you will examine the microscopic structure of blood vessels and identify the major arteries and veins of the systemic circulation and other special circulations.

Microscopic Structure of the Blood Vessels

Except for the tiny capillaries, the walls of blood vessels have three coats, or tunics (**Figure 21.1**).

- **Tunica intima:** Lines the lumen of a vessel and is composed of the *endothelium*, subendothelial layer, and internal elastic membrane. The simple squamous cells of the endothelium fit closely together, forming an extremely smooth blood vessel lining that helps decrease resistance to blood flow.
- **Tunica media:** Middle coat, made primarily of smooth muscle and elastic tissue. The smooth muscle is active in changing the diameter of blood vessels, which in turn alters blood flow and blood pressure.
- **Tunica externa:** Outermost tunic, composed of areolar or fibrous connective tissue. Its function is to support and protect the vessel.

In general, the walls of arteries tend to be thicker than those of veins. The tunica media in particular is much heavier and contains much more smooth muscle and elastic tissue. Arteries, which are closer to the pumping action of the heart, must be able to expand as blood is propelled into them during systole and then recoil passively as the blood flows off into the circulation during diastole. The anatomical differences between the types of vessels reflect their functional differences. **Table 21.1** summarizes the structure and function of various blood vessels.

Valves in veins prevent backflow of blood. The skeletal muscle “pump” also promotes venous return; as the skeletal muscles surrounding the veins contract and relax, the blood is milked through the veins toward the heart. Pressure changes that occur in the thorax during breathing also help blood return to the heart.

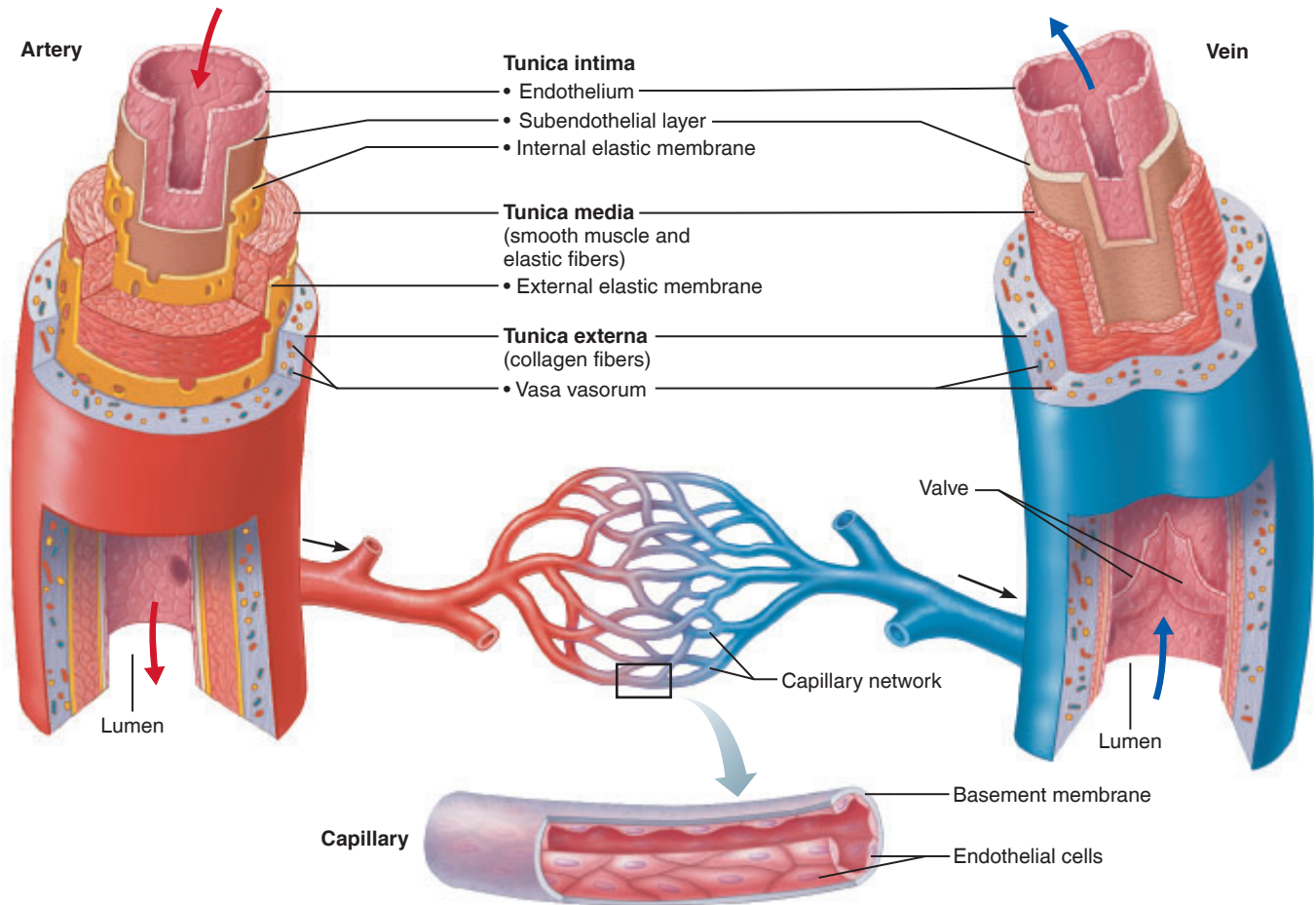


Figure 21.1 Structure of arteries, veins, and capillaries.

Table 21.1 Summary of Blood Vessel Anatomy and Physiology

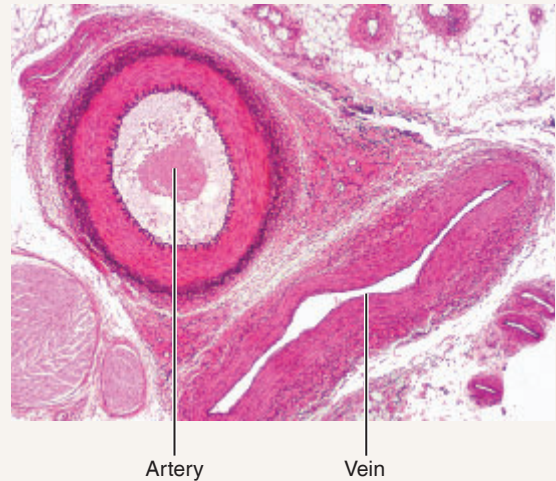Type of vessel	Description	Average lumen diameter	Average wall thickness	Function
Elastic (conducting) arteries	Largest, most elastic arteries. Contain more elastic tissue than other arteries.	1.5 cm	1.0 mm	Act as a pressure reservoir, expanding and recoiling for continuous blood flow. Examples: aorta, brachiocephalic artery, and common carotid artery.
Muscular (distributing) arteries	Medium-sized arteries, accounting for most arteries found in the body. They have less elastic tissue and more smooth muscle than other arteries.	0.6 cm	1.0 mm	Better ability to constrict and less stretchable than elastic arteries. They distribute blood to specific areas of the body. Examples: brachial artery and radial artery.
Arterioles	Smallest arteries, with a very thin tunica externa and only a few layers of smooth muscle in the tunica media.	37 μm	6 μm	Blood flows from arterioles into a capillary bed. They play a role in regulating the blood flow to specific areas of the body.
Capillaries	Contain only a tunica intima.	9 μm	0.5 μm	Provide for the exchange of materials (gases, nutrients, etc.) between the blood and tissue cells.
Venules	Smallest veins. All tunics are very thin, with at most two layers of smooth muscle and no elastic tissue.	20 μm	1 μm	Drain capillary beds and merge to form veins.
Veins	Contain more fibrous tissue in the tunica externa than corresponding arteries. The tunica media is thinner, with a larger lumen than the corresponding artery.	0.5 cm	0.5 mm	Low-pressure vessels; return blood to the heart. Valves prevent the backflow of the blood.

Activity 1

Examining the Microscopic Structure of Arteries and Veins

1. Go to the demonstration area to examine a slide showing a cross-sectional view of blood vessels.
2. Using **Figure 21.2** as a guide, scan the section to identify a thick-walled artery. Often, but not always, its lumen will appear scalloped because of the constriction of its walls by the elastic tissue of the tunica media.
3. Identify a vein. Its lumen may be elongated or irregularly shaped and collapsed, and its walls will be considerably thinner. Also, notice the thinness of the tunica intima layer.

Figure 21.2 Photomicrograph of a muscular artery and the corresponding vein in cross section (40 \times). See also Plate 21 in the Histology Atlas.



Major Systemic Arteries of the Body

The **aorta** is the largest artery of the body. It has three main regions: ascending aorta, aortic arch, and descending aorta. Extending upward as the **ascending aorta** from the left ventricle, it arches posteriorly and to the left as the **aortic arch** and then travels downward as the **descending aorta** through the thoracic cavity. Called the **thoracic aorta** from T₅ to T₁₂, the descending aorta penetrates the diaphragm to enter the abdominal cavity. As it enters the abdominal cavity, it becomes the **abdominal aorta**. The branches of the ascending aorta and the aortic arch are summarized in **Table 21.2**. Branches of the thoracic and abdominal aorta are summarized in Tables 21.3 and 21.4.

Figure 21.3 depicts the relationship of the aorta and its major branches. As you locate the arteries on this figure and the ones that follow, notice that in many cases, the name of the artery reflects the body region traveled through (axillary, subclavian, brachial, popliteal), the organ served

(renal, hepatic), or the bone followed (tibial, femoral, radial, ulnar).

Aortic Arch

The **brachiocephalic** (literally, “arm-head”) **trunk** is the first branch of the aortic arch (**Figure 21.4**). The other two major arteries branching off the aortic arch are the **left common carotid artery** and the **left subclavian artery**. The brachiocephalic trunk splits and divides into the **right common carotid artery** and the **right subclavian artery**.

Arteries Serving the Head and Neck

The common carotid artery on each side divides to form an **internal carotid artery**, which serves the brain, and an **external carotid artery**. The external carotid artery supplies the tissues external to the skull in the neck and head.

(Text continues on page 262.)

Table 21.2 The Aorta: Ascending Aorta and Aortic Arch (Figure 21.3)

Ascending aorta branches	Structures served
Right coronary artery	The myocardium of the heart (see Exercise 20)
Left coronary artery	The myocardium of the heart (see Exercise 20)
Aortic arch branches	Structures served
Brachiocephalic trunk (branches into right common carotid and right subclavian arteries)	Right common carotid artery—right side of the head and neck Right subclavian artery—right upper limb
Left common carotid artery	Left side of the head and neck
Left subclavian artery	Left upper limb

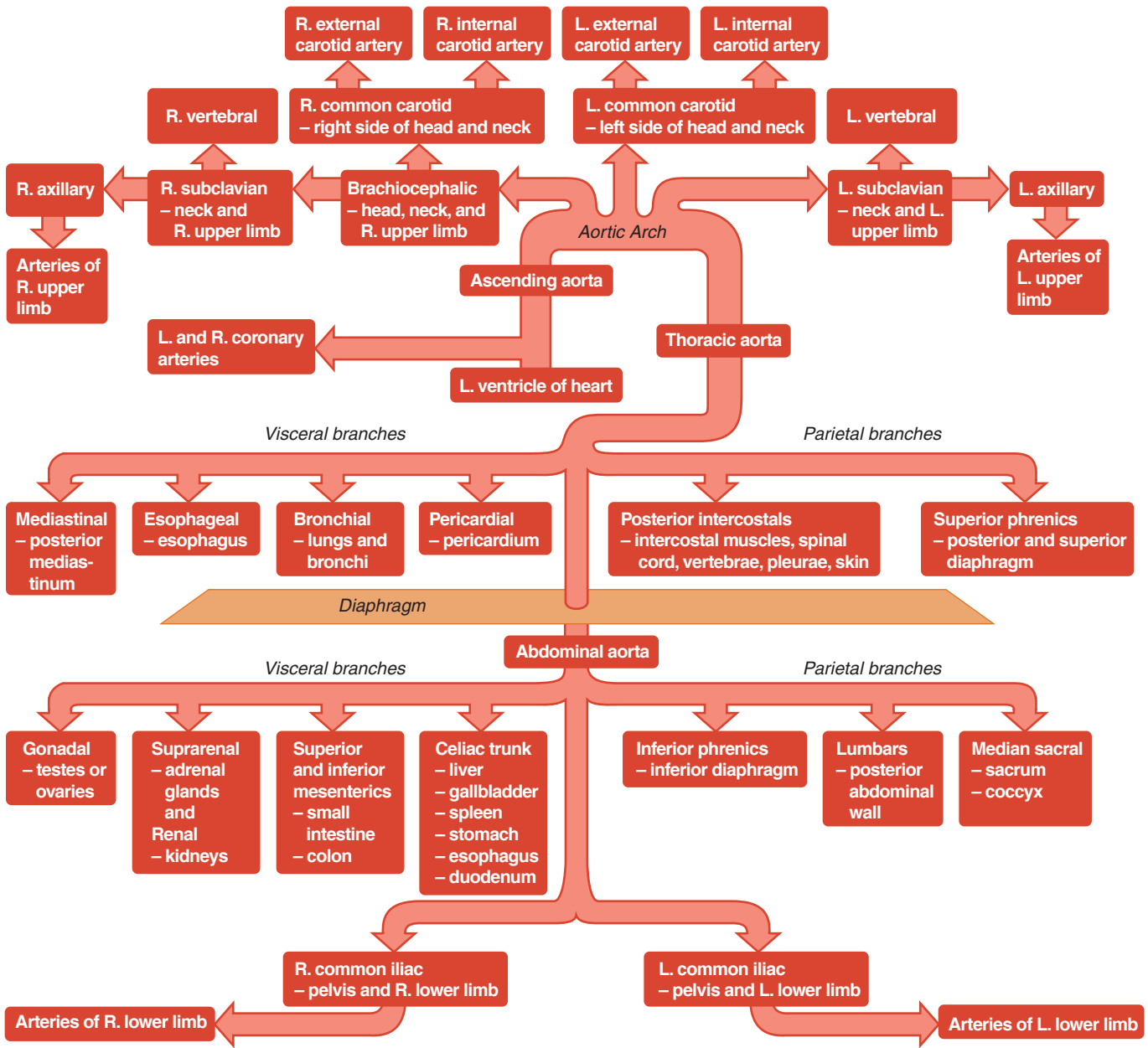


Figure 21.3 Schematic of the systemic arterial circulation. (L. = left, R. = right.)

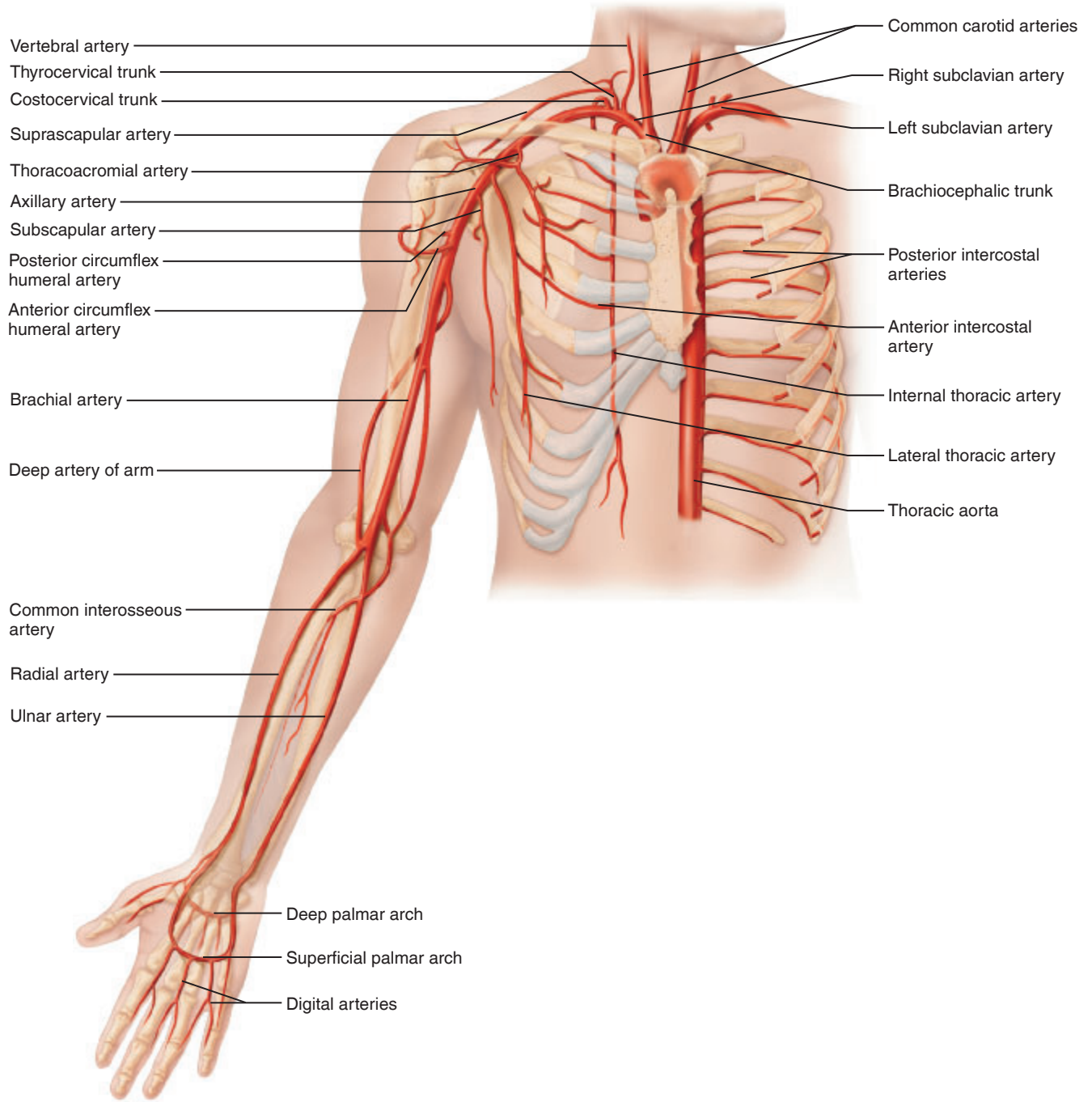


Figure 21.4 Arteries of the right upper limb and thorax.

Table 21.3 The Aorta: Thoracic Aorta (Figure 21.3) (Note that many of these arteries vary in number from person to person)

Visceral thoracic aorta branches	Structures served
Pericardial arteries	Pericardium, the serous membrane of the heart
Bronchial arteries	Bronchi, bronchioles, and lungs
Esophageal arteries	Esophagus
Mediastinal arteries	Posterior mediastinum
Parietal thoracic aorta branches	Structures served
Posterior intercostal arteries (inferior pairs)	Intercostal muscles, spinal cord, vertebrae, and skin
Subcostal arteries	Intercostal muscles, spinal cord, vertebrae, and skin
Superior phrenic arteries	Posterior, superior part of the diaphragm

The right and left subclavian arteries each give off several branches to the head and neck. The first of these is the **vertebral artery**, which runs up the posterior neck to supply the cerebellum, brain stem, and the posterior cerebral hemispheres. In the armpit, the subclavian artery becomes the axillary artery, which serves the upper limb.

Arteries Serving the Thorax and Upper Limbs

As the **axillary artery** runs through the axilla, it gives off several branches to the chest wall and shoulder girdle (Figure 21.4). As it enters the arm, the axillary artery becomes the **brachial artery**. This gives off a deep branch, and, at the elbow, the brachial artery divides into the **radial** and **ulnar arteries**, which follow the same-named bones to supply the forearm and hand. The radial artery is often palpated to take a pulse.

Most of the thorax wall and the anterior intercostal structures are supplied by **anterior intercostal artery** branches. The posterior intercostal regions are served by the **posterior**

intercostal arteries. Not shown in Figure 21.4 are the small arteries that serve the diaphragm (*phrenic arteries*), esophagus (*esophageal arteries*), and bronchi (*bronchial arteries*). However, these vessels *are* indicated in Figure 21.3 and summarized in **Table 21.3**.

Thoracic Aorta

The thoracic aorta is the superior portion of the descending aorta (Figure 21.4). It begins where the aortic arch ends and ends as it pierces the diaphragm. The main branches of the thoracic aorta are summarized in Table 21.3.

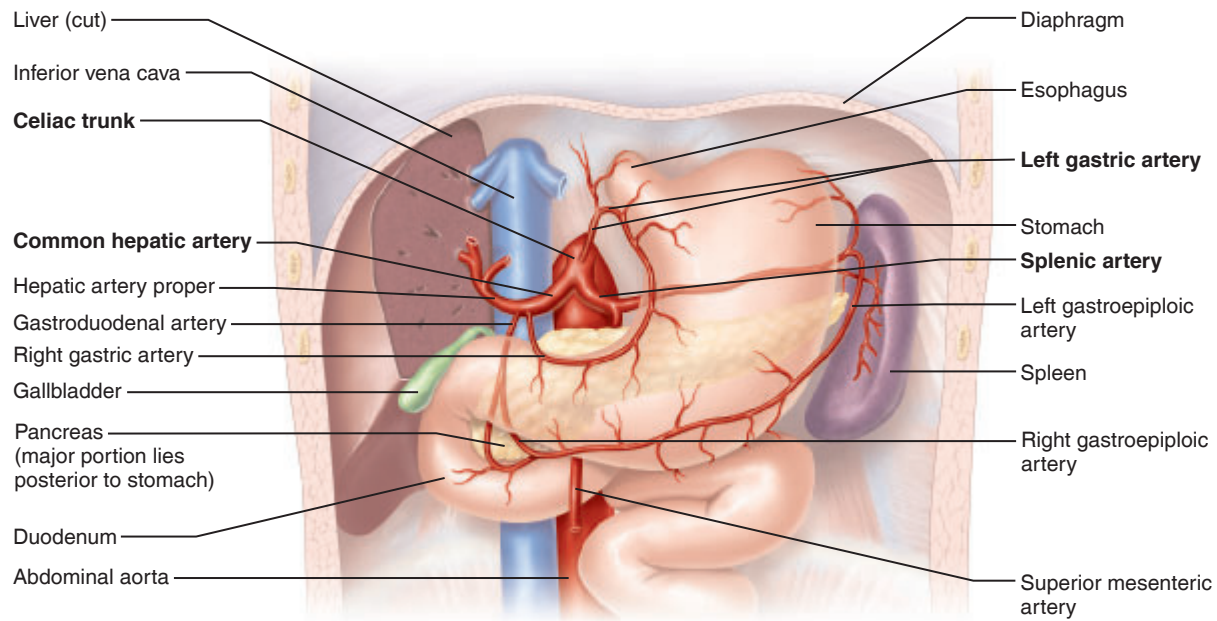
Abdominal Aorta

Although several small branches of the descending aorta serve the thorax, its more major branches serve the abdominal organs and the lower limbs (**Figure 21.5**).

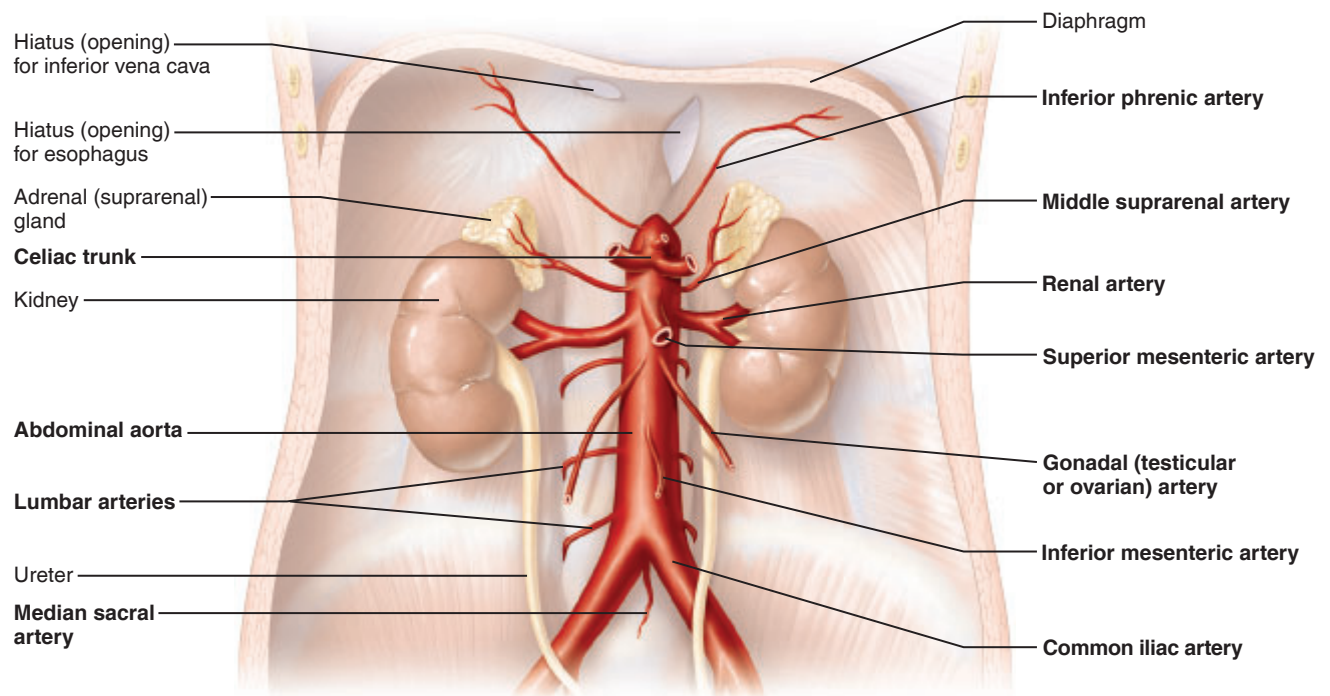
The major branches of the abdominal aorta are summarized in **Table 21.4**.

Table 21.4 The Aorta: Abdominal Aorta (Figure 21.5)

Branches	Structures served
Inferior phrenic arteries	Inferior surface of the diaphragm
Celiac trunk: left gastric artery	Stomach and esophagus
Celiac trunk: splenic artery	Branches to the spleen; short gastric arteries branch to the stomach; and the left gastroepiploic artery branches to the stomach
Celiac trunk: common hepatic artery	Branches into the hepatic artery proper (its branches serve the liver, gallbladder, and stomach) and the gastroduodenal artery (its branches serve the stomach, pancreas, and duodenum)
Superior mesenteric artery	Most of the small intestine and the first part of the large intestine
Middle suprarenal arteries	Adrenal glands that sit on top of the kidneys
Renal arteries	Kidneys
Gonadal arteries	Ovarian arteries (female)—ovaries Testicular arteries (male)—testes
Inferior mesenteric artery	Distal portion of the large intestine
Lumbar arteries	Posterior abdominal wall
Median sacral artery	Sacrum and coccyx
Common iliac arteries	The distal abdominal aorta splits to form the left and right common iliac arteries, which serve the pelvic organs, lower abdominal wall, and the lower limbs



(a)



(b)

Figure 21.5 Arteries of the abdomen. (a) The celiac trunk and its major branches. The left half of the liver has been removed. (b) Major branches of the abdominal aorta.

Arteries Serving the Lower Limbs

Each of the common iliac arteries extends for about 2 inches into the pelvis before it divides into the internal and external iliac arteries (**Figure 21.6**). The **internal iliac artery** supplies the gluteal muscles, and the adductor muscles of the medial thigh, as well as the genitals.

The **external iliac artery** supplies the anterior abdominal wall and the lower limb. In the thigh, its name changes to **femoral artery**. Proximal branches of the femoral artery supply the head of the femur and the hamstring muscles. Slightly lower, the femoral artery gives off a deep branch, the **deep artery of the thigh**, which supplies blood to most of the thigh muscles. At the knee, the femoral artery briefly becomes the **popliteal artery**; its subdivisions—the **anterior** and **posterior tibial arteries**—supply the leg, ankle, and foot. The anterior tibial artery supplies the extensor muscles and terminates with the **dorsalis pedis artery**. The dorsalis pedis supplies the dorsum of the foot and continues on as the **arcuate artery**. The dorsalis pedis is often palpated in patients with circulation problems of the leg to determine the circulatory efficiency to the limb as a whole.

- Palpate your own dorsalis pedis artery.

Activity 2

Locating Arteries on an Anatomical Chart or Model

Now that you have identified the arteries on Figures 21.3–21.6, attempt to locate and name them (without referring to these figures) on a large anatomical chart or three-dimensional model of the vascular system.

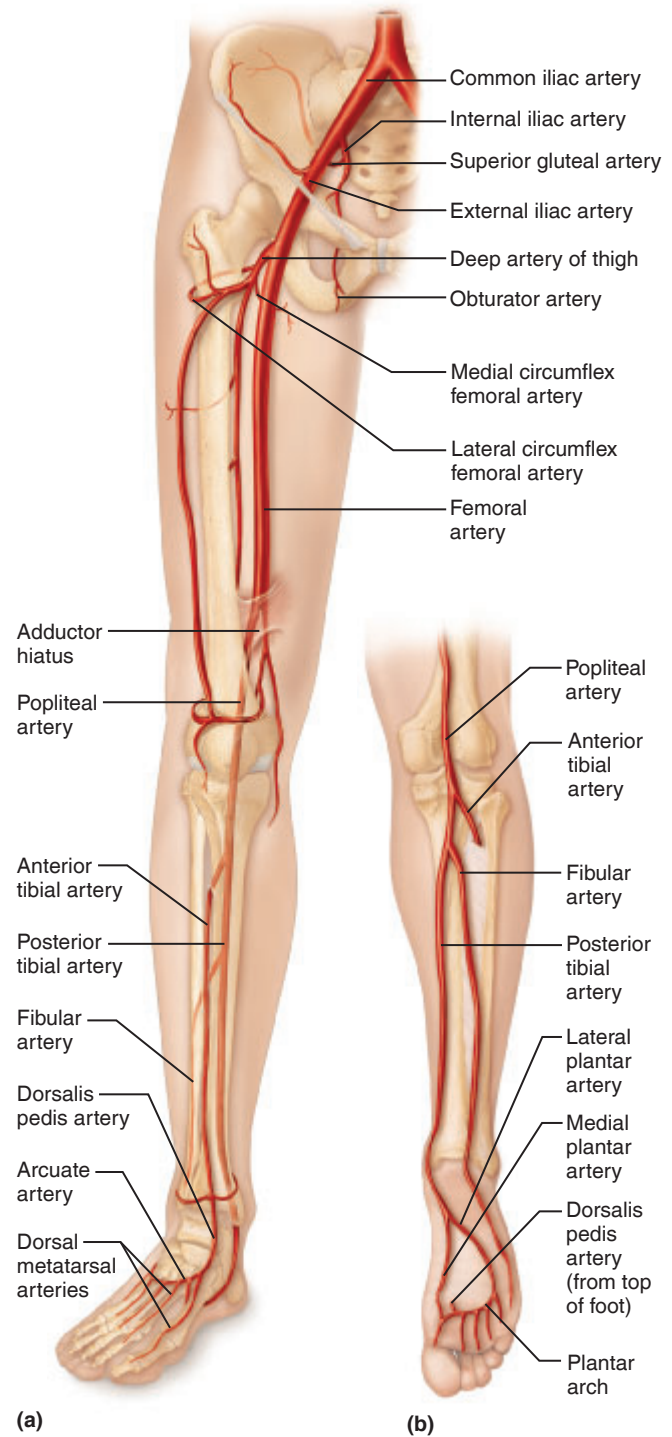


Figure 21.6 Arteries of the right pelvis and lower limb. (a) Anterior view. (b) Posterior view.

Major Systemic Veins of the Body

Arteries are generally located in deep, well-protected body areas. However, veins tend to follow a more superficial course and are often easily seen on the body surface. Most deep veins parallel the course of the major arteries, and in many cases the vein has the same name as its corresponding

artery. Veins draining the head and upper extremities empty into the **superior vena cava**, and those draining the lower body empty into the **inferior vena cava**. **Figure 21.7** shows the systemic veins and their relationship to the venae cavae to get you started.

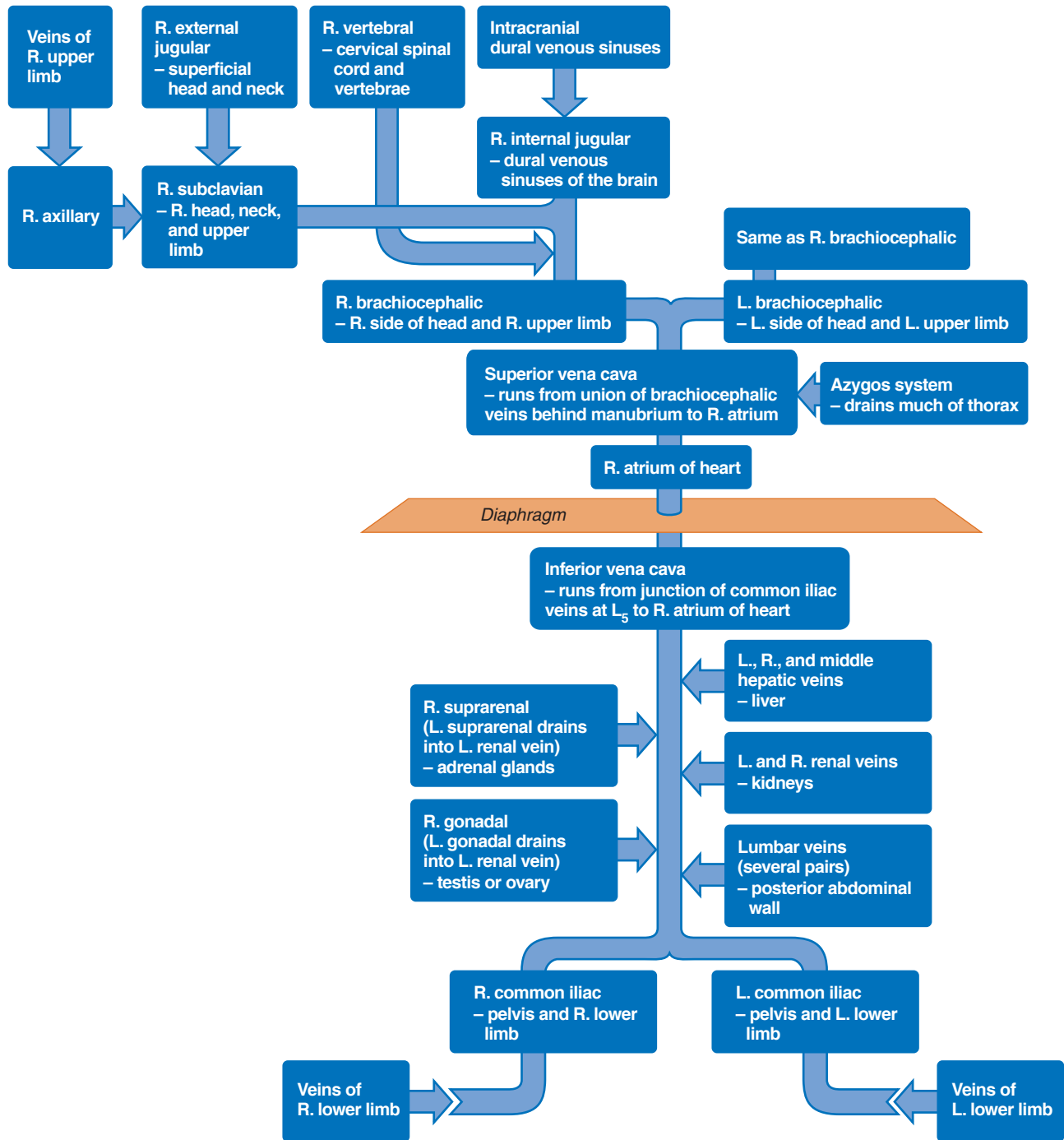


Figure 21.7 Schematic of systemic venous circulation. (L. = left, R. = right.)

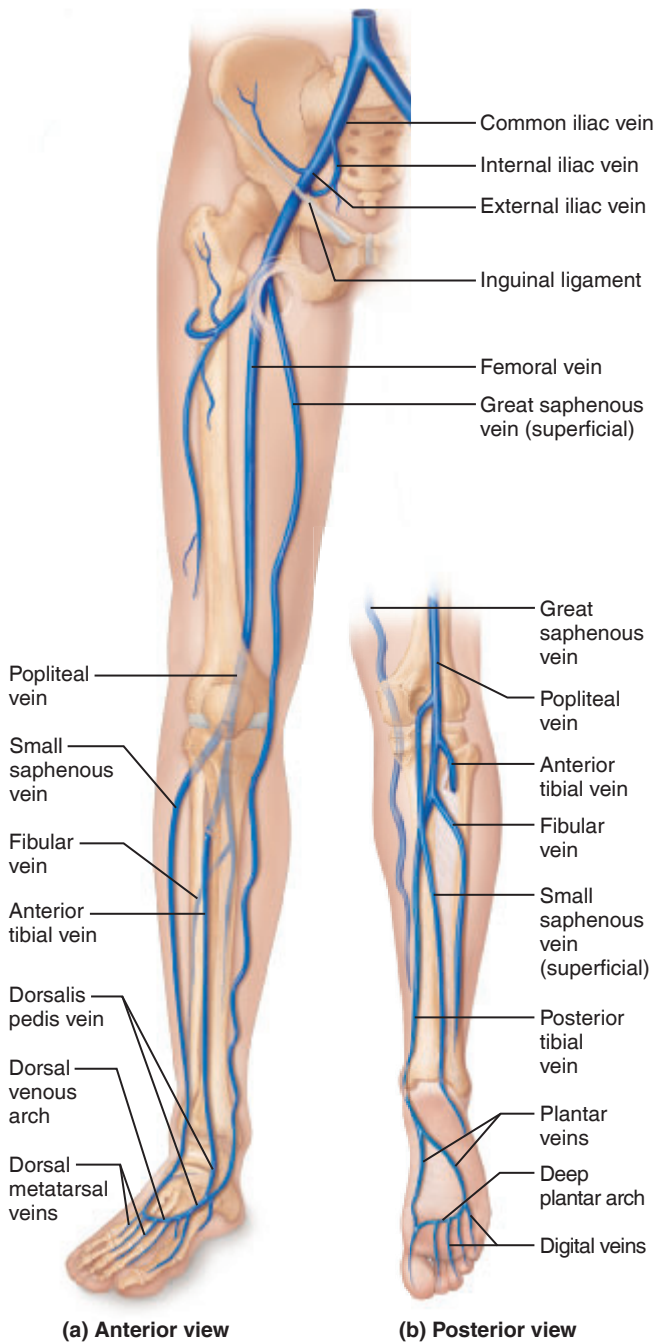


Figure 21.8 Veins of the right lower limb.

Veins Draining into the Inferior Vena Cava

The inferior vena cava, a much longer vessel than the superior vena cava, returns blood to the heart from all body regions below the diaphragm. It begins in the lower abdominal region with the union of the paired **common iliac veins** (Figure 21.8), which drain venous blood from the legs and pelvis.

Veins of the Lower Limbs

Each common iliac vein is formed by the union of the **internal iliac vein**, draining the pelvis, and the **external iliac vein**, which receives venous blood from the lower limb (Figure 21.8). Veins of the leg include the **anterior** and **posterior tibial veins**, which serve the calf and foot. The anterior tibial vein is a continuation of the **dorsalis pedis vein** of the foot. The posterior tibial vein is formed by the union of the **medial** and **lateral plantar veins**, and it ascends deep in the calf muscles. It joins with the **fibular vein** at the knee to produce the **popliteal vein**, which crosses the back of the knee. The popliteal vein becomes the **femoral vein** in the thigh. The femoral vein in turn becomes the external iliac vein in the inguinal region.

The **great saphenous vein**, a superficial vein, is the longest vein in the body. Beginning in common with the **small saphenous vein** from the **dorsal venous arch**, it extends up the medial side of the leg, knee, and thigh to empty into the femoral vein. The small saphenous vein drains the calf muscle and then empties into the popliteal vein at the knee (Figure 21.8b).

Veins of the Abdomen

Moving superiorly in the abdominal cavity (Figure 21.9), the inferior vena cava receives blood from the posterior abdominal wall via several pairs of **lumbar veins** and from the right ovary or testis via the **right gonadal vein**. (The **left gonadal vein** drains into the left renal vein superiorly.) The paired **renal veins** drain the kidneys. Just above the right renal vein, the **right suprarenal vein** (receiving blood from the adrenal gland on the same side) drains into the inferior vena cava, but its partner, the **left suprarenal vein**, empties into the left renal vein inferiorly. The **right** and **left hepatic veins** drain the liver. The unpaired veins draining the digestive tract organs empty into a special vessel, the **hepatic portal vein**, which carries blood to the liver to be processed before it enters the systemic venous system. (The hepatic portal system is discussed separately on page 269.)

Veins Draining into the Superior Vena Cava

Veins draining into the superior vena cava are named from the superior vena cava distally, but remember that the blood flows in the *opposite* direction.

Veins of the Head and Neck

The **right** and **left brachiocephalic veins** drain the head, neck, and upper extremities and unite to form the superior vena cava (Figure 21.10). Notice that although there is only one brachiocephalic artery (trunk), there are two brachiocephalic veins.

Branches of the brachiocephalic veins include the **internal jugular**, **vertebral**, and **subclavian veins**. The **internal jugular veins** are large veins that drain the dural sinuses of the brain, and they receive blood from the head and neck as they move inferiorly. The **vertebral veins** (not shown in Figure 21.10) drain the posterior aspect of the head and neck.

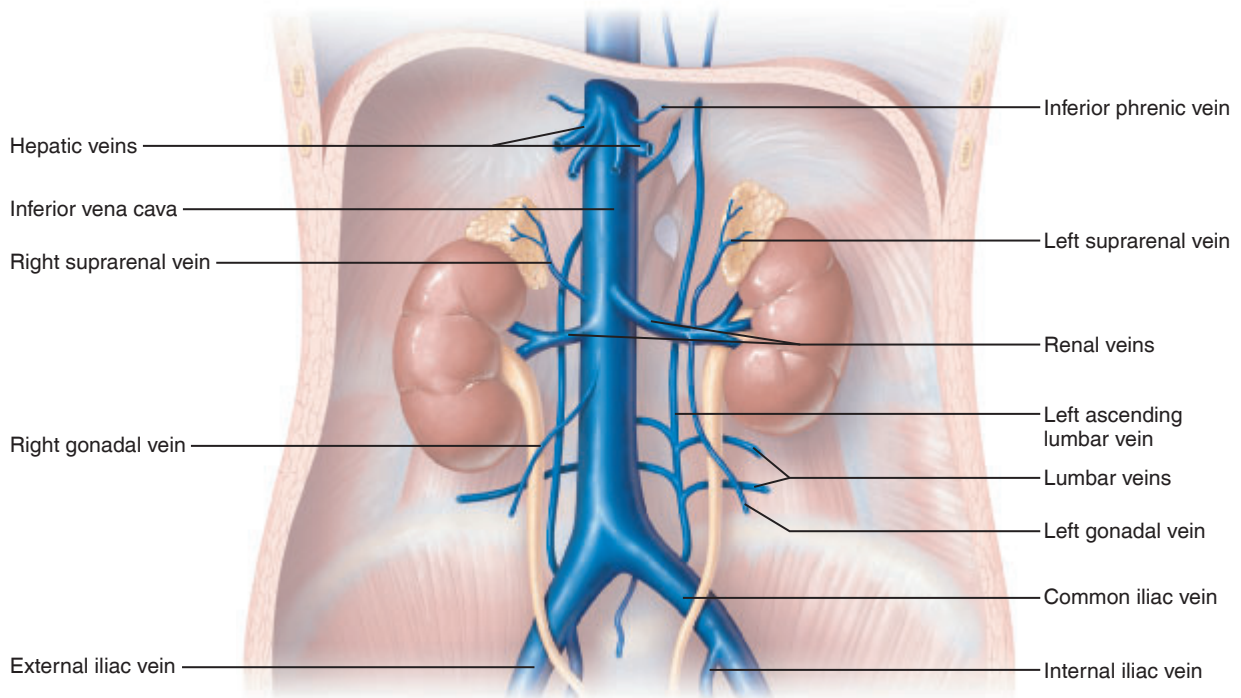


Figure 21.9 Venous drainage of abdominal organs not drained by the hepatic portal vein.

The **subclavian veins** receive venous blood from the upper limb. The **external jugular vein**, returning venous drainage of the extracranial (superficial) tissues of the head and neck, joins the subclavian vein near its origin.

Veins of the Upper Limb and Thorax

As the subclavian vein enters the axilla, it becomes the **axillary vein** and then the **brachial vein** as it runs the course of the humerus (Figure 21.10). The **deep** and **superficial venous palmar arches** empty into the **radial** and **ulnar veins** of the forearm, which then unite to form the brachial vein. The superficial venous drainage of the arm includes the **cephalic vein** laterally, which empties into the axillary vein; the medial **basilic vein**, which enters the brachial vein; and

the **median cubital vein**, which runs between the cephalic and basilic veins in the anterior elbow.

The **azygos vein**, which drains the right side of the thorax, enters the dorsal aspect of the superior vena cava just before that vessel enters the heart.

Activity 3

Identifying the Systemic Veins

Identify the important veins of the systemic circulation on the large anatomical chart or model without referring to the figures.

Special Circulations

Pulmonary Circulation

The pulmonary circulation (discussed with heart anatomy on page 248) differs in many ways from systemic circulation because it does not serve the metabolic needs of the body tissues. It functions instead to bring blood into close contact with the air sacs of the lungs to permit gas exchanges that rid the blood of excess carbon dioxide and replenish its supply of vital oxygen.

Pulmonary circulation begins with the large **pulmonary trunk**, which leaves the right ventricle and divides into the **right** and **left pulmonary arteries** about 2 inches above its origin (Figure 21.11). The pulmonary arteries plunge into the lungs, where they subdivide into **lobar arteries** (three on the right and two on the left), which accompany the main bronchi into the lungs. The lobar arteries branch extensively within the lungs and finally end in the capillary networks

surrounding the air sacs of the lungs. The respiratory gases diffuse across the walls of the air sacs (alveoli) and **pulmonary capillaries**. The pulmonary capillary beds are drained by venules, which converge to form larger and larger veins and finally the four **pulmonary veins** (two leaving each lung), which return the blood to the left atrium of the heart.

Activity 4

Identifying Vessels of the Pulmonary Circulation

In Figure 21.11, *label* all structures provided with leader lines using choices from the list at the right.

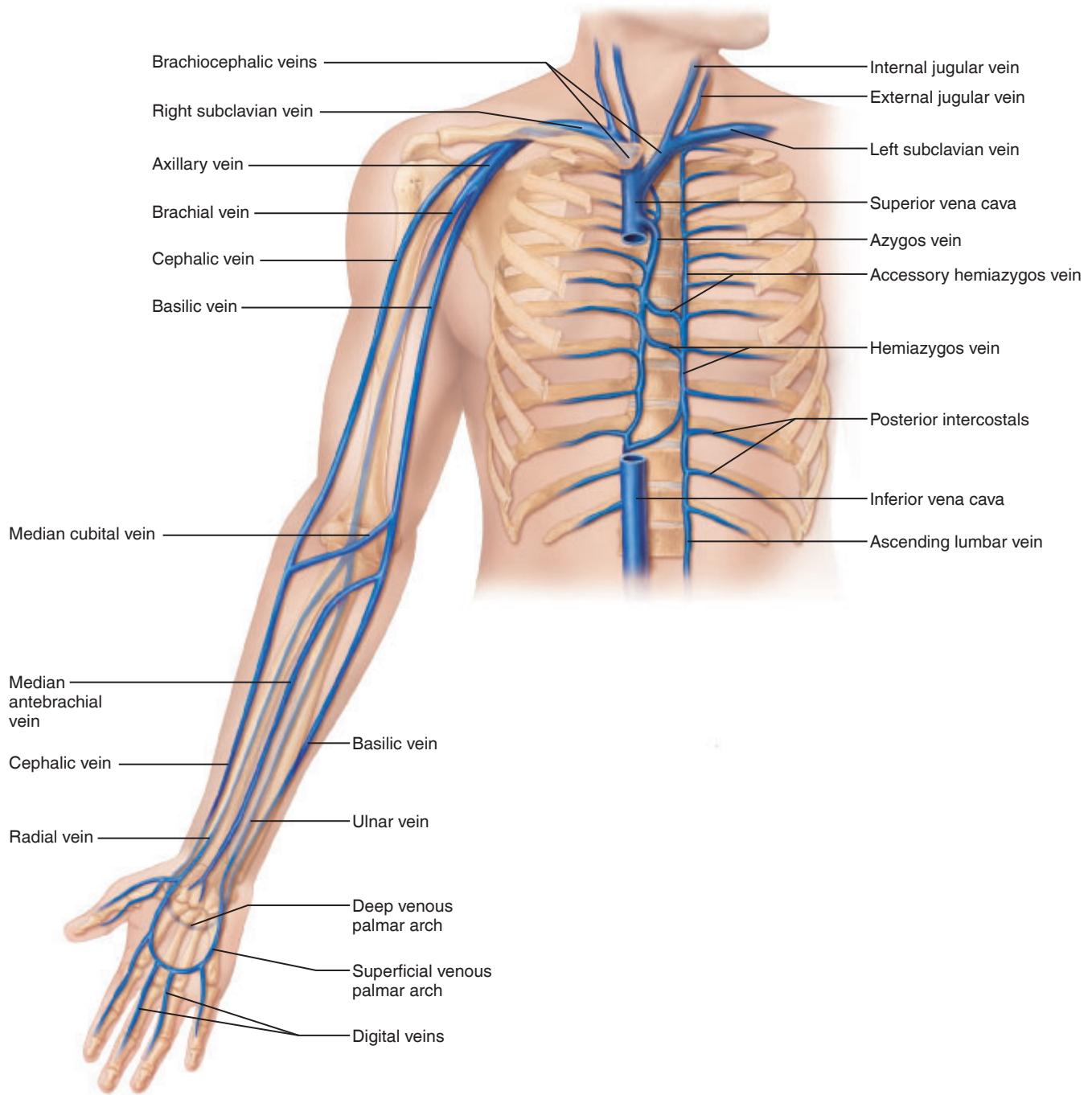


Figure 21.10 Veins of the right upper limb and shoulder. For clarity, the abundant branching and anastomoses of these vessels are not shown.

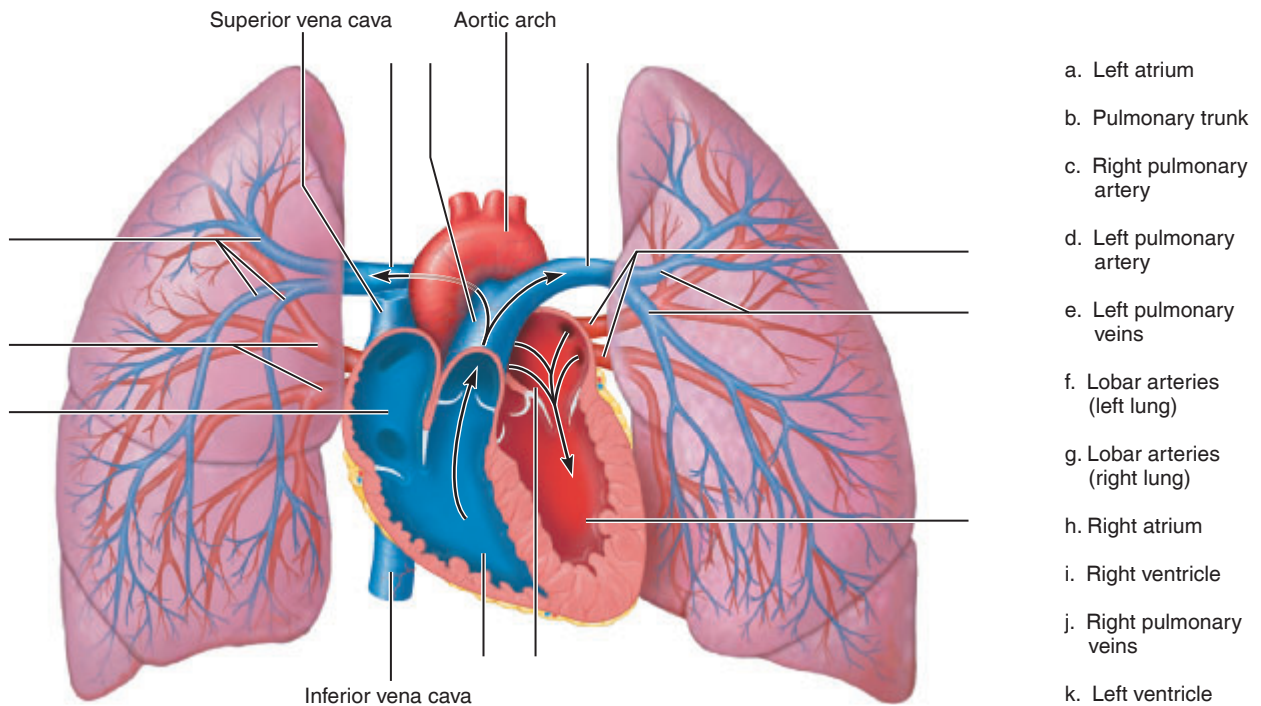


Figure 21.11 The pulmonary circulation.

Hepatic Portal Circulation

The veins of the hepatic portal circulation (**Figure 21.12**) drain the digestive organs, spleen, and pancreas and deliver this blood to the liver via the **hepatic portal vein** (formed by the union of the splenic and superior mesenteric vein). As blood travels through the liver, some of the nutrients are stored or processed in various ways for release to the general circulation. The liver in turn is drained by the hepatic veins that enter the inferior vena cava.

The **splenic vein** carries blood from the spleen, parts of the pancreas, and the stomach. The splenic vein unites with the **superior mesenteric vein** to form the hepatic portal vein. The superior mesenteric vein drains the small intestine, part of the large intestine, and the stomach. The **inferior mesenteric vein**, which drains the distal portion of the large intestine and rectum, empties into the splenic vein just before the splenic vein merges with the superior mesenteric vein.

Activity 5

Tracing the Hepatic Portal Circulation

Locate on Figure 21.12 the vessels named above.

Arterial Supply of the Brain and the Cerebral Arterial Circle

A continuous blood supply to the brain is essential because the delicate brain tissue will die if it is deprived of oxygen for even a few minutes. The brain is supplied by two pairs of arteries arising from the region of the aortic arch—the **internal carotid arteries** and the **vertebral arteries** (**Figure 21.13**).

Activity 6

Tracing the Arterial Supply of the Brain

The internal carotid and vertebral arteries are labeled in Figure 21.13. As you read the description of the brain's blood supply, *complete the labeling of this diagram*.

The **internal carotid arteries**, which are branches of the common carotid arteries, take a deep course through the neck, entering the skull through the carotid canals of the temporal bone. Within the cranium, each divides into **anterior** and **middle cerebral arteries**, which supply the bulk of the cerebrum. The internal carotid arteries also contribute to the **cerebral arterial circle (circle of Willis)**, an arterial network

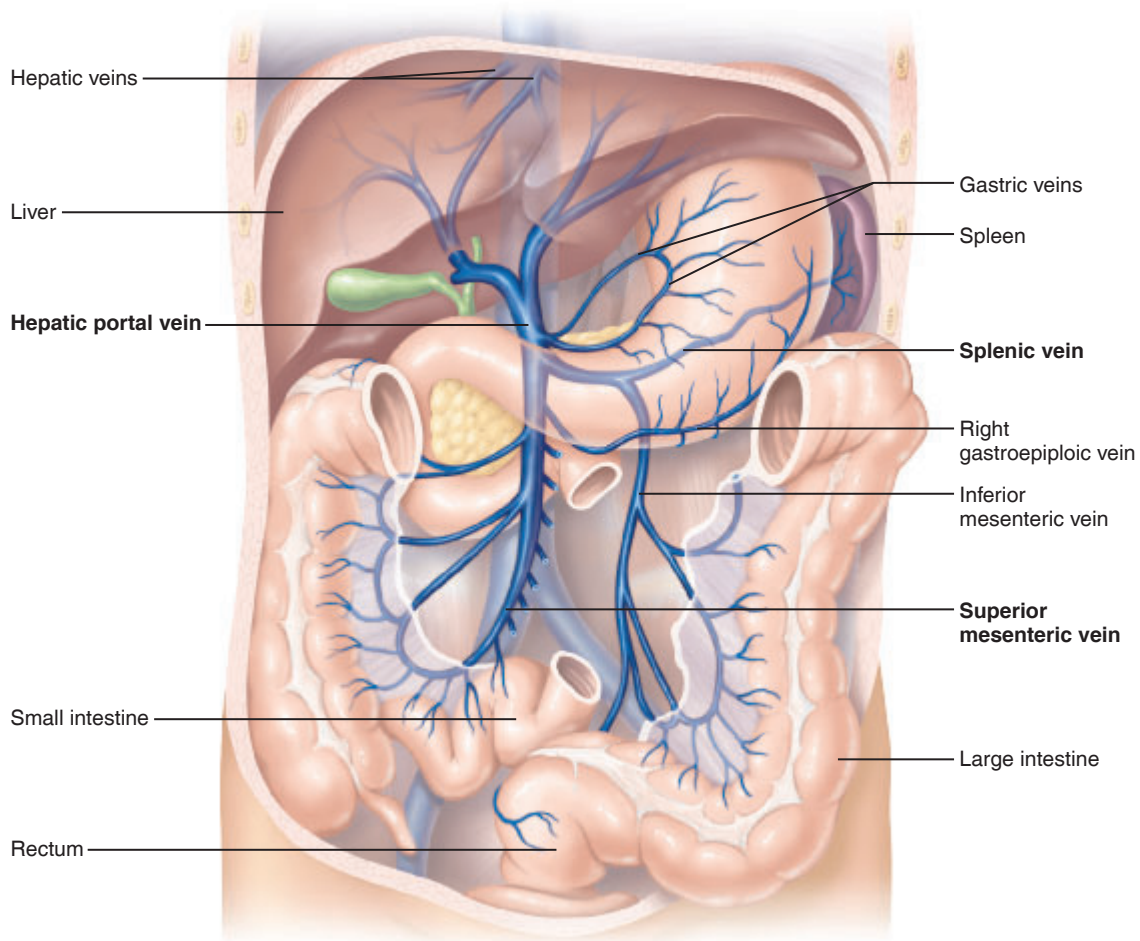


Figure 21.12 The hepatic portal circulation.

21

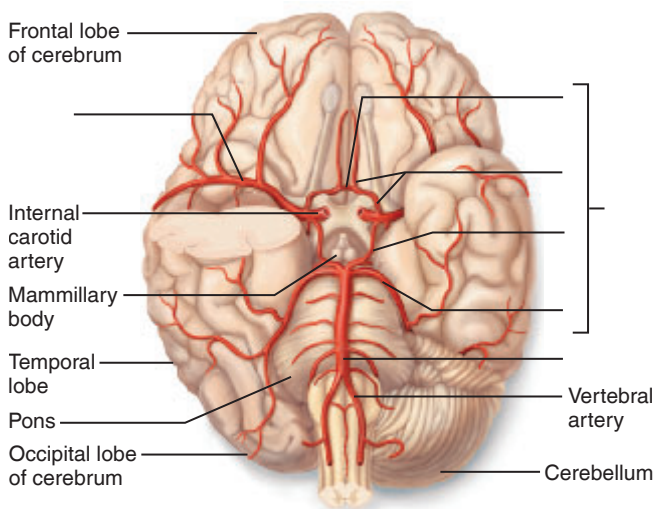


Figure 21.13 Major arteries serving the brain. Inferior view, right side of cerebellum and part of right temporal lobe removed.

at the base of the brain surrounding the pituitary gland and the optic chiasma, by helping to form a **posterior communicating artery** on each side. The circle is completed by the **anterior communicating artery**, a short shunt connecting the right and left anterior cerebral arteries.

The paired **vertebral arteries** branch from the subclavian arteries and pass superiorly through the foramina of the transverse processes of the cervical vertebrae to enter the skull through the foramen magnum. Within the skull, the vertebral arteries unite to form the single **basilar artery**, which runs superiorly along the ventral brain stem, giving off branches to the pons, cerebellum, and internal ear. At the base of the cerebrum, the basilar artery divides to form the **posterior cerebral arteries**, which supply the posterior part of the cerebrum and become part of the cerebral arterial circle by joining with the posterior communicating arteries.

The uniting of the anterior and posterior blood supplies via the cerebral arterial circle is a protective device that provides an alternate set of pathways for blood to reach the brain tissue in the case of impaired blood flow anywhere in the system.

EXERCISE
21

REVIEW SHEET

Anatomy of Blood Vessels

Name _____ Lab Time/Date _____

Microscopic Structure of the Blood Vessels

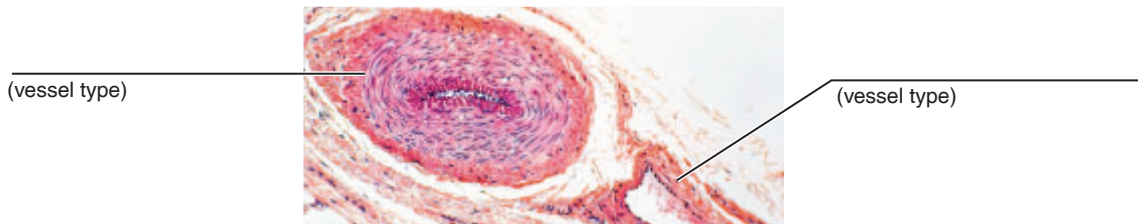
1. Use the key choices to identify the blood vessel tunic described. (Some choices may be used more than once.)

Key: tunica intima tunica media tunica externa

- _____ 1. innermost tunic
- _____ 2. bulky middle tunic; contains smooth muscle and elastic tissue
- _____ 3. its smooth surface decreases resistance to blood flow
- _____ 4. tunic of capillaries
- _____, _____, _____ 5. tunic(s) of arteries and veins
- _____ 6. tunic that is especially thick in arteries
- _____ 7. most superficial tunic

2. Describe the basic function that capillaries provide.

3. Cross-sectional views of an artery and of a vein are shown here. Identify each, and also respond to the related questions that follow.



Which of these vessels may have valves? _____

Which of these vessels depends on its elasticity to propel blood along? _____

Which depends on the skeletal muscle pump and changes during breathing? _____ Explain this dependence.

4. Why are the walls of arteries relatively thicker than those of the corresponding veins? _____

Major Systemic Arteries and Veins of the Body

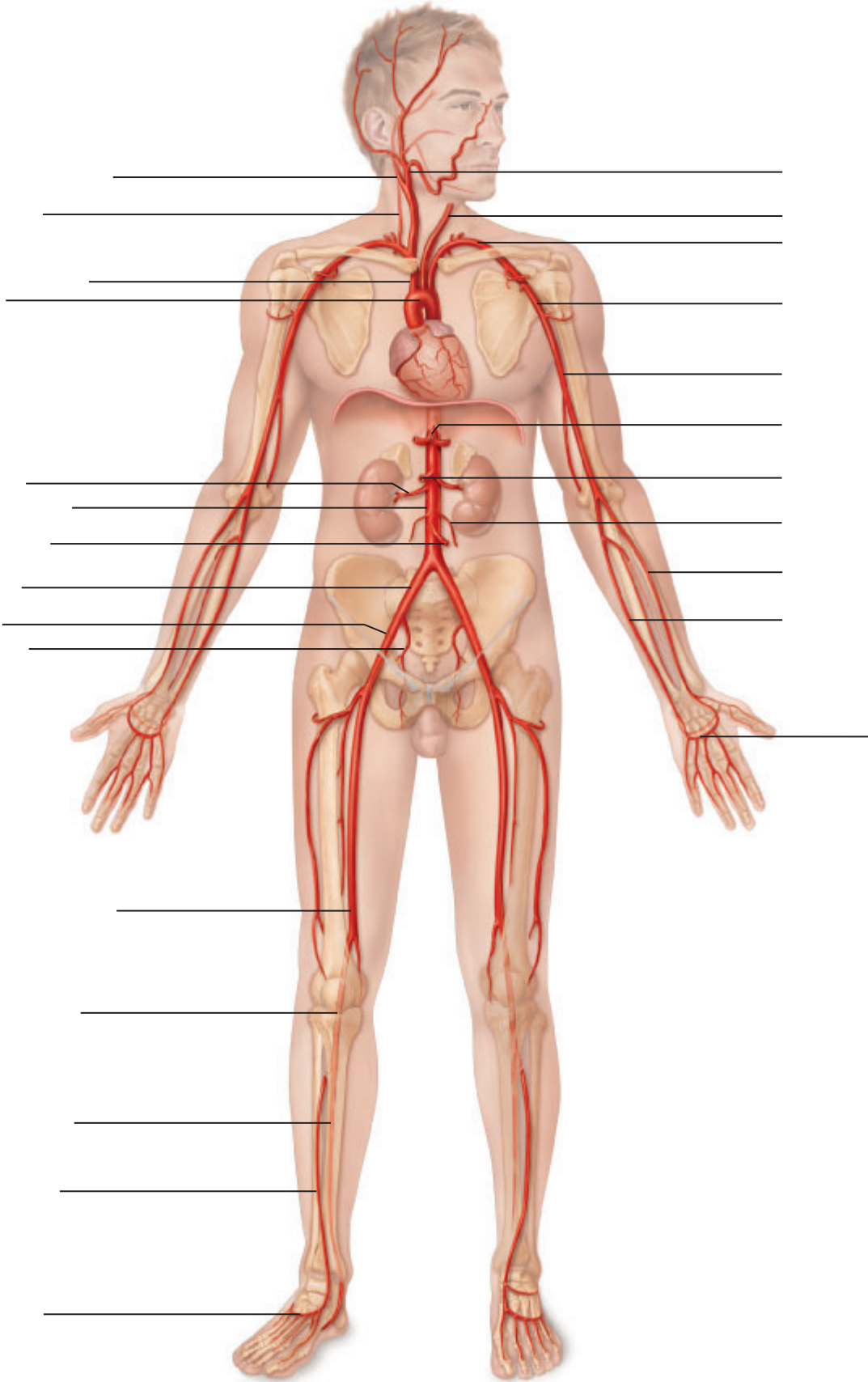
5. Use the key on the right to identify the arteries or veins described on the left.

Key:

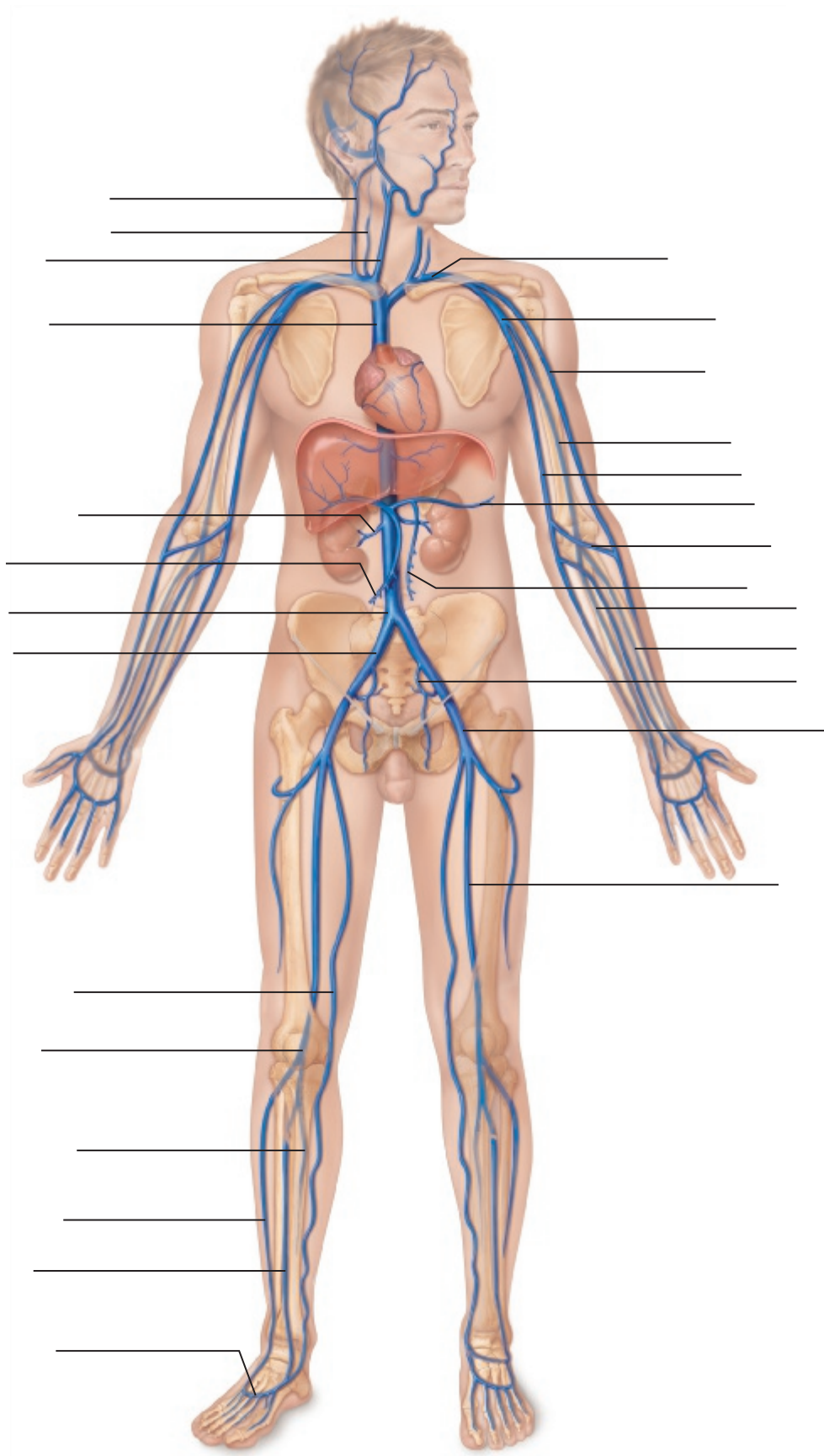
- _____ 1. vessel that is paired in the venous system but only a single vessel is present in the arterial system
- _____ 2. these arteries supply the myocardium
- _____ 3. the more anterior artery pair serving the brain
- _____ 4. longest vein in the body
- _____ 5. artery on the foot checked to determine circulation of the leg
- _____ 6. main artery that serves the thigh muscles
- _____ 7. supplies the diaphragm
- _____ 8. formed by the union of the radial and ulnar veins
- _____, _____ 9. two superficial veins of the arm
- _____ 10. artery serving the kidney
- _____ 11. testicular or ovarian veins
- _____ 12. artery that supplies the distal half of the large intestine
- _____ 13. divides into the external and internal carotid arteries
- _____ 14. arteries that merge to form the basilar artery
- _____ 15. artery serving the gluteal muscles
- _____ 16. supplies most of the small intestine
- _____ 17. what the femoral artery becomes at the knee
- _____ 18. an arterial trunk that has three major branches, which run to the liver, spleen, and stomach
- _____ 19. major artery serving the skin and scalp of the head
- _____, _____ 20. two veins that join, forming the popliteal vein
- _____ 21. artery generally used to take the pulse at the wrist

- anterior tibial
- basilic
- brachial
- brachiocephalic
- celiac trunk
- cephalic
- common carotid
- coronary
- deep artery of the thigh
- dorsalis pedis
- external carotid
- gonadal
- great saphenous
- inferior mesenteric
- internal carotid
- internal iliac
- phrenic
- popliteal
- posterior tibial
- radial
- renal
- superior mesenteric
- vertebral

6. The human arterial and venous systems are diagrammed on this page and the next. Identify all indicated blood vessels.



Arteries



Veins

7. Trace the blood flow for the following situations:

a. From the capillary beds of the left thumb to the capillary beds of the right thumb _____

b. From the pulmonary vein to the pulmonary artery by way of the right side of the brain _____

Pulmonary Circulation

8. Trace the pathway of a carbon dioxide gas molecule in the blood from the inferior vena cava until it leaves the bloodstream. Name all structures (vessels, heart chambers, and others) it passes through en route.

9. Most arteries of the adult body carry oxygen-rich blood, and the veins carry oxygen-depleted, carbon dioxide-rich blood. What is different about the pulmonary arteries and veins? _____

Hepatic Portal Circulation

10. Why is the blood that drains into the hepatic portal circulation nutrient-rich? _____


11. Why is this blood carried to the liver before it enters the systemic circulation? _____


12. The hepatic portal vein is formed by the union of the _____ and the _____. The _____ vein carries blood from the _____, _____, and _____. The _____ vein drains the _____, _____, and _____. The _____ vein empties into the splenic vein and drains the _____ and _____.

Arterial Supply of the Brain and the Cerebral Arterial Circle

13. Branches of the internal carotid and vertebral arteries cooperate to form a ring of blood vessels encircling the pituitary gland, at the base of the brain. What name is given to this communication network? _____
 What is its function? _____

14. What portion of the brain is served by the anterior and middle cerebral arteries? _____

 Both the anterior and middle cerebral arteries arise from the _____ arteries.
15.  A peripherally inserted central catheter (PICC) line involves the use of a long, thin tube to deliver medications or nutrients to a patient. For adult patients, it is usually inserted into the right cephalic vein. Trace the route that a medication would take to reach the right atrium. List all vessels on the route. _____

16.  A patient with iliofemoral deep vein thrombosis (IFDVT) has a blood clot located in the femoral or external iliac vein. Such a patient is at risk of the clot traveling to the lungs, resulting in a pulmonary embolism. Trace the route of the clot from the femoral vein to the pulmonary artery. List all vessels on the route. _____

Human Cardiovascular Physiology—Blood Pressure and Pulse Determinations

Materials

- Stethoscope
- Sphygmomanometer
- Watch (or clock) with a second hand
- Felt marker
- Step stools (16 in. and 20 in. in height)
- Cot (if available)
- Alcohol swabs

Learning Outcomes

- Define *systole*, *diastole*, and *cardiac cycle*, and describe the events of the cardiac cycle.
- Relate heart sounds to events of the cardiac cycle.
- Define *pulse*, and accurately determine a subject's radial and apical pulse.
- Define *blood pressure*, and accurately determine a subject's blood pressure with a sphygmomanometer.
- Investigate the effects of exercise on blood pressure, pulse, and cardiovascular fitness.
- Indicate factors affecting or determining blood flow and skin color.

During this exercise, we will investigate pulse, heart sounds, and blood pressure, all of which reflect the heart and blood vessels in action. The discussion of the cardiac cycle below will help you to understand and interpret the physiological measurements taken during the lab.

Cardiac Cycle

In a healthy heart, the atria contract simultaneously. Then, as they begin to relax, the ventricles contract. However, in general usage, the terms **systole** and **diastole** refer to contraction and relaxation, respectively, of the ventricles.

The **cardiac cycle** includes events of one complete heartbeat. During the cardiac cycle, both atria and ventricles contract and then relax, and a predictable sequence of changes in blood volume and pressure occur within the heart. To better understand the events of the cardiac cycle, read the descriptions for a given phase in **Table 22.1** and correlate each phase to the electrical events, heart sounds, pressure changes in the left side of the heart, and volume changes in the left side of the heart depicted in **Figure 22.1**. We begin with the heart in total relaxation, mid-to-late diastole; however, you could start anywhere within the cycle.

Assuming the average heart beats approximately 75 beats per minute, the length of the cardiac cycle is about 0.8 second. (This value was obtained by dividing 60 seconds by the number of beats per minute.)

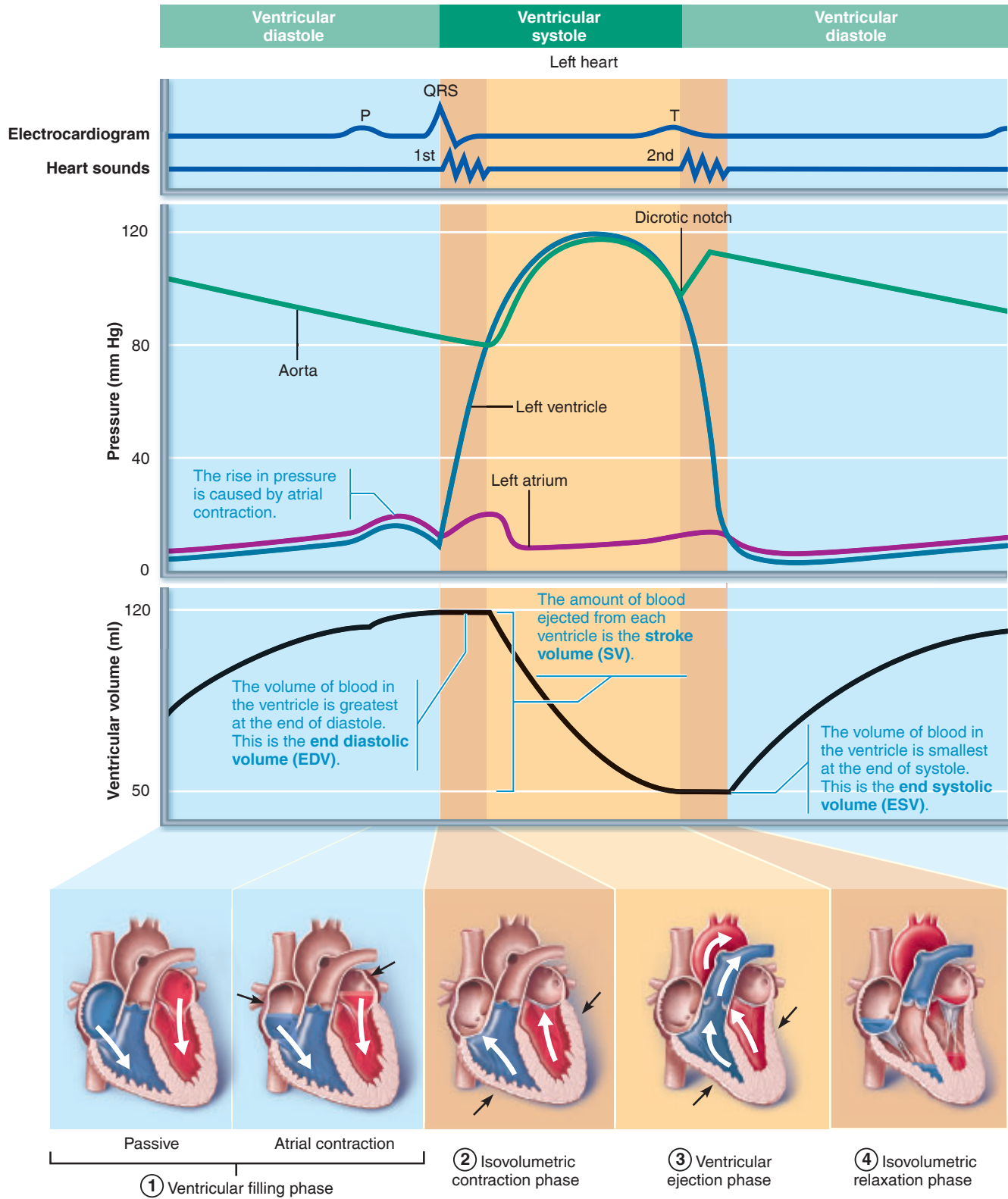


Figure 22.1 Summary of events occurring in the heart during the cardiac cycle.

Table 22.1 Events of the Cardiac Cycle

Phase	Description of events	Status of ventricles	Status of atria	Status of AV valves	Status of SL valves
Mid-to-late diastole ① Ventricular filling (passive)	When atrial pressure is greater than ventricular pressure, the AV valves are forced open, and blood flows passively into the atria and on through to the ventricles.	Relaxed (diastole)	Relaxed (atrial diastole)	Opened	Closed
Mid-to-late diastole ① Ventricular filling with atrial contraction	The atria contract to complete the filling of the ventricles. Ventricular diastole ends, and so the end diastolic volume (EDV) of the ventricles is achieved.	Relaxed (diastole)	Contracted (atrial systole)	Opened	Closed
Ventricular systole ② Isovolumetric contraction	The contraction of the ventricles begins, and ventricular pressure increases, closing the AV valves.	Contracted (systole)	Relaxed (atrial diastole)	Closed	Closed
Ventricular systole ③ Ventricular ejection	Ventricular pressure continues to rise; when the pressure in the ventricles exceeds the pressure in the great vessels exiting the heart, the SL valves open, and blood is ejected.	Contracted (systole)	Relaxed (atrial diastole)	Closed	Opened
Early diastole ④ Isovolumetric relaxation	The ventricles relax, decreasing the pressure in the ventricles; the decrease in pressure causes the SL valves to close. The dicrotic notch is the result of a pressure fluctuation that occurs when the aortic valve snaps shut.	Relaxed (diastole)	Relaxed (atrial diastole)	Closed	Closed

Heart Sounds

Two distinct sounds can be heard during each cardiac cycle. These **heart sounds** are commonly described by the monosyllables “lub” and “dup”; and the sequence is lub-dup, pause, lub-dup, pause. The first heart sound (lub) occurs as the AV

valves close at the beginning of ventricular systole. The second heart sound (dup) occurs as the semilunar valves close at the end of ventricular systole. Figure 22.1 indicates the timing of heart sounds in the cardiac cycle and in relation to an ECG.

Activity 1

Auscultating Heart Sounds

In the following procedure, you will auscultate (listen to) your partner’s heart sounds with a stethoscope.

1. Obtain a stethoscope and some alcohol swabs. Heart sounds are best auscultated if the person’s outer clothing is removed, so a male subject is preferable.
2. Clean the earpieces of the stethoscope with an alcohol swab. Allow the alcohol to dry. Notice that the earpieces are angled. For comfort, the earpieces should be angled in a *forward* direction when you place them into your ears.
3. Don the stethoscope. Place the diaphragm of the stethoscope on your partner’s thorax, just medial to the left nipple at the fifth intercostal space. Listen carefully

for heart sounds. The first sound will be a longer, louder (more booming) sound than the second, which is short and sharp. After listening for a couple minutes, try to time the pause between the second sound of one heartbeat and the first sound of the subsequent heartbeat.

How long is this interval? _____ sec

How does it compare to the interval between the first and second sounds of a single heartbeat?

The Pulse

The term **pulse** refers to the alternating surges of pressure (expansion and then recoil) in an artery that occur with each beat of the left ventricle. Normally the pulse rate equals the heart rate, and the pulse averages 70 to 76 beats per minute in the resting state.

Conditions other than pulse *rate* are also useful clinically. Can you feel it strongly—does the blood vessel expand and recoil (sometimes visibly) with the pressure waves—or is it difficult to detect? Is it regular like the ticking of a clock, or does it seem to skip beats?

Activity 2

Palpating Superficial Pulse Points

The pulse may be felt easily on any artery close to the body surface when the artery is compressed over a bone or firm tissue. Palpate the following pulse points on your partner or yourself by placing the fingertips of the first two fingers of one hand over the artery. Note that you should never use your thumb when measuring an individual's pulse, because your thumb has a faint pulse of its own. It helps to compress the artery firmly as you begin your palpation and then immediately ease up on the pressure slightly. In each case, notice the regularity of the pulse, and assess its force. **Figure 22.2** illustrates the superficial pulse points to be palpated. Check off the boxes as you locate each pulse point.

- Common carotid artery:** At the side of the neck.
- Superficial temporal artery:** Anterior to the ear.
- Facial artery:** Clench the teeth, and palpate the pulse just anterior to the masseter muscle in line with the corner of the mouth.
- Brachial artery:** In the antecubital fossa, at the point where it splits into the radial and ulnar arteries.
- Radial artery:** At the lateral aspect of the wrist, just above the thumb.
- Femoral artery:** In the groin.
- Popliteal artery:** At the back of the knee.
- Posterior tibial artery:** Just above the medial malleolus.
- Dorsalis pedis artery:** On the dorsum of the foot.

Which pulse point had the greatest amplitude?

Which the least? _____

Can you offer any explanation for this? _____

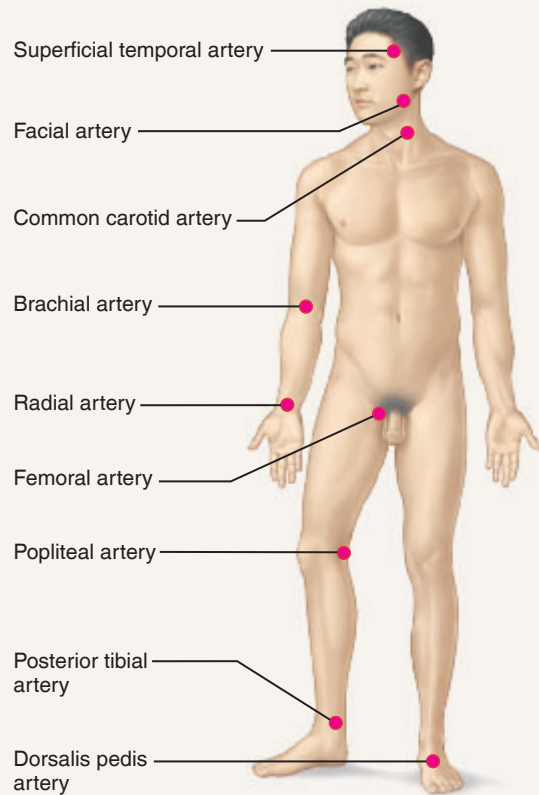


Figure 22.2 Body sites where the pulse is most easily palpated.

Because of its easy accessibility, the pulse is most often taken on the radial artery. With your partner sitting quietly, practice counting the radial pulse for 1 minute. Make three counts, and average the results.

count 1 _____ count 2 _____

count 3 _____ average _____

Apical-Radial Pulse

The relationship between the apical and radial pulse rates can be determined by counting them simultaneously. The **apical pulse** (actually the counting of heartbeats) may be slightly faster than the radial because of a slight lag in time as the

blood rushes from the heart into the large arteries where it can be palpated. A difference between the values observed is referred to as a **pulse deficit**. A large difference may indicate a weakened heart that is unable to pump sufficient blood into the arterial tree, or abnormal heart rhythms. Apical pulse counts are routinely ordered for patients with cardiac disease.

Activity 3

Taking an Apical Pulse

With the subject sitting quietly, one student, using a stethoscope, determines the apical pulse rate while another counts the radial pulse rate at the same time. The stethoscope should be positioned over the fifth left intercostal space. The person taking the radial pulse will determine the

starting point for the count and give the stop-count signal exactly 1 minute later. Record your values.

apical count _____ beats/min

radial count _____ pulses/min

pulse deficit _____ pulses/min

Blood Pressure Determinations

Blood pressure is the pressure the blood exerts against the inner blood vessel walls; it is generally measured in the arteries. Because the heart alternately contracts and relaxes, the rhythmic flow of blood into the arteries causes the blood pressure to rise and fall during each beat. Thus you must take two blood pressure readings: the **systolic pressure**, which is the pressure in the arteries at the peak of ventricular contraction,

and the **diastolic pressure**, the pressure during ventricular relaxation. Blood pressures are reported in millimeters of mercury (mm Hg), with the systolic pressure appearing first; 120/80 translates to 120 over 80, or a systolic pressure of 120 mm Hg and a diastolic pressure of 80 mm Hg. However, normal blood pressure varies considerably from one person to another.

Activity 4

Using a Sphygmomanometer to Measure Arterial Blood Pressure Indirectly

The **sphygmomanometer**, commonly called a *blood pressure cuff*, is an instrument used to measure blood pressure by the auscultatory method (Figure 22.3). It consists of an inflatable cuff with an attached pressure gauge. The cuff is wrapped snugly around the arm (see Figure 22.3b) and inflated to stop blood flow to the forearm. As cuff pressure is gradually released, the examiner listens with a stethoscope over the brachial artery (Figure 22.3c) for characteristic sounds called the **sounds of Korotkoff**, which indicate the resumption of blood flow into the forearm. The pressure at which the first soft tapping sounds are heard is recorded as the systolic pressure. As the pressure is reduced further, blood flow becomes more turbulent, and the sounds become louder. Below the diastolic pressure, when the artery is no longer compressed, blood flows freely and the sounds of Korotkoff can no longer be heard. The pressure at which the sounds disappear is recorded as the diastolic pressure (Figure 22.3d).

1. Work in pairs to obtain radial artery blood pressure readings. Obtain a stethoscope, alcohol swabs, and a sphygmomanometer. Clean the earpieces of the stethoscope with the alcohol swabs, and check the cuff for the presence of trapped air by compressing it against the laboratory table. (A partially inflated cuff will produce erroneous measurements.)

2. The subject should sit in a comfortable position with one arm resting on the laboratory table (approximately at heart level if possible). Wrap the cuff around the subject's arm, just above the elbow, with the inflatable area on the medial arm surface. The cuff may be marked with an arrow; if so, position the arrow over the brachial artery (Figure 22.3). Secure the cuff by tucking the distal end under the wrapped portion or by bringing the Velcro® areas together.

Text continues on next page. →

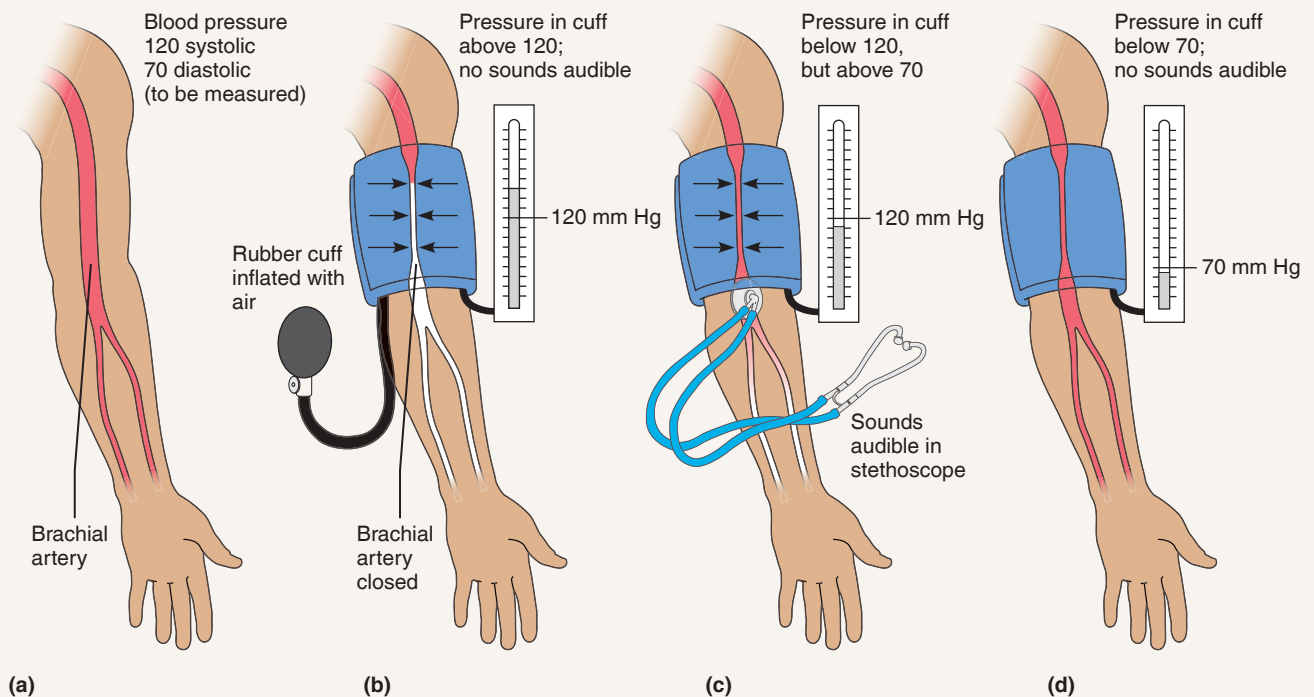


Figure 22.3 Procedure for measuring blood pressure. (Assume a blood pressure of 120/70.)

3. Palpate the brachial pulse, and lightly mark its position with a felt pen. Don the stethoscope, and place its diaphragm over the pulse point.



Do not keep the cuff inflated for more than 1 minute.

If you have any trouble obtaining a reading within this time, deflate the cuff, wait 1 or 2 minutes, and try again. (A prolonged interruption of blood flow can cause fainting.)

4. Inflate the cuff to approximately 160 mm Hg pressure, and slowly release the pressure valve. Watch the pressure gauge as you listen for the first soft thudding sounds of the blood spurting through the partially blocked artery.

Make a mental note of this pressure (systolic pressure), and continue to release the cuff pressure. You will notice first an increase, then a muffling, of the sound. Record as the diastolic pressure, the pressure at which the sound disappears. Make two blood pressure determinations, and record your results.

First trial:

systolic pressure _____

diastolic pressure _____

Second trial:

systolic pressure _____

diastolic pressure _____

Activity 5

Observing the Effect of Various Factors on Blood Pressure and Heart Rate

Arterial blood pressure (BP) is directly proportional to cardiac output (amount of blood pumped out of the left ventricle per minute; CO) and total peripheral resistance (TPR) to blood flow. The following equation shows this relationship:

$$BP = CO \times TPR$$

Total peripheral resistance is increased by blood vessel constriction (most importantly, the arterioles), by an increase in blood viscosity or volume, and by a loss of elasticity of the arteries (seen in arteriosclerosis). Any factor that increases either the cardiac output or the total peripheral resistance causes an almost immediate reflex rise in blood pressure. Two factors that alter blood pressure—posture and exercise—are investigated here.

To do the following tests efficiently, students should work in groups of four: one student acts as the subject and two as examiners (one taking the radial pulse, and the other auscultating the brachial blood pressure). A fourth student collects and records the data. The sphygmomanometer cuff should be left on the subject's arm throughout the experiments (in a deflated state, of course) so that, at the proper times, the blood pressure can be taken quickly. In each case, take the measurements at least twice.

Posture

To monitor circulatory adjustments to changes in position, take blood pressure and pulse measurements under the

conditions noted in the **Activity 5A Posture chart**. Also record your results in that chart.

Exercise

Changes in blood pressure and pulse during and after exercise provide a good yardstick for measuring overall cardiovascular fitness. Although there are more accurate tests to evaluate fitness, the *Harvard Step Test* described here is a quick way to compare the relative fitness level of a group of people.

You will be working in groups of four, duties assigned as indicated above, except that student 4, in addition to recording the data, will act as the timer and call the cadence (rhythm).



Any student with a known heart problem should refuse to be the subject.

All four students may act as the subject in turn, if desired, but the bench stepping is to be performed *at least twice* in each group—once with a well-conditioned person acting as the subject, and once with a poorly conditioned subject.

Bench stepping is the following series of movements repeated sequentially:

1. Place one foot on the step.
2. Step up with the other foot so that both feet are on the platform. Straighten the legs and the back.

Activity 5A: Cardiovascular Responses to Changes in Posture

BP = blood pressure

	Trial 1		Trial 2	
	BP	Pulse	BP	Pulse
Sitting quietly	_____	_____	_____	_____
Reclining (after 2 to 3 min)	_____	_____	_____	_____
Immediately on standing from the reclining position ("at attention" stance)	_____	_____	_____	_____
After standing for 3 min	_____	_____	_____	_____

3. Step down with the other foot.
4. Bring the other foot down.

The pace for the stepping will be set by the “timer” (student 4), who will repeat “Up-2-3-4, up-2-3-4” at such a pace that each “up-2-3-4” sequence takes 2 sec (so there are 30 cycles/min).

1. Student 4 should obtain the step (20-in. height for male subject, or 16 in. for a female subject) while baseline measurements are being obtained on the subject.
2. Once the baseline pulse and blood pressure measurements have been recorded in the **Activity 5B Exercise chart** below, the subject is to stand quietly at attention for 2 min to allow his or her blood pressure to stabilize before beginning to step.
3. The subject is to bench step for as long as possible, up to a maximum of 5 min, according to the cadence called by the timer. Watch the subject for crouching (posture must remain erect). If the subject is unable to keep the pace up for 15 sec, stop the test.
4. When the subject is stopped by the timer for crouching, stops voluntarily because he or she is unable to continue, or has completed 5 min of bench stepping, he or she is to sit down. At this point, record the duration of exercise (in seconds), and measure the blood pressure and pulse immediately and thereafter at 1-min intervals for 3 min postexercise.

Duration of exercise: _____ sec

5. The subject’s *index of physical fitness* is to be calculated using the following formula:

$$\text{index} = \frac{\text{duration of exercise in seconds} \times 100}{2 \times \text{sum of the 3 pulse counts in recovery}}$$

Scores are interpreted according to the following scale:

below 55	poor physical condition
55 to 62	low average
63 to 71	average
72 to 79	high average
80 to 89	good
90 and over	excellent

6. Record the test values in the chart below, and repeat the testing and recording procedure with the second subject.

When did you notice a greater elevation of blood pressure and pulse?

Explain: _____

Was there a sizeable difference between the after-exercise values for well-conditioned and poorly conditioned individuals?

_____ Explain: _____

Activity 5B: Cardiovascular Responses to Changes in Exercise										BP = blood pressure	P = pulse
Harvard Step Test for 5 min at 30/min	Baseline		Interval Following Test								
	BP	P	Immediately		1 min		2 min		3 min		
			BP	P	BP	P	BP	P	BP	P	
Well-conditioned individual	_____	_____	_____	_____	_____	_____	_____	_____	_____	_____	_____
Poorly conditioned individual	_____	_____	_____	_____	_____	_____	_____	_____	_____	_____	_____

Skin Color as an Indicator of Local Circulatory Dynamics

Skin color reveals, with surprising accuracy, the state of the local circulation. The experiments on local circulation that follow consider a number of factors that affect blood flow to the tissues.

A good clinical diagnosis often depends on good observation skills and logical interpretation of the findings. One of the earliest responses of the body to impaired blood flow to

the brain is constriction of the skin’s blood vessels. This reduces blood flow to the skin and diverts it into the circulatory mainstream to serve other, more vital tissues. As a result, the skin, particularly that of the extremities, becomes pale, cold, and eventually moist with perspiration. Therefore, pale, cold, clammy skin should immediately prompt a suspicion that the circulation is dangerously inadequate.

Activity 6

Examining the Effect of Local Chemical and Physical Factors on Skin Color

The local blood supply to the skin (indeed, to any tissue) is influenced by (1) local metabolites, (2) the oxygen supply, (3) local temperature, and (4) substances released by injured tissues, to name a few. Three of these factors are examined in the simple experiments that follow. Each experiment should be conducted by students in groups of three or four. One student will act as the subject; the others will conduct the tests and make and record observations.

Vasodilation and Flushing of the Skin Due to Lack of Oxygen

1. Obtain a blood pressure cuff (sphygmomanometer) and stethoscope. You will also need a watch with a second hand.
2. The subject should roll up the sleeves as high as possible and then lay the forearms side by side on the bench top.
3. Observe the general color of the subject's forearm skin, and the normal contour and size of the veins. Notice whether skin color is similar bilaterally. Record your observations:

4. Apply the blood pressure cuff to one arm, and inflate it to 250 mm Hg. Keep it inflated for 1 min. During this period, repeat the observations made above and record the results:

5. Release the pressure in the cuff (leaving the deflated cuff in position), and again record the forearm skin color and the condition of the forearm veins. Make this observation immediately after deflating and then again 30 sec later.

Immediately after deflating _____

30 sec after deflating _____

The above observations constitute your baseline information. Now conduct the following tests.

6. Instruct the subject to raise the cuffed arm above his or her head and to clench the fist as tightly as possible. While the hand and forearm muscles are tightly contracted, rapidly inflate the cuff to 240 mm Hg or more. This maneuver partially empties the hand and forearm of blood and stops most blood flow to the hand and forearm. Once the cuff has been inflated, the subject is to relax the

fist and return the forearm to the bench top so it can be compared to the other forearm.

7. Leave the cuff inflated for exactly 1 min. During this interval, compare the skin color in the "ischemic" (blood-deprived) hand to that of the "normal" (noncuffed limb) hand. After 1 min, quickly release the pressure.

What are the subjective effects (sensations felt by the subject, such as pain, cold, warmth, tingling, weakness) of stopping blood flow to the arm and hand for 1 min?

What are the objective effects (actual color of skin and condition of veins)?

How long does it take for the subject's ischemic hand to regain its normal color?

Effects of Venous Congestion

1. Again, but with a different subject, observe and record the appearance of the skin and veins on the forearms resting on the bench top. Pay particular attention to the color of the fingertips and the nail beds. Record this information:

2. Wrap the blood pressure cuff around one of the subject's arms, and inflate it to 40 mm Hg. Maintain this pressure for 5 min. Record the subjective and objective findings just before the 5 min are up, and then again immediately after release of the pressure at the end of 5 min.

Subjective (arm cuffed) _____

Objective (arm cuffed) _____

Subjective (pressure released) _____

Objective (pressure released) _____

3. With still another subject, conduct the following simple experiment: Raise one arm above the head, and let the other hang by the side for 1 min. After 1 min, quickly lay both arms on the bench top, and compare their color.

Color of raised arm _____

Color of dependent arm _____

From this and the two preceding observations, analyze the factors that determine tint of color (pink or blue) and intensity of skin color (deep pink or blue as opposed to light pink or blue). Record your conclusions.

Effect of Mechanical Stimulation of Blood Vessels of the Skin

With moderate pressure, draw the blunt end of your pen across the skin of a subject's forearm. Wait 3 min to observe the effects, and then repeat with firmer pressure.

What changes in skin color do you observe with light-to-moderate pressure?

With heavy pressure? _____

The redness, or *flare*, observed after mechanical stimulation of the skin results from a local inflammatory response promoted by *chemical mediators* released by injured tissues. These mediators stimulate increased blood flow into the area and cause the capillaries to leak fluid into the local tissues.

This page intentionally left blank

EXERCISE
22

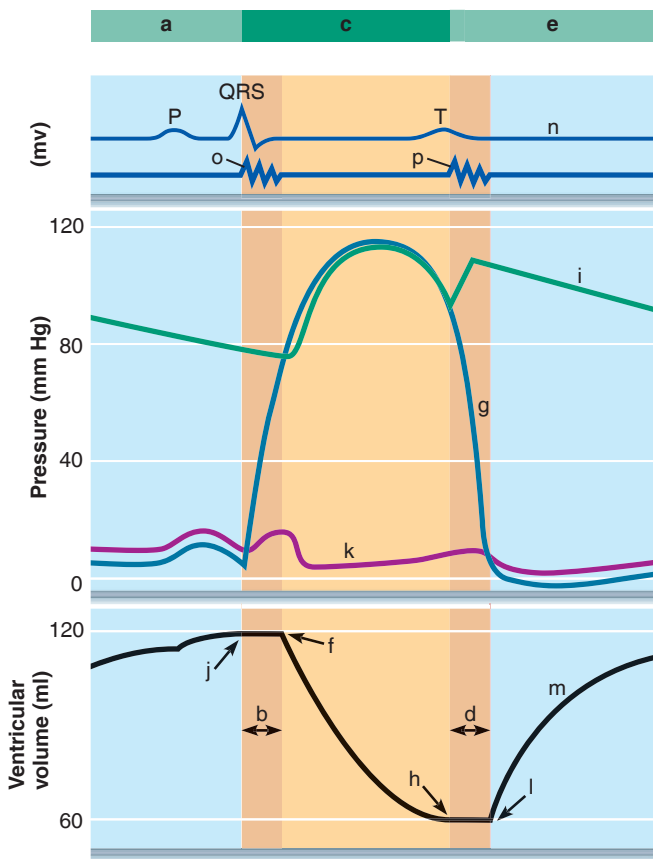
REVIEW SHEET

Human Cardiovascular Physiology—Blood Pressure and Pulse Determinations

Name _____ LabTime/Date _____

Cardiac Cycle

1. Using the terms to the right of the diagram, correctly identify each trace, valve closings and openings, and each time period of the cardiac cycle.



- _____ 1. aortic pressure
- _____ 2. atrial pressure (left)
- _____ 3. ECG
- _____ 4. first heart sound
- _____ 5. second heart sound
- _____ 6. ventricular pressure (left)
- _____ 7. ventricular volume
- _____ 8. aortic (semilunar) valve closes
- _____ 9. aortic (semilunar) valve opens
- _____ 10. AV and semilunar valves are closed (2 letters)
- _____ 11. AV valve closes
- _____ 12. AV valve opens
- _____ 13. ventricular diastole (2 letters)
- _____ 14. ventricular systole

2. Define the following terms:

systole: _____

diastole: _____

cardiac cycle: _____

3. Answer the following questions concerning events of the cardiac cycle:

During which phase of the cardiac cycle are the AV valves opened? _____

Describe the pressure difference that causes the AV valves to open. _____

During which phase of the cardiac cycle are the semilunar valves opened? _____

What event causes the semilunar valves to open? _____

Are both sets of valves closed during any part of the cycle? _____

If so, when? _____

Are both sets of valves open during any part of the cycle? _____

During which phase in the cardiac cycle is the pressure in the left ventricle highest? _____

What event results in the pressure deflection called the dicrotic notch? _____

4. If an individual's heart rate is 80 beats/min, what is the length of the cardiac cycle? _____

Heart Sounds

5. Complete the following statements:

The two monosyllables describing the heart sounds are 1.
 The first heart sound is a result of closure of the 2 valves, whereas
 the second is a result of closure of the 3 valves. The heart chambers
 that have just been filled when you hear the first heart sound
 are the 4, and the chambers that have just emptied are the 5.
 Immediately after the second heart sound, the 6 are filling with
 blood, and the 7 are empty.

1. _____

2. _____

3. _____

4. _____

5. _____

6. _____

7. _____

The Pulse

6. Define *pulse*: _____

7. Identify the artery palpated at each of the following pressure points:

at the wrist _____

on the dorsum of the foot _____

in front of the ear _____

at the side of the neck _____

in the groin _____

above the medial malleolus _____

8. How would you tell by simple observation whether bleeding is arterial or venous? _____

Blood Pressure Determinations

9. Define *blood pressure*: _____
10. Identify the phase of the cardiac cycle to which each of the following apply:
systolic pressure _____ diastolic pressure _____
11. What is the name of the instrument used to compress the artery and record pressures in the auscultatory method of determining blood pressure? _____
12. What are sounds of Korotkoff? _____

What causes the systolic sound? _____

What causes the disappearance of the sound? _____
13. Describe how blood pressure is measured using a sphygmomanometer. _____

14. Based on what you know about the relative positions of veins and arteries (Exercise 21), how would you expect venous pressures to compare to arterial pressures? _____
Why? _____

Observing the Effect of Various Factors on Blood Pressure and Heart Rate

15. What effect do the following have on blood pressure? (Use I to indicate increase and D to indicate decrease.)

_____ 1. increased diameter of the arterioles	_____ 4. hemorrhage
_____ 2. increased blood viscosity	_____ 5. arteriosclerosis
_____ 3. increased cardiac output	_____ 6. increased pulse rate

16. In which position (sitting, reclining, or standing) is the blood pressure normally the highest?

_____ The lowest? _____

What immediate changes in blood pressure did you observe when the subject stood up after sitting or reclining?

What changes in the blood vessels might account for the change? _____

After the subject stood for 3 minutes, what changes in blood pressure did you observe? _____

How do you account for this change? _____

17. What was the effect of exercise on blood pressure? _____

On pulse rate? _____


Skin Color as an Indicator of Local Circulatory Dynamics

18. Describe normal skin color and the appearance of the veins in the subject's forearm before any testing was conducted.


19. What changes occurred when the subject emptied the forearm of blood (by raising the arm and making a fist) and the flow was blocked with the cuff? _____

What changes occurred during venous congestion? _____

20. Explain the mechanism by which mechanical stimulation of the skin produced a flare. _____

21.  A left ventricular assist device (LVAD) is a medical device that is sometimes used as an alternative to heart transplant for patients who have a weakened left ventricle. Once implanted, the LVAD pumps blood from the left ventricle to the aorta. Name the phase of the cardiac cycle that this device assists:

_____. Describe the status of the AV and SL valves during this phase.

22.  Fainting (syncope) during or shortly after urination (micturition) is common in men of advanced age. Although the phenomenon of micturition syncope is not well understood, it is known to be due to a sudden drop in blood pressure.

Explain why dehydration would be an additional risk factor for micturition syncope. _____

Anatomy of the Respiratory System

Materials

- Resin cast of the bronchial tree (if available)
- Human torso model
- Respiratory organ system model and/or chart of the respiratory system
- Preserved inflatable lung preparation (obtained from a biological supply house) or sheep pluck fresh from the slaughterhouse
- Source of compressed air*
- 2-foot length of laboratory rubber tubing
- Dissecting tray
- Disposable gloves
- Disposable autoclave bag
- Demonstration area:

Station 1: Cross section of trachea set up for viewing under low power of a microscope

Station 2: Lung tissue set up for microscopic viewing

*If a compressed air source is not available, cardboard mouthpieces that fit the cut end of the rubber tubing should be available for student use. Disposable autoclave bags should also be provided for discarding the mouthpiece.

Learning Outcomes

- Define *pulmonary ventilation*, *external respiration*, and *internal respiration*.
- Identify the major structures of the upper respiratory system on a diagram or model, and describe their functions.
- Identify lower respiratory system organs and describe the structure of each.
- Recognize the microscopic structure of tissue of the trachea and lungs.

The major role of the respiratory system, our focus in this exercise, is to supply the body with the oxygen it needs and dispose of carbon dioxide. To fulfill this role, at least four distinct processes, collectively referred to as *respiration*, must occur.

Pulmonary ventilation: The movement of air into and out of the lungs; more simply called *breathing*.

External respiration: Gas exchanges to and from the pulmonary circuit blood that occur in the lungs (oxygen loading and carbon dioxide unloading).

Transport of respiratory gases: Transport of respiratory gases between the lungs and tissue cells of the body using blood as the transport vehicle.

Internal respiration: Exchange of gases to and from the blood capillaries of the systemic circulation (oxygen unloading and carbon dioxide loading).

Only the first two processes are the tasks of the respiratory system, but all four must occur for the respiratory system to function completely. Hence, the respiratory and circulatory systems are irreversibly linked.

Upper Respiratory System Structures

The upper respiratory system structures—the external nose, nasal cavity, pharynx, and paranasal sinuses—are summarized in **Table 23.1** and illustrated in **Figure 23.1**. As you read through the descriptions in the table, identify each structure in the figure.

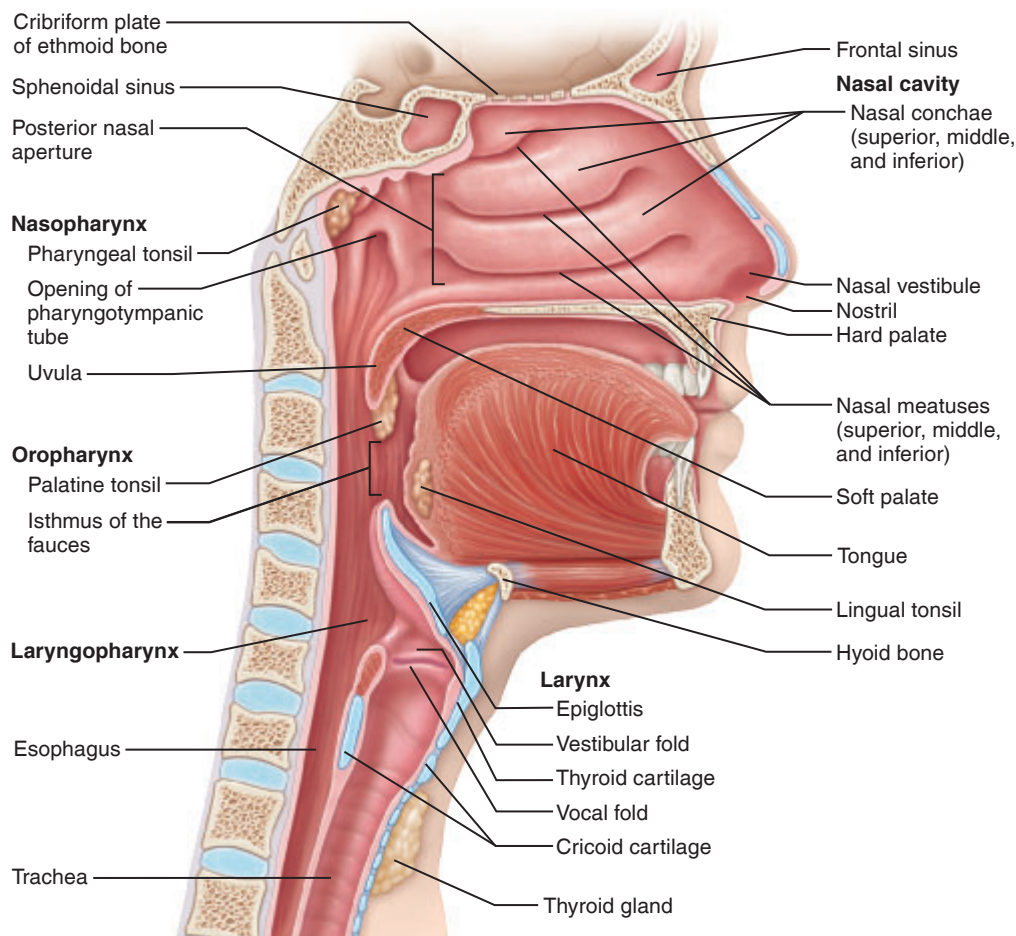
Activity 1

Identifying the Upper Respiratory System Organs

Before continuing identify all the respiratory organs described in Table 23.1 on a torso model or anatomical chart.

Table 23.1 Structures of the Upper Respiratory System (Figure 23.1)

Structure	Description	Function
External Nose	Externally visible, its inferior surface has nostrils (nares). Supported by bone and cartilage and covered with skin.	The nostrils provide an entrance for air into the respiratory system.
Nasal Cavity (includes the structures listed below)	Lined with respiratory mucosa composed of pseudostratified ciliated columnar epithelium. The floor of the cavity is formed by the hard and soft palates.	Functions to filter, warm, and moisten incoming air; resonance chambers for voice production.
Superior, middle, and inferior nasal conchae	Turbينات that project medially from the lateral walls of the cavity. Each concha has a corresponding meatus beneath it.	Increase the surface area of the mucosa, which enhances air turbulence and aids in trapping large particles in the mucus.
Pharynx (3 subdivisions: nasopharynx, oropharynx, and laryngopharynx—listed below)		
Nasopharynx	Superior portion of the pharynx located posterior to the nasal cavity. The pharyngeal tonsil and openings of the pharyngotympanic tubes are located in this region.	Provides for the passage of air from the nasal cavity. Tonsils in the region provide protection against pathogens.
Oropharynx	Located posterior to the oral cavity and extends from the soft palate to the epiglottis. Its lateral walls contain the palatine tonsils. The lingual tonsils are in the anterior oropharynx at the base of the tongue.	Provides for the passage of air and swallowed food. Tonsils provide protection against pathogens.
Laryngopharynx	Extends from the epiglottis to the larynx. It diverges into respiratory and digestive branches.	Provides for the passage of air and swallowed food.
Pharyngotympanic Tube	Tube that opens into the lateral walls of the nasopharynx and connects the nasopharynx to the middle ear.	Allows the middle ear pressure to equalize with the atmospheric pressure.
Paranasal Sinuses	Surround the nasal cavity and are named for the bones in which they are located.	Act as resonance chambers for speech; warm and moisten incoming air.

**Figure 23.1 Structures of the upper respiratory tract (sagittal section).**

Lower Respiratory System Structures

Anatomically, the lower respiratory structures include the larynx, trachea, bronchi, and lungs.

The **larynx** (Figure 23.1) is made up of nine cartilages, most quite small. The largest are the shield-shaped **thyroid cartilage**, whose anterior protrusion is commonly called the *Adam's apple*, and the more inferior ring-shaped **cricoid cartilage**. All laryngeal cartilages are composed of hyaline cartilage except the **epiglottis**, a flaplike elastic cartilage superior to the opening of the larynx. The epiglottis forms a lid over the larynx when we swallow. This closes off the respiratory passageway and routes the incoming food or drink into the esophagus, or food chute, posteriorly.

□ Palpate your larynx by placing your hand on the anterior neck surface approximately halfway down its length. Swallow. Can you feel the cartilaginous larynx rising?

The mucous membrane of the larynx is thrown into a pair of folds called the **vocal folds**, or **true vocal cords**, which vibrate with expelled air for speech. The slitlike passageway between the vocal folds is called the **glottis**.

Air entering the **trachea** travels down its length (about 4 inches) to the level of the fifth thoracic vertebra. There the passageway divides into the right and left **main (primary) bronchi** (Figure 23.2).

The trachea is lined with a ciliated mucus-secreting epithelium, as are many other respiratory system passageways. The cilia propel mucus (produced by goblet cells) loaded with dust particles, bacteria, and other debris away from the lungs and toward the throat, where it can be spat out or swallowed. The walls of the trachea are reinforced with C-shaped

cartilages, with the incomplete portion of the rings toward the esophagus. The open parts of these cartilages allow the esophagus to expand anteriorly when a large piece of food is swallowed. The solid portions reinforce the trachea walls to keep its passageway open regardless of the pressure changes that occur during breathing.

The main bronchi plunge into their respective lungs at an indented area called the **hilum** (see Figure 23.4b). The right main bronchus is wider, shorter, and more vertical than the left, and inhaled foreign objects are more likely to become lodged in it. Inside the lungs, the main bronchi divide further into smaller and smaller branches (the secondary, tertiary, on down), finally becoming the **bronchioles**. Each bronchiole divides into many **terminal bronchioles**. Each terminal bronchiole branches into two or more **respiratory bronchioles** (Figure 23.2b). All but the tiniest branches have cartilage in their walls, usually in the form of small plates of hyaline cartilage. As the respiratory tubes get smaller and smaller, the relative amount of smooth muscle in their walls increases and the amount of cartilage declines and finally disappears. The continuous branching of the respiratory passageways in the lungs is often referred to as the **bronchial tree**.

□ The comparison becomes much more meaningful if you observe a cast of the respiratory passages. Do so, if one is available for observation in the laboratory.

The respiratory bronchioles subdivide into **alveolar ducts**, which end in alveolar sacs that rather resemble clusters of grapes. **Alveoli**, tiny balloonlike expansions that each

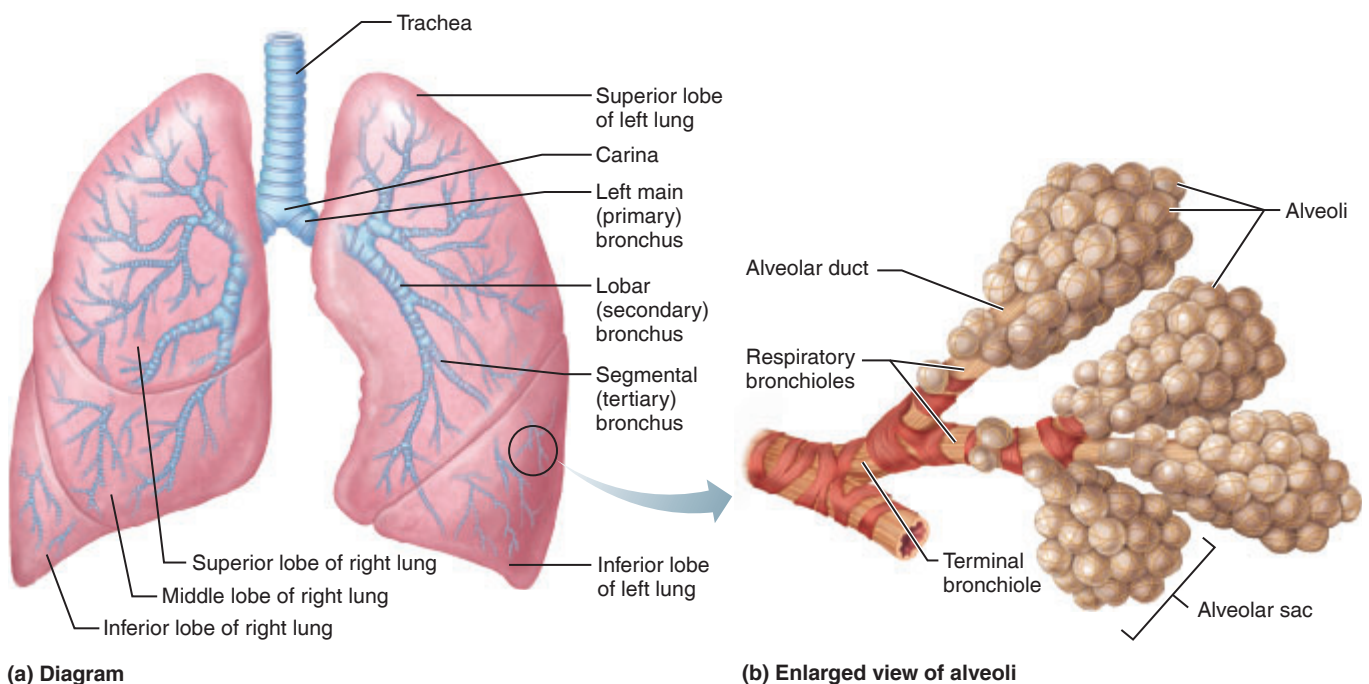


Figure 23.2 Structures of the lower respiratory tract.

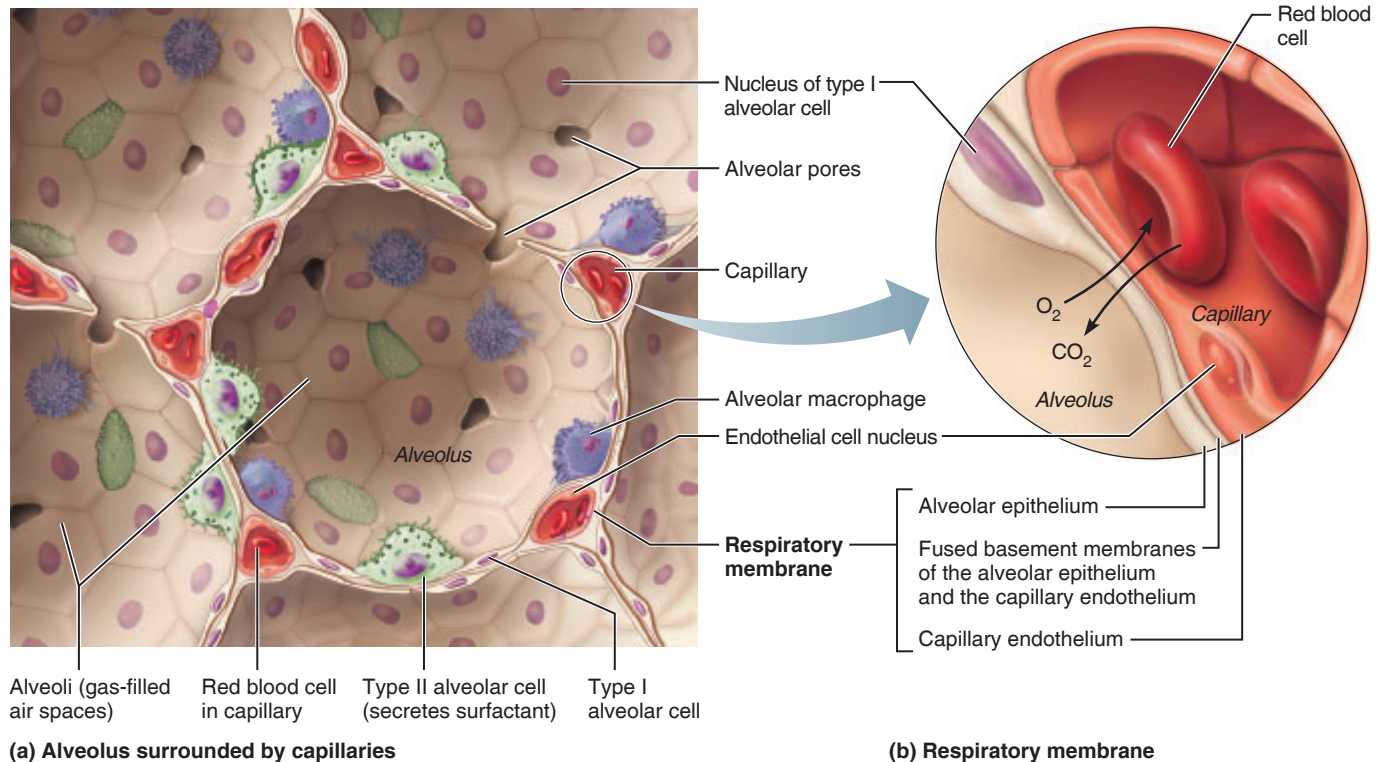


Figure 23.3 Diagram of the relationship between the alveoli and pulmonary capillaries involved in gas exchange.

represent a single grape in the alveolar sac, are composed of a single thin layer of squamous epithelium (called type I alveolar cells) overlying a wispy connective tissue layer. Type II alveolar cells secrete a fluid called *surfactant*, which alters the surface tension of the alveoli to prevent a collapse. The external surfaces of the alveoli are densely spiderwebbed with pulmonary capillaries (**Figure 23.3**). Together, the alveolar and capillary walls and their fused basement membranes form the **respiratory membrane**.

Because gas exchanges occur by simple diffusion across the respiratory membrane, the alveoli, alveolar ducts, and respiratory bronchioles are referred to as **respiratory zone structures**. All other respiratory passageways serve as access or exit routes to and from these gas exchange chambers and are called **conducting zone structures**.

The Lungs and Pleurae

The paired lungs are soft, spongy organs that occupy the entire thoracic cavity except for the *mediastinum*, which houses the heart, bronchi, esophagus, and other organs (**Figure 23.4**). Each lung is connected to the mediastinum by a *root* containing its vascular supply and bronchial attachments. All structures distal to the primary bronchi are inside the lungs. A lung's *apex*, its narrower superior aspect, is just deep to the clavicle, and its *base*, the inferior surface, rests on the diaphragm. The medial surface of the left lung has a recess, or impression, that accommodates the heart. Fissures divide the lungs into a number of *lobes*—two in the left lung and three in the right. Other than the respiratory passageways and air spaces that make up their bulk, the lungs

are mostly elastic connective tissue, which allows them to recoil passively during expiration.

Each lung is enclosed in a double-layered serous membrane sac called the **pleura**. The outer layer, the **parietal pleura**, is attached to the thoracic walls and the **diaphragm**. The inner layer, covering the lung tissue, is the **visceral pleura**. The two pleural layers are separated by the *pleural cavity*. The pleural layers produce lubricating serous fluid that causes them to adhere closely to one another, holding the lungs to the thoracic wall and allowing them to move easily against one another during the movements of breathing.

Activity 2

Identifying the Lower Respiratory System Organs

Before proceeding, be sure to locate all the lower respiratory structures described on the torso model, thoracic cavity structures model, or an anatomical chart.

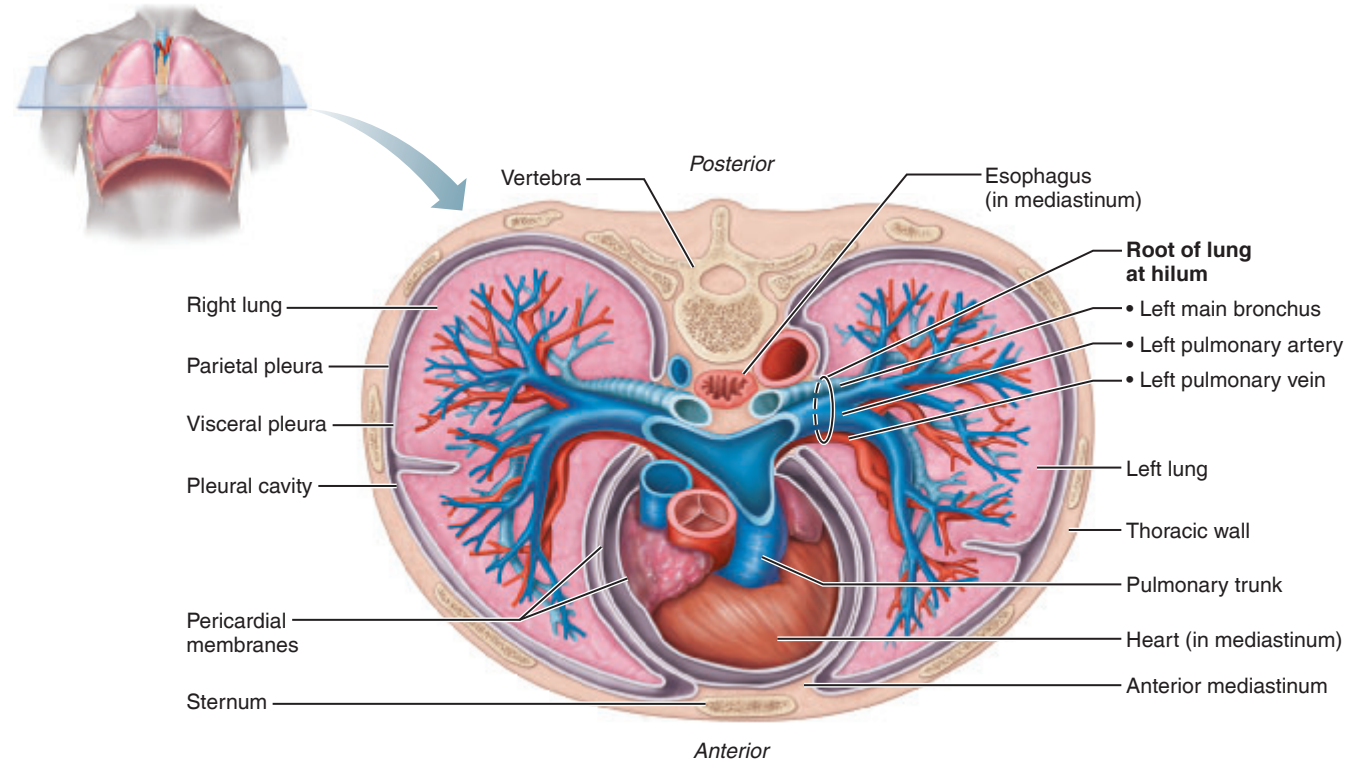
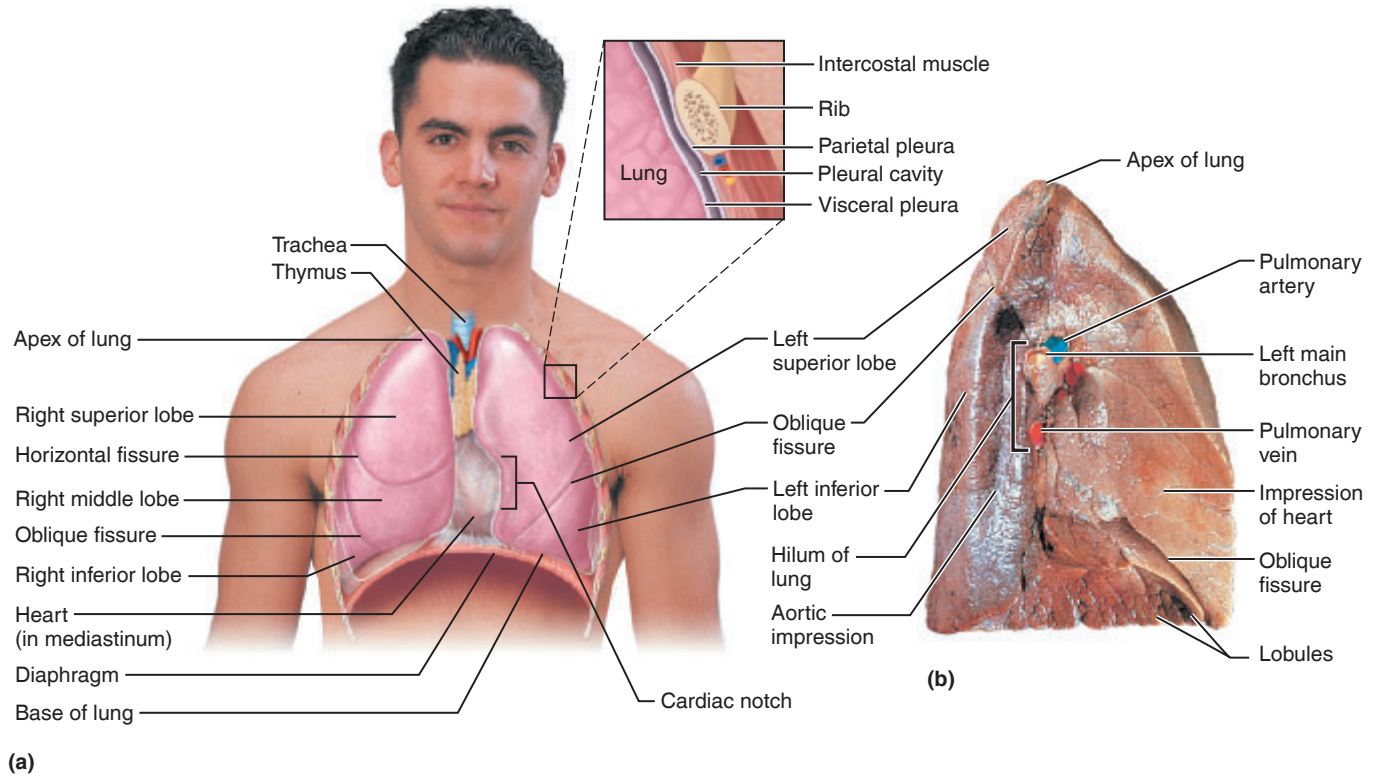



Figure 23.4 Anatomical relationships of organs in the thoracic cavity. (a) Anterior view of the thoracic organs. The lungs flank the central mediastinum. The enlargement at upper right depicts the pleura and the pleural cavity. (b) Photograph of medial aspect of left lung. (c) Transverse section through the superior part of the thorax, showing the lungs and the main organs in the mediastinum. Note that the size of the pleural cavity is exaggerated for clarity.


Activity 3

Demonstrating Lung Inflation in a Sheep Pluck

A *sheep pluck* includes the larynx, trachea with attached lungs, the heart, and portions of the major blood vessels found in the mediastinum.

 Don disposable gloves, obtain a fresh sheep pluck (or a preserved pluck of another animal), and identify the lower respiratory system organs. Once you have completed your observations, insert a hose from an air compressor (vacuum pump) into the trachea, and allow

air to flow alternately into and out of the lungs. Notice how the lungs inflate. This observation is educational in a preserved pluck but it is a spectacular sight in a fresh one. When a fresh pluck is used, it changes color (becomes redder) as hemoglobin in trapped red blood cells becomes loaded with oxygen.

 Dispose of the mouthpiece and gloves in the autoclave bag immediately after use.

Activity 4

Examining Prepared Slides of Trachea and Lung Tissue

1. Go to station 1 at the demonstration area to examine a slide of a cross section of the tracheal wall. Identify the smooth muscle layer, the hyaline cartilage supporting rings, and the pseudostratified ciliated epithelium. Using **Figure 23.5a** and Plates 27 and 28 in the Histology Atlas as a guide, also try to identify a few goblet cells in the epithelium.

2. Next, at station 2, examine a slide of lung tissue. The alveolus is the main structural and functional unit of the lung and is the actual site of gas exchange. Identify the

thin squamous epithelium of the alveolar walls (Figure 23.5b). (See also Plate 26 in the Histology Atlas.)

How does the structure of the alveolar walls aid in their

role of gas exchange? _____

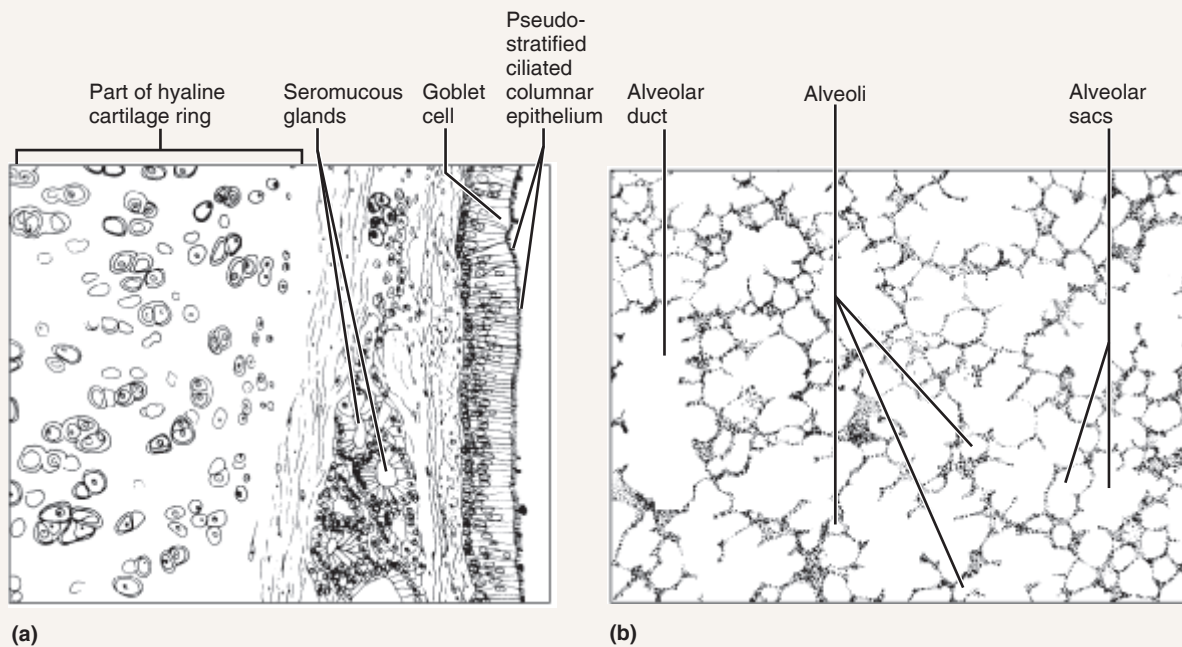


Figure 23.5 Microscopic structure of (a) a portion of the trachea, cross-sectional view, and (b) alveoli.

EXERCISE
23

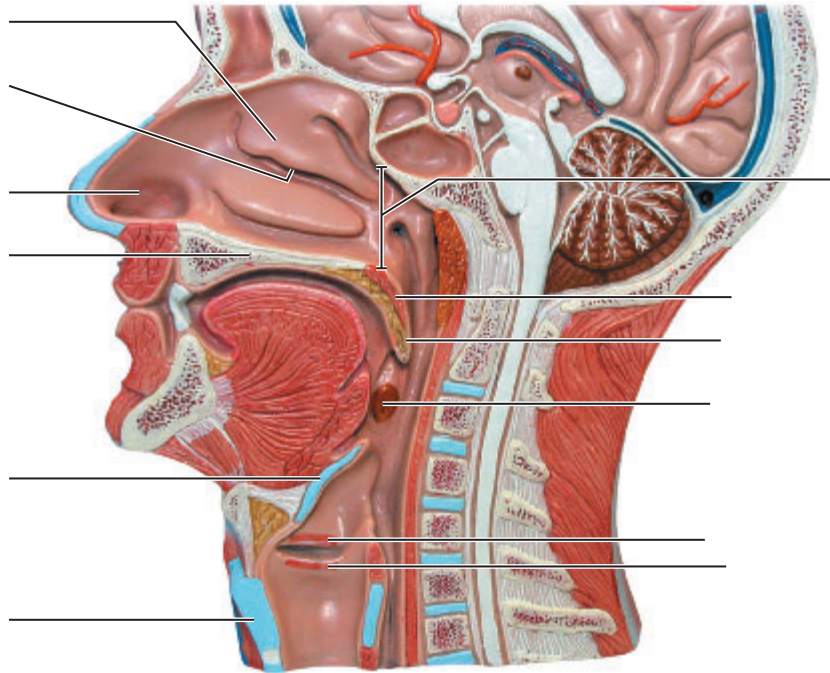
REVIEW SHEET

Anatomy of the Respiratory System

Name _____ Lab Time/Date _____

Upper and Lower Respiratory System Structures

1. Label the upper respiratory structures (sagittal section) shown in the model below.



2. Why is it important that the human trachea is reinforced with cartilage rings?

Why is it important that the rings are incomplete posteriorly? _____

3. Name the specific cartilages in the larynx that are described below:

1. forms the Adam's apple _____ 3. shaped like a ring _____

2. a "lid" for the larynx _____

4. Trace a molecule of oxygen from the nostrils (nares) to the pulmonary capillaries of the lungs:

Nostrils → _____

_____ → pulmonary capillaries

5. What is the function of the pleural fluid? _____

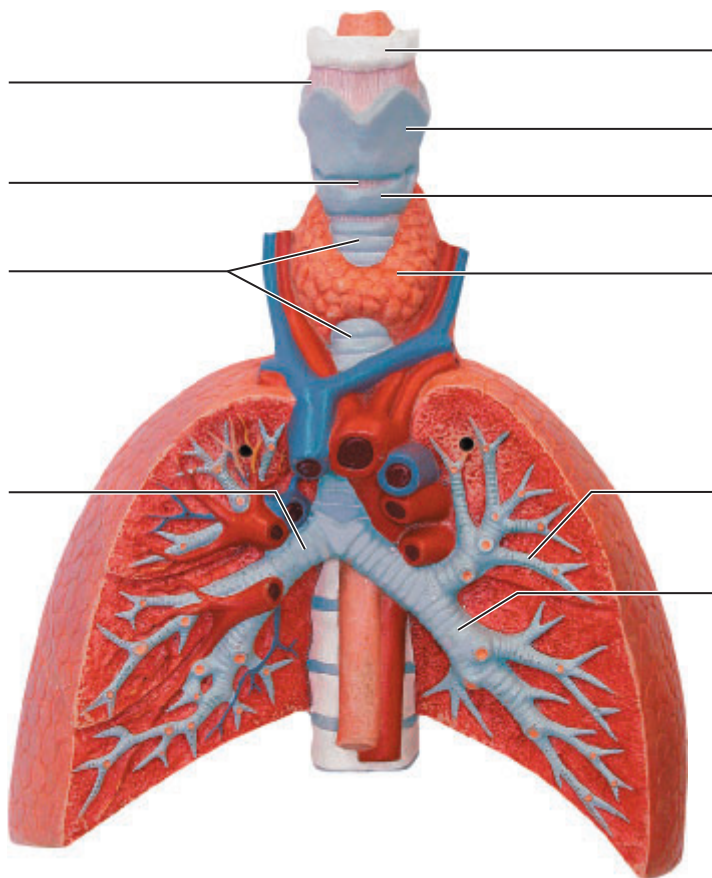
6. Name two functions of the nasal conchae. _____

7. The following questions refer to the primary bronchi:

Which is longer? _____ Larger in diameter? _____ More horizontal? _____

The more common site for lodging of a foreign object that has entered the respiratory passageways? _____

8. Appropriately label all structures provided with leader lines on the model shown below.



9. Match the terms in column B to those in column A.

Column A	Column B
_____ 1. pleural layer attached directly to the lung	alveolus
_____ 2. "floor" of the nasal cavity	concha
_____ 3. food and fluid passageway inferior to the laryngopharynx	epiglottis
_____ 4. flaps over the glottis during swallowing of food	esophagus
_____ 5. contains the vocal cords	glottis
_____ 6. the part of the conducting pathway between the larynx and the main bronchi	larynx
_____ 7. pleural layer lining the walls of the thorax	palate
_____ 8. site from which oxygen enters the pulmonary blood	parietal pleura
_____ 9. opening between the vocal folds	trachea
_____ 10. increases air turbulence in the nasal cavity	visceral pleura

10. Define *external respiration*: _____

internal respiration: _____

Demonstrating Lung Inflation in a Sheep Pluck

11. Does the lung inflate part by part or as a whole, like a balloon? _____

What happened when the pressure was released? _____

What type of tissue ensures this phenomenon? _____

Examining Prepared Slides of Lung and Tracheal Tissue

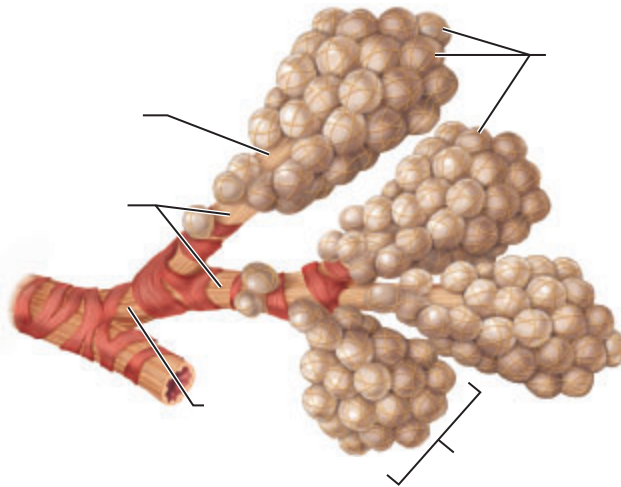
12. The tracheal epithelium is ciliated and has goblet cells. What is the function of each of these modifications?

cilia: _____


goblet cells: _____


13. The tracheal epithelium is pseudostratified. Describe the appearance of a pseudostratified epithelium.

14. On the diagram below, identify alveolar duct, respiratory bronchioles, terminal bronchiole, alveoli, and alveolar sac.



15. By what process does oxygen move from the alveolar sac into the blood in a pulmonary capillary? Which of these structures, the alveolus or the pulmonary capillary, would initially have a higher partial pressure of oxygen? _____

16.  Epiglottitis is a condition in which the epiglottis is inflamed. It is most often caused by a bacterial infection. Explain why this type of inflammation is life-threatening. _____

17.  Pneumonia is an infectious disease in which fluid accumulates in the alveoli. Patients who are diagnosed with pneumonia are monitored for their oxygen saturation levels. Describe how pneumonia could affect the amount of oxygen in the blood. _____

Respiratory System Physiology

Materials

- Model lung (bell jar demonstrator)
- Tape measure
- Spirometer (nonrecording)
- Disposable mouthpieces
- Nose clips
- Alcohol swabs
- 70% ethanol solution in a battery jar
- Disposable autoclave bag
- Paper bag
- Pneumograph, recording attachments, and recording apparatus—kymograph or physiograph (if available)
- Table for recording class data
- Millimeter ruler

Learning Outcomes

- Define *inspiration* and *expiration*, and explain the role of muscles and volume changes in the mechanical process of breathing.
- Define and provide volume figures for the various respiratory volumes investigated in the laboratory.
- Demonstrate proper usage of a spirometer.
- Explain the relative importance of various chemical and mechanical factors causing respiratory variations.

Mechanics of Respiration

Pulmonary ventilation, or breathing, consists of two phases: **inspiration**, when air is flowing into the lungs, and **expiration**, when air passes out of the lungs. As the inspiratory muscles contract, the size of the thoracic cavity increases. The diaphragm moves from its relaxed dome shape to a flattened position, increasing the vertical dimension, and the external intercostal muscles lift the rib cage, increasing the anteroposterior and lateral dimensions (**Figure 24.1**). Since the lungs adhere to the thoracic walls because of the presence of serous fluid in the pleural cavity, the intrapulmonary volume also increases, lowering the air (gas) pressure inside the lungs. The gases then expand to fill the available space, creating a partial vacuum that causes airflow into the lungs—the act of inspiration.

During expiration, the inspiratory muscles relax, and the elastic lung tissue recoils. Thus, both the intrathoracic and intrapulmonary volumes decrease. As the gas molecules within the lungs are forced closer together, intrapulmonary pressure rises above atmospheric pressure. This causes gases to flow out of the lungs to equalize the pressure inside and outside the lungs—the act of expiration.

Activity 1

Operating the Model Lung

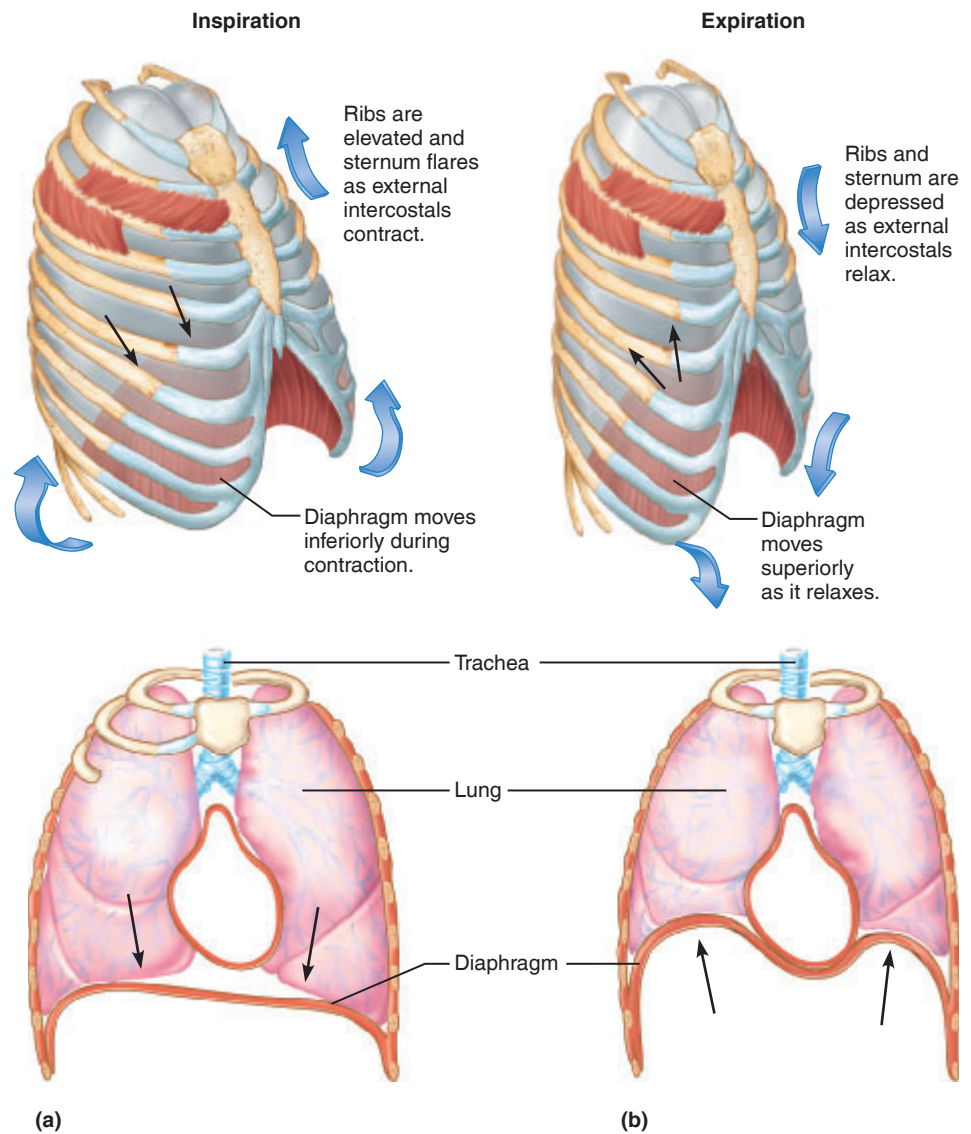
Observe the bell jar model of the lungs, which demonstrates the principles involved as gas flows into and out of the lungs. It is a simple device with a hard plastic dome-shaped container called a bell jar (representing the parietal pleura), the interior of the bell jar (representing the thoracic cavity), a rubber membrane (representing the diaphragm), two balloons (representing the lungs), and an inverted Y-shaped tube (representing the trachea and main bronchi).

1. Go to the demonstration area, and work the model lung by moving the rubber diaphragm up and down. Notice the changes in balloon (lung) size as the volume of the thoracic cavity is alternately increased and decreased. Note that this demonstration shows the effects of manipulating the diaphragm only. The lungs would show a more dramatic change if the action of the rib cage could also be shown.

2. Check the appropriate columns in the chart concerning these observations in the Review Sheet at the end of this exercise.

Text continues on next page. →

Figure 24.1 Rib cage and diaphragm positions during breathing. (a) At the end of a normal inspiration: chest expanded, diaphragm contracted. (b) At the end of a normal expiration: chest depressed, diaphragm relaxed.



24

3. After observing the operation of the model lung, conduct the following tests on your lab partner. Use the tape measure to determine chest circumference by placing the tape around the chest as high up under the armpits as possible. Record the measurements in inches in the appropriate space for each of the conditions.

Quiet breathing:

Inspiration _____ Expiration _____

Forced breathing:

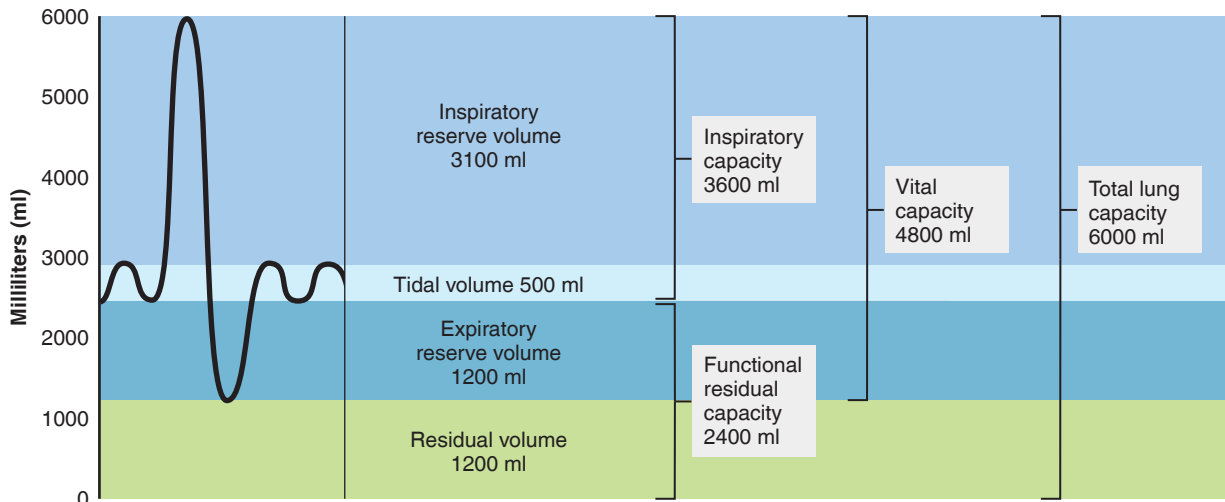
Inspiration _____ Expiration _____

Respiratory Volumes and Capacities—Spirometry

A person's size, sex, age, and physical condition can all produce variations in respiratory volumes. Normal quiet breathing moves about 500 ml of air into and out of the lungs with each breath. As you have seen in the first activity, we can usually forcibly inhale or exhale much more air than is exchanged in normal quiet breathing. The terms denoting the

measurable respiratory volumes and capacities are defined and illustrated with an idealized tracing in **Figure 24.2**.

Respiratory volumes are measured with an apparatus called a **spirometer**. There are two major types of spirometers, which give comparable results—the handheld dry, or wheel, spirometers, such as the Wright spirometer



(a) Spirographic record for a male

	Measurement	Adult male average value	Adult female average value	Description
Respiratory volumes	Tidal volume (TV)	500 ml	500 ml	Amount of air inhaled or exhaled with each breath under resting conditions
	Inspiratory reserve volume (IRV)	3100 ml	1900 ml	Amount of air that can be forcefully inhaled after a normal tidal volume inspiration
	Expiratory reserve volume (ERV)	1200 ml	700 ml	Amount of air that can be forcefully exhaled after a normal tidal volume expiration
	Residual volume (RV)	1200 ml	1100 ml	Amount of air remaining in the lungs after a forced expiration
Respiratory capacities	Total lung capacity (TLC)	6000 ml	4200 ml	Maximum amount of air contained in lungs after a maximum inspiratory effort: $TLC = TV + IRV + ERV + RV$
	Vital capacity (VC)	4800 ml	3100 ml	Maximum amount of air that can be expired after a maximum inspiratory effort: $VC = TV + IRV + ERV$
	Inspiratory capacity (IC)	3600 ml	2400 ml	Maximum amount of air that can be inspired after a normal tidal volume expiration: $IC = TV + IRV$
	Functional residual capacity (FRC)	2400 ml	1800 ml	Volume of air remaining in the lungs after a normal tidal volume expiration: $FRC = ERV + RV$

(b) Summary of respiratory volumes and capacities for males and females

Figure 24.2 Respiratory volumes and capacities.

(Figure 24.3a) and “wet” spirometers, such as the Phipps and Bird spirometer (Figure 24.3b). The more sophisticated wet spirometer consists of a plastic or metal *bell* that air can be added to or removed from and that rests in a rectangular

or cylindrical tank. The tank contains water and has a tube running through it to carry air above the water level and into the floating bottomless bell, which is inverted over the water-containing tank and connected to a volume indicator.

Activity 2

Measuring Respiratory Volumes

1. Before using the spirometer, count and record the subject’s normal respiratory rate.

Respirations per minute _____

2. Identify the parts of the spirometer you will be using by comparing it to Figure 24.3a or b. Before you begin,

examine the spirometer volume indicator to make sure you know how to read the scale. Work in pairs, with one person acting as the subject while the other records the volume measured. The subject should stand up straight during testing. *Note:* Reset the indicator to zero before beginning each trial.

Text continues on next page. →




Figure 24.3 Spirometers. (a) The Wright handheld dry spirometer. Reset to zero prior to each test. (b) The Phipps and Bird “wet” spirometer.

Obtain a disposable cardboard mouthpiece and clean the valve assembly with an alcohol swab. Then insert it in the open end of the valve assembly (attached to the flexible tube) of the wet spirometer or over the fixed stem of the handheld dry spirometer. Before beginning, the subject should practice exhaling through the mouthpiece without exhaling through the nose, or prepare to use the nose clips (clean them first with an alcohol swab). If you are using the handheld spirometer, make sure its dial faces upward so that the volumes can be easily read during the tests.

3. Ensure the subject stands erect during testing. Run the test three times for each required measurement. Record the data, and then find the average volume figure for that measurement. After you have completed the trials and calculated the averages, enter the average values on the table prepared on the board for tabulating class data, and copy all averaged data onto the Review Sheet.

4. Measure **tidal volume (TV)**. The TV, or volume of air inhaled and exhaled with each normal respiration, is approximately 500 ml (see Figure 24.2). To conduct the test, inhale a normal breath, and then exhale a normal breath of air into the spirometer mouthpiece. (Do not force the expiration!) Record the volume, and repeat the test twice more.

trial 1 _____ ml trial 2 _____ ml
 trial 3 _____ ml average TV _____ ml

5. Measure **expiratory reserve volume (ERV)**. The expiratory reserve volume, the volume of air that can be forcibly exhaled after a normal expiration, ranges between 700 and 1200 ml.

Inhale and exhale normally two or three times. Then, insert the spirometer mouthpiece, and exhale forcibly as

much of the additional air as you can. Record your results, and repeat the test twice more.

trial 1 _____ ml trial 2 _____ ml
 trial 3 _____ ml average ERV _____ ml

6. Measure **vital capacity (VC)**. The VC, or total exchangeable air of the lungs (the sum of TV + IRV + ERV), is normally around 4500 ml with a range of 3100 ml to 4800 ml.

Breathe in and out normally two or three times, and then bend over and exhale all the air possible. Then, as you raise yourself to the upright position, inhale as fully as possible. (It is very important to strain to inhale as much air as you possibly can.) Quickly insert the mouthpiece, and exhale as forcibly as you can. Record your results and repeat the test twice more.

trial 1 _____ ml trial 2 _____ ml
 trial 3 _____ ml average VC _____ ml

7. Calculate the **inspiratory reserve volume (IRV)**, or volume of air that can be forcibly inhaled following a normal inspiration. You can now calculate the IRV; using the average values you obtained for TV, ERV, and VC, plug them into this equation:

$$IRV = VC - (TV + ERV)$$

Record your average IRV: _____ ml

The normal IRV is substantial, ranging from 1900 to 3100 ml. How does your calculated value compare?

Reexamine Figure 24.2 carefully. How closely do your test results compare to the values in that tracing?

8. Calculate **residual volume (RV)**. A respiratory volume that cannot be experimentally demonstrated here is RV, the amount of air remaining in the lungs after a maximal expiratory effort. The presence of RV (usually about 1200 ml) is important because it allows gas exchange to go on continuously—even between breaths.

Although RV cannot be measured directly, you can approximate it by using one of the following factors:

For ages 16–34	Factor = 0.250
For ages 35–49	Factor = 1.305
For ages 50–69	Factor = 1.445

Compute your predicted RV using the following equation:

$$RV = VC \times \text{factor}$$



9. Finish recording for this subject. Before continuing with the next member of your group:

- Dispose of used cardboard mouthpieces in the autoclave bag.
- Swish the valve assembly (if removable) in the 70% ethanol solution, then rinse with tap water.
- Put a fresh mouthpiece into the valve assembly (or on the stem of the handheld spirometer). Using the procedures outlined previously, measure and record the respiratory volumes for all members of your group.

Factors Influencing Rate and Depth of Respiration

The neural centers that control respiratory rhythm and depth are located in the medulla and pons. Although the neural centers maintain the rate of breathing, typically at 12 to 18 respirations/min, physical actions such as talking, yawning, coughing, and exercise can modify the rate and depth of respiration. So too can chemical factors such as changes in oxygen or carbon dioxide concentrations in the blood or changes in blood pH. Changes in carbon dioxide blood levels act directly on the medulla control centers, whereas changes in pH and oxygen levels are monitored by chemoreceptor regions in the aortic and carotid bodies, which in turn send input to the medulla. Experiments in this section test the relative importance of various physical and chemical factors in the process of respiration.

The **pneumograph**, an apparatus that records variations in breathing patterns, is the best means of observing respiratory variations. The chest pneumograph is a coiled rubber hose that is attached around the thorax. As the subject breathes, chest movements produce pressure changes within the pneumograph that are transmitted to a recorder.

The instructor will demonstrate the method of setting up the pneumograph and discuss the interpretation of the results. Work in pairs so that one person can mark the record to identify the test for later interpretation. Ideally, the student being tested should face *away* from the recording apparatus.

Activity 3

Visualizing Respiratory Variations

1. Attach the pneumograph tubing firmly, but not restrictively, around the thoracic cage at the level of the sixth rib, leaving room for the chest to expand during testing. If the subject is female, position the tubing above the breasts to prevent slippage during testing. Set the pneumograph speed at 1 or 2, and the time signal at 10-second intervals. Record quiet breathing for 1 minute with the subject in a sitting position. If the pneumograph is not available, simply count the subject's breaths per minute.

Record breaths per minute: _____

2. The next step is to make a vital capacity tracing. (This will not be done if the pneumograph is not available. Use the VC measurement obtained earlier as your baseline.) Record a maximal inhalation followed by a maximal exhalation. This should agree with the vital capacity measurement obtained earlier and will provide a baseline for comparison

during the rest of the pneumograph testing. Stop the recording apparatus and mark the graph appropriately to indicate tidal volume, expiratory reserve volume, inspiratory reserve volume, and vital capacity (the total of the three measurements). Also mark, with arrows, the direction the recording stylus moves during inspiration and during expiration.

Measure in millimeters the height of the vital capacity recording. Divide the vital capacity measurement average recorded on the Review Sheet by the number of millimeters to obtain the volume (in milliliters of air) represented by 1 mm on the recording. For example, if your vital capacity reading is 4000 ml and the vital capacity tracing occupies a vertical distance of 40 mm on the pneumograph recording, then a vertical distance of 1 mm equals 100 ml of air.

Record your computed VC value: _____ ml air/mm

Text continues on next page. →

3. Record or count the subject's breathing as he or she performs activities from the list that follows. Make sure the record is marked accurately to identify each test conducted. Record your results on the Review Sheet.

- | | |
|------------------|----------------------|
| talking | swallowing water |
| yawning | coughing |
| laughing | lying down |
| standing | doing a math problem |
| running in place | (concentrating) |

4. Without recording, have the subject breathe normally for 2 minutes then inhale deeply and hold his or her breath for as long as he or she can.

Time the breath-holding interval: _____ sec

As the subject exhales, turn on the recording apparatus, and record the recovery period (time to return to normal breathing—usually slightly over 1 minute):

Time of recovery period: _____ sec

Did the subject have the urge to inspire *or* expire during breath holding?

Without recording, repeat the above experiment, but this time have the subject exhale completely and forcefully *after* taking the deep breath. What was observed this time?

5. During the next task, the subject may experience dizziness. As the carbon dioxide is washed out of the blood by hyperventilation, the blood pH increases, leading to a decrease in blood pressure and reduced cerebral circulation.



If you have a history of dizzy spells or a heart condition, do not perform this task.

The subject may experience a lack of desire to breathe after forced breathing is stopped. If the period of breathing cessation—apnea—is extended, cyanosis of the lips may occur.

Have the subject hyperventilate (breathe deeply and forcefully at the rate of 1 breath/4 sec) for about 30 seconds. Record, or visually count breaths per minute, both during and after hyperventilation. How does the pattern obtained during hyperventilation compare with that recorded during the vital capacity tracing?

Is the respiratory rate after hyperventilation faster *or* slower than during normal quiet breathing?

6. Repeat the above test, but do not record or do a visual count until after hyperventilation. After hyperventilation, the subject is to hold his or her breath as long as he or she can. Can the subject hold his or her breath for a longer or shorter time after hyperventilating?

7. Without recording, have the subject breathe into a paper bag for 3 minutes, and then record his or her breathing movements.



During the bag-breathing exercise, the subject's partner should watch the subject carefully for any unusual reactions.

Is the breathing rate faster *or* slower than that recorded during normal quiet breathing?

After hyperventilating? _____

8. Have the subject run in place for 2 minutes, and then determine the length of time that the person can hold his or her breath.

Length of breath holding: _____ sec

9. To prove that respiration has a marked effect on circulation, conduct the following test. Before you begin, record the rate and relative force of your lab partner's radial pulse.

Rate _____ beats/min Relative force _____

Have your partner inspire forcibly. The person then immediately closes the mouth and nose to retain the inhaled air and makes a forceful and prolonged expiration. Observe and record the condition of the blood vessels of your partner's neck and face, and again immediately palpate the radial pulse.

Observations _____

Radial pulse _____ beats/min Relative force _____

Explain the changes observed. _____



Dispose of the paper bag in the autoclave bag. Keep the pneumograph records to interpret results, and hand them in if the instructor requests them. By looking at the test results, you should be able to determine which chemical factor has the greater effect on modifying the respiratory rate and depth.

EXERCISE
24

REVIEW SHEET

Respiratory System Physiology

Name _____ Lab Time/Date _____

Mechanics of Respiration

1. Base your answers to the following on your observations of the operation of the model lung.

Under what *internal* conditions of the thoracic cavity does air tend to flow into the lungs? _____

Under what *internal* conditions of the thoracic cavity does air tend to flow out of the lungs? Explain. _____

2. Activation of the diaphragm and the external intercostal muscles begins the inspiratory process. What effect does contraction of these muscles have on thoracic volume, and how is this accomplished? _____

3. What was the approximate increase in diameter of chest circumference during a quiet inspiration?

_____ inches During forced inspiration? _____ inches

4. What temporary advantage does the substantial increase in chest circumference during forced inspiration create?

Respiratory Volumes and Capacities: Spirometry

5. Write the respiratory volume term and the normal value that is described by the following statements:

Volume of air present in the lungs after a forceful expiration _____

Volume of air that can be expired forcibly after a normal expiration _____

Volume of air that is breathed in and out during a normal respiration _____

Volume of air that can be inspired forcibly after a normal inspiration _____

Volume of air corresponding to TV + IRV + ERV _____

6. Record experimental respiratory volumes as determined in the laboratory.

Average TV _____ ml Average VC _____ ml
 Average ERV _____ ml Average IRV _____ ml

Factors Influencing Rate and Depth of Respiration

7. Where are the neural control centers of respiratory rhythm? _____ and _____
8. Based on pneumograph reading of respiratory variation, what was the rate of quiet breathing?

Initial testing _____ breaths/min

Record observations of how the initial pneumograph recording was modified during the various testing procedures described below. Indicate the respiratory rate, and include comments on the relative depth of the respiratory peaks observed.

Pneumograph Readings	
Test performed	Observations (breaths per minute)
Talking	
Yawning	
Laughing	
Standing	
Running in place	
Swallowing water	
Coughing	
Lying down	
Concentrating	

9. Student data:

Breath-holding interval after a deep inhalation _____ sec length of recovery period _____ sec

Breath-holding interval after a forceful expiration _____ sec length of recovery period _____ sec

After breathing quietly and taking a deep breath (which you held), was your urge to inspire or expire? _____

After exhaling and then holding your breath, did you want to inspire or expire? _____

10. Observations after hyperventilation: _____

11. Blood CO_2 levels and blood pH are related. When blood CO_2 levels increase, the pH increases.

Explain what changes would occur in the blood's pH if the breathing rate were increased or decreased. _____

12. Length of breath holding after hyperventilation: _____ sec

Why does hyperventilation produce apnea or reduce respiratory rate? _____

13. Observations for rebreathing breathed air: _____

Why does rebreathing breathed air increase respiratory rate? _____

14. What was the effect of running in place (exercise) on the duration of breath holding? _____

Explain: _____

15. Record your data for the test illustrating the effect of respiration on circulation:

Radial pulse before beginning test _____/min Radial pulse after testing _____/min

Relative radial pulse force before beginning test _____ Relative radial pulse force after testing _____

Condition of neck and facial veins after testing _____

Explain: _____


16. Do the following factors generally increase (indicate with I) or decrease (indicate with D) the respiratory rate and depth?


1. increase in blood CO_2 _____ 3. increase in blood pH _____

2. decrease in blood O_2 _____ 4. decrease in blood pH _____

Did it appear that CO_2 or O_2 had a greater effect on modifying the respiratory rate? _____

17. Where are sensory receptors sensitive to changes in O_2 levels in the blood located? _____

18.  Atelectasis is a collapsed lung. Explain how a pneumothorax might result in atelectasis and what should be done to restore the negative pressure of the pleural cavity. _____

19.  Pectus excavatum is a condition in which the anterior thoracic cage is caved inward because of abnormal development of the sternum and ribs. What effect would you expect this condition to have on vital capacity, and why?

Functional Anatomy of the Digestive System

Materials

Digestive System Anatomy

- Dissectible torso model
- Anatomical chart of the human digestive system
- Model of a villus (if available)
- Jaw model or human skull
- Demonstration area: Prepared microscope slides for student viewing under low power:

Station 1: cross section of the duodenum (small intestine)

Station 2: mixed salivary gland

Station 3: liver

Chemical and Physical Processes of Digestion

Enzyme Action Supply Area

- Test tubes and test tube rack
- Graduated cylinder
- Wax markers
- Hot plates
- 250-ml beakers
- Boiling chips (or beads)
- Water bath set at 37°C (if not available, incubate at room temperature and double the time)
- Ice water bath
- Chart on chalkboard for recording class results
- Dropper bottle of 1% trypsin
- Dropper bottle of 0.01% BAPNA solution
- Dropper bottle of vegetable oil
- Bile salts (sodium taurocholate)
- Parafilm (small squares to cover the test tubes)

Physical Processes Supply Area

- Water pitcher
- Paper cups
- Stethoscope
- Alcohol swabs
- Disposable autoclave bag

Learning Outcomes

- Describe the general histologic structure of the wall of the alimentary canal.
- Identify on a model or appropriate diagram the organs that make up the alimentary canal, and indicate the digestive role of each organ.
- Describe structural specializations of the small intestine that contribute to its digestive role(s).
- Name and indicate the function of each accessory digestive organ.
- Name human deciduous and permanent teeth, and describe the basic anatomy of a tooth.
- List and indicate the specific function of the major enzymes or enzyme groups produced by the salivary glands, stomach, small intestine, and pancreas. Summarize conditions promoting their optimal functioning.
- Perform an appropriate chemical test to determine whether protein digestion has occurred.
- Describe the function(s) of bile in the digestive process.
- Identify the alimentary canal organs involved in the physical processes of digestion.
- Compare and contrast segmentation and peristalsis as mechanisms of propulsion.

The **digestive system** provides the body with the nutrients essential for health. The organs of this system ingest, digest, and absorb food and eliminate the undigested remains as feces.

The digestive system consists of a hollow tube extending from the mouth to the anus, into which a number of accessory organs empty their secretions (**Figure 25.1**). Before ingested food is available to the body cells, it must be broken down into its smaller diffusible molecules—a process called **digestion**. The digested end products can then pass through the epithelial cells lining the tract into the blood to be distributed to the body cells—a process termed **absorption**.

The organs of the digestive system are separated into two major groups: the **alimentary canal**, or **gastrointestinal (GI) tract**, and the **accessory digestive organs**. The alimentary canal consists of the mouth, pharynx, esophagus, stomach, small and large intestines, and anus. The accessory structures include the teeth and tongue, which participate in the mechanical breakdown of the food; and the salivary glands, gallbladder, liver, and pancreas, which release their products into the alimentary canal.

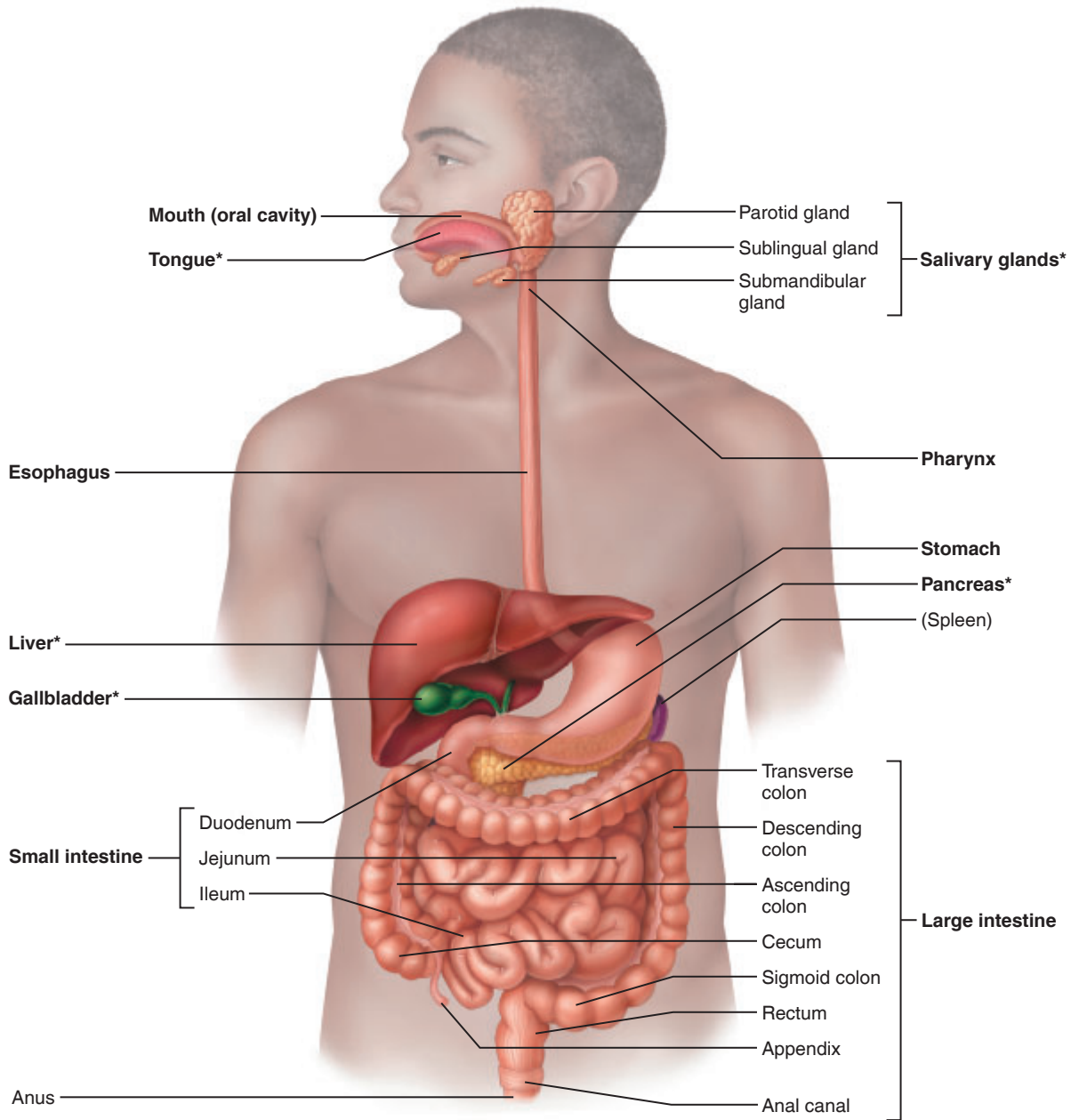


Figure 25.1 Alimentary canal and related accessory digestive organs. Organs labeled with asterisks are accessory organs. Organs without asterisks are alimentary canal organs (except the spleen, an organ of the lymphatic system).

General Histologic Plan of the Alimentary Canal

Because the organs of the alimentary canal share a basic structural plan, it makes sense to review that structure as we begin studying this group of organs. Essentially, the alimentary canal walls have four basic layers, or **tunics**. From the lumen outward, these are the *mucosa*, the *submucosa*, the *muscularis*

externa, and either a *serosa* or *adventitia* (**Figure 25.2**). Each layer has a predominant tissue type and plays a specific role in digestion. **Table 25.1** summarizes the characteristics of the layers of the wall of the alimentary canal.

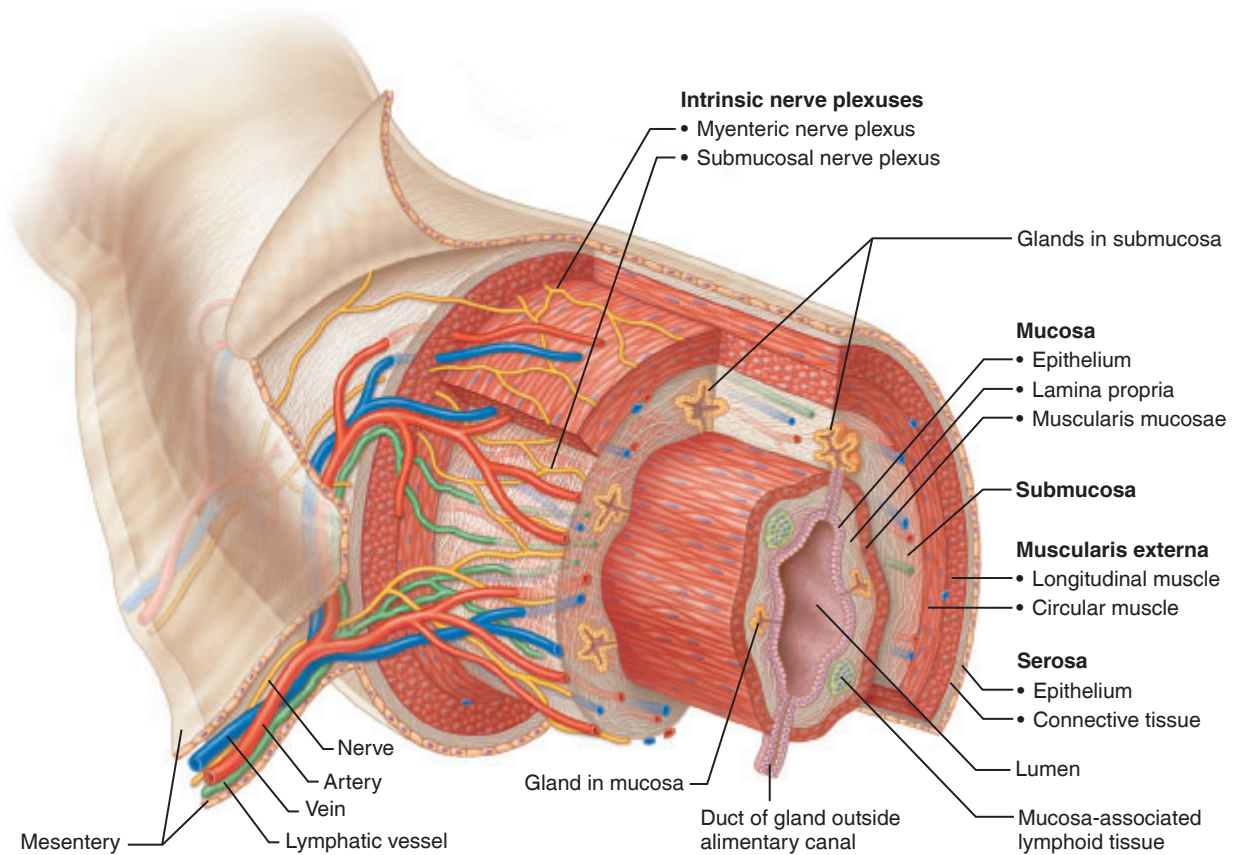


Figure 25.2 Basic structure of the alimentary canal wall. (See also Plate 33 in the Histology Atlas.)

Table 25.1 Alimentary Canal Wall Layers (Figure 25.2)

Layer	Subdivision of the layer	Tissue type	Major functions (generalized for the layer)
Mucosa	Epithelium	Stratified squamous epithelium in the mouth, oropharynx, laryngopharynx, esophagus, and anus; simple columnar epithelium in the remainder of the canal	Secretion of mucus, digestive enzymes, and hormones; absorption of end products into the blood; protection against infectious disease.
	Lamina propria	Areolar connective tissue with blood vessels; many lymphoid follicles, especially as tonsils and mucosa-associated lymphoid tissue (MALT)	
	Muscularis mucosae	A thin layer of smooth muscle	
Submucosa	N/A	Areolar and dense irregular connective tissue containing blood vessels, lymphatic vessels, and nerve fibers (submucosal nerve plexus)	Blood vessels absorb and transport nutrients. Elastic fibers help maintain the shape of each organ.
Muscularis externa	Circular layer	Inner layer of smooth muscle	Segmentation and peristalsis of digested food along the tract are regulated by the myenteric nerve plexus.
	Longitudinal layer	Outer layer of smooth muscle	
Serosa* (visceral peritoneum)	Connective tissue Epithelium (mesothelium)	Areolar connective tissue Simple squamous epithelium	Reduces friction as the digestive system organs slide across one another.

*Since the esophagus is outside the peritoneal cavity, the serosa is replaced by an adventitia made of areolar connective tissue that binds the esophagus to surrounding tissues.

Activity 1

Observing the Histological Structure of the Alimentary Canal Wall

Go to the demonstration area where a cross section of the duodenum (part of the small intestine) is secured to the microscope stage. Observe the tissue to identify the four basic tunics of the intestinal wall—that is, the **mucosa** (and its three sublayers), the **submucosa** (connective tissue layer deep to the mucosa), the **muscularis externa** (composed of circular and longitudinal smooth muscle layers), and the **serosa** (the outermost layer). Examine the large

leaflike **villi**, which increase the surface area for absorption. (Consult Figure 25.2 and Table 25.1, as well as Plate 33 in the Histology Atlas as you work.)

What type of epithelium do you see here? _____

Organs of the Alimentary Canal

Activity 2

Identifying Alimentary Canal Organs

The pathway that food takes as it passes through the alimentary canal organs is described in the next sections. Identify each structure in Figure 25.1 and on the torso model as you work.

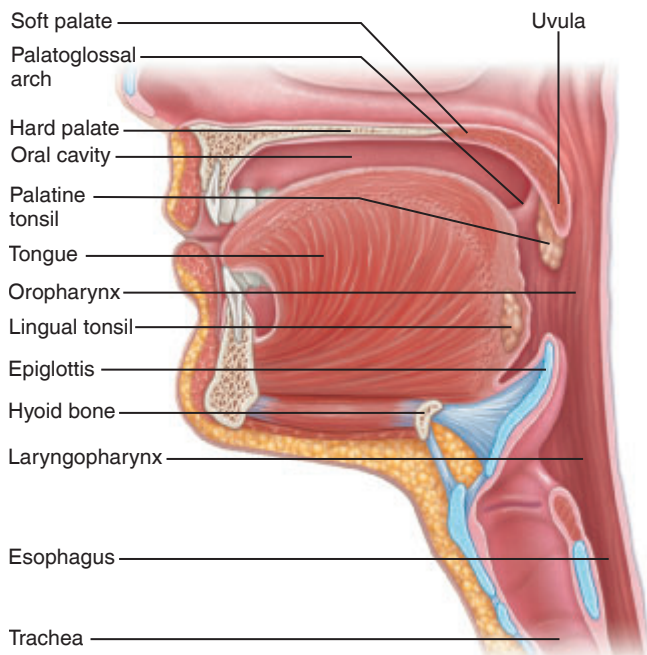
Mouth, or Oral Cavity

Food enters the digestive tract through the **mouth**, or **oral cavity** (Figure 25.3). Within this mucous membrane-lined cavity are the gums, teeth, tongue, and openings of the ducts of the salivary glands. The **lips (labia)** protect the anterior opening, the **oral orifice**. The **cheeks** form the mouth's lateral walls, and the **palate**, its roof. The anterior part of the palate is

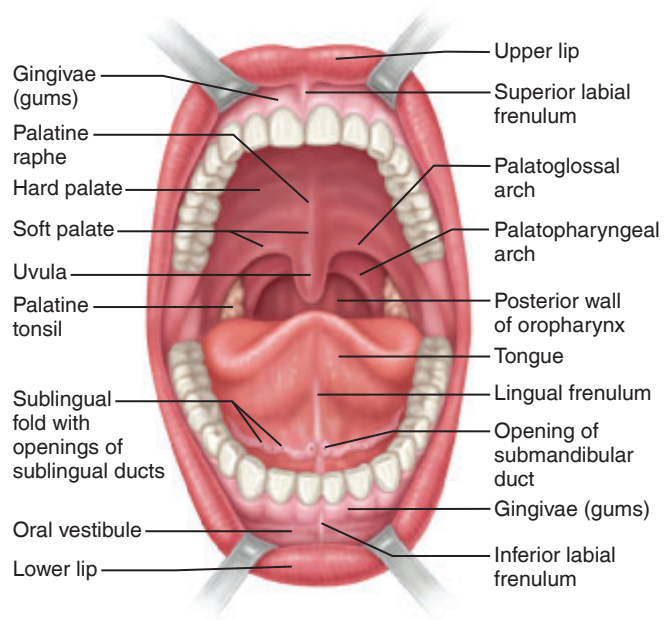
called the **hard palate** because bone underlies it. The posterior **soft palate** is unsupported by bone. The **uvula**, a fingerlike projection of the soft palate, extends inferiorly from its posterior edge. The muscular **tongue** occupies the floor of the oral cavity. A membrane, the **lingual frenulum**, secures the tongue to the floor of the mouth (Figure 25.3b). The space between the lips and cheeks and the teeth is the **oral vestibule**; the area that lies within the teeth and gums is the **oral cavity** proper.

On each side of the mouth at its posterior end are masses of lymphoid tissue, the **palatine tonsils** (Figure 25.3). The **lingual tonsil** covers the base of the tongue, posterior to the oral cavity proper. The tonsils, along with other lymphoid tissues, are part of the body's defense system. (For histology of the palatine tonsils, see Plate 25 in the Histology Atlas.)

Three pairs of **salivary glands** secrete saliva into the oral cavity. One component of saliva, salivary amylase, begins the digestion of starchy foods in the mouth. (The salivary glands are discussed in more detail on page 319.)



(a) Sagittal section of the oral cavity and pharynx



(b) Anterior view

Figure 25.3 Anatomy of the oral cavity (mouth).

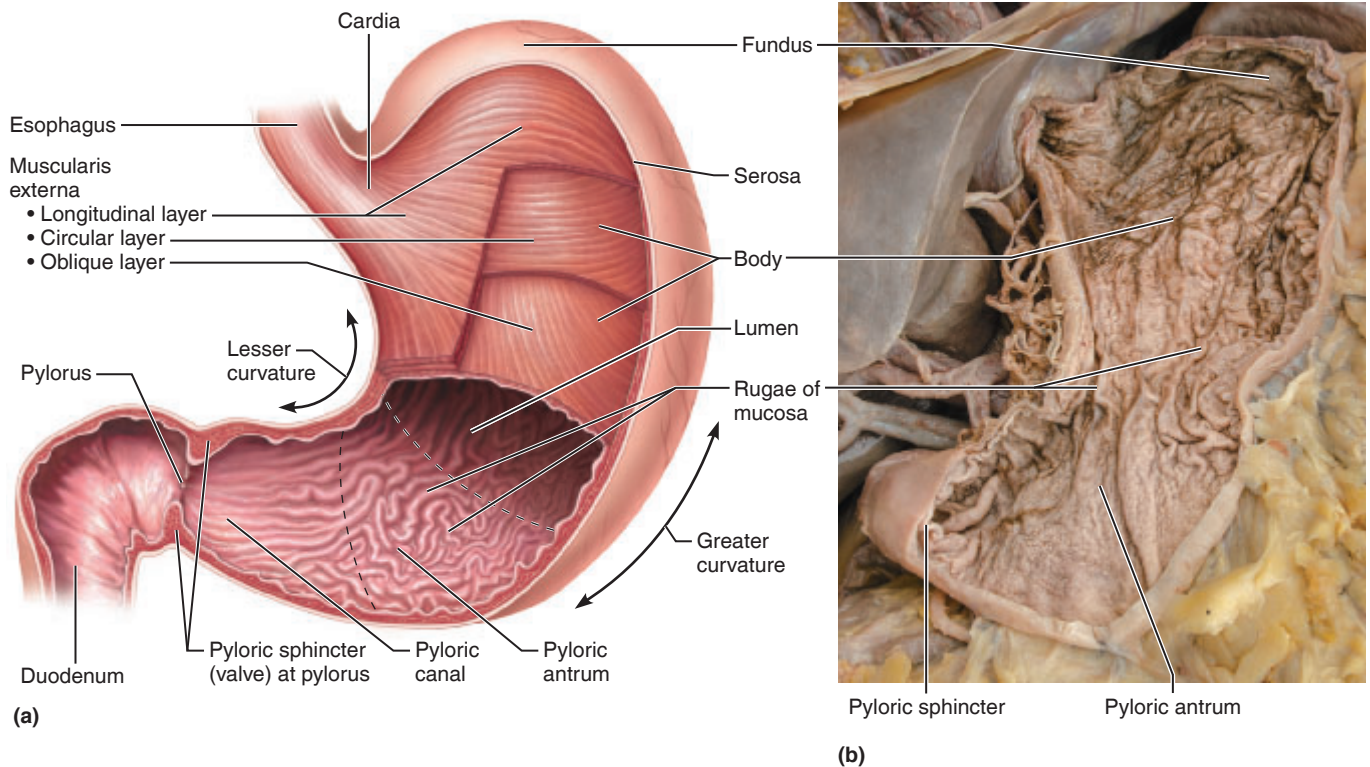


Figure 25.4 Anatomy of the stomach. (a) Gross anatomy of the stomach (frontal section). (b) Photograph of internal aspect of stomach.

As food enters the mouth, it is mixed with saliva and masticated (chewed). The cheeks and lips help hold the food between the teeth during mastication. The mobile tongue mixes the food with saliva during chewing and initiates swallowing. Thus the mechanical and chemical breakdown of food begins before the food has left the mouth.

Pharynx

From the mouth, food passes posteriorly into the pharynx, a common passageway for food, fluid, and air (Figure 25.3). The pharynx has three parts—the **nasopharynx** (behind the nasal cavity), the **oropharynx** (extends from the soft palate to the epiglottis), and the **laryngopharynx** (behind the larynx extending from the epiglottis to the base of the larynx), which is continuous with the esophagus.

The walls of the pharynx contain two layers of skeletal muscle: an inner longitudinal layer and an outer layer of

circular constrictor muscles. These muscles initiate wavelike contractions that propel the food inferiorly into the esophagus.

Esophagus

The **esophagus** extends from the laryngopharynx through the diaphragm to the stomach. It is approximately 10 inches long in humans and is basically a food passageway that conducts food to the stomach by *peristalsis*. At its superior end, its walls contain skeletal muscle; this is replaced by smooth muscle in the area nearing the stomach. The **gastroesophageal sphincter**, a thickening of the smooth muscle layer at the esophagus-stomach junction, controls food passage into the stomach.

Stomach

The **stomach** (Figure 25.1 and **Figure 25.4**) is primarily located in the upper left quadrant of the abdominopelvic cavity and is nearly hidden by the liver and diaphragm.

Table 25.2 Parts of the Stomach (Figure 25.4)

Structure	Description
Cardia (cardial part)	The area surrounding the cardiac orifice through which food enters the stomach
Fundus	The dome-shaped area that is located superior and lateral to the cardia
Body	Midportion of the stomach and largest region
Pyloric part:	Funnel-shaped pouch that forms the distal stomach
Pyloric antrum	Wide superior portion of the pyloric part
Pyloric canal	Narrow tubelike portion of the pyloric part
Pylorus	Distal end of the pyloric part that is continuous with the small intestine
Pyloric sphincter	Valve that controls the emptying of the stomach into the small intestine

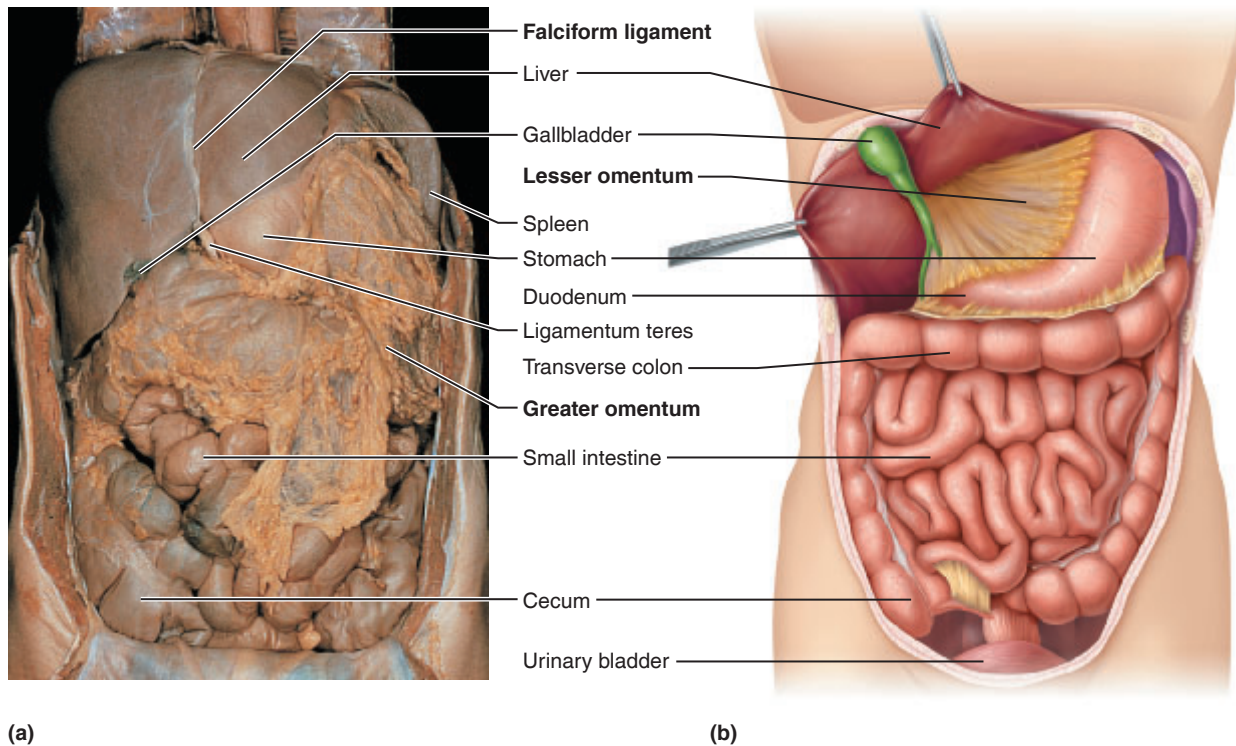


Figure 25.5 Peritoneal attachments of the abdominal organs. (a) Anterior view; the greater omentum is shown in its normal position covering the abdominal viscera. (b) Anterior diagram showing greater omentum removed and liver and gallbladder reflected superiorly.

The stomach is made up of several regions, summarized in **Table 25.2**. *Mesentery* is the general term that refers to a double layer of peritoneum—a sheet of two serous membranes fused together—that extends from the digestive organs to the body wall. There are two mesenteries, the greater omentum and the lesser omentum, that connect to the stomach.

The **lesser omentum** extends from the liver to the lesser curvature of the stomach. The **greater omentum** extends from the greater curvature of the stomach, drapes downward over the abdominal contents to cover them in an apronlike fashion, and then attaches to the posterior body wall. **Figure 25.5** illustrates the omenta as well as the other peritoneal attachments of the abdominal organs.

The stomach is a temporary storage region for food as well as a site for food breakdown. It contains a third *obliquely* oriented layer of smooth muscle in its muscularis externa that allows it to churn, mix, and pummel the food, physically breaking it down to smaller fragments. *Gastric glands* of the mucosa secrete hydrochloric acid and hydrolytic enzymes. The hydrochloric acid in the stomach serves two functions: it creates an environment that is hostile to foreign organisms, and it activates the digestive enzymes that are initially secreted into the stomach in an inactive form. The *mucosal glands* also secrete a thick mucus that protects the stomach from being digested by its protein-digesting enzymes. Food processed in the stomach resembles a creamy mass (chyme). The chyme enters the small intestine through the pyloric sphincter. (For histology of the stomach, see Plates 31 and 32 in the Histology Atlas.)

Small Intestine

The **small intestine** is a convoluted tube that extends from the pyloric sphincter to the **ileocecal valve (sphincter)**. The

small intestine is suspended by the fan-shaped **mesentery** from the posterior abdominal wall (see Figure 25.5), and it lies, framed on both sides and superiorly by the large intestine, in the abdominal cavity. The small intestine has three regions (see Figure 25.1).

1. The **duodenum** extends from the pyloric sphincter for about 10 inches and curves around the head of the pancreas.
2. The **jejunum**, continuous with the duodenum, extends for about 8 feet.
3. The **ileum**, the terminal portion of the small intestine, is about 12 feet long and joins the large intestine at the ileocecal valve (see Figure 25.7).

In the small intestine, enzymes from two sources complete the digestive process: **brush border enzymes**, enzymes bound to the microvilli of the columnar epithelial cells; and, more important, enzymes produced by the pancreas and ducted into the duodenum via the **pancreatic duct**. Bile (formed in the liver) also enters the duodenum via the **bile duct** in the same area. At the duodenum, the ducts join to form the bulb-like **hepatopancreatic ampulla** and empty their products into the duodenal lumen through an opening called the **major duodenal papilla**, an orifice controlled by a smooth muscle valve called the **hepatopancreatic sphincter**.

Nearly all food absorption occurs in the small intestine, where three structural modifications that increase the absorptive area appear—microvilli, villi, and circular folds (**Figure 25.6**).

- **Microvilli:** Microscopic projections of the surface plasma membrane of the columnar epithelial cells of the mucosa.
- **Villi:** Fingerlike projections of the mucosa that give it a velvety appearance and texture. In the core of each villus is

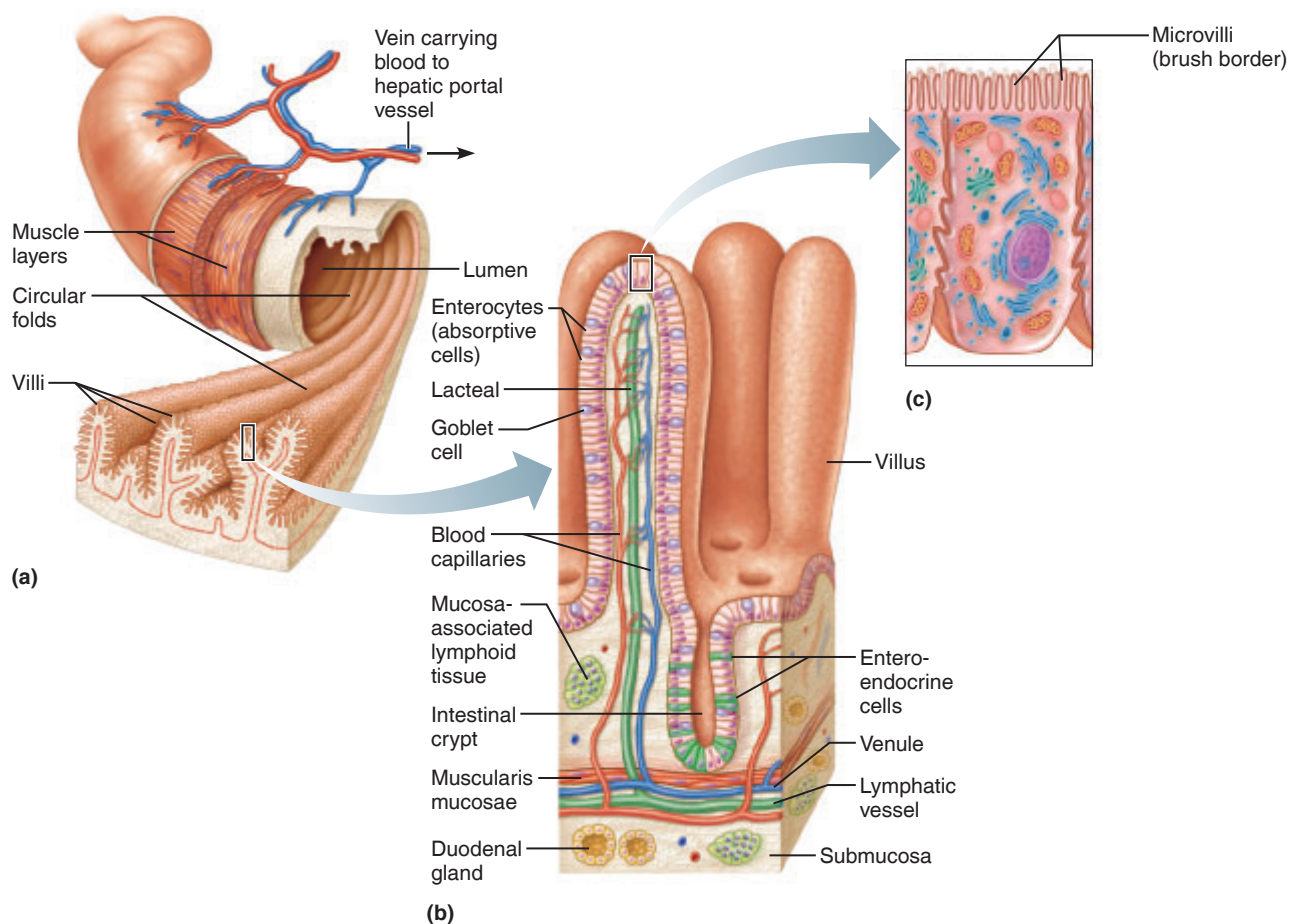


Figure 25.6 Structural modifications of the small intestine. (a) Several circular folds seen on the inner surface of the small intestine. (b) Enlargement of one villus extension of the circular fold. (c) Enlargement of the enterocytes to show microvilli.

a dense capillary bed and a wide lymphatic capillary called a **lacteal**. Digested foodstuffs are absorbed through the epithelial cells into both the capillary blood and the lacteal.

- **Circular folds:** Deep folds of the mucosal and submucosal layers that force chyme to spiral through the intestine, mixing it and slowing its progress to allow time for digestion and absorption. Any residue remaining undigested at the end of the small intestine enters the large intestine through the ileocecal valve. Local collections of lymphoid nodules found in the submucosa called **Peyer's patches** increase along the length of the small intestine. (See Plate 35 in the Histology Atlas.)

Activity 3

Examining the Villus Model

If a villus model is available, identify the following cells or regions before continuing: epithelium, goblet cells, lamina propria, slips of the muscularis mucosae, capillary bed, and lacteal.

Large Intestine

The **large intestine** (Figure 25.7) is about 1.5 m (5 feet) long and extends from the ileocecal valve to the anus. It consists of the following subdivisions: the **cecum**, **appendix**, **colon**, **rectum**, and **anal canal**.

The colon has several regions. The **ascending colon** travels up the right side of the abdominal cavity and makes a right-angle turn at the **right colic (hepatic) flexure** to cross the abdominal cavity as the **transverse colon**. It then turns at the **left colic (splenic) flexure** and continues downward as the **descending colon**, where it becomes the S-shaped **sigmoid colon**. The sigmoid colon, rectum, and the anal canal lie in the pelvis and thus are not considered abdominal cavity structures.

The anal canal terminates in the **anus**, the opening to the body exterior. The anus has an external sphincter of skeletal muscle (the voluntary sphincter) and an internal sphincter of smooth muscle (the involuntary sphincter). These sphincters are normally closed except during defecation, when feces are eliminated from the body.

In the large intestine, the longitudinal muscle layer of the muscularis externa is reduced to three muscle bands. These bands are shorter than the rest of the wall of the large intestine, so they cause the wall to pucker into small pocketlike sacks called **haustra**.

The major function of the large intestine is to compact and propel the fecal matter toward the anus and to eliminate it from the body. While it does this task, it (1) provides a site for intestinal bacteria to manufacture vitamins B and K, which it then absorbs into the bloodstream; and (2) reclaims most of the remaining water (and some of the electrolytes) from undigested food, thus conserving body water.

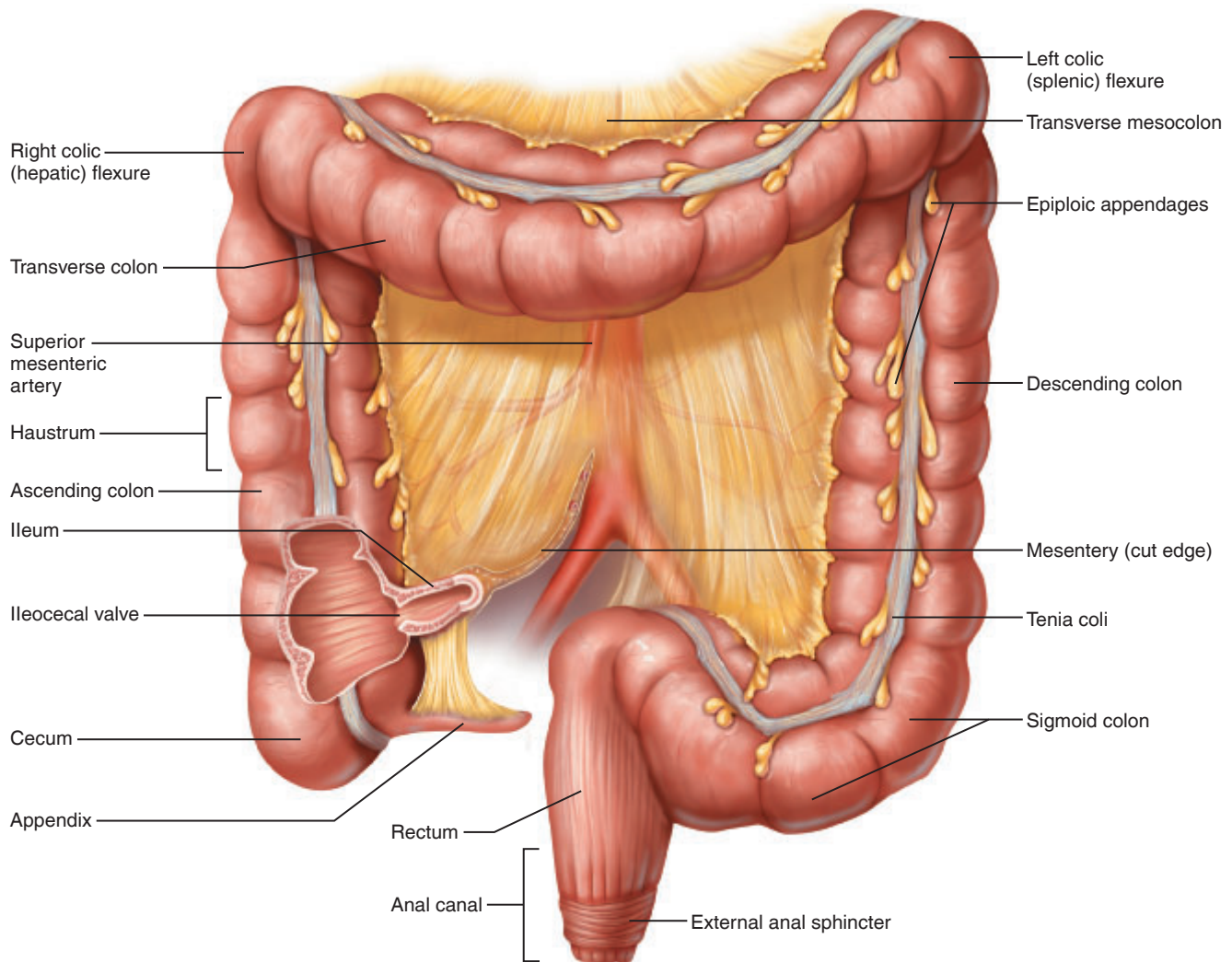


Figure 25.7 The large intestine. A section of the cecum is removed to show the ileocecal valve.

Accessory Digestive Organs

Teeth

Usually by the early 20s, two sets of teeth have developed (**Figure 25.8**). The initial set, the **deciduous** (or **milk**) **teeth**, appears between the ages of 6 months and 2½ years. The child begins to shed the deciduous teeth around the age of 6, and a second set of teeth, the **permanent teeth**, gradually replaces them.

Teeth are classified as **incisors**, **canines** (eye teeth, cuspids), **premolars** (bicuspid), and **molars**. Teeth names reflect differences in relative structure and function. The chisel-shaped incisors are used in biting. Canines are fang-like, used for tearing or piercing food. The premolars and molars have broad crowns with rounded cusps (grinding surfaces) specialized for the grinding of food.

Dentition is described by means of a **dental formula**, which specifies the numbers, types, and position of the teeth in one side of the jaw. Because tooth arrangement is bilaterally symmetrical, it is necessary to indicate only one side of the jaw. The complete dental formula for the deciduous teeth from the medial to posterior aspect of each jaw is as follows:

Upper teeth: 2 incisors, 1 canine, 0 premolars, 2 molars
Lower teeth: 2 incisors, 1 canine, 0 premolars, 2 molars $\times 2$

This formula is generally shortened to read as follows:

$$\frac{2,1,0,2}{2,1,0,2} \times 2 \text{ (20 deciduous teeth)}$$

The 32 permanent teeth are then described by the following dental formula:

$$\frac{2,1,2,3}{2,1,2,3} \times 2 \text{ (32 permanent teeth)}$$

Although 32 is the usual number of permanent teeth, not everyone develops a full set. In many people, the third molars, commonly called *wisdom teeth*, never erupt.

Activity 4

Identifying Types of Teeth

Identify the four types of teeth (incisors, canines, premolars, and molars) on the jaw model or human skull.

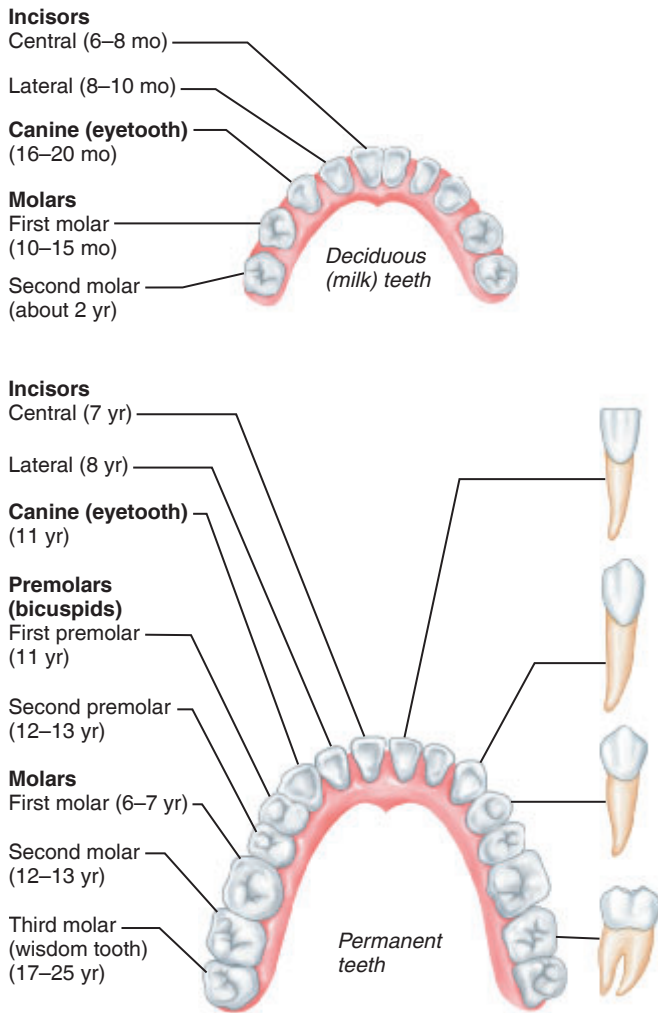


Figure 25.8 Human dentition. (Approximate time of teeth eruption shown in parentheses.)

A tooth consists of two major regions, the **crown** and the **root**. These two regions meet at the **neck** near the gum line. A longitudinal section made through a tooth shows the following basic anatomy (**Figure 25.9**). The enamel-covered crown is the superior portion of the tooth visible above the **gum**, or **gingiva**, which surrounds the tooth. Enamel is the hardest substance in the body and is fairly brittle because it is heavily mineralized with calcium salts.

That part of the tooth embedded in the bone is the root. The outermost surface of the root is covered by **cement**, which is similar to bone in composition. The cement attaches the tooth to the **periodontal ligament**, which holds the tooth in the bony socket. **Dentin**, which comprises the bulk of the tooth, is the bonelike material deep to the enamel and cement.

Dentin surrounds the **pulp cavity**, which is filled with pulp. **Pulp** is comprised of connective tissue liberally supplied with blood vessels, nerves, and lymphatics that provide for tooth sensation and supply nutrients to the tooth tissues. Where the pulp cavity extends into the root, it becomes the **root canal**.

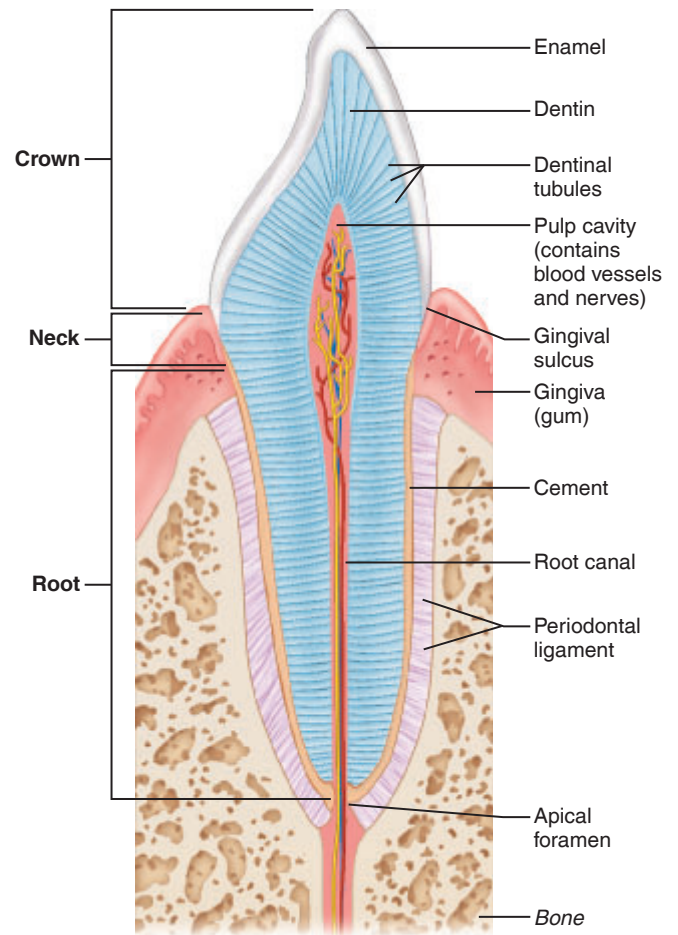


Figure 25.9 Longitudinal section of a canine tooth.

Activity 5

Studying Internal Tooth Anatomy

If the jaw model provided has a removable tooth that is sectioned longitudinally, identify as many of the structures detailed in Figure 25.9 as possible.

Salivary Glands

Three pairs of major **salivary glands** (see Figure 25.1) empty their secretions into the oral cavity.

Parotid glands: Large glands located anterior to the ear and ducting via the parotid duct into the mouth over the second upper molar.

Submandibular glands: Located along the medial aspect of the mandible in the floor of the mouth, and ducting under the tongue close to the lingual frenulum.

Sublingual glands: Small glands located most anteriorly in the floor of the mouth and emptying under the tongue via several small ducts.

Saliva is a mixture of mucus, which moistens the food and helps to bind it together into a mass called a **bolus**, and a clear serous fluid containing the enzyme *salivary amylase*. Salivary amylase begins the digestion of starch.

Activity 6

Locating the Salivary Glands

Identify on an anatomical chart or torso model each of the salivary glands discussed above. Also, attempt to follow their ducts to where they empty into the oral cavity.

Activity 7

Examining the Histology of Salivary Gland Tissue

Go to station 2 at the demonstration area, and examine salivary gland tissue under low power to become familiar with the appearance of a glandular tissue. Notice the clustered arrangement of the cells around their ducts. The cells are basically triangular, with their pointed ends facing the duct lumen. If possible, differentiate between mucus-producing cells, which look hollow or have a clear cytoplasm, and serous cells, which produce the clear, enzyme-containing fluid and have granules in their cytoplasm. The serous cells often form *demilunes* (caps) around the more central mucous cells. (The photomicrograph in Plate 37 in the Histology Atlas may be helpful in this task.)

Liver and Gallbladder

The **liver** (see Figure 25.1), the largest gland in the body, is located inferior to the diaphragm, more to the right side of the body. The human liver has four lobes and is suspended from the diaphragm and anterior abdominal wall by the **falciform ligament** (see Figure 25.5a).

The liver's digestive function is to produce bile, which leaves the liver through the **common hepatic duct** and then enters the duodenum via the **bile duct**. Bile has no enzymes, but it is important to fat digestion because it acts as an emulsifier, breaking up fat globules into small droplets. This creates a larger surface area for fat-digesting enzymes (lipases) to work on. Without bile, little fat digestion or absorption occurs.

When digestive activity is not occurring, bile backs up in the **cystic duct** and enters the **gallbladder**, a small green sac on the inferior surface of the liver. Bile produced by the **hepatocytes** (liver cells) is stored there until needed for the digestive process. While there, bile is concentrated by the removal of water and some ions.

The liver is very important in the initial processing of the nutrient-rich blood draining the digestive organs. Special

phagocytic cells, **stellate macrophages**, remove debris such as bacteria from the blood as it flows past, while the hepatocytes pick up oxygen and nutrients. Much of the glucose transported to the liver from the GI tract is stored as glycogen in the liver for later use, and amino acids taken from the blood by the liver cells are used to make plasma proteins. The processed blood ultimately drains from the liver via the *hepatic veins*.

Pancreas

The **pancreas** is a soft, triangular gland that extends across the posterior abdominal wall from the spleen to the duodenum (see Figure 25.1). Like the duodenum, the pancreas is a retroperitoneal organ. It has both an endocrine function, producing the hormones insulin and glucagon, and an exocrine function. (See Plate 38 in the Histology Atlas.) Its exocrine secretion includes many hydrolytic enzymes, which it secretes into the duodenum via the main pancreatic duct. Pancreatic juice is very alkaline. Its high concentration of bicarbonate ion (HCO_3^-) neutralizes the acidic chyme entering the duodenum from the stomach, enabling the pancreatic and intestinal enzymes to operate at their optimal pH, which is slightly alkaline.

Activity 8

Locating the Liver, Pancreas, and Associated Structures

Identify the liver, gallbladder, and the common hepatic, bile, and cystic ducts on the anatomical chart or torso model before continuing. Notice the relationship of the liver to the diaphragm and stomach. Also identify the pancreas, pancreatic duct, and if possible, the hepatopancreatic ampulla and duodenal papilla.

Activity 9

Examining the Histology of the Liver

Go to station 3 at the demonstration area, and examine a slide of liver tissue. Identify as many of the structural features illustrated in the photomicrograph (Plate 39 in the Histology Atlas) as you can. Notice the central vein and how the hepatocytes form cords that radiate from the vein. If possible, identify a **portal triad**—a region containing a branch of the hepatic artery, a branch of the hepatic portal vein, and a bile duct. The liver units, called lobules, have six sides, and a portal triad is found at each corner.

Chemical Digestion of Foodstuffs: Enzymatic Action

Figure 25.10 depicts the progressive digestion and absorption of proteins, fats, and carbohydrates. It indicates the enzymes involved, their site of formation, and their site of action. Acquaint yourself with the flowchart before beginning this experiment, and refer to it as necessary during the laboratory session.

Enzymes are large protein molecules produced by body cells that act as biologic *catalysts*. The digestive enzymes are hydrolytic enzymes, or *hydrolases*. Their **substrates**, or the molecules on which they act, are organic food molecules that they break down by adding water to the molecular bonds, thus breaking the bonds between the building blocks, or monomers.

The hydrolytic enzymes are very specific in their action. Each enzyme hydrolyzes only one or a small group of substrate molecules, and certain environmental conditions are necessary for it to function optimally. Because digestive enzymes and bile actually function *outside* the body cells while in the digestive tract, their activity can also be studied in a test tube.

In this laboratory session we will examine factors that influence trypsin's digestion of proteins and explore the role of bile made by the liver.

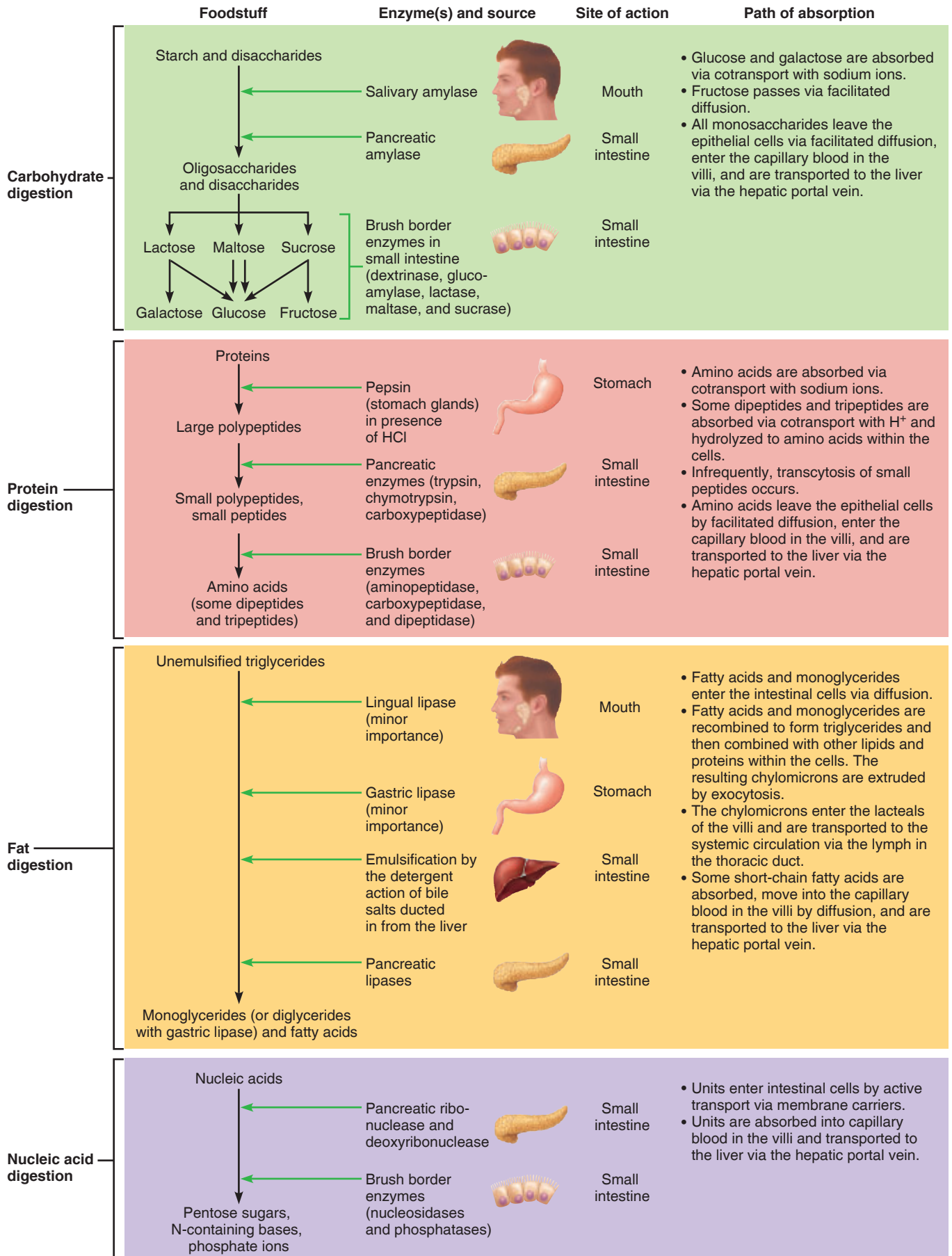


Figure 25.10 Flowchart of digestion and absorption of foodstuffs.

Protein Digestion by Trypsin

Trypsin, an enzyme produced by the pancreas, hydrolyzes proteins to small fragments. BAPNA is a synthetic substrate consisting of a dye covalently bound to an amino acid. Trypsin hydrolysis of BAPNA cleaves the dye molecule from the amino acid, causing the solution to change from colorless to

bright yellow. The covalent bond between the dye molecule and the amino acid is the same as the peptide bonds that link amino acids together, so the appearance of a yellow color indicates the activity of an enzyme that is capable of cleaving peptide bonds and is direct evidence of hydrolysis by trypsin.

Activity 10

Assessing Protein Digestion by Trypsin

Work in groups of three or four, with each person in the group taking responsibility for setting up some of the experimental samples.

1. From supply area 1, obtain five test tubes, a test tube rack, a dropper bottle of trypsin and one of BAPNA, a graduated cylinder, a wax pencil, a 250-ml beaker, boiling chips (or boiling beads), and a hot plate and bring them to your bench.

2. One student should prepare the controls (tubes 1T and 2T), and two should prepare the experimental samples (tubes 3T to 5T).

- Mark each tube with a wax pencil, and load the tubes as indicated in **Figure 25.11**, using 3 drops of each indicated substance.

1T—trypsin and water

2T—BAPNA and water

3T, 4T, and 5T—trypsin and BAPNA

- For experimental sample 3T, which is to be boiled before incubation, place a few boiling chips in the 250-ml beaker, add about 125 ml of water (or enough to cover

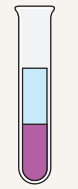
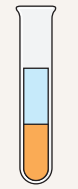
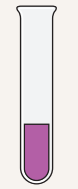
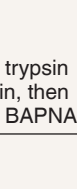

the sample-containing part of the test tube), and bring the water to a boil on the hot plate. Place the specimen in the boiling water for 4 minutes.

- Place all tubes in a rack in the appropriate water bath for approximately 1 hour. Shake the rack occasionally to keep the contents well mixed.

3. Assess your results. The presence of a yellow color indicates a **positive hydrolysis test**. If the sample mixture remains clear, no detectable hydrolysis has occurred.

Record the color of the experimental tube in Figure 25.11.

Upon completing the experiments, each group should communicate its results to the rest of the class by recording them in a chart on the board. All members of the class should observe the **controls** as well as the positive and negative results of all experimental samples. Controls are specimens or standards against which experimental samples are compared. Additionally, all members of the class should be able to explain the tests used and the results anticipated and observed for each experiment.

Activity 10: Trypsin Digestion of Protein						
Tube no.	1T	2T	3T	4T	5T	
Additives (3 drops ea)	 trypsin, water	 BAPNA, water	 trypsin	 boiled trypsin, BAPNA	 trypsin, BAPNA	
Incubation condition	37°C	37°C	37°C	37°C	0°C	
Color change						
Result: (+) or (-)						

Additive key:




 = Trypsin  = BAPNA  = Water

Figure 25.11 Summary table for trypsin digestion of protein.

The Action of Bile on Fats

The treatment that fats and oils go through during digestion in the small intestine is more complicated than that of carbohydrates or proteins—pretreatment with bile to physically emulsify the fats is required. Hence, two sets of reactions occur.

First: Fats/oils $\xrightarrow[\text{(emulsification)}]{\text{Bile}}$ minute fat/oil droplets

Then: Fat/oil droplets $\xrightarrow[\text{(digestion)}]{\text{Lipase}}$ monoglycerides and fatty acids

In this activity we will be investigating the emulsifying activity of bile.

Activity 11

Demonstrating the Action of Bile on Fats

1. From supply area 1, obtain two test tubes and a test tube rack, plus one dropper bottle of vegetable oil, bile salts, a wax marker, and two squares of Parafilm®.

2. Although *bile*, a secretory product of the liver, is not an enzyme, it emulsifies fats, providing a larger surface area for enzymatic activity. To demonstrate the action of bile on fats, mark one of the test tubes as #1 and the other as #2 with a wax marker, and prepare them as follows:

- To tube 1, add 20 drops of water and 4 drops of vegetable oil.
- To tube 2, add 20 drops of water, 4 drops of vegetable oil, and a pinch of bile salts.
- Cover each tube with a small square of Parafilm, shake vigorously, and allow the tubes to stand at room temperature.

After 10–15 minutes, observe both tubes. If emulsification has not occurred, the oil will be floating on the surface of the water. If emulsification has occurred, the fat droplets will be suspended throughout the water.

In which tube has emulsification occurred?

Physical Processes: Mechanisms of Food Propulsion and Mixing

Although enzyme activity is very important in the overall digestion process, foods must also be broken down (through chewing and churning) and moved by mechanical means along the tract if digestion and absorption are to be completed. Both skeletal and smooth muscles are involved in digestion. This fact is demonstrated by the simple activities that follow.

Activity 12

Observing Movements and Sounds of Digestion

1. From supply area 2, obtain a pitcher of water, a stethoscope, a paper cup, an alcohol swab, and an autoclave bag to prepare for the following observations.

2. While swallowing a mouthful of water, consciously notice the movement of your tongue. Record your observations.

3. Repeat the swallowing process while your laboratory partner watches movements of your larynx that are visible externally. (This movement is more obvious in males, who have larger thyroid cartilages.) Record your observations.

Deglutition (Swallowing)

Deglutition, or **swallowing**, is largely the result of skeletal muscle activity and occurs in two phases: *buccal* (mouth) and *pharyngeal-esophageal*. The initial phase—the buccal—is voluntarily controlled and initiated by the tongue. Once begun, the process continues involuntarily in the pharynx and esophagus, through peristalsis, resulting in the delivery of the swallowed contents to the stomach.

What do these movements accomplish? _____

4. Before donning the stethoscope, your lab partner should clean the earpieces with an alcohol swab. Then, he or she should place the diaphragm of the stethoscope over your abdominal wall, approximately 1 inch below the xiphoid process and slightly to the left, to listen for sounds as you again take two or three swallows of water. There should be two audible sounds—one when the water splashes against the gastroesophageal (cardiac) sphincter, and the second when the peristaltic wave of the esophagus arrives at the sphincter and the sphincter opens, allowing water to gurgle into the stomach. Determine, as accurately as possible, the time interval between these two sounds, and record it on the next page.

Text continues on next page. →

Interval between arrival of water at the sphincter and the opening of the sphincter:

_____ sec

This interval gives a fair indication of the time it takes for the peristaltic wave to travel down the 10-inch-long

esophagus. (Actually, the time interval is slightly less than it seems, because pressure causes the sphincter to relax before the peristaltic wave reaches it.)



Dispose of the used paper cup in the autoclave bag.

Segmentation and Peristalsis

Although several types of movements occur in the alimentary canal, segmentation and peristalsis are most important as mixing and propulsive mechanisms.

Segmental movements are local constrictions of the organ wall that occur rhythmically. They serve mainly to mix the foodstuffs with digestive juices. However, segmentation is also important in propelling food through the small intestine.

Peristaltic movements are the major means of propelling food through most of the digestive viscera. Essentially they are waves of contraction followed by waves of relaxation that squeeze foodstuffs through the alimentary canal. They are superimposed on segmentation.

Activity 13

Viewing Segmental and Peristaltic Movements

If a video showing some of the propulsive movements is available, go to a viewing station to view it before leaving the laboratory.

EXERCISE
25

REVIEW SHEET

Functional Anatomy of the Digestive System

Name _____ Lab Time/Date _____

General Histologic Plan of the Alimentary Canal

1. The basic structural plan of the digestive tube has been presented. Fill in the table below to complete the information listed.

Structure of the Alimentary Canal		
Wall layer	Subdivisions of the layer (if applicable)	Major functions
Mucosa		
Submucosa	(Not applicable)	
Muscularis externa		
Serosa or adventitia	(Not applicable)	

Organs of the Alimentary Canal

2. The tubelike digestive system canal that extends from the mouth to the anus is the _____ canal.
3. How is the muscularis externa of the stomach modified? _____

How does this modification relate to the stomach's function? _____

4. Using the key letters, match the items in column B with the descriptive statements in column A. (Some responses may be used more than once.)

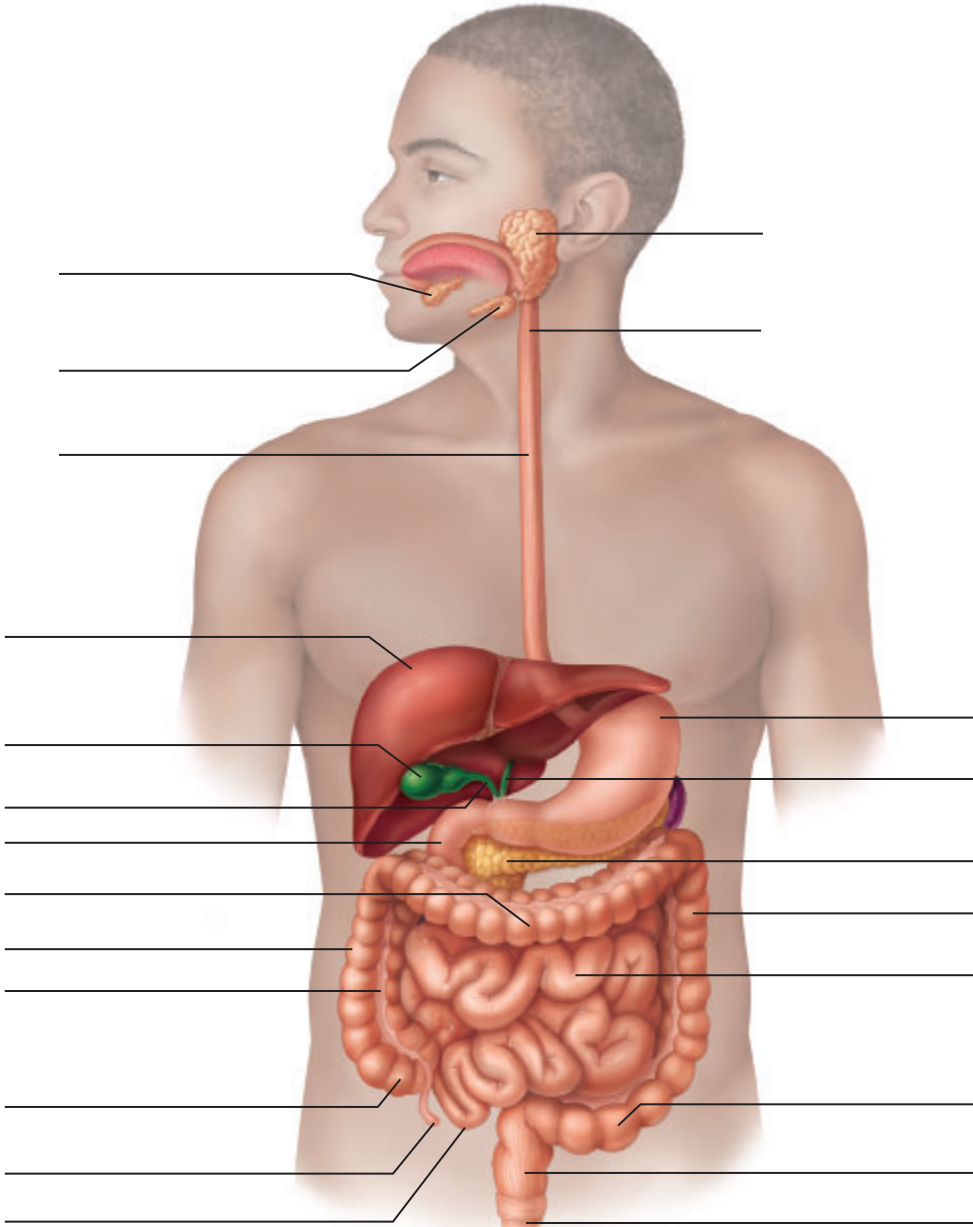
Column A

- _____ 1. structure that suspends the digestive organs to the body wall
- _____, _____, _____ 2. three modifications of the small intestine that increase the surface area for absorption
- _____ 3. large collections of lymphoid tissue found in the submucosa of the small intestine
- _____ 4. deep folds of the mucosa and submucosa that extend completely or partially around the circumference of the small intestine
- _____ 5. initiates protein digestion
- _____ 6. mobile organ that manipulates food in the mouth and initiates swallowing
- _____ 7. passageway that serves the respiratory and digestive systems
- _____ 8. lies posterior to the trachea; moves food from the pharynx to the stomach
- _____ 9. surface projections of a mucosal epithelial cell
- _____ 10. valve at the junction of the small and large intestines
- _____ 11. primary region of nutrient absorption
- _____ 12. membrane securing the tongue to the floor of the mouth
- _____ 13. area between the teeth and lips/cheeks
- _____ 14. pocketlike sacs of the large intestine
- _____ 15. carbohydrate (starch) digestion begins here
- _____ 16. two-layered serous membrane attached to the greater curvature of the stomach
- _____ 17. distal portion of the anal canal
- _____ 18. valve preventing movement of chyme from the duodenum into the stomach
- _____ 19. posterosuperior boundary of the oral cavity
- _____ 20. location of the hepatopancreatic sphincter through which pancreatic secretions and bile pass
- _____ 21. food passageway that has no digestive/absorptive function
- _____ 22. principal site for the synthesis of vitamins B and K by bacteria
- _____ 23. absorbs water and forms feces
- _____ 24. bone-supported part of roof of the mouth

Column B

- a. anus
- b. appendix
- c. circular folds
- d. esophagus
- e. frenulum
- f. greater omentum
- g. hard palate
- h. haustra
- i. ileocecal valve
- j. large intestine
- k. lesser omentum
- l. mesentery
- m. microvilli
- n. oral cavity
- o. oral vestibule
- p. parietal peritoneum
- q. Peyer's patches
- r. pharynx
- s. pyloric sphincter
- t. rugae
- u. small intestine
- v. soft palate
- w. stomach
- x. tongue
- y. villi

5. Correctly identify all structures depicted in the diagram below.



Accessory Digestive Organs

6. Use the key terms to identify each tooth area described below. (Some terms may be used more than once.)

_____ 1. visible portion of the tooth	Key:
_____ 2. material covering the tooth root	cement
_____ 3. hardest substance in the body	crown
_____ 4. attaches the tooth to the tooth socket	dentin
_____ 5. portion of the tooth embedded in bone	enamel
_____ 6. forms the major portion of tooth structure; similar to bone	gingiva
_____ 7. gum that surrounds the tooth	periodontal ligament
_____ 8. site of blood vessels, nerves, and lymphatics	pulp
_____ 9. portion of the tooth covered with enamel	root

7. In humans, the number of deciduous teeth is _____; the number of permanent teeth is _____.

8. The dental formula for permanent teeth is $\frac{2, 1, 2, 3}{2, 1, 2, 3}$.

Explain what this means: _____

9. Which teeth are the "wisdom teeth"? _____

10. Various types of glands form a part of the alimentary tube wall or release their secretions into it by means of ducts. Match the glands listed in column B with the function/locations described in column A.

Column A	Column B
_____ 1. produce(s) mucus; found in the submucosa of the small intestine	duodenal glands
_____ 2. produce(s) a product containing amylase that begins starch breakdown in the mouth	gastric glands
_____ 3. produce(s) a whole spectrum of enzymes and an alkaline fluid that is secreted into the duodenum	liver
_____ 4. produce(s) bile that it secretes into the duodenum via the bile duct	pancreas
_____ 5. produce(s) HCl and pepsinogen	salivary glands

11. What is the role of the gallbladder? _____

Chemical Digestion of Foodstuffs: Enzymatic Action

12. Match the following definitions with the proper choices from the key.

_____	1. increases the rate of a chemical reaction without becoming part of the product	Key: catalyst
_____	2. provides a standard of comparison for test results	control
_____	3. biologic catalyst: protein in nature	enzyme
_____	4. substance on which a catalyst works	substrate

13. The enzymes of the digestive system are classified as hydrolases. What does this mean?

14. Fill in the following chart about the various digestive system enzymes described in this exercise.

Digestive Enzymes				
Enzyme	Organ producing it	Site of action	Substrate(s)	Optimal pH
Salivary amylase				
Trypsin				
Lipase (pancreatic)				

15. Name the end products of digestion for the following macromolecules:

proteins: _____ carbohydrates: _____

fats: _____

16. In the exercise concerning trypsin function, how could you tell protein hydrolysis occurred? _____

Why was tube 1T necessary? _____

Why was tube 2T necessary? _____

Why was 37°C the optimal incubation temperature? _____

Why did very little, if any, digestion occur in test tube 3T? _____

Why did very little, if any, digestion occur in test tube 5T? _____

Trypsin is a protein-digesting enzyme similar to pepsin, the protein-digesting enzyme in the stomach. Would trypsin work well in the stomach? _____ Why or why not? _____

17. In the procedure concerning the action of bile salts, how did the appearance of tubes 1 and 2 differ? _____

Explain the difference. _____

18. Pancreatic and intestinal enzymes operate optimally at a pH that is slightly alkaline, yet the chyme entering the duodenum from the stomach is very acidic. How is the proper pH for the functioning of the pancreatic-intestinal enzymes ensured?


19. Assume you have been chewing a piece of bread for 5 or 6 minutes. How would you expect its taste to change during this interval? _____


Why? _____

Physical Processes: Mechanisms of Food Propulsion and Mixing

20. Match the items in the key to the descriptive statements that follow.

_____ 1. blocks off the nasal cavity during swallowing	Key:
_____ 2. voluntary phase of swallowing	buccal
_____ 3. propulsive waves of smooth muscle contraction	gastroesophageal
_____ 4. sphincter that opens when food or fluids exert pressure on it	peristalsis
_____ 5. movement that mainly serves to mix foodstuffs	pharyngeal-esophageal
_____ 6. forces food into the pharynx	segmentation
_____ 7. involuntary phase of swallowing	tongue
	uvula

21.  Pyloric stenosis is a type of gastric outlet obstruction caused by a narrowing of the pyloric part of the stomach. It is most common in infants. Describe the clinical signs that you would expect to see with this condition.

22.  Individuals with cystic fibrosis are plagued by increased production of mucus. This excess mucus has a variety of effects on the body, including decreased production of pancreatic enzymes and blockage of the pancreatic ducts that secrete enzymes.

Describe how impaired pancreatic enzyme secretion affects digestion. _____

Functional Anatomy of the Urinary System

Materials

- Human dissectible torso model and/or anatomical chart of the human urinary system
- Three-dimensional model of the cut kidney and of a nephron (if available)
- Dissecting tray and instruments
- Pig or sheep kidney, doubly or triply injected
- Disposable gloves
- Demonstration area: Longitudinal section of the kidney, set up for microscopic examination under low power; pointer on a glomerulus
- Student samples of urine collected in sterile containers at the beginning of the lab or “normal” artificial urine provided by the instructor
- Numbered “pathological” urine specimens provided by the instructor
- Wide-range pH paper
- Urinometer
- Disposable autoclave bags
- Laboratory buckets containing 10% bleach solution
- Combination dipsticks (Multistix® preferred)

Learning Outcomes

- Identify, on an appropriate model or diagram, the urinary system organs and describe the function of each.
- Identify the major anatomical areas of a dissected kidney.
- Trace the blood supply of the kidney from the renal artery to the renal vein.
- Describe the anatomy of a nephron.
- List the physical characteristics and normal pH and specific gravity ranges of urine.
- Conduct dipstick tests to determine the presence of abnormal substances in the urine specimens.

Metabolism of nutrients produces wastes that must be removed from the body. Although excretory processes involve several organ systems (the lungs excrete carbon dioxide and skin glands excrete salts and water), it is mainly the **urinary system** that removes nitrogenous wastes from the body. The kidney also maintains the electrolyte, acid-base, and fluid balances of the blood.

To properly do its job, the kidney acts first as a blood “filter” and then as a filtrate processor. It allows toxins, metabolic wastes, and excess ions to leave the body via the urine while retaining needed substances and returning them to the blood.

Gross Anatomy of the Human Urinary System

The paired kidneys and ureters and the single urinary bladder and urethra make up the urinary system (**Figure 26.1**). The kidneys perform the functions described and manufacture urine in the process. The remaining organs of the system provide temporary storage or transportation channels for urine.

Activity 1

Identifying Urinary System Organs

Examine the human torso model, a large anatomical chart, or a three-dimensional model of the urinary system to locate and study the anatomy and relationships of the urinary organs.

1. Locate the paired **kidneys** on the dorsal body wall in the superior lumbar region. Notice that the right kidney is slightly lower than the left kidney because it is “crowded” by the liver. In a living person, a *perirenal fat capsule* and a fibrous *renal fascia* hold the kidneys in place in a retroperitoneal position against the muscles of the posterior trunk wall.

2. Observe the **renal arteries** as they diverge from the descending aorta and plunge into the indented medial region, called the **hilum**, of each kidney. Note also the **renal veins**, which drain the kidneys and the two **ureters**, which drain urine from the kidneys, moving it by peristalsis to the bladder for temporary storage.

Text continues on next page. →

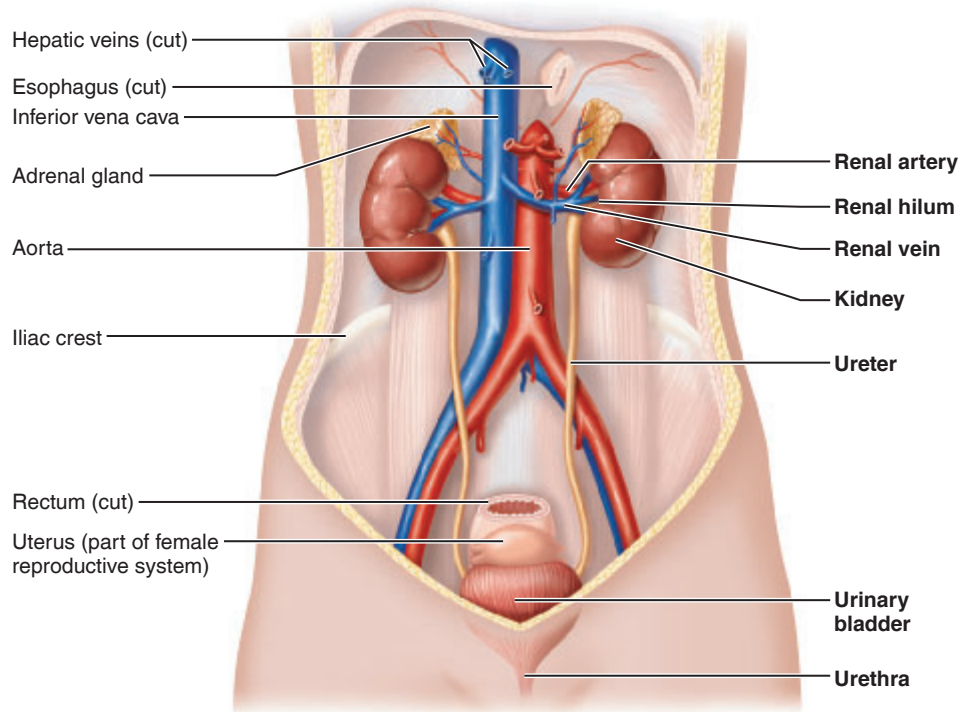


Figure 26.1 Organs of the female urinary system. Anterior view.

3. Locate the **urinary bladder**, and notice where the two ureters enter this organ. Also identify the single **urethra**, which drains the bladder. The triangular region of the bladder, which is outlined by these three openings (two ureteral and one urethral orifice), is the **trigone** (Figure 26.2). If possible, identify the two sphincter muscles that control the outflow of urine from the bladder. The more superior **internal urethral sphincter** is an involuntary sphincter composed of smooth muscle. The **external urethral sphincter** consists of skeletal muscle and is voluntarily controlled.

4. Follow the course of the urethra to the body exterior. In the male, it is approximately 20 cm (8 inches) long, travels the length of the **penis**, and opens at its tip. Its three named regions—the *prostatic*, *intermediate part*, and *spongy (penile) urethrae*—are described in more detail with the reproductive system (Exercise 27). The male urethra has a dual function: it conducts urine to the body exterior, and it provides a passageway for semen ejection from the body. Thus, in the male, the urethra is part of both the urinary and reproductive systems. In females, the urethra is very short, approximately 4 cm (1½ inches) long, and it serves only to transport urine. Its external opening, the **external urethral orifice**, lies anterior to the vaginal opening.

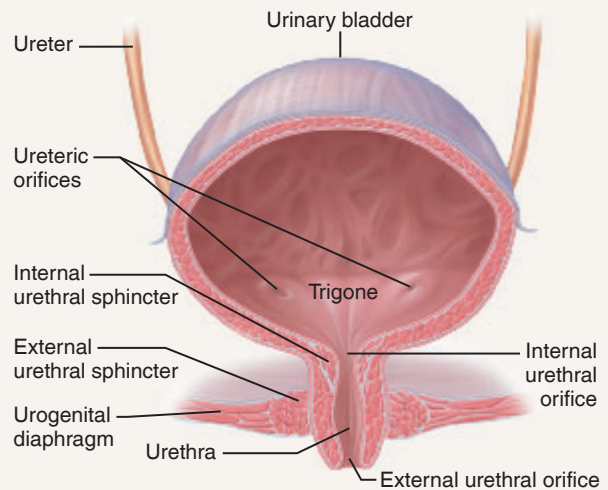


Figure 26.2 Basic structure of the urinary bladder and urethra of a female.


DISSECTION

Gross Internal Anatomy of the Pig or Sheep Kidney

1. In preparation for dissection, don gloves. Obtain a preserved sheep or pig kidney, dissecting tray, and instruments. Observe the kidney to identify the **fibrous capsule**, a smooth transparent membrane that adheres tightly to the surface of the kidney.

2. Find the ureter, renal vein, and renal artery at the hilum. The renal vein has the thinnest wall and will be collapsed. The ureter is the largest of these structures and has the thickest wall.

3. Make a cut through the longitudinal axis (frontal section) of the kidney, and locate the regions described below and shown in **Figure 26.3**.

Renal cortex: The superficial kidney region, which is lighter in color. If the kidney is doubly injected with latex, you will see a predominance of red and blue latex specks in this region, indicating its rich blood supply.

Renal medulla: Deep to the cortex; a darker, reddish brown color. The medulla is segregated into triangular

areas that have a striped appearance—the **renal (medullary) pyramids**. The base of each pyramid faces the cortex, whereas the pointed *papilla*, or *apex*, points to the innermost kidney region.

Renal columns: Areas of tissue within the medulla but more like the cortex in appearance. They separate the renal pyramids.

Renal pelvis: Medial to the hilum; a relatively flat, basin-like cavity that is continuous with the **ureter**, which exits from the hilum region. Fingerlike extensions of the pelvis form cuplike areas called calyces that enclose the apexes of the renal pyramids. There is a **minor calyx** (plural: **calyces**) associated with each renal pyramid, and several minor calyces combine together to form a **major calyx**. The calyces collect urine draining continuously from the papillae into the pelvis.

4. Now obtain a three-dimensional model of a cut kidney and re-identify the structures described in steps 2 through 3.

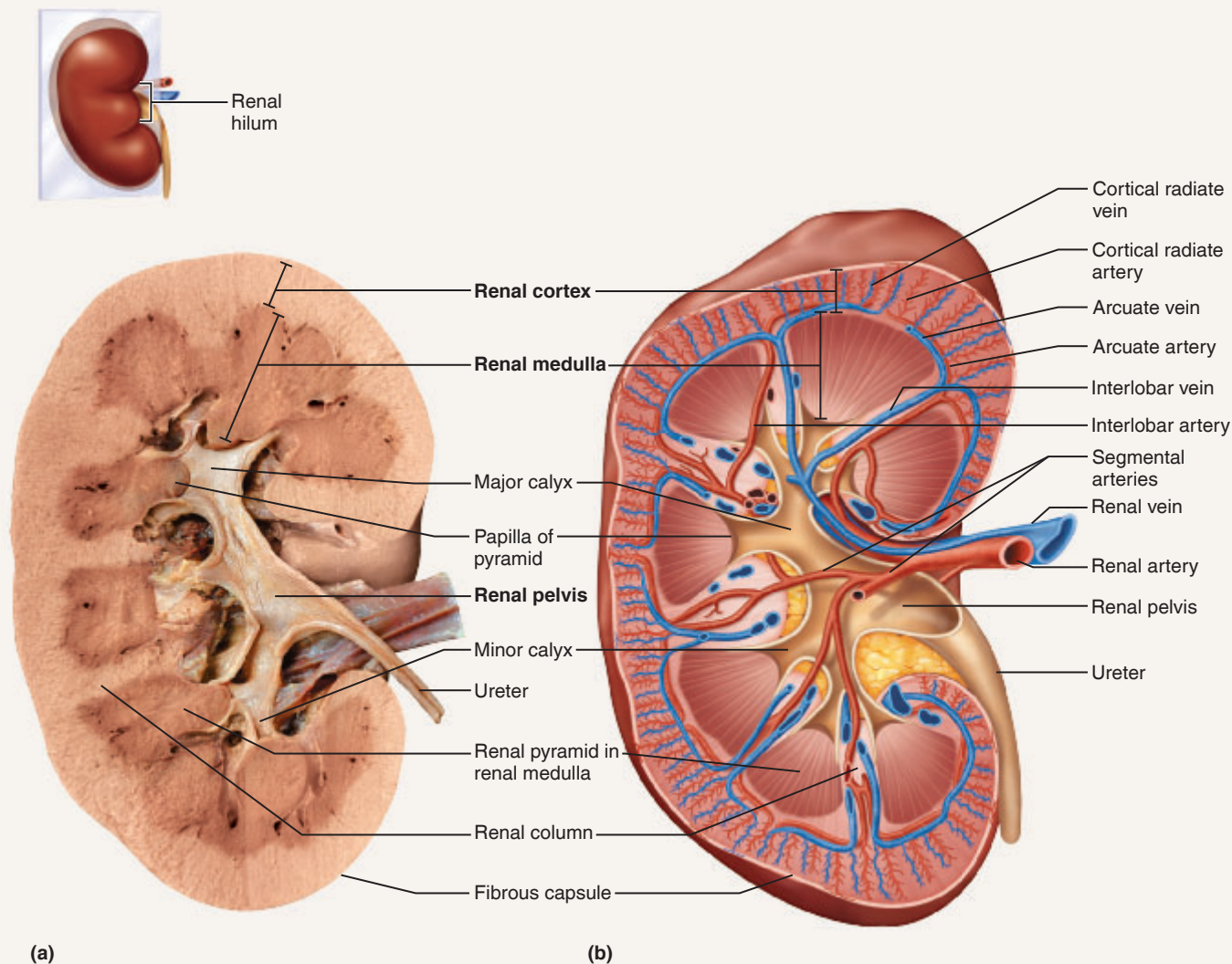


Figure 26.3 Internal anatomy of the kidney. Frontal sections. (a) Photograph of a right kidney. (b) Diagram showing the larger blood vessels supplying the kidney tissue.

The arterial blood supply is delivered to the kidneys by the large **renal arteries**. As a renal artery approaches the kidney, it breaks up into five branches called **segmental arteries**, which enter the hilum. Each segmental artery, in turn, divides into several **interlobar arteries**, which ascend toward the cortex in the renal column areas. At the top of the cortex-medulla junction, the interlobar arteries branch into the **arcuate arteries**, which curve over the bases of the renal pyramids. Small **cortical radiate arteries** branch off

the arcuate arteries and ascend into the cortex, giving off the individual **afferent arterioles**, which lead to the **glomerulus**, a ball of capillaries. **Efferent arterioles** drain the glomerulus and feed into one of two capillary beds, either the **peritubular capillaries** or the **vasa recta**. Blood draining from the nephron capillary networks in the cortex enters the **cortical radiate veins** and then drains through the **arcuate veins** and the **interlobar veins** to finally enter the **renal vein** in the pelvis region. There are no segmental veins.

Functional Microscopic Anatomy of the Kidney

Each kidney contains over a million nephrons, the anatomical units responsible for forming urine (**Figure 26.4**).

Each nephron consists of a **renal corpuscle** and a **renal tubule**. The structures within the renal corpuscle are summarized individually in **Table 26.1**.

The renal tubule is approximately 3 cm (1.25 inches) long. As it extends from the glomerular capsule, it coils and drops down into a long hairpin loop, and then again coils and twists before entering a collecting duct. In order from the glomerular capsule, the anatomical areas of the renal tubule are as follows: the **proximal convoluted tubule**, **nephron loop**, and the **distal convoluted tubule**.

Most nephrons, called **cortical nephrons**, are located entirely within the cortex. The renal corpuscles of the **juxtamedullary nephrons** are located deep in the cortex; their long nephron loops dip deep into the medulla. The **collecting ducts**, each of which receives urine from many nephrons, run downward through the renal pyramids to empty the urine product into the calyces and pelvis of the kidney.

Nephron function depends on some unique features of the renal circulation. There are three distinct capillary beds, the **glomerulus**, the **peritubular capillary bed**, and the **vasa recta**. Because (1) the **glomerulus** is fed and drained by arterioles (arterioles are high-resistance vessels as opposed to venules) and (2) the feeder **afferent arteriole** is larger in diameter than the **efferent arteriole** draining the bed, the glomerulus is a high-pressure bed along its entire length. The high hydrostatic pressure created by these two anatomical features forces out fluid and blood components smaller than proteins from the glomerulus into the glomerular capsule. That is, it forms the filtrate, which is processed by the renal tubule.

The **peritubular capillary bed** arises from the efferent arteriole draining the glomerulus. These capillaries cling to

the renal tubule and empty into the cortical radiate veins that leave the cortex. The peritubular capillaries are *low-pressure* porous capillaries adapted for absorption and readily take up the solutes and water reclaimed from the filtrate by the tubule cells. Efferent arterioles that supply juxtamedullary nephrons form long, straight, highly interconnected vessels called **vasa recta**. The vasa recta is essential for the formation of concentrated urine.

Substances that are almost entirely reabsorbed from the filtrate include water, glucose, and amino acids. Various ions are selectively reabsorbed or allowed to go out in the urine according to what is required to maintain appropriate blood pH and electrolyte balance. Wastes are reabsorbed to a much lesser degree or not at all. Most of tubular reabsorption occurs in the proximal convoluted tubule.

Activity 2

Studying Nephron Structure

1. Obtain a nephron model, and bring it to your lab bench. Begin your study of nephron structure by identifying the glomerulus, glomerular capsule, proximal and distal convoluted tubules, and the nephron loop on the model. Also identify the arcuate and interlobar arteries and the corresponding veins, the afferent and efferent arterioles, and the peritubular capillary bed.
2. Go to the demonstration area to continue your study of nephron structure by examining a longitudinal section of the kidney. Scan the slide under low power.

Text continues on page 336. →

Table 26.1 Structures of the Renal Corpuscle (Figure 26.4)

Structure	Description	Function
Glomerulus	A cluster of capillaries supplied by the afferent arteriole and drained by the efferent arteriole	Forms part of the filtration membrane.
Visceral layer of the glomerular capsule	Podocytes that wrap around the glomerular capillaries branch into foot processes	Forms part of the filtration membrane. Spaces between the foot processes form filtration slits that allow filtrate to enter the capsular space.
Parietal layer of the glomerular capsule	Outer impermeable wall of the glomerular capsule	Forms the outside of the cuplike glomerular capsule. Plays no role in filtration.

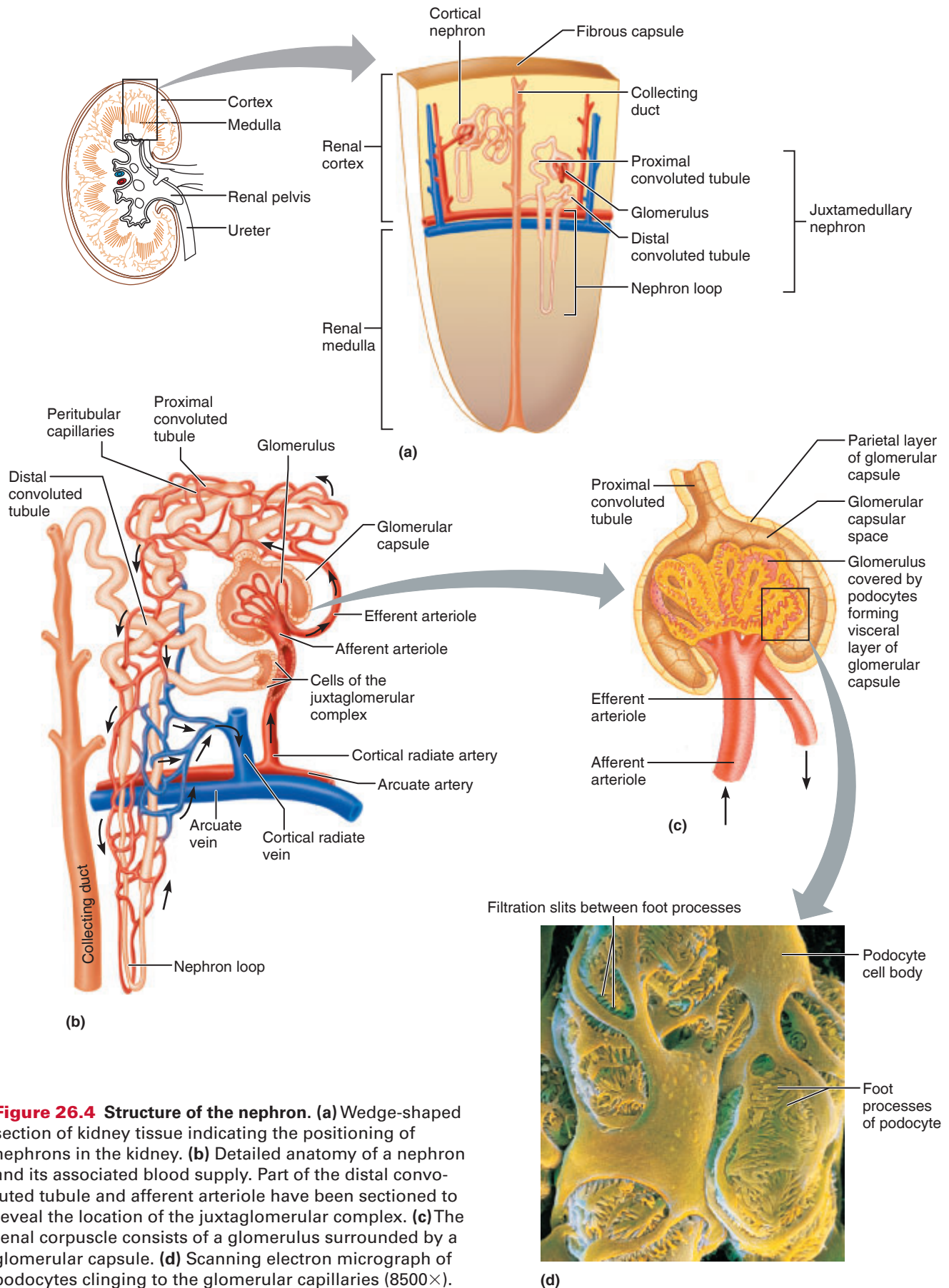


Figure 26.4 Structure of the nephron. (a) Wedge-shaped section of kidney tissue indicating the positioning of nephrons in the kidney. (b) Detailed anatomy of a nephron and its associated blood supply. Part of the distal convoluted tubule and afferent arteriole have been sectioned to reveal the location of the juxtaglomerular complex. (c) The renal corpuscle consists of a glomerulus surrounded by a glomerular capsule. (d) Scanning electron micrograph of podocytes clinging to the glomerular capillaries (8500 \times).

3. Take a close look at the cortical area. Identify a glomerulus (pointed-out structure), which appears as a ball of tightly packed material containing many small nuclei (**Figure 26.5**). Notice the vacant-appearing region corresponding to the lumen of the glomerular capsule that surrounds it.

4. The balance of the kidney tissue consists of renal tubules. Note that the renal tubules are cut at various angles. Also try to pick out the thin-walled nephron loop portion of the tubules and a section of the proximal convoluted tubule, which has dense microvilli that provide for increased capability for reabsorption.

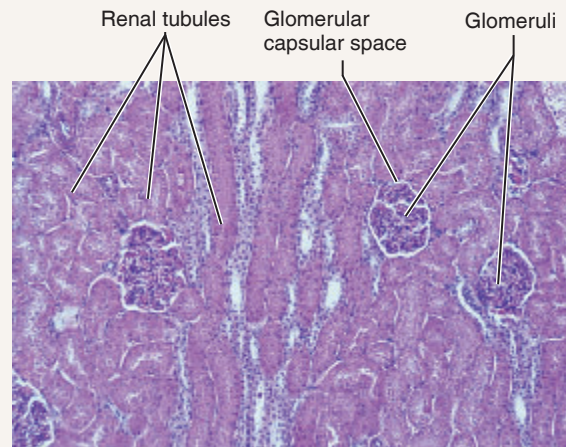


Figure 26.5 Microscopic structure of kidney tissue. Low-power view of the renal cortex (70 \times). (See also Plate 41 in the Histology Atlas.)

Urinalysis

Blood composition depends largely on three factors: diet, cellular metabolism, and urinary output. In 24 hours, the kidneys filter approximately 150 to 180 liters of blood plasma into

their tubules, where it is processed. In the same period, urine output is 0.8 to 1.8 liters.

Characteristics of Urine

Freshly voided urine is usually clear and pale to deep yellow in color. This normal yellow color is due to *urochrome*, a pigment arising from the body's breakdown of hemoglobin. As a rule, the greater the solute concentration, the deeper the yellow color. Abnormal urine color may be due to certain foods, such as beets, various drugs, bile, or blood.

The odor of freshly voided urine is slightly aromatic, but bacterial action gives it an ammonia-like odor when left standing. Certain diseases may alter the characteristic odor of urine. For example, the urine of a person with uncontrolled diabetes mellitus (and elevated levels of ketones) smells fruity, like acetone.

The pH of urine ranges from 4.5 to 8.0, but its average value is slightly acidic (usually around 6). Diet may markedly influence the pH of the urine. For example, a high-protein diet increases the acidity of urine, while a vegetarian diet increases the alkalinity of the urine. A bacterial infection of the urinary tract may also result in urine with a high pH.

Specific gravity is the relative weight of a specific volume of liquid compared with an equal volume of distilled water. The specific gravity of distilled water is 1.000, because 1 ml weighs 1 g. Because urine contains dissolved solutes, a given volume of urine weighs more than the same volume of water, and its customary specific gravity ranges from 1.001 to 1.030. Urine with a specific gravity of 1.001 contains few solutes and is very dilute. Dilute urine is common when a person drinks large amounts of water, uses diuretics, or suffers from chronic renal failure. Conditions that produce urine with a high specific gravity include limited fluid intake, fever, diabetes mellitus, gonorrhea, and kidney inflammation, called *pyelonephritis*. If urine becomes excessively concentrated, some of the solutes begin to precipitate or crystallize, forming **kidney stones**, or **renal calculi**.

Solutes normally found in urine (in order of *decreasing* concentration) include urea; sodium, potassium, phosphate, and sulfate ions; creatinine; and uric acid. Much smaller but highly variable amounts of calcium, magnesium, and bicarbonate ions are also found in urine.

Abnormal Constituents of Urine

Abnormal urinary constituents are substances not normally present in the urine when the body is operating properly. These include glucose, ketone bodies, blood proteins (primarily albumin), red blood cells (erythrocytes), hemoglobin,

white blood cells (leukocytes), and bile. **Table 26.2** lists abnormal urinary constituents and possible conditions in which they might be seen.

Table 26.2 Abnormal Constituents of Urine

Substance	Name of condition	Possible causes
Glucose	Glycosuria	Nonpathological: excessive carbohydrate intake Pathological: uncontrolled diabetes mellitus
Proteins	Proteinuria, albuminuria	Nonpathological: excessive physical exertion, pregnancy Pathological (over 150 mg/day): heart failure, severe hypertension, glomerulonephritis, often initial sign of asymptomatic renal disease
Ketone bodies	Ketonuria	Excessive formation and accumulation of ketone bodies, as in low-carbohydrate diets, starvation and uncontrolled diabetes mellitus
Hemoglobin	Hemoglobinuria	Various: transfusion reaction, hemolytic anemia, severe burns, poisonous snake bites, and renal disease
Bile pigments	Bilirubinuria	Liver disease (hepatitis, cirrhosis) or obstruction of bile ducts from liver or gallbladder
Erythrocytes	Hematuria	Bleeding in the urinary tract (due to trauma, kidney stones, infection, or cancer)
Leukocytes (pus)	Pyuria	Urinary tract infection, gonorrhea

Activity 3

Analyzing Urine Samples

In this part of the exercise, you will use combination dip sticks and perform a number of tests to determine the characteristics of normal urine as well as to identify abnormal urinary components. You will investigate both “normal” urine—yours or a normal sample provided by your instructor—designated as the *standard urine specimen* in **Table 26.3** and an unknown urine specimen provided by your instructor. Record the number of your unknown specimen in the table. Then conduct the following tests on both samples, and record your results by circling the appropriate description or by adding data to complete Table 26.3.



Obtain and wear disposable gloves throughout this laboratory session. Although the instructor-provided

urine samples are actually artificial urine, you should still observe the techniques of safe handling of body fluids as part of your learning process. When you have completed the laboratory procedures: (1) dispose of the gloves and used pH paper strips in the autoclave bag; (2) put used glassware in the bleach-containing laboratory bucket; (3) wash the lab bench down with 10% bleach solution.

Determining Physical Characteristics of Urine

1. Assess the color, transparency, and odor of your standard sample and one of the numbered pathological samples, and circle the appropriate descriptions in Table 26.3.

Table 26.3 Urinalysis Results*

Observation or test	Normal values	Standard urine specimen	Unknown specimen (#)
Physical Characteristics			
Color	Pale yellow	Yellow: pale medium dark other _____	Yellow: pale medium dark other _____
Transparency	Clear	Clear Slightly cloudy Cloudy	Clear Slightly cloudy Cloudy
Odor	Aromatic	Describe _____	Describe _____
pH	4.5–8.0	_____	_____
Specific gravity	1.001–1.030	_____	_____
Organic Components			
Glucose	Negative	Record results: _____	Record results: _____
Protein	Negative	Record results: _____	Record results: _____
Ketone bodies	Negative	Record results: _____	Record results: _____
RBCs/hemoglobin	Negative	Record results: _____	Record results: _____
Bilirubin	Negative	Record results: _____	Record results: _____

*In recording urinalysis data, circle the appropriate description if provided; otherwise, record the results you observed.

2. Obtain a roll of wide-range pH paper to determine the pH of each sample. Use a fresh piece of paper for each test, and dip the strip into the urine to be tested two or three times before comparing the color obtained with the chart on the dispenser. Record your results in Table 26.3. You will be using one of the combination dipsticks (e.g., Multistix[®]) later; recheck this pH determination then.

3. To determine specific gravity, obtain a urinometer cylinder and float. Mix the urine well, and fill the urinometer cylinder about two-thirds full with urine.

4. Examine the urinometer float to determine how to read its markings. In most cases, the scale has numbered lines separated by a series of unnumbered lines. The numbered lines give the reading for the first two decimal places. You must determine the third decimal place by reading the lower edge of the meniscus—the curved surface representing the urine-air junction—on the stem of the float.

5. Carefully lower the urinometer float into the urine. Make sure it is floating freely before attempting to take the reading. Record the specific gravity of both samples in the table. *Do not dispose of this urine if the samples that you have are less than 200 ml in volume* because you will need to make more determinations.

Determining Organic Constituents in Urine

Combination dipsticks will be used for all of the tests in this section, so you should be prepared to take the readings on several factors (pH, protein [albumin], glucose,

ketones, and blood/hemoglobin) at the same time. Generally speaking, results for all of these tests may be read *during* the second minute after immersion, but readings taken after 2 minutes have passed should be considered inaccurate. Pay careful attention to the directions for method and time of immersion and disposal of excess urine from the strip, regardless of the dipstick used.

Glucose

Conduct the dipstick test according to the instructions on the vial. Record the results in Table 26.3.

Protein

Use a combination dipstick, and conduct the determinations as indicated on the vial. Record your results.

Ketone Bodies

Use a combination dipstick, and conduct the tests as indicated on the vial. Record your results.

Blood/Hemoglobin

Test your urine samples for the presence of hemoglobin by using a combination dipstick according to the directions on the vial. Usually a short drying period is required before the reading can be made, so read the directions carefully. Record your results.

Verify your conclusions on the unknown specimen with your instructor before cleaning your bench with bleach solution and leaving the laboratory.

EXERCISE
26

REVIEW SHEET

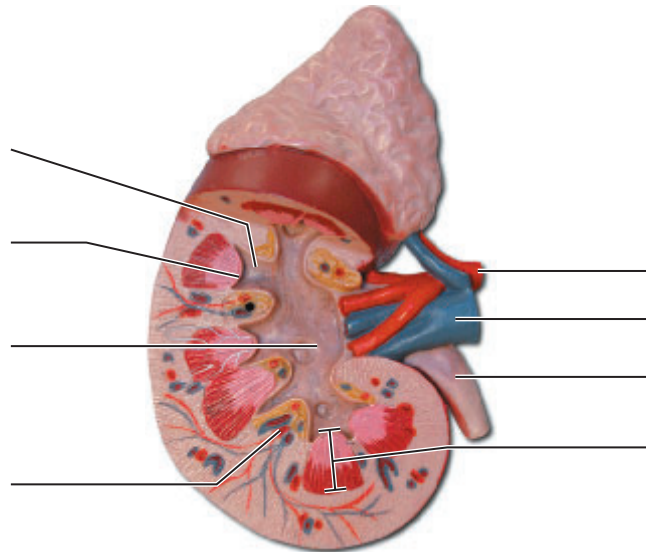
Functional Anatomy of the Urinary System

Name _____ Lab Time/Date _____

Gross Anatomy of the Human Urinary System

1. What is the function of the fat capsule that surrounds the kidneys in life? _____

2. Label the photograph of the kidney model by selecting the letter for the correct structure from the key below.



Key:

- | | | |
|-----------------|------------------|---------------|
| a. minor calyx | d. renal papilla | g. renal vein |
| b. renal artery | e. renal pelvis | h. ureter |
| c. renal column | f. renal pyramid | |

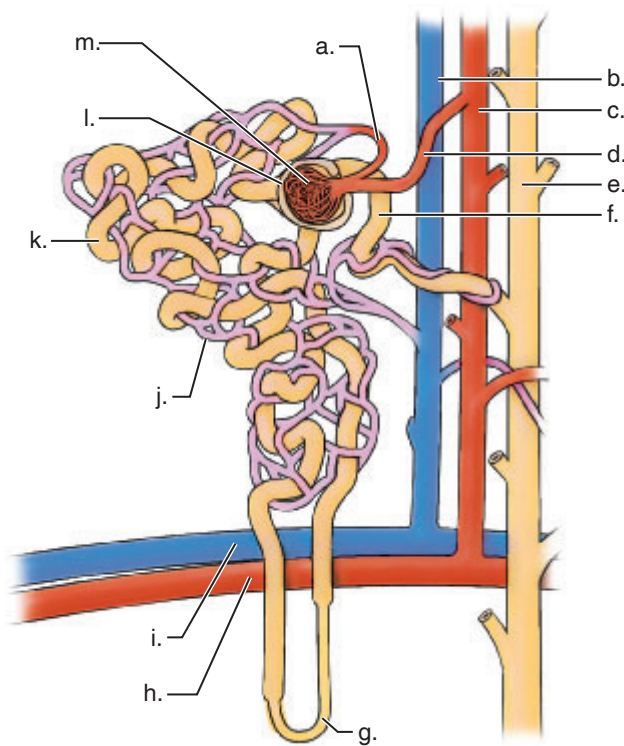
Gross Internal Anatomy of the Pig or Sheep Kidney

3. Match the appropriate structure in Column B to its description in Column A.

Column A	Column B
_____ 1. smooth membrane clinging tightly to the kidney surface	cortex
_____ 2. portion of the kidney containing mostly collecting ducts	medulla
_____ 3. superficial region of kidney tissue	minor calyx
_____ 4. basinlike area of the kidney, continuous with the ureter	fibrous capsule
_____ 5. an extension of the pelvis that encircles the apex of a pyramid	renal column
_____ 6. tissue running between the renal pyramids	renal pelvis

Functional Microscopic Anatomy of the Kidney

4. Match each of the lettered structures on the diagram of the nephron (and associated renal blood supply) on the left with the terms on the right:



- _____ 1. collecting duct
- _____ 2. glomerulus
- _____ 3. peritubular capillaries
- _____ 4. distal convoluted tubule
- _____ 5. proximal convoluted tubule
- _____ 6. cortical radiate artery
- _____ 7. glomerular capsule
- _____ 8. arcuate artery
- _____ 9. cortical radiate vein
- _____ 10. efferent arteriole
- _____ 11. arcuate vein
- _____ 12. nephron loop
- _____ 13. afferent arteriole


5. Using the terms provided in question 4, identify the following:


- _____ 1. ball of capillaries within the renal corpuscle
- _____ 2. primary site of tubular reabsorption
- _____ 3. structure that conveys the processed filtrate (urine) from many nephrons

- _____ 4. blood supply that directly receives substances from the tubular cells
- _____ 5. its inner (visceral) membrane forms part of the filtration membrane
6. Explain *why* the glomerulus is such a high-pressure capillary bed. _____


How does its high-pressure condition help the glomerulus carry out filtrate formation? _____


7. What structural modification of certain tubule cells enhances their ability to reabsorb substances from the filtrate?
- _____
8. Trace a drop of blood from the time it enters the kidney in the renal artery until it leaves the kidney through the renal vein.

Renal artery  _____

_____  renal vein

9. Trace the anatomical pathway of a molecule of a waste substance from the glomerular capsule to the urethra. Note each microscopic and/or gross structure it passes through in its travels, and include the names of the subdivisions of the renal tubule.

Glomerular capsule  _____

_____  urethra

Urinalysis: Characteristics of Urine

10. What is the range for the volume of urine normally excreted in a 24-hour period? _____

11. List three solutes that are routinely found in urine:

List three substances that are absent from the urine of healthy individuals:

List two substances that are routinely found in filtrate but *not* in the urine product:

12. Explain why urinalysis is a routine part of any good physical examination. _____

13. What substance is responsible for the normal yellow color of urine? _____

14. Which has a greater specific gravity: 1 ml of urine or 1 ml of distilled water? _____

Explain. _____

15. Explain the relationships among the color, specific gravity, and volume of urine. _____

Abnormal Constituents of Urine


16. Explain two reasons why glucose might be present in the urine. _____


17. Several specific terms have been used to indicate the presence of abnormal urine constituents. Identify which urine abnormalities listed in column A might be caused by each of the conditions listed in column B.

Column A	Column B
_____ 1. blood in the urine	proteinuria
_____ 2. hemolytic anemia	glycosuria
_____ 3. eating a 2-lb box of candy at one sitting	hematuria
_____ 4. pregnancy	hemoglobinuria
_____ 5. starvation	ketonuria
_____ 6. urinary tract infection	pyuria

18. What are renal calculi, and what conditions favor their formation? _____

19. Describe the effect that dehydration would have on the specific gravity of urine and why. _____

20.  A urinary tract infection (UTI) is an infection of any of the urinary tract structures: kidneys, ureter, bladder, or urethra. Considering the differences in the male and female anatomy and that the bacteria that cause UTIs are often found in the feces, explain why females are more likely to contract a UTI. _____

21.  *Proteus mirabilis* produces the enzyme urease, which converts urea into ammonia. Explain why patients with a UTI caused by *Proteus mirabilis* would have a higher-than-normal urine pH. _____

Anatomy of the Reproductive System

Materials

- Models or large laboratory charts of the male and female reproductive tracts
- Ovary model
- Demonstration area: Prepared microscope slides set up for microscopic examination
Station 1: Human sperm (oil-immersion)
Station 2: Ovary

Learning Outcomes

- Identify structures of the male reproductive system on an appropriate model or diagram, and give the function of each.
- Trace the pathway of sperm from the testis to the body exterior.
- Name the exocrine and endocrine products of the testis.
- Relate sperm structure to sperm function.
- Identify the structures of the female reproductive system when provided with an appropriate model or diagram, and explain the function of each.
- Identify the fundus, body, and cervix regions of the uterus.
- Name the exocrine and endocrine products of the ovary.

The **reproductive system** is unique. Most simply stated, its biological function is to produce offspring. The reproductive role of the male is to manufacture sperm and to deliver them to the female reproductive tract. The female, in turn, produces eggs. If the time is suitable, the combination of sperm and egg produces a fertilized egg. Once fertilization has occurred, the female uterus provides a nurturing, protective environment in which the embryo, later called the fetus, develops until birth.

Gross Anatomy of the Human Male Reproductive System

The primary sex organs of the male are the **testes**, the male **gonads**, which have both an exocrine (sperm production) and an endocrine (testosterone production) function. All other reproductive structures are ducts or sources of secretions, which help deliver the sperm safely to the body exterior or female reproductive tract. A sagittal view of the male reproductive system is illustrated in **Figure 27.1**.

Activity 1

Identifying Male Reproductive Organs

As the following organs and structures are described, locate them on Figure 27.1, and then identify them on a model of the male reproductive system or on a large laboratory chart.

The paired oval testes lie in the **scrotum** outside the abdominopelvic cavity. The temperature there is slightly lower than body temperature, a requirement for producing viable sperm.

The accessory structures forming the *duct system* are the epididymis, the ductus deferens, the ejaculatory duct, and the urethra. Identify the **epididymis**, an elongated structure running up the posterior and lateral aspect of the testis and capping its superior aspect. The epididymis forms the first portion of the duct system and provides a site for immature sperm to mature. Follow the **ductus deferens**, or

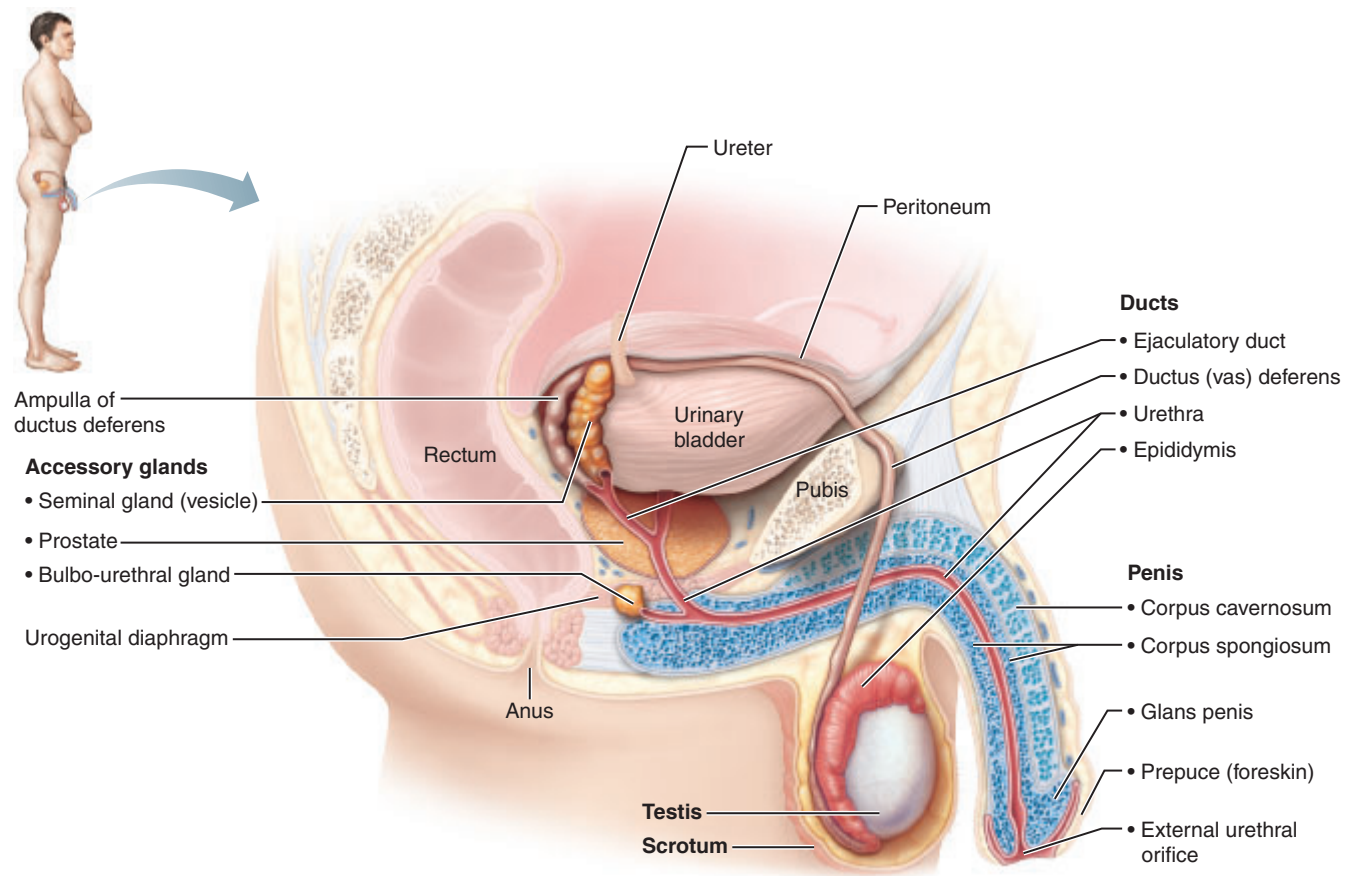


Figure 27.1 Reproductive system of the human male, sagittal view.

vas deferens (sperm duct) as it runs superiorly from the epididymis, passes through the inguinal canal into the pelvic cavity, and arches over the superior aspect of the urinary bladder. The ductus deferens is enclosed along with blood vessels and nerves in a connective tissue sheath called the **spermatic cord**. The end of the ductus deferens empties into the **ejaculatory duct**. During ejaculation, contraction of the ejaculatory duct propels the sperm through the prostate gland to the **prostatic urethra**, which in turn empties into the **intermediate part of the urethra** and then into the **spongy urethra**, which runs through the length of the penis to the body exterior.

The *accessory glands* include the prostate gland, the paired seminal glands (seminal vesicles), and the bulbo-urethral glands. These glands produce **seminal fluid**, the liquid

medium in which sperm leave the body. The location and secretion of accessory glands are summarized in **Table 27.1**.

The **penis**, part of the external genitalia of the male along with the scrotum, is the copulatory organ of the male. Designed to deliver sperm into the female reproductive tract, it consists of a body or shaft, which terminates in an enlarged tip, the **glans penis**. The skin covering the penis is loosely applied, and it reflects downward to form a fold of skin, the **prepuce**, or **foreskin**, around the proximal end of the glans. The foreskin is sometimes removed in the surgical procedure called *circumcision*. Internally, the penis consists primarily of three elongated cylinders of erectile tissue that fill with blood during sexual excitement. This causes the penis to enlarge and become rigid so that it may serve as a penetrating device. This event is called **erection**.

Table 27.1 Accessory Glands of the Male Reproductive System (Figure 27.1)

Accessory gland	Location	Secretion
Seminal glands	Paired glands located posterior to the urinary bladder. The duct of each gland merges with a ductus deferens to form the ejaculatory duct.	A thick, light yellow, alkaline secretion containing fructose and citric acid, which nourish the sperm, and prostaglandins for enhanced sperm motility. Its secretion has the largest contribution to the volume of semen.
Prostate	Single gland that encircles the prostatic urethra inferior to the bladder.	A milky, slightly acidic fluid that contains citric acid, several enzymes, and prostate-specific antigen (PSA). Its secretion plays a role in activating the sperm.
Bulbo-urethral glands	Paired tiny glands that drain into the intermediate part of the urethra.	A clear alkaline mucus that lubricates the tip of the penis for copulation and neutralizes traces of acidic urine in the urethra prior to ejaculation.

Microscopic Anatomy of the Testes and Sperm

Testis

Each testis is covered by two connective tissue layers: the outermost **tunica vaginalis** and the deeper **tunica albuginea**. Extensions of the tunica albuginea enter the testis, dividing it into a number of lobules, each of which houses one to four highly coiled **seminiferous tubules**, the sperm-forming factories (**Figure 27.2**). The seminiferous tubules of each lobule empty the sperm into another set of tubules, the **rete testis**, at the posterior side of the testis. Sperm traveling through the rete testis then enter the epididymis, located on the exterior aspect of the testis, as previously described. Lying in the connective tissue between the seminiferous tubules are the **interstitial endocrine cells**, which produce testosterone, the hormonal product of the testes.

Sperm


During sperm formation, all the excess cytoplasm is sloughed off the developing sperm, and what remains is compacted into the three regions. At the risk of oversimplifying, these regions are the *head*, the *midpiece*, and the *tail* (**Figure 27.3**), which correspond roughly to the activating and genetic region, the metabolic region (rich in mitochondria for ATP production), and the locomotor region (a flagellum powered by ATP), respectively. The mature sperm is a streamlined cell equipped with an organ of locomotion that enables it to move long distances in jig time to get to the egg.

The sperm head contains the DNA of the chromosomes. Essentially it is the nucleus of the spermatid. Anterior to the nucleus is the **acrosome**, which contains enzymes involved in sperm penetration of the egg.

Activity 2

Viewing Sperm Microscopically

Go to station 1 of the demonstration area, and view a prepared slide of human sperm with the oil immersion lens. Compare what you see to Figure 27.3a and Plate 47 in the Histology Atlas. Identify the head, acrosome, and tail regions. Draw and appropriately label two or three sperm in the space below.



Deformed sperm, for example, sperm with multiple heads or tails, are sometimes present in such preparations. Did you observe any?

_____ If so, describe them. _____

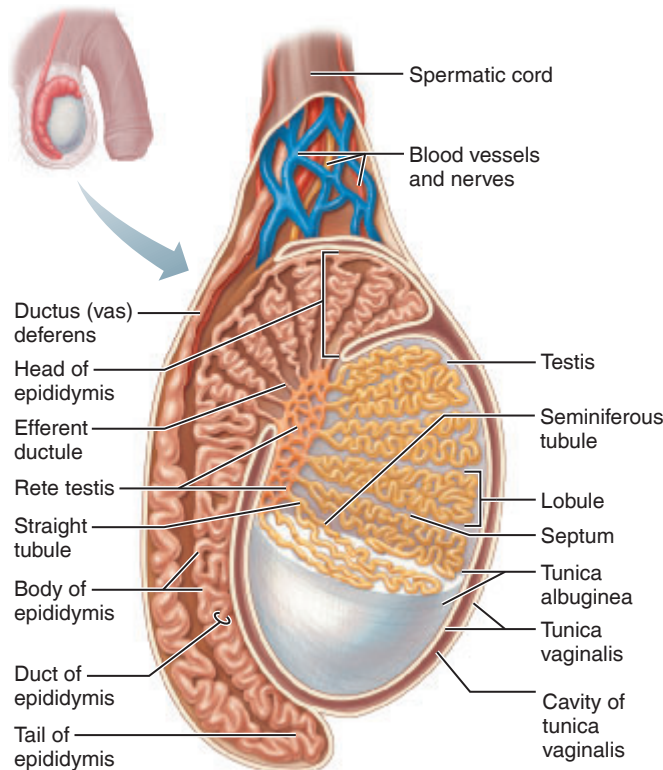
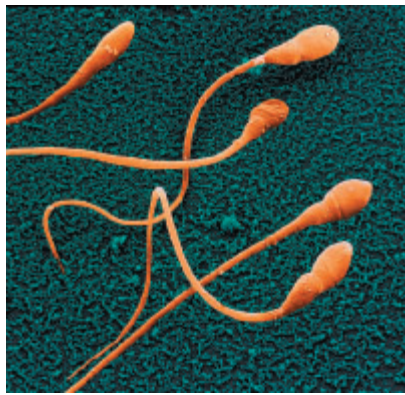
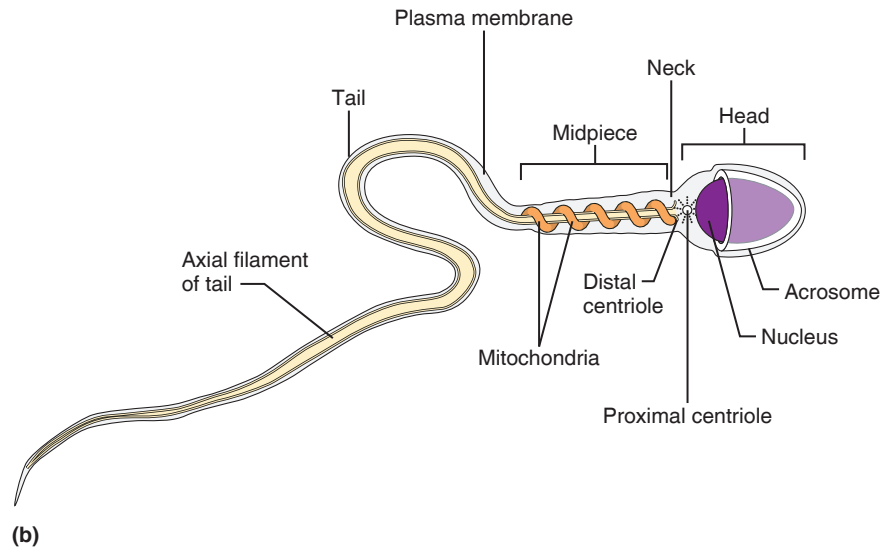


Figure 27.2 Structure of the testis. Longitudinal section of the testis showing seminiferous tubules. Epididymis and part of the ductus deferens also shown. (See also Plates 44 and 46 in the Histology Atlas.)



(a)



(b)

Figure 27.3 Structure of a sperm. (a) Scanning electron micrograph of mature sperm (2100 \times). (b) Diagram of a sperm.

Gross Anatomy of the Human Female Reproductive System

The ovaries (female gonads) are the primary sex organs of the female. Like the testes of the male, the ovaries produce both an exocrine product (eggs, or ova) and endocrine products (estrogens and progesterone). The accessory structures of the female reproductive system transport, house, nurture, or otherwise serve the needs of the reproductive cells and/or the developing fetus.

Activity 3

Identifying Female Reproductive Organs

As you read the descriptions of these structures, locate them on Figures 27.4, 27.5, and 27.6 and then on the female reproductive system model or large laboratory chart.

The **external genitalia (vulva)** consist of the mons pubis, the labia majora and minora, the clitoris, the urethral and vaginal orifices, and greater vestibular glands. **Table 27.2** summarizes the structures of the female external genitalia (**Figure 27.4**).

The diamond-shaped region between the anterior end of the labial folds, the ischial tuberosities laterally, and the anus posteriorly is called the **perineum**.

The internal female organs include the vagina, uterus, uterine tubes, ovaries, and the structures that suspend these organs in the pelvic cavity (**Figure 27.5**). The **vagina** extends for approximately 10 cm (4 inches) from the vestibule to the uterus superiorly. It serves as a copulatory organ because it receives the penis (and semen) during sexual intercourse. The vagina also provides a passageway for delivery

Table 27.2 External Genitalia (Vulva) of the Human Female (Figure 27.4)

Structure	Description
Mons pubis	Rounded fatty eminence that cushions the pubic symphysis; covered with coarse pubic hair after puberty.
Labia majora (singular: <i>labium majus</i>)	Two elongated hair-covered skin folds that extend from the mons pubis. They contain sebaceous glands, apocrine glands, and adipose. They are homologous to the scrotum.
Labia minora (singular: <i>labium minus</i>)	Two smaller folds located medial to the labia majora. They don't have hair or adipose but they do have many sebaceous glands.
Vestibule	Region located between the two labia minora. From anterior to posterior, it contains the clitoris, the external urethral orifice, and the vaginal orifice.
Clitoris	Small mass of erectile tissue located where the labia minora meet anteriorly. It is homologous to the penis.
Prepuce of the clitoris	Skin folds formed by the union of the labia minora; they serve to hood the clitoris.
External urethral orifice	Serves as the outlet for the urinary system. It has no reproductive function in the female.
Hymen	A thin fold of vascular mucous membrane that may partially cover the vaginal opening.
Greater vestibular glands	Pea-sized mucus-secreting glands located on either side of the hymen. They lubricate the distal end of the vagina during coitus. They are homologous to the bulbo-urethral glands of males.

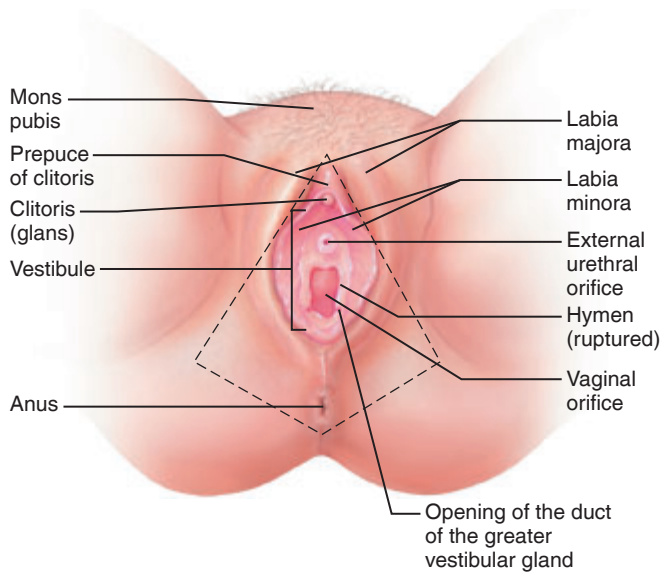


Figure 27.4 External genitalia (vulva) of the human female. The region enclosed by the dashed lines is the perineum.

of an infant and for menstrual flow. The pear-shaped **uterus**, situated between the bladder and the rectum, is a muscular organ with its narrow end, the **cervix**, directed inferiorly. The major portion of the uterus is the **body**; its superior rounded region above the entrance of the uterine tubes is the **fundus**.

A fertilized egg is implanted in the uterus, which houses the embryo or fetus during its development.

The **uterine**, or **fallopian**, **tubes** enter the superior part of the uterus and extend for about 10 cm (4 inches) toward the **ovaries** in the peritoneal cavity. The distal ends of the tubes are funnel-shaped and have fingerlike projections called **fimbriae**. Unlike the male duct system, there is no actual contact between the female gonad and the initial part of the female duct system—the uterine tube. Therefore, the function of the fimbriae is to create a current that sweeps the ovulated egg into the uterine tube.

The internal female organs are all retroperitoneal, except the ovaries. They are supported and suspended somewhat freely by folds of peritoneum. The peritoneum takes an undulating course. The fold that encloses the uterine tubes and uterus and secures them to the lateral body walls is the **broad ligament** (Figure 27.6). The **round ligaments** and the **uterosacral ligaments** also help attach the uterus to the body wall. The ovaries are supported medially by the **ovarian ligament** (extending from the uterus to the ovary) and laterally by the **suspensory ligaments**. The ovaries are considered to be homologous to the testes and possess the same covering as the tunica albuginea.

Within the ovaries, the female gametes (eggs) begin their development in saclike structures called **follicles** (Figure 27.7). The growing follicles also produce **estrogens**. When a developing egg has reached the appropriate stage of maturity, it is ejected from the ovary in an event called **ovulation**. The ruptured follicle is then converted to a **corpus luteum**, which secretes progesterone (and some estrogens).

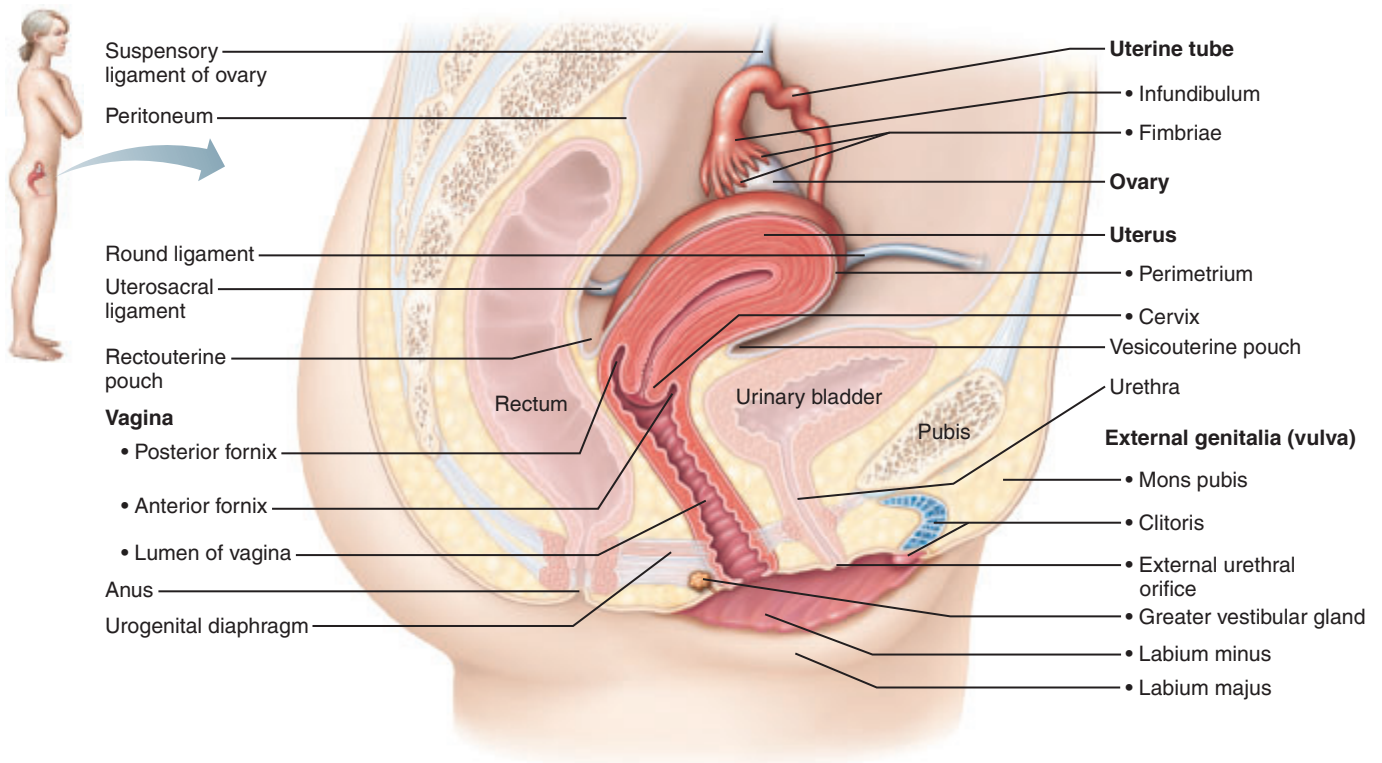


Figure 27.5 Midsagittal section of the human female reproductive system.

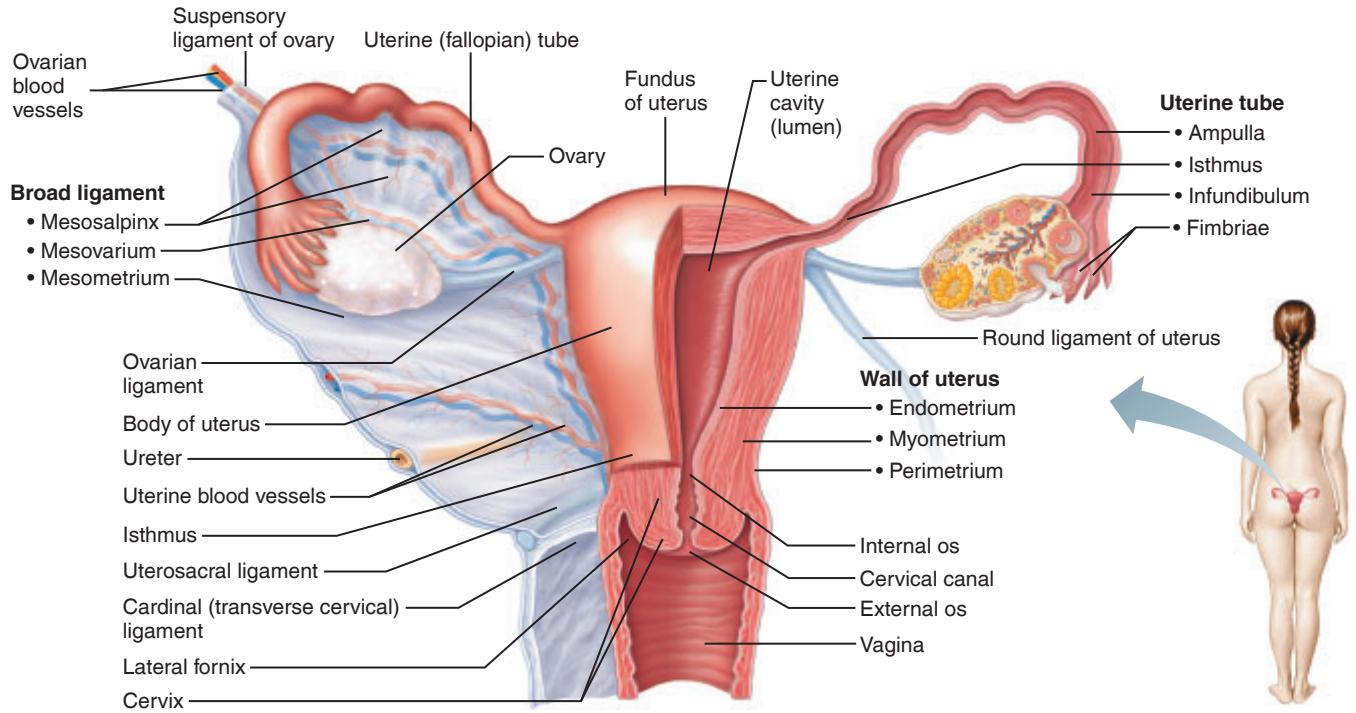


Figure 27.6 Internal reproductive organs of a female, posterior view. The posterior walls of the vagina, uterus, and uterine tubes, and the broad ligament (a peritoneal fold) have been removed on the right side to reveal the shape of the lumen of these organs.

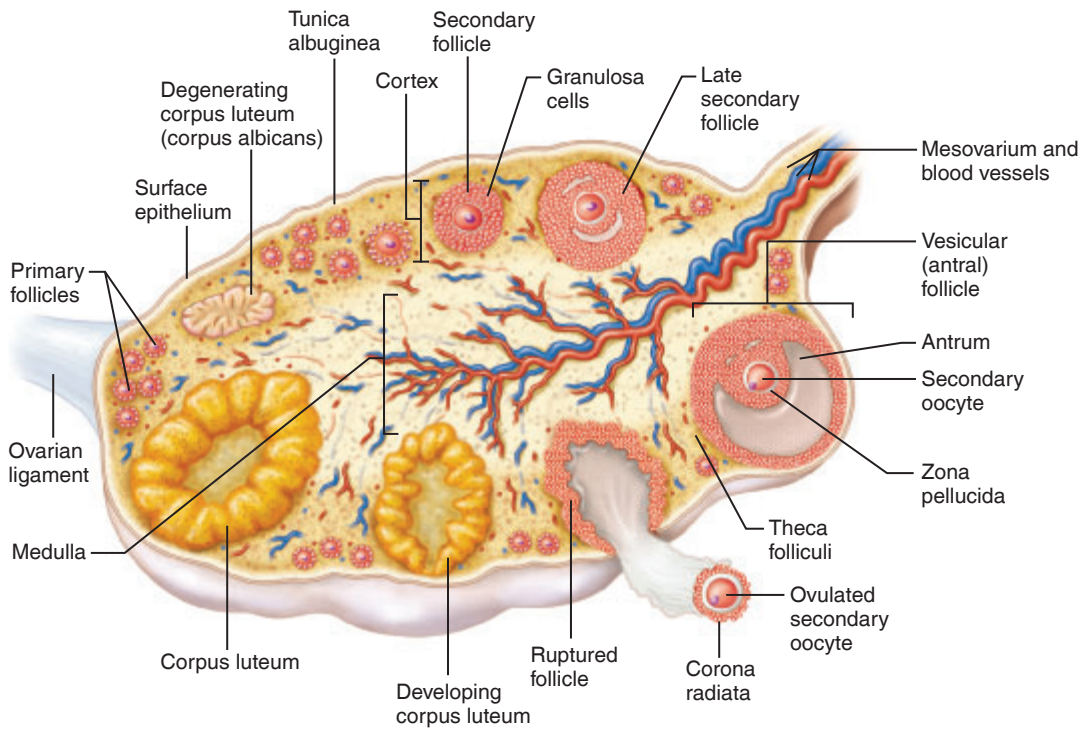


Figure 27.7 Anatomy of the human ovary.

Activity 4

Conducting a Microscopic Study of the Ovary

Because many different stages of ovarian development exist within the ovary at any one time, a single microscopic preparation will contain follicles at many different stages of development. Go to station 2 of the demonstration area where a cross section of ovary tissue has been set up for viewing, and identify the following structures. Refer to Figure 27.7 and **Figure 27.8** as you work.

Surface epithelium: Outermost layer of the ovary.

Primary follicle: One or a few layers of cuboidal follicle cells surrounding the larger central developing ovum.

Secondary follicles: Follicles consisting of several layers of follicle cells surrounding the central developing ovum and beginning to show evidence of fluid accumulation in a central cavity. Secrete estrogens.

Vesicular (antral) follicle: At this stage of development, the follicle has a large antrum containing fluid. The developing ovum is pushed to one side of the follicle and is surrounded by a capsule of several layers of follicle cells called the **corona radiata** (radiating crown). When the secondary oocyte is released, it enters the uterine tubes with its corona radiata intact.

Corpus luteum: A solid glandular structure or a structure containing a scalloped lumen that develops from the ovulated follicle. Produces both estrogens and progesterone. Now examine the ovary model to re-identify the same structures on a model.

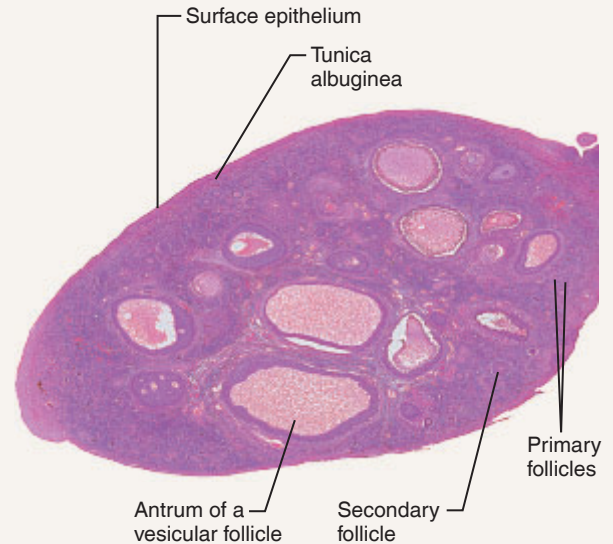


Figure 27.8 Photomicrograph of a mammalian ovary showing follicles in different developmental phases (2.5 \times). (See also Plates 19, 20, and 49 in the Histology Atlas.)

This page intentionally left blank

EXERCISE
27

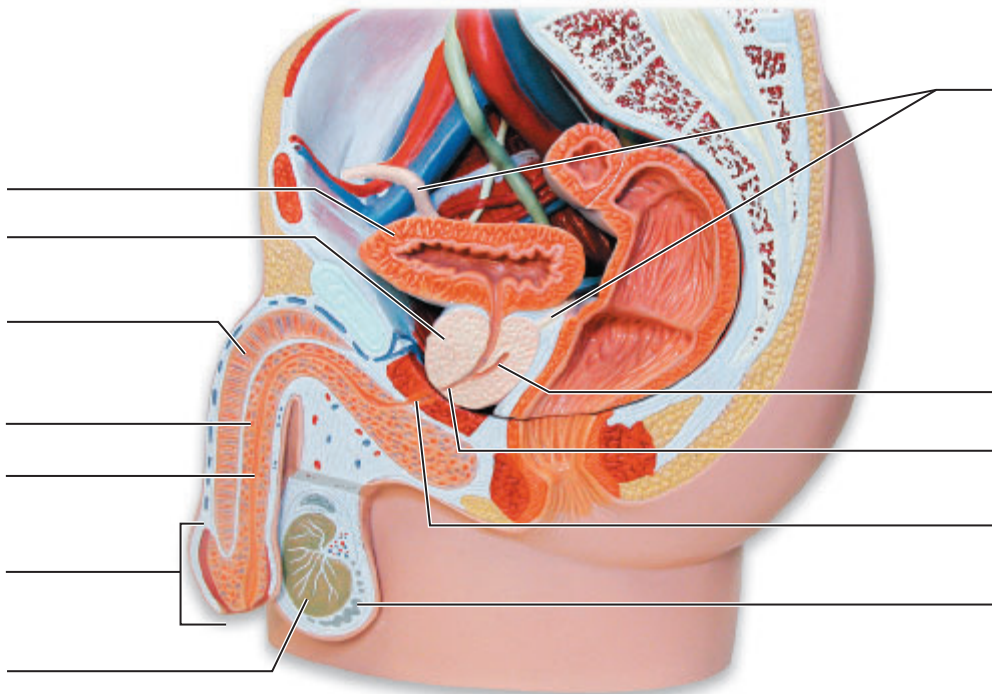
REVIEW SHEET

Anatomy of the Reproductive System

Name _____ Lab Time/Date _____

Anatomy of the Human Male Reproductive System

1. List the two main functions of the testis: _____
2. Identify all indicated structures or portions of structures on the photo of the model of the male reproductive system below.



3. How might enlargement of the prostate gland interfere with urination or a man's reproductive ability?

4. Why are the testes located in the scrotum rather than inside the ventral body cavity? _____

5. Match the terms in column B to the descriptive statements in column A.

Column A	Column B
_____ 1. copulatory organ/penetrating device	bulbo-urethral gland
_____ 2. produces sperm	ductus deferens
_____ 3. duct conveying sperm to the ejaculatory duct; in the spermatic cord	epididymis
_____ 4. distal urethra that transports urine and semen	intermediate part of the urethra
_____ 5. sperm maturation site	penis
_____ 6. location of the testis in adult males	prepuce
_____ 7. hoods the glans penis	scrotum
_____ 8. portion of the urethra that is located in the urogenital diaphragm	seminal gland
_____ 9. accessory gland that secretes fluid to cleanse the urethra prior to ejaculation	spongy urethra
_____ 10. accessory gland that secretes the largest contribution to semen	testis

6. Name the male structure that is homologous to the female structures named below.

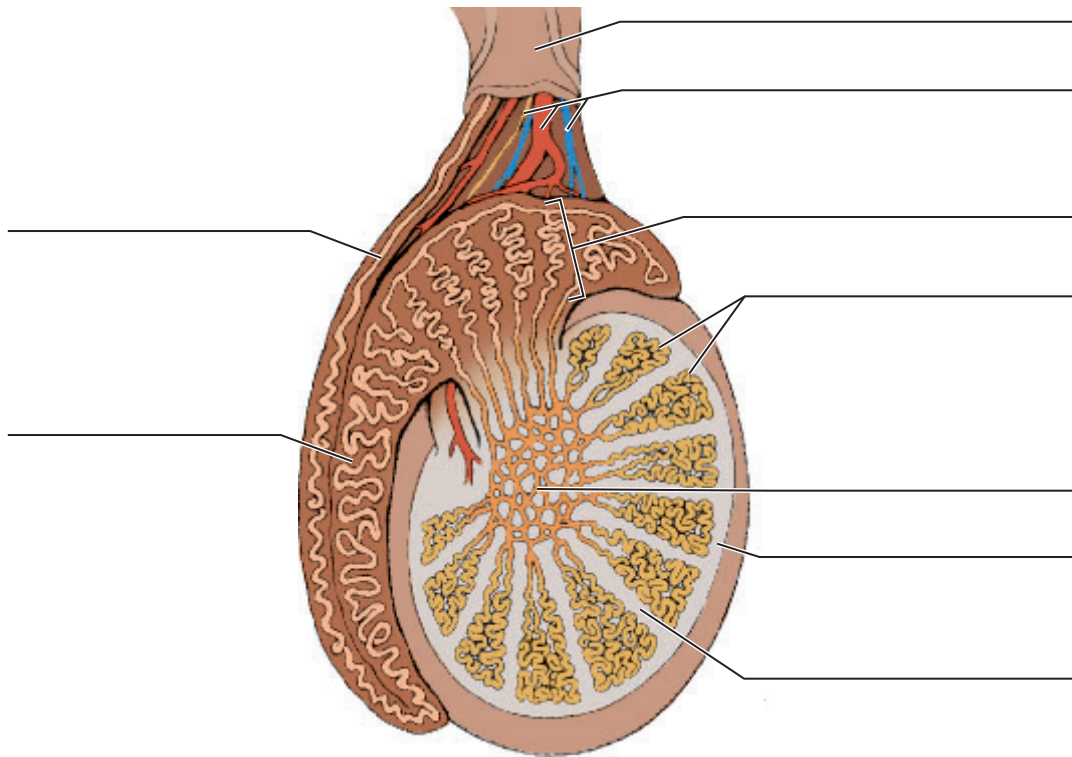
labia majora _____ clitoris _____ ovaries _____

7. Describe the composition of semen, and name all structures contributing to its formation. _____

8. Using the following terms, trace the pathway of sperm from the testes to the urethra: rete testis, epididymis, seminiferous tubule, ductus deferens.

9. The testis is divided into a number of lobes by connective tissue. Each of these lobes contains one to four _____
 _____, which converge on a tubular region called _____
 _____.

10. On the diagram showing the sagittal section of the human testis, correctly identify all structures provided with leader lines.



Anatomy of the Human Female Reproductive System

11. Name the structures composing the external genitalia, or vulva, of the female. _____

12. Identify the female reproductive system structures described below:

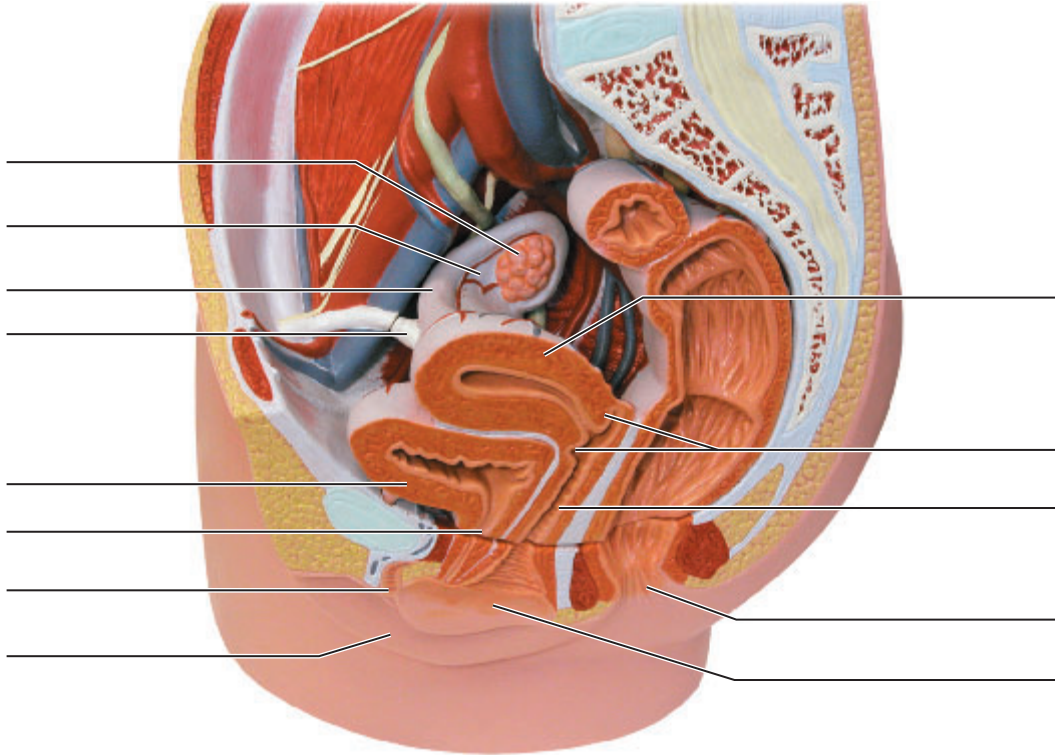
- _____ 1. site of fetal development
- _____ 2. copulatory canal
- _____ 3. winglike structure that holds the uterine tubes and uterus in place
- _____ 4. becomes erect during sexual excitement
- _____ 5. glands homologous to the bulbo-urethral glands of the male
- _____ 6. produces eggs, estrogens, and progesterone
- _____ 7. fingerlike ends of the uterine tube

13. Put the following vestibular-perineal structures in their proper order from the anterior to the posterior aspect: vaginal orifice, anus, urethral opening, and clitoris.

14. Assume a couple has just consummated the sex act and the male's sperm have been deposited in the woman's vagina. Trace the pathway of the sperm to the site of possible fertilization. (*Hint: fertilization occurs in the uterine tube.*)

15. Define *ovulation*: _____

16. On the photo of the model of the female reproductive system below, identify all indicated structures.



17. How are primary and vesicular follicles anatomically different? _____

18. **+** Cryptorchidism is failure of the testes to descend. Explain why this would cause sterility if not corrected.

19. **+** Hysterectomy is a surgical removal of the uterus. It may or may not be accompanied by a salpingo-oophorectomy, removal of the uterine tubes and ovaries. Why would it be an advantage to leave the ovaries intact? _____

Histology Atlas

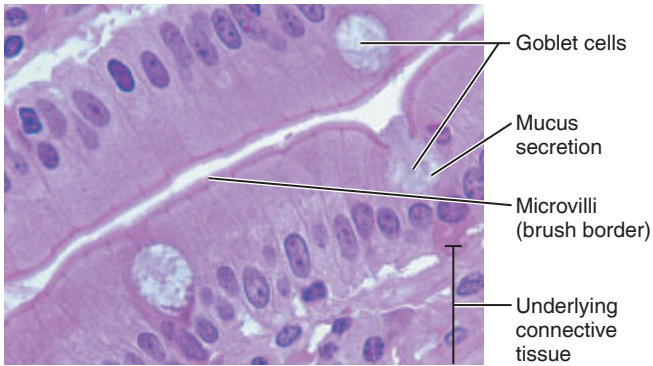


PLATE 1 Simple columnar epithelium containing goblet cells, which are secreting mucus (430 \times). (Exercise 5, page 40)

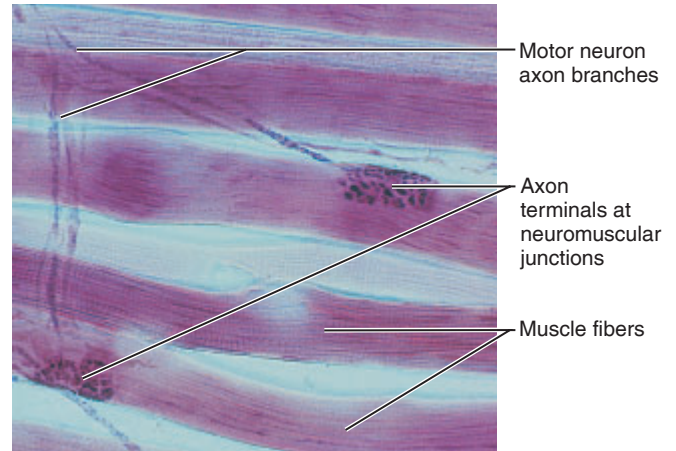


PLATE 4 Part of a motor unit, neuromuscular junctions (740 \times). (Exercise 11, page 126)

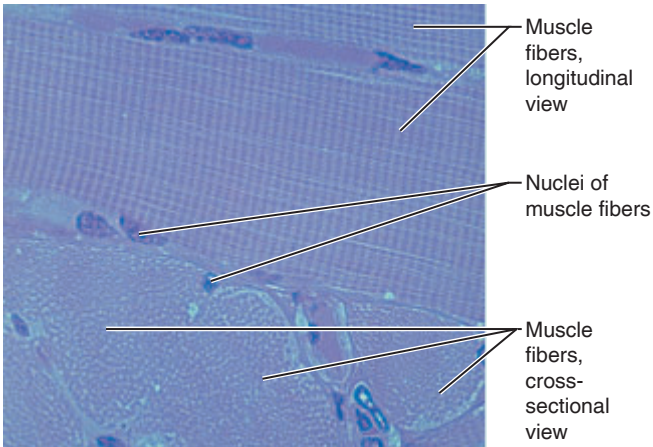


PLATE 2 Skeletal muscle, cross section and longitudinal views shown (480 \times). (Exercise 5, page 47; Exercise 11, page 123)

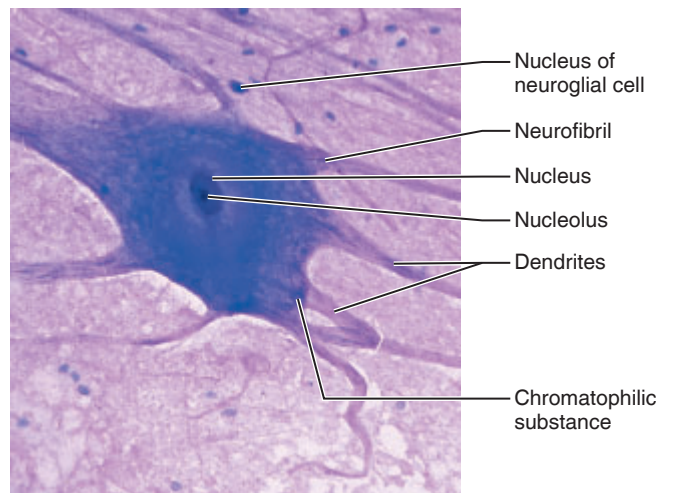


PLATE 5 Light micrograph of a multipolar neuron (450 \times). (Exercise 5, page 49; Exercise 13, page 153)

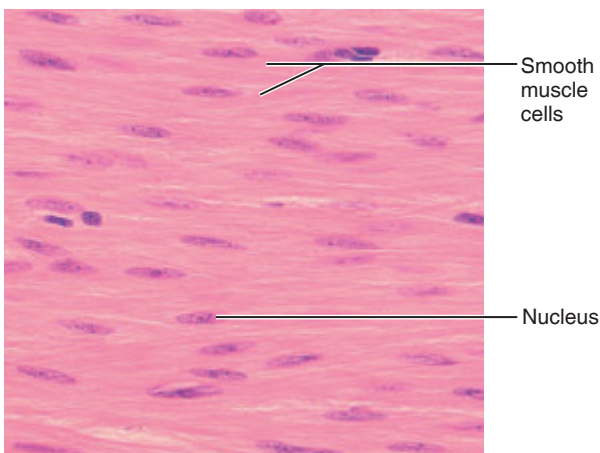


PLATE 3 Smooth muscle (330 \times). (Exercise 5, page 47)




PLATE 6 Silver-stained Purkinje cells of the cerebellum (65 \times). (Exercise 13, page 154)

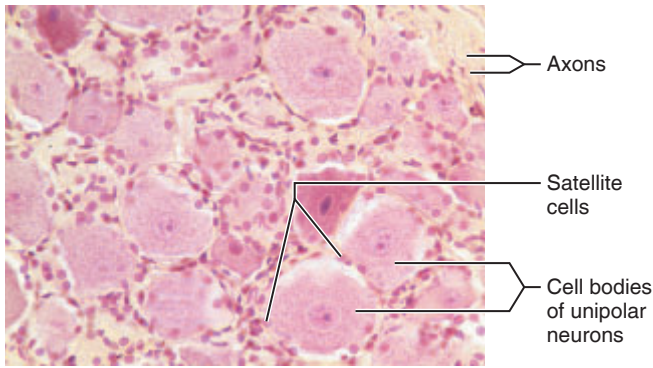


PLATE 7 Dorsal root ganglion displaying neuron cell bodies and satellite cells (185×). (Exercise 13, page 154)

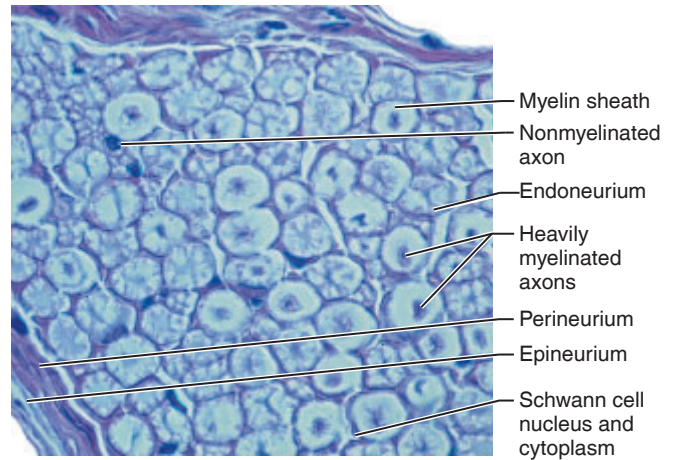


PLATE 10 Cross section of a portion of a peripheral nerve (510×). Heavily myelinated fibers are identified by a centrally located axon surrounded by an unstained ring of myelin. (Exercise 13, page 157)

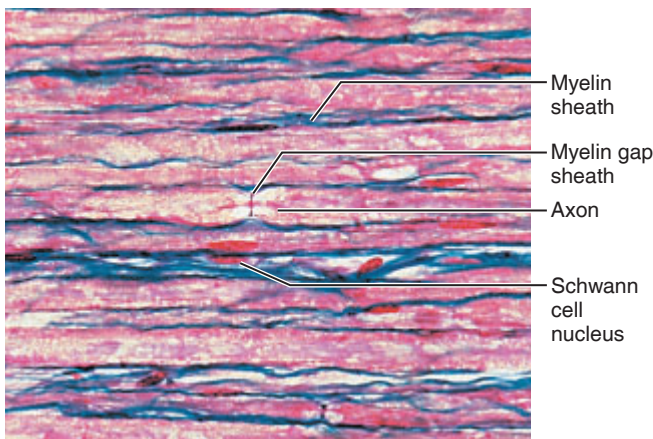


PLATE 8 A small portion of a peripheral nerve in longitudinal section (300×). (Exercise 13, page 153)

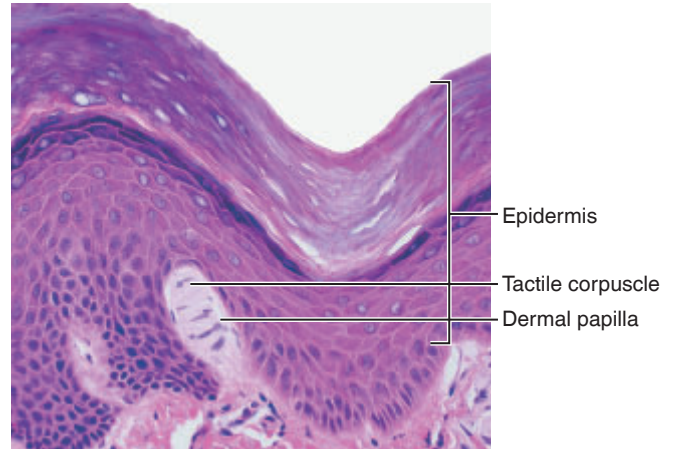


PLATE 11 Tactile corpuscle in a dermal papilla (400×). (Exercise 6, page 58)

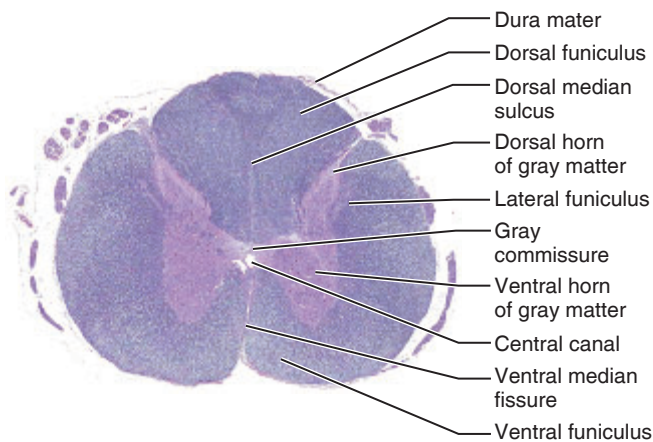


PLATE 9 Cross section of an adult spinal cord (4×). (Exercise 15, page 182)

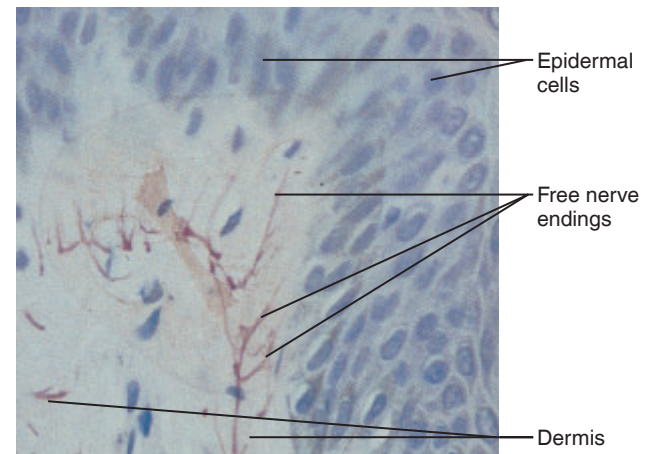


PLATE 12 Free nerve endings at dermal-epidermal junction (430×). (Exercise 6, page 58)

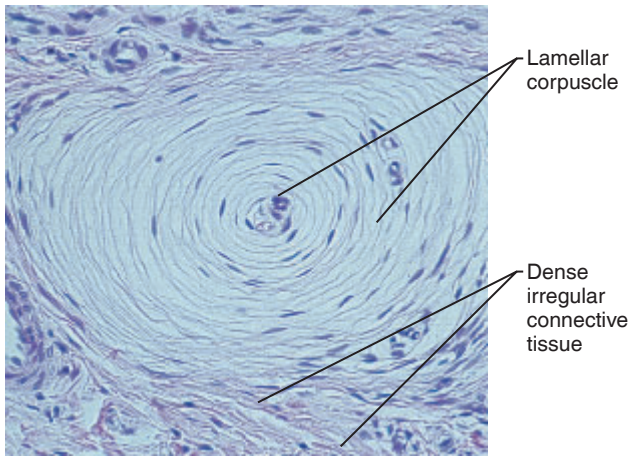


PLATE 13 Cross section of a lamellar corpuscle in the dermis (120×). (Exercise 6, page 58)

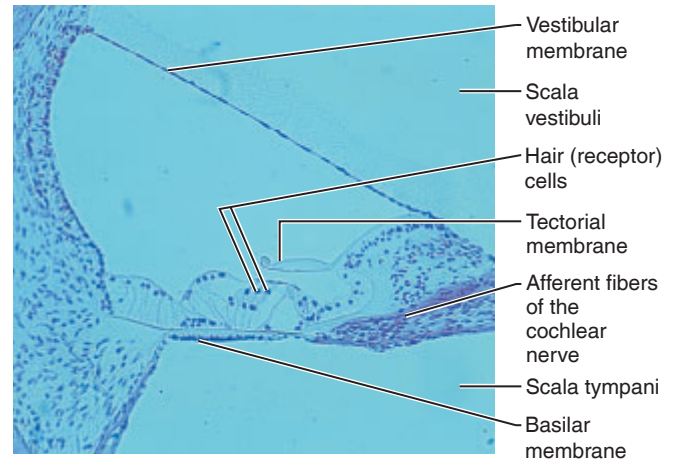


PLATE 16 The spiral organ (160×). (Exercise 17, page 205)

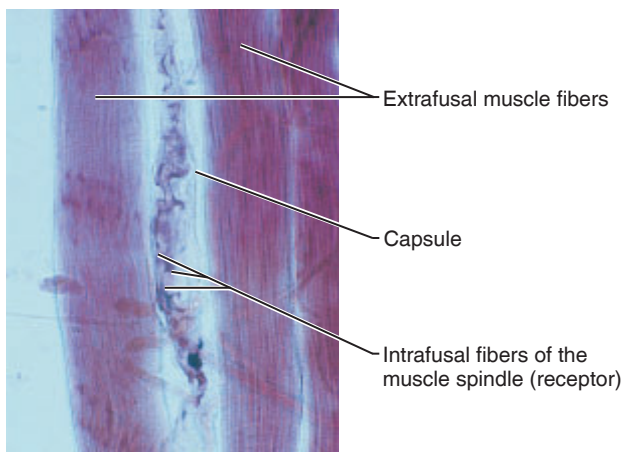


PLATE 14 Longitudinal section of a muscle spindle (80×).

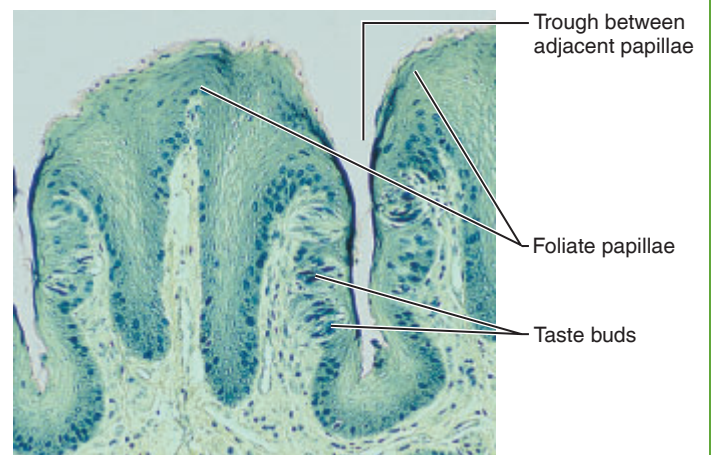


PLATE 17 Location of taste buds on lateral aspects of foliate papillae of tongue (105×). (Exercise 17, page 210)

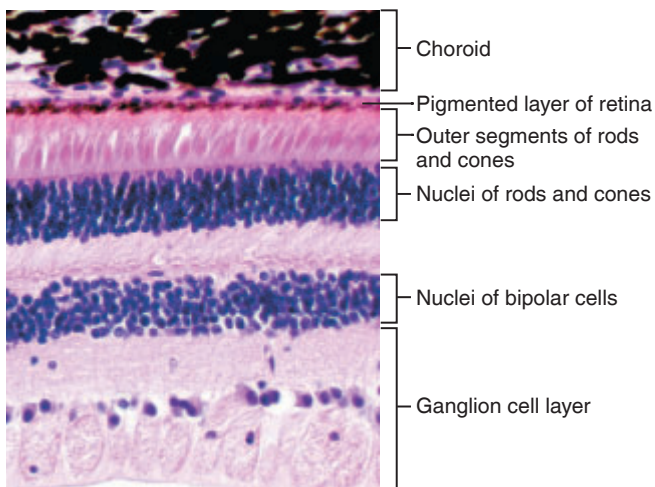


PLATE 15 Structure of the retina of the eye (140×). (Exercise 17, page 197)

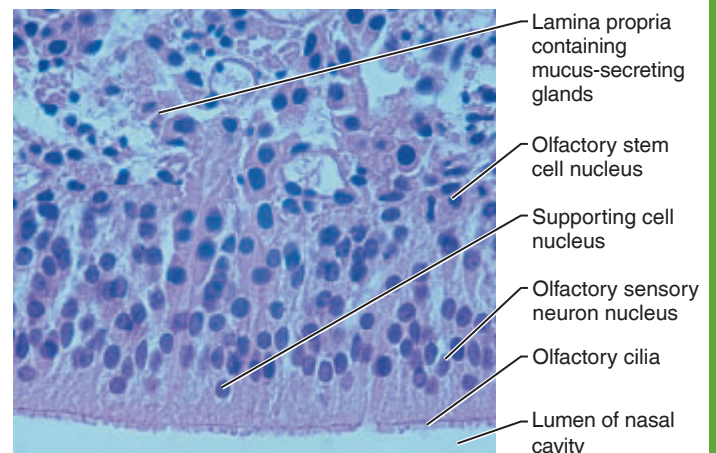


PLATE 18 Olfactory epithelium. From lamina propria to nasal cavity, the general arrangement of cells in this pseudostratified epithelium: olfactory stem cells, olfactory sensory neurons, and supporting cells (260×). (Exercise 17, page 209)

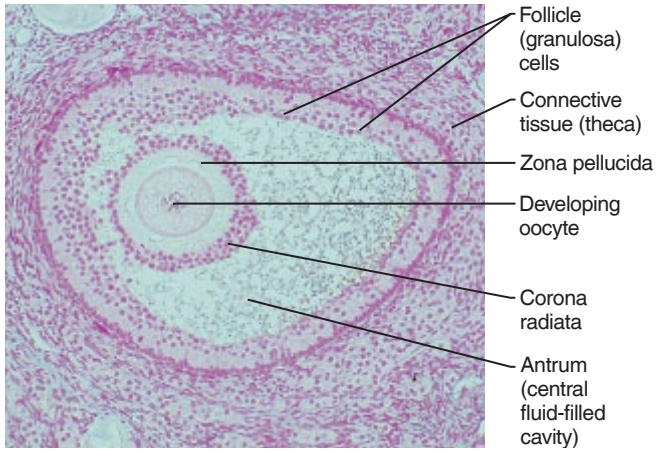


PLATE 19 Vesicular (antral) follicle of an ovary (100×). (Exercise 27, page 349)

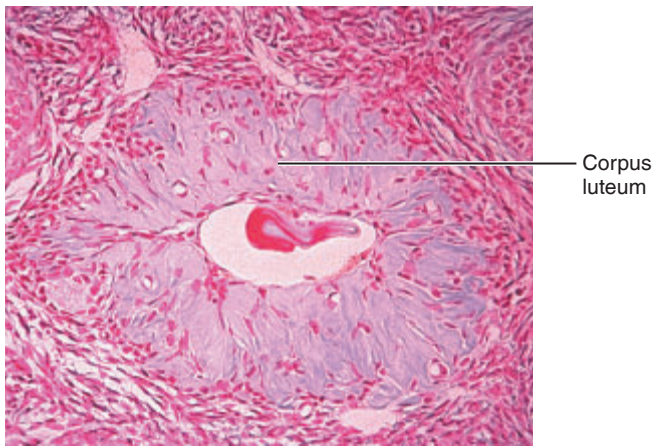


PLATE 20 Glandular corpus luteum of an ovary (90×). (Exercise 27, page 349)

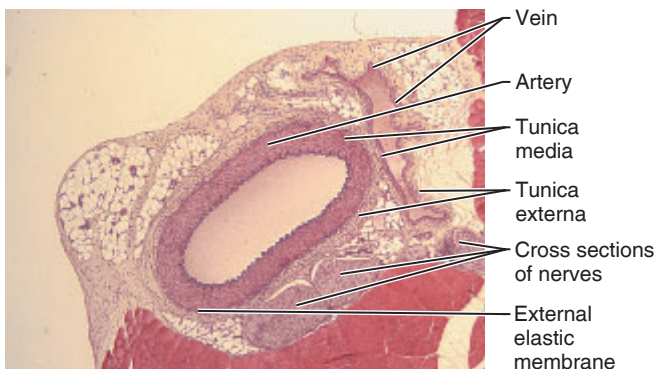


PLATE 21 Cross-sectional view of an artery, a vein, and nerves (25×). (Exercise 21, page 259)

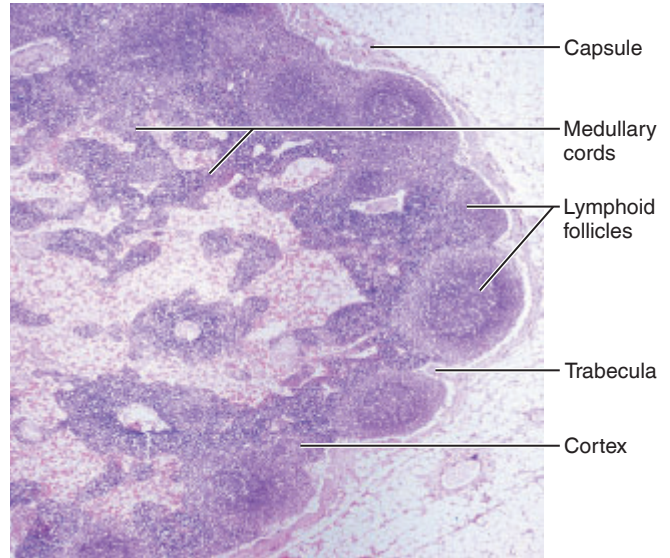


PLATE 22 Main structural features of a lymph node (40×).

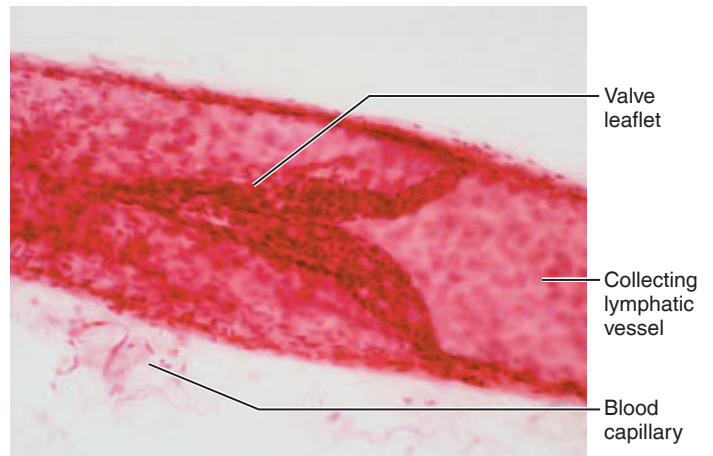


PLATE 23 Collecting lymphatic vessel (700×).

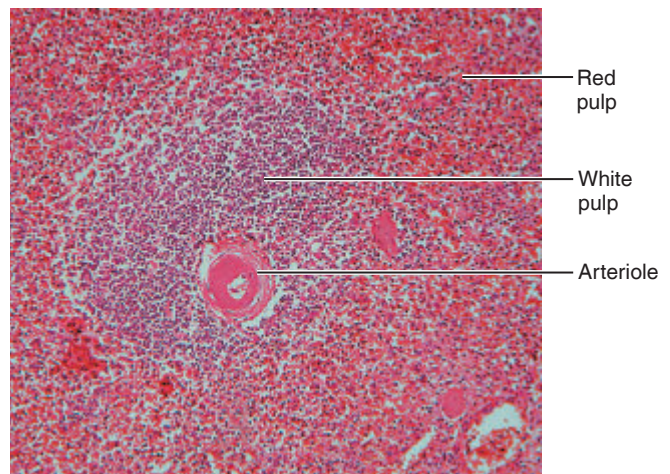


PLATE 24 Microscopic portion of spleen showing red and white pulp regions (80×).

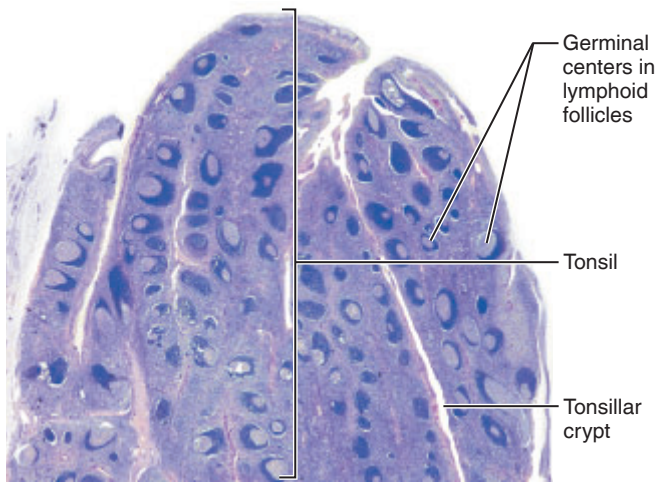


PLATE 25 Palatine tonsil. The exterior surface of the tonsil is covered by stratified squamous epithelium, which invaginates deeply to form tonsillar crypts (12 \times). (Exercise 25, page 314)

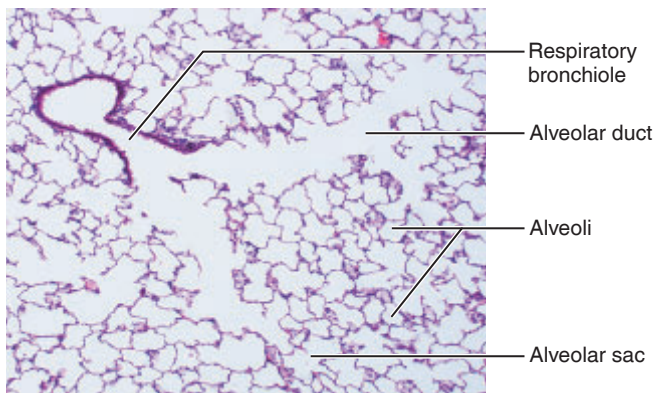


PLATE 26 Part of the lung showing alveoli and alveolar ducts and sacs (50 \times). (Exercise 23, page 296)

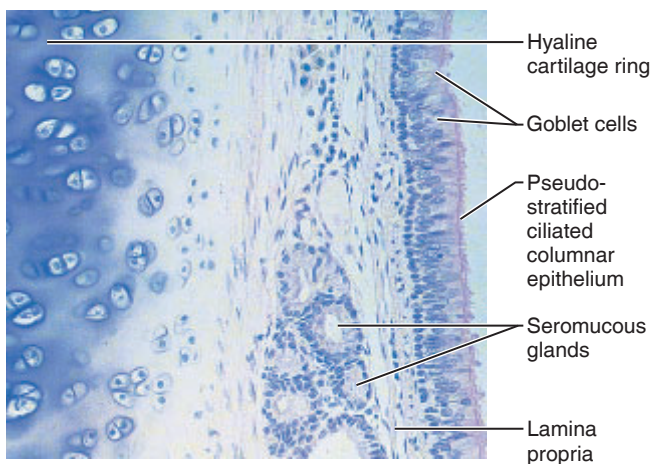


PLATE 27 Cross section through the trachea showing the pseudostratified ciliated epithelium, glands, and part of the supporting ring of hyaline cartilage (140 \times). (Exercise 23, page 296)

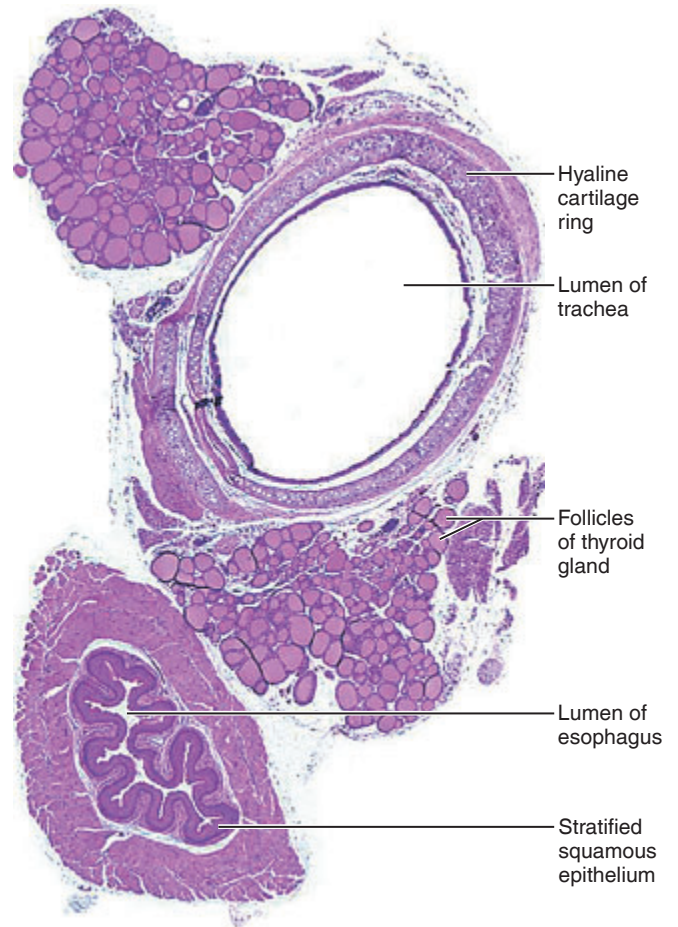


PLATE 28 Cross section through trachea and esophagus (1.5 \times). (Exercise 23, page 296)

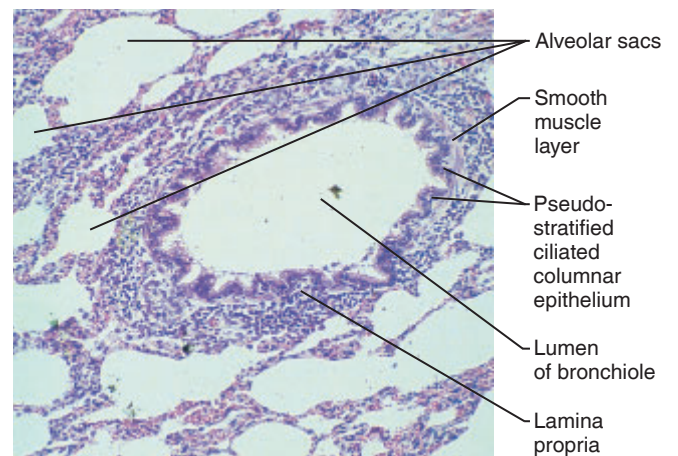


PLATE 29 Bronchiole, cross-sectional view (75 \times).

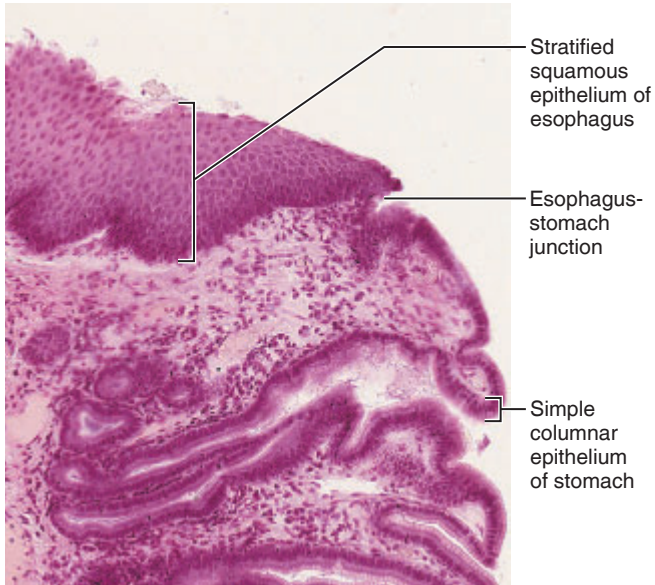


PLATE 30 Esophagus-stomach junction showing simple columnar epithelium of stomach meeting stratified squamous epithelium of esophagus (130 \times).

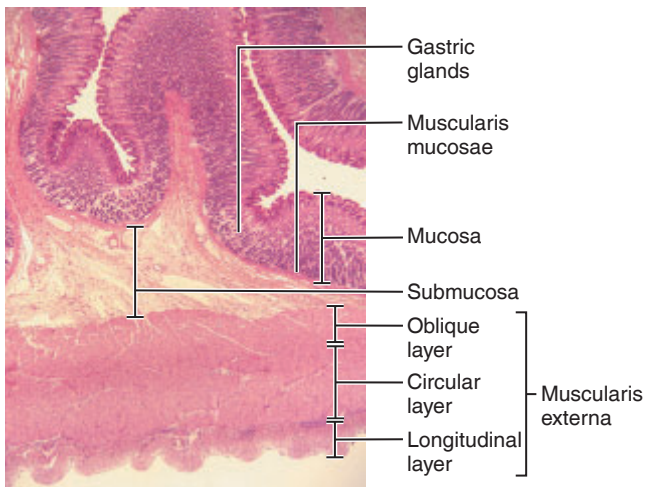


PLATE 31 Stomach. Longitudinal view (18 \times). (Exercise 25, page 316)

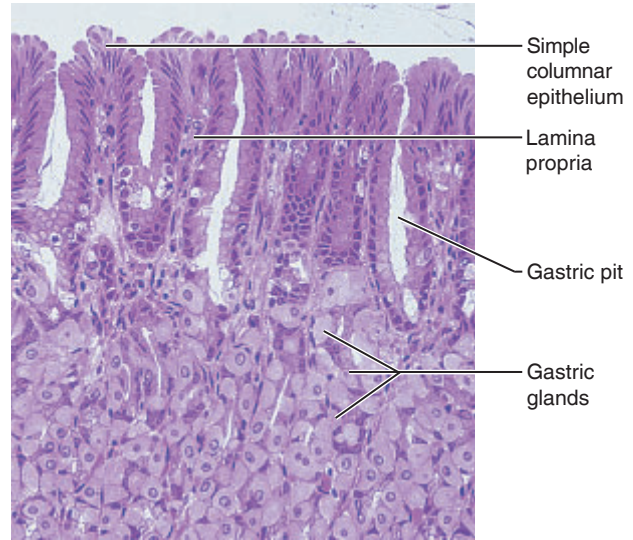


PLATE 32 Detailed structure of gastric glands and pits (150 \times). (Exercise 25, page 316)

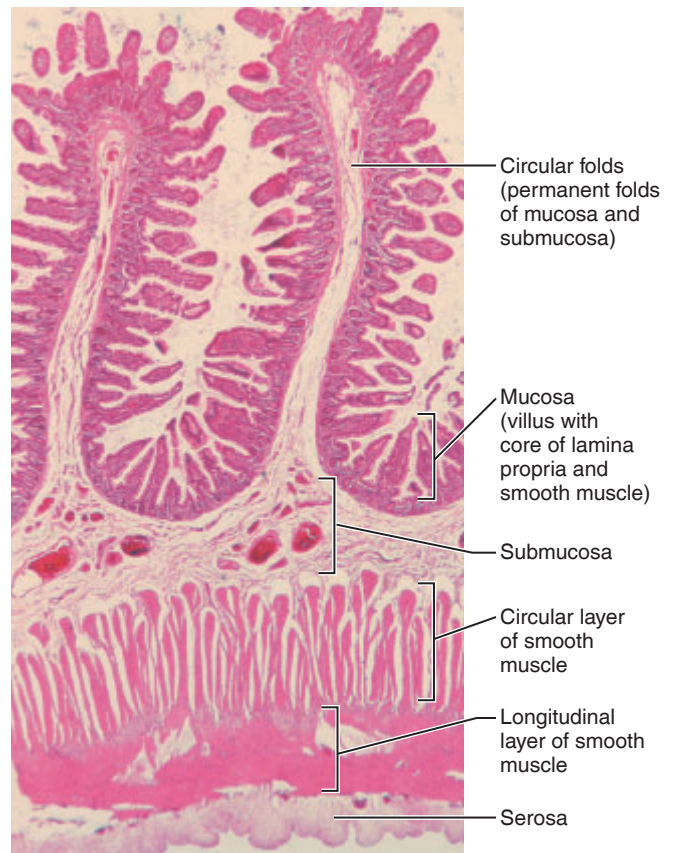


PLATE 33 Cross-sectional view of the duodenum of the small intestine (35 \times). (Exercise 25, page 314)

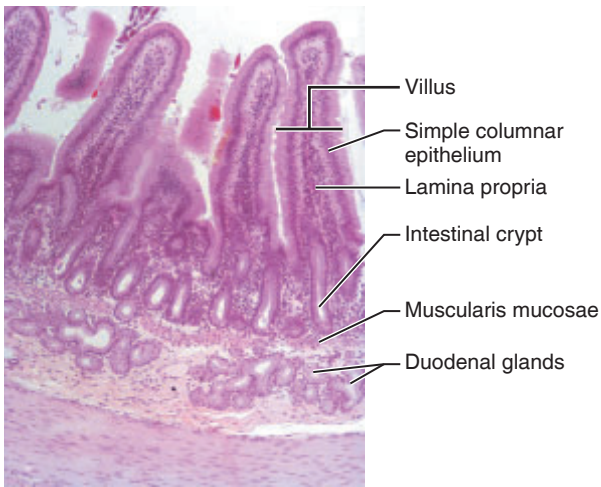


PLATE 34 Cross-sectional view of duodenum showing villi and duodenal glands (55×).

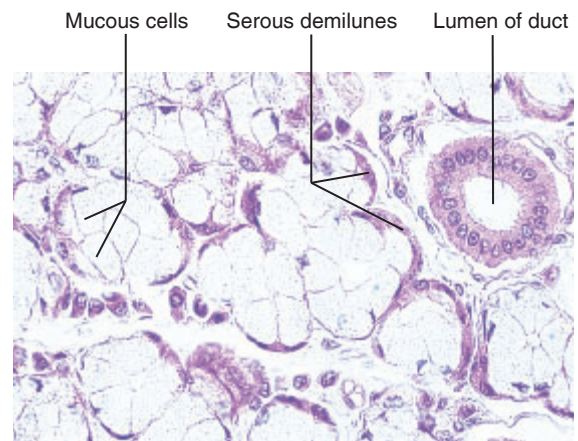


PLATE 37 Sublingual mixed salivary glands (170×). (Exercise 25, page 320)

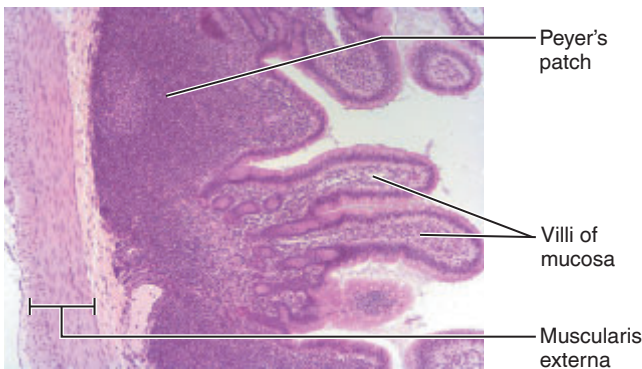


PLATE 35 Cross section through ileum, showing Peyer's patches (50×). (Exercise 25, page 317)

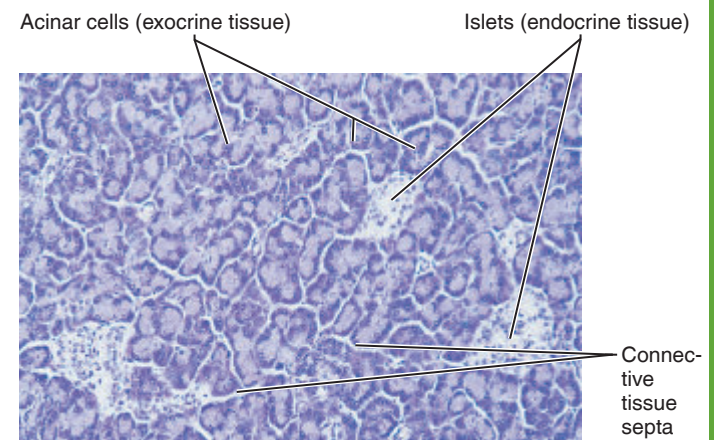


PLATE 38 Pancreas tissue. Exocrine and endocrine (islets) areas clearly visible (90×). (Exercise 18, page 225; Exercise 25, page 320)

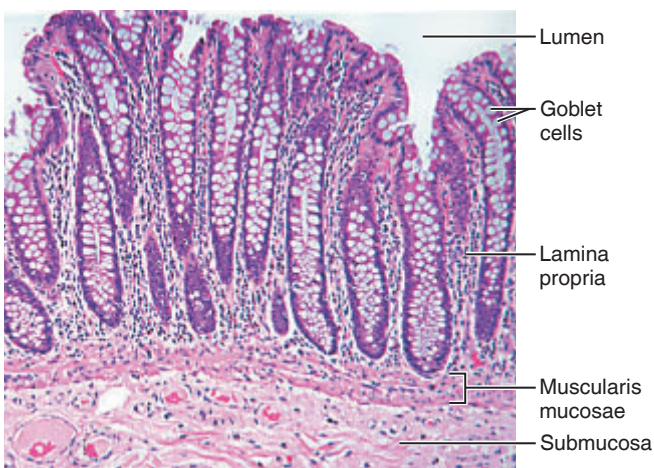

PLATE 36 Large intestine. Cross-sectional view showing the abundant goblet cells of the mucosa (75×).

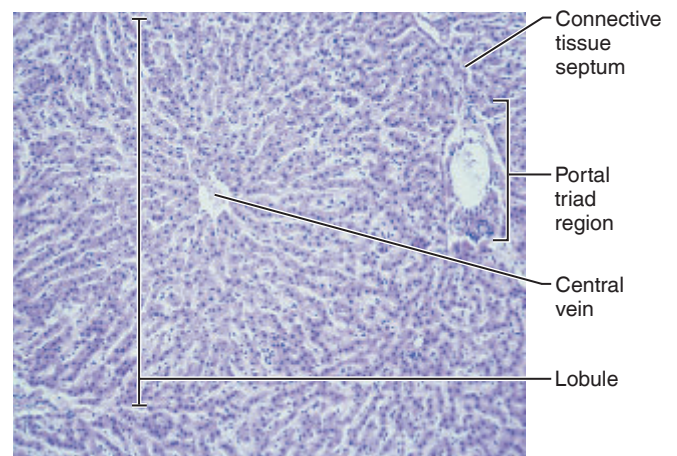


PLATE 39 Pig liver. Structure of a liver lobule (65×). (Exercise 25, page 320)

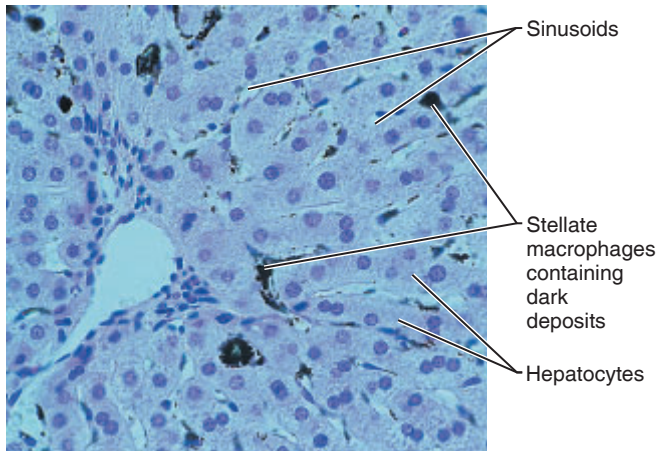


PLATE 40 Liver stained to show location of phagocytic cells (Stellate macrophages) lining sinusoids (280×).

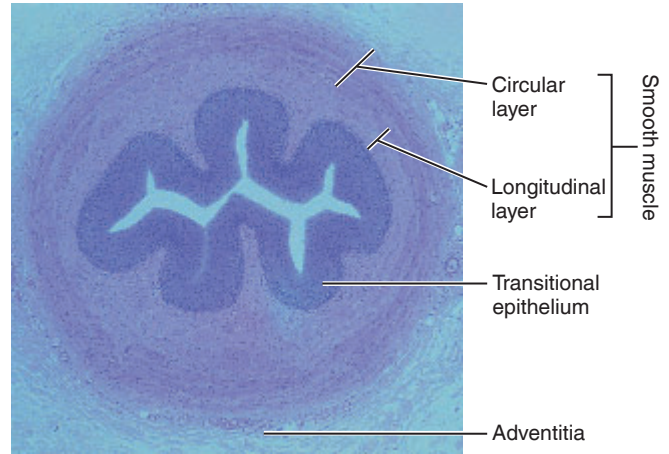


PLATE 43 Cross section of ureter (40×).

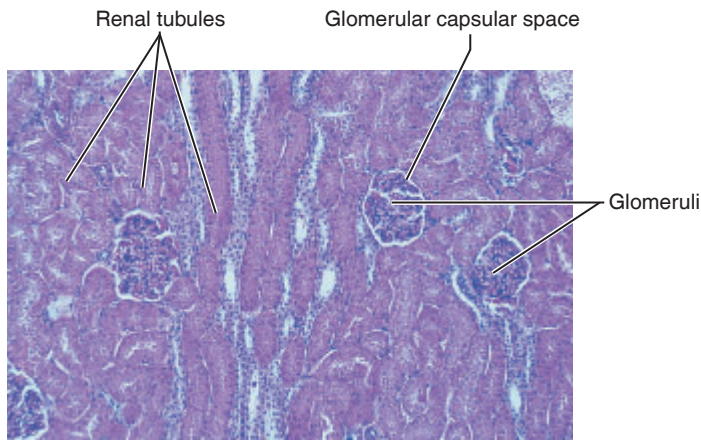


PLATE 41 Renal cortex (60×). (Exercise 26, page 336)

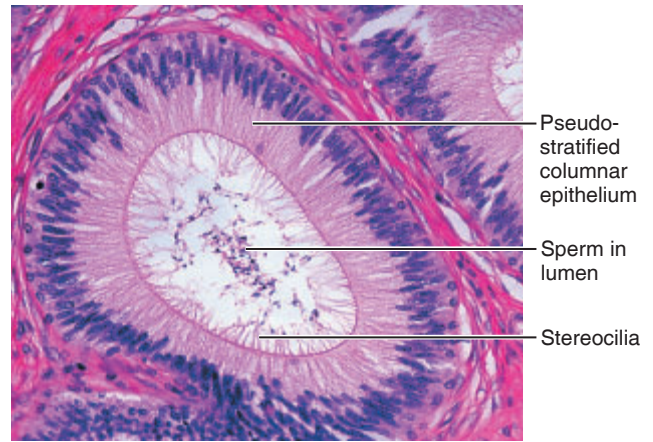


PLATE 44 Cross section of epididymis (165×). Stereocilia of the epithelial lining are obvious. (Exercise 27, page 345)

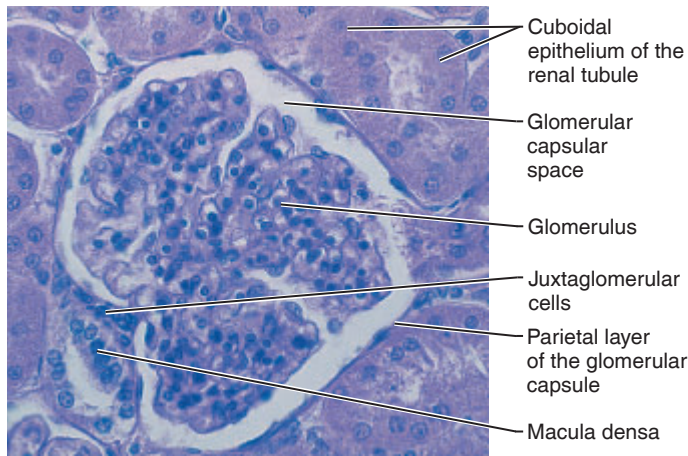


PLATE 42 Detailed structure of a glomerulus (260×).

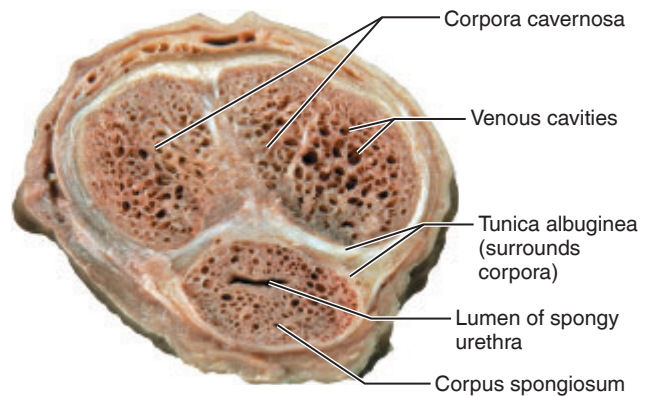


PLATE 45 Penis, transverse section (2×).

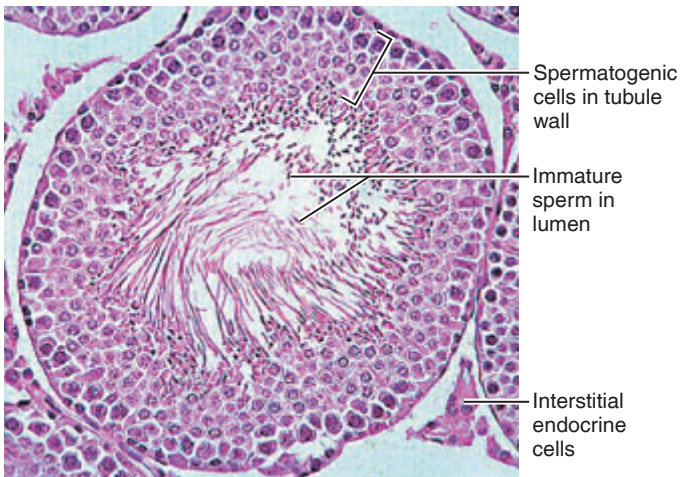


PLATE 46 Cross section of a portion of a seminiferous tubule (220×). (Exercise 27, page 345)

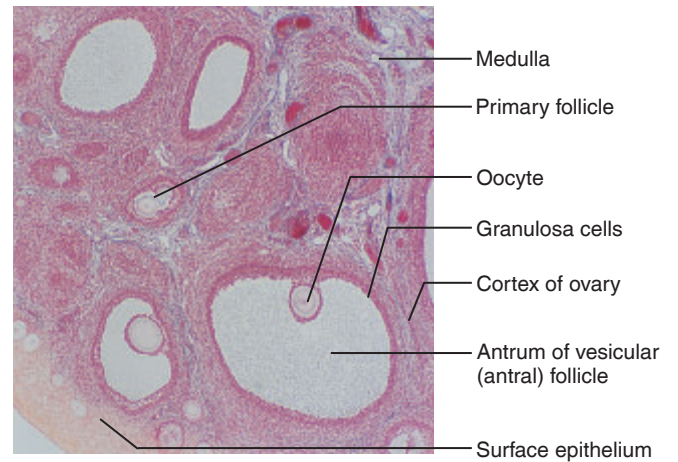


PLATE 49 The ovary, showing its follicles in various stages of development (25×). (Exercise 27, page 349)

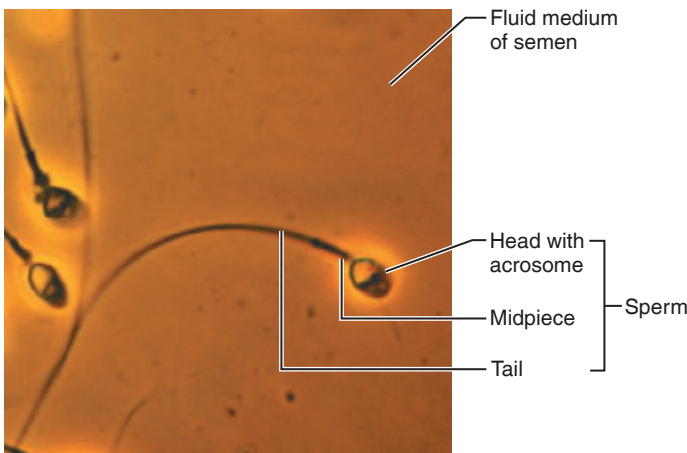


PLATE 47 Semen, the product of ejaculation, consisting of sperm and fluids secreted by the accessory glands, particularly the prostate and seminal vesicles (1950×). (Exercise 27, page 345)

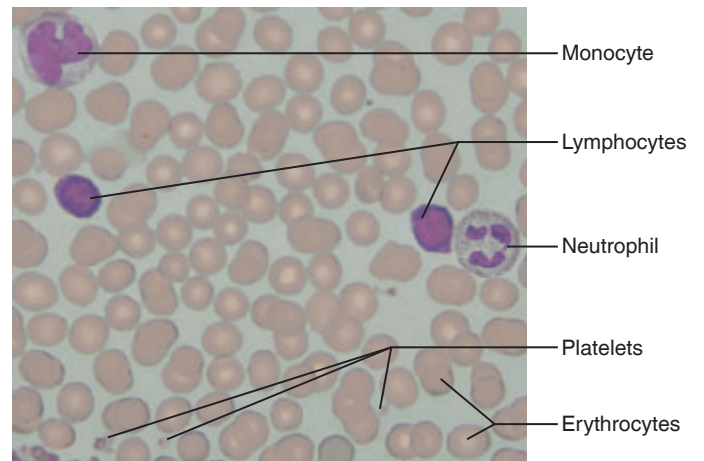


PLATE 50 Human blood smear (630×). (Exercise 19, page 232)

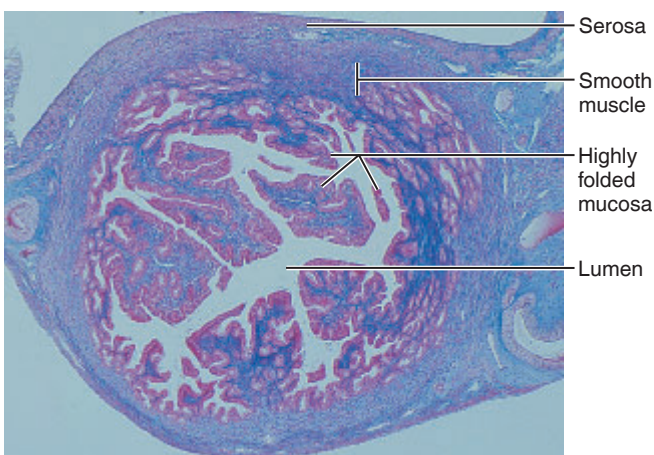


PLATE 48 Cross-sectional view of the uterine tube (12×).

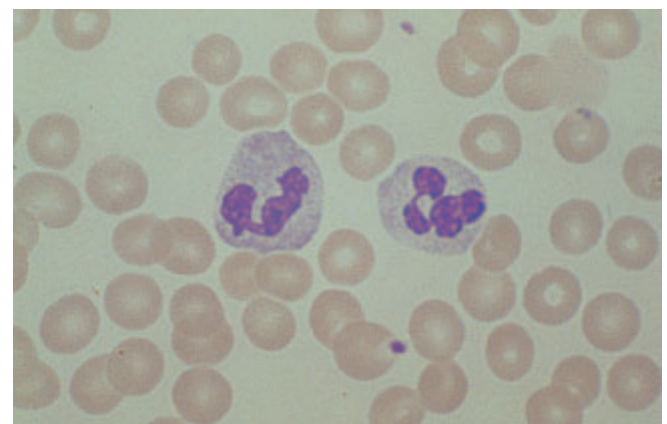


PLATE 51 Two neutrophils surrounded by erythrocytes (1100×). (Exercise 19, page 232)

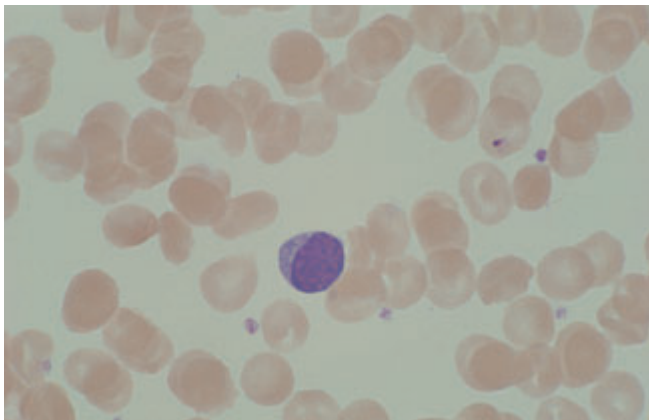


PLATE 52 Lymphocyte surrounded by erythrocytes (1040 \times). (Exercise 19, page 233)

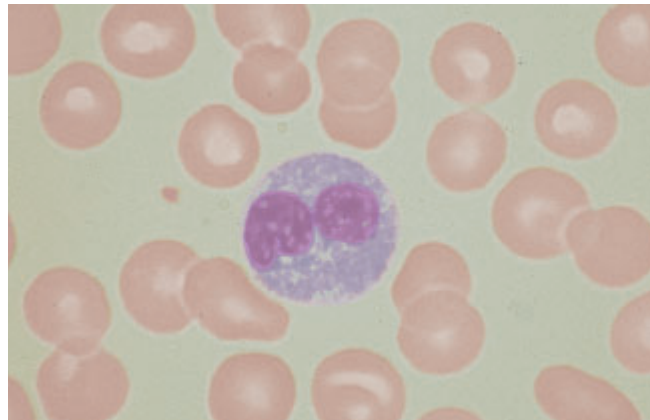


PLATE 54 An eosinophil surrounded by erythrocytes (1540 \times). (Exercise 19, page 232)

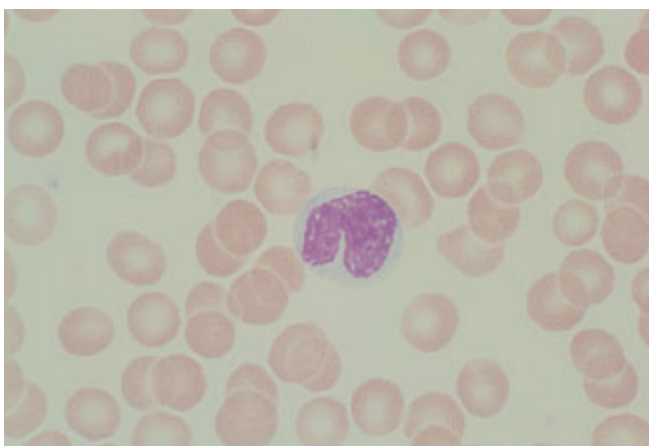


PLATE 53 Monocyte surrounded by erythrocytes (1060 \times). (Exercise 19, page 233)

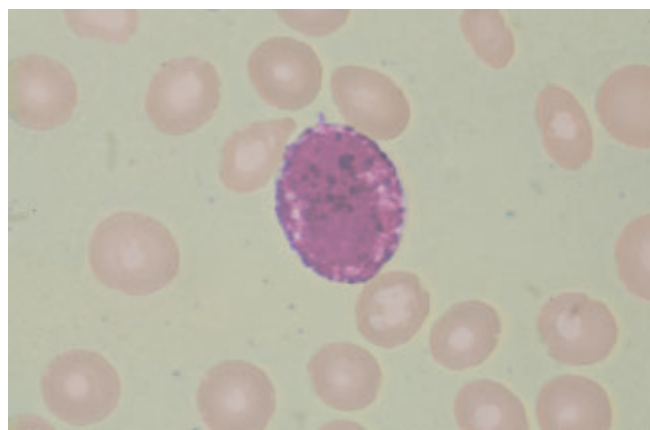


PLATE 55 A basophil surrounded by erythrocytes (1330 \times). (Exercise 19, page 232)

The Microscope

Materials

- Compound microscope
- Millimeter ruler
- Prepared slides of the letter *e* or newsprint
- Immersion oil in a dropper bottle
- Lens paper
- Prepared slide of grid ruled in millimeters (grid slide)
- Prepared slide of three colored crossed threads
- Clean microscope slide and coverslip
- Toothpicks (flat-tipped)
- Physiological saline in a dropper bottle
- Methylene blue stain (dilute) in a dropper bottle
- Filter paper
- Forceps
- Beaker containing fresh 10% household bleach solution for wet mount disposal
- Disposable autoclave bag

Note to the Instructor: The slides and coverslips used for viewing cheek cells are to be soaked for 2 hours (or longer) in 10% bleach solution and then drained. The slides, coverslips, and disposable autoclave bag (containing used toothpicks) are to be autoclaved for 15 min at 121°C and 15 pounds pressure to ensure sterility. After autoclaving, the disposable autoclave bag may be discarded in any disposal facility and the glassware washed with laboratory detergent and reprepared for use. These instructions apply as well to any bloodstained glassware or disposable items used in other experimental procedures.

Learning Outcomes

- Identify the parts of the microscope, and list the function of each.
- Describe and demonstrate the proper techniques for care of the microscope.
- Define *total magnification* and *resolution*.
- Demonstrate proper focusing technique.
- Define *parfocal*, *field diameter*, and *depth of field*.
- Estimate the size of objects in a field.

With the invention of the microscope, biologists gained a valuable tool to observe and study structures, such as cells, that are too small to be seen by the unaided eye. As a result, many of the theories basic to the understanding of biological sciences have been established. This exercise will familiarize you with the workhorse of microscopes—the compound microscope—and provide you with the necessary instructions for its proper use.

Care and Structure of the Compound Microscope

The **compound microscope** is a precision instrument and should always be handled with care. *At all times you must observe the following rules for its transport, cleaning, use, and storage:*

- When transporting the microscope, hold it in an upright position, with one hand on its arm and the other supporting its base. Avoid jarring the instrument when setting it down.
- Use only special grit-free lens paper to clean the lenses. Clean all lenses before and after use.
- Always begin the focusing process with the scanning objective lens in position, changing to the higher-power lenses as necessary.
- Never use the coarse adjustment knob with the high-power or oil immersion lenses.
- Always use a coverslip with temporary (wet mount) preparations.
- Before putting the microscope in the storage cabinet, remove the slide from the stage, rotate the scanning objective lens into position, and replace the dust cover.
- Never remove any parts from the microscope; inform your instructor of any mechanical problems that arise.

Activity

Identifying the Parts of a Microscope

1. Using the proper transport technique, obtain a microscope and bring it to the laboratory bench.

- Record the number of your microscope in the **Microscope Summary Chart** (page 368).

Compare your microscope with **Figure A.1**, and identify the microscope parts described in **Table A.1**.

2. Examine the objectives carefully; note their relative lengths and the numbers inscribed on their sides. On most microscopes, the **scanning** objective lens is the shortest and typically has a magnification of 4 \times . The low-power objective lens typically has a magnification of 10 \times . The high-power objective lens is of intermediate length and has a magnification range from 40 \times to 50 \times , depending on the microscope. The oil immersion objective lens is

usually the longest of the objectives and has a magnifying power of 95 \times to 100 \times . Note that some microscopes lack the oil immersion lens.

- Record the magnification of each objective lens of your microscope in the first row of the Microscope Summary Chart. Also, cross out any column relating to a lens that your microscope does not have.

3. Rotate the scanning objective until it clicks into position, and turn the coarse adjustment knob about 180 degrees. Notice how far the stage (or objective) travels during this adjustment. Move the fine adjustment knob 180 degrees, noting again the distance that the stage (or the objective) moves.

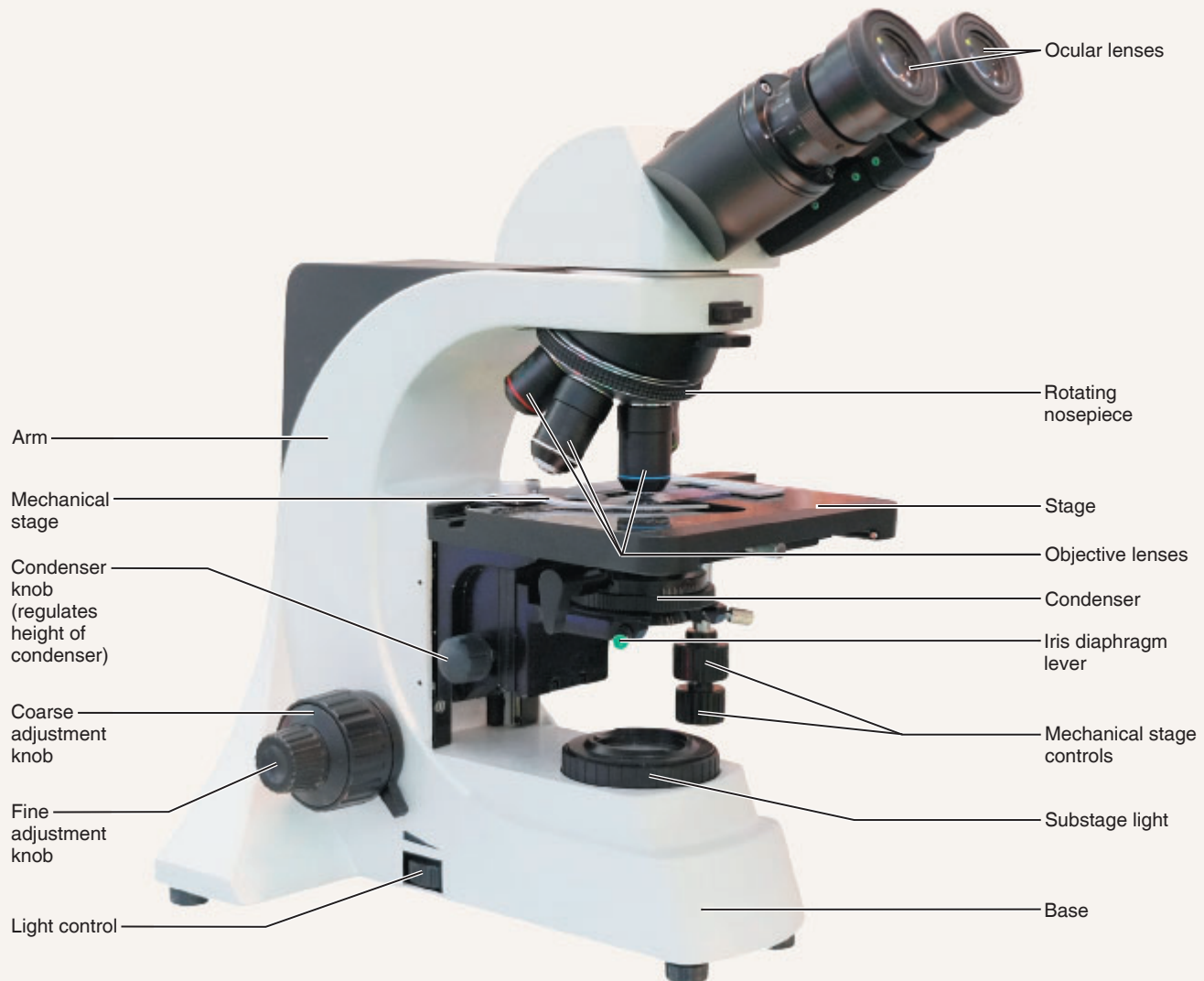


Figure A.1 Compound microscope and its parts.

Table A.1 Parts of the Microscope

Microscope part	Description and function
Base	The bottom of the microscope. Provides a sturdy flat surface to support and steady the microscope.
Substage light	Located in the base. The light from the lamp passes directly upward through the microscope.
Light control	Located on the base or arm. This dial allows you to adjust the intensity of the light passing through the specimen.
Stage	The platform that the slide rests on while being viewed. The stage has a hole in it to allow light to pass through the stage and through the specimen.
Mechanical stage	Holds the slide in position for viewing and has two adjustable knobs that control the precise movement of the slide.
Condenser	Small nonmagnifying lens located beneath the stage that concentrates the light on the specimen. The condenser may have a knob that raises and lowers the condenser to vary the light delivery. Generally, the best position is close to the inferior surface of the stage.
Iris diaphragm lever	The iris diaphragm is a shutter within the condenser that can be controlled by a lever to adjust the amount of light passing through the condenser. The lever can be moved to close the diaphragm and improve contrast. If your field of view is too dark, you can open the diaphragm to let in more light.
Coarse adjustment knob	This knob allows you to make large adjustments to the height of the stage to initially focus your specimen.
Fine adjustment knob	This knob is used for precise focusing once the initial coarse focusing has been completed.
Head	Attaches to the nosepiece to support the objective lens system. It also provides for attachment of the eyepieces which house the ocular lenses.
Arm	Vertical portion of the microscope that connects the base and the head.
Nosepiece	Rotating mechanism connected to the head. Generally, it carries three or four objective lenses and permits positioning of these lenses over the hole in the stage.
Objective lenses	These lenses are attached to the nosepiece. Usually, a compound microscope has four objective lenses: scanning (4 \times), low-power (10 \times), high-power (40 \times), and oil immersion (100 \times) lenses. Typical magnifying powers for the objectives are listed in parentheses.
Ocular lens(es)	Binocular microscopes will have two lenses located in the eyepieces at the superior end of the head. Most ocular lenses have a magnification power of 10 \times . Some microscopes will have a pointer and/or reticle (micrometer), which can be positioned by rotating the ocular lens.

Magnification and Resolution

The microscope is an instrument of magnification. In the compound microscope, magnification is achieved through the interplay of two lenses—the ocular lens and the objective lens. The objective lens magnifies the specimen to produce a **real image** that is projected to the ocular. This real image is magnified by the ocular lens to produce the **virtual image** that your eye sees (**Figure A.2**).

The **total magnification** of any specimen being viewed is equal to the power of the ocular lens multiplied by the power of the objective lens used. For example, if the ocular lens magnifies 10 \times and the objective lens being used magnifies 45 \times , the total magnification is 450 \times (10 \times 45).

Activity

Determining Total Magnification

Determine the total magnification for each of the objectives on your microscope, and record the figures on the second row of the Microscope Summary Chart.

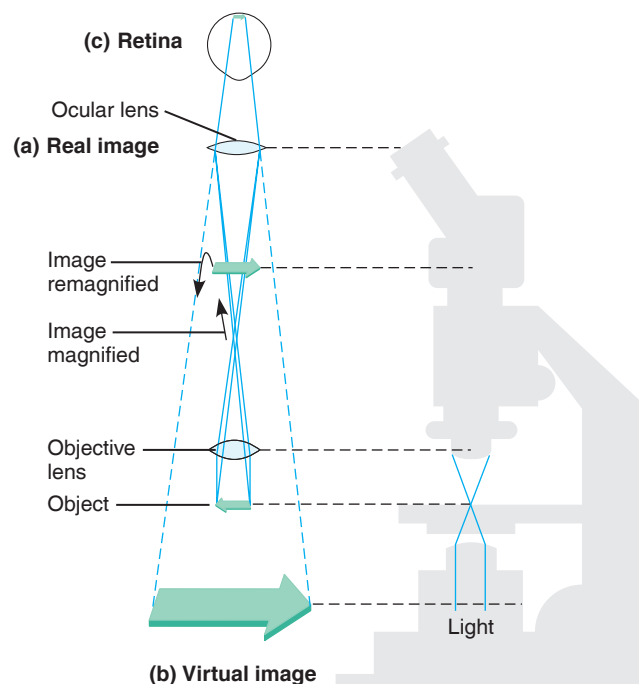


Figure A.2 Image formation in light microscopy. (a) Light passing through the objective lens forms a real image. (b) The real image serves as the object for the ocular lens, which remagnifies the image and forms the virtual image. (c) The virtual image passes through the lens of the eye and is focused on the retina.

Microscope Summary Chart

	Microscope # _____		Magnification of Ocular Lens _____ ×	
	Scanning	Low power	High power	Oil immersion
Magnification of objective lens	×	×	×	×
Total magnification	×	×	×	×
Detail observed				
Field diameter	mm μm	mm μm	mm μm	mm μm
Working distance	mm	mm	mm	mm


The compound light microscope has certain limitations. Although the level of magnification is almost limitless, the **resolution** (or resolving power), the ability to discriminate two close objects as separate, is not. The human eye can resolve objects about 100 μm apart, but the compound microscope has a resolution of 0.2 μm under ideal conditions. Objects closer than 0.2 μm are seen as a single fused image.

Resolution is determined by the amount and physical properties of the visible light that enters the microscope. In general, the more light delivered to the objective lens, the greater the resolution. The size of the objective lens aperture (opening) decreases with increasing magnification, allowing less light to enter the objective. Thus, you will probably find it necessary to increase the light intensity at the higher magnifications.

Activity

Viewing Objects Through the Microscope

1. Obtain a millimeter ruler, a prepared slide of the letter *e* or newsprint, a dropper bottle of immersion oil, and some lens paper. Adjust the condenser to its highest position, and switch on the light source of your microscope.
2. Secure the slide on the stage so that the letter *e* is centered over the light beam passing through the stage. On the mechanical stage of your microscope, open the jaws of its slide retainer (holder) by using the control lever, typically located at the rear left corner of the mechanical stage. Insert the slide squarely within the confines of the slide retainer.
3. With your scanning objective in position over the stage, use the coarse adjustment knob to bring the objective and stage as close together as possible.
4. Look through the ocular lens, and adjust the light for comfort. Now use the coarse adjustment knob to focus slowly away from the *e* until it is as clearly focused as possible. Complete the focusing with the fine adjustment knob.
5. Sketch the letter in the circle just as it appears in the **field**—the area you see through the microscope.



What is the total magnification? _____ ×

How far is the bottom of the objective lens from the surface of the slide? In other words, what is the **working distance**? Hold a millimeter ruler vertically to make this measurement, and record it here and in the summary chart.

_____ mm

How has the apparent orientation of the *e* changed in terms of top to bottom, right to left, and so on?

6. Move the slide slowly away from you on the stage as you view it through the ocular. In what direction does the image move?

Move the slide to the left. In what direction does the image move?

7. Today most good laboratory microscopes are **parfocal**; that is, the slide should be in focus (or nearly so) at the higher magnifications once you have properly focused in 1.p. If you are unable to swing the objective into position without raising the objective, your microscope is not parfocal. Consult your instructor. Without touching the focusing knobs, increase the magnification by rotating the next

higher magnification lens (low-power or high-power) into position over the stage. Make sure it clicks into position. Using the fine adjustment only, sharpen the focus. What new details become clear?

What is the total magnification now? _____ ×

As best you can, measure the distance between the objective and the slide (the working distance), and record it on the chart.

Why should you *not* use the coarse focusing knob when focusing with the higher-powered objective lenses?

Is the image larger or smaller? _____

Approximately how much of the letter *e* is visible now?

Is the field diameter larger or smaller? _____

Why is it necessary to center your object (or the portion of the slide you wish to view) before changing to a higher power?

Move the iris diaphragm lever while observing the field. What happens?

Is it more desirable to increase *or* decrease the light when changing to a higher magnification?

_____ Why? _____

8. If you have just been using the low-power objective, repeat the steps given in direction 7 using the high-power objective lens. Record the total magnification, approximate

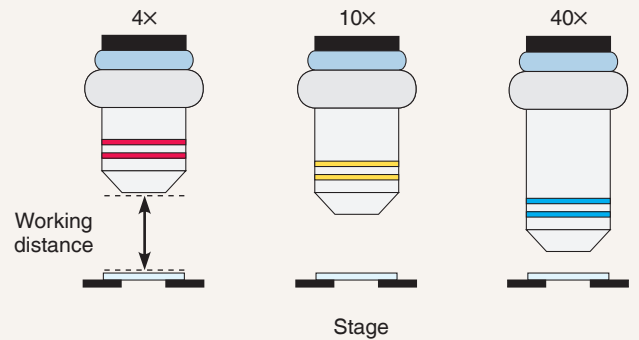


Figure A.3 Relative working distances of the 4×, 10×, and 40× objectives.

working distance, and information on detail observed on the Microscope Summary Chart (page 368).

9. Without touching the focusing knob, rotate the high-power lens out of position so that the area of the slide over the opening in the stage is unobstructed. Place a drop of immersion oil over the *e* on the slide and rotate the oil immersion lens into position. Set the condenser at its highest point (closest to the stage), and open the diaphragm fully. Adjust the fine focus and fine-tune the light for the best possible resolution.

Is the field diameter again decreased in size? _____

What is the total magnification with the oil immersion lens?

 ×

Is the working distance less *or* greater than it was when the high-power lens was focused?

Compare your observations on the relative working distances of the objective lenses with **Figure A.3**. Explain why it is desirable to begin the focusing process in low power.

10. Rotate the oil immersion lens slightly to the side, and remove the slide. Clean the oil immersion lens carefully with lens paper, and then clean the slide in the same manner with a fresh piece of lens paper.

Diameter of the Microscope Field

The microscope field decreases with increasing magnification. Measuring the diameter of each of the microscope fields will allow you to make a fairly accurate estimate of the size of the objects you view in any field. For example, if you have calculated the field diameter to be 4 mm and the object being

observed extends across half this diameter, you can estimate the length of the object to be approximately 2 mm.

Microscopic specimens are usually measured in micrometers and millimeters, both units of the metric system. You can get an idea of the relationship and meaning of these units from the **Comparing Metric Units of Length chart**. A more detailed treatment appears in the inside back cover.

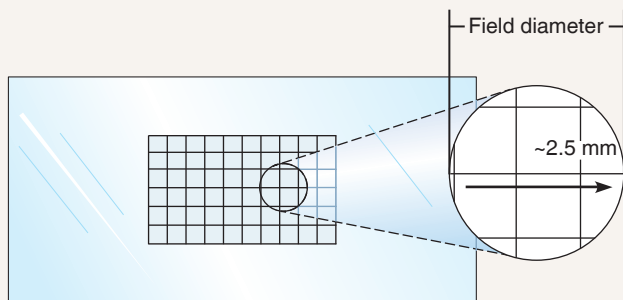
Comparing Metric Units of Length

Metric unit	Abbreviation	Equivalent
Meter	m	about 39.37 in.
Centimeter	cm	10^{-2} m
Millimeter	mm	10^{-3} m
Micrometer (or micron)	μm (μ)	10^{-6} m
Nanometer	nm ($\text{m}\mu$)	10^{-9} m

Activity

Determining the Diameter of the Microscope Field

- Return the letter *e* slide to the supplies area, and obtain a grid slide (a slide prepared with graph paper ruled in millimeters). Each of the squares in the grid is 1 mm on each side. Use your scanning objective to bring the grid lines into focus.
- Move the slide so that one grid line touches the edge of the field on one side, and then count the number of squares you can see across the diameter of the field. If you can see only part of a square, as in the accompanying diagram, estimate the part of a millimeter that the partial square represents.



For future reference, record this figure in the appropriate space marked "field diameter" on the Microscope Summary Chart (page 368). (If you have been using the scanning lens, repeat the procedure with the low-power objective lens.) Complete the chart by computing the

approximate diameter of the high-power and immersion fields. Say the diameter of the low-power field (total magnification of $50\times$) is 2 mm. You would compute the diameter of a high-power field with a total magnification of $100\times$ as follows:

$$2 \text{ mm} \times 50 = Y(\text{diameter of h.p. field}) \times 100$$

$$100 \text{ mm} = 100Y$$

$$1 \text{ mm} = Y(\text{diameter of the h.p. field})$$

The formula is:

Diameter of the l.p. field (mm) \times total magnification of the l.p. field = diameter of field $Y \times$ total magnification of field Y

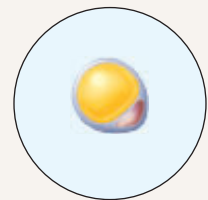
- Estimate the length (longest dimension) of the following drawings of microscopic objects. *Base your calculations on the field diameters you have determined for your microscope.* The first one is done for you.

Fat cell seen in $400\times$ (total magnification, TM) field:

Field diameter = 0.4 mm = 400 μm

Portion of the field diameter occupied by the object = $1/3$

Approximate length = 133 μm

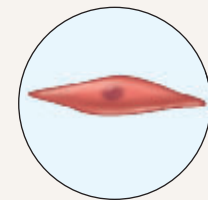


Smooth muscle cell seen in $400\times$ (TM) field:

approximate length:

_____ mm

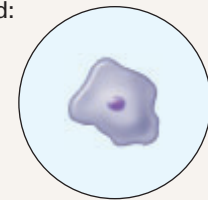
or _____ μm



Cheek cell seen in oil immersion field:

approximate length:

_____ μm



Perceiving Depth

Any microscopic specimen has depth as well as length and width; it is rare indeed to view a tissue slide with just one layer of cells. Normally you can see two or three cell thicknesses. Therefore, it is important to learn how to determine

relative depth with your microscope. In microscope work, the **depth of field** (the depth of the specimen clearly in focus) is greater at lower magnifications.

Activity

Perceiving Depth

- Return the grid slide, and obtain a slide with colored crossed threads. Focusing at low magnification, locate the point where the three threads cross each other.

- Use the iris diaphragm lever to greatly reduce the light, thus increasing the contrast. Focus down with the coarse adjustment until the threads are out of focus, then slowly

focus upward again, noting which thread comes into clear focus first. This one is the lowest, or most inferior, thread. (You will see two or even all three threads, so you must be very careful in determining which one comes into clear focus first.) Record your observations:

_____ thread over _____

Continue to focus upward until the uppermost thread is clearly focused. Again record your observation.

_____ thread over _____

Which thread is uppermost? _____

Lowest? _____


Activity

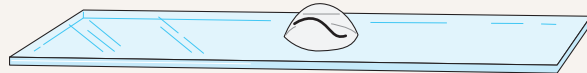Preparing and Observing a Wet Mount

1. Obtain the following: a clean microscope slide and coverslip, a flat-tipped toothpick, a dropper bottle of physiological saline, a dropper bottle of methylene blue stain, forceps, and filter paper.

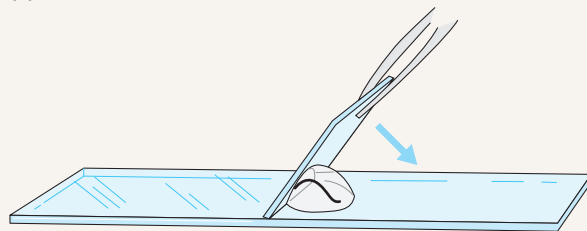
2. Place a drop of physiological saline in the center of the slide. Using the flat end of the toothpick, *gently* scrape the inner lining of your cheek. Agitate the end of the toothpick containing the cheek scrapings in the drop of saline (**Figure A.4a**).

3. Add a tiny drop of the methylene blue stain to the preparation. (These epithelial cells are nearly transparent and thus difficult to see without the stain, which colors the nuclei of the cells and makes them look much darker than the cytoplasm.) Stir again and then dispose of the toothpick as described below.

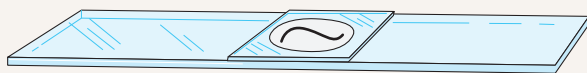
 *Immediately* discard the used toothpick in the disposable autoclave bag provided at the supplies area.



(a)



(b)




(c)

Figure A.4 Procedure for preparing a wet mount. (a) Place the object in a drop of water (or saline) on a clean slide, (b) hold a coverslip at a 45° angle with forceps, and (c) lower the coverslip slowly.

4. As shown in Figure A.4b, hold the coverslip with the forceps so that its bottom edge touches one side of the fluid drop, then *slowly* lower the coverslip onto the preparation (Figure A.4c). *Do not just drop the coverslip*, or you will trap large air bubbles under it, which will obscure the cells. *Always use a coverslip with a wet mount* to prevent soiling the lens if you should misfocus.

5. Examine your preparation carefully. The coverslip should be closely apposed to the slide. If there is excess fluid around its edges, you will need to remove it. Obtain a piece of filter paper, fold it in half, and use the folded edge to absorb the excess fluid.

 Before continuing, discard the filter paper in the disposable autoclave bag.

6. Place the slide on the stage and locate the cells in low power. You will probably want to dim the light with the iris diaphragm lever to provide more contrast for viewing the lightly stained cells.

7. Cheek epithelial cells are very thin, flat cells. In the cheek, they provide a smooth, tilelike lining (**Figure A.5**).

8. Make a sketch of the epithelial cells that you observe.

Approximately how wide are the cheek epithelial cells?

_____ mm

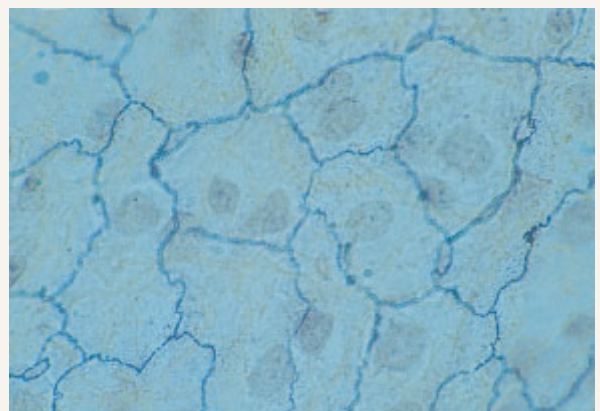


Figure A.5 Epithelial cells of the cheek cavity (surface view, 710×).

Why do *your* cheek cells look different from those in Figure A.5? (*Hint*: What did you have to *do* to your cheek to obtain them?)



9. When you complete your observations, dispose of your wet mount preparation in the beaker of bleach solution.

10. Before leaving the laboratory, make sure all other materials are properly discarded or returned to the appropriate laboratory station. Clean the microscope lenses, and put the dust cover on the microscope before you return it to the storage cabinet.

Credits

Photographs

Exercise 1 1.3, 1.7a: John Wilson White/Pearson Education, Inc.

Exercise 2 2.1-2.4: Elena Dorfman/Pearson Education, Inc.; 2.5: Arcady/Shutterstock.

Exercise 3 3.3, 3.RS.5: William Karkow/Pearson Education, Inc.

Exercise 4 4.1: Richard Megna/Fundamental Photographs.

Exercise 5 5.2a, d, 5.4b: William Karkow/Pearson Education, Inc.; 5.2b, c, f, 5.3c, h: Allen Bell/Pearson Education, Inc.; 5.2e, 5.3b, f, g, 5.4a: Nina Zanetti/Pearson Education, Inc.; 5.3a: PAL 3.0/Pearson Education, Inc.; 5.3d: Lisa Lee/Pearson Education, Inc.; 5.3e: Steve Downing/Pearson Education, Inc.; 5.4c, 5.5: Biophoto Associates/Science Source.

Exercise 6 6.1b: William Karkow/Pearson Education, Inc.; 6.3: PAL/Pearson Education, Inc. 6.RS.1: BSIP/UIG/Getty Images; 6.RS.2: 3B Scientific.

Exercise 7 7.3c: William Karkow/Pearson Education, Inc.; 7.RS.10: Pearson Education, Inc.

Exercise 8 8.RS.10a, 8.RS.16: PAL 3.0/Pearson Education, Inc.; 8.RS.10b: Larry DeLay/Pearson Education, Inc.

Exercise 9 9.T.4, 9.RS.1-3, 9.RS.8, 9.RS.11, 9.RS.12: PAL 3.0/Pearson Education, Inc.

Exercise 10 10.4, 10.RS.7: John Wilson White/Pearson Education, Inc.

Exercise 11 11.1a: Marian Rice; 11.3b: William Karkow/Pearson Education, Inc.; 11.RS.3: Don W. Fawcett/Science Source.

Exercise 12 12.3b: Karen Krabbenhoft/Pearson Education, Inc.; 12.RS.1: PAL 3.0/Pearson Education, Inc.

Exercise 13 13.1b: William Karkow/Pearson Education, Inc.; 13.2b: Don W. Fawcett/Science Source; 13.6b: Karen Krabbenhoft/PAL 3.0/Pearson Education, Inc.

Exercise 14 14.1b, 14.2, 14.3b, 14.RS.2: Karen Krabbenhoft/Pearson Education, Inc.; 14.4a: From A Stereoscopic Atlas of Human Anatomy, by David L. Bassett; 14.7b: Sharon Cummings/Pearson Education, Inc.; 14.8, 14.9: Elena Dorfman/Pearson Education, Inc.; 14.RS.5: 3B Scientific.

Exercise 16 16.3, 16.4, 16.5: Richard Tauber/Pearson Education, Inc.

Exercise 17 17.4b: From A Stereoscopic Atlas of Human Anatomy, by David L. Bassett; 17.5: Elena Dorfman/Pearson Education, Inc.; 17.11: Richard Tauber/Pearson Education, Inc.; 17.16c, 17.RS.21: PAL 3.0/Pearson Education, Inc.

Exercise 19 19.2, 19.3: Elena Dorfman/Pearson Education, Inc.; 19.5: Jack Scanlan/Pearson Education, Inc.; 19.RS.7: PAL 3.0/Pearson Education, Inc.; 19.RS.15: Jack Scanlan/Pearson Education, Inc.

Exercise 20 20.5: William Karkow/Pearson Education, Inc.; 20.6: Wally Cash/Pearson Education, Inc.; 20.RS.2: Steve Downing/Pearson Education, Inc.

Exercise 21 21.2, 21.RS.1: PAL 3.0/Pearson Education, Inc.; 21.RS.11: Ed Reschke/Photolibrary/Getty Images.

Exercise 23 23.4a: Richard Tauber/Pearson Education, Inc.; 23.4b: From A Stereoscopic Atlas of Human Anatomy, by

David L. Bassett; 23.RS.1, 23.RS.8: 3B Scientific.

Exercise 24 24.3: Elena Dorfman/Pearson Education, Inc.

Exercise 25 25.4b: Karen Krabbenhoft/Pearson Education, Inc.; 25.5a: From A Stereoscopic Atlas of Human Anatomy, by David L. Bassett.

Exercise 26 26.3a: Karen Krabbenhoft/PAL 3.0/Pearson Education, Inc.; 26.4d: Professor P.M. Motta & M. Castellucci/Science Source; 26.5: Victor Eroschenko/Pearson Education, Inc.; 26.RS.2: PAL 3.0/Pearson Education, Inc.

Exercise 27 27.3a: JUERGEN BERGER/Science Source; 27.8: Lisa Lee/Pearson Education, Inc.; 27.RS.3, 27.RS.16: Pearson Education, Inc.

Histology Atlas Plates 1, 6, 7, 28: Nina Zanetti/Pearson Education, Inc.; Plates 2, 4, 8-10, 12-14, 16-19, 21, 24, 27, 29, 31, 32-46, 48-53: Victor Eroschenko/Pearson Education, Inc.; Plates 3, 5, 26: William Karkow/Pearson Education, Inc.; Plates 11, 22: PAL 3.0/Pearson Education, Inc.; Plate 15: Lisa Lee/Pearson Education, Inc.; Plate 20: Marian Rice; Plate 23: Astrid & Hanns-Frieder Michler/Science Source; Plate 25: Biophoto Associates/Science Source; Plate 30: Pearson Education, Inc.; Plate 47: J. Walsh/Science Source; Plate 54: PH College. /Pearson Education, Inc.; Plate 55: James O. Ballard, M.D.

Appendix A.1: Vereshchagin Dmitry/Shutterstock; A.5: Victor Eroschenko/Pearson Education, Inc.

This page intentionally left blank

Index

NOTE: Page numbers in **boldface** indicate a definition. A *t* following a page number indicates tabular material and an *f* indicates an illustration.

- A (dark) bands, 121, 122*f*
Abdomen
 arteries, 260*f*, 262*t*, 263*f*
 muscles, 132*f*, 136*t*
 veins, 265*f*, 266, 266*f*, 267*f*
Abdominal aorta, **259**, 262, 262*t*, 263*f*
Abdominal cavity, **5**
 rat, 13–14*f*
Abdominal reflex, 191
Abdominal region, 1, 2*f*
Abdominopelvic cavity, **5–6**, 5*f*, **15**, 16*f*
 quadrants, **5–6**, 6*f*
 rat dissection, 12–15
 regions, 5–6
Abducens nerve (VI), 170*t*, 171*f*
Abduction (movement), **113**, 115*f*
ABO blood groups, 238, 238*t*, 239*f*
 typing of, 238–239
Absorption of foodstuffs, **311**, 313*t*,
 316–317
 flowchart, 321*f*
Accessory glands, male reproductive,
 344, 344*t*
Accessory nerve (XI), 170*t*, 171*f*
Accessory organs
 digestive, **311**, 312*f*, 318–320
 of skin, 59–62
Accommodation pupillary reflex,
 202–203
Accommodation, visual, **201**
 near point of, **201**
Acetabulum, **99**, 100*f*
 in females vs. males, 102*t*
Acetylcholine, 125, 125*f*
Achilles (calcaneal) tendon, 133*f*, 143*f*
 reflex, **191**
Acid hydrolases, 21*t*
Acinar cells (exocrine tissue), 361*f*
Acne, 59
Acoustic meatus
 external, 80*f*, 80*t*, 82*f*, 84, 203*f*, 204*t*
 internal, 81*f*
Acromegaly, 226*t*
Acromial region, 1
Acromioclavicular (shoulder) joint,
 96*f*, 97*t*, 111*f*, 112*f*, 112*t*
 palpating, 99
Acromion of scapula, 96*f*, 97*t*, 112*f*
Acrosome, **345**, 346*f*, 363*f*
ACTH (adrenocorticotropic) hormone,
 222*f*, 222*t*
Actin, **121**, 122*f*
Actin filaments, 122*f*
Action potential, 152, **155**, 156*f*, 208*f*.
 muscle contraction, 123, 125
 physiology of, 155, 156*f*
 transmission of, 155, 156*f*
 See also Nerve impulses
Active transport processes, **29**
Adam's apple, 291
Adaptation of sensory receptors, **59**
Adduction (movement), **113**, 115*f*
Adductor brevis muscle, 140*t*
Adductor longus muscle, 132*f*, 140*t*,
 141*f*
Adductor magnus muscle, 133*f*, 140*t*,
 141*f*, 143*f*
Adductor tubercle of femur, 103*f*
ADH (antidiuretic hormone), 223*t*, 226*t*
Adhesions, 116
Adipocytes (fat cells), 43*f*
Adipose tissue, 42, 43*f*, 55, 56*f*, 60*f*
Adrenal cortex, 224*t*
Adrenal glands, 10*t*, **15**, 16*f*, 224
 rat, 14*f*, 15
Adrenal medulla, **224**, 224*t*
Adrenocorticotropic hormone (ACTH),
 222*f*, 222*t*
Adventitia alimentary canal, 312, 313*t*
Afferent arterioles, **334**, 335*f*
Afferent (sensory) nerves, **157**
Afferent (sensory) neurons, **154**, 155*f*
Agar gel, observing diffusion in, 30*f*
Agglutinins, **238**, 239*f*
Agglutinogens (antigens), **238**, 239*f*
Agonist muscles, **126**
Agranulocytes, **232–233**
Air sacs (alveoli), 39*f*
Ala/ala of sacrum, **87**, 87*f*
Albumin, in urine, 336, 337*t*, 338
Alcohol detoxification, 21*t*
Aldosterone, 224*t*
Alimentary canal.
 See Gastrointestinal (GI) tract
Alpha cells of pancreatic islets, **225**
Alveolar ducts, **293**, 293*f*, 296*f*, 359*f*
Alveolar processes, 80*f*, 82*t*, 83*f*
Alveolar sacs, 293*f*, 359*f*
Alveoli (air sacs), 39*f*, **293**, 293*f*, 359*f*
 microscopic structure, 296*f*
 pulmonary capillaries, gas exchange
 in, 294*f*
Amphiarthroses, **109**
Ampulla, **207**, 207*f*
 of ductus deferens, 344*f*
Ampullary cupula, **207**, 207*f*
Anal canal, 312*f*, **317**, 318*f*
Anal sphincter, external, 318*f*
Anaphase stage of mitosis, **23**, 24*f*
Anatomical neck of humerus, **95**, 98*f*
Anatomical position, **1**, 4*f*
Anatomical terminology, 1
 body cavities, 5–6
 body landmarks, 1–3
 body orientation, 3, 3*f*
 body planes, 4
 body sections, 4
 directional, 3, 3*f*
Anatomy
 gross, **1**
 surface, 1–3, 2*f*
Anemia, **234**
Angles of scapula, 96*f*
Animal (four-legged) anatomical terms, 3
Ankle, 2
 bones, 101, 104*t*
 palpating, 104
Ankle-jerk (calcaneal tendon) reflex, **191**
Antagonist muscles, **126**
Antebrachial region, 1
Antebrachial vein, median, 268*f*
Antecubital region, 2
Anterior border of tibia, 104*t*
Anterior columns of spinal cord, **182**,
 183*f*
Anterior gluteal line, 100*f*
Anterior inferior iliac spine, 100*f*
Anterior orientation/direction, **3**, 3*f*
Anterior pituitary, **221**, 222*f*
Anterior pituitary hormones, 221
Anterior segment of eye, **197**, 198*f*
Anterior superior iliac spine, 100*f*, 141*f*
 palpating, 99
Anterior (ventral) horns, spinal cord,
 181, 183*f*, 356*f*
Antibodies (agglutinins), **238**, 239*f*
Antidiuretic hormone (ADH), 223*t*
 hyposecretion/hypersecretion of,
 226*t*
Antigens (agglutinogens), 238, 239*f*
Anus, 312*f*, **317**
 rat, 14*f*, **15**
Anvil (incus), 203*f*, 204*t*
Aorta, 246*f*, 247*f*, 248*f*, **249**, **259–264**,
 260*f*
 sheep, 251*f*
Aortic arch, 246*f*, **259–262**, 260*f*
Aortic (SL) valve, 247*f*, **248**
Apex of coccyx, 87*f*
Apex of heart, **245**, 246*f*, 247*f*
 sheep, 251*f*
Apex of lung, 294, 295*f*
Apical impulse, 246*f*
Apical pulse, **280**
Apical surface of epithelial
 membranes, 37, 38, 38*f*
Apical-radial pulse, 280
Apocrine sweat glands, **59**
Aponeuroses, **124**, 137*f*
 epicranial, 135*f*
Appendages of skin.
 See Skin
Appendicular skeleton, **67**, 68*f*,
 95–108, 97*t*
 lower limbs, 101, 103–104*f*,
 103–104*t*
 pectoral girdle, 95, 96*f*, 97*t*
 pelvic girdle, 68*f*, **99–101**, 100*f*
 upper limbs, 95–99, 97*t*, 98*f*, 99*f*
Appendix, 6*f*, 312*f*, 317, 318*f*
Aqueous humor, **197**, 198*f*
Arachnoid mater, **167**, 168*f*, 183*f*
Arachnoid granulations, **167**, 168*f*, 169*f*
Arbor vitae, 166*f*, **167**
Arcuate artery
 of foot, **264**, 264*f*
 of kidney, 333*f*, **334**, 335*f*
Arcuate veins, of kidney, 333*f*, **334**, 335*f*
Areolar connective tissue, 42, 43*f*
Arm
 arteries, 260*f*, 261*f*, 262
 bone, 68*f*, 70*f*, 95, 96*f*
 muscles, 132*f*, 133*f*, 136*t*, 137–138,
 137*f*, 138*t*, 139*f*
 nerves, 184*f*, 185*t*
 veins, 267, 268*f*
Arrector pili muscles, 56*f*, 60*f*, **61**
Arteries, 257–264, 258*f*
 elastic (conducting), 258*t*
 factors affecting blood flow, 284
 major, of body, 259–264, 260*f*
 microscopic structure, 257–259,
 259*f*, 358*f*
 muscular (distributing), 258*t*
Arterioles, 258*t*
Articular capsule of synovial joints,
 110, 110*t*, 112*f*
Articular cartilage, 70*f*, **71**, 112*f*
Articular facet, superior, 85*f*, 87*f*
Articular processes, vertebral, **85**,
 85*f*, 86*f*
Articulations.
 See Joints (articulations)
Ascending aorta, **259**, 260*f*
Ascending colon, 6*f*, 312*f*, **317**, 318*f*
Ascending (sensory) tracts, 182
Association neurons.
 See Interneurons
Association tracts (cerebral
 hemisphere), 167
Aster, 23*f*
Astigmatism, **201**
 testing, 202, 202*f*
Atlantoaxial joints, 112*t*
Atlas (C₁), **85**, 86*f*, 113
ATP
 in active transport, **29**
 mitochondria and, 21*t*
 in muscle contraction, 123–124
Atria of heart, **246**, 246*f*, 247*f*, 248*f*
 sheep, 251*f*
Atrioventricular (AV) valves, **246–248**,
 247*f*
Attachment sites, skeletal muscle, 113,
 124, 126
Auditory (pharyngotympanic) tubes,
 203*f*, 204*t*, 292*f*, 292*t*
Auditory receptors (hair cells), 205, 357*f*
Auricle (pinna) of outer ear, 46*f*,
 203*f*, 204*t*
Auricles of heart, sheep, **250**, 251*f*
Auricular surface of sacrum, 87*f*
Auscultation of heart sounds, 279
Autonomic reflexes, **189**, 192, 202
Axial skeleton, **67**, 68*f*, **79–94**
 skull, **79–84**
 vertebral column, 84–87
Axillary artery, 260*f*, 261*f*, **262**
Axillary nerve, 184*f*, **185**, 185*t*
Axillary region, 2
Axillary vein, **267**, 268*f*
Axis (C₂), **85**, 86*f*, 113
Axon hillock, 152*f*
Axon terminals, 124, 125*f*, **151–152**,
 152*f*, 355*f*
Axons (nerve fibers), 49*f*, **151**, 152,
 154, 355*f*, 356*f*
 of bipolar/multipolar/unipolar
 neurons, 154*f*
 bundles of in CNS (tracts), **157**
 bundles of in PNS (nerves), **157**
 myelin sheaths of, **152**, 153*f*, 356*f*
 myelinated, 356*f*
 nonmyelinated, 356*f*
 of peripheral nerve, 157*f*, 356*f*
 vs. dendrites, 151, 152*f*
Azygos system, 265*f*
Azygos vein, **267**, 268*f*

Babinski's sign, 191
Back muscles, 136*t*, 138*t*
Balance. *See* Equilibrium
Ball-and-socket joint, 110*t*, 112*t*
Basal epithelial cells, **210**, 210*f*
Basal surface of epithelial membranes,
 38*f*
Base of heart, **245**
Base of lung, 294, 295*f*
Basement membrane, **38**, 39*f*, 40*f*, 41*f*
Basilar artery, **270**
Basilar membrane, **205**, 205*f*, 357*f*
Basilic vein, **267**, 268*f*
Basophils, **232**, 233*f*, 364*f*
Benedict's solution, 32*t*
Beta cells of pancreatic islets, **225**
Biaxial movement, **112**, 112*t*
Biceps brachii muscle, 132*f*, 136*t*,
 137*f*, 138
Biceps femoris muscle, 133*f*, 142*t*, 143*f*
Bicuspid (mitral) valve of heart, **246**,
 247*f*
Bile
 emulsifying actions of, 321*f*, 323
 in urine, 336, 337*t*
Bile duct, **316**, **320**
Bipolar cells, **197**, 197*f*
Bipolar neurons, **154**, 154*f*
Blackheads, 59
Bladder. *See* Urinary bladder
Blastulas of whitefish, 24

- Blind spot (optic disc), **197**, 198*f*
 cow eye, 200*f*
 demonstrating, 200–201, 201*f*
- Blindness, color, 202
- Blisters, 55
- Blood, **10r**, 231–244
 composition of, 231–233, 233*f*
 as connective tissue, 42, 231
 hematologic tests, 234–239
 microscopic examination, 232–233, 363*f*, 364*f*
 safe handling of, 231
- Blood cell formation, site for, 67
- Blood clotting (coagulation) test, **237**, 237*f*
- Blood pressure, **281**
 cardiac cycle and, **277–279**, 278*f*
 cuff (sphygmomanometer), **281**, 281*f*
 effects of exercise on, 282–283
 measuring, 281–282, 281*f*
 postural effects on, 282
- Blood typing, 238–239
 for ABO, Rh blood groups, 238–239
- Blood vessels, **10r**, 257–276, 358*f*. *See also* specific types
 arteries, 257–264, 258*f*
 of brain, 269–270
 factors affecting blood flow, 283–285
 of hepatic portal circulation, 269, 270*f*
 microscopic structure, 257–259, 259*f*
 of pulmonary circulation, 267, 269*f*
 of skin, effect of mechanical stimulation on, 285
 summary of anatomy and physiology, 258*t*
 veins, 265–267, 266*f*, 268*f*
- Body
 of hyoid bone, 83*f*
 of mandible, 82*t*
 of nail, 61*f*, 62
 of stomach, 315*f*, 315*t*
 of uterus, **347**
- Body cavities, 5–6
- Body landmarks, 1–3
- Body movements
 joint function in, 109
 types of, 113–116, 114*f*
- Body orientation terminology, 3, 3*f*
- Body planes and sections, **4**, 4*f*
- Body temperature regulation
 dermal blood supply and, 57
 sweat glands and, 59
- Bolus, **319**
- Bone markings, **67**, 69*t*
- Bone (osseous tissue), **42**, 46*f*
- Bone salts, 71
- Bone spurs, 116
- Bones, **10r**
 acid effects on, 71–72
 of appendicular skeleton, 68*f*, 95–108, 97*t*
 of axial skeleton, 68*f*, 79–94
 chemical composition of, 71–72
 heat effects on, 71–72
 long, **68**, 70–71, 70*f*
 surface markings, 69*t*
 tensile/compressional strength, 71
 types of, 67–71
- Bony labyrinth, 204*t*
 equilibrium apparatus in, 207
- Bony matrix, 71
- Bony pelvis, **99**
- Borders of scapula, 96*f*, 97*t*
- Brachial artery, 261*f*, **262**
 blood pressure measurements at, 281–282, 281*f*
 as pulse point, 280, 280*f*
- Brachial plexus, 184*f*, **185**, 185*t*
 distribution of nerves arising from, 184*f*
- Brachial pulse, 282
- Brachial region, 2, 3
- Brachial vein, **267**, 268*f*
- Brachialis muscle, 132*f*, 133*f*, 136*t*, 137*f*
- Brachiocephalic trunk, **259**, 259*t*, 260*f*, 261*f*
 sheep, **251**, 251*f*
- Brachiocephalic veins, 265*f*, **266**, 268*f*
- Brachioradialis muscle, 132*f*, 133*f*, 136*t*, 137*f*
- Brain, **10r**, 15, 16*f*, 163–171
 arteries, 269–270, 270*f*
 cerebral arterial circle (circle of Willis), **269–270**
 cerebrospinal fluid, 168
 cranial nerves and, 163, **170–171**, 170*t*, 171*f*
 meninges, **167**, 168*f*
 neuroglia, **49**, **151**
 neurons, **49**, 151–162
 sheep dissection, 171–174, 173*f*, 174*f*
 structures
 external, 163–166
 internal, 167
 veins, 265*f*, 266
- Brain stem, **165**, 165*f*, 166*f*, 167
 medulla oblongata, 164*f*, **165**, 165*f*, 166*f*, 168*f*
- Breathing (pulmonary ventilation), **291**, **301**
 factors influencing rate/depth, 305–306
 measuring respiratory volume, 302–305
 mechanics, 294*f*, 301, 302*f*
 observing variations in, 305–306
 operating model lung, 301–302
 rib cage/diaphragm positions during, 302*f*
- Broad ligament, **347**, 348*f*
- Broca's area, 164*f*, 165*t*
- Bronchi, **10r**, 15
 primary (main), **293**, 293*f*
 rat, **12**
- Bronchial arteries, 260*f*, 262, 262*t*
- Bronchial tree, **293**
- Bronchioles, **293**, 293*f*, 359*f*
 respiratory, **293**, 293*f*
 terminal, **293**, 293*f*
- Brush border enzymes, **316**, 321*f*
- Buccal region, 2*f*
- Buccinator muscle, 134*t*, 135*f*
- Bulbar conjunctiva, 196*f*, 196*t*
- Bulbo-urethral glands, 344*f*, 344*t*
 rat, 14*f*
- Bursa, 110
- Bursitis, 116
- Buttocks, 2*f*, 3
- C (parafollicular) cells, **223**
- Calcaneal (Achilles) tendon, 133*f*, 143*f*
 ankle-jerk reflex, **191**
- Calcaneal region, 2*f*, 3
- Calcaneus (heel bone), 101, 104*f*
- Calcitonin, 223*t*, 3
- Calcium ions
 stored by bones, 67
 tetany and, 226*t*
- Calf region of leg, 3*f*
- Calyces of renal pelvis, minor and major, **333**, 333*f*
- Canaliculi, **72**, 73*f*
 lacrimal, 196*f*, 196*t*
- Canines (eye teeth), **318**, 319*f*
- Capillaries, 258*t*
 body temperature regulation and, 55, 57
 pulmonary, 248*f*, **267**
 of small intestine, 316, 317*f*
 structure of, 258*f*
- Capillary walls, filtration process and, 29
- Capitate, 99*f*
- Capitulum, 97*t*, 98*f*
- Carbohydrate digestion, 320, 321*f*
- Carbon dioxide
 cell membrane transport and, 29
 cell's need to dispose of, 291
- Cardia (cardial part of stomach), 315*f*, 315*t*
- Cardiac cycle, **277–279**, 278*f*
 events of, 278*f*, 279*t*
 heart sounds during, **279**
- Cardiac (gastroesophageal) sphincter, **315**
- Cardiac muscle, **47**, 48*f*, 245, 247*f*
 examining, 250, 250*f*
 microscopic anatomy of, 249–250
- Cardiac skeleton, 245
- Cardiac veins, 246*f*, 247*f*, 249*t*
- Cardinal (transverse) ligament, 348*f*
- Cardiovascular system, **10r**, **245**
 blood, 231–244
 blood pressure and, 277–279
 blood vessels, 257–276
 cardiac cycle and, **277–279**, 278*f*
 components, 10*t*
 functions (overview), 10*t*
 heart, **10r**, **245–256**
- Carina, 293*f*
- Carotid arteries, **259**, 259*t*, 260*f*, 261*f*, **269**, 270*f*
 as pulse point, 280, 280*f*
- Carotid canal, 80*t*, 82*f*
- Carpal bones, 68*f*, **98**, 99*f*
- Carpal region, 2*f*
- Carpometacarpal joint of thumb, 112*t*
- Carpus (wrist), **98**
- Cartilage, **10r**, **42**
 articular, 70*f*, **71**
 elastic, 46*f*
 joints and, 109
- Cartilaginous joints, 109, 110*t*, 111*f*
- Catalysts, 320
- Catecholamines, 224*t*
- Cauda equina, **181**, 182*f*, 184*f*
- Caudal orientation/direction, **3**, 3*f*
- Cavities of body, 5–6
- Cecum, 6*f*, 312*f*, 317, 318*f*
 peritoneal attachments, 316*f*
 rat, 12
- Celiac trunk, 260*f*, 262*t*, 263*f*
- Cell, **9**, 19–27
 active membrane transport, 29
 anatomy, 19–22
 cytokinesis, **23–24**, **24**, 24*f*
 division, 23–24, 23–24*f*
 inclusions of, **21**
 life cycle, 23–24, 23–24*f*
 mitosis, **23–24**, 23–24*f*
 passive membrane transport, **29–36**
 specialization, benefits/risks, 37
- Cell division, **23–24**, 23–24*f*
 in skin layers, 57*t*
- Cellular energy, mitochondria and, 21*t*
- Cement, **319**, 319*f*
- Central canal of spinal cord, **181**, 183*f*, 356*f*
- Central (Haversian) canal, 46*f*, **72**, 73*f*
- Central nervous system (CNS), **163**
 brain, 163–171
 neurons, **151–157**
 spinal cord, **10r**, 15, 16*f*, **181–183**, 182*f*, 183*f*
 tracts, **157**
- Central sulcus of cerebral hemisphere, **163**, 164*f*
- Central vein of liver, 361*f*
- Centrioles, 20*f*, 21*t*
- Centromere, **23**, 23*f*
- Centrosome(s), 23*f*
- Centrosome matrix, 20*f*
- Centrum (body) of vertebrae, 85, 85*f*, 86*f*
- Cephalad/caudad (caudal) body orientation/direction, **3**
 in animals, 3
- Cephalic region, 2*f*, 3
- Cephalic vein, **267**, 268*f*
- Cerebellum, 164*f*, 165*f*, **166**, 166*f*, 167
 Purkinje cells of, 355*f*
- Cerebral aqueduct, 166*f*, **167**
- Cerebral arterial circle (circle of Willis), **269–270**
- Cerebral arteries, **269**, **270**
- Cerebral cortex, **164**, 164*f*, 165*t*
- Cerebral hemispheres (cerebrum), **163–165**, 164*f*, 166*f*, 167
- Cerebral peduncles, **165**
- Cerebral white matter, 151, **164**, 164*f*
- Cerebrospinal fluid, 167, 168
 tracing pathway through CNS, 168, 169*f*
- Ceruminous glands, 204*t*
- Cervical curvature, 84*f*
- Cervical plexus, 184*f*, **185**, 185*t*
- Cervical region, 2*f*
- Cervical spinal nerves, 182*f*, 184*f*
- Cervical vertebrae, 84, 85–86
 palpating, 86
 regional features, 86*f*
- Cervix, **347**, 347*f*, 348*f*
- Cheeks, 2, **314**, 315
 epithelial cells of, wet mount of, 371–372
- Chemical digestion of foodstuffs, 320–323
 flowchart, 321*f*
- Chemical mediators, local
 inflammatory response promoted by, 285
- Chemical senses, 209–212
- Chemoreceptors
 lab experiments, 211–212
 of smell sense, 209–210, 209*f*
 of taste sense, 210–211, 357*f*
- Chest. *See* Thorax
- Chewing muscles, 134*t*, 135*f*
- Cholesterol in plasma membrane, 20, 21*f*
- Chondrocytes
 in fibrocartilage, 45*f*
 in hyaline cartilage, 45*f*
 in lacuna, 46*f*
- Chordae tendineae, **246**, 247*f*
- Choroid, eye, 198*f*, 199*t*, 357*f*
 cow, 199, 200*f*
- Choroid plexuses, 166*f*, **167**, **168**
- Chromatid, sister, **23**, 23*f*
- Chromatin, **19**, 20*f*, 23*f*
- Chromatophilic substance (Nissl bodies), **151**, 152*f*
- Chromosomes, **19**, **23**, 23–24*f*
 daughter, 24*f*
- Cilia, 40*f*
 as specialized epithelial cells, 37, 42
- Ciliary body, 198*f*, 199*t*
 cow eye, 199, 200*f*
- Ciliary glands, 196*t*
- Ciliary muscle, 198*f*, 199*t*
- Ciliary process, **197**, 198*f*, 199*t*
- Ciliary zonule, 198*f*, 199*t*
 cow eye, 199
- Circle of Willis (cerebral arterial circle), **269–270**
- Circular folds of small intestine, **317**, 317*f*, 360*f*
- Circulatory system
 coronary, 246*f*, 249, 249*t*
 factors affecting blood flow, 283–284
 pulmonary and systemic, 248–249, 248*f*, 267, 269*f*
- Circumduction, 344
- Circumduction movement, **113**, 115*f*
- Circumferential lamellae, **72**, 73*f*
- Circumflex artery, 246*f*, 249*t*
- Circumflex humeral artery, 261*f*
- Clavicle, 68*f*, 95, 96*f*, 97*t*
 palpating, 99

- Clavicular notch, 88f
 Cleavage furrow, 24, 24f
 Clitoris, 346, 347f
 Coagulation (blood clotting), 237, 237f
 determining clotting time, 237–238
 Coccygeal nerve, 184f
 Coccyx, 84, 84f, 87, 87f, 100f
 in females vs. males, 102t
 Cochlea, 203f, 204t, 205f
 microscopic exam, 205, 357f
 Cochlear duct, 205, 205f, 207f
 Cochlear nerve, 207f, 357f
 Colic flexures of large intestine, 317, 318f
 Collagen fibers, 42, 44f
 of areolar connective tissue, 43f
 in bone matrix, 71
 of dermis, 57
 of fibrocartilage, 45f
 of intervertebral discs, 85
 Collaterals, of axons, 151
 Collecting ducts of nephrons, 334, 335f
 Colon, 6f, 312f, 317, 318f
 Color blindness, 202
 Columnar epithelia, 38, 38f
 pseudostriated, 40f
 simple, 40f, 355f
 Commissures
 cerebral hemisphere, 166f, 167
 gray, of spinal cord, 183f, 356f
 Common fibular nerve, 185t, 186, 186f
 Common hepatic duct, 320
 Communicating arteries of brain, 270
 Compact bone, 67, 70f, 72–73, 73f
 Compound microscope, 365
 care and structure of, 365–370, 366f, 367t
 depth of field, 370–371
 diameter of microscope field, 369–370
 magnification of, 367–368
 resolution of, 368
 viewing objects through, 368–369
 wet mount, preparing and observing, 371–372
 Compressive strength of bone matrix, 71
 Concentration gradient, 29
 Concept map of tissues, 50, 50f
 Conducting zone structures, 294
 Condylar joints, 110t, 112t
 Condylar process, 80f, 82t
 Condyles, 69t
 of femur, 103f, 103t
 palpating, 104
 of tibia, 103f, 104t
 Cones and rods, 197, 197f, 202, 357f
 Conjunctiva, 196f, 196t
 Conjunctivitis, 196t
 Connective tissue, 9, 37, 42, 43–46f
 blood as, 42
 bone as, 42
 dense, 42, 44f
 elastic cartilage, 46f
 extracellular matrix and, 42
 fibrocartilage, 45f
 hyaline cartilage, 45f
 ligaments as, 42
 loose, 42
 reticular, 44f
 tendons as, 42
 Connective tissue proper, 42
 Connective tissue sheath
 of fibers within nerves, 157, 157f
 of hair follicle, 60f, 61
 Connective tissue wrappings of skeletal muscle, 124, 125f
 Consensual reflex, 192
 Contraction of skeletal muscle, 121, 123
 observational experiment, 123–124
 Contralateral response to reflex tests, 192
 Controls, experimental, 322
 Conus medullaris, 181, 182f
 Convergence reflex, 202, 203
 Coracoid process of scapula, 96f, 97t
 Cornea, 198f, 199t
 astigmatism and, 201
 cow eye, 199, 200f
 Corneal reflex, 192
 Cornua (horn) of hyoid bone, 83, 84f
 Corona radiata, 348f, 349
 Coronal (frontal) plane, 4, 4f
 Coronal (frontal) section, 4f
 Coronal suture, 79, 80f
 Coronary arteries, 246f, 247f, 249t, 259t, 260f
 Coronary circulation, 246f, 249, 249t
 Coronary sinus, 247f, 249t
 Coronary sulcus, 246f, 247f, 249t
 Coronoid fossa of humerus, 97t, 98f
 Coronoid processes
 of mandible, 80f, 82t
 of ulna, 97t, 98f
 Corpora quadrigemina, 166, 166f
 Corpus callosum, 166f, 167
 Corpus cavernosum, 344f
 Corpus luteum, 347, 348f, 349, 358f
 Corpus spongiosum, 344f
 Corrugator supercilii muscle, 135f
 Cortex
 cerebral, 164, 164f, 165t
 of hair, 60f
 renal, 333, 333f, 335f, 336f
 Cortical nephrons, 334, 335f
 Cortical radiate arteries, 333f, 334
 Cortical radiate veins, 333f, 334
 Costal cartilage, 45f, 88f
 Costal facets of thoracic vertebrae, 86f, 87
 Costocervical trunk, 261f
 Coxal bones (ossa coxae), 99, 100f
 Coxal region, 2f
 Cranial aponeurosis, 134t
 Cranial bones (cranium), 68f, 79–83
 Cranial cavity, 5
 Cranial fossa, 81f
 Cranial nerves, 170–171, 170t, 171f
 reflex tests, 192
 testing of, 170t, 171
 Cranium (cranial bones), 68f, 79–83
 Crest, bone marking, 69t
 Cretinism, 226t
 Cribriform foramina, 81f
 Cribriform plate of ethmoid bone, 81f, 81t, 209f
 Cricoid cartilage, 292f, 293
 Crista ampullaris, as receptor for equilibrium, 207, 207f
 Crista galli, 81f, 81t
 Cristae, 21t
 Cross section (transverse section), 4, 4f
 Crown, tooth, 319, 319f
 Crural region, 2f
 Crystals in cell cytoplasm, 21
 Cuboid bone, 104f
 Cuboidal epithelia, 38, 38f
 simple, 39f
 Cuneiform bones, intermediate/lateral/medial, 104f
 Curvatures, stomach (greater/lesser), 315f, 316
 Cutaneous glands, 56f, 59–60
 Cutaneous receptors, 10t, 55, 57–59
 adaptation test, 59
 tactile localization test, 58–59
 two-point threshold test, 58
 Cuticle
 of hair, 60f
 of nail, 61f, 62
 Cyanotic signs in nail beds, 61
 Cystic duct, 320
 Cytokinesis, 23, 24, 24f
 Cytoplasm, 19, 20–21
 organelles, 21, 21t
 of Schwann cell, 153f
 Cytoplasmic organelles, 21, 21t
 Cytoskeletal elements, 20f, 21t
 of neurons, 151, 152f
 Cytoskeleton, filaments of, 21f
 Cytosol, 20f, 21
 Dark (A) bands, 121, 122f
 Daughter chromosomes, 24f
 Deafness
 conduction, 206
 sensorineural, 206
 Deciduous (milk) teeth, 318, 319f
 Deep artery of arm, 261f
 Deep artery of thigh, 264, 264f
 Deep (internal) direction/orientation, 3
 Deglutition (swallowing), 323
 Deltoid muscle, 132f, 133f, 136t, 137, 137f, 138t, 139f
 Deltoid tuberosity, 97t, 98f
 Demilunes of serous cells, 320, 361f
 Dendrites, 49f, 151, 152, 152f, 355f
 of bipolar/multipolar/unipolar neurons, 154f
 vs. axons, 151, 154
 Dendritic cells, 56
 Dens of axis, 85
 Dense connective tissue, 42, 44f
 Dental formula, 318
 Dentin, 319, 319f
 Dentinal tubules, 319f
 Depolarization in action potential/nerve impulse, 155, 156f, 208f
 Depressor anguli oris muscle, 135f
 Depressor labii inferioris muscle, 135f
 Dermal papillae, 56f, 57, 356f
 Dermal vascular plexus, 56f
 Dermis, 55, 56f, 57, 61f
 blood supply, 57
 cutaneous receptors of, 57–59
 Descending aorta, 15, 16f, 259
 rat, 14f, 15
 Descending colon, 6f, 312f, 317, 318f
 Descending (motor) tracts of CNS, 182
 Diabetes insipidus, 226t
 Diabetes mellitus, 226t
 Diagnostic blood tests, 234–239
 Dialysis sacs, 31
 Diaphragm, 6f, 15, 16f, 294, 295f
 rat, 12, 13f
 Diaphysis, 70f, 71
 Diarthroses, 109, 110, 110t
 Diastole, 277, 278f, 279t
 Diastolic blood pressure, 281–282, 281f
 Dicrotic notch, 278f, 279t
 Diencephalon, 165, 166f, 167
 Differential (selective) permeability, 29
 Diffusion, 29–33
 through nonliving membranes, 31–32
 observing dyes in agar gel, 30f
 by osmosis, 29, 32
 through semipermeable membranes, 29–32
 simple, 29, 32
 of solutes, 29, 31
 Digestion, 311
 of carbohydrates, 320, 321f
 chemical, 320–323
 of fats, 320, 321f
 flowchart, 321f
 physical processes of, 323–324
 of proteins, 320, 321f, 322, 322f
 Digestive enzymes, 21t, 320–322, 321f
 Digestive system, 10t, 311–330
 accessory organs, 311, 312f, 318–320
 alimentary canal histology, 312–314, 360f, 361f
 functions (overview), 10t
 organs, 10t, 314–318
 Digestive tract, rat, 12
 Digital arteries, 261f
 Digital region, 2f
 Digital veins, 266f, 268f
 Directional terminology, 3, 3f
 Dissections
 cow eye, 199–200, 200f
 pig/sheep kidney, 333
 rat, 9–15, 11f, 12f, 13–14f
 sheep brain, 171–174, 173f, 174f
 sheep heart, 250–252, 251f
 spinal cord, 182, 356f
 Distal convoluted tubule, 334, 335f
 Distal direction/orientation, 3, 3f
 Distal vision, 201
 DNA replication, in cell division, 23
 Dorsal body cavity, human, 5, 5f, 15, 16f
 Dorsal direction/orientation, 3, 3f
 in animals, 3
 Dorsal median sulcus of spinal cord, 183f, 356f
 Dorsal pedis vein, 266, 266f
 Dorsal (posterior) columns (funiculi) of spinal cord, 182, 183f, 356f
 Dorsal (posterior) horns, spinal cord, 181, 183f, 356f
 Dorsal rami, spinal nerves, 184, 184f
 Dorsal root ganglion, 155f, 181, 183f, 356f
 Dorsal roots, spinal cord, 181, 183f
 Dorsal venous arch, 266
 Dorsalis pedis artery, 264, 264f
 as pulse point, 280, 280f
 Dorsiflexion movement of foot, 113, 115f
 Drug detoxification site, 21t
 Ductus arteriosus, sheep, 251
 Ductus (vas) deferens, 343, 344f, 345f
 rat, 14f, 15
 Duodenal glands, 361f
 Duodenal papilla, major, 316
 Duodenum, 312f, 315f, 316, 360f
 peritoneal attachments of, 316f
 Dura mater, 167, 168f, 356f
 Dwarfism, pituitary, 226t
 Ear
 anatomy, 203–205, 203f, 207
 equilibrium mechanism, 207
 examining with otoscope, 204
 hearing mechanism, 205, 357f
 Eardrum (tympanic membrane), 203f, 204t
 otoscopic viewing, 204
 Earlobe (lobule), 203f, 204t
 Eccrine sweat gland, skin, 56f, 59
 Effectors, in reflex arcs, 189f, 190, 190f
 Efferent arteriole, 334, 335f
 Efferent ductule of testis, 345f
 Efferent (motor) nerves, 157
 Efferent (motor) neurons, 154, 155f
 Ejaculatory duct, 344, 344f
 Elastic cartilage, 46f
 Elastic fibers, 42
 of areolar connective tissue, 43f
 of dermis, 57
 Elastic (titin) filaments, 122f
 Elbow joint, 110t, 111f, 112t
 muscles crossing, 136t, 137
 muscles of, 136t
 Elbow, palpating, 99
 Embryonic development, of skeletal muscle cells, 23
 Emmetropic eye, 201
 Enamel, tooth, 319, 319f
 End plate. *See* Neuromuscular junction
 Endocardium, 245, 247f
 Endocrine system, 221–229
 disorders of, 226, 226t
 functions, 10t, 221–226
 hormones, 221–226
 organs, 10t, 226f
 Endolymph, 205, 205f, 207, 207f

- Endometrium, 348f
Endometriosis, **124**, 125f
Endoneurium, **157**, 157f, 356f
Endoplasmic reticulum (ER), 20f, 21t
Endosteum, 70f, **71**, 73f
Endothelium, 257, 258f
Enterocytes, 317f
Enzymes, **320**
 digestive, 320–322, 321f
Eosinophils, **232**, 233f, 364f
Epicardium, **245**, 247f
Epicondyle(s), 69t
 of femur, 103f
 of humerus, 97t, 98f, 99
Epicranial aponeurosis, 135f
Epicranium
 frontal belly of, 132f, 134t, 135f
 occipital belly of, 133f, 134t, 135f
Epidermis, 55, 56–57, 56f, 61f
Epididymis, **343**, 344f, 345f, 362f
Epigastric region, **6**, 6f
Epiglottis, 292f, **293**, 314f
Epimysium, **124**, 125f
Epinephrine, **224**, 224t
Epineurium, **157**, 157f, 356f
Epiphyseal lines, 70f, **71**
Epiphyseal plate, **71**
Epiphysis, 70f, **71**
Epiploic appendages, 318f
Epithalamus, 166f, **167**
Epithelial root sheath of hair follicle,
 60f, 61
Epithelial tissues (epithelia), **9**, **37–42**
 descriptions/functions/locations, 39–41f
 of GI tract, 313f, 313t
 simple, 22f, **38**, 38f, 39f, 40f, 355f, 360f
Eponychium (cuticle), 61f, **62**
Equilibrium (balance), 207–209
 apparatus anatomy, 207
 dynamic, 207
 laboratory tests of, 208–209
 mechanism of, 207
 role of vision in, 209
 static, 207
ER. *See* Endoplasmic reticulum (ER)
Erection, **344**
Erector spinae muscles, 138t, 139f
Erythrocytes (red blood cells/RBCs),
 22f, **231**, 232, 233f
 hematologic tests, 234–239
 microscopic examination, 33
 microscopic examinations, 232,
 363f, 364f
 normal values, 234
 permeability properties, 33
 total counts, 234
 in urine, 336, 337t
Esophageal arteries, 260f, 262, 262t
Esophagus, 10r, 15, 16f, 41f, 312f, **315**,
 315f, 359f
 digestive functions, 315
 rat, **12**
Esophagus-stomach junction, 360f
Estrogens, 224t, **225**, 347
Ethmoid bone, 80f, 81t, 83f
 cribriform plate, 81f, 81t, 209f
 crista galli, 81f
Ethmoidal air cells, 84f
Eversion movement of foot, **113**, 115f
Exercise, effects on blood pressure,
 282–283
Exocytosis, 20f
Expiration phase of breathing, **301**, 302f
Expiratory reserve volume (ERV),
 303f, **304**
Extension movement, **113**, 114f
Extensor carpi radialis longus muscle,
 133f, 138t
Extensor carpi ulnaris muscle, 133f, 138t
Extensor digitorum brevis, 141f
Extensor digitorum longus muscle,
 132f, 140t, 141f
Extensor digitorum muscle, 133f, 138,
 138t
Extensor hallucis brevis, 141f
Extensor hallucis longus muscle, 141f
External acoustic meatus, 80f, 80t, 82f,
 84, 203f, 204t
External ear, 204t
 anatomy, 203f, 204t
External genitalia
 female, **346**, 346t, 347f
 male, 343, 344f
External oblique muscle, 132f, 133f,
 136t, 137f, 139f
External occipital crest, 82f
External occipital protuberance, 82f
External respiration, **291**
Extracellular matrix, **42**, 45f, 46f
Extrinsic eye muscles, 196t, 197f
 cow eye, 199, 200f
 reflexes, 202
Eye, 195–203
 accessory structures, 195–197, 196f,
 196t
 anatomy, 195–200
 muscles
 extrinsic, 196t, 197f, 202
 intrinsic, 202
 reflexes, 192, 202
 refraction, **201**, 201f
 visual acuity, **201**
Eyebrows, 196f, 196t
 muscles, 134t
Eyelashes, 196f, 196t
Eyelids, 196f, 196t
 muscles, 134t
Face
 muscles of facial expression, 131, 134t
 superficial muscles, 132f, 135f
Facet, bone marking, 69t
Facial artery, as pulse point, 280, 280f
Facial bones, 68f, 82t, 83
 palpating bone markings, 83–84
Facial nerves (VII), 170t, 171f, 210
Falciform ligament, 316f, **320**
Fallopian tubes, **347**, 347f, 348f
False pelvis, **101**
False ribs, 88, 88f
Falx cerebri, **167**, 168f
Fascicles
 nerve fibers, **157**, 157f
 skeletal muscle, **124**, 125f
Fat cells (adipocytes), 43f
Fatigue, stretch reflex response and, 191
Fats, digestion of, 320, 321f
Female reproductive system, 10t, 225,
 346–349, 347f, 348f
 histology, 358f, 363f
 rat, 14f, 15
Femoral artery, **264**, 264f
 as pulse point, 280, 280f
Femoral nerve, 185t, **186**, 186f
Femoral region, 2f, 3
Femoral vein, **266**, 266f
Femur, 68f, **101**, 103f, 103t
 bone markings, 69t
 palpating surface anatomy of, 104
Fibers, joints and, 109
Fibers of extracellular matrix, 42
Fibers (processes) of neuron cell bodies
 in CNS, 151
 in PNS, 151
Fibrin, **237**, 237f
Fibrinogen, **237**, 237f
Fibroblast nuclei, 43f
Fibroblasts, of dermis, 57
Fibrocartilage, 45f, 110t
 of intervertebral discs, 45f, 85,
 110t, 111f
Fibrous capsule, **333**, 333f, 335f
Fibrous connective tissue
 of sutures, 110t, 111f
 of syndesmoses, 111f
Fibrous joints, 110t, 111f
Fibrous layer
 of articular capsule, 110, 112f
 of eye, **197**, 199t
Fibrous pericardium, **245**
Fibula, 68f, **101**, 103f, 104t
Fibular artery, 264f
Fibular region, 2f, 3
Fibular vein, **266**, 266f
Fibularis longus muscle, 132f, 133f,
 140t, 141f
Fibularis tertius muscle, 141f
Field, microscope, **368**
 depth of, **370–371**
 diameter of, 369–370
Filaments
 of cytoskeleton, 21f
 intermediate, 20f, 21t
 of olfactory nerve, 171f
 thick/thin, 122f
Filtration, 29, 33–34
 observing, 33–34
Filum terminale, **181**, 182f
Fimbriae, **347**, 347f, 348f
Fingerprints, 57
Fingers
 bones, 98, 99f
 muscles, 136t, 137, 138, 138t
Fissure, bone marking, 69t
Fissures
 of cerebral hemispheres, **163**, 164f
 of spinal cord, 183f, 356f
Fixator (fixation) muscles, **126**
Flare, after mechanical stimulation of
 skin, 285
Flat bones, **68**
Flexion movement, **113**, 114f
Flexor carpi radialis muscle, 132f, 136t
Flexor carpi ulnaris muscle, 133f, 136t
Flexor digitorum superficialis, 136t
Flexor reflexes, 190, 190f
Floating ribs, 88, 88f
Foliate papillae, 210, 210f, 357f
Follicles
 hair, 56f, 60–61, 60f, 61f
 of ovaries, 347, 349f, 363f
 of thyroid gland, **223**
Follicle-stimulating hormone (FSH),
 222f, 222t
Foot
 arteries, 264
 bones, 101, 104f
 joints, 112t
 movements of, 113, 115f
 muscles, 140t
 nerve supply, 185t, 186f
 veins, 265f, 266, 266f
Foot processes of podocyte, 335f
Foramen, 69t
Foramen lacerum, 81f, 82f
Foramen magnum, 80t, 81f, 82f
Foramen ovale, 81f, 81t, 82f
Foramen rotundum, 81f
Foramen spinosum, 81f, 82f
Forearm
 bones, 98
 muscles, 132f, 133f, 136t, 138t
 nerves, 185–186, 185t
Formed elements of blood, **231**, 233f
 examining microscopically,
 232–233
Fornix
 corpus callosum, 166f
 vagina, 347f, 348f
Fossa, 69t
Fossa ovalis, heart, 247f
Fovea capitis of femur, 103f
Fovea centralis, **197**, 198f
Free edge of nail, 61f, 62
Free nerve endings in skin, 56f, 58,
 356f
Frenulum, lingual, **314**, 314f
Friction-reduction demonstration, 112
Frontal bone, 79, 80f, 80t, 81f, 83f
 squamous part of, 83f
Frontal (coronal) plane, **4**, 4f
Frontal (coronal) section, 4f
Frontal lobe, **163**, 164f, 165f
Frontal sinus, 84f
Frontonasal suture, 83f
FSH (follicle-stimulating hormone),
 222f, 222t
Functional residual capacity (FRC), 303f
Fundus of stomach, 315f, 315t
Fundus of uterus, **347**, 348f
Fungiform papillae, 210, 210f
Funiculi (columns) of spinal cord,
 dorsal/lateral/ventral, **182**, 183f,
 356f
Gag reflex, **192**
Gallbladder, 6f, 10t, 15, 16f, 312f, **320**
 peritoneal attachments of, 316f
Ganglia, **151**
 dorsal root, 155f, **181**, 183f, 356f
Ganglion cells, retina, **197**, 197f, 357f
Gas exchanges
 in external respiration, **291**, 294f
 in internal respiration, 248f, **291**
Gastric arteries, 262t, 263f
Gastric glands, 316, 360f
Gastric pit, 360f
Gastric veins, 270f
Gastrocnemius muscle, 132f, 133f,
 141f, 142, 142t, 143f
Gastroepiploic arteries, 263f
Gastroepiploic vein, 270f
Gastroesophageal (cardiac) sphincter,
 315
Gastrointestinal (GI) tract, **311**
 histology, 312–314, 313f, 360f
 nerve plexuses, 313f, 313t
 organs, 312f
 rat, 12
Genitalia, external
 female, **346**, 346t, 347f
 male, 343, 344f
Germinal centers, 259f
GH (growth hormone), 222f, 222t
GI tract. *See* Gastrointestinal (GI) tract
Gigantism, 226t
Gingiva (gum), **319**, 319f
Gingival sulcus, 319f
Glabella, 83f
Glans penis, **344**, 344f
Glassy membrane, 61
Glenoid cavity, 96f, 97t
Glial cells (neuroglia), **49**, **151**
 oligodendrocytes in CNS, **152**
 Schwann cells of PNS, 151, **152**
Glomerular capsular space, 335f, 336f,
 362f
Glomerular capsule, 334t, 335f, 336f,
 362f
Glomeruli
 of nephrons, **334**, 334t, 335f, 336f,
 362f
 olfactory, 209f
Glossopharyngeal nerve (IX), 170t,
 171f, 192, 210
Glottis, **293**
Glucagon, 224t
Glucocorticoids, 224t
Glucose, in urine, 336, 337t, 338
Gluteal arteries, 264f
Gluteal nerves, superior and inferior,
 185t, 186f
Gluteal region, 3f

- Gluteal tuberosity, 103*f*, 103*t*
 Gluteus maximus muscle, 133*f*, 142, 142*t*, 143*f*
 Gluteus medius muscle, 133*f*, 142*t*, 143*f*
 Glycogen granules, 21
 Glycolipids, 57*t*
 GnRH (gonadotropin-releasing hormones), 222*t*
 Goblet cells, 40*f*, 42
 GI tract, 317*f*, 355*f*, 359*f*, 361*f*
 respiratory, 293
 Golgi apparatus, 20*f*, 21*t*
 Gomphosis, 110*t*
 Gonadal arteries, 260*f*, 262*t*, 263*f*
 Gonadal veins, 265*f*, 266, 267*f*
 Gonadocorticoid hormones, 224*t*
 Gonadotropin-releasing hormones (GnRH), 222*t*
 Gonads, 343
 ovaries, 224*t*, 225, 346, 347, 347*f*, 348, 348*f*, 349, 358*f*, 363*f*
 testes, 224*t*, 225, 343, 344*f*, 345, 345*f*, 362*f*, 363*f*
 Gracilis muscles, 132*f*, 141*f*, 143*f*
 Granulocytes, 232
 Granulosa cells, 348*f*, 358*f*, 363*f*
 Grave's disease, 226*t*
 Gravitational pull, equilibrium and, 207, 208*f*
 Gray commissure, spinal cord, 183*f*, 356*f*
 Gray matter
 of brain, 151, 164*f*
 of spinal cord, 181–182, 183*f*, 356*f*
 Greater horns of hyoid bone, 83*f*
 Greater omentum, 316, 316*f*
 rat, 12
 Greater sciatic notch, 100*f*, 101*t*, 102*t*
 Greater trochanter of femur, 103*f*, 103*t*
 Greater tubercle of humerus, 97*t*, 98*f*
 Greater vestibular glands, 346*t*, 347*f*
 Greater wing of sphenoid bone, 80*f*, 81*f*, 81*t*, 82*f*, 84
 Groove, bone marking, 69*t*
 Gross anatomy, 1
 Ground substance, 42, 43*f*
 Growth hormone (GH), 222, 222*f*
 hyposecretion/hypersecretion of, 226*t*
 Gum (gingiva), 319, 319*f*
 Gustation. *See* Taste sense
 Gustatory cortex, 164*f*
 Gustatory epithelial cells, 210, 210*f*
 Gustatory hairs, 210, 210*f*
 Gyri of cerebral hemispheres, 163, 164*f*
- H zone, skeletal muscle fiber, 122
 Hair, 10*t*, 56*f*, 60–61, 60*f*
 Hair bulb, 60*f*, 61
 Hair cells, 205, 205*f*, 208*f*, 357*f*
 of equilibrium apparatus, 207, 207*f*, 208*f*
 hearing mechanism and, 205
 Hair follicle, 56*f*, 60–61, 60*f*, 61*f*
 Hair follicle receptor (root hair plexus), 56*f*
 Hair matrix, 60*f*, 61
 Hair papilla, 60*f*, 61
 Hair root, 56*f*, 60, 60*f*
 Hair shaft, 60*f*, 61, 61*f*
 Hallux region, 2*f*
 Hamate bone, 99*f*
 Hammer (malleus), 203*f*, 204*t*
 Hamstring muscles, 133*f*, 142*t*, 143*f*
 Hand (manus), 2
 bones, 98
 joints, 112*t*
 muscles, 136*t*, 137, 138
 nerves, 184*f*, 185*t*
 wrist joint, 111*f*
 Hard palate, 82*f*, 292*f*, 292*t*
- Harvard Step Test, 282–283
 Hastra, 317, 318*f*
 Haversian (central) canal, 46*f*, 72, 73*f*
 Haversian system (osteon), 72, 73*f*
 Head, 3
 arteries, 259–262, 260*f*
 bones (skull), 79–84
 muscles, 131, 132*f*, 134*t*, 135*f*
 veins, 265*f*, 266–267, 268*f*
 Head, bone marking, 69*t*
 of femur, 103*t*
 of fibula, 103*t*
 of humerus, 98*f*
 of radius, 98*f*
 of ulna, 98*f*
 Hearing sense
 ear anatomy, 203–205, 203*f*
 mechanism of, 205
 sensory areas and related association areas in brain for, 164*f*
 sensory receptors, 205
 sound waves and, 205
 Hearing tests (laboratory), 205–206
 Heart, 10*t*, 15, 16*f*, 245–256
 blood pressure determinations, 281–283, 281*f*
 cardiac cycle, 277–279, 278*f*
 cardiac muscle cells, 47, 48*f*, 249, 250*f*
 chambers, 246–247*f*, 250*f*
 dissection (sheep), 250–252, 251*f*
 location in thorax, 246*f*
 pathway of blood through, 248–249, 248*f*
 pulse/pulse points, 279–280, 280*f*
 rat, 12, 13*f*
 valves, 246–248, 247*f*
 Heart rate
 exercise effects on, 282–283
 observing postural effects, 282
 palpating pulse points, 280
 Heart sounds, 279
 auscultating, 279
 timing of, 278*f*
 Heat loss regulation, dermal blood supply and, 55, 57
 Hematocrit, 234
 determining, 234–235*f*
 normal values, 234
 Hematologic tests, 234–239
 Hemiazygos vein, 268*f*
 Hemoglobin concentration test, 235–237, 236*f*
 Hemoglobin, in urine, 336, 337*t*, 338
 Hemoglobinometer, 236–237, 236*f*
 Hemostasis, 231, 237, 237*f*
 Hepatic arteries, 262*t*, 263*f*
 Hepatic portal circulation, 269, 270*f*
 Hepatic portal vein, 266, 269, 270*f*
 Hepatic veins, 265*f*, 266, 267*f*, 270*f*, 320
 Hepatocytes, 320, 362*f*
 Hepatopancreatic ampulla, 316
 Hepatopancreatic sphincter, 316
 Hilum
 lung, 293, 295*f*
 renal, 331, 332*f*, 333*f*
 Hinge joints, 110*t*, 112*t*
 Hip
 arteries, 260*f*, 264
 bones, 99–101
 joint, 112*t*
 muscles, 133*f*, 140, 140*t*, 141*f*, 142, 142*t*, 143*f*
 veins, 265*f*, 266, 266*f*
 Hip (pelvic) girdle, 68*f*, 99–101, 100*f*
 Hormones, 221
 adrenal, 224*t*
 glucocorticoids, 224*t*
 hyposecretion/hypersecretion of, 226, 226*t*
 hypothalamus, 221, 222*f*, 223*t*
 pancreas, 224*t*
 parathyroid, 223*t*
 pituitary, 221–223
 steroid, 221, 225
 target cells of, 221
 thyroid, 223
 tropic, 221, 222*t*
 Horns (cornua) of hyoid bone, 83, 83*f*
 Human torso model, 15–16*f*
 Humerus, 68*f*, 96*f*, 97*t*, 98*f*
 epicondyles, 97*t*, 98*f*
 muscles that move, 136*t*, 137
 at shoulder joint, 95, 111*f*, 112*f*
 tubercles, 97*t*, 98*f*
 typical long bone structure of, 70*f*
 Hyaline cartilage, 45*f*, 111*f*
 ring, 359*f*
 Hydrolases (hydrolytic enzymes), 320
 Hydrolysis test of protein digestion, 322
 Hymen, 346*t*, 347*f*
 Hyoid bone, 83, 83*f*
 Hyperextension movement, 113, 114*f*
 Hyperinsulinism, 225
 Hyperopia, 201
 Hyperparathyroidism, 226*t*
 Hyperpolarization, 208*f*
 Hypersecretion of hormones, 226, 226*t*
 Hypertonic solution, 33
 Hyperventilation, 306
 Hypochondriac regions, 6, 6*f*
 Hypodermis (subcutaneous layer), 43*f*, 55, 56*f*, 60*f*
 Hypogastric (pubic) region, 2*f*, 6, 6*f*
 Hypoglossal canal, 81*f*
 Hypoglossal nerve (XII), 170*t*, 171*f*
 Hypoglycemia, 226*t*
 Hyponychium, 61*f*, 62
 Hypoparathyroidism, 226*t*
 Hypophyseal fossa of sella turcica, 81*f*
 Hyposecretion of hormones, 226, 226*t*
 Hypothalamus, 166*f*, 167, 226*f*
 releasing/inhibiting hormones of, 221, 222*f*, 223*t*
 Hypotonic solution, 33
- I (light) bands, 121, 122*f*
 Ileocecal valve, 316, 318*f*
 Ileum, 312*f*, 316, 318*f*, 361*f*
 Iliac arteries, 260*f*, 262*t*, 263*f*, 264, 264*f*
 Iliac crest, 69*t*, 100*f*, 101*t*, 141*f*
 palpating, 99
 Iliac fossa, 100*f*
 Iliac region, 6, 6*f*
 Iliac spine, anterior inferior/anterior superior, 99, 100*f*, 141*f*
 Iliac veins, 265*f*, 266, 266*f*, 267*f*
 Iliacus muscle, 140*t*, 141*f*
 Iliocostalis muscle, 139*f*
 Iliopsoas muscle, 132*f*, 140*t*, 141*f*
 Iliotibial tract, 133*f*
 Ilium, 68*f*, 100*f*, 101*t*
 Image formation in light microscopy, 367*f*
 Immobile joints, 109
 Incisive fossa, 82*f*
 Incisors (teeth), 318, 319*f*
 Incus (anvil) bone, 203*f*, 204*t*
 Indirect muscle attachments, 124
 Inferior colliculi, corpora quadrigemina, 166, 166*f*
 Inferior direction/orientation, 3, 3*f*
 Inferior gluteal line, 100*f*
 Inferior orbital fissure, 69*t*
 Inferior vena cava, 15, 16*f*, 246*f*, 247*f*, 248, 248*f*, 265, 265*f*, 267*f*
 rat, 14*f*, 15
 sheep, 251*f*
 veins draining into, 266
- Infraorbital foramen, 82*f*, 83*f*
 Infrapinnatus muscle, 133*f*, 139*f*
 Infrapinnatus fossa, 96*f*, 97*t*
 Infundibulum, 167, 347*f*, 348*f*
 Inguinal ligament, 137*f*
 Inguinal region, 2*f*
 Inhibiting hormones of hypothalamus, 221
 Initial segment of axon, 152*f*
 Inner layer of eye. *See* Retina
 Insertion/origin (skeletal muscle), 113, 113*f*, 124, 126
 Inspiration phase of breathing, 301, 302*f*
 Inspiratory capacity (IC), 303*f*
 Inspiratory reserve volume (IRV), 303*f*, 304–305
 Instep of foot, 101, 104*f*
 Insulin, 224*t*, 225
 hyposecretion/hypersecretion of, 226*t*
 Integration centers of CNS, reflex arcs and, 189, 189*f*, 190*f*
 Integumentary system, 55–66
 components, 10*t*
 functions, 55
 functions (overview), 10*t*
 structure, 55–59, 56*f*
 Interatrial septum, 246
 Intercalated discs of cardiac muscle, 47, 48*f*, 250*f*
 Intercarpal joints, 112*t*
 Intercondylar eminence of tibia, 103*f*, 104*t*
 Intercondylar fossa of femur, 103*f*, 103*t*
 Intercostal arteries, 260*f*, 261*f*, 262, 262*t*
 Intercostal muscles, 132*f*
 Intercostal nerves, 184, 184*f*
 Intercostal spaces, 88*f*
 Interlobar arteries, 333*f*, 334
 Interlobar veins, 333*f*, 334
 Intermaxillary suture, 82*f*
 Intermediate filaments, 20*f*, 21*t*
 Intermediate mass (interthalamic adhesion) of thalamus, 166*f*, 167
 Intermediate part of the urethra, 332, 344, 344*f*
 Internal acoustic meatus, 81*f*
 Internal (deep) direction/orientation, 3
 Internal ear, 207*f*
 anatomy, 203*f*
 equilibrium apparatus, 207
 hearing apparatus, 204*t*
 Internal oblique muscle, 132*f*, 136*t*, 137*f*
 Internal respiration, 291
 Interneurons, 154, 155*f*
 in reflex arcs, 189*f*, 190, 190*f*
 Interosseous artery, 261*f*
 Interosseous membrane
 of forearm, 98*f*
 of leg, 103*f*
 Interphalangeal joints, as hinge joints, 112*t*
 Interphase stage of cell life cycle, 23, 23*f*
 Interstitial endocrine cells, 345, 363*f*
 Interstitial lamellae, 73*f*
 Intertarsal joints, 112*t*
 Interthalamic adhesion (intermediate mass) of thalamus, 166*f*, 167
 Intertrochanteric crest, 103*f*, 103*t*
 Intertrochanteric line, 69*t*, 103*f*
 Intertubercular sulcus, 97*t*, 98*f*
 Interventricular arteries, 246*f*, 247*f*, 249*t*
 Interventricular foramen, 166*f*
 Interventricular septum, 246, 247*f*
 Interventricular sulcus, sheep, 251*f*
 Intervertebral discs, 45*f*, 84*f*, 85, 110*t*, 111*f*
 fibrocartilage of, 45*f*

- Intervertebral foramen, 84f
 Intestinal crypt, 317f, 361f
 Intestinal enzymes, 321f
 Intestines
 large. *See* Large intestine
 small. *See* Small intestine
 Intrinsic eye muscles, 202
 Inversion movement of foot, **113**, 115f
 Involuntary muscles, 47, 48f
 Ipsilateral response to reflex tests, **192**
 Iris, 198f, 199r
 cow eye, 199
 Irregular bones, **68**
 Ischial body, 100f
 Ischial ramus, 100f
 Ischial spine, 69r, 100f, 101, 101t
 Ischial tuberosity, 69r, 100f, 101t
 Ischium, 68f, 100f, 101t
 Islets of Langerhans (pancreatic islets), **225**, 361f
 Isotonic solution, **33**
 Isthmus of the fauces, 292f
- Jaws, muscles that move, 134r
 Jejunum, 312f, **316**
 Joint cavity, 110r, 112f
 Joints (articulations), 10r, 67, **109–119**
 disorders, 116
 projections helping to form, 69r
 Jugular foramen, 80r, 81f, 82f
 Jugular notch, 88, 88f, 97t
 Jugular veins, 265f, **266**, **267**, 268f
 Juxtaglomerular cells, 362f
 Juxtamedullary nephrons, **334**, 335f
- Keratin, **56**, 57t
 Keratinocytes, **56**, 57t
 Keratohyaline granules, 57t
 Ketone bodies, in urine, 336, 337t, 338
 Kidney stones (renal calculi), **336**
 Kidneys, 10r, 15, 16f, **331**, 332f
 blood supply, 332f, 333f, 334, 335f
 capillary beds, 334, 335f
 dissection, 333
 histology, 362f
 inflammations of, 336
 nephrons, 334–336, 335f
 rat, 14f, **15**
 stones, **336**
 tubules, simple cuboidal epithelia of, 39f
- Kinetic energy, diffusion and, 29
 Kinetochore, 23f
 Kinetochore microtubule, 23f
 Kinocilium, 207f, 208f
 Knee joint, 101
 muscles, 140r, 141f
 Kneecap (patella), 68f, **101**
 Knee-jerk (patellar) reflex, **190**, 190f, 191f
 testing, 190–191
 Knuckle (metacarpophalangeal joint), 99, 112t
 Kyphosis, 85, 85f
- Labia (lips), of mouth, **314**, 314f
 Labia majora, 346r, 347f
 Labia minora, 346r, 347f
 Labial frenulum, superior/inferior, 314f
 Lacrimal apparatus, 196r
 Lacrimal bones, 80f, 82r, 83f
 Lacrimal canaliculi, 196f, 196r
 Lacrimal caruncle, 196f, 196t
 Lacrimal fossa, 80f, 82t
 Lacrimal glands, 196f, 196t
 Lacrimal punctum, 196f, 196t
 Lacrimal sac, 196f, 196t
 Lacteal, **316**, 317f, 321f
 Lacunae, 42, 45f, 46f, **72**, 73f
 Lambda suture, **79**, 80f
 Lamellae, 46f, **72**, 73f
 Lamellar corpuscle, 56f, 57, 58, 357f
- Lamellar granules, 57t
 Lamina of vertebra, 85, 85f
 Lamina propria
 of areolar connective tissue, 43f
 of GI tract, 313f, 313r, 360f, 361f
 of olfactory epithelium, 357f
 of respiratory organs, 359f
 Landmarks, anatomical, 1–3
 Langerhans (dendritic) cells, 56
 Large intestine, 6f, 10r, 15, 16f, 312f, **317**, 318f
 digestive functions, 317
 histology, 361f
 rat, **12**, 13f
 Laryngeal cartilages, 291
 Laryngopharynx, 292f, 292t, 314f, **315**
 Larynx, 10r, 292f, **293**
 Lateral columns (funiculi) of spinal cord, **182**, 183f, 356f
 Lateral commissure of eyelids, **196**, 196f
 Lateral horns of spinal cord, **181**, 182, 183f
 Lateral malleolus of fibula, 103f, 104r
 Lateral sulcus of cerebral hemisphere, **163**, 164f
 Lateral/medial orientation/direction, **3**
 Latissimus dorsi muscle, 133f, 137, 138r, 139f
 Left colic (splenic) flexure, **317**, 318f
 Left lower quadrant (LLQ), 6f
 Left upper quadrant (LUQ), 5, 6f
 Leg
 arteries, 264
 bones, 101, 103f
 muscles, 132f, 133f, 140, 140r, 141f, 142, 142r, 143f
 nerve supply, 185r, 186f
 veins, 265f, 266, 266f
 Lens, 197, 198f
 astigmatism and, **201**
 cow eye, 199, 200f
 elasticity of, 201
 Lesser horn of hyoid bone, 83f
 Lesser omentum, **316**, 316f
 Lesser sciatic notch, 100f
 Lesser trochanter of femur, 103f, 103r
 Lesser tubercle of humerus, 97r, 98f
 Lesser wing of sphenoid bone, 81f, 81r
 Leukemia, 234
 Leukocytes (white blood cells/WBCs), **231**, 233f
 microscopic examinations, 232–233, 363f, 364f
 normal blood values, 234
 total counts, 234
 in urine, 336, 337t
 Leukocytosis, 234
 Leukopenia, 234
 Levator labii superioris muscle, 135f
 Levator scapulae muscle, 139f
 LH (luteinizing hormone), 222f, 222t
 Life cycle of cell
 cell division, **23–24**, 23–24f
 interphase, **23**
 Ligaments, 10r, 110
 attachment sites, 69r
 composed of connective tissue, 42
 tearing of, 116
 Ligamentum arteriosum, 246f
 sheep, **251**, 251f
 Ligamentum teres, 316f
 Light (l) bands, 121, 122f
 Light ray refraction, **201**
 close/distant vision and, 201
 eye reflexes and, 202
 Limbs
 lower. *See* Lower limbs
 upper. *See* Upper limbs
 Line, bone marking, 69t
 Linea alba, 137f
 Linea aspera of femur, 103f
- Lingual frenulum, **314**, 314f
 Lingual tonsil, 292f, 292t, **314**, 314f
 Lipid droplets, 21
 Lipid metabolism site, 21r
 Lipid structure of plasma membrane, 20
 Lipid synthesis site, 21r
 Lipids digestion, 320, 321f
 Lips (labia), mouth, **314**, 314f
 Liver, 6f, 10r, 15, 16f, 312f, 316f, **320**
 cytoplasmic division and, 23
 digestive functions, 320
 histology, 361f, 362f
 lobules, 320, 361f
 peritoneal attachments of, 316f
 portal triad region, **320**, 361f
 rat, 13f, **15**
 LLQ (left lower quadrant), 6f
 Lobar arteries, **267**, 269f
 Lobes, lung, 293f, 294, 295f
 Lobule (earlobe), 203f, 204r
 Loin region, 2f, 3
 Long bones, **68**, 70–71, 70f
 Longissimus muscle, 139f
 Longitudinal fissure of cerebral hemispheres, **163**, 165f, 173f
 Loose connective tissues, **42**
 adipose, 43f
 areolar, 43f
 reticular, 44f
 Lordosis, 85, 85f
 Lower limbs, 68f
 arteries, 260f, 264, 264f
 bones, 101, 103–104f, 103–104r
 muscles, 132f, 133f, 140, 140r, 141f, 142, 142r
 nerve supply, 185r, 186, 186f
 palpating surface anatomy, 104, 142
 veins, 266, 266f
 Lower respiratory tract, 293–296
 Lugol's iodine, 32r
 Lumbar arteries, 262r, 263f
 Lumbar curvature, 84f
 Lumbar plexus, 184f, 185r, **186**, 186f
 Lumbar regions, 3f, **6**, 6f
 Lumbar spinal nerves, 182f, 184f
 Lumbar veins, 265f, **266**, 267f
 Lumbar vertebrae, 84
 regional features, 86f
 Lunate bone, 99f, 111f
 Lungs, 10r, 15, 16f, 293f, 294, 295f
 examining slides, 296, 359f
 operating model lung, 301–302
 pleural coverings of, 294, 295f
 rat, **12**, 13f
 sheep, demonstrating inflation in, 296
 Lunule of nail matrix, 61, 61f
 LUQ (left upper quadrant), 6f
 Luteinizing hormone (LH), 222f, 222t
 Lymph nodes, 10r, 358f
 Lymphatic vessels, 10r, 358f
 Lymphatic/immune system, 10r
 Lymphocytes, **233**, 233f, 363f, 364f
 Lysosomal enzymes, Golgi apparatus, 21r
 Lysosomes, 20f, 21r
- M line, 122f
 Macula lutea, **197**, 198f
 Maculae, **207**, 207f, 208f
 Magnesium ions (Mg²⁺), in muscle contraction, 123–124
 Magnification in light microscopy, total, **367**
 Main (primary) bronchi, **293**, 293f
 Major calyx of renal pelvis, **333**, 333f
 Male reproductive system, 10r, 225, 343–346, 346f
 histology, 362f, 363f
 rat, 14f, 15
 Malleolus of leg bones, lateral/medial, 103f, 104, 104r
- Malleus (hammer) bone, 203f, 204r
 Mammary glands, 43f
 Mammary region, 2f
 Mammillary bodies, 165, 165f, 166f, **167**
 Mandible, 80f, 82r, 83f
 muscles that move, 134r
 Mandibular angle, 80f
 palpating, 84
 Mandibular fossa, 80r, 82f
 Mandibular notch, 80f, 82r
 Mandibular ramus, 80f, 82t
 Mandibular symphysis, 83f
 Manubrium of sternum, **88**, 88f
 clavicle and, 96f
 Manus region, 2f.
 bones of, 98, 99f *See also* Hand
 Marginal arteries, 246f, 249r
 Marrow, bone, 71
 Masseter muscle, 132f, 134r, 135f
 palpating, 131
 Mastication, muscles of, 134r, 135f
 Mastoid process, 80f, 80r, 82f, 83
 Matrix, hair, 60f, **61**
 Maxilla/maxillae, 80f, 82f, 82r, 83f
 Maxillary sinus, 84f
 Meatus, 69r
 Medial commissure of eyelids, **196**, 196f
 Medial malleolus of tibia, 104, 104r
 Medial/lateral orientation/direction, **3**
 Median cubital vein, **267**, 268f
 Median (midsagittal) plane, **4**, 4f
 Median (midsagittal) section, 4f
 Median nerve, 184f, **185**, 185r
 Median sacral crest, **87**, 87f
 Mediastinal arteries, 260f, 262t
 Mediastinum, **5**, **245**, 294, 295f
 Medulla oblongata, of brain stem, 164f, **165**, 165f, 166f
 Medulla, renal, **333**, 333f, 335f
 Medullary cavity of long bone, 70f, 71
 Medullary (renal) pyramids, **333**, 333f
 Megakaryocytes, **233**
 Melanin, **56**
 Melanocytes, **56**
 of hair matrix, 60f
 Melatonin, **226**
 Membranes, formed by epithelial cells, 37
 Membranous labyrinth of inner ear, 204r
 Meningeal layer of dura mater, 167, 168f
 Meninges
 brain, **167**, 168f
 spinal cord, 181
 Mental foramen, 80f, 83f
 Mentalis muscle, 135f
 Merkel (tactile) cells, **57**
 Mesenteric arteries, 260f, 262r, 263f
 Mesenteric veins, **269**, 270f
 Mesenteries
 of small intestine, **316**, 316f, 318f
 of stomach, 315–316, 316f
 Mesentery, rat, **15**
 Mesometrium, 348f
 Mesosalpinx, 348f
 Mesovarium, 348f
 Metacarpal bones, 68f, **98**, 99f
 Metacarpophalangeal joint (knuckle), 112r
 palpating, 99
 Metaphase plate, 24f
 Metaphase state of mitosis, **23**, 24f
 Metatarsal arteries, 264f
 Metatarsal bones, 68f, **101**, 104f
 Metatarsal veins, 266f
 Methylene blue dye, 30f
 Microfilaments, 20f, 21r
 Microscope, 365–372
 compound, care and structure of, **365–370**
 depth of field in, **370–371**

- Microtubules, 20*f*, 21*t*, 23
 mitotic spindle as, **23**, 23–24*f*
 Microvilli, **20**, 20*f*, 40*f*, 42
 of GI tract, **316**, 317*f*, 355*f*
 Midbrain, **165**, 165*f*, 166*f*
 Middle ear anatomy, 203*f*, 204*t*
 Midsagittal (median) plane, 4*f*
 Mineralocorticoids, 224*t*
 Minor calyx of renal pelvis, **333**, 333*f*
 Mitochondria, 20*f*, 21*t*, 125, 125*f*
 Mitosis, **23–24**, 23–24*f*
 daughter nuclei products of, 23
 function of, 23
 Mitotic spindle, **23**, 23–24*f*
 early, 23*f*
 Mitral (bicuspid) valve of heart, **246**, 247*f*
 Mitral cell (output cell), 209*f*
 Mixed nerves, **157**
 Molars (teeth), **318**, 319*f*
 Monocytes, **233**, 233*f*, 363*f*, 364*f*
 Monosynaptic reflex arcs, 190, 190*f*
 Mons pubis, 346*t*, 347*f*
 Motor (descending) tracts of CNS, 182
 Motor (efferent) nerves, **157**
 Motor (efferent) neurons, **154**, 155*f*
 in muscle contraction, 124
 in reflex arcs, 189, 189*f*, 190*f*
 structure of typical, 152*f*
 Motor unit, **124**, 125*f*, 355*f*
 Mouth (oral cavity), 10*t*, 312*f*, **314**, 314–315, 314*f*
 digestion and absorption in, 321*f*
 digestive functions, 314–315
 muscles, 134*t*
 rat, 11
 Movement, body
 function of joints in, 109, 112*t*
 skeleton as lever system for, 67
 types of, 113–116, 114*f*
 Mucosa (mucous membrane), of GI tract, 40*f*, 312, 313*f*, 313*t*, **314**, 315*f*, 317*f*, 360*f*
 Mucosal glands of stomach, 316
 Mucus of goblet cell, 40*f*
 Multiaxial joints, 111*f*, 113
 Multiaxial movement, **112**, 112*t*
 Multipolar neurons, **154**, 154*f*, 355*f*
 Muscle attachment sites, 69*t*, 126
 Muscle contraction, 121, 123
 observing, 123–124
 Muscle fibers, skeletal, **121–124**, 122*f*, 123*f*, 355*f*. *See also* Skeletal muscles
 Muscle, skeletal. *See* Skeletal muscles
 Muscle spindle, 357*f*
 Muscle tissue, 9, 37, **47**
 cardiac, **47**. *See also* Cardiac muscle
 rat, 11*f*, 12
 skeletal, **47**. *See also* Skeletal muscles
 smooth, **47**, 48*f*. *See also* Smooth muscle tissue
 Muscular system, 10*t*, 121, 131–149.
 of head and neck, 131, 134*t*, 135*f*
 of hip/lower limb, 140–143, 140*t*, 141*f*, 142*t*, 143*f*
 making a muscle painting, 142
 of shoulder/upper limb, 136*t*, 137–138, 137*f*, 138*t*, 139*f*
 superficial muscles, 132*f*, 133*f*
 of trunk, 131, 136–137, 136*t*, 137*f*, 138*t*, 139*f*. *See also* Skeletal muscles
 Muscularis externa, 312, 313*f*, 313*t*, **314**, 360*f*, 361*f*
 of large intestine, 317
 of stomach, 315*f*, 316
 Muscularis mucosae, 313*f*, 313*t*, 317*f*, 360*f*, 361*f*
 Musculocutaneous nerve, 184*f*, 185*t*, **186**
- Myelin, 152
 Myelin sheath gaps (nodes of Ranvier), **152**, 152*f*, 356*f*
 Myelin sheaths, **152**
 identifying, 153, 356*f*
 of peripheral nerve, 157*f*, 356*f*
 Myelinated axons, 356*f*
 Myelinated nerve fibers, 151, **152**, 153*f*
 identifying, 153, 356*f*
 Myelination of nerve fibers
 by oligodendrocytes in CNS, **152**
 by Schwann cells in PNS, 151, **152**, 153*f*
 Myenteric plexus (GI tract), 313*f*, 313*t*
 Myocardium, **245**, 247*f*
 Myofibrils, **121**, 122*f*, 125*f*
 Myofilaments, **121**, 122*f*, 125*f*
 Myometrium, 348*f*
 Myopia, **201**
 Myosin, **121**
 Myosin filaments, 122*f*
 Myxedema, 226*t*
- Nail bed/folds/matrix, 61*f*, **62**
 Nails, 10*t*, 61–62, 61*f*
 Na⁺-K⁺ (sodium-potassium) pump, 155, 156*f*
 Nares (nostrils), 292*f*, 292*t*
 Nasal bones, 80*f*, 82*t*, 83*f*
 palpating, 84
 Nasal cavity, 292*f*, 292*t*, 357*f*
 Nasal conchae, 81*t*, 82*t*, 83*f*, 292*f*, 292*t*
 Nasal meatuses, 292*f*
 Nasal region, 2*f*
 Nasal vestibule, 292*f*
 Nasolacrimal duct, 196*f*, 196*t*
 Nasopharynx, 292*f*, 292*t*, **315**
 Navel, 2
 Navicular bone, 104*f*
 Near point of vision, **201**
 Near vision, 201
 Neck
 arteries, 259–262, 260*f*
 muscles, 131, 132*f*, 133*f*, 134*t*, 135*f*, 137*f*, 138*t*, 139*f*
 tooth, **319**, 319*f*
 veins, 265*f*, 266–267, 268*f*
 Nephron loop, **334**, 335*f*
 Nephrons, 334–336, 335*f*
 cortical, **334**, 335*f*
 juxtamedullary, **334**, 335*f*
 Nerve(s), 10*t*, **157**, 358*f*
 nerve endings in skin, 57–58
 structure, 157
 Nerve fibers, **151**, 356*f*. *See also* Axons (nerve fibers)
 Nerve impulses, 151, **155**, 208*f*
 in muscle contraction, 124
 physiology of, 155, 156*f*
 transmission of, 151–152, 155, 156*f*
 Nerve plexuses
 GI tract, 313*f*, 313*t*
 spinal, **184**, 184*f*, 185–186, 185*t*
 Nervous system
 central. *See* Central nervous system (CNS)
 components, 10*t*
 functions (overview), 10*t*
 peripheral. *See* Peripheral nervous system (PNS)
 Nervous tissue, 9, 37, **49**, 49*f*
 neurons, **151–157**
 supporting cells, 49, 151
 Neural (nervous tissue) layer of retina, 197, 197*f*, 199*t*
 Neurofibrils, 151, 355*f*
 Neuroglia (glial cells), **49**, **151**
 oligodendrocytes in CNS, **152**
 Schwann cells of PNS, 151, **152**
 Neuromuscular junction, **124–126**, 125*f*, 355*f*
- Neuron cell bodies, 49*f*, **151**, 152*f*, 355*f*, 356*f*
 bipolar, 154*f*
 clusters, in CNS. *See* Nuclei clusters, in PNS. *See* Ganglia
 fibers (processes), 151
 multipolar, 154*f*
 neurofibrils, 151
 Nissl bodies (chromatophilic substance), **151**, 152*f*
 unipolar (pseudounipolar), **154**, 154*f*, 356*f*
 Neurons, **49**, **151–162**
 action potential (nerve impulse)
 physiology, 155, 156*f*
 anatomy, 49*f*, 151–153, 152*f*
 functional classes, 154, 155*f*
 identifying parts of, 153, 355*f*
 motor, structure of typical, 152*f*
 nucleus, 151, 152*f*
 structural classes, 154, 154*f*
 typical structure, 151, 152*f*
 Neurotransmitters, 151–152
 released in action potential (nerve impulse), 155
 Neutrophils, **232**, 233*f*, 363*f*
 Nissl bodies (chromatophilic substance), **151**, 152*f*
 Nodes of Ranvier (myelin sheath gaps), **152**, 152*f*, 356*f*
 Nonkinetochore microtubule, 23*f*
 Norepinephrine, **224**, 224*t*
 Nose, 2, 10*t*, 292*f*, 292*t*
 Nostrils (nares), 292*f*, 292*t*
 Notch, bone, 69*t*
 Nuchal line, inferior/superior, 82*f*
 Nuclear envelope, **19**, 20*f*, 23–24*f*
 Nuclear pores, 19, 20*f*
 Nuclei
 basal, 167
 cerebral, **151**, **167**
 Nucleic acid digestion, 321*f*
 Nucleolus/nucleoli, **19**, 20*f*, 23–24*f*, 355*f*
 of neuron, 152*f*, 153
 Nucleus, **19**, 20*f*
 of cardiac muscle cell, 250*f*
 of fat cell, 43*f*
 of neuroglial cell, 152*f*, 355*f*
 of neuron, 151, 152*f*, 153, 355*f*
 of Schwann cell, 153*f*, 356*f*
 of skeletal muscle cell, 47*f*, 121, 122*f*, 123*f*
 of smooth muscle cell, 48*f*
 of squamous epithelial cells, 39*f*, 41*f*
 Nystagmus, **208**
- Obturator artery, 264*f*
 Obturator foramen, **99**, 100*f*
 Obturator nerve, 185*t*, 186*f*
 Occipital bone, 80*f*, 80*t*, 81*f*, 82*f*
 basilar part of, 82*f*
 Occipital condyle, 80*t*, 82*f*
 Occipital crest, external, 82*f*
 Occipital lobe, **163**, 164*f*
 Occipital protuberance, external, 82*f*
 Occipital region, 3*f*
 Occipitomastoid suture, 80*f*
 Occulomotor nerve (III), 170*t*, 171*f*
 Oil (sebaceous) glands, 56*f*, **59**, 60*f*
 Olecranon region, 3*f*
 Olecranon fossa of humerus, 97*t*, 98*f*
 Olecranon process of ulna, 97*t*, 98*f*
 palpating, 99
 Olfaction. *See* Smell sense
 Olfactory bulbs, 165, 165*f*, 171, 171*f*, 209*f*
 Olfactory cilia, 357*f*
 Olfactory epithelium, **209**, 209*f*, 357*f*
 Olfactory nerves (I), 170*t*, 171*f*, 209*f*, 210
 Olfactory receptors, 209–210, 209*f*
- Olfactory sensory neurons, **209**, 209*f*, 357*f*
 Olfactory stem cell, **209**, 209*f*, 357*f*
 Olfactory tracts, 165, 165*f*, 209*f*
 Oligodendrocytes, **152**
 Omentums, greater/lesser, **316**, 316*f*
 Oocyte, 358*f*, 363*f*
 Optic canal, 81*f*, 81*t*, 83*f*
 Optic chiasma, 165, 165*f*, 166*f*
 Optic disc (blind spot), **197**, 198*f*, 200–201, 201*f*
 cow eye, 200*f*
 Optic nerves (II), 165, 165*f*, 170*t*, 171*f*, 198*f*
 cow eye, 199, 200*f*
 Optic tracts, 165, 165*f*
 Ora serrata, 198*f*
 Oral cavity. *See* Mouth
 Oral orifice, **314**
 Oral region, 2*f*
 Oral vestibule, **314**, 314*f*
 Orbicularis oculi muscle, 132*f*, 134*t*, 135*f*
 Orbicularis oris muscle, 132*f*, 134*t*, 135*f*
 Orbital fissures, inferior/superior, 81*t*, 83*f*
 Orbital region, 2*f*
 Organ systems, 9–18, 10*t*
 of rat, 9, 11–15
 Organelles, cytoplasmic, **21**, 21*t*
 Organs, **9**, **37**
 Orientation of body, anatomical terms, 3, 3*f*
 Origin/insertion (skeletal muscle), **113**, 113*f*, 124, 126
 Oropharynx, 292*f*, 292*t*, 314*f*, **315**
 Os, internal/external, 348*f*
 Osmosis, **29**, 32
 Ossa coxae (coxal bones), **99**, 100*f*
 Osseous tissue (bone), **42**, 46*f*
 in compact bone, 67, 72–73, 73*f*
 in spongy bone, 67, 70*f*, 71, 73*f*
 Ossicles of tympanic cavity, 203*f*, 204*t*
 Osteocytes, 46*f*, **72**, 73*f*
 Osteon (Haversian system), **72**, 73*f*
 Otic region, 3*f*
 Otolith membrane, **207**, 208*f*
 Otoliths, **207**
 Outer collar of the perinuclear cytoplasm, **152**, 153*f*
 Oval window, 203*f*, 204*t*
 Ovarian arteries, 260*f*, 262*t*, 263*f*
 Ovarian ligaments, **347**, 348*f*
 Ovarian veins, 265*f*, 266
 Ovaries, 10*t*, 224*t*, 225, 346, **347**, 347*f*, 348*f*
 histology, 358*f*, 363*f*
 microscopic study, 349
 rat, 14*f*, **15**
 Ovulation, **347**
 Oxidase enzymes, 21*t*
 Oxygen
 cell membrane transport and, 29
 cell's need for, 291
 lack of, effects on skin, 284
 Oxytocin, 223*t*
- Pain receptors in skin, 57–58
 Palate, **314**
 hard/soft, 292*f*, 292*t*, **314**, 314*f*
 Palatine bones, 82*f*, 82*t*
 Palatine process of maxilla, 82*f*, 82*t*
 Palatine raphe, 314*f*
 Palatine suture, median, 82*f*
 Palatine tonsils, 292*f*, 292*t*, **314**, 314*f*, 359*f*
 Palatoglossal arch, 314*f*
 Palatopharyngeal arch, 314*f*
 Palm of hand, bones, 98, 99*f*
 Palmar arches, deep/superficial, 261*f*
 Palmaris longus muscle, 132*f*
 Palpebral conjunctiva, 196*f*, 196*t*

- Pancreas, 10r, 15, 16f, 312f, **320**, 361f
 digestive functions, 320
 histology, 361f
 hyperinsulinism experiment, 225
 microscopic examination, 225
 rat, **15**
- Pancreatic duct, **316**
- Pancreatic islets (islets of Langerhans), **225**, 361f
- Papillae
 dermal, 56f, **57**
 hair, 60f, **61**
 taste bud, **210**, 210f, 357f
- Papillary dermis, 56f, **57**
- Papillary muscle of heart, **246**, 247f
- Papilliferous (C) cells, **223**
- Paranasal sinuses, 83, 84f, 292t
- Parathyroid glands, 10r, 223, 226f
- Parathyroid hormone (PTH), **223**, 223t
 hyposecretion/hypersecretion of, 226t
- Parfocal microscopes, **368–369**
- Parietal bones, 79, 80f, 80r, 81f, 82f, 83f
- Parietal layer
 of glomerular capsule, 334t, 335f
 of pericardium, **245**
- Parietal lobe, **163**, 164f
- Parietal pleura, **294**, 295f
- Parieto-occipital sulcus, **163**, 164f
- Parotid glands, 312f, **319**
- Passive transport processes, **29–36**
 diffusion, **29–33**
 filtration, 33–34
- Patella (kneecap), 68f, **101**
 palpating, 104
- Patellar bursa, 116
- Patellar reflex, **190**, 190f, 191f
 testing, 190–191
- Patellar region, 2f
- Patellar surface, 103f
- Pectinate muscles, 247f
- Pectineus muscle, 132f, 141f
- Pectoral (shoulder) girdle, 68f, **95**,
 96f, 97t
 palpating surface anatomy of, 98–99
- Pectoralis major muscle, 132f, 136t,
 137, 137f
- Pectoralis minor muscle, 132f
- Pedicle, 85, 85f
- Pelvic brim, 100f, 102t
- Pelvic cavity, **5**
- Pelvic (hip) girdle, 68f, **99–101**, 100f
- Pelvic inlet/brim, **101**, 102t
 in females vs. males, 102t
- Pelvic outlet, **101**
 in females vs. males, 102t
- Pelvic region, 2f
- Pelvis, **99**
 arteries, 260f, 264, 264f
 bony, 99, 100f
 false, **101**
 of females vs. males, 101, 102t
 muscles, 132f, 140–143, 140r, 141f,
 142t, 143f
 true, **101**, 102t
- Penis, 10r, **332**, **344**, 344f
 histology, 362f
 rat, 14f, **15**
 urethra, 332
- Perforating (Sharpey's) fibers, 70f, **71**, 73f
- Perforating (Volkmann's) canals, **72**, 73f
- Pericardial arteries, 260f, 262t
- Pericardial cavity, **5**
- Pericardium
 epicardium (visceral layer), **245**, 247f
 fibrous, **245**
 parietal layer of, **245**
 serous, 245
- Perilymph, 204t, 205, 205f
- Perimetry, 347f, 348f
- Perimysium, **124**, 125f
- Perineum, female, **346**
- Perineurium, **157**, 157f, 356f
- Periodontal ligament, **319**, 319f
- Periosteal layer of dura mater, 167, 168f
- Periosteum, 70f, **71**, 73f
- Peripheral nervous system (PNS), **163**
 cranial nerves, **170–171**, 170r, 171f
 distribution of major nerves, 184f, 186f
 nerve structure of, 356f
 nerves, structure of, **157**
 neuron cell bodies in (ganglia), **151**
 supporting cells in, 151
- Perirenal fat capsule, 331
- Peristalsis, 315
 peristaltic movements, **324**
- Peritubular capillary beds, **334**, 335f
- Permanent teeth, **318**, 319f
- Peroxisomes, 20f, 21t
- Perpendicular plate of ethmoid bone,
 81t, 83f
- Perspiration, 59
- Peyer's patches, **317**, 361f
- PF₃ from platelets, **237**, 237f
- pH
 of blood plasma, 232
 of urine, 336
- Phagocytes
 dermal, 57
 neuroglia acting as, 151
- Phalanges
 of foot, 68f, **101**, 104f
 of hand, 68f, **98**, 99f
- Pharyngeal tonsils, 292f, 292t
- Pharyngotympanic (auditory) tube,
 203f, 204t, 292f, 292t
- Pharynx, 10r, 292t, 312f, 314f, 315
- Phosphatidylserine (platelet factor 3),
237, 237f
- Phospholipid bilayer of plasma
 membrane, 20, 21f
- Photopupillary reflex, 192
- Photoreceptors, **197**, 197f
 color, 202
- Phrenic arteries, 260f, 262, 262t, 263f
- Phrenic nerve, **185**, 185t
- Phrenic veins, 267f
- Physical fitness index, 283
- Physiological saline, 33
- Pia mater, **167**, 168f, 183f
- Pigment granules, 21
- Pigmented choroid coat, cow eye, 199,
 200f
- Pigmented layer of retina, **197**, 197f,
 199t, 357f
- Pineal body/gland, 10t, 166f, **167**,
 226, 226f
- Pinna (auricle) of outer ear, 46f, 203f, 204t
- Pisiform bone, 99f
- Pituitary dwarfism, 226t
- Pituitary gland, 10r, 165, 165f, 166f,
167, 221
 hormones, 221–223, 222f, 222t, 223t
- Pivot joints, 110t, 112t
- Plane joints, 110t, 112t
- Planes, body, **4**, 4f
- Plantar arteries, 264f
- Plantar flexion movement of foot,
113, 115f
- Plantar reflex, **191–192**, 191f
- Plantar veins, **266**, 266f
- Plantaris muscle, 143f
- Plasma, blood, **231**, 233f
 determining pH/color/clarity/
 consistency, 232
 normal percentage of whole blood,
 231, 233f
- Plasma membrane, **19**, **20**, 20f, 23f
 cell transport mechanisms and, 29–36
 respiratory gases and, 29
 selective (differential) permeability
 of, **29**
 structure, 21f
- Platelets, **231**, 233, 233f, 363f
 blood clotting and, 237, 237f
- Platysma muscle, 132f, 134t, 135f
- Pleura, **294**, 295f
- Pleural cavity, 5, 294, 295f
- Plexuses, spinal nerve, **184**, 184f,
 185–186, 185t
- Pneumograph, **305**
- Podocytes, 334t, 335f
- Polarization, in action potential (nerve
 impulse), **155**, 156f
- Pollex region, 2f
- Polycythemia, **234**
- Polysynaptic reflex arcs, 190, 190f
- Pons, **165**, 165f, 166f
- Popliteal artery, **264**, 264f
 as pulse point, 280, 280f
- Popliteal region, 2f, 3
- Popliteal vein, **266**, 266f
- Pores, sweat, 56f, 59
- Portal circulation, hypothalamus/
 anterior pituitary, 221
- Portal triad, **320**, 361f
- Posterior direction/orientation, **3**, 3f
- Posterior (dorsal) columns of spinal
 cord, **182**, 183f
- Posterior (dorsal) horns of spinal cord,
181, 183f, 356f
- Posterior gluteal line, 100f
- Posterior inferior iliac spine, 100f
- Posterior pituitary, **221**, 222f
- Posterior pituitary hormones, 221
- Posterior segment of eye, **197**
- Posterior superior iliac spine, 100f, 101t
- Posture, effects on blood pressure, 282
- Potassium ions (K⁺)
 in action potential (nerve impulse),
 155, 156f
 in muscle contraction, 123–124
- Potassium permanganate dye, 30f
- Prefrontal cortex, 164f
- Premolars (bicuspid), **318**, 319f
- Premotor cortex, 164f
- Prepuce of the clitoris, 346t
- Presbyopia, **201**
- Pressure receptors, 58
 adaptation demonstration, 59
 tactile localization test, 58–59
 two-point threshold test, 58
- Primary auditory cortex, 164f, 165t
- Primary follicle of ovary, 348f, **349**,
 349f, 363f
- Primary (main) bronchi, **293**, 293f
- Primary motor cortex, 164f, 165t
- Primary olfactory cortex, 165t
- Primary somatosensory cortex, 164f, 165t
- Primary visual cortex, 164f, 165t
- Prime mover (agonist) muscles, **126**
- PRL (prolactin), 222f, 222t
- Process, bone marking, 69t
- Progesterone, 224t, **225**
- Projection tracts (cerebral hemisphere),
 167
- Prolactin (PRL), 222f, 222t
- Pronation movement, **113**, 115f
- Pronator teres muscle, 132f, 136t
- Prophase state of mitosis, **23**, 23f
- Propulsion mechanisms (digestion),
 323–324
- Prostate gland, 344f, 344t
 rat, 14f
- Prostatic urethra, 332, **344**, 344f
- Protein(s)
 keratin, **56**, 57t
 in plasma membrane, 20, 21f
 in ribosomes, 21t
 synthesis site, 21t
 in urine, 336, 337t, 338
- Protein digestion, 320, 321f, 322, 322f
- Prothrombin, **237**, 237f
- Prothrombin activator, **237**, 237f
- Proximal convoluted tubule, **334**, 335f
- Proximal direction/orientation, **3**, 3f
- Proximal radioulnar joint, 110r, 112t
- Pseudostratified epithelia, **38**, 40f, 359f
- Pseudounipolar (unipolar) neurons,
154, 154f, 356f
- Psoas major muscle, 140t, 141f
- Psoas minor muscle, 141f
- Pterygoid processes, 81t
- PTH (parathyroid hormone), **223**,
 223t, 226t
- Pubic angle/arch, 100f
 in females vs. males, 102t
- Pubic body, 100f
- Pubic bones (pubis), 68f, 100f, 101t
 joint of, 111f
 rami of, **99**, 101t
- Pubic crest, 100f
- Pubic (hypogastric) region, 2f, **6**, 6f
- Pubic ramus, inferior/superior, 100f, 101t
- Pubic symphysis, **99**, 100f, 110r, 111f
- Pubic tubercle, 100f
- Pubis. *See* Pubic bones
- Pulmonary arteries, 246f, 247f, 248f,
249, 267, 269f
 sheep, 251f
- Pulmonary capillaries, 248f, **267**
- Pulmonary circuit/circulation, **248**,
 248f, 267, 269f
 gas exchange and, 291
- Pulmonary (SL) valve, 247f, **248**
- Pulmonary trunk, 246f, 247f, **249**,
267, 269f
 sheep, 251f
- Pulmonary veins, 246f, 247f, 248f,
 249, **267**, 269f
 sheep, 251f
- Pulmonary ventilation. *See* Breathing
- Pulp, **319**
- Pulp cavity, **319**, 319f
- Pulse, **279**
 deficit, **280**
- Pulse points, 280, 280f
- Pupil, 198f, 199t
- Pupillary reflexes, 202–203
 accommodation reflex, 202–203
 light reflex, **192**
- Purkinje cells of cerebellum, 355f
- Pyelonephritis, 336
- Pyloric antrum, 315f, 315t
- Pyloric canal, 315f, 315t
- Pyloric sphincter, 315f, 315t
- Pylorus, 315f, 315t
- Quadrants of abdominopelvic cavity,
5, 6f
- Quadratus lumborum muscle, 141f
- Quadriceps femoris muscle, 140t,
 141f, 142
- Radial artery, 261f, **262**
 as pulse point, 280, 280f
- Radial fossa, 97t, 98f
- Radial groove, 98f
- Radial nerve, 184f, **185**, 185t
- Radial notch of ulna, 98f
- Radial styloid process, 97t
- Radial tuberosity, 97t, 98f
- Radial vein, **267**, 268f
- Radiocarpal joints, 112t
- Radioulnar joints, 98f
- Radius, 68f, 97t, **98**, 98f, 99f
 at elbow and wrist joints, 111f
- Rami of the pubic bone, **99**
- Ramus, 69t
- Rat dissection, 9–15, 11f, 12f, 13–14f
- RBCs (red blood cells). *See* Erythrocytes
- Real image, **201**, 201f
 in light microscopy, **367**, 367f

- Receptors, sensory. *See* Sensory receptors
- Receptors, special sense, 195–212
eye, 195–203, 197*f*
in reflex arcs, 189, 189*f*
- Rectouterine pouch, 347*f*
- Rectum, 15, 312*f*, 317, 318*f*
rat, **12**, 14*f*
- Rectus abdominis muscle, 132*f*, 136*t*, 137*f*
- Rectus femoris muscle, 132*f*, 140*t*, 141*f*
- Red blood cells (RBCs). *See* Erythrocytes (red blood cells/RBCs)
- Red marrow, **71**
- Reflex arcs, **189–190**, 189*f*
- Reflexes, 189–194
autonomic, **189**
somatic, **189**, 190–192
- Refraction, **201**, 201*f*
- Regions of abdominopelvic cavity, 5–6
- Releasing hormones of hypothalamus, 221, 222*f*
- Renal arteries, 260*f*, 262*t*, 263*f*, **331**, 332*f*, 333*f*, **334**
- Renal calculi (kidney stones), **336**
- Renal columns, **333**, 333*f*
- Renal corpuscle, **334**, 334*t*
- Renal cortex, **333**, 333*f*, 335*f*, 336*f*, 362*f*
- Renal fascia, 331
- Renal hilum, **331**, 332*f*, 333*f*
- Renal medulla, **333**, 333*f*, 335*f*
- Renal pelvis, **333**, 333*f*
- Renal pyramids, **333**, 333*f*
- Renal tubules, **334**, 335*f*, 336*f*, 362*f*
- Renal vein, 265*f*, **266**, 267*f*, **331**, 332*f*, 333*f*, **334**
- Repolarization, **155**, 156*f*
- Reproductive system, 10*t*, **343–354**.
See also specific organs
female, 10*t*, 225, 346–349, 347*f*, 348*f*, 358*f*, 363*f*
male, 10*t*, 225, 343–346, 344*f*, 346*f*, 362*f*, 363*f*
rat, 14*f*, 15
- Residual reserve (RV), 303*f*, **305**
- Resolution of compound light microscope, **368**
- Respiration, 291. *See also* Breathing
- Respiratory bronchioles, **293**, 293*f*, 359*f*
- Respiratory capacities, 303*f*
- Respiratory gas exchanges, 291, 294*f*
plasma membrane and, 29
- Respiratory membrane, **294**, 294*f*
- Respiratory system, 10*t*, 291–300
breathing mechanics, 301, 302*f*
circulatory system links to, 291, 306
conducting zone, **294**
functions (overview), 10*t*
lower structures, 293–296
lungs, 10*t*, 294, 295*f*, 296, 301–302, 359*f*
organs, 10*t*
other thoracic cavity organs and, 295*f*
physiology, 301–309
respiratory volume measurement, 302–305
respiratory zone, **294**
upper structures, 291–293, 292*f*
- Respiratory volume measurement, 302–305
- Respiratory zone structures, **294**
- Resting membrane potential, **155**, 156*f*
- Rete testis, **345**, 345*f*
- Reticular connective tissue, 42, 44*f*
- Reticular fibers, **42**, 44*f*
- Reticular dermis, 56*f*, **57**
- Retina, 197, 197*f*, 198*f*, 199*t*, 357*f*
cow eye, 199, 200*f*
- Rh blood group, 238
typing of, 238–239
- Rhomboid major muscle, 133*f*, 139*f*
- Ribosomes, 19, 20*f*, 21*t*
- Ribs, 68*f*, **88**, 88*f*
vertebrae and, 87, 88
- Right colic (hepatic) flexure, **317**, 318*f*
- Right lower quadrant (RLQ), 5, 6*f*
- Right upper quadrant (RUQ), 5, 6*f*
- Rinne tuning fork test, 206, 206*f*
- Risorius muscle, 135*f*
- RLQ (right lower quadrant), 5, 6*f*
- Rods and cones, **197**, 197*f*, 202, 357*f*
- Romberg test, 208–209
- Root
hair, 56*f*, **60**, 60*f*
of lung at hilum, 294, 295*f*
nail, 61*f*, 62
of tooth, **319**, 319*f*
- Root canal of tooth, **319**, 319*f*
- Root hair plexus (hair follicle receptor), 56*f*
- Rotation movement, **113**, 115*f*
- Rough endoplasmic reticulum (rough ER), 20*f*, 21*t*
of neurons (chromatophilic substance), **151**, 152*f*
- Round ligaments, **347**, 347*f*, 348*f*
- Round window, 203*f*, 207*f*
- Ruptured follicle, 348*f*
- RUQ (right upper quadrant), 5, 6*f*
- Sacculi, **207**, 207*f*
- Sacral arteries, 262*t*, 263*f*
- Sacral canal, **87**, 87*f*
- Sacral curvature, 84*f*
- Sacral foramina, **87**, 87*f*
- Sacral hiatus, **87**, 87*f*
- Sacral plexus, 184*f*, 185*t*, **186**, 186*f*
- Sacral promontory, **87**, 87*f*, 100*f*
- Sacral region, 3*f*
- Sacral spinal nerves, 182*f*, 184*f*
- Sacroiliac joints, 87, 100*f*, 101*t*
- Sacrum, 84, 84*f*, **87**, 87*f*, 100*f*
in females vs. males, 102*t*
- Saddle joint, 110*t*, 112*t*
- Sagittal plane, **4**
- Sagittal section, 4, 4*f*
- Sagittal sinus, 167, 168*f*
- Sagittal suture, **79**
- Saline, physiological, 33
- Saliva, 314–315, 319
- Salivary amylase, 314, 319, 321*f*
- Salivary glands, 10*t*, 312*f*, **314**, **319–320**, 361*f*
- Saphenous veins, **266**, 266*f*
- Sarcolemma, 121, 122*f*, 125, 125*f*, 250*f*
- Sarcomeres, **121**, 122*f*
- Sartorius muscle, 132*f*, 140*t*, 141*f*
- Satellite cells, **151**, 356*f*
- Scala media/scala vestibuli/scala tympani, 205*f*
- Scalp muscles, 134*t*, 135*f*
- Scanning lens of microscope, **366**
- Scaphoid bone, 99*f*, 111*f*
- Scapula, 68*f*, 95, 96*f*, 97*t*
as body landmark, 3
at shoulder joint, 111*f*
- Scar tissue, 42
- Schwann cells, 151, **152**, 152*f*, 153*f*, 356*f*
- Sciatic nerve, 185*t*, **186**, 186*f*
- Sciatic notches, 101*t*, 102*t*
- Sclera, 198*f*, 199*t*
cow eye, 200*f*
- Scleral venous sinus, **197**, 198*f*
- Scoliosis, 85, 85*f*
- Scrotum, 10*t*, **343**, 344*f*
rat, 14*f*, **15**
- Sebaceous (oil) glands, 56*f*, **59**, 60*f*
- Sebum, **59**
- Secondary follicles of ovary, 348*f*, **349**, 349*f*
- Sectioned specimens, observing, 4
- Sections, body, **4**, 4*f*
- Segmental arteries, 333*f*, **334**
- Segmental movements, 324
- Selective (differential) permeability, **29**
- Sella turcica, 81*f*, 81*t*
- Semen, 363*f*
- Semicircular canals, 203*f*, 204*t*, 207*f*
- Semicircular ducts, **207**, 207*f*
- Semilunar (SL) valves of heart, **246**, 247*f*
aortic, 247*f*, **248**
pulmonary, 247*f*, **248**
- Semimembranosus muscle, 133*f*, 142*t*, 143*f*
- Seminal fluid, **344**
- Seminal gland (vesicle), 344*f*, 344*t*
rat, 14*f*
- Seminiferous tubules, **345**, 345*f*, 363*f*
- Semitendinosus muscle, 133*f*, 142*t*, 143*f*
- Sense organs, cutaneous, 55
- Sensorineural deafness, 206
- Sensory (afferent) nerves, **157**
- Sensory (afferent) neurons, **154**, 155*f*
olfactory, **209**, 209*f*, 357*f*
in reflex arcs, 189, 189*f*, 190*f*
- Sensory (ascending) tracts, 182
- Sensory receptors, 155*f*
equilibrium, 207
hearing, 205
special. *See* Special senses
vision, 197, 197*f*
- Septum pellucidum, 166*f*
- Serosa (visceral peritoneum) of
alimentary canal, 312, 313*f*, 313*t*, **314**, 315*f*, 360*f*
- Serous pericardium, 245
- Serratus anterior muscle, 132*f*, 137*f*
- Sesamoid bones, of fingers, 99*f*
- Sex hormones (gonadocorticoids), 224*t*
- Shaft, hair, 60*f*, **61**, 61*f*
- Sharpey's (perforating) fibers, 70*f*, **71**, 73*f*
- Sheep brain dissection, 171–174, 173*f*, 174*f*
- Sheep heart dissection, 250–252, 251*f*
- Sheep kidney dissection, 333
- Sheep pluck, 296
- Short bones, **68**
- Shoulder
arteries, 260*f*, 262
bones, 68*f*, 95
joint, 96*f*, 97*t*, 110*t*, 111*f*, 112*f*, 112*t*
muscles, 132*f*, 133*f*, 136, 137, 137*f*, 138*t*, 139*f*
nerves, 184*f*, 185*t*
veins, 265*f*, 266–267, 268*f*
- Shoulder (pectoral) girdle, 68*f*, 95, 96*f*, 97*t*
palpating surface anatomy of, 98–99
- Sigmoid colon, 6*f*, 312*f*, **317**, 318*f*
- Silver nitrate, 32*t*
- Simple diffusion, **29**, 32
- Simple epithelia, 22*f*, **38**, 38*f*, 39*f*, 40*f*, 355*f*, 360*f*
- Sinus, bone marking, 69*t*
- Sinusoids, 362*f*
- Sister chromatids, **23**, 23*f*
- Skeletal muscles, **47**, **121**
attachment sites, 113, 113*f*, 124, 126
cells (fibers) of, **121–124**, 122*f*, 123*f*, 355*f*
connective tissue wrappings of, 124
contraction of, 121, 123–124
embryonic development, 23
fibers (cells) of, **121–124**, 355*f*
- microscopic structure, 121–124, 355*f*
naming criteria, 126
neuromuscular junction of, **124–126**, 125*f*
skeleton in relation to, 67
structure, 124–126
as tissue, 47, 47*f*
types of, 126
- Skeletal system
bones. *See* Bones
components, 10*t*
functions (overview), 10*t*
joints. *See* Joints
- Skeleton, **67–77**
appendicular, **67**, 68*f*, 95–108
axial, **67**, 68*f*, 79–94
bone markings, **67**, 69*t*
bone types, 67–71
cardiac, 245
construction of, 104
functions, 10*t*, 67
- Skin, 10*t*, **55–66**
accessory organs, 59–62
appendages, 56*f*
blood supply, 57
body temperature regulation by, 10*t*, 57
color, as indicators, 57, 283–285
effects of venous congestion, 284–285
functions, 10*t*, 55
microscopic examination, 61, 61*f*
nerve supply, 56*f*, 57–58
structure, 55–59, 56*f*
- Skull, 68*f*, **79–84**
cranial bones, 79–83
facial bones, 82*t*, 83
muscles covering, 134*t*, 135*f*
palpating bone markings, 83–84
- Small intestine, 6*f*, 10*t*, 15, 16*f*, 312*f*, **316**, 316*f*
digestive functions, 316–317, 321*f*
histology, 360*f*
mucosa of, 40*f*
peritoneal attachments, 316*f*
rat, **12**, 13*f*
structural modifications, 317*f*
- Smell sense (olfaction), 209–212
lab experiments, 211–212
receptors, 209–210, 209*f*, 357*f*
- Smooth endoplasmic reticulum, 20*f*, 21*t*
- Smooth muscle tissue, **47**, 48*f*
cells, 22*f*, 355*f*
of GI tract, 313*f*, 313*t*, 314, 315, 315*f*, 360*f*
of hair follicles, 61
of ureters, 362*f*
- Sodium ions (Na⁺)
in action potential (nerve impulse), 155, 156*f*
in muscle contraction, 125
- Sodium-potassium (Na⁺-K⁺) pump, 155, 156*f*
- Soft palate, 292*f*, 292*t*
- Soleus muscle, 132*f*, 133*f*, 141*f*, 142*t*
- Somatic reflexes, **189**, 190–192, 202
- Somatic sensory area, 164*f*
- Sound localization test, 205
- Sound waves, hearing and, 205
- Sounds of Korotkoff, **281**
- Special sense organs, 10*t*
- Special senses, 195–220. *See also* specific senses
equilibrium, 203, 207–209
hearing, 203–207
smell, 209–212
taste, 209, 210–212
vision, 195–203
- Specific gravity of urine, 336
- Sperm, 22*f*, 345, 346*f*, 363*f*
- Spermatic cord, **344**, 345*f*

- Sphenoid bone, 80f, 81f, 81t, 82f, 83f
 Sphenoidal sinus, 84f
 Sphygmomanometer, **281**, 281f
 Spinal cavity, **5**
 Spinal cord, 10r, 15, 16f, **181–183**, 182f, 183f
 cross-sectional view, 183f, 356f
 dissection, 182
 gray matter, **181–182**, 183f, 356f
 neuroglia, **151**
 white matter, **182**, 183f
 Spinal curvatures, 85, 85f
 abnormal, 85, 85f
 Spinal dura mater, 183f
 Spinal nerve plexuses, 184f, 185–186, 185t
 Spinal nerves, **182**, 182f, 183–184, 183f
 spinal cord and, 181, 182
 Spinal reflexes, **190–192**
 Spinalis muscle, 139f
 Spindle, mitotic, **23**, 23–24f
 Spindle pole, 23f
 Spine. *See* Vertebral column
 Spine, bone marking, 69t
 Spine of scapula, 96f, 97t, 99
 Spinous processes of vertebrae, 84f, **85**, 85f, 86f
 cervical, palpating, 86
 Spiral organ, 205, 205f, 207f, 357f
 Spirometers, **302**, 304f
 Spirometry measurements, 302–305
 Spleen, 6f, 10r, 15, 16f, 44f, 358f
 peritoneal attachments, 316f
 rat, 13f, **15**
 Splenic artery, 260f, 262t, 263f
 Splenic vein, **269**, 270f
 Splenius capitis muscle, 135f
 Spongy bone, **67**, 73f
 Spongy (penile) urethra, 332, **344**, 344f
 Squamous epithelia, **38**, 38f
 simple, 39f
 stratified, 41f
 Squamous suture, **79**, 80f
 Stapes (stirrup), 203f, 204t
 Stellate macrophages, **320**, 362f
 Stereocilia, 207f, 208f, 362f
 Sternal angle, 88f
 Sternal (medial) end of clavicle, 96f
 Sternal region, 2f
 Sternoclavicular joint, 96f
 palpating, 99
 Sternocleidomastoid muscle, 132f, 133f, 134t, 135f, 137f
 Sternohyoid muscle, 132f
 Sternum, 68f, **88**, 88f
 Steroid hormones, 221, 225
 Steroid synthesis site, 21t
 Stirrup (stapes), 203f, 204t
 Stomach, 5, 6f, 10r, 15, 16f, 312f, **315**, 315f, 360f
 digestion/absorption in, 321f
 digestive functions, 315–316
 histology, 40f, 315f, 355f, 360f
 mesenteries, 315–316, 316f
 mucosa of, 316–317, 355f
 peritoneal attachments, 316f
 rat, **12**, 13f
 Straight tubule of testis, 345f
 Stratified epithelia, **38**, 38f, 41f
 Stratum basale, 56f, 57t
 Stratum corneum, 56f, 57t, 61f
 Stratum germinativum.
 See Stratum basale
 Stratum granulosum, 56f, 57t
 Stratum lucidum, 56f, 57t
 Stratum spinosum, 56f, 57t
 Stretch reflexes, **190–191**
 Striations, muscle, 47, 47f
 Sty, 196t
 Styloid processes, 80f, 80r, 82f, 98f, 99
 Stylomastoid foramen, 82f
 Subacromial bursa, 112f
 Subarachnoid space, **167**, 168f
 Subclavian arteries, **259**, 259t, 260f, 261f
 Subclavian veins, 265f, **267**, 268f
 Subcostal arteries, 262t
 Subcutaneous layer (hypodermis), 43f, **55**, 56f, 60f
 Subdural space, **167**, 168f
 Sublingual glands, 312f, **319**, 361f
 Submandibular glands, 312f, **319**
 Submucosa of GI tract, 312, 313f, 313t, **314**, 317f, 360f, 361f
 Submucosal plexus (GI tract), 313f, 313t
 Subscapular artery, 261f
 Subscapular fossa, 96f, 97t
 Substrates of enzymes, **320**
 Sudoriferous (sweat) glands, 56f, **59**
 Sulci, cerebral, **163**, 164f
 Superficial cord reflexes, **191**
 Superficial direction/orientation, **3**
 Superior colliculi, corpora quadrigemina, **166**, 166f
 Superior orientation/direction, **3**, 3f
 Superior pubic ramus, 100f
 Superior sagittal sinus, **167**, 168f
 Superior vena cava, 246f, 247f, **248**, 248f, **265**, 265f
 sheep, 251f
 veins draining into, 266–267
 Supination movement, **113**, 115f
 Supporting cells (neuroglia) of nervous tissue, **151**
 of olfactory epithelium, **209**, 209f, 357f
 Supracondylar lines of femur, medial and lateral, 103t
 Supracondylar ridges of humerus, 98f
 Supraorbital foramen (notch), 80r, 83f
 Supraorbital margin, 83f
 Suprarenal arteries, 260f, 262t
 Suprarenal glands. *See* Adrenal glands
 Suprarenal veins, 263f, 265f, **266**, 267f
 Suprascapular artery, 261f
 Suprascapular notch, 96f, 97t
 Supraspinatus muscle, 139f
 Supraspinous fossa, 96f, 97t
 Sural region, 2f, 3
 Surface anatomy, 1–3, 2f
 body cavities, 5–6, 5f, 6f
 body landmarks, 1–3
 body orientation/direction, 3, 3f
 body planes, **4**, 4f
 body sections, **4**, 4f
 Surface epithelium, **348**, 349f, 363f
 Surfactant, alveolar, 293
 Surgical neck of humerus, **95**, 98f
 Suspensory ligaments
 lens, 198f, 199, 199t
 ovaries, **347**, 347f, 348f
 Sutures, 79, 110r, 111f
 Swallowing (deglutition), **323**
 Sweat pore, 56f, 59
 Sweat (sudoriferous) glands, 56f, **59**
 plotting sweat maps, 59–60
 Synphyses, 110r, 111f
 Synaptic cleft, **124–125**, 125f, **152**
 Synarthroses joints, **109**
 Synchondrosis, 110r, 111f
 Syndesmoses, 110r, 111f
 Syndrome of inappropriate ADH secretion, 226t
 Synergist muscles, **126**
 Synovial fluid, **110**
 Synovial joints, 109, **110–116**, 110r, 111f
 identifying types of, 112
 movements allowed by, 113–116, 114f
 Synovial membrane, 110, 112f
 Systemic circuit, **248**, 248f
 gas exchanges and, 248f, 291
 Systole, **277**, 278f, 279t
 Systolic blood pressure, **281–282**, 281f
 T lymphocytes or T cells, 225
 T₃ (triiodothyronine), 223t
 T₄ (thyroxine), 223t
 Tactile corpuscles, 56f, 57, 58, 356f
 Tactile localization, **58–59**
 Tactile epithelial (Merkel) cells, **57**
 Talus bone, 101, 104f
 tibia and, 101
 Tapetum lucidum, cow eye, **199**, 200f
 Target cells (target) of hormone, **221**
 Tarsal bones (tarsals), 68f, **101**, 104f
 Tarsal glands, 196f, 196t
 Tarsal region, 2f
 Taste buds, 37, **210**, 210f, 211, 357f
 Taste sense (gustation), 209, 210–212, 210f
 effects of smell/texture/temperature, 211–212
 identifying tongue papillae, 210
 sensory areas in brain for, 164f
 stimulating, 211
 taste buds of, 37, **210**, 210f, 211, 357f
 Tectorial membrane, **205**, 205f, 357f
 Teeth, 10r, 318–319, 319f
 Telophase stage of mitosis, **23**, 24f
 Temperature of foods, taste sense and, 212
 Temperature receptors, 57–58
 Temporal artery, as pulse point, 280, 280f
 Temporal bones, 79, 80f, 80r, 81f, 82f, 83f
 Temporal lobe, **163**, 164f, 165f
 Temporalis muscle, 131, 132f, 134t, 135f
 Temporomandibular joint, 84
 Tendinous intersection, 137f
 Tendon sheaths, 110, 112f
 Tendons, 10r, 42, 44f, 112f, **124**
 Tenia coli, 318f
 Tensile strength of bone matrix, 71
 Tensor fascia lata muscle, 132f, 141f
 Teres major muscle, 133f, 139f
 Teres minor muscle, 139f
 Terminal bronchioles, **293**, 293f
 Testes, 10r, 224r, 225, **343**, 344f, 345, 345f
 histology, 362f, 363f
 rat, 14f, **15**
 Testicular arteries, 260f, 262t, 263f
 Testicular veins, 265f, 266
 Testosterone, 224r, **225**
 Tetany, 226t
 TF (tissue factor), **237**, 237f
 Thalamus, 166f, **167**
 Thick filaments, 122f
 Thigh
 arteries, 264
 bone, 101, 103f
 muscles, 132f, 133f, 140–143, 140r, 141f, 142r, 143f
 nerves supply, 185r, 186, 186f
 veins, 265f, 266, 266f
 Thin filaments, 122f
 Thoracic aorta, **259**, 260f, 261f, 262, 262t
 Thoracic cage, 68f, **88**, 88f
 thoracic vertebrae, 84f, 86f, 87
 Thoracic cavity, **5**, 5f, **15**, 16f
 organs in, 295f
 rat, 12, 13f
 Thoracic curvature, 84f
 Thoracic organs, rat, 12, 13f
 Thoracic region, 2f
 Thoracic spinal nerves, 182f, 184f
 Thoracic vertebrae, 84f, 87
 regional features, 86f
 Thoracoacromial artery, 261f
 Thorax
 arteries, 260f, 261f, 262
 muscles, 132f, 136r, 137f, 138r
 veins, 267, 268f
 Threshold, **155**
 Throat, 293
 rat, 12
 Thrombin, **237**, 237f
 Thumb, 98, 99f, 112t
 Thymopoietin, **225**
 Thymosin, **225**
 Thymulin, **225**
 Thymus, 10r, 225, 226f
 rat, **12**, 13f
 Thyrocervical trunk, 261f
 Thyroglobulin, **223**
 Thyroid cartilage, 292f, **293**
 Thyroid gland, 10r, 15, 16f, 222f, 223, 226f
 effects of smell/texture/temperature, 211–212
 hormones, 223t
 Thyroid hormone (TH), 223t
 hyposecretion/hypersecretion of, 226t
 Thyroid-stimulating hormone (TSH), 222f, 222t, 223t
 Thyroxine (T₄), 223t
 Tibia, 68f, **101**, 103f, 104r
 Tibial arteries, **264**, 264f
 as pulse point, 280, 280f
 Tibial nerve, 185r, **186**, 186f
 Tibial tuberosity, 103f, 104r
 Tibial veins, **266**, 266f
 Tibialis anterior muscle, 132f, 140r, 141f, 142
 Tibiofibular joints, 103f, 103r
 Tidal volume (TV), 303f, **304**
 Tissue factor (TF), **237**, 237f
 Tissues, **9**, 37–54
 connective, 9, 37, **42**, 43–46f
 constructing concept map, 50, 50f
 epithelial, 9, 37–42
 muscle, 9, 37, **47**, 47f
 nervous, 9, 37, **49**, 49f
 Titin (elastic) filaments, 122f
 Toes, 2
 bones, 68f, 101, 104f
 muscles, 140r
 Tongue, 312f, **314**, 314f
 taste buds, **210**, 210f, 211, 357f
 Tonsillar crypts, 359f
 Tonsils, 10r, 292f, 292t, 314, 314f, 359f
 Total blood cell count, 234
 Total lung capacity (TLC), 303f
 Total magnification, **367**
 Total peripheral resistance, 282
 Touch receptors, 57, 58–59
 Trabeculae, 67, **72**, 73f
 Trabeculae carneae, 247f
 Trachea, 10r, 15, 16f, 40f, **293**, 296f, 359f
 rat, **12**, 13f
 Tracts, nerve fiber, 151, **182**
 CNS, **157**
 Transitional epithelia, **38**, 41f, 362f
 Transport mechanisms, cell, 29–36
 Transverse colon, 6f, 312f, **317**, 318f
 peritoneal attachments, 316f
 Transverse plane, **4**, 4f
 Transverse processes, vertebral, 84f, **85**, 85f, 86f
 Transverse ridges of sacrum, 87f
 Transverse section (cross section), **4**, 4f
 Transversus abdominis muscle, 132f, 136r, 137f
 Trapezium bone, 99f, 110r
 Trapezius muscle, 132f, 133f, 135f, 137, 137f, 138r, 139f
 Trapezoid bone, 99f
 Triceps brachii muscle, 132f, 133f, 138, 138r
 Tricuspid valve of heart, **246**, 247f

- Trigeminal nerves (V), 170*t*, 171*f*
 Trigone, **332**, 332*f*
 Triiodothyronine (T₃), 223*t*
 Triquetrum, 99*f*, 111*f*
 Trochanter, 69*t*
 Trochlea of humerus, 97*t*, 98*f*
 Trochlear nerve (IV), 170*t*, 171*f*
 Trochlear notch of ulna, 97*t*, 98*f*
 Tropic hormones, **221**, 222*t*
 True ribs, 88, 88*f*
 Trunk muscles, 131, 132*f*, 133*f*,
 136–137, 136*t*, 137*f*, 138*t*, 139*f*
 Trunk region of body, 1
 Trypsin, 321*f*, **322**
 assessing protein digestion by,
 322, 322*f*
 TSH (thyrotropic hormone), 222*f*,
 222*t*, 223*t*
 Tubercle, 69*t*
 of humerus, 97*t*, 98*f*
 Tuberosity, 69*t*
 Tunica albuginea, **345**, 345*f*, 348*f*,
 349*f*, 362*f*
 Tunica externa, **257**, 258*f*, 358*f*
 Tunica intima, **257**, 258*f*
 Tunica media, **257**, 258*f*, 358*f*
 Tunica vaginalis, **345**, 345*f*
 Tunics
 of alimentary canal, **312**, 313*f*, 314
 of blood vessel, 257, 258*f*, 358*f*
 Turbinates. *See* Nasal conchae
 Two-point threshold, **58**
 Tympanic cavity of middle ear, 204*t*
 Tympanic membrane (eardrum), 203*f*,
 204*t*
 otoscopic viewing, 204
- Ulna, 68*f*, 97*t*, 98*f*, 99*f*
 at elbow and wrist joints, 111*f*
 Ulnar artery, 261*f*, **262**
 Ulnar nerve, 184*f*, 185*t*, **186**
 Ulnar notch, 98*f*
 Ulnar styloid process, 97*t*, 98*f*
 Ulnar veins, **267**, 268*f*
 Umami, 210
 Umbilical region, 2*f*, **5**, 6*f*
 Umbilicus, 5
 Uniaxial joints, 111*f*, 113
 Uniaxial movement, **112**, 112*t*
 Unipolar (pseudounipolar) neurons,
154, 154*f*, 356*f*
 Upper limbs, 68*f*, 95
 arteries, 260*f*, 261*f*, 262
 bones, 95–99, 97*t*, 98*f*, 99*f*
 muscles, 132*f*, 133*f*, 136*t*, 137–138,
 137*f*, 138*t*, 139*f*
 nerve supply, 184*f*, 185*t*
 veins, 267, 268*f*
 Upper respiratory tract, 291–293,
 292*f*
 Ureteric orifices, 332*f*
 Ureters, 10*t*, 15, 16*f*, **331**, 332*f*, 362*f*
 rat, 14*f*, **15**
 Urethra, 10*t*, **332**
 female, 332*f*, 347*f*
 male, 332, 344, 344*f*
 Urethral orifice, external, **332**, 332*f*
 female, 346*t*, 347*f*
 male, 344*f*
 rat, 14*f*
 Urethral sphincters, **332**, 332*f*
 Urinalysis, 336–338
 Urinary bladder, 6*f*, 10*t*, 15, **332**, 332*f*
 rat, 12, 13*f*, 14*f*, **15**
 transitional epithelium lining, 41*f*
 Urinary system, **331**–342
 functions (overview), 10*t*
 kidney structure, 333, 333*f*
 nephron structure, 334–336, 335*f*
 organs, 10*t*, 331–332, 332*f*
 pig/sheep kidney dissection, 333
 urine, 336–338
 Urine, 336–338
 abnormal constituents, 337*t*
 sample analysis, 337–338
 solutes normally found in, 336
 Urochrome, 336
 Uterine horns, rat, 14*f*
 Uterine tubes, 10*t*, **347**, 347*f*, 348*f*, 363*f*
 Uterosacral ligaments, **347**, 347*f*, 348*f*
 Uterus, 10*t*, 15, **347**, 347*f*, 348*f*
 rat, 14*f*, **15**
 Utricle, **207**, 207*f*
 gravitational pull on macula
 receptor in, 208*f*
 Uvula, **314**, 314*f*
- Vagina, 10*t*, **346**, 347*f*
 rat, 14*f*
 Vaginal orifice, 347*f*
 rat, 14*f*, **15**
 Vagus nerve (X), 170, 170*t*, 171*f*, 192,
 210
 Vallate papillae, 210, 210*f*
 Vas (ductus) deferens, **344**, 344*f*, 345*f*
 rat, 14*f*, **15**
 Vasa recta, **334**
 Vasa vasorum, 258*f*
 Vascular layer of eye, **197**, 199*t*
 Vasodilation, oxygen and, 284
 Vastus intermedius muscle, 140*t*
 Vastus lateralis muscle, 132*f*, 140*t*, 141*f*
 Vastus medialis muscle, 132*f*, 140*t*, 141*f*
 Veins, 257–259, 258*f*, 258*t*, 265–267,
 268*f*, 358*f*
 factors affecting blood flow,
 284–285
 hepatic portal circulation, 269, 270*f*
 major, of body, 265–267, 268*f*
 microscopic examination, 259, 259*f*
 Venae cavae
 sheep, 251*f*
 superior/inferior, 246*f*, 247*f*, **248**,
 248*f*, **265**–267, 265*f*, 267*f*, 269*f*
 Venous congestion, effects of, 284–285
 Venous palmar arches, deep and
 superficial, 266*f*, **267**, 268*f*
 Ventilation. *See* Breathing
 Ventral (anterior) columns (funiculi) of
 spinal cord, **182**, 183*f*
 Ventral (anterior) horns, spinal cord,
181, 183*f*, 356*f*
 Ventral body cavity
 human, 5–6, 5*f*
 rat dissection, 11–15
 Ventral direction/orientation, **3**, 3*f*
 in animals, 3
 Ventral median fissure of spinal cord,
 183*f*, 356*f*
 Ventral rami of spinal nerves, **184**,
 184*f*, 185, 186
 Ventral roots, spinal cord, **182**, 183*f*
 Ventricles of heart, **246**, 246*f*, 247*f*, 248*f*
 sheep, 251*f*
 Venules, 258*t*
 Vertebra prominens, 86
 Vertebrae, 68*f*, **84**–87
 bone markings, 69*t*
 cervical, 85–86, 86*f*
 joints of, 111*f*
 lumbar, 87
 regional features, 86*f*
 structure of typical, 85
 thoracic, 87
 Vertebral arch, **85**, 85*f*
 Vertebral arteries, 86, 260*f*, 261*f*, **262**,
 269, **270**, 270*f*
 Vertebral column (spine), 3, 68*f*,
84–87, 84*f*
 curvatures, 85, 85*f*
 intervertebral discs, 84*f*, **85**
 joints, 111*f*
 vertebrae, 84–87
 Vertebral facets, 86*f*
 Vertebral foramen, **85**, 85*f*, 86*f*
 Vertebral veins, 265*f*, **266**
 Vesicouterine pouch, 347*f*
 Vesicular (antral) follicle, 348*f*, **349**,
 349*f*, 358*f*
 Vestibular apparatus, **207**
 Vestibular fold, 292*f*
 Vestibular glands, greater, 346*t*, 347*f*
 Vestibular membrane, **205**, 205*f*, 357*f*
 Vestibular nerve, 207*f*
 Vestibule
 of female genitals, 346*t*, 347*f*
 of inner ear, 203*f*, 204*t*, 207*f*
 oral, **314**, 314*f*
 Vestibulocochlear nerve (VIII), 170*t*,
 171*f*, 203*f*, 208*f*
 Villi, 314, **316**, 317*f*, 360*f*, 361*f*
 Virtual image in light microscopy,
367, 367*f*
 Visceral layer
 of glomerular capsule, 334*t*, 335*f*
 of pericardium (epicardium), **245**, 247*f*
 Visceral peritoneum, 312, 313*f*, 313*t*,
314, 315*f*, 360*f*
 Visceral pleura, **294**, 295*f*
 Vision
 eye anatomy, 195–200, 196*f*, 197*f*
 mechanism of, 201
 photoreceptors, **197**, 197*f*, 202
 role in equilibrium, 209
 sensory areas and related association
 areas in brain for, 164*f*
 Visual acuity, **201**
 Visual tests, 201–202
 Vital capacity (VC), 303*f*, **304**
 Vitamin D synthesis, skin and, 55
 Vitreous humor, **197**, 198*f*
 Vocal folds (true vocal cords), 292*f*,
293
 Volkmann's (perforating) canals, **72**,
 73*f*
 Voluntary muscles, 47, 47*f*
 Vomer, 82*f*, 82*t*, 83*f*
- Water, osmosis and, 29
 Water vacuoles in cell cytoplasm, 21
 WBCs (white blood cells).
See Leukocytes (white blood cells/
 WBCs)
 Weber tuning fork test, 206, 206*f*
 Wernicke's area, 164*f*
 Wet mount for microscope, 371–372
 White blood cells (WBCs).
See Leukocytes (white blood cells/
 WBCs)
 White columns of spinal cord, 182,
 183*f*
 White matter
 cerebral, 151, **164**, 164*f*
 spinal cord, **182**, 183*f*
 Whitefish blastulas, 24
 Wisdom teeth, 318, 319*f*
 Working distance of microscope, **368**,
 369*f*
 Wrist (carpus), 2, 98, 110*t*
 joint, 111*f*
 muscles, 136*t*, 137, 138*t*
- Xiphisternal joint, 88*f*
 Xiphoid process, **88**, 88*f*
- Yellow marrow, 70*f*, **71**
- Z disc (Z line), 121, 122*f*
 Zona pellucida, 348*f*, 358*f*
 Zygomatic arch, 80*t*, 83
 Zygomatic bone, 80*f*, 82*f*, 83, 83*f*
 Zygomatic bone paranasal sinuses,
 82*t*
 Zygomatic process, 80*f*, 80*t*, 82*f*
 Zygomaticus muscle, 132*f*, 134*t*,
 135*f*

Anatomy and Physiology

Laboratory Safety Guidelines*

1. Upon entering the laboratory, locate exits, fire extinguisher, fire blanket, chemical shower, eyewash station, first aid kit, containers for broken glass, and materials for cleaning up spills.
2. Do not eat, drink, smoke, handle contact lenses, store food, or apply cosmetics or lip balm in the laboratory. Restrain long hair, loose clothing, and dangling jewelry.
3. Students who are pregnant, are taking immunosuppressive drugs, or have any other medical conditions (e.g., diabetes, immunological defect) that might necessitate special precautions in the laboratory must inform the instructor immediately.
4. Wearing contact lenses in the laboratory is inadvisable because they do not provide eye protection and may trap material on the surface of the eye. Soft contact lenses may absorb volatile chemicals. If possible, wear regular eyeglasses instead.
5. Use safety glasses in all experiments involving liquids, aerosols, vapors, and gases.
6. Decontaminate work surfaces at the beginning and end of every lab period, using a commercially prepared disinfectant or 10% bleach solution. After labs involving dissection of preserved material, use hot soapy water or disinfectant.
7. Keep all liquids away from the edge of the lab bench to avoid spills. Clean up spills of viable materials using disinfectant or 10% bleach solution.
8. Properly label glassware and slides.
9. Use mechanical pipetting devices; mouth pipetting is prohibited.
10. Wear disposable gloves when handling blood and other body fluids, mucous membranes, and nonintact skin, and when touching items or surfaces soiled with blood or other body fluids. Change gloves between procedures. Wash hands immediately after removing gloves. (**Note:** Cover open cuts or scrapes with a sterile bandage before donning gloves.)
11. Place glassware and plasticware contaminated by blood and other body fluids in a disposable autoclave bag for decontamination by autoclaving, or place them directly into a 10% bleach solution before reuse or disposal. Place disposable materials such as gloves, mouthpieces, swabs, and toothpicks that have come into contact with body fluids into a disposable autoclave bag, and decontaminate before disposal.
12. To help prevent contamination by needlestick injuries, use only disposable needles and lancets. Do not bend the needles and lancets. Needles and lancets should be placed promptly in a labeled, puncture-resistant, leakproof container and decontaminated, preferably by autoclaving.
13. Do not leave heat sources unattended.
14. Report all spills or accidents, no matter how minor, to the instructor.
15. Never work alone in the laboratory.
16. Remove protective clothing before leaving the laboratory.

*Adapted from:

Biosafety in Microbiological and Biomedical Laboratories (BMBL), Fifth Edition. 2007. U.S. Government Printing Office. Washington, D.C. www.cdc.gov/od/OHS/biosfty/bmb15/bmb15toc.htm

Centers for Disease Control. 1996. "Universal Precautions for Prevention of Transmission of HIV and Other Blood-borne Infections." Washington, D.C. www.cdc.gov/ncidod/dhqp/bp_universal_precautions.html

Johnson, Ted, and Christine Case. 2010. *Laboratory Experiments in Microbiology*, Ninth Edition. San Francisco: Pearson Benjamin Cummings.

School Chemistry Laboratory Safety Guide. 2006. U.S. Consumer Product Safety Commission. Bethesda, MD. www.cpsc.gov/CPSPUB/PUBS/NIOSH2007107.pdf

The Metric System

Measurement	Unit and abbreviation	Metric equivalent	Metric to English conversion factor	English to metric conversion factor
Length	1 kilometer (km)	= 1000 (10^3) meters	1 km = 0.62 mile	1 mile = 1.61 km
	1 meter (m)	= 100 (10^2) centimeters = 1000 millimeters	1 m = 1.09 yards 1 m = 3.28 feet 1 m = 39.37 inches	1 yard = 0.914 m 1 foot = 0.305 m 1 foot = 30.5 cm 1 inch = 2.54 cm
	1 centimeter (cm)	= 0.01 (10^{-2}) meter	1 cm = 0.394 inch	
	1 millimeter (mm)	= 0.001 (10^{-3}) meter	1 mm = 0.039 inch	
	1 micrometer (μm) [formerly micron (μ)]	= 0.000001 (10^{-6}) meter		
	1 nanometer (nm) [formerly millimicron ($\text{m}\mu$)]	= 0.000000001 (10^{-9}) meter		
	1 angstrom (\AA)	= 0.0000000001 (10^{-10}) meter		
Area	1 square meter (m^2)	= 10,000 square centimeters	1 m^2 = 1.1960 square yards 1 m^2 = 10.764 square feet	1 square yard = 0.8361 m^2 1 square foot = 0.0929 m^2
	1 square centimeter (cm^2)	= 100 square millimeters	1 cm^2 = 0.155 square inch	1 square inch = 6.4516 cm^2
Mass	1 metric ton (t)	= 1000 kilograms	1 t = 1.103 ton	1 ton = 0.907 t
	1 kilogram (kg)	= 1000 grams	1 kg = 2.205 pounds	1 pound = 0.4536 kg
	1 gram (g)	= 1000 milligrams	1 g = 0.0353 ounce 1 g = 15.432 grains	1 ounce = 28.35 g
	1 milligram (mg)	= 0.001 gram	1 mg = approx. 0.015 grain	
	1 microgram (μg)	= 0.000001 gram		
Volume (solids)	1 cubic meter (m^3)	= 1,000,000 cubic centimeters	1 m^3 = 1.3080 cubic yards 1 m^3 = 35.315 cubic feet	1 cubic yard = 0.7646 m^3 1 cubic foot = 0.0283 m^3
	1 cubic centimeter (cm^3 or cc)	= 0.000001 cubic meter = 1 milliliter	1 cm^3 = 0.0610 cubic inch	1 cubic inch = 16.387 cm^3
	1 cubic millimeter (mm^3)	= 0.000000001 cubic meter		
Volume (liquids and gases)	1 kiloliter (kl or kL)	= 1000 liters	1 kL = 264.17 gallons	1 gallon = 3.785 L
	1 liter (l or L)	= 1000 milliliters	1 L = 0.264 gallon 1 L = 1.057 quarts	1 quart = 0.946 L
	1 milliliter (ml or mL)	= 0.001 liter = 1 cubic centimeter	1 ml = 0.034 fluid ounce 1 ml = approx. $\frac{1}{4}$ teaspoon 1 ml = approx. 15–16 drops (gtt.)	1 quart = 946 ml 1 pint = 473 ml 1 fluid ounce = 29.57 ml 1 teaspoon = approx. 5 ml
	1 microliter (μl or μL)	= 0.000001 liter		
Time	1 second (s or sec)	= $\frac{1}{60}$ minute		
	1 millisecond (ms or msec)	= 0.001 second		
Temperature	Degrees Celsius ($^{\circ}\text{C}$)		$^{\circ}\text{F} = \frac{9}{5} (^{\circ}\text{C}) + 32$	$^{\circ}\text{C} = \frac{5}{9} (^{\circ}\text{F} - 32)$